


A 2-7.02, 1900.1

Harvard University
Library of
The Medical School



The Gift of



CANCER OF THE UTERUS

*ITS PATHOLOGY, SYMPTOMATOLOGY,
DIAGNOSIS, AND TREATMENT*

ALSO

THE PATHOLOGY OF DISEASES
OF THE ENDOMETRIUM

BY

THOMAS STEPHEN CULLEN, M. B. (TORONTO)

ASSOCIATE PROFESSOR OF GYNÆCOLOGY IN
THE JOHNS HOPKINS UNIVERSITY

*WITH ELEVEN LITHOGRAPHIC PLATES AND OVER THREE HUNDRED
COLOURED AND BLACK ILLUSTRATIONS IN THE TEXT*

BY

MAX BRÖDEL AND HERMANN BECKER

NEW YORK
D. APPLETON AND COMPANY

1900



COPYRIGHT, 1900,
By D. APPLETON AND COMPANY.


All rights reserved.

RESPECTFULLY DEDICATED TO
MY TEACHERS,

HOWARD A. KELLY

AND

WILLIAM H. WELCH.



Digitized by the Internet Archive
in 2011 with funding from
Open Knowledge Commons and Harvard Medical School

<http://www.archive.org/details/cancerofuterusit00cull>

P R E F A C E

THE number of cases of cancer of the genital tract coming too late for operation is so appalling that the surgeon is ever seeking to devise ways and means by which the dread malady may be more generally detected at the earliest possible moment—at a time when complete removal of the malignant tissue is still possible. But since it is the general practitioner who, as a rule, is first consulted, upon him largely falls the responsibility of arriving at a timely diagnosis.

In the present volume it has been my aim to give the family physician a clear idea of the early signs of carcinoma, in order that he may always be on his guard, and may not treat too lightly any suspicious indications which may be present.

Even the skilled pathologist is sometimes in doubt as to the exact nature, benign or malignant, of a given scraping. Nevertheless, it is evident that a careful comparison of the clinical histories with the pathological findings in a large number of cases will undoubtedly allow him to speak with authority in the majority of instances.

From the abundant material at my disposal, and with the complete clinical histories easy of access, I have endeavoured to make a relatively simple classification of carcinoma of the uterus, and also to treat in detail of the various clinical and pathological conditions that may be confused with cancer.

In this work I have received the most hearty support and encouragement from Prof. Howard A. Kelly and Prof. William H. Welch.

It gives me much pleasure to acknowledge my indebtedness to Dr. Henry M. Hurd for many valuable suggestions. Dr. Elizabeth Hurdon has helped me throughout in the preparation of the pathological material. Miss Elizabeth Thies and Miss Eleanor H. Watts have given efficient aid in the arrangement of the subject-matter and in the preparation of the indices.

Dr. Frank R. Smith has been kind enough to thoroughly revise the manuscript and correct the proofs.

It is impossible for me to adequately thank my friends, Mr. Max Brödel and Mr. Hermann Becker, for their excellent drawings and for many practical suggestions.

With the publishers, Messrs. D. Appleton and Company, my relations have been most cordial. My thanks are especially due to them for their untiring efforts to obtain the best possible reproduction of the drawings.

JOHNS HOPKINS HOSPITAL,
BALTIMORE. *June 15, 1900.*

C O N T E N T S

CHAPTER	PAGE
I. INTRODUCTORY	1
II. ANATOMY OF THE UTERUS	5
III. THE REMOVAL AND EXAMINATION OF UTERINE TISSUES FOR DIAGNOSTIC PURPOSES .	27
IV. SQUAMOUS-CELL CARCINOMA OF THE CERVIX	40
V. SQUAMOUS-CELL CARCINOMA OF THE CERVIX (CONTINUED). EXTENSION TO ADJOIN- ING STRUCTURES. CONDITION OF THE TUBES AND OVARIES. INVOLVEMENT OF THE LYMPH GLANDS. AUTOPSY FINDINGS	124
VI. CLINICAL ASPECTS IN SQUAMOUS-CELL CARCINOMA OF THE CERVIX	174
VII. DIFFERENTIAL DIAGNOSIS IN SQUAMOUS-CELL CARCINOMA OF THE CERVIX	179
VIII. TREATMENT OF SQUAMOUS-CELL CARCINOMA OF THE CERVIX	211
IX. ADENO-CARCINOMA OF THE CERVIX	280
X. ADENO-CARCINOMA OF THE CERVIX. ORGANS SECONDARILY INVOLVED. AUTOPSY FINDINGS	326
XI. THE CLINICAL HISTORY IN CASES OF ADENO-CARCINOMA OF THE CERVIX	334
XII. DIFFERENTIAL DIAGNOSIS IN ADENO-CARCINOMA OF THE CERVIX	339
XIII. ADENO-CARCINOMA OF THE BODY OF THE UTERUS	353
XIV. ADENO-CARCINOMA OF THE BODY OF THE UTERUS (CONTINUED).	409
XV. OTHER PATHOLOGICAL PROCESSES IN THE BODY OF THE UTERUS, SOMETIMES ASSOCI- ATED WITH ADENO-CARCINOMA	439
XVI. THE SYMPTOMATOLOGY OF ADENO-CARCINOMA OF THE BODY OF THE UTERUS	472
XVII. THE DIFFERENTIAL DIAGNOSIS IN ADENO-CARCINOMA OF THE BODY OF THE UTERUS	476
XVIII. TREATMENT OF CARCINOMA OF THE BODY OF THE UTERUS.	573
XIX. PRIMARY SQUAMOUS-CELL CARCINOMA OF THE BODY OF THE UTERUS	578
XX. A RARE VARIETY OF ADENO-CARCINOMA OF THE UTERUS	587
XXI. COINCIDENT APPEARANCE OF CARCINOMA IN THE CERVIX AND IN THE BODY OF THE UTERUS	592
XXII. DECIDUOMA MALIGNUM. SARCOMA UTERI DECIDUO-CELLULARE (SÄNGER).	595
XXIII. PREGNANCY COMPLICATING CARCINOMA OF THE CERVIX	611
XXIV. CLINICAL PHENOMENA COMMON TO ALL VARIETIES OF CARCINOMA OF THE UTERUS .	625
XXV. PROGNOSIS	631
XXVI. ÆTIOLGY OF CARCINOMA	647
XXVII. INOCULATION EXPERIMENTS BEARING UPON THE NATURE AND ÆTIOLGY OF CARCI- NOMA	658
APPENDIX. A PLEA FOR THE EARLY DIAGNOSIS OF MALIGNANT DISEASE OF THE UTERUS	665

LIST OF ILLUSTRATIONS

FIG.	PAGE
1. The normal adult uterus on sagittal section	5
2. The normal uterus opened anteriorly	6
3. Longitudinal section of the pelvis in the adult woman	7
4. Origin of the uterine artery and its relations to the ureter	9
5. Relations of the pelvic organs	10
6. Blood supply of the uterus	11
7. The sacral plexus <i>in situ</i>	12
8. Vascular trunks of the lower abdomen	13
9. Lymphatics of the uterus	15
10. Normal vaginal portion of the cervix	17
11. A transverse section of the cervix at a point one centimetre within the external os	18
12. A normal cervical gland	19
13. Normal cervical mucosa just within the external os	20
14. Normal endometrium from a patient forty-one years of age	21
15. Normal endometrium from a patient thirty-three years of age	21
16. Schematic representation of a normal uterine gland	22
17. Normal endometrium after the menopause or following the removal of the appendages	22
18. Normal endometrium in a patient twenty-six years of age	23
19. A small projection upward from the bottom of a normal gland	24
20. A normal gland with a branched projection going upward from its base	24
21. Projections into the gland cavities from their sides and bases	25
22. Normal uterine gland	26
23. Three-pronged tenaculum forceps for drawing down and holding the cervix	27
24. Goodell-Ellinger dilator with spring instead of ratchet	28
25. The dilating ends of the three sizes of the Ellinger and Goodell-Ellinger dilators	28
26. Small sharp curette	28
27. Long sharp curette	29
28. Complete apparatus for making frozen sections	30
29. Method of opening the uterus	34
30. Appearance of the normal uterus when opened in the manner shown in Fig. 29	35
31. Early squamous-cell carcinoma of the cervix	42
32. A "cauliflower" mass springing from the anterior cervical lip	43
33. Advanced squamous-cell carcinoma of the cervix	44
34. Changes in the epithelium along the margin of a squamous-cell carcinoma of the cervix	46
35. Epithelial pearls	49
36. Cross sections of the finger-like growths in squamous-cell carcinoma of the cervix	50
37. Scheme demonstrating the manner in which squamous-cell carcinoma of the cervix develops	52
38 A. Cell-nest, showing disintegration of its centre	53
38 B. Invasion of a very large cancer cell by polymorphonuclear leucocytes	54
38 C. An oblique section of a finger-like process near its base	54
39. Squamous-cell carcinoma of the cervix	55
PLATE I. Squamous-cell carcinoma of the cervix, showing its point of junction with the normal mucosa of the vaginal portion	56

FIG.	PAGE
40. Squamous-cell carcinoma of the cervix, showing the advancing margin and the knob-like projections from the surface	56
41. Suspicious changes in the epithelium along the outer margin of a squamous-cell carcinoma of the cervix	57
42. Transition of normal into carcinomatous epithelium in squamous-cell carcinoma of the cervix	58
43. Partial obliteration of a cervical gland by squamous-cell carcinoma of the cervix	59
44. Squamous-cell carcinoma of the cervix, mode of extension	60
45. Squamous-cell carcinoma of the cervix, cauliflower-like mass springing from the anterior lip	62
46. A section of the cauliflower-like mass seen in Fig. 45	63
47. A typical cauliflower growth springing from the anterior cervical lip in squamous-cell carcinoma of the cervix	67
48. A longitudinal section of one of the many finger-like outgrowths which form the cauliflower growth of Fig. 47	68
PLATE II. Fresh specimen of squamous-cell carcinoma of the cervix; polypoid formation of the uterine mucosa	
49. Squamous-cell carcinoma of the cervix	75
50. Squamous-cell carcinoma of the cervix, with loss of the cervical landmarks	80
51. Longitudinal and cross sections of finger-like outgrowths in squamous-cell carcinoma of the cervix	81
52. Appearance on section of a squamous-cell carcinoma of the cervix	83
53. Cross sections of four finger-like outgrowths in a squamous-cell carcinoma of the cervix	84
54. Cell changes in squamous-cell carcinoma of the cervix	89
55. Squamous-cell carcinoma of the cervix; finger-like processes arising from a common stem	91
56. Partial obliteration of the cervical glands in squamous-cell carcinoma of the cervix	93
57. A portion of a cell-nest, showing the characteristic epithelium and giant cells	95
58. A very large cell containing a large, irregular mass of chromatin	96
59. Squamous-cell carcinoma of the cervix, with giant cells in the cell-nests and lying free in the stroma	97
60. Nuclear division in cancer cells	99
61. A cell-nest (frequently spoken of as an alveolus) in squamous-cell carcinoma of the cervix	102
62. Cross section of a finger-like outgrowth near its base	103
63. Squamous-cell carcinoma of the cervix, showing filling up of the depressions on the surface with pus cells and detritus	107
64. Scirrhous squamous-cell carcinoma of the cervix	109
65. A mass of cancer cells lying in a lymph vessel	112
66. Pyometra and physometra due to closure of the cervical canal in squamous-cell carcinoma of the cervix	116
67. Squamous-cell carcinoma of the cervix, with commencing pyometra	117
68. Giant cells occurring in squamous-cell carcinoma of the cervix	118
69. Passive involvement of uterine gland in squamous-cell carcinoma of the cervix	119
70. Tuberculous peritonitis associated with squamous-cell carcinoma of the cervix	122
71. Squamous-cell carcinoma of the cervix, with extension to the vagina	127
PLATE III. Squamous-cell carcinoma of the cervix	129
PLATE IV. Squamous-cell carcinoma of the uterus: autopsy specimen	131
72. Squamous-cell carcinoma of the cervix associated with multiple uterine myomata	133
73. Carcinoma of the bladder secondary to squamous-cell carcinoma of the cervix	135
74. Invasion of a myoma by squamous-cell carcinoma of the cervix	136
75. Cell degenerations occurring in squamous-cell carcinoma of the cervix	137
76. A very large carcinomatous cell showing characteristic degeneration	138
77. A typical cell formation in squamous-cell carcinoma of the cervix	139
78. Carcinoma of the ovary secondary to squamous-cell carcinoma of the cervix	140
79. Involvement of the broad ligaments in squamous-cell carcinoma of the cervix	142

FIG.	PAGE
80. Carcinoma of the bladder secondary to squamous-cell carcinoma of the cervix	144
81. Squamous-cell carcinoma of the cervix with extension to the bladder and rectum: vesico-vaginal fistula	146
82. A vesico-vaginal fistula, seen from above, resulting from the squamous-cell carcinoma of the cervix	147
83. Remarkably large cell-nests in squamous-cell carcinoma of the cervix	151
84. Carcinoma of the Fallopian tube secondary to squamous-cell carcinoma of the cervix	157
85. Metastases in a pelvic lymph gland following squamous-cell carcinoma of the cervix	159
86. Carcinoma of a pelvic lymph gland secondary to squamous-cell carcinoma of the cervix	161
87. Pyometra complicating squamous-cell carcinoma of the cervix	167
88. A late stage of squamous-cell carcinoma of the cervix	168
89. Double hydro-ureter due to pressure exerted by a squamous-cell carcinoma of the cervix	170
90. Hydro-ureter caused by a squamous-cell carcinoma of the cervix	171
PLATE V. Eversion of the cervical mucosa—the so-called erosion	180
91. Margin of an ulcer in the vaginal portion of the cervix	181
92. Slight erosion of the cervical portion of the cervix	182
93. An apparent cell-nest due to a fold in the mucosa	183
94. A picture somewhat resembling squamous-cell carcinoma, due to distortion of the epi- thelium by the curette	184
95. Section from an hypertrophied cervix	186
96. Dilatation of the glands of the cervix	187
97. Cross section of a silk ligature	188
98. Sloughing submucous myoma	190
PLATE VI. Tuberculosis of the uterus and tubes	193
99. Condylomata and tuberculosis of the cervix and vaginal vault	195
100. Condylomata and tuberculosis of the cervix	196
101. Condylomata and tuberculosis of the cervix	197
102. Sarcoma of the cervix	198
103. Sarcoma of the cervix	201
104. Sarcoma of the cervix	202
105. Advanced squamous-cell carcinoma of the cervix	205
106. Squamous-cell carcinoma of the cervix suggesting adeno-carcinoma on account of its situation	208
107. Epithelial cells in squamous-cell carcinoma of the cervix	209
108. Kelly's urethral calibrator and dilator	214
109. Kelly's cystoscope with the end cut obliquely; the obturator is inserted	215
110. Examination of the bladder with the patient in the knee-chest posture	215
111. Using the goniometer	216
112. Kelly's ureteral searcher	216
113. Inner surface of the bladder as seen from the abdominal cavity	217
114. Passing a metal ureteral catheter into the left ureteral orifice, which is exposed in the lumen of the speculum	218
115. The catheterization of the ureters in hysterectomy for cancer of the cervix	219
116. Diagram showing a case of carcinoma of the cervix in which the bougie cannot be made to pass into the ureter	220
117. Scheme showing the steps in a radical operation for cancer of the cervix	224
118. The clear space	225
119. Abdominal hysterectomy for cancer of the cervix	226
120. Abdominal hysterectomy for cancer of the cervix	227
PLATE VII. Removal of the lymph glands in the radical operation for cancer of the uterus	228
121. The uterus and glands as removed in a radical operation	228
122. A semi-diagrammatic illustration of the first step in Werder's operation	229

FIG.	PAGE
123. The second step in Werder's operation	231
124. Introducing normal salt solution under the breast	234
125. Ligation of the internal iliac or uterine arteries	238
126. Squamous-cell carcinoma of the cervix: dilatation of the uterine cavity due to pyometra	243
127. Lateral uretero-ureteral anastomosis in a dog	246
128. Uretero-ureteral anastomosis	247
129. Uretero-ureteral anastomosis	248
130. Uterus enucleated <i>per vaginam</i>	254
131. Three sizes of silk used	254
132. Partial prolapse of the uterus and vagina with an elongated and lacerated cervix	255
133. Vaginal hysterectomy, step 1	256
134. Vaginal hysterectomy, step 2	257
135. Vaginal hysterectomy, step 3	258
136. Blunt aneurismal needle with left curve	258
137. Vaginal hysterectomy, step 4	259
138. End of the stout blunt tenaculum	260
139. Vaginal hysterectomy, step 5	261
140. Vaginal hysterectomy, step 6	262
141. Vaginal hysterectomy, step 7	263
142. Vaginal hysterectomy, step 8	264
143. Advanced squamous-cell carcinoma of the cervix	266
144. Advanced squamous-cell carcinoma of the cervix	267
145. Recto-vaginal and vesico-vaginal fistula caused by the accidental removal of portions of the bladder and rectum in vaginal hysterectomy; complete occlusion of the ureters by scar tissue around the vesico-vaginal opening	268
146. Branches of the internal iliac artery	275
147. Very early adeno-carcinoma of the cervix	285
148. Right uretero-cystostomy for uretero-vaginal fistula following hysterectomy for cancer of the cervix	287
149. Uretero-cystostomy	288
150. Adeno-carcinoma of the cervix	289
151. Early changes in the cylindrical surface epithelium in adeno-carcinoma of the cervix	290
152. Adeno-carcinoma of the cervix	292
153. Early gland changes in adeno-carcinoma of the cervix	293
154. A gland showing marked branching in adeno-carcinoma of the cervix	296
155. A carcinomatous gland in adeno-carcinoma of the cervix	300
156. Adeno-carcinoma of the cervix with extension to a polyp and to both uterine horns	306
157. Adeno-carcinoma of the cervix	307
158. Adeno-carcinoma of the cervix	308
159. Adeno-carcinoma in a uterine polyp, secondary to adeno-carcinoma of the cervix	309
160. Adeno-carcinoma in the uterine horn, secondary to adeno-carcinoma of the cervix	310
161. Pyometra associated with adeno-carcinoma of the cervix	313
162. Adeno-carcinoma of the cervix; only slight involvement of the vaginal portion	315
163. Carcinomatous glands in adeno-carcinoma of the cervix	316
164. A mass of cancer cells projecting into a blood-vessel of the broad ligament in a case of adeno-carcinoma of the cervix	317
165. Proliferation of the gland epithelium in adeno-carcinoma of the cervix with formation of solid nests resembling those of squamous-cell carcinoma	321
166. Probable commencing adeno-carcinoma of the body of the uterus independent of the adeno-carcinoma of the cervix	322
167. Adeno-carcinoma of the cervix secondary to carcinoma of the ovary	324
168. Metastases in a pelvic lymph gland in a case of adeno-carcinoma of the cervix	329
169. Adeno-carcinoma of the body of the uterus	330

FIG.	PAGE
170. Compression of a double left ureter in advanced adeno-carcinoma of the cervix	331
171. Adeno-carcinoma of the liver secondary to that of the cervix	332
172. Thickening of the cylindrical cervical epithelium on the surface and around the glands	338
173. A giant cell in the wall of the cervical gland	340
174. A cervical polyp	341
175. A cervical polyp	342
176. Polyp springing from the posterior lip of the cervix	343
177. A cervical polyp	344
178. Endothelioma of the cervix	350
179. Endothelioma of the cervix	351
180. Endothelioma of the cervix	352
181. One of the delicate branching outgrowths so often seen macroscopically in adeno-carcinoma of the body of the uterus	357
182. Adeno-carcinoma of the body of the uterus diagnosed from a small scraping	358
183. Adeno-carcinoma of the body of the uterus; scrapings from which the condition shown in Fig. 184 was diagnosed	362
184. Early adeno-carcinoma of the body of the uterus diagnosed from scrapings shown in Fig. 183	363
185. Early adeno-carcinoma of the body of the uterus	365
186. Early adeno-carcinoma of the body of the uterus; dilated cervical glands	367
187. Earliest change in the gland epithelium in adeno-carcinoma of the body	369
188. Proliferation of the gland epithelium with the formation of new glands in adeno-carcinoma of the body of the uterus	370
189. Adeno-carcinoma of the body of the uterus; scrapings from which the condition represented in Fig. 190 was diagnosed	372
190. Early adeno-carcinoma of the body of the uterus, diagnosed from scrapings represented in Fig. 189	373
191. Early adeno-carcinoma of the body of the uterus	374
192. Adeno-carcinoma of the body of the uterus; scrapings from which the condition represented in Fig. 193 was diagnosed	376
193. Adeno-carcinoma of the body of the uterus	377
194. Proliferation of the surface epithelium along the edge of an adeno-carcinoma of the body of the uterus	378
195. Early changes in the surface epithelium along the margin of an adeno-carcinoma of the body of the uterus	378
196. Changes in the mucosa along the margin of an adeno-carcinoma of the body of the uterus	379
PLATE VIII. Early adeno-carcinoma of the body of the uterus	380
197. Outgrowths from the surface of the mucosa along the margin of an adeno-carcinoma of the body of the uterus	380
198. An isolated finger-like outgrowth in adeno-carcinoma of the body of the uterus	381
199. Proliferation of the surface epithelium resembling squamous epithelium, but belonging to adeno-carcinoma of the body of the uterus	381
200. A group of carcinomatous glands deep down in the uterine muscle, and showing marked proliferation of cells resembling squamous epithelium	382
201. Adeno-carcinoma of the body of the uterus	384
202. Necrosis of the surface of an adeno-carcinoma of the body of the uterus	385
203. Adeno-carcinoma of the body of the uterus, showing calcareous plates both in the glands and in the surrounding muscle	387
204. Adeno-carcinoma of the body of the uterus	389
205. Adeno-carcinoma presumably of the body of the uterus	391
206. Adeno-carcinoma probably originating in the body of the uterus; a scraping from the uterus represented in Fig. 205	392
207. Adeno-carcinoma of the body of the uterus with extension to the peritoneal surface	394
208. Adeno-carcinoma of the body of the uterus	395

FIG.	PAGE
209. Adeno-carcinoma of the body of the uterus originating from proliferation of the surface epithelium	396
210. Adeno-carcinoma of the body of the uterus	399
211. Adeno-carcinoma of the body of the uterus with only a faint gland-like arrangement	400
212. Adeno-carcinoma of the body of the uterus showing an unusual polypoid formation	402
213. Adeno-carcinoma of the body of the uterus with excessive formation of polypi	403
214. Early changes in the surface and gland epithelium in adeno-carcinoma of the body of the uterus	404
215. Adeno-carcinoma of the body of the uterus	406
216. Giant cells lying in the glands of an adeno-carcinoma of the body of the uterus	407
217. Calculus removed from the uterine cavity during curettage	412
218. Adeno-carcinoma of the posterior vaginal wall secondary to adeno-carcinoma of the body of the uterus	416
219. Adeno-carcinoma of the vagina secondary to adeno-carcinoma of the body of the uterus	417
220. Atypical proliferation of the gland epithelium with formation of new glands in adeno-carcinoma of the body of the uterus	418
221. The manner in which new glands are frequently formed in adeno-carcinoma of the body of the uterus	419
222. Adeno-carcinoma of the body of the uterus with extension to the left round ligament	422
223. Adeno-carcinoma of the body of the uterus commencing near the internal os	425
224. Adeno-carcinoma of a pelvic lymph gland in adeno-carcinoma of the body of the uterus	427
225. Two utero-vaginal fistulæ turned into the bladder by a plastic operation	428
226. Completion of a plastic operation by which two uretero-vaginal fistulæ, situated in the upper part of the vaginal vault, have been successfully turned into the bladder	429
227. A carcinomatous gland containing giant cells, from a case of adeno-carcinoma of the body of the uterus	432
228. Adeno-carcinoma in a myoma, secondary to adeno-carcinoma of the body of the uterus	433
229. Adeno-carcinoma of the lymph glands of the neck, secondary to adeno-carcinoma of the body of the uterus	434
230. A scraping showing indications of the presence of a malignant growth in the uterus, represented in Fig. 231	441
231. Adeno-carcinoma of the body of the uterus associated with large myomata	442
232. Adeno-carcinoma of the body of the uterus over a submucous myoma	443
233. Adeno-carcinoma of the body of the uterus still limited to the superficial portion of the mucosa	445
234. New glands developed in the tips of finger-like projections in adeno-carcinoma of the body of the uterus	446
235. The tips of two finger-like projections in adeno-carcinoma of the body of the uterus	447
236. A large myomatous uterus, showing also an adeno-carcinoma of the body	451
237. Adeno-carcinoma of the body of the uterus associated with interstitial myomata	454
238. Cervical endometritis occurring in a case of adeno-carcinoma of the body of the uterus	455
239. Chronic endometritis in a case of adeno-carcinoma of the body of the uterus	457
240. Parallel glands in adeno-carcinoma of the body of the uterus bearing some resemblance to syncytial ribbons in deciduoma malignum	458
241. Adeno-carcinoma of the body of the uterus associated with a small subperitoneal adeno-myoma	460
242. Adeno-carcinoma of the body of the uterus showing remarkably well-preserved glands	462
243. A large myomatous uterus choking the pelvis; small ovarian cysts on both sides; thickening and retraction of the omentum; metastases in the liver secondary to an adeno-carcinoma in the body of the uterus	464
244. An enlarged myomatous uterus; adeno-carcinoma of the body of the uterus: papillo-cystomata of both ovaries with extension by continuity to the inguinal glands	466
245. Suspicious changes in the uterine mucosa resulting from imperfect hardening	477
246. Normal uterine glands deep down in the muscle	478

FIG.	PAGE
247. Large venous sinuses in the uterine mucosa causing severe hæmorrhages	480
248. Slight polypoid formation due entirely to excessive thickness of normal mucosa	482
249. Histological appearances of a uterine polyp	482
250. Cross section of a very large uterine polyp in a case of myoma	484
251. Cross section of a large uterine polyp in a case of myoma	484
252. A small uterine polyp	485
253. Giant cells in the wall of a dilated gland, from a uterine polyp	487
254. Hypertrophy of the uterine glands	489
255. Moderate gland hypertrophy occurring in a myomatous uterus	490
256. Hypertrophy of the uterine glands	491
257. Hypertrophy of the uterine glands	493
258. Hypertrophy of the uterine glands	494
259. Normal placenta at about the sixth week	497
260. A normal placenta at about the twelfth week	498
261. Normal placenta (at about the twelfth week) showing the syncytial buds, cross sections of which produce the so-called placental giant cells	499
262. Appearances of the villi in a placenta which has been retained for some weeks in the uterine cavity	501
263. Gland hypertrophy occurring in pregnancy	502
264. Normal decidua	504
265. Development of decidual cells from the endothelium of the blood-vessels	505
266. Decidual giant cells in the muscle	506
267. Decidual giant cells in the underlying uterine muscle	509
268. Polypoid endometritis	514
269. Polypoid endometritis	515
270. Polypoid endometritis	516
271. Slight proliferation of the surface epithelium with the formation of a new gland in a case of endometritis of the body of the uterus	520
272. A small, knob-like outgrowth from the mucosa of the body of the uterus in a case of endometritis	521
273. A small outgrowth from the surface of the mucosa in endometritis of the body of the uterus	523
274. New glands developing from the surface epithelium in endometritis of the body of the uterus	524
275. An area of thickened surface epithelium, strongly suggestive of squamous-cell carci- noma, in a case of endometritis of the body of the uterus	526
276. Localized thickenings of the surface epithelium in endometritis	528
277. Localized proliferation of the gland epithelium in acute endometritis	529
278. Localized thickening of the surface epithelium, suggesting squamous epithelium, in endometritis in the body of the uterus	530
279. Certain changes in the blood-vessels which sometimes occur in endometritis	531
280. Changes in the walls of the blood-vessels in endometritis, producing a picture sugges- tive of tuberculosis	532
281. Changes in the capillary walls in endometritis	533
282. Diffuse adeno-myoma of the anterior uterine wall	537
PLATE IX. Diffuse adeno-myoma of the anterior uterine wall	538
283. A small, circumscribed sarcoma of the body of the uterus	548
284. A round-cell sarcoma of the body of the uterus	550
285. A round-cell sarcoma of the body of the uterus	552
286. Round-cell sarcoma of the body of the uterus	553
287. Sarcoma of the body of the uterus secondary to that in the right ovary	556
288. Secondary sarcoma of the body of the uterus with the protrusion of a portion of it through the external os	557
289. Angio-sarcoma of the ovary with extension to the body of the uterus	559

FIG.	PAGE
290. Sarcoma of the body of the uterus, secondary to sarcoma of the ovary	560
PLATE X. Tuberculosis of the endometrium	563
291. Photomicrograph of a section taken from the fundus of the uterus in Case 3,193	565
292. Scrapings from a tuberculous cervix	566
293. A suspicious but benign area from a scraping	571
294. Adeno-myoma of the round ligament	575
295. Adeno-myoma of the round ligament	576
296. Squamous-cell carcinoma of the cervix with extension to the body of the uterus	584
297. Thickening of the vaginal epithelium in the neighbourhood of a squamous-cell carcinoma	585
298. Extension of a squamous-cell carcinoma of the cervix along the surface of the endometrium in the body of the uterus	586
299. Adeno-carcinoma of the uterus	589
PLATE XI. A rare form of adeno-carcinoma of the uterus	590
300. Carcinoma of the Fallopian tube secondary to that in the uterus	591
301. Alveolar arrangement in a deciduoma malignum	604
302. Isolated tumour cells in deciduoma malignum	605
303. Syncytial masses invading a venous channel in a case of deciduoma malignum	606
304. Vaginal metastases in deciduoma malignum	607
305. Squamous-cell carcinoma of cervix in a pregnant uterus at full term	620
306. Squamous-cell carcinoma of cervix with definite formation of decidual cells from the stroma of the cervix	622
307. Extension of a squamous-cell carcinoma of the cervix to the body of the uterus, in a case of pregnancy	623
308. Papillomata of both ovaries	661
309. A papillary growth transplanted to the abdominal wall by a trocar introduced to relieve ascites	662
310. Papillo-cystoma of the abdominal wall, secondary to that of the ovary, transplanted by a trocar	663

CANCER OF THE UTERUS

CHAPTER I

INTRODUCTORY

1. Historical sketch.
2. Frequency of carcinoma of the uterus.
3. Sources of our material.
4. Varieties of carcinoma of the uterus.

ALTHOUGH carcinoma was described by pathologists early in the present century, its epithelial origin was not definitely established. Robin* was probably one of the first to demonstrate that the morbid process had its commencement in the epithelium. In an article on Some Gland Hypertrophies, published in 1852, in speaking of certain tumours of the cervix, he says: "There is an infiltration of the tissue by epithelium. The elements of the tissue atrophy, and where there is friability of the diseased structures the epithelium is more abundant than the other elements. When ulceration commences there is rapid proliferation of the tissue. The ulceration is fetid. It is important to operate early." Cornil,† in 1865, in his Contributions to the History of the Histological Development of Epithelial Tumours, also showed clearly the epithelial origin of squamous-cell carcinoma. In speaking of a tumour of the breast, he says: "This anatomical protocol which we have submitted to the control of the members of the Biological Society, and especially to M. Robin, shows absolutely that the mammary tumour, which we call scirrhus, consists primarily in an increased production of the gland epithelium."

In 1865 Thiersch‡ published his valuable monograph on epithelioma of the skin.

But although Robin, Cornil, and Thiersch showed that epitheliomata were derivatives of the squamous epithelium, the starting-point of other carcinomata as yet remained unsettled, many authorities still believing that they were of con-

* Robin. *Sur quelques hypertrophies glandulaires.* *Gaz. d. hôp.*, Paris, 1852, t. xxv, p. 41.

† Cornil, Victor. *Contributions à l'histoire du développement histologique des tumeurs épithéliales*, 31 pp., 4 pl., 8vo, Paris [1865].

‡ Thiersch, C. *Der Epithelialkrebs, namentlich der Haut. Eine anatomisch-klinische Untersuchung. Mit einem Atlas mikroskopischer Abbildungen*, xvi, 310 pp., 8vo; Atlas, 11 1., 11 Taf., 4to, Leipzig, 1865.

nective-tissue origin. It remained for Waldeyer* to demonstrate most conclusively that all carcinomata owe their development to a proliferation of epithelium.

The extensive monograph on carcinoma of the cervix, published by Wagner, † of Leipzig, in 1858, although it appeared at a time at which the epithelial origin of carcinoma was not yet firmly established, was characterized by the utmost fidelity of description, and contained even the minutest histological details. Even at the present time his work remains the most exhaustive that we possess on squamous-cell carcinoma of the cervix, and in the preparation of the following chapters I have frequently drawn from his rich storehouse. The next epoch-making article was that by Ruge and Veit, ‡ the first part of which appeared in 1878, the remainder at a later date. This article, and that of Sir John Williams, § published in London in 1888, are among the best known. The literature on carcinoma of the uterus has now reached tremendous proportions. I have tried as far as possible to cover it in my reading, but shall make no attempt to utilize it, except in filling up various gaps not illustrated by our own cases.

Before the histological basis of cancer had been discovered, these growths were supposed by many to represent simply local manifestations of a constitutional dyscrasia, some claiming that the virus was present in the blood, and that even if the affected organ was removed the cancer would nevertheless develop at some distant site. We now know that in the beginning cancer is essentially a local process, and that the apparently independent growths occurring later in other organs are really metastases from the primary tumour. This point has been proved not only by histological studies, but also by clinical experience, since if the primary growth can be removed by operation, before metastases have taken place, the patient is permanently cured. To this further reference will be made in the chapter on Prognosis.

The Frequency of Carcinoma.—Roger Williams, who has made numerous statistical studies, ventures the assertion that cancer is four times as common as it was fifty years ago. But since his observations in many instances were based on cases in which no histological examination was made, there is considerable room for error. Nevertheless, there does appear to be an increase in the frequency of malignant growths.

Welch, || wishing to determine the relative frequency of carcinoma of the stomach and uterus, has made a most exhaustive analysis of the literature. In the accompanying table he has collected from various sources over 31,000 cases of cancer.

* Waldeyer, H. *Die Entwicklung der Carcinome.* *Virchow's Arch.*, 1867, Bd. xli, S. 470; and 1872, Bd. lv.

† Wagner, Ernst. *Der Gebärmutterkrebs. Eine pathologisch-anatomische Monographie*, vi, 169 pp., 2 Taf., 8vo, Leipzig, 1858.

‡ Ruge u. Veit. *Zur Pathologie der Vaginalportion*, *Zeitschr. f. Geburtsh. u. Gynäk.*, 1878, Bd. ii, S. 415. *Der Krebs der Gebärmutter*, *Zeitschr. f. Geburtsh. u. Gynäk.*, 1881, Bd. vi, S. 261.

§ Williams, John. *On Cancer of the Uterus, being the Harveian Lectures for 1886*, 119 pp., 18 pl., 8vo, London, 1888.

|| Welch, William H. *Cancer of the Stomach.* *Pepper's System of Med.*, vol. ii, p. 533.

PRIMARY CANCERS.	Stomach.	Uterus.
11,131 in Vienna.....	10 per cent.	31 per cent.
7,150 in New York.....	25.7 "	24.2 "
9,118 in Paris (Tanchou).....	25.2 "	32.8 "
1,378 in Paris (Salle).....	31.9 "	32 "
587 in Berlin.....	35.8 "	25 "
183 in Würzburg.....	34.9 "	19 "
1,046 in Prague.....	37.6 "	33.3 "
889 in Geneva.....	45 "	15.6 "
31,482 total.....	21.4 per cent.	29.5 per cent.

Commenting on this large group of cases, Welch says: "From this table it appears that in some collections of cases the uterus is the most frequent seat of primary cancer, while in other collections the stomach takes the first rank. If the sum total of all the cases be taken, the conclusion would be that about one fifth of all primary cancers are seated in the stomach, and somewhat less than one third in the uterus. Even if allowance be made for the apparently too low percentage of cases of gastric cancer in the large Vienna statistics, I should still be inclined to place the uterus first in the list of organs most frequently affected with primary cancer, and to estimate the frequency of gastric cancer compared with that of primary cancer elsewhere as not over twenty-five per cent." Similar averages have been obtained by Orth* and others.

During a period of less than six years (May, 1893, to April, 1899) we have met with one hundred and eighty-two cases of cancer of the uterus; one hundred and twenty-eight were of the squamous-cell type, nineteen were adeno-carcinomata of the cervix, and thirty-five adeno-carcinomata of the body. Cancer of the uterus is so prevalent that nearly all general practitioners see at least two or three cases yearly, and it is upon the family physician that we must rely to recognise the early symptoms and to indicate to the patient the appropriate treatment. Without his assistance the gynæcologist will almost invariably see the case only when the disease is too far advanced to permit of a complete removal of the morbid growth.

We have thought it advisable to enter somewhat in detail into the gross and histological appearances of the normal uterus, as without a clear idea of the normal structures it is very difficult to thoroughly comprehend the various pathological changes. For the gross anatomy we have made free use of the illustrations from Kelly's *Operative Gynæcology*.

Sources of our Material.—With but few exceptions, the material utilized in our studies came from the gynæcological operating room of the Johns Hopkins Hospital and from Dr. Kelly's private sanatorium. The operations were performed by Dr. Kelly, Dr. William W. Russell, Dr. John G. Clark, Dr. Otto Ramsay, Dr. J. Ernest Stokes, and myself. I am under especial obligations to my chief and my colleagues for their kindness in refraining from mutilating the specimens. Thanks to their forethought, practically all have been sent to the labora-

* Orth, J. *Lehrbuch der speciellen pathologischen Anatomie*, 1893, Bd. ii, S. 472.

tory unopened, and hence the finer structures of the various tissues were preserved intact. Professor Welch was good enough to place all the laboratory records at my disposal, and the greater part of the autopsies were performed by Dr. Welch, Dr. William T. Councilman, Dr. Simon Flexner, and Dr. L. F. Barker.

The illustrations are faithful reproductions of the original tumours. The majority of the gross specimens were hardened in Müller's fluid before being drawn, since it was found that in the fresh state the delicate finger-like processes were so frequently glued together by blood and mucus that they could readily be overlooked; whereas in specimens hardened in Müller's fluid these finer points stand out prominently. The histological pictures are absolute reproductions of the original slides. The majority of the specimens were stained with hæmatoxylin and eosin. The gross specimens and the slides from which the drawings have been made are permanently preserved, and are always open for inspection.

Before undertaking the study of cancer of the uterus we were impressed with the many varieties described. In endeavouring to arrive at a classification which should be as simple as possible, we have been able to include all cancerous growths of the uterus in one or other of the four following groups:

1. Squamous-cell carcinoma of the cervix.
2. Adeno-carcinoma of the cervix.
3. Adeno-carcinoma of the body.
4. Squamous-cell carcinoma of the body (rare).

For the sake of convenience, the organs secondarily involved, the autopsy findings, and the condition of the tubes and ovaries have been considered in other chapters.

In dealing with the differential diagnosis of carcinoma of the cervix we have thoroughly sifted all the hospital material for the past seven years, and have taken into consideration all growths that might be mistaken for carcinoma.

The chapter on Differential Diagnosis of Cancer of the Body of the Uterus contains a description of nearly every disease of the endometrium.

The general practitioner will, I fear, be somewhat surprised at the small space accorded to symptomatology; but after thoroughly analyzing our own cases, and studying the records of others, we find that diagnostic symptoms at best are meagre, and in the early stages give little or no clue to the real nature of the disease. Hence the value of curettage when there is the slightest uterine hæmorrhage that cannot be satisfactorily explained. We have endeavoured, as far as possible, to adapt the pathological findings to the clinical picture, and *vice versa*. In the chapter on Treatment we have not given all the various operative procedures which have been suggested, but only those which have been found most satisfactory at the Johns Hopkins Hospital.

A short chapter has been devoted to *deciduoma malignum*, as it probably belongs to the epithelial growths, at least in all cases where syncytium is found.

The chapter on Inoculation Experiments is introduced chiefly to demonstrate to the surgeon the great care that should be adopted to avoid transplantation of carcinoma cells into the wound during operation.

CHAPTER II

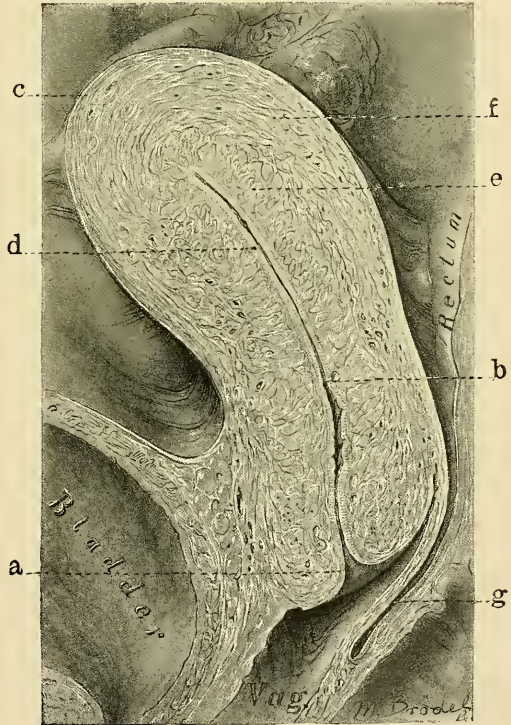
ANATOMY OF THE UTERUS

1. Gross anatomy of the uterus: (1) Of the body; (2) of the cervix; (3) of the cervical canal; (4) of the uterine cavity; (5) situation of the uterus; (6) uterine arteries; (7) uterine veins; (8) nerves of the uterus; (9) relations of the ureter; (10) lymphatics of the uterus.
2. Histology of the uterine mucosa: (1) Of the vaginal portion; (2) of the cervical portion; (3) of the endometrium; (4) changes in the endometrium at the menstrual period.

THE uterus in the adult is pyriform in shape (Fig. 1), averaging about 8 centimetres in length, and from 4 to 5 centimetres in its greatest transverse diameter. Its posterior surface is convex, the anterior aspect being flattened or slightly concave. The upper two thirds of the organ make up what is known

FIG. 1.—THE NORMAL ADULT UTERUS ON SAGITTAL SECTION. (Natural size.)

The uterus is slightly bent forward toward the bladder. The rounded cervix anteriorly is flush with the vaginal vault; posteriorly there is a distinct cleft. *a* marks the situation of the external os; *b* is the internal os. The remaining portion constitutes the body of the uterus, and the convex upper surface, *e*, indicates the fundus. The uterine mucosa is easily recognised at *d*. It is here represented as being about 1 millimetre thick, but often reaches 2 to 3 millimetres in depth. The inner muscular zone is indicated by *e*, the outer by *f*; Douglas's cul-de-sac is seen at point *g*. If the close relationship between the cervix, bladder, and vaginal vault be noted, it will readily be seen how cancer of the cervix can extend to these organs by direct continuity; posteriorly the growth must first travel down the vagina before the rectum is implicated, direct extension being only possible when the tissues have previously become adherent to the rectum.



as the body, or *corpus uteri*, the remaining third being formed by the cervix. The upper part of the body, together with its convex surface, is usually spoken of as the fundus (Fig. 1, *f*). Anteriorly over its upper two thirds, and posteri-

only over almost the entire surface, the uterus is covered by peritoneum. The uterine walls vary from 1.3 to 2 centimetres in thickness. In the body the muscular walls may be divided into three fairly well-defined layers: an inner longi-

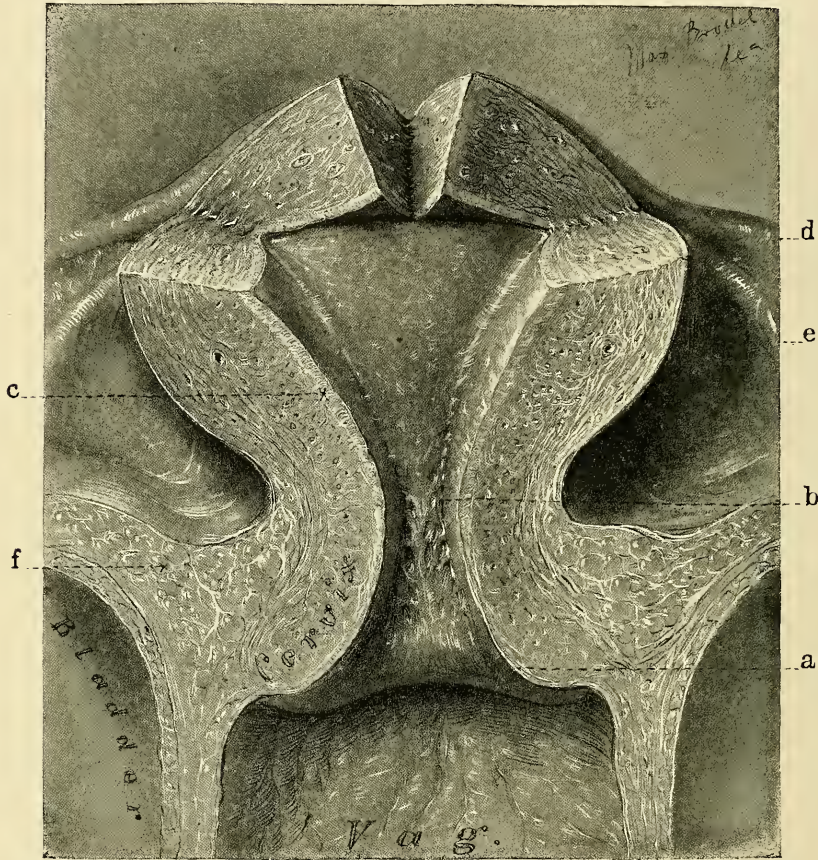


FIG. 2.—THE NORMAL UTERUS OPENED ANTERIORLY. (Natural size.)

The slightly corrugated vagina is seen in the lower part of the drawing. To the right is the right half of the bladder, to the left the corresponding half. The vaginal portion of the cervix presents the characteristic convex appearance; the external os is situated at *a*; the mucosa lining the canal at this point, when laid out flat, measures over 2 centimetres in breadth. *b* represents the internal os. The mucosa lining the cervical canal shows an ill-defined longitudinal ridge with delicate, somewhat indistinct, ridges passing off laterally. This is the so-called *arbor vite*, much more prominent in the virgin than in women who have borne children. The uterine cavity in this specimen is nearly 4 centimetres in length, and measures 4 centimetres in breadth in the vicinity of the horns. It forms a fairly well-defined triangle with the apex directed downward. The mucosa is everywhere perfectly smooth; near the internal os it is slightly more than 1 millimetre, while at *c* it is 2 millimetres in thickness. The uterine walls in this specimen vary from 1.5 to 2 centimetres in thickness; the muscular fibres are shown running in all directions. *d* is the Fallopian tube; *e*, the round ligament. Had the specimen not included the vagina or bladder it would still be possible to determine that the uterus has been opened anteriorly, since the round ligament is found in front of the tube.

tudinal, lying in direct contact with the mucosa; a middle layer, much thicker, consisting of bundles of fibres having a somewhat circular arrangement, and containing many large veins; and an outer muscular layer, composed chiefly of longi-

itudinally arranged fibres. When the tissue has been submitted to a process of maceration these various layers can be fairly well outlined, and numerous subdivisions can be made. But on examining a longitudinal section of the uterus, fibres are seen running in all directions, while projecting from the cut surface are numerous cross sections of blood-vessels (Figs. 1 and 2).

The cervix projects on an average about 1 centimetre from the vaginal wall, and when viewed from below has a rounded snout-like appearance. It varies from 2 to 3 centimetres in diameter, is pinkish in colour, and is arbitrarily divided into an anterior and a posterior lip, the latter being usually a little longer and thinner. In the centre of the cervix is seen a small opening, which may be cir-

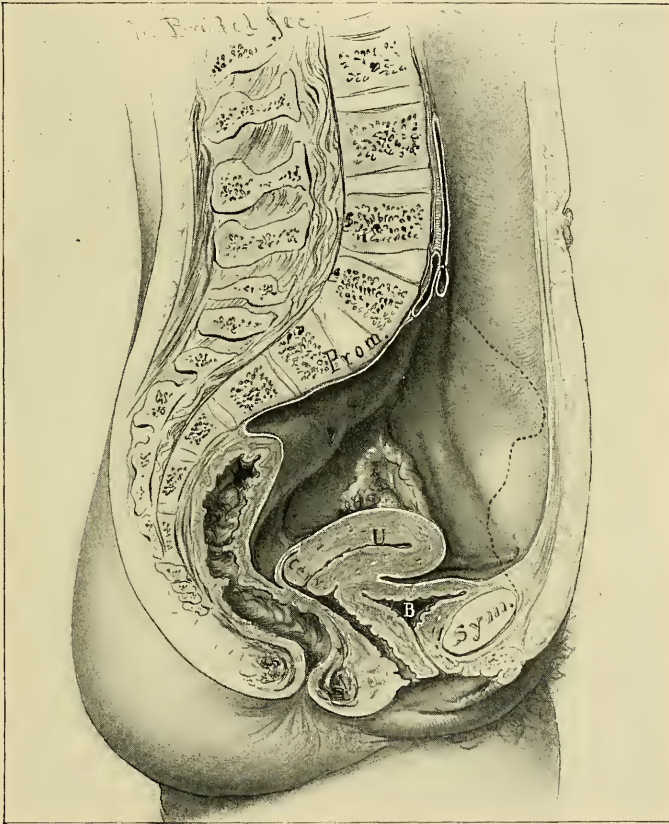


FIG. 3.—LONGITUDINAL SECTION OF THE PELVIS IN THE ADULT WOMAN. ($\frac{1}{3}$ natural size.)

Just posterior to the symphysis pubis the urethra is seen passing from the contracted and thick-walled bladder, *B*. Posterior and parallel to the urethra is the vagina with its convoluted walls. The uterus is in its normal position, being slightly anteverted. The cervix points downward and backward toward the rectum. Attached to the left side of the uterus are the corresponding tube and ovary. A portion of the rectum is seen; two of its valves stand out prominently. The dotted lines indicate the bony pelvic contour. (After H. A. KELLY.)

cular, and measure about 3 millimetres in diameter, but which more frequently appears as a slit with a transverse measurement of about 8 to 10 millimetres.

This represents the outer orifice of the cervical canal, and is known as the external os (Fig. 1, *a*). In women that have borne children there is invariably some slight laceration of the cervix, the slit-like opening being continued outward in one or both directions, according as the laceration has been unilateral or bilateral. As a consequence of such tears the lips become everted, and a considerable portion of the bright red inner mucosa is seen. This stands out in sharp contrast to the mucous membrane covering the outer or vaginal portion of the cervix.

For the sake of clearness, the interior of the uterine body and the cervical canal will be described separately, although they together form one continuous cavity. The cervical canal extends from the external os to the internal os (Figs. 1 and 2, *a, b*). At both these points there is some narrowing. The mucosa has a reddish hue, when examined *in situ*, but as seen in the laboratory is yellow and translucent. It presents a distinctly arborescent appearance. Traversing both the anterior and posterior surfaces are several longitudinal folds with secondary branchings, which are given off obliquely. These corrugations constitute the *arbor vitæ*. The tissue of the cervix is much denser than that of the body of the uterus, and even with the naked eye a partial or complete absence of muscle is readily determined. The exact thickness of the mucosa is difficult to determine without the microscope. Scattered throughout the cervix, in many cases, are cyst-like spaces varying from 1 to 10 millimetres in diameter, and filled with mucus. These represent the so-called Nabothian follicles, and occur so frequently that they can hardly be called pathological. At the internal os the cervical mucosa passes over almost imperceptibly into that of the body.

The uterine cavity consists of a narrow space between the anterior and posterior uterine walls. In shape it forms a triangle, the apex corresponding to the internal os, the base to the fundus. It averages 4 centimetres in length, and varies from 3 to 4 centimetres in breadth, where the cavity extends into the cornu. The mucosa is yellowish pink in colour, and presents a velvety and comparatively smooth surface, although on careful scrutiny small depressions are here and there visible—the mouths of the uterine glands. It varies from 1 to 3 millimetres in thickness; its thinnest point is near the internal os, the maximum thickness is in the vicinity of the fundus.

Situation of the Uterus.—In the child the uterus is an abdominal organ, but in adult life it occupies one third of the pelvis and lies between the bladder and rectum. Normally it is anteflexed, the body resting gently on the bladder, while the cervix points backward and downward toward the rectum (Fig. 3). As can readily be gathered from the drawing, in proportion as the bladder fills with urine, the body of the uterus is pushed backward, while the cervix is gradually tilted upward and forward. It will also be noted that the upper half of the anterior surface of the uterus is free, but that the lower part of the body and the upper segment of the cervix are fastened to the bladder. This attachment is rather lax and is supplied by loose connective tissue (Figs. 1 and 2), which sometimes contains a considerable amount of fat. Anteriorly, posteriorly, and laterally the cervix is loosely attached to the vaginal vault and the adjacent connective tissue, the mucosa of the vagina passing imperceptibly into that of the vaginal portion of the cervix. This close relationship between the cervix and

vaginal vault must always be clearly borne in mind in the consideration of malignant growths of the cervix.

The peritoneum is thrown as a mantle over the uterus. On referring to Fig. 3, it will be seen that the upper half of the anterior surface, the fundus,

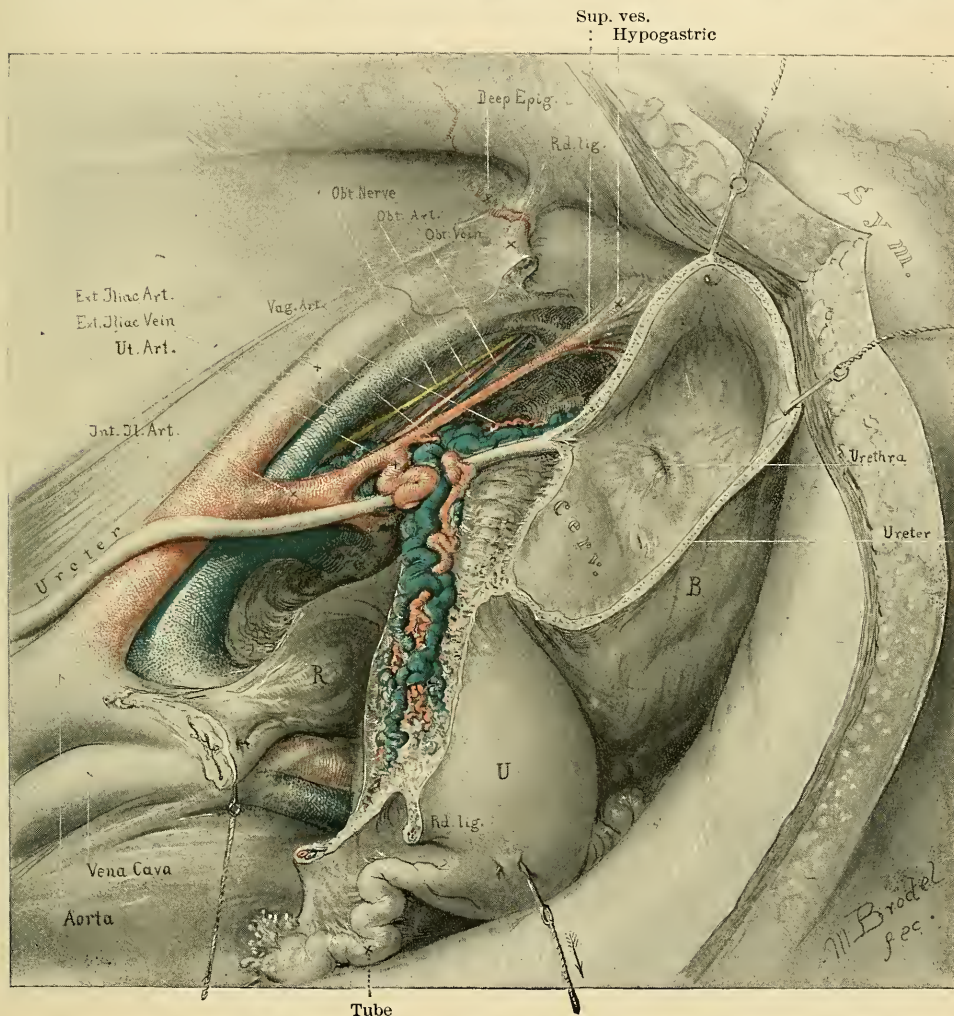


FIG. 4.—ORIGIN OF THE UTERINE ARTERY AND ITS RELATION TO THE URETER. ($\frac{2}{3}$ natural size.)

The left side of the uterus has been dissected free and drawn to the right. The internal iliac artery is seen arising from the common iliac, and is traced to the point where it divides into its anterior and posterior branches. The uterine artery arises from the anterior branch, immediately becomes very tortuous, passes over to the side of the cervix, and then courses over the side of the uterus between the folds of the broad ligament, being intimately entwined with the uterine veins. The left ureter is seen, as it passes over the pelvic brim, lying just to the inner side of the internal iliac artery. It courses beneath the uterine vessels and enters obliquely into the bladder. The inner urethral orifice is clearly seen; with the two ureteral orifices it forms a distinct triangle. (After H. A. KELLY.)

and practically the entire posterior surface, is covered by it. Laterally the serosa envelops the tubes and the round ligaments and forms the chief constituent of the

broad ligaments. In the space between these folds of the peritoneum are found the arteries, veins, lymphatics, and nerves, which pass to and from the uterus. The broad ligaments also contain a moderate number of muscle bundles and a varying quantity of fat. In spare individuals there is little difficulty in isolat-

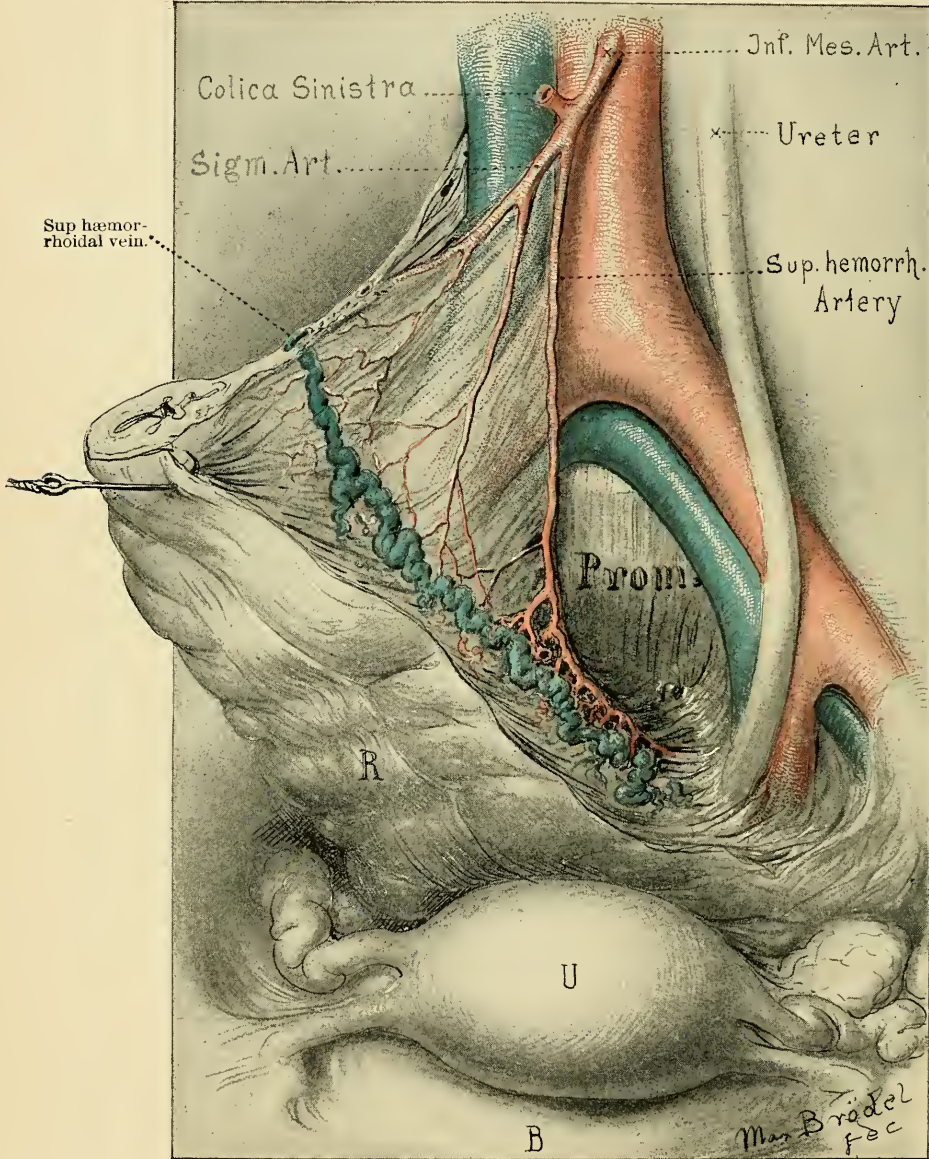


FIG. 5.—RELATIONS OF THE PELVIC ORGANS. (Natural size.)

The rectum has been dissected away and drawn to the right. The exact distance of the uterus from the promontory of the sacrum is well shown. In advanced cases of cancer of the cervix almost the whole lower rectal segment may be involved, while the lower part of the sacrum is encroached upon. The exact position of the ureter as it passes over the pelvic brim is clearly outlined. It is at this point that the situation of the ureter can be most readily detected, and if the peritoneum be split, its course can be easily followed into the pelvis. (After H. A. KELLY.)

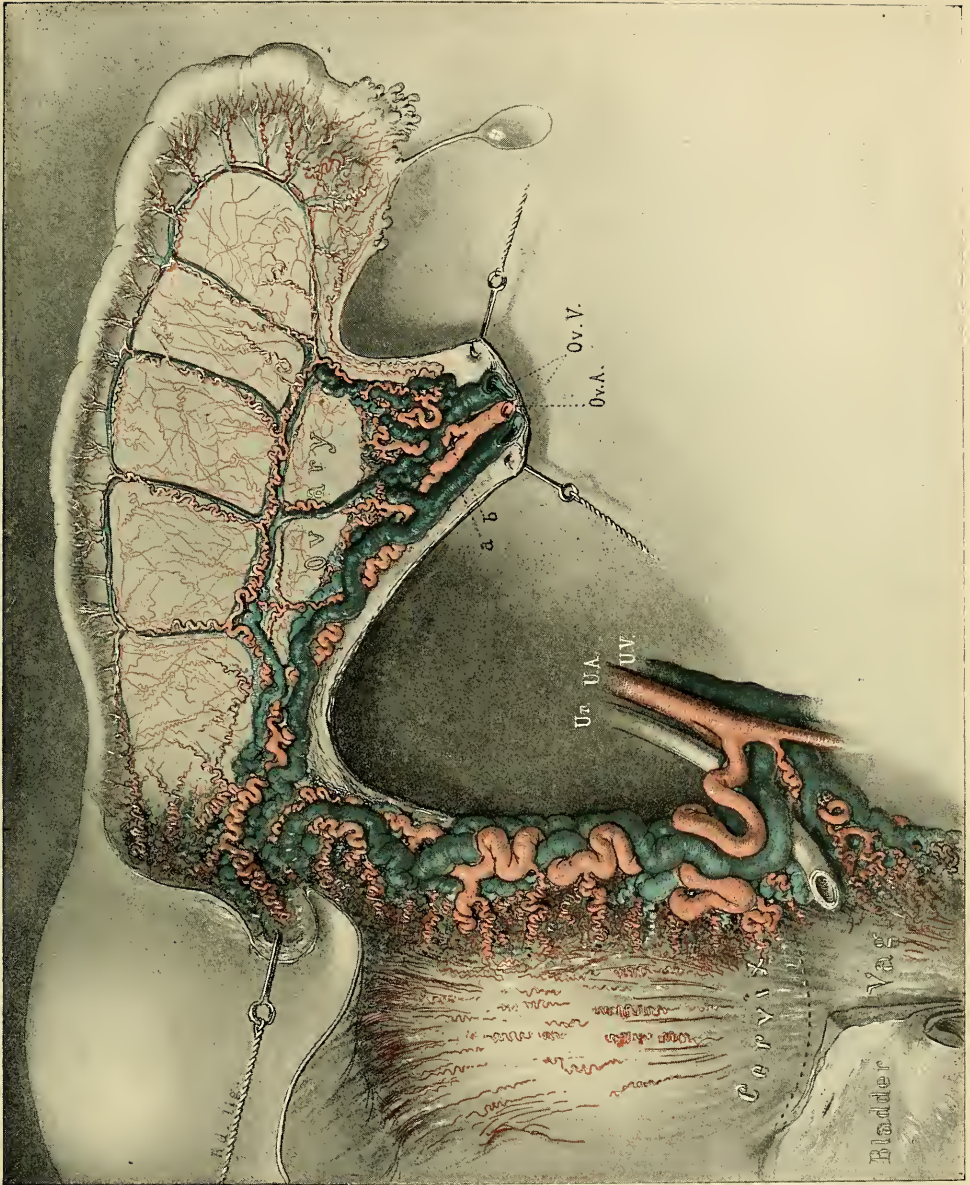


FIG. 6.—BLOOD SUPPLY OF THE UTERUS. (Natural size.)

The uterine artery passes almost transversely from the side of the pelvic wall to the cervix, where it gives off a large branch. It is exceedingly tortuous throughout its entire extent. Passing up the side of the uterus it gives off numerous branches into the muscle, which anastomose freely with those of the artery of the opposite side. Near the cornu the anastomosis is so free that the uterine and ovarian arteries are directly continuous with one another. The ovarian artery enters the pelvis in the suspensory ligament, and divides, just before it reaches the hilum, into two branches, *a* and *b*. The main branch on reaching the utero-ovarian ligament penetrates it and passes to the side of the uterus, joining the uterine artery. The uterine veins are seen to be two in number.

The relation of the ureter to the blood-vessels is very clearly shown, the uterine vessels passing in front of it. A large vaginal vein is present just below and to the outer side of the ureter; its situation should always be remembered at operation, as an injury to it may give rise to troublesome hæmorrhage. (After H. A. KELLY.)

ing the various anatomical structures, but in stout patients the quantity of fat often renders the necessary dissection extremely difficult.

The uterine artery arises from the anterior division of the internal iliac (Fig. 4), passes downward and inward between the layers of the broad ligament

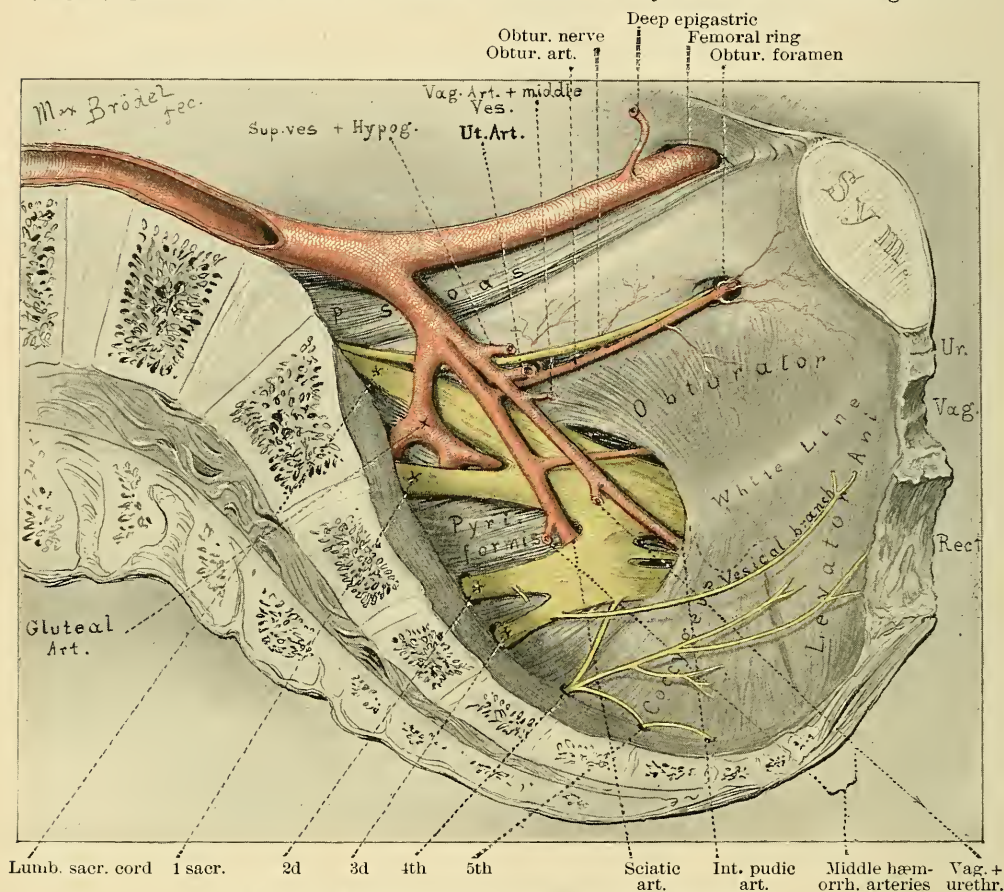


FIG. 7.—THE SACRAL PLEXUS *IN SITU*. ($\frac{3}{5}$ natural size.)

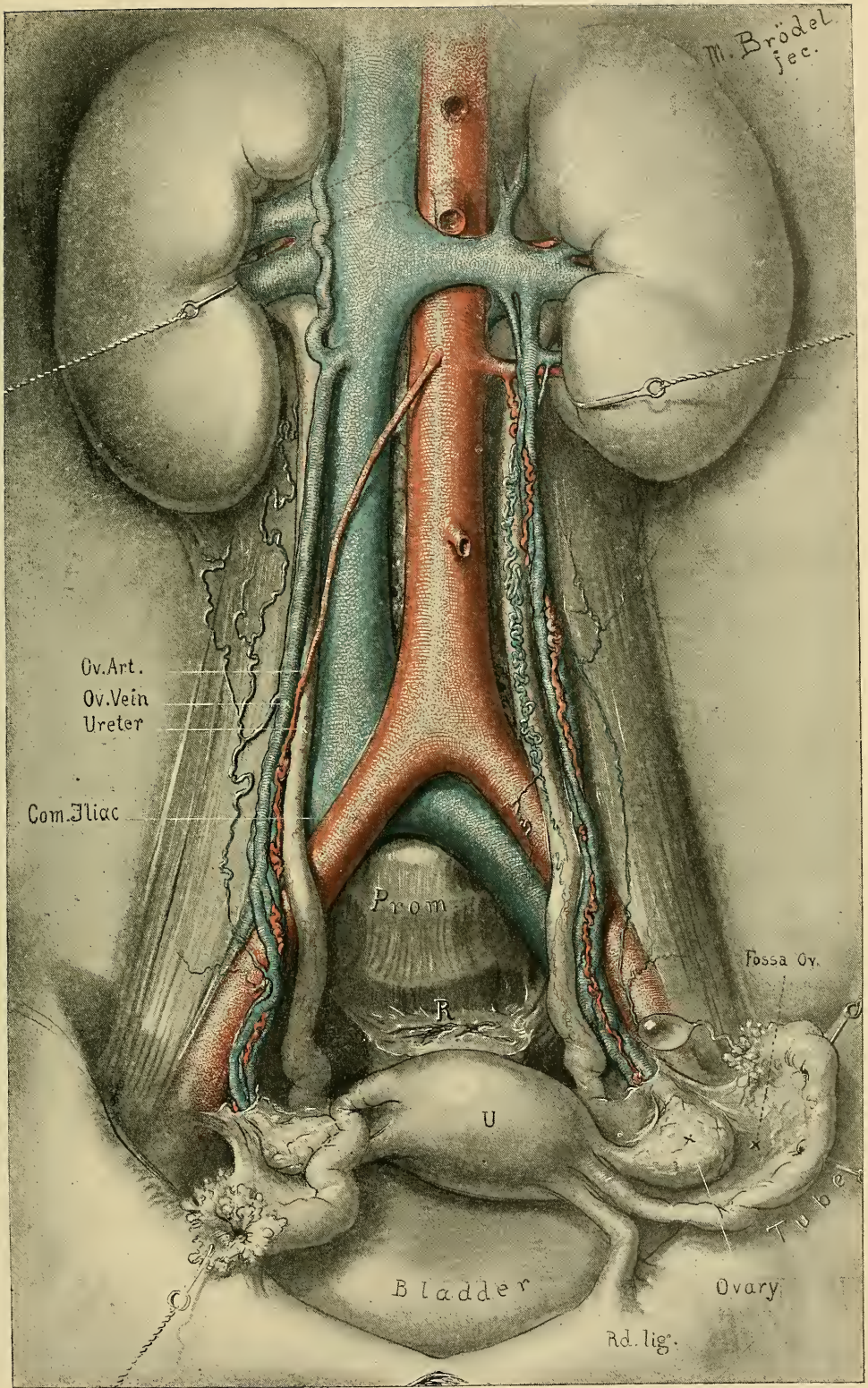
The large nerves of the pelvis are derived chiefly from the lumbar and sacral plexus. In very advanced stages of cancer, where the broad ligaments are greatly thickened by the growth, the nerves situated deep down in the pelvis are subjected to pressure, which undoubtedly accounts for much of the pain so frequently experienced in these cases. (After H. A. KELLY.)

to the cervix, and then ascends the side of the uterus, pursuing a very tortuous course (Fig. 6). It sends off numerous branches, to the anterior and posterior surfaces, which penetrate the muscular layers in all directions. There is, as has

FIG. 8.—VASCULAR TRUNKS OF THE LOWER ABDOMEN. ($\frac{5}{6}$ natural size.)

The general relations of the pelvic contents, as seen at operation, are well shown. The bladder is somewhat distended, and the uterus has accordingly been pushed gently against the rectum. On the left side the relations of the round ligament, tube and ovary, to the uterus are clearly outlined. In this dissection the right ovarian artery arises from the anterior surface of the aorta, the left from an accessory renal artery. The right ovarian vein empties into the inferior vena cava, the left into the renal vein. The ureters, on emerging from the kidneys, pass downward behind the renal and ovarian vessels, cross the common iliac arteries, and drop into the pelvis from 2.5 to 3 centimetres to the right and left of the promontory. (After H. A. KELLY.)

M. Brödel
fec.



Ov. Art.
Ov. Vein
Ureter

Com. Iliac

Prom.

R

U

Bladder

Fossa Ov.

Ovary

Rd. lig.

TUBE

FIG. 8.

been pointed out by my colleague, Dr. Clark,* a very free anastomosis between the two uterine arteries. In fact, so close is the connection, that fluid injected into one uterine artery passes directly over to that of the opposite side. In the vicinity of the round ligaments the uterine arteries also anastomose so freely with the ovarian arteries that it would be useless to tie the one without the other. In fact, whenever we desire to shut off entirely the blood supply of the uterus both uterine and both ovarian vessels must be controlled.

The arteries in the outer muscular walls of the uterus, as has been shown by Dr. Clark,† follow a parallel direction and anastomose freely with one another. They give off numerous branches, which, passing inward at right angles, supply the inner muscular layers and terminate in a rich plexus in the mucosa. During pregnancy the uterine arteries are greatly increased in size.

Uterine Veins.—Even in the mucosa it is frequently possible to detect delicate venous capillaries, recognisable by their very thin walls. From these the blood is conveyed into larger channels in the thick muscular walls, which unite to form the uterine plexus. The vessels of this plexus anastomose freely with each other. Much of the venous blood finds its way into the ovarian veins (Fig. 6); the remainder is carried off by one or two large veins, which follow the course of the artery, are less tortuous, and empty into the internal iliac vein. During pregnancy the veins become greatly enlarged.

Nerves of the Uterus.—The motor fibres to the uterus are derived from the lumbar nerves. The sympathetic nerves come mainly from the lateral fasciculus, prolonged to the pelvic plexus from the hypogastric plexus, some filaments being added from the third and fourth sacral nerves. They are directed upward with the blood-vessels, between the layers of the broad ligament along the side of the organ, and some slender filaments accompany the branches of the uterine artery. The larger number of the nerves, however, sink directly into the substance of the uterus, penetrating for the most part its neck and the lower portion of its body. They form connections in the broad ligament with the ovarian nerves, and the fundus of the uterus also receives an offshoot from that plexus. Numerous small ganglia are contained in the plexus by the side of the neck of the uterus, and a cluster of these constitutes the ganglion cervicale of Frankenhäuser. They appear to be absent in the muscular substance of the organ. One branch continued directly from the common hypogastric plexus reaches the hinder surface of the body of the uterus above the rest.‡

Course of the Ureter.—From the operator's standpoint a knowledge of the course of the ureter is of the utmost importance, as in the removal of the uterus the dissection is often carried beyond one or both of the ureters, and they may therefore be easily severed or included in the ligatures. A study of Fig. 4 shows the ureter crossing the common iliac artery just to the inner side of and parallel to the internal iliac artery. It skirts the pelvic wall, passing downward and inward, curves under the uterine artery and veins 1 to 1.5 centimetres from the cervix, and then enters the bladder obliquely (Fig. 6).

* Clark, J. G. *The Cause and Significance of Uterine Hæmorrhage in Cases of Myoma Uteri*, Johns Hopkins Hospital Bulletin, 1899, p. 11.

† *Op. cit.*

‡ Thane, G. D. Quain's *Anatomy*, vol. iii, Part II, p. 378.

THE LYMPHATICS OF THE UTERUS

Our knowledge on this point we owe chiefly to Poirier,* who has based his observations on the study of over three hundred cases.

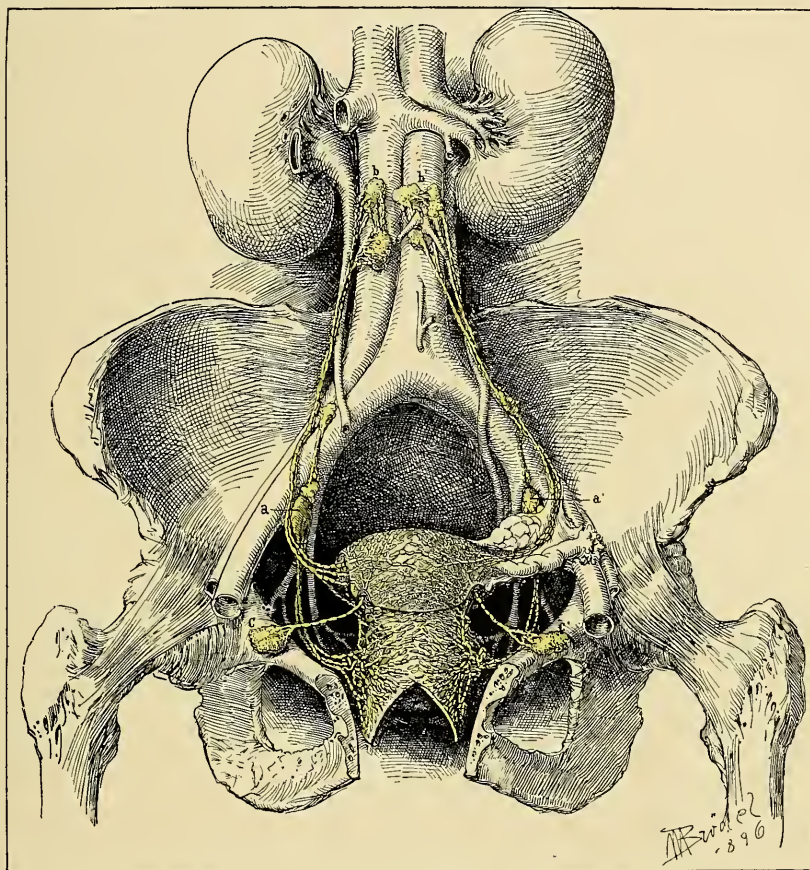


FIG. 9.—LYMPHATICS OF THE UTERUS. ($\frac{3}{7}$ natural size.)

Covering the entire surface of the uterus is a rich network of lymphatics. The lymph channels of the upper part of the vagina and cervix converge to form two lymph vessels on each side. These follow the course of the uterine artery and empty into the iliac glands, *a, a'*, situated at the bifurcation of the common iliac arteries. The iliac glands are usually three in number.

The lymphatics from the body and fundus form two large vessels on either side. These pass outward in the utero-ovarian ligament between the tube and ovary, ascend to the outer side of the large vessel, and empty into the lumbar glands, *b, b'*. The glands lie on the vena cava and aorta, and are seen to be on a level with the lower margins of the kidneys. There are usually two on each side, but in this case three are shown on the left side. The lymphatics in the vicinity of the uterine horn pass down the round ligament and terminate in the deep inguinal glands. (After W. W. RUSSELL.)

Poirier found that the uterine lymphatics were divisible into two groups: 1, a superficial, 2, a deep group; these anastomose with one another in all directions.

* Poirier, P. *Lymphatiques des organes génitaux de la femme*. Paris, 1890.

The lymphatics of the cervix originate in the mucous membrane and muscular coats and pass to the periphery of the cervix, where they become convoluted and then follow a transverse direction, the various branches anastomosing or uniting to form larger trunks. These, usually two or three in number, pass outward along the course of the uterine arteries and may even equal them in size. Their valves are so arranged that the concave surfaces look away from the uterus. After reaching the pelvis they skirt its side to reach the iliac glands situated at the bifurcation of the common iliac artery.

The iliac glands are usually three in number. The uppermost one, which is also the largest, occupies the summit of the angle formed by the external iliac with the hypogastric artery and partly covers the external iliac vein. The other two glands are situated along the course of the hypogastric vein, and are consequently in the pelvis.

A lymph gland on either side of the cervix, described by Henle, is frequently though not always present.

Lymphatics of the Body of the Uterus.—The lymphatics of the body and fundus approach the surface of the organ through the tissue in which they lie, gradually converge, and unite to form two large trunks on each side. These pass outward along the upper surface of the broad ligament by the side of the utero-ovarian ligament and then upward to the lumbar glands. Of these lymph channels there are usually two on each side, varying from 1 to 2 millimetres in diameter. From their course it is seen that they pass between the tube and ovary. The lumbar glands are situated on a level with the lower extremity of the kidney and envelop the vena cava and aorta.

The lymph vessels of the uterine cornu pass down the round ligament to the inguinal glands.

On either side of the uterus is a large lymph vessel providing free anastomosis between the flow from the body and that from the cervix.

The distribution of the lymph channels and the glands to which their currents are carried is well shown in Fig. 9, prepared on the lines laid down by Poirier.

HISTOLOGICAL APPEARANCES OF THE UTERINE MUCOSA

The mucosa of the uterus consists of three distinct portions :

1. That covering the vaginal part of the cervix.
2. That of the cervical canal (from the internal to the external os).
3. That lining the cavity of the body of the uterus.

The vaginal portion of the cervix is covered by numerous layers of squamous epithelium (Fig. 10). In the deepest layer the cells are cylindrical or cuboidal, and with their long axes at right angles to the underlying stroma. The successive layers of cells at first are more or less polygonal, but gradually become more and more flattened as the surface is approached. Here they may be almost flat, but rarely show any tendency to become horny, a fact readily explained, since they are not subjected to the drying influence of the air. Usu-

ally outgrowths of the underlying stroma form small papillæ (Fig. 10, *a*, *a'*, *a''*). These do not, however, project far from the surface of the mucosa.

The cervical tissue immediately beneath the squamous epithelium is composed of many interlacing fibres and appears to be a variety of connective tissue. Its cellular elements are rather sparse; its blood supply is abundant. The stroma in the deeper portions contains isolated bundles of non-stripped muscle fibres which

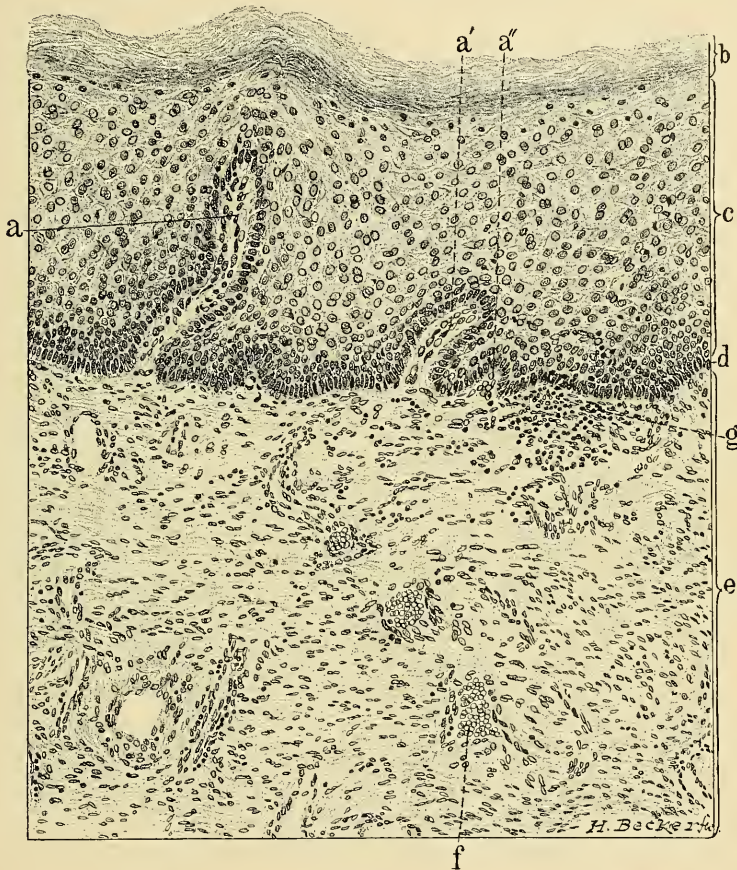


FIG. 10.—NORMAL VAGINAL PORTION OF THE CERVIX. (135 diameters.)

Gyn.-Path. No. 423. *a*, *a'*, *a''* are papillæ projecting from the stroma toward the surface. *b* is the wavy horny layer. It is, however, rarely so well developed. The thick layer of polygonal cells is indicated by *c*. Near the stroma these cells are small and closely packed, but toward the horny layer they are much larger. The nuclei, however, are very uniform in size. *d* represents the layer of cuboidal or low cylindrical cells arranged at right angles to and situated directly on the stroma. The stroma is indicated by *e*. *f* is one of the numerous capillaries. At *g* the stroma shows slight small round-cell infiltration.

rapidly increase in number as one passes upward toward the internal os. It is interesting and important to note the position of the upper limit of the squamous epithelium, inasmuch as, wherever this epithelium is found, squamous-celled carcinoma may develop. The usual belief is that it ends abruptly at the external os, but from Ruge we learn that it may extend far up into the cervical canal.

This has likewise been our experience, and I have been able to trace it to within a short distance of the internal os. On the other hand, as might be supposed, the cylindrical cervical epithelium may reach below the external os. It will be well, then, while assuming that as a general rule the squamous epithelium ceases at or just within the external os, to remember that its limits are subject to much variation.

The Mucosa of the Cervical Canal.—As a rule, the cylindrical epithelium commences at the external os and extends upward as far as the internal os. It must be remembered, however, that while the squamous epithelium of the vaginal portion usually ends at the external os, it is occasionally found further upward, as is shown in Fig. 11. In this is represented a transverse section of the cervix 1 centimetre within the external os; the surface *a* is seen to be covered by typical squamous epithelium. Fig. 12 is taken from the same case near the same point. It shows the gland *B* opening on to the surface covered by squamous epithelium.

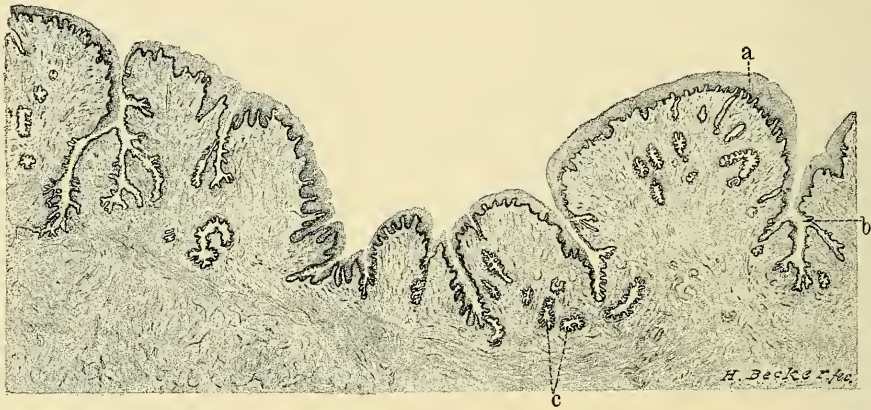

FIG. 11.—A TRANSVERSE SECTION OF THE CERVIX ONE CENTIMETRE WITHIN THE EXTERNAL OS. (8 diameters.)

Gyn.-Path. No. 171. The surface is covered by many layers of squamous epithelium, *a*. *b* is one of several racemose glands emptying into the cervical canal. *c* represents cross sections of the glands in their deeper portions.

In the cylindrical epithelium of the cervix the cell is relatively very high, being nearly twice as long as that of the body, but much more slender. In a specimen stained with hæmatoxylin and eosin the cell protoplasm is either colourless, or faintly tinged by the hæmatoxylin, a very unusual reaction for protoplasm. The upper part of the cell is at times swollen and goblet-shaped, owing to the abundant presence of mucus. It is this mucus that causes the protoplasm to take the hæmatoxylin stain. The nuclei are round, oval, or irregularly triangular; they stain very deeply, and are usually situated directly at or near the base of the cell (Figs. 12 and 13).

According to Ruge and Veit, the cervical epithelium is ciliated, but in spite of careful systematic search I have never been able to demonstrate cilia. Were they present, the mucus would tend to glue them together, thus rendering the delicate threads indistinct. The cervical mucosa, near the external os, frequently shows numerous elevations and depressions, which represent the glands open-

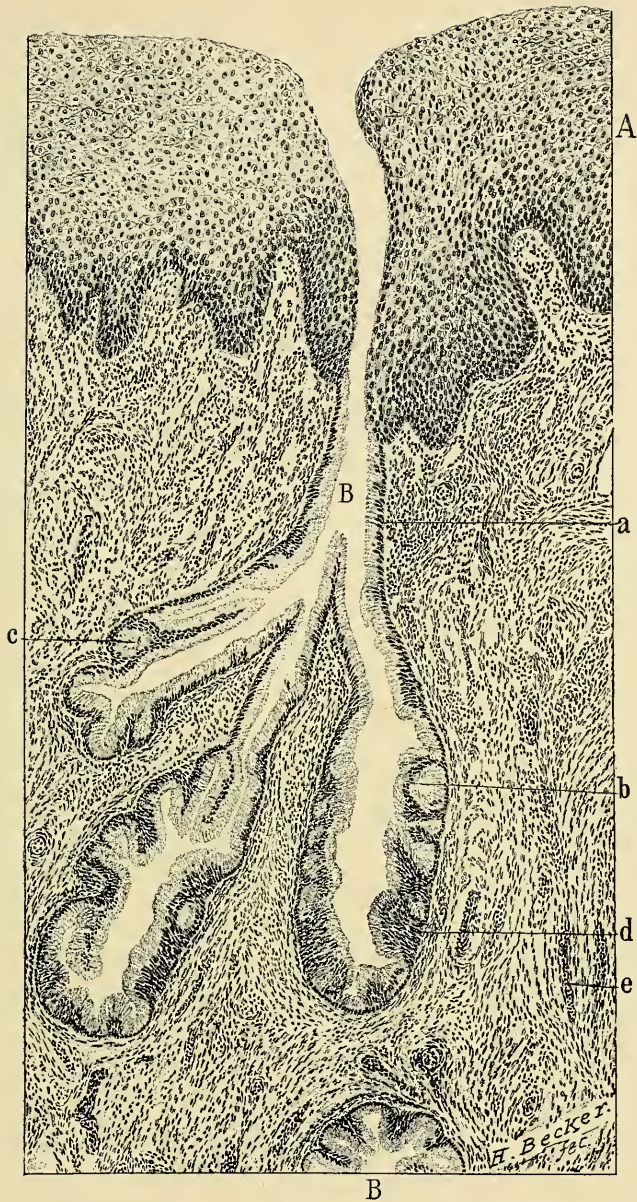


FIG. 12.—A NORMAL CERVICAL GLAND. (90 diameters.)

Gyn.-Path. No. 171. This section has been taken from a point about 1 centimetre above the external os. Ordinarily the surface should be covered by one layer of high cylindrical epithelium instead of by many layers of squamous cells, as indicated by *A*. It is to be noted that even the superficial layers of the squamous epithelium show no tendency to become horny. *B* is a typical cervical gland. It is racemose, and consists of three distinct pockets opening into a common duct. The gland is lined by one layer of very high cylindrical epithelium, well seen at *a*, where the majority of the nuclei are situated directly at the base of the cell. They are triangular, spindle-shaped, or round, and stain intensely. In the deeper portions of the gland the epithelium is gathered into little tufts, or forms secondary glands, *b* and *c*. At *d* the epithelium appears to be several layers in thickness. This appearance is due first to the thickness of the specimen, and secondly to the fact that the cells have been cut obliquely. The tissue surrounding the glands is dense, and consists for the most part of cells containing spindle-shaped nuclei. *e* is one of the many capillaries.

ing on the surface. Fig. 13 affords a very good illustration of this point. The section has been taken from an area just within the external os, and is readily divisible into three distinct parts, *B*, *C*, *D*. *B* is a longitudinal section of one of the cervical folds. It contains the racemose gland *b*, which presents many ramifications. It opens directly on the surface. *c* is a secondary fold; *c'* is a similar secondary fold in cross section. The groups *C* and *D* are cross sections of cervical folds similar to *B*. The mucosa in the upper part of the cervical canal is usually more regular, not presenting the uneven surface seen in Fig. 13.

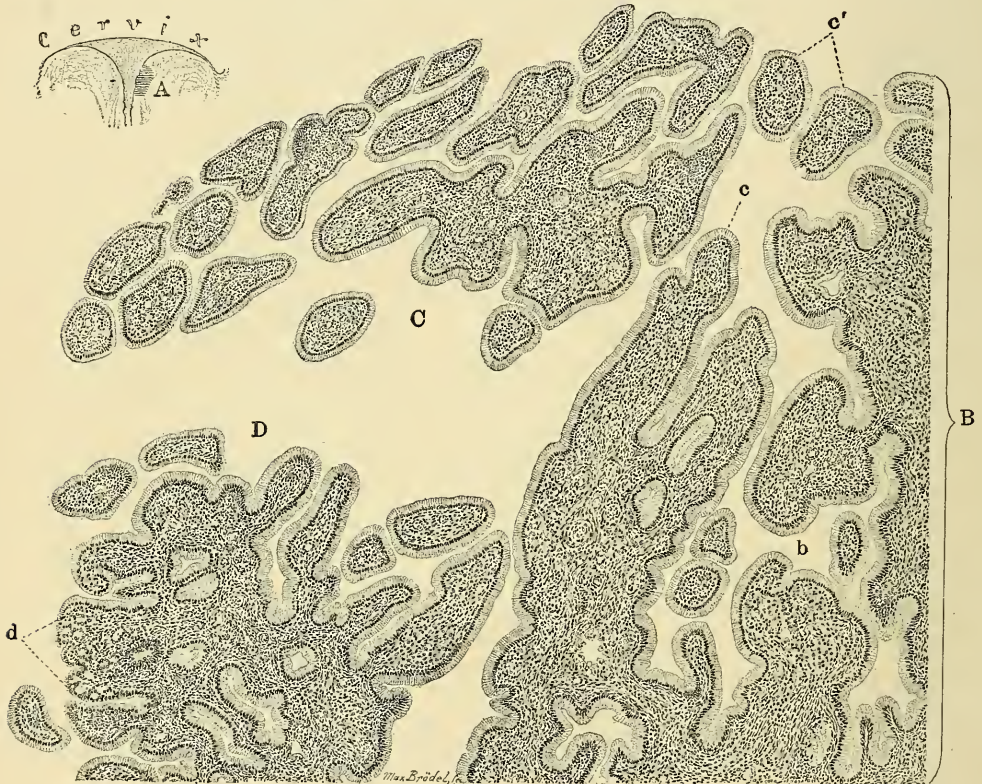

FIG. 13.—NORMAL CERVICAL MUCOSA JUST WITHIN THE EXTERNAL OS. (55 diameters.)

Gyn.-Path. No. 112. *A* indicates the point at which the section was taken; consequently the left side and the upper surface will correspond to the cervical canal, the right portion of the figure showing the stroma of the cervix. The section naturally divides itself into three distinct parts, *B*, *C*, and *D*. *B* is a longitudinal section of one of the cervical folds. Its surface is covered by one layer of characteristic high cylindrical epithelium. Opening on the surface is the racemose gland, *b*, which is seen to be nothing more than a reduplication of the surface. The stroma of the fold is dense, and consists of cells having spindle-shaped nuclei, some of which are cut transversely and accordingly appear round. Scattered throughout the stroma are numerous capillaries, easily recognised by the concentric arrangement of the surrounding stroma cells. *c* is one of the secondary folds from *B*; *c'* indicates two similar folds in cross section. *C* and *D* are cross sections of large cervical folds. *d* is a secondary fold showing some flattening of the surface epithelium and an increase in the number of underlying capillaries.

The surface is everywhere covered by this high cylindrical epithelium, which is also continued down into the glands. The glands may therefore be looked upon as nothing more than reduplications of the surface. They often contain mucus

which takes the hæmatoxylin stain with avidity. It is thoroughly characteristic, and although fairly homogeneous, shows a faint fibrillation. The stroma of the cervix, which forms the tissue between the glands, is rather dense, and consists of an interlacing network of cells having oval vesicular nuclei. It contains

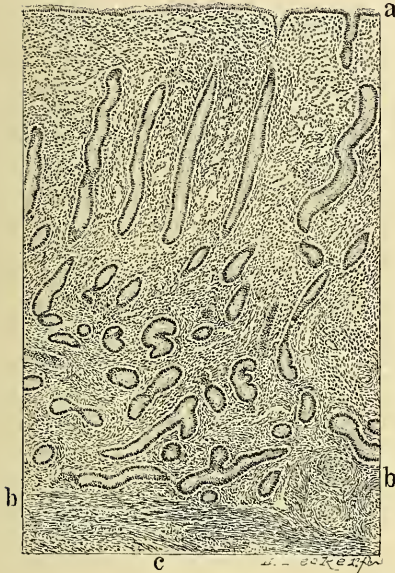

FIG. 14.—NORMAL ENDOMETRIUM FROM A PATIENT FORTY-ONE YEARS OF AGE. (25 diameters.)

Gyn.-Path. No. 1,530. The surface of the mucosa is even, and the surface epithelium *a* is intact. At two points the mouths of the glands are visible. Near the surface the glands are relatively straight: they run parallel with one another and are seen in longitudinal section. About the middle of their course they are more convoluted, and hence cross and oblique sections are seen, while at a few points the gland has been cut just along the margin. In the deeper portions some of the glands run parallel to the muscle *c*, and two show slight dichotomous branching. The stroma of the mucosa in the superficial portion is lax, but near the muscle is quite dense. *b* indicates the line of junction between the mucosa and muscle.

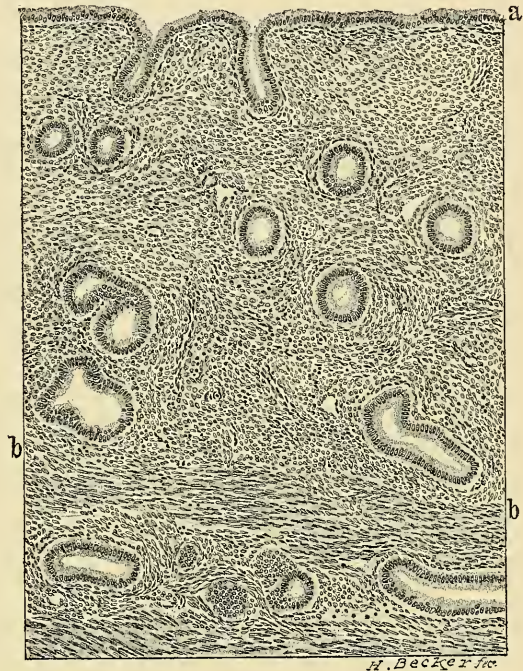

FIG. 15.—NORMAL ENDOMETRIUM FROM A PATIENT THIRTY-THREE YEARS OF AGE. (50 diameters.)

Gyn.-Path. No. 704. The surface is even and its epithelial covering is well preserved. Two glands are seen opening on the surface. In the superficial portion the glands are few in number and are round on cross section, but in the vicinity of the muscle they are cut obliquely and are slightly dilated. The gland epithelium is everywhere intact. The stroma is uniform in density, and consists of cells having oval vesicular nuclei. The majority of the spindle-shaped nuclei of the stroma belong to the endothelium of the capillaries. *b* indicates the line of junction between the mucosa and the muscle. In the muscles are seen sections of several glands. The epithelium of these is in no wise altered, and the glands are surrounded by the stroma of the mucosa.

bundles of non-stripped muscle fibres, increasing in number in the upper part of the cervix.

The Normal Endometrium.—Since the uterine mucosa is always in a state of activity, at different periods slight deviations in appearance may be expected. Furthermore, under ordinary conditions, the endometrium in one case may differ

materially from that in another, and yet both must be considered to be normal. With the low power the mucosa is seen to be covered by one layer of cylindrical ciliated epithelium; on examining this more closely, the nuclei of the epithelial cells are found to be oval, vesicular, and situated usually at some distance from the base of the cell. The cell protoplasm takes the eosin stain.

The mucosa consists of two chief elements: glands, and an intervening substance, the stroma. The glands are tubular (Figs. 14 and 15), and open directly into the uterine cavity. At times they show a slight dichotomous branching at their bases (Fig. 14). If the lumen be perfectly straight, a transverse section will naturally give the picture of a perfectly round gland (Fig. 16). If cut

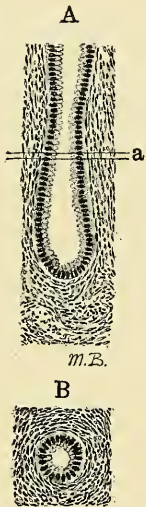

FIG. 16.—A SCHEMATIC REPRESENTATION OF A NORMAL UTERINE GLAND.

A cross section of A, as indicated at point a, would give the picture B.

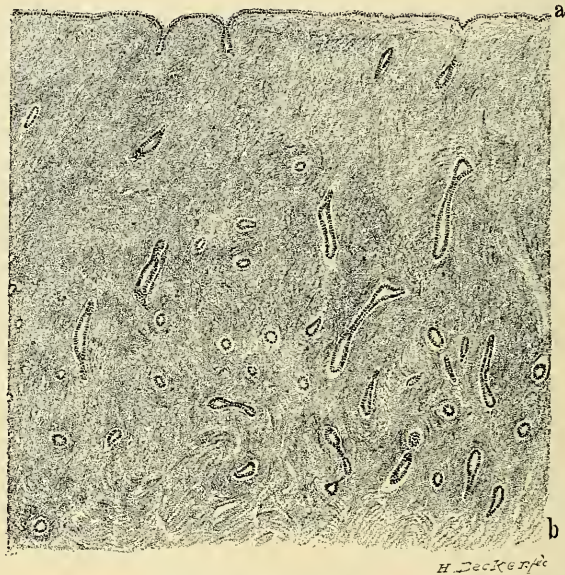

FIG. 17.—NORMAL ENDOMETRIUM AFTER THE MENOPAUSE OR FOLLOWING THE REMOVAL OF THE APPENDAGES. (50 diameters.)

Gyn.-Path. No. 454. The surface of the mucosa is perfectly smooth, save for the indentations produced by the mouths of the glands. The surface epithelium is intact, but slightly flattened. The glands are normal in number, but are exceedingly small. They have an intact epithelium. The stroma of the mucosa is very dense. b indicates the commencement of muscle tissue.

obliquely, the gland will appear oval. These tubular glands vary considerably in size, some being fully two or three times as large as others. A good example of this variation is seen in tissues from women who have passed the menopause. In these cases the glands are usually very narrow (Fig. 17). During active menstrual life the glands often present a wavy contour, and if cut longitudinally will give a snake-like appearance (Fig. 18). A transverse or oblique section of such a gland will give an irregularly oval picture. Very frequently a little stem of stroma will be found springing from the base of the gland and projecting a short distance into the gland cavity (Figs. 19 and 21). It carries the epithelium before it, and hence appears to be covered by one layer of cells. If the stem be cut

longitudinally, its origin is apparent, but in transverse section the appearance of a small cylinder of stroma covered by one layer of epithelium and lying free in

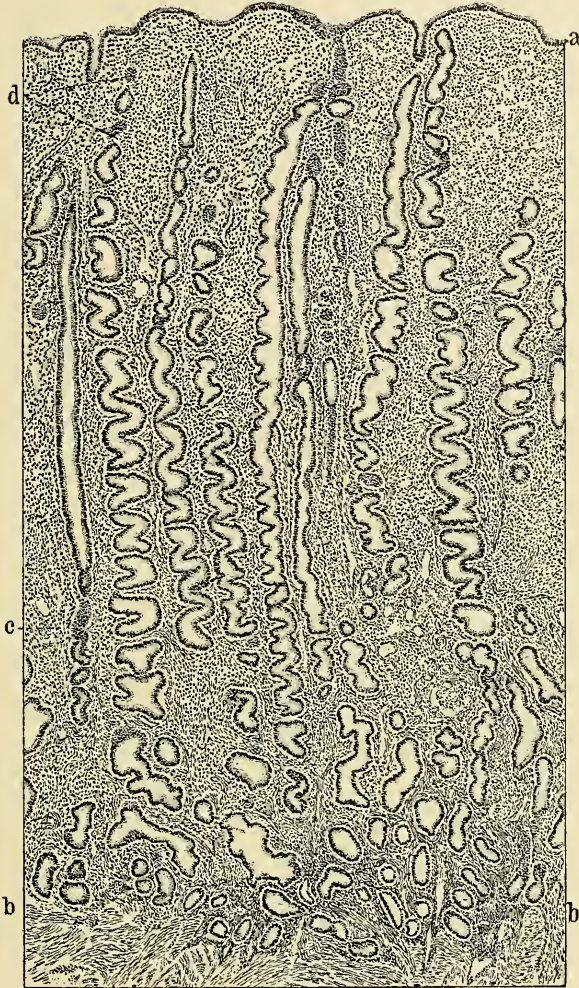


FIG. 18.—NORMAL ENDOMETRIUM IN A PATIENT TWENTY-SIX YEARS OF AGE. (25 diameters.)

Gyn.-Path. No. 614. The mucosa is slightly thickened, its surface is wavy, and its epithelial covering *a* is intact. In this section it is possible to trace the glands in their continuity almost from the surface to the muscle. A few of them are practically cylindrical throughout, but the majority have a wavy contour presenting a well-defined corkscrew arrangement. Quite a number, cut just along their margin, can be recognised as little masses of epithelial cells; *c* is cut longitudinally; *d* almost transversely. At first sight one would think that there was a great excess of glands in the section, whereas in reality, at most, there are not more than twelve, the distances between any neighbouring two being about the same. The gland epithelium is intact throughout. The stroma in the superficial portions is rather lax, in the deeper portions more compact. *b* indicates the line of junction between the muscle and mucosa. Its irregularity is especially noticeable.

the gland cavity is somewhat puzzling. Often this stem has secondary branches, which render the picture still more complex (Fig. 20).

The glands, though usually terminating before the muscle is reached, occasionally penetrate it for a short distance. Sometimes in longitudinal sections their continuity can be traced, but at other times cross sections of one or two glands are found lying in the muscle, at least two to five millimetres from the mucosa (Figs. 15, 246). They are invariably surrounded by stroma, which separates them from the muscle. This slight extension of the gland into the muscle is of such common occurrence that it cannot be considered abnormal.

The uterine glands are lined by one layer of cylindrical ciliated epithelium identical with that forming the surface of the mucosa. As these glands are very active, a few nuclear figures are invariably demonstrable in the epithelium (Fig. 22). The gland cavities are either empty or contain a small amount of granular material that takes the eosin stain. This is probably coagulated albumin. The stroma of the mucosa is of moderate density, and consists of spindle-shaped cells having oval vesicular nuclei (Fig. 22). Scattered sparsely through the stroma are small round cells. The arteries of the stroma are usually small, and are found in bunches of from four to eight. It is quite possible that these may be cross sections of the same vessel, as the arteries are always markedly convoluted. Their walls are thick, and they lie embedded

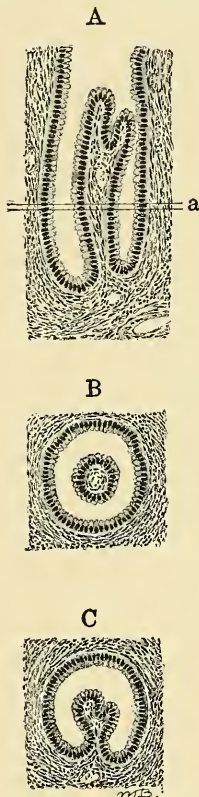


FIG. 19.—A SMALL PROJECTION UPWARD FROM THE BOTTOM OF A NORMAL GLAND.

A shows a normal gland. Projecting into its lumen is a slight elevation, the top of which is somewhat branched. If the projection is free on all sides a cross section at *a* will give the picture B. If, on the other hand, it be merely a longitudinal fold attached to the side of the gland, a similar section will give the picture C.

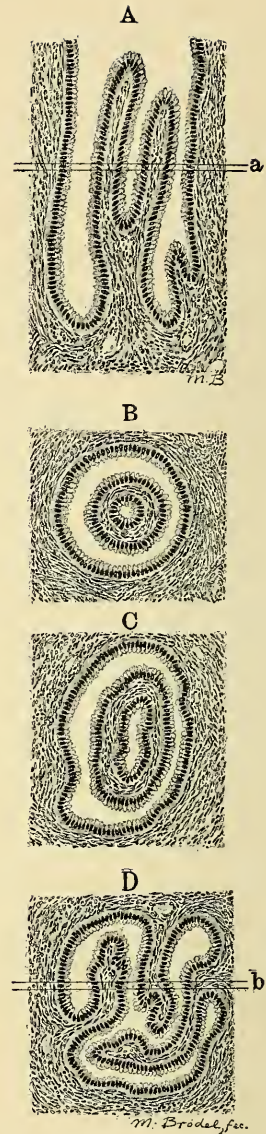


FIG. 20.—A NORMAL GLAND WITH A BRANCHED PROJECTION GOING UPWARD FROM ITS BASE.

Another slight projection into the cavity from the right side is also noticeable. If the gland be fairly circular a cross section at *a* will give the picture B. If there be some compression of the gland the cross section at *a* will look like C. Occasionally we meet with a complicated picture, in the bottom of the gland, similar to D. Here, if a longitudinal section were made at *b*, it might be possible to get the picture A.

in rather dense connective tissue. The veins of the stroma, on the other hand, are relatively much larger, and their walls are very delicate, a single layer of endothelium separating the blood from the stroma. The muscle is usually sharply defined from the stroma, the latter being much darker. Occasionally, however, one merges almost imperceptibly into the other, and in a few instances it really looked as if some of the stroma cells were derivatives of the muscle fibres.

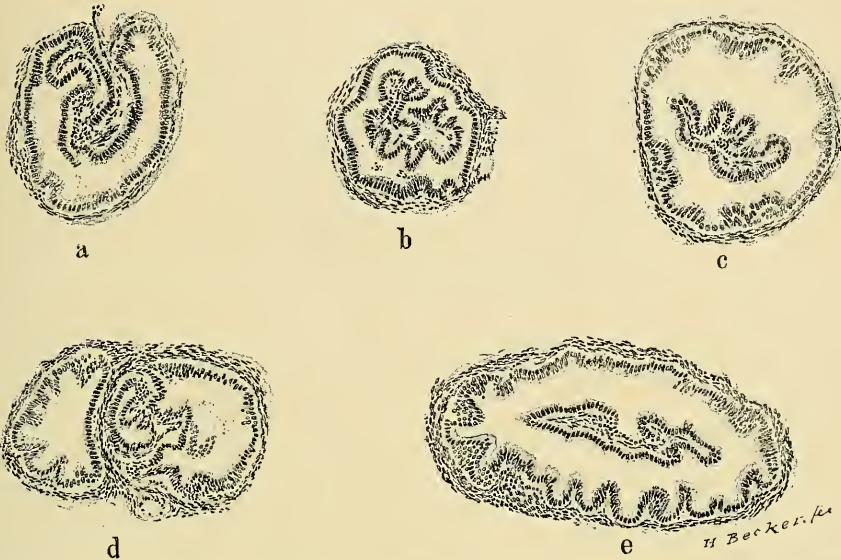

FIG. 21.—PROJECTIONS INTO THE GLAND CAVITIES FROM THEIR SIDES AND BASES. (90 diameters.)

Gyn.-Path. No. 336. *a* and *d* show small projections from the side of the gland. *b*, *c*, and *e* represent cross sections of complicated projections, evidently arising from the bottom of the gland. All the glands are lined by normal epithelium. The stems are covered with normal epithelium, and the stroma of the stems, as well as that surrounding the glands, is normal.

Only rarely is it possible to find nuclear figures in normal stroma cells. Under pathological conditions, however, they are not infrequent.

CHANGES IN THE ENDOMETRIUM AT THE MENSTRUAL PERIOD

The general teaching is that at the menstrual period there is a distinct loss of substance, the surface epithelium and superficial portions of the mucosa undergoing fatty degeneration and necrosis, and later being thrown off. The mouths of the vessels are thus laid open, allowing free menstrual hæmorrhage; regeneration is said to follow rapidly.

This theory at once impresses not only the investigator but also the clinician as a very unusual and crude manner for Nature to bring about the menstrual flow, and quite unlike the orderly and simple way in which the various functions normally take place. For several years we have paid especial attention to this point, and thus far have always found the mucosa intact throughout the monthly period, there being no loss of substance whatsoever. The mucosa during menstruation is usually somewhat thick-

ened. The surface epithelium is normal or slightly swollen, the glands are frequently somewhat tortuous, but otherwise normal. The veins are usually dilated, the stroma in the deeper portions is unaltered, but near the surface many red corpuscles are found lying between the stroma cells. They are also present

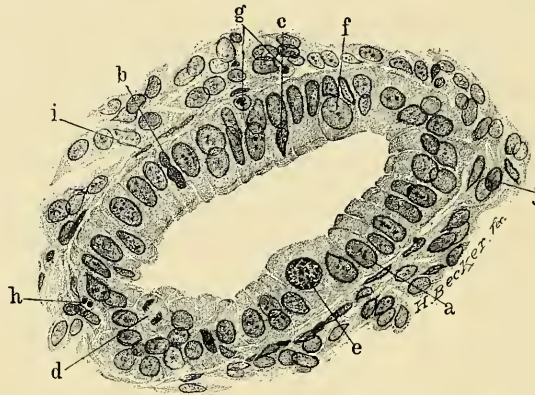


FIG. 22.—NORMAL UTERINE GLAND. (500 diameters.)

Gyn.-Path. No. 941. The specimen was fixed immediately after removal, in order that the cell changes might be instantly checked. *a* is a type of normal cell. The nucleus is oval, vesicular, and situated a short distance from the base. The cilia are not shown. *b* is a cell containing a rather deeply staining nucleus. *c* also contains an irregular nucleus. *d* is a cell in which the nucleus is undergoing division, and the spindle is at right angles to the general arrangement of the cells. *e* is a very large nucleus, which has probably just undergone division. *f* is a similar nucleus containing less chromatin. Thus it will be seen that, although the gland arrangement is definite, hardly any two epithelial nuclei are exactly alike. *g* indicates two polymorphonuclear leucocytes. *h* represents small round cells. *i* is a spindle-shaped nucleus of a cell just beneath the epithelium. *j* is an oval vesicular nucleus from one of the surrounding stroma cells.

between the epithelial cells of the glands and those of the surface epithelium, and are also abundant in the gland cavities and on the surface of the mucosa. The walls of the veins in the mucosa are very delicate, and it is easily understood how it can happen that, with the increased blood pressure present at the monthly period, there should be a diapedesis of the red corpuscles into the loose stroma, whence the blood can readily find its way to the uterine cavity, which is directed downward, and thus favours the free escape of the flow. It is a matter of common observation that unless the mucous membrane is very carefully handled the surface epithelium may be rubbed off, and we have also seen that at the menstrual period the mucosa is somewhat thickened, and that the superficial portions are filled with blood. Thus the chance of losing the superficial portions, unless very careful technique be employed in hardening and mounting, is greatly increased. If the superficial portions are thus mechanically removed we shall naturally find that the surface epithelium and upper portion of the mucosa are missing, and the vessel mouths lie open. We feel confident that subsequent investigations will confirm our observation that no destruction of the mucosa takes place at the menstrual period.

CHAPTER III

THE REMOVAL AND EXAMINATION OF UTERINE TISSUES FOR DIAGNOSTIC PURPOSES

1. Operation for removal of uterine tissue for diagnostic purposes: (1) from the cervix; (2) from the body.
2. Preparation of frozen sections.
3. Gross changes to be noted: (1) in the cervix; (2) in uterine scrapings.
4. Histological alterations to be looked for: (1) in the cervix; (2) in scrapings from the body.
5. Unfortunate consequences that may arise from careless manipulation of tissues; necessity for the prompt labelling of scrapings.
6. Routine examination of the uterus after removal: (1) examination of the gross specimen; (2) method of opening the uterus; (3) choice of the hardening reagent; (4) staining and mounting; (5) routine method of description; (6) indexing.

IN those cases in which carcinoma is suspected but the diagnosis is not clear, as a preliminary routine pieces of tissue are removed for microscopic examination. Thus, when the cervix presents a suspicious appearance, a wedge-shaped piece is excised; where symptoms of carcinoma of the body are present, the cavity is curetted. It will then be well to first describe in detail the method of removal of such tissues and the precautions to be observed.

Occasionally it is deemed advisable to do the operation under cocaine, but, as a rule, ether or chloroform is administered. On the preceding day an aperient should be given, followed by an enema a few hours previous to operation.

Operation.—The patient is placed in the dorsal position, with the thighs flexed upon the abdomen and held in place by a Robb leg-holder. Under the buttocks is placed a Kelly pad, which drains into a proper receptacle below.

The external genitals may or may not be shaved, according to the discretion of the operator. We rarely find it necessary. The parts are thoroughly washed with green soap or ordinary soap and water, then successively with 10-per-cent creolin, 1 to 1000 bichloride solution, and lastly with boiled water.

After the bladder has been catheterized the patient is ready for the dressings. These consist of sterilized stockings applied over the other stockings, a gauze diaphragm, which more than covers the field of operation, and four or five sterilized towels, judiciously placed over the lower part of the abdomen and around



FIG. 23.—THREE-PRONGED
TENACULUM FORCEPS FOR
DRAWING DOWN AND
HOLDING THE CERVIX.

the uncovered parts of the buttocks. The operator wears a long rubber apron over which a sterilized linen apron is applied, so that he may, if short of assistants or for the sake of convenience, lay instruments in his lap.

The instruments for dilatation and curetting consist of a Simon's speculum, one pair of bullet forceps (Fig. 23), three graduated dilators without ratchets

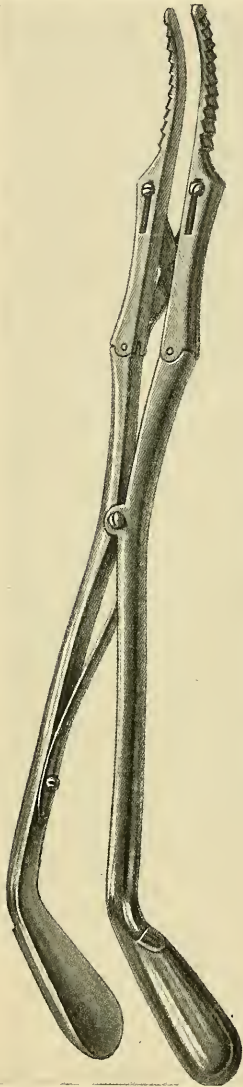


FIG. 24.—GOODELL-ELLINGER DILATOR WITH SPRING INSTEAD OF RATCHET. ($\frac{1}{2}$ natural size.)

The corrugations of the blades prevent slipping during the dilatation.

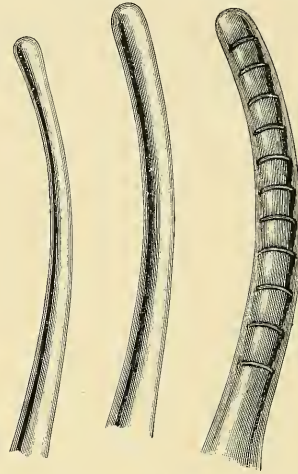


FIG. 25.—THE DILATING ENDS OF THE THREE SIZES OF THE ELLINGER AND GOODELL-ELLINGER DILATORS. (Natural size.)

Showing a slight curve and the relative sizes.

(Figs. 24 and 25), two curettes (Figs. 26 and 27), one dull, the other sharp, one uterine sound, a long, slender pair of artery forceps, and one ordinary teaspoon.

The anterior lip of the cervix having been drawn down with the bullet forceps, the small dilator is introduced. Should any difficulty be experienced in passing it, a sound can be inserted and any constriction or unusual curve noted, after which the dilator can be reintroduced more intelligently. Occasionally it will be necessary to insert the long, slender artery forceps and separate the handles, thus dilating the canal to a certain degree. Dilators No. 2 and 3 are introduced in rapid succession, the cervix being dilated equally in all directions, and no special force being exerted



FIG. 26.—SMALL SHARP CURETTE. (Natural size.)

Usually employed where the uterine cavity is curetted for diagnostic purposes.

at any one point. In this way it is often possible to distend the diameter of the canal up to one centimetre without the occurrence of any bleeding whatever.

The uterus is now systematically and thoroughly curetted from fundus to cervix, both laterally and antero-posteriorly. If this thoroughness is not insisted upon, it may happen that in the case of an early carcinoma the diseased tissue may be left untouched. The spoon catches the curettings as they emerge from the external os and before the water has had time to macerate them in the least.

When it is desirable to remove a piece of the cervix the same preparatory treatment is adopted. The cervix is drawn down with the bullet forceps, and a wedge-shaped piece, about one centimetre broad at the base and one centimetre from base to apex, is excised with the knife. The raw surfaces are approximated by two or three silk or catgut sutures.



FIG. 27.—LONG SHARP CURETTE. (Natural size.)

Employed especially in cancer of the cervix, when comparatively large quantities of friable tissue are to be removed.

FROZEN SECTIONS OF THE TISSUE

If an immediate diagnosis is desired, the uterine mucosa, or portion of the cervix, as the case may be, is at once frozen and examined; otherwise the specimen is placed in a hardening medium, and can be cut and studied at leisure. For rapid diagnosis I devised two methods, which were published in the *Johns Hopkins Hospital Bulletin*, April, 1895. Both have been in use since that time, and we have found none more satisfactory.*

In Method I the procedure is as follows:

- (a) Place the frozen section in 5-per-cent aq. sol. formalin for three to five minutes.
- (b) Leave in 50-per-cent alcohol three minutes.
- (c) In absolute alcohol one minute.
- (d) Wash out in water.
- (e) Stain in hæmatoxylin for two minutes.
- (f) Decolourize in acid alcohol.
- (g) Rinse in water.
- (h) Stain with eosin.
- (i) Transfer to 95-per-cent alcohol.
- (j) Pass through absolute alcohol, then through either creosote or oil of cloves, and mount in Canada balsam.

A diagnosis can in this way be readily reached in fifteen minutes or less.

This rapid method is of great importance in those cases in which it is not desirable to administer an anæsthetic twice, as the patient can come to the operating room prepared for hysterectomy, which can be proceeded with as soon as an affirmative diagnosis is made. After curetting, the usual preparations will be made, and by the time they are completed the scrapings have been examined and

* L. Pick published a modification of my method in the *Centralblatt f. Gynäk.*, 1896, Bd. xx, S. 1016, claiming that it consumes less time. The microtome employed by him is easily manipulated, and does not require the use of carbonic acid, ether being substituted for it. The method is a simple one; it is rapid, and gives excellent results.

the report is given. If carcinoma is present the organ is removed at once; if, however, the examination is negative, the patient is returned to the ward, and is saved the suspense of awaiting for days to know whether she is suffering from malignant trouble or not.

For freezing tissues we have had a cylinder of carbonic acid placed in a room adjoining the operating room, so that no delay occurs (Fig. 28). These cylinders

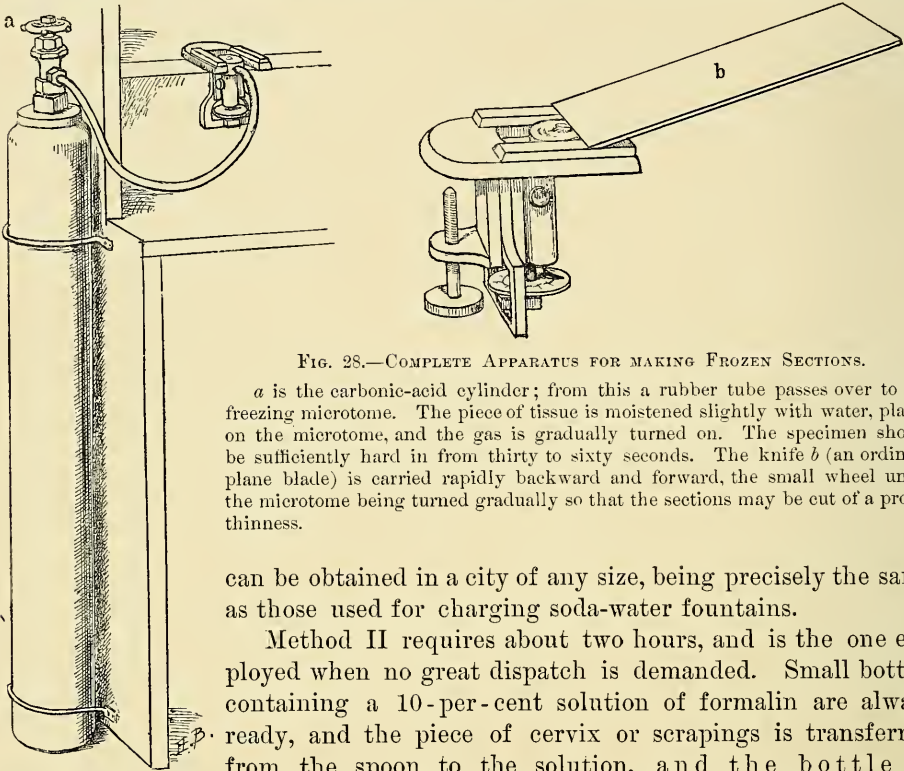


FIG. 28.—COMPLETE APPARATUS FOR MAKING FROZEN SECTIONS.

a is the carbonic-acid cylinder; from this a rubber tube passes over to the freezing microtome. The piece of tissue is moistened slightly with water, placed on the microtome, and the gas is gradually turned on. The specimen should be sufficiently hard in from thirty to sixty seconds. The knife *b* (an ordinary plane blade) is carried rapidly backward and forward, the small wheel under the microtome being turned gradually so that the sections may be cut of a proper thinness.

can be obtained in a city of any size, being precisely the same as those used for charging soda-water fountains.

Method II requires about two hours, and is the one employed when no great dispatch is demanded. Small bottles containing a 10-per-cent solution of formalin are always ready, and the piece of cervix or scrapings is transferred from the spoon to the solution, and the bottle is labelled at once. By the time the specimen reaches the laboratory, which is usually two hours or more, the tissue is of sufficient firmness to cut well. Method II differs only slightly from No. I.

(a) A piece of tissue $1 \times .5 \times .2$ centimetres is placed in 10-per-cent aq. sol. formalin for two hours.

(b) Frozen sections are made.

(c) Left in 50-per-cent alcohol three minutes.

(d) In absolute alcohol one minute.

(e) The sections are now run through water and stained in hæmatoxylin for two minutes.

(f) Decolourized in acid alcohol.

(g) Rinsed in water.

(h) Stained in eosin.

(i) Transferred to 95-per-cent alcohol.

(j) Passed through absolute alcohol, then through either creosote or oil of cloves, and mounted in Canada plug balsam.

EXAMINATION OF THE TISSUES REMOVED

Before studying the specimen it is necessary to refresh one's mind as to the normal appearance of such tissue, and to clearly remember what features are of special importance. Furthermore, it is incumbent as far as possible to follow a systematic method of studying the slides, as in this way few if any alterations are overlooked.

(a) **Piece of Cervix.**—Here one first looks at the vaginal portion, ascertains if the squamous epithelium shows the requisite number of layers, if its cells present the usual appearance, and whether there is any tendency to invasion of the underlying tissue. Further, whether there is any small-round-cell or polymorphonuclear infiltration between the individual cells. Various points in the character of the underlying stroma, any cell infiltration, or a peculiarly rich blood supply, etc., are to be noted.

Attention is now directed to the portion from the cervical canal. Where does the squamous epithelium end and the cylindrical commence? Is the surface comparatively smooth, or is it gathered up into small polypi? Are the cervical glands normal in number? What is their shape? Are they lined by one layer of epithelium, or more, and are the individual epithelial cells uniform in size, or do they vary greatly, and tend to invade surrounding tissue? Lastly, the condition of the stroma is to be looked into.

(b) **Uterine Scrapings.**—Under normal conditions rarely more than a teaspoonful of uterine scrapings can be obtained, hence, if more be present, suspicion is immediately aroused. The mucosa is removed in long ribbons about 2 to 3 millimetres broad and 1 to 1.5 millimetres thick. Of course these measurements will vary with the size of the curette. If the tissue be normal, the surface is smooth and velvety. Where malignant trouble is present the scrapings are usually abundant, masses fully one centimetre in diameter not infrequently coming away. This tissue is friable, and on careful teasing it will often be possible to make out a thread-like branching appearance on the surface. This is a condition never present in normal mucous membrane, and is practically pathognomonic of adenocarcinoma.

Histological Examination.—It is first necessary to study the surface of the mucosa, and learn whether it is smooth, gathered up into polypi, papillary or tree-like growths, etc. Its relative thickness and the character of the surface epithelium should be determined. The shape of the glands on cross section should be described, whether they are round, oval, convoluted, branching, etc.; if they are uniformly distributed or closely packed together; whether the gland epithelium forms one or several layers, and if the individual cells present a normal appearance. The gland contents, if any be present, should be noted.

The attention is now turned to the stroma. Is it dense, or rarefied? What is the character of the stroma cells? Is there any small-round-cell or polymorphonuclear infiltration? What is the character of its vessels?

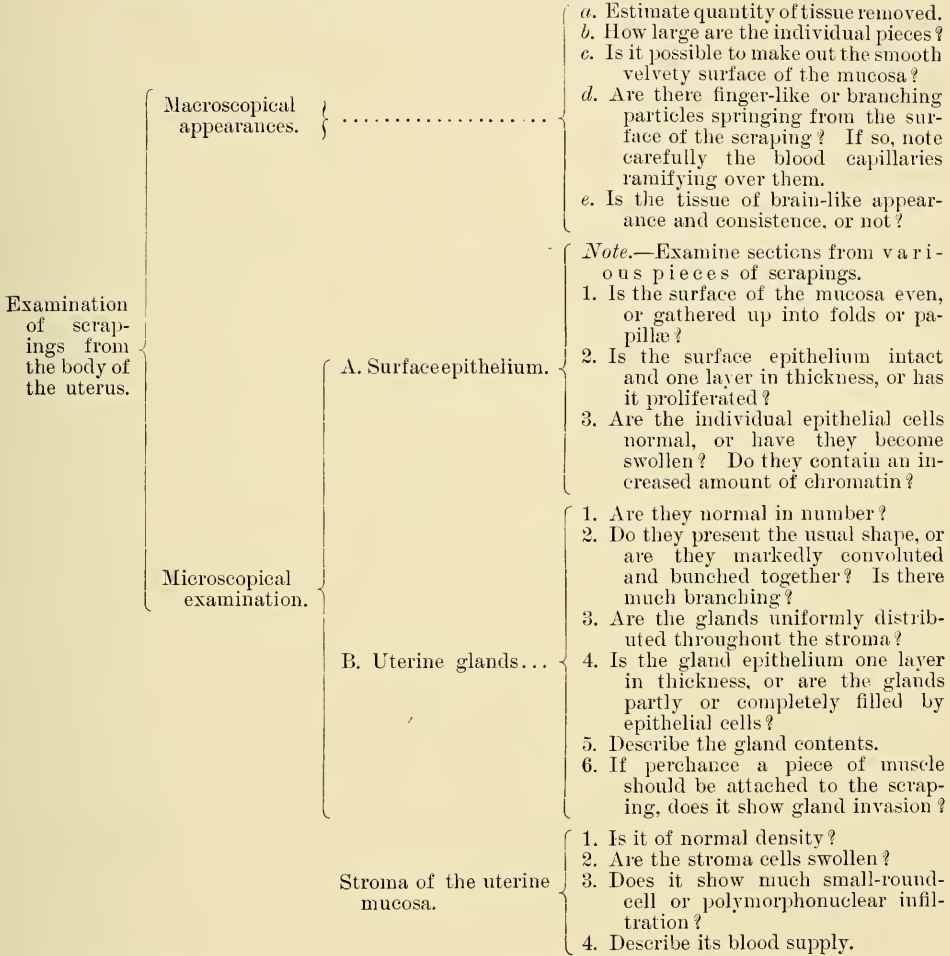
To the blood which surrounds the various pieces of scrapings, and which is found lying in many of the glands, no attention need, as a rule, be paid, as it generally results from the hæmorrhage produced by the curette.

From the foregoing it will be seen that many little points are to be noted in each case. For the convenience of the observer the important features to be described have been tabulated.

Points to be noted in Examination of a Piece of Tissue from the Cervix

Examination of a piece of tissue from the cervix.	{	Macroscopical examination.	{	A. Its measurements. B. Character of mu- cous surface.	{	1. Smooth and glistening. 2. Small finger-like or branching masses springing from surface. 3. Necrotic or sloughing surface.
		Appearance of cut surface.	{	1. Normal density or not. 2. Whitish yellow, or waxy, and very hard. 3. Small yellow dots scattered through- out tissue (abscesses).		
		{	{	The vaginal portion..	{	a. Condition of squamous epithelium. 1. Cells normal in size or swollen. 2. Increase in chromatin. 3. Infiltration of polymorphonuclear leucocytes or small round cells. b. Does squamous epithelium dip down into underlying stroma? If so, how far? c. If any finger-like masses are pres- ent on the surface, describe their histological appearance. d. If any loss of substance on surface of cervix, describe histological appearance of tissue at this point. e. Does the underlying stroma show any small-round-cell infiltra- tion? Describe its blood sup- ply. f. If stroma be invaded by new growth, how far outward and upward does this extend? g. Where does squamous epithelium end and the cylindrical begin?
					{	a. Character of epithelium covering cervical portion. 1. Is it one layer in thickness, or gathered up into small finger- like projections? 2. Does it tend to form new glands? 3. If finger or papillary-like bodies spring from the surface, de- scribe their appearance. b. The cervical glands. 1. Are they normal in number? 2. Do they present the usual convo- luted appearance? 3. Are they lined by one layer of epithelium, or has the epithe- lium proliferated, forming new glands, or filling the old glands completely? 4. Do the glands invade the deeper cervical tissues? If so, to what extent? c. Stroma of the cervical portion. 1. Does it show small round-cell in- filtration? 2. Describe its blood supply.
				{	Cervical portion.....	
		{	{	Histological examination.		

Method of studying Scrapings from the Body of the Uterus



Unfortunate Consequences that may arise from Careless Manipulation of the Specimens.—In private practice the dangers are not so great, but in a hospital, where many operations are performed, and perhaps two or three patients are curetted on the same day, it is always imperative that the specimens be labelled as soon as they are received, otherwise it is very easy for them to become mixed. Let us take for example two specimens, one of curettings from an early cancer, the other from a case of hypertrophy of the mucosa. If the two get mixed, the carcinomatous case may be reported to have a comparatively normal mucosa, and no treatment be advised, while the woman with but little trouble is told that a hysterectomy is the only hope of cure. Thus one patient is doomed, and the other subjected to an unwarrantable and dangerous operation.

If one is not sure about the specimens, it is always better to throw them away at once, even though it be necessary to curette again.

Another source of error may occur as a result of want of care in keeping the alcohols clean. This point I cannot better illustrate than by detailing a case which occurred in our laboratory. The absolute alcohol, into which the small pieces of tissue are placed, is frequently so little deteriorated that it can be used over again. It is always advisable, however, to filter it before employing it a second time. On this occasion curettings from a case of tuberculosis of the endometrium had been hardened,

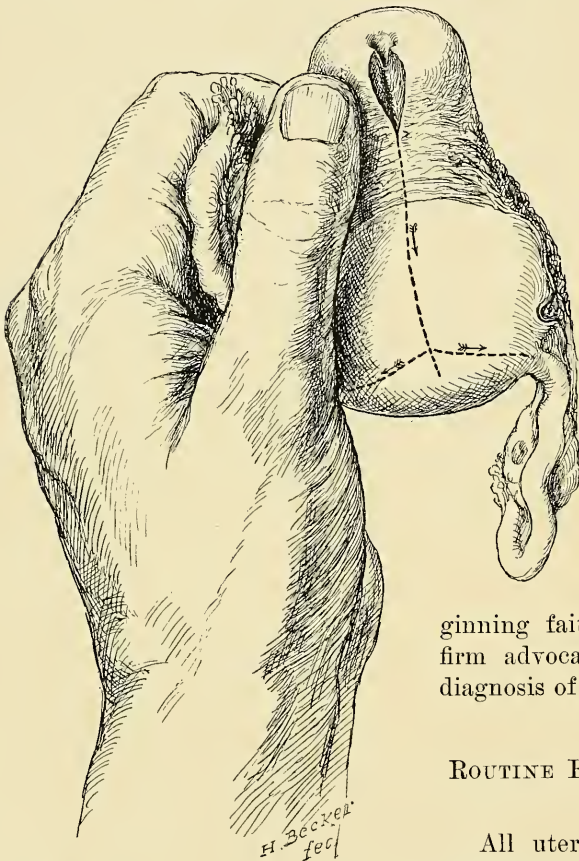


FIG. 29.—METHOD OF OPENING THE UTERUS.

The organ is grasped in the left hand, the anterior surface being directed forward. The incision is then commenced at the external os, as indicated, and is continued to the end of the dotted line, care being taken to keep the anterior uterine wall on the stretch, in order to avoid injury to the mucosa covering the posterior wall. Two lateral incisions are then continued to the uterine horns from the point indicated. In this way no injury whatever is done to the mucosa.

the finer structures would to a considerable extent have been obliterated, since there is always damage done to these tissues by exposure to the air, and more especially by thoughtless handling. I will endeavour to briefly outline the

and the next specimen also consisted of uterine scrapings. On examining the latter they were found to be perfectly normal, except that at one point a small piece showed appearances typical of tuberculosis of the endometrium. Further sections were made from the bottle, but all showed normal tissue. Had the source of the tuberculous tissue not been recognised tuberculosis of the uterine mucosa might very readily have been reported, and the patient operated on for a condition which did not exist. A few such errors would shake forever any beginning faith in those who are not as yet firm advocates of the microscope in the diagnosis of carcinoma of the uterus.

would shake forever any beginning faith in those who are not as yet firm advocates of the microscope in the diagnosis of carcinoma of the uterus.

ROUTINE EXAMINATION OF THE UTERUS AFTER REMOVAL

All uteri after removal are thoroughly examined to determine whether the growth has been entirely taken away or not. Much depends on the operator as to whether the pathologist receives the specimen in a good state of preservation or not. Dr. Kelly very kindly refrained from cutting open the uterus in our cases, so that when we received the specimen, one, two, or three hours after removal, the interior had not been disturbed. Had the uterus been opened,

the interior had not been disturbed. Had the uterus been opened,

method of description that I have employed in the pathological department during the past six years.

Macroscopical Examination.—The name, date, age, and ward are first entered up and the specimen is numbered. The operation is noted, and the specimen is said to consist of the uterus, or uterus, tubes, and ovaries, as the case may be.

The length, breadth, and thickness of the uterus are now accurately noted, whether or not it is covered by adhesions, and if the body be enlarged, firm, or soft. Any unusual appearance on the surface—for example, a subperitoneal nodule—is carefully measured and described. Attention is now directed to the cervix. It is measured, and if intact is so described. Where it is thickened, indurated, or eaten out, the various changes are minutely detailed. The character of the secretion covering the surface, the appearance of the surface itself, the condition of the new growth on section, its colour, consistence, and the extent of its encroachment, both laterally and upward, are accurately described in order. Next it is noted whether its advancing margin stands out in sharp contrast with the surrounding tissues or not.

Opening the Uterus.—Here considerable care must be taken not to disturb the uterine mucosa, since any injury will interfere with subsequent histological studies; further, the organ must be so opened that all portions of the mucosa can come in direct contact with the hardening agent. Grasp the uterus with the left hand, the fundus lying in the palm, and the left thumb being so placed on the cervix that the anterior lip is separated from the posterior (Fig. 29). An incision is now made with a sharp knife through the anterior wall from the external os to the fundus, the thumb gradually following the knife, so that while separating the anterior wall from the posterior it also prevents injury to the mucosa on the posterior wall of the cervix and body. The use of the thumb also answers a third purpose, in indicating the course of the canal, and thus obviating the necessity of introducing a sound. After the cavity has been laid open to the fundus, the cut is continued laterally to both uterine horns. The triangular flaps so formed are rolled outward and fixed in place by pins, thus allowing free access of the hardening fluid to all crevices of the mucosa (Fig. 30).

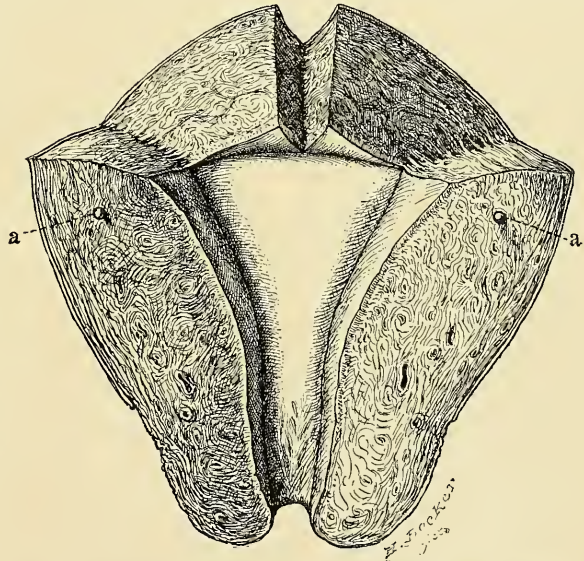


FIG. 30.—APPEARANCE OF THE NORMAL UTERUS WHEN OPENED IN THE MANNER SHOWN IN FIG. 29.

After opening the uterus, the lateral walls are bent slightly outward and fastened by the pins *a, a*. This device prevents the mucosa of the anterior wall from coming in contact with that of the posterior wall, and insures thorough hardening by allowing the fluid to reach all parts of the mucosa.

After the cavity has been laid open to the fundus, the cut is continued laterally to both uterine horns. The triangular flaps so formed are rolled outward and fixed in place by pins, thus allowing free access of the hardening fluid to all crevices of the mucosa (Fig. 30).

It is now in order to give measurements of the length of the cervical canal and describe its mucous membrane.

The thickness of the uterine walls, the length and breadth of the uterine cavity are measured, and the mucous membrane is carefully described. Measurements of its thinnest and thickest portions are also given, and any unevenness is noted. If a new growth is found springing into the cavity, its situation, size, and finer structure are given and its margin is minutely studied. The appendages, if present, are now described.

CHOICE OF THE HARDENING AGENT

Müller's Fluid.—In routine practice Müller's fluid cannot be improved upon. The uterus is placed in a quantity of fluid equal to five or six times its bulk and left for three to four weeks. Should despatch be required, the jar may be placed in the thermostat for two weeks. The Müller's fluid is changed at the end of forty-eight hours, and again about the eighth day. The necessity for further change is indicated by cloudiness which may develop in the fluid. When the specimen ceases to make the fluid muddy it is usually sufficiently hardened. It is then placed in running water for twenty-four to forty-eight hours, according to its size. While the tissue is in running water some special precaution is necessary to preserve the specimen number, which if pasted on the bottle is liable to be washed off. A piece of paper with the number on it may be fastened to the spigot, or a piece of tin may be numbered and wired to the specimen. After thorough washing, care having continually been exercised to prevent any injury to the mucous membrane by too forcible a stream or by contact with the rubber tube, the specimen is drained for a few minutes and placed in 95-per-cent alcohol, where it remains about two weeks, after which it is ready to be cut. Tissue prepared in this way has just the right consistency, and shows little contraction. A further advantage is that the blood has been well preserved.

Alcohol.—This is little used except where it is desirable to examine the tissue for organisms—for example, in a case of pyometra, or where coincidentally with the carcinoma pyosalpinx or ovarian abscess is present. In such cases, after being opened, the uterus is cut lengthwise into two portions, one half being then put into Müller's fluid, the other into alcohol. The drawback to alcohol is that it contracts the mucous membrane materially, so that on comparing a section hardened in alcohol with another fixed in Müller's fluid it is difficult to realize that both are from the same case.

Where alcohol is employed, the specimen is placed in 95-per-cent alcohol at once (in preference to being passed through graded alcohols, 50, 70, and 95 per cent) and allowed to remain two or three weeks, according to the size of the organ. It is well to shake the jar from time to time, as the specimen at first tends to stick to the bottom.

Formalin.—For the preservation of gross specimens this solution is very suitable, but where histological examination is desirable the results are rather unsatisfactory. The uterine muscle soon becomes very hard in the formalin, and cuts, as a rule, with considerable difficulty. We have therefore abandoned its use

except in the preparation of frozen sections, where it has been shown to be of the greatest service.

Those wishing to study cell division, inclusion forms, and so-called parasites, will, of course, take very thin pieces of tissue, about 1 millimetre thick and 8 millimetres in diameter, and immediately place them in a special hardening medium while warm, within a minute or two after removal, if possible. To such we can recommend bichloride solution (1 to 1,000), a saturated Flemming or Hermann's solution, or the various hardening reagents which Pianese has recently found so satisfactory.

PORTIONS OF THE SPECIMEN BEST SUITED FOR MICROSCOPICAL EXAMINATION

This will of course depend upon the situation of the growth, whether it be in the cervix or in the body of the uterus. It is always well to start off without any preconceived idea of what is likely to be found, and as a routine to cut pieces of tissue from all portions of the uterus.

Carcinoma of the Cervix.—Here four to seven pieces of tissue are removed. These are usually 1 to 1.5 millimetres thick, and vary from 1 to 3 centimetres in diameter; in fact, they are sometimes larger. The outer margin of the growth offers the best field for study; hence it is especially desirable that sections should take in this portion. Other sections must include the broad ligament attachment, in order that the lateral advancement of the growth may be determined. A long strip of tissue, about 1 centimetre broad and 1 millimetre thick, made up of the mucosa and part of the muscle, is taken from fundus to cervix. If its length makes it cumbersome, it may be cut up into two or three smaller pieces. Examination of this strip enables one to feel certain about the condition of the uterine mucosa throughout the entire cavity. Pieces from any other suspicious points are selected, and, as a routine measure, specimens are taken from each uterine horn and both tubes and ovaries, to determine whether secondary involvement has occurred, and also if any other pathological process be present in them. Should lymph glands accompany the specimen, numerous pieces are taken from them.

Carcinoma of the Body.—Here one or two pieces, including the entire length of the cervix, and embracing both the vaginal and cervical portion, are removed. From the growth in the body of the uterus sections are taken, not only from its central portion, but especially from the parts near its margin. Pieces of the mucosa at a distance are also selected, since minute and early changes are often to be noted at points remote from the main tumour. Special attention is paid to the taking of muscle sections from any point where the growth appears to have penetrated the uterine wall. In these cases also pieces are cut from the tubes, ovaries, and lymph glands, should they be included in the specimen.

Before proceeding to cut these pieces it will always amply repay one to get the knife as sharp as possible, so that the sections may be clean cut. With a blunt knife considerable pressure is often required, and the tissue becomes distorted or squeezed. Especial care must be taken never to leave a uterus, which has been hardened in Müller's fluid, exposed to the air for more than five minutes, since the mucosa becomes dry, and its superficial portions are apt to

peel off. To avoid this, it is advisable to dip the specimen every few moments into the alcohol from which it has recently been taken.

Each piece of tissue is now picked up with the forceps, care being taken not to disturb the mucous surface or the carcinomatous area, and is placed on a little slip of paper on which the specimen number is written, the other end being smeared with a little tragacanth paste (gum tragacanth dissolved in water). The specimen sticks firmly upon the paper, and can be immediately dropped into the hardening agent. All these pieces of tissue bear the same number, those from the right or left horn, tube, or ovary being marked with an additional R. or L., as the case may be. Thus, from fifteen to forty pieces of tissue are placed in the same bottle.

VARIOUS SOLUTIONS EMPLOYED IN FURTHER HARDENING

Absolute Alcohol.—The pieces of tissue are left in absolute alcohol for a varying length of time (from two days to two weeks or more). They may be transferred as soon as they are firm. Some specimens of uterine muscle harden very slowly, and after three weeks it has occasionally been necessary to wait still longer. The alcohol may be changed from time to time.

Alcohol and Ether.—The pieces are quickly dried on blotting paper and transferred to equal parts of absolute alcohol and ether, where they remain one or two days, after which time they may be placed in the next solution.

Celloidin.—They may be left in a thin celloidin one day and then transferred to a thick solution. We usually employ a single solution of medium consistency, and leave them one day. They are then placed on corks or blocks of vulcanized paper and thrown into 50-per-cent alcohol, to which formalin has been added. After a few hours the tissue is ready for cutting.

Method Usually Employed in Mounting Sections.—For our general work hæmatoxylin and eosin have proved satisfactory, and unless some special feature is to be brought out, no other stains are employed.

The celloidin sections, after being rinsed in water, are :

- (a) Stained in hæmatoxylin, one to two minutes.
- (b) Decolourized in acid alcohol.
- (c) Placed in water until they turn blue again.
- (d) Counterstained in eosin about ten to fifteen seconds.
- (e) Run through 95-per-cent alcohol.
- (f) Absolute alcohol.
- (g) Cleared in creosote or oil of cloves, and mounted in Canada balsam.

Labelling and Filing away of Sections.—After the descriptions have been written up, the sections are labelled and filed away for future use. It is well to mention from what portion of the uterus the specimen has been taken, and the diagnosis and the number of the case should always be added. Sections from the right appendages also have the letter R attached to them, those from the left, L.

Indexing.—It is a very useful and time-saving practice to index all cases as soon as the specimen has been described and diagnosed. The chief features may be recorded on index cards printed for the purpose. For example, when we have a case of squamous-cell carcinoma of the cervix, pyometra of the body, and a hydro-

salpinx, a card is made out for each of these three conditions, so that when looking up squamous-cell carcinoma, or, in fact, any other subject, it will be possible to lay one's hand not only upon the number of the case, but also upon the name and date. The index card which I have found most useful for our work is the following :

Disease.....

.....

.....

Path. No...... *Vol.*..... *Page*.....

Date.....

Name.....

Histological Study of the Uterus and its Appendages.—It is always well to adopt some definite system in the description of these organs. In our experience it has been found most practical to follow the anatomical course, viz., to commence with the vaginal portion of the cervix, pass up through the cervix, and describe various portions of the uterine cavity, then take up the right uterine horn, tube, parovarium, and ovary, and finally the left horn, tube, and ovary, in the order named. If all cases are described in this way, one point will invariably remind us of the succeeding one.

Before commencing the description, all sections should be arranged in the above order, beginning with those from the cervix and ending with those of the left ovary. This arrangement is accomplished with little difficulty, as the shape of each section will indicate the point from which it has been taken. When any doubt arises, a glance at the microscope will show a cervical or uterine gland, etc., which will immediately give a clue as to the proper place of the section. The details that are to be studied have been spoken of at length in the description of examinations of pieces of the cervix or uterine mucosa (pages 32 and 33).

CHAPTER IV

SQUAMOUS-CELL CARCINOMA OF THE CERVIX

1. Gross appearances of squamous-cell carcinoma of the cervix.
 1. Stage I. Hardness and induration of the cervix, but without any loss of tissue.
 2. Stage II. Moderate disintegration of the cervix.
 3. Stage III. Extensive or complete involvement of the cervix.
2. Histological picture in squamous-cell carcinoma of the cervix.
 1. Stage I. Hardness and induration of the cervix, but without any loss of tissue.
 2. Epithelial pearls.
 3. Nuclear figures.
 4. Increase in the cell chromatin.
 5. Finger-like projections.
 6. The stroma.
 7. Stage II. Moderate disintegration of the cervix.
 8. Cell degeneration.
 9. Changes in the nuclei.
 10. Stage III. Extensive or complete involvement of the cervix.
3. Cases illustrating the various stages of squamous-cell carcinoma of the cervix.
4. Scirrhus squamous-cell carcinoma of the cervix.
5. Carcinomatous masses in lymph spaces.
6. Condition of the uterine mucosa in squamous-cell carcinoma of the cervix.
7. Pyometra occurring in conjunction with squamous-cell carcinoma of the cervix.
8. Squamous-cell carcinoma of the uterus associated with prolapsus.
9. Simultaneous appearance of squamous-cell carcinoma of the cervix and tuberculosis of the uterus.

SQUAMOUS-CELL carcinoma of the cervix is the most common form of cancer of the uterus. For this reason, and from the fact that its position renders it easily accessible, it has been the subject of more exhaustive study and has been better understood than any of the other varieties. Unfortunately, owing to the insidiousness of its onset and the lack of symptoms, the morbid process is too often liable to pass unrecognised until it is far advanced, and only in recent years, and then in rare instances, have specimens been obtained from living patients which offered opportunities for the microscopical study of the early stages.

Before taking up the consideration of this pathological condition it will be well to review very briefly certain points in the anatomy of the cervix, both in its normal state and also after it has been subjected to laceration. The normal cervix is usually round or slightly conical, and projects from 1 to 1.5 centimetres into the vaginal vault. To the touch it presents a somewhat firm consistence, which is uniform throughout. At its outlet the cervical canal varies from 2 to 5 millimetres in diameter, and through the external os a small amount of the bright-red cervical mucous membrane can be seen. The vaginal portion appears bluish white or whitish, and is smooth or slightly wrinkled. In the majority of women who have borne children a laceration of moderate degree is present.

This is most frequently bilateral, but the tear on one side is usually deeper than on the other. The lips are somewhat everted, and an abnormal amount of the bright cervical mucous membrane is thus exposed. The lips themselves are generally soft, except in the vicinity of the clefts, where they may feel somewhat dense to the touch or slightly nodular, owing to the presence of old scar tissue. There is little or no tendency to hæmorrhage from the areas of laceration.

THE MACROSCOPICAL APPEARANCES OF SQUAMOUS-CELL CARCINOMA OF THE CERVIX

For the sake of adding clearness to our description, it is convenient to distinguish three stages according to the condition of the cervix by which each is characterized. In the first stage the cervix is hard and indurated, but the surface of the mucous membrane is still unbroken; in the second the cervix shows signs of moderate disintegration; in the third and final stage the whole organ is involved in the destructive process.

Stage 1. Hardness and Induration of the Cervix, but without any Loss of Tissue.—If one is fortunate enough to detect the existence of a new growth at this stage, the cervical lip will be found thickened, hard, nodular, and on examination may bleed slightly. When the cervix is exposed the mucous membrane shows numerous large and small bosses, which, although still intact, have a glazed bluish-white appearance, as though the tissue was very tense and ready to burst. On more careful study there can be seen at several points masses of teat-like or branching papillæ, averaging 1 millimetre in diameter and projecting 1 to 2 millimetres from the surface. It often happens, however, that the papillæ are held together in masses by a ropy mucus, so that they may readily be overlooked.

Fig. 39 (p. 55) shows in the central portion a slight depression covered by delicate finger-like projections which at certain points have coalesced, forming small mounds. At *a* the very earliest stage is demonstrable. Here, extending over an area 1.5 centimetres in diameter, is a slight elevation of the surface, due to the presence of recently formed projections less than 2 millimetres in length. Fig. 40 (p. 56) represents a small portion of Fig. 39 at point 1'. It is magnified six times, and shows the advancing margin of the growth, sharply defined and consisting of delicate projections.

In Fig. 31 (p. 42) the entire anterior lip and more than half of the posterior lip are seen to be involved in a growth which is sharply distinguished from the remaining vaginal portion of the cervix. It is elevated, and presents a finely lobulated surface. The delicate fingers are not visible in it, and no breaking down of tissue has as yet occurred.

These little projections in many cases grow rapidly, forming the large bunches or cauliflower growths described by Clark* in 1824. Reference to the accompanying histories shows that the vaginal vault is filled by a fungous or cauliflower-like mass. This must be examined *in situ*, as it is not advisable, and indeed rarely possible, to remove the uterus with such a mass attached to it. This fact

* Clark, C. M. *Observations on the Diseases of Females*, London, 1824, p. 151.

accounts for the meagre descriptions of cauliflower outgrowths recorded by the pathologists, inasmuch as they receive from the operating room in such cases the hollowed-out uterus together with a large quantity of scrapings, which represent the remains of the cauliflower excrescences. More typical examples of such

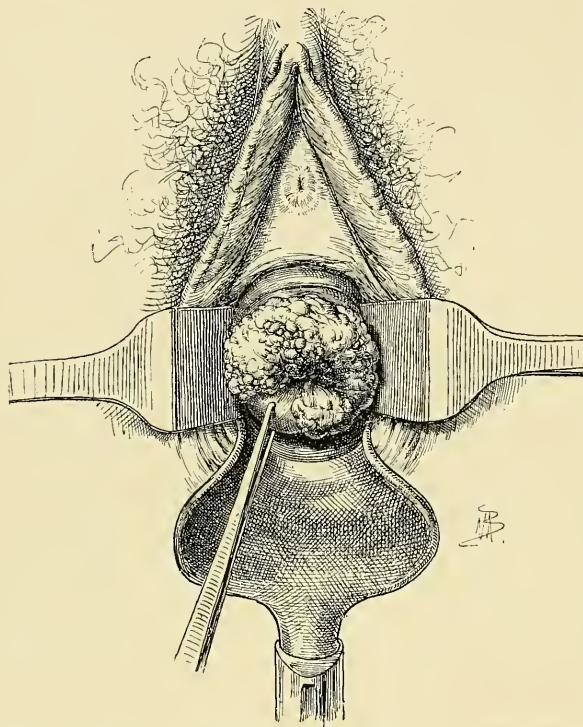


FIG. 31.—EARLY SQUAMOUS-CELL CARCINOMA OF THE CERVIX.
($\frac{2}{3}$ natural size.)

The entire anterior lip and half of the posterior lip are the seat of a new growth, which is sharply defined from the remaining portion of the cervix. It is raised from the surface and consists of small lobulated masses. No distinct finger-like projections are visible. There is no evidence of disintegration.

This is a very favourable case for operation, as the disease is confined entirely to the cervix, not having encroached at all upon the vaginal vault. (After H. A. KELLY.)

surface consists of small knob-like elevations, which resemble somewhat a bunch of grapes. Fig. 47 (p. 67) shows another cauliflower growth occupying one entire lip, and forming an almost circular elevated shaggy growth made up of the same delicate finger-like processes. The section 1, which is a projection to the right, shows the thickness of the growth as seen macroscopically. A slightly different picture is presented in Fig. 49 (p. 77). Here there is very little projection from the surface, but both lips have been replaced by the finger-like processes, and not only the entire cervix but also part of the body has been invaded.

While the growth is extending outward into the vagina, there is a simultane-

growths could hardly be found than those represented in the following cases. In Fig. 45 (p. 62) the uterus has been cut open posteriorly. Springing from almost the entire anterior lip is seen a spongy or cauliflower-like mass with a rather narrow basal attachment. The entire mass is composed of small semi-translucent papillæ varying in size from a pin-point to 3 millimetres in diameter. On examining the specimen, after hardening in Müller's fluid, the individual elements are more sharply defined, and are found to consist of long and short finger-like masses, having rounded or knob-like extremities. In longitudinal sections (cf. Fig. 46, p. 63) the small papillæ are seen projecting from the surface, while the deeper portions are seen cut at all levels and angles. In Fig. 32 the growth is found occupying almost the entire anterior cervical lip. Starting from a broad basal attachment it tapers almost to a point. Its

ous involvement of the underlying cervical tissue, which becomes very hard. Where the cervix is incised the neoplasm is recognised as a translucent, grayish, or yellowish-white growth, which extends upward toward the internal os and outward toward the vaginal vault and in the direction of the connective tissue of the parametrium. In appearance it is not unlike raw pork, but when cut with the knife frequently has an almost cartilaginous consistence. When examined closely with the magnifying glass, the tissue is found to consist of a network of glistening fibres constituting the stroma, throughout which appear at intervals round, oval, irregularly oval, or branching spaces filled with a crumbly substance that has a somewhat yellowish tinge. These "nests," as they are called, are sometimes of considerable size. By exerting gentle pressure it is often possible to dislodge these masses, small cavities being left behind; as Wagner expresses it, they can be squeezed out like comedones. If a thin section be made from such an area and the nests or crumbly masses be washed out, a regular sieve-like structure is left.

The cervical glands frequently show no alteration; at other times, however, they are dilated, forming the so-called Nabothian follicles, and the mucosa may be gathered up so as to give rise to small polypoid excrescences.

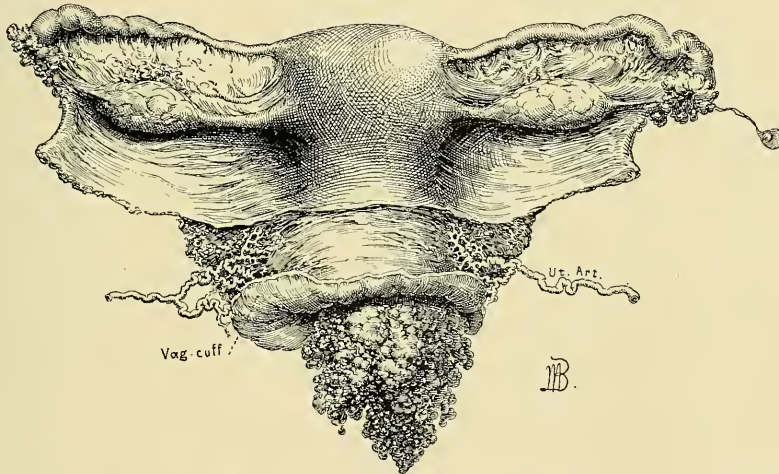


FIG. 32.—A "CAULIFLOWER" MASS, SPRINGING FROM THE ANTERIOR CERVICAL LIP. ($\frac{1}{2}$ natural size.)

The uterus and appendages are seen from behind. Attached to the anterior lip by a broad base is a fungous growth composed of small, rounded, semi-translucent masses. It resembles somewhat a bunch of grapes. The posterior lip is entirely free from the growth. The uterine arteries have been tied at a distance from the cervix and are seen sending off their various branches to it. The uterus is of the usual size; the tubes and ovaries are normal. The small cyst projecting from the neighbourhood of the fimbriated extremity of the right tube is the hydatid of Morgagni. (After J. G. CLARK.)

Stage 2. Moderate Disintegration of the Cervix.—With this stage we are much more familiar. The patient has been complaining for some time, but has not deemed it necessary or has been afraid to apply to a physician until the process has gone on to such an extent that the large or small cauliflower mass has broken down in part or entirely. In the case of such a patient, the examining finger recognises that the cervical landmarks are obscured or even completely obliterated.

ated. Frequently more than half of the cervix is gone, and the portion which remains is hard and nodular. Where the tissue is lacking a large or small depression is found, the margins of which are very hard, irregular, and bleed freely on the slightest manipulation. Examination of the uterus after removal shows that the margins of the cavity are to a great extent composed of small finger-like

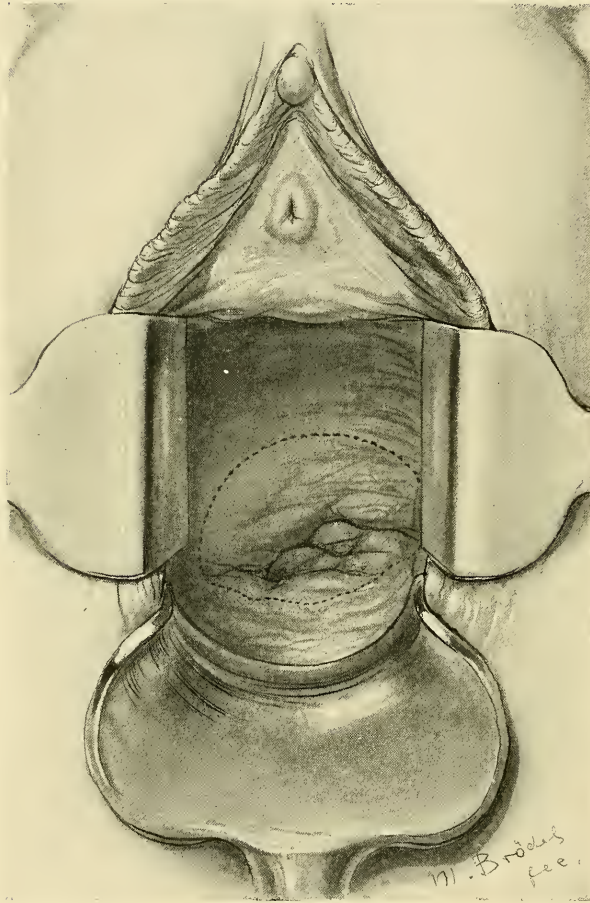


FIG. 33.—ADVANCED SQUAMOUS-CELL CARCINOMA OF THE CERVIX.
(Natural size.)

The cervix has entirely disappeared; in its place is seen an irregular and puckered-looking opening, through which a foul-smelling discharge escaped at operation. On digital examination the tissue around this opening was found to be very hard and unyielding, and the area of infiltration extended laterally and anteriorly as far as the dotted lines. When the vaginal vault is so extensively involved there is little to be gained by operative interference. (After H. A. KELLY.)

Fig. 143 (p. 266), for example, not only is the cervix entirely occupied by the cancer, but only a small portion of the body is left. In fact, so extensively had the normal tissue been displaced by the carcinomatous growth that the gentlest

masses similar to those found in the cauliflower growth. The invasion of the cervical tissue is more advanced, and the disease may have extended as far as the broad ligament and also out on the vaginal vault. In Fig. 50 (p. 80) the cervical outlines have entirely disappeared, and the examining finger met with a hard, uneven, excavated surface in the vaginal vault. The growth extended upward to the internal os, and laterally, even with the naked eye, could be recognised as involving the tissues to within 1 millimetre of the bladder attachments. Fig. 52 (p. 83) shows the cervix somewhat magnified. Here also the cervical outlines are gone, and the growth has reached the lateral attachments.

Scattered throughout the growth can be seen numerous small yellow dots, which on further examination can be identified as small abscesses.

In some cases it is astonishing to note how far the disease may sometimes progress before the vaginal examination or the clinical phenomena are suggestive of any serious involvement. In

traction during the operation was sufficient to sever the cervix from the body. Fig. 144, which gives a lateral view of the same specimen, shows that only a faint outer covering of muscle remains. Vaginal examination in this case had given but little information, except that the cervix and body were somewhat enlarged and rather firm.

Stage 3. Extensive or Complete Involvement of the Cervix.—Unfortunately, many cases reach this stage before medical aid is summoned. Practically these cases can almost always be diagnosed, even without examination, from the foul odour of the discharge. The cervix as such is not, as a rule, recognisable, its place being occupied by a crater-like or funnel-shaped opening, whose walls are rough, covered by necrotic material or pus, and present on casual examination a worm-eaten appearance, which for the most part is due to the many small finger-like masses springing from the surface of the growth (Fig. 88, p. 168).

The vaginal vault has been encroached upon in one or other direction, generally to the side or in front, but occasionally posteriorly. The advancing margin of the growth is rounded, elevated, and very hard. Here also slight manipulation is sufficient to occasion free hæmorrhage. In Plate III the cervix has entirely disappeared, and situated in the vaginal vault is an irregular, eaten-out area with sharp margins, and with some portions of the surface red and glistening, while others are covered by a necrotic greenish or brown slough. Fig. 33 shows a slightly different picture. Here there has not been so much ulceration, and the loss of tissue has been succeeded by some contraction, so that a puckered slit is seen in the vault. On palpation the tissue of the vault was dense and board-like. The dotted line indicates the limits of the growth as determined by the examining finger. On cutting open such a uterus the growth will be found extending to the connective tissue immediately beneath the vaginal epithelium, as well as on the surface. Seelig* found only one case in which the extension took place along the surface alone (see our case, Fig. 297, p. 585).

Occasionally the isolated nodules are found beneath the vaginal mucosa at some distance from the advancing margin of the growth (see Plate III). The parametrium is likewise involved, and the broad ligaments have a board-like consistence. Upward the carcinoma extends to or beyond the internal os, occasionally reaching almost to the fundus. Posteriorly it may involve the entire thickness of the uterus, but a direct communication between the uterus and Douglas's sac is prevented by adhesions to the rectum. On section, the growth presents the same appearance as in stages 1 and 2, save that the small yellowish dots or abscesses have materially increased in number.

HISTOLOGICAL PICTURE IN SQUAMOUS-CELL CARCINOMA OF THE CERVIX

In describing the macroscopical appearances, we have for convenience divided the course of squamous-cell carcinoma into three stages. In giving the histological picture we shall adopt the same plan.

* Seelig, A. *Pathologisch-anatomische Untersuchungen über die Ausbreitungswege des Uterus-carcinoms im Bereiche des Genitaltractus.* Virchow's *Archiv* (1895), Bd. cxl, S. 80.

Stage 1. Hardness and Induration of the Cervix, but without any Loss of Tissue.—In the histological study the most instructive pictures will invariably be found along the outer or advancing margin of the growth. Accordingly, we shall always endeavour to start from the normal mucosa and trace it to the point where it ends abruptly or gradually in the new growth.

In the early stage the mucosa of the vaginal portion in the vicinity of the growth either appears normal or shows some slight inflammatory reaction, small round cells or polymorphonuclear leucocytes being found between the normal

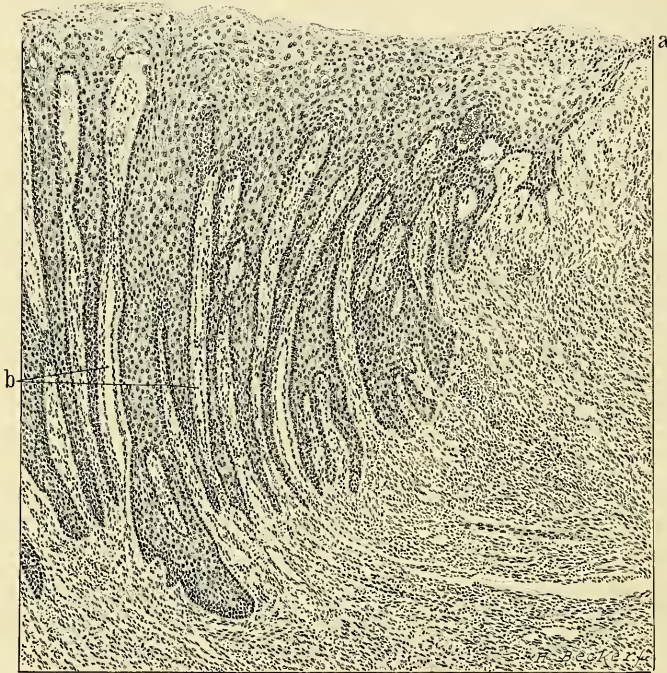


FIG. 34.—CHANGES IN THE EPITHELIUM ALONG THE MARGIN OF A SQUAMOUS-CELL CARCINOMA OF THE CERVIX. (56 diameters.)

Gyn.-Path. No. 1507. Just to the right of this section (at *a*) the epithelium has invaded the cervical tissue in all directions, giving the typical picture of squamous-cell carcinoma. In this drawing it is noted that the surface of the mucosa is comparatively even, there being no outgrowths. The stroma has been invaded to a considerable depth by the epithelium. The epithelial cells, however, are uniform in size, present the usual appearance, and even in the deep or cuboidal layer are still sharply defined. The lengthening of the papillæ is due to the downgrowth of the epithelium, as they do not project from the surface. The clear spaces indicated by *b* represent delicate blood capillaries. The underlying stroma is normal, showing no signs of infiltration. Although the picture might at first sight be suggestive, there is no evidence of a malignant growth in this section.

squamous cells. As one advances toward the margin of the growth some suggestive epithelial alterations may be present, such as appear, for example, in the case illustrated in Fig. 39. In fact, so full of interest is this case that it may with profit be discussed in detail. Fig. 41 (p. 57) is taken from Fig. 39 (p. 55) at point 3, which, it will be noted, is fully 1 centimetre distant from the uneven surface of the growth; and yet even a cursory examination of this section shows that considerable alteration in the superficial epithelium has taken place. The

surface on both sides is perfectly normal, but at point *a* the superficial layers of squamous epithelium have disappeared, while considerable proliferation can be noted in the deeper layers. In this downgrowth it will be seen that the cell protoplasm is greatly diminished in amount, and that the nuclei are closely packed, less uniform in size, and stain more deeply. The underlying stroma immediately in the vicinity of this downgrowth shows abundant small-round-cell infiltration. Plate I is taken from Fig. 39 (p. 55) at point 2, and includes the margin of the growth. To the right is the normal cervical epithelium (*a*), which ends very abruptly, being replaced by cells more closely packed. This epithelium penetrates the underlying tissue in all directions, being seen as long or short, branching and irregular, masses of cells, which stain much more deeply than the surrounding tissue. In many places the epithelium can be traced from the surface far into the depth, but often its prolongations are seen on cross section, these forming the isolated islands or nests of epithelial cells.

Fig. 44 (p. 60) is a particularly favourable section from which to obtain a clear insight into the manner in which the penetration of the epithelium takes place. The upper portion represents the surface of the growth. Extending into the depth are long dark strands of cells, which give off numerous branches, as seen at *a*; these again subdivide into the terminals *b*, *b'*, *b''*. *c* is one of the rootlets cut obliquely, and *d* is a cross section of a terminal branch of cells—a small cell-nest. The masses of epithelium invade the cervix precisely in the way the roots of a tree penetrate the soil.

In Plate I was illustrated the abrupt change from normal epithelium to carcinomatous tissue, but in other places it is possible to study the gradual transition from the normal to the distinctly carcinomatous cell. For instance, in Fig. 42 (p. 58), taken from Fig. 39 at point 5, the right third of the surface consists of perfectly normal squamous epithelium, *a*; while the remaining portion has undergone carcinomatous transformation. *b* indicates cross sections of normal papillæ; *c* shows the point of transition from the normal to the pathological cell. The enlarged and deeply staining nuclei at *d* should be compared with those at *a*, which are normal. *e* is an elongated papilla; at *f* there is some necrosis of the surface, and at *g* are several cells containing large and deeply staining nuclei. The stroma beneath the normal mucosa is unaltered, but that underlying the carcinomatous portion already shows small-round-cell infiltration, although the epithelium has not penetrated into the depth. The nuclei of the carcinomatous cells are in strong contrast with those of the normal ones.

In the case now under discussion it will be noted (Fig. 39) that the cervical canal was implicated at an early stage, and hence the cervical mucosa was encroached upon. Fig. 43 (p. 59), taken from Fig. 39 at point 4, portrays the beginning involvement of a uterine gland. *a* represents the upper half of a normal cervical gland; at *b* the stroma of its wall has been invaded by a mass of epithelial cells. It is instantly seen that the cells are irregular in size, many of them containing large and deeply staining nuclei. This phase is well illustrated at *c*. Not only is the gland wall invaded on both sides, but the squamous epithelium has grown into the gland and extends as far as *d* and *d'*. The irregularity in the size of the nuclei, together with the increased amount of chromatin (*e*, *e'*), leaves no doubt as to the malignant character of the tissue.

In Fig. 56 (p. 93) the glands are also involved. The three presented in the picture are practically choked by masses of squamous cells, and cell-nests (*b*) are seen lying between the glands. The cervical glands occasionally become occluded and markedly dilated. The epithelium lining the ducts is somewhat flattened, and the lumina contain desquamated epithelial cells and mucus. The cervical mucosa is usually preserved until the growth is fairly well advanced. Fig. 305 (p. 620) represents a remarkable instance of its preservation. Here, although the growth has extended upward beyond the internal os, the epithelium of the cervical canal has remained intact (Fig. 306), notwithstanding the fact that masses of cancer cells were lying almost directly upon it.

All the epithelial layers take part in the invasion of the cervix, and the deep cylindrical or cuboidal layer forms the front row of the encroaching mass of cells (Fig. 37, p. 52). Thus, if a section be made of these penetrating, finger-like or branching, masses of cells, the cylindrical layer appears to form the outer or external layer. This arrangement can usually be traced through all portions of the growth, but is most characteristic along the margin of the carcinoma. The cells forming the nests have large, oval, vesicular nuclei, and are sometimes uniform in size. In Fig. 107, if the three large nuclei be excluded, there is little variation in size, but, as a rule, a given nucleus will be two or three times as large as its neighbour, as seen in Fig. 57 (p. 95). In this specimen giant cells are also found, one mass of protoplasm containing as many as nine vesicular nuclei (*g*). In Fig. 59 (p. 97) giant cells not only form part of the cell-nest, but are found lying free in the stroma at *c*. Fig. 77 (p. 139) also contains giant cells at *b* and *c*.

The cell-nest represented in Fig. 61 (p. 102) is a very good example of those frequently found along the advancing margin of the growth. The cells vary much in size; some are slightly vesicular, but the majority stain deeply. To the right, where the process seems to be advancing, the cells are elongated and the nuclei rich in chromatin.

Epithelial Pearls.—In the cervix the horny layer is usually poorly developed or entirely wanting; hence epithelial pearls are not frequent in squamous-cell carcinoma in this region. In Fig. 35, however, typical examples are represented. In the outermost layers of the cross sections of the pearls, *a*, *b*, *c* (Fig. 35), the cells are seen to be faintly cuboidal. The succeeding layers consist of cells having small, round, somewhat deeply staining nuclei, and a few that are vesicular, while the centre is filled with cells concentrically arranged, forming pearls and containing spindle-shaped nuclei. This central portion consists of horny epithelium; not infrequently the cells are oval or irregular in shape, and, as a result of kerato-hyaline change, stain deeply with eosin. In most of them the nuclei have entirely disappeared.

Nuclear Figures.—Even in specimens hardened in Müller's fluid many nuclear figures are found. The division is often perfectly regular, as in Fig. 60, A, C, E, and F (p. 99); in other cases some modification is noticeable, as in D and B; D represents the diaster stage; the separation of the chromatin has been retarded, some fragments still remaining along the achromatic filaments. In Fig. 60, B, a portion of the chromatin is still clinging to the poles. Such slight divergences from the normal probably account for the unequal division of the cells. At times three, four, and even more centres of division are found in the same cell.

Increase in the Cell Chromatin.—One of the most important alterations in the epithelial cell, after its carcinomatous transformation, consists in an increase in the amount of chromatin contained in it. Even in Fig. 41, *b* (p. 57), although the picture is only suggestive of carcinoma, the nuclei have already reacted much

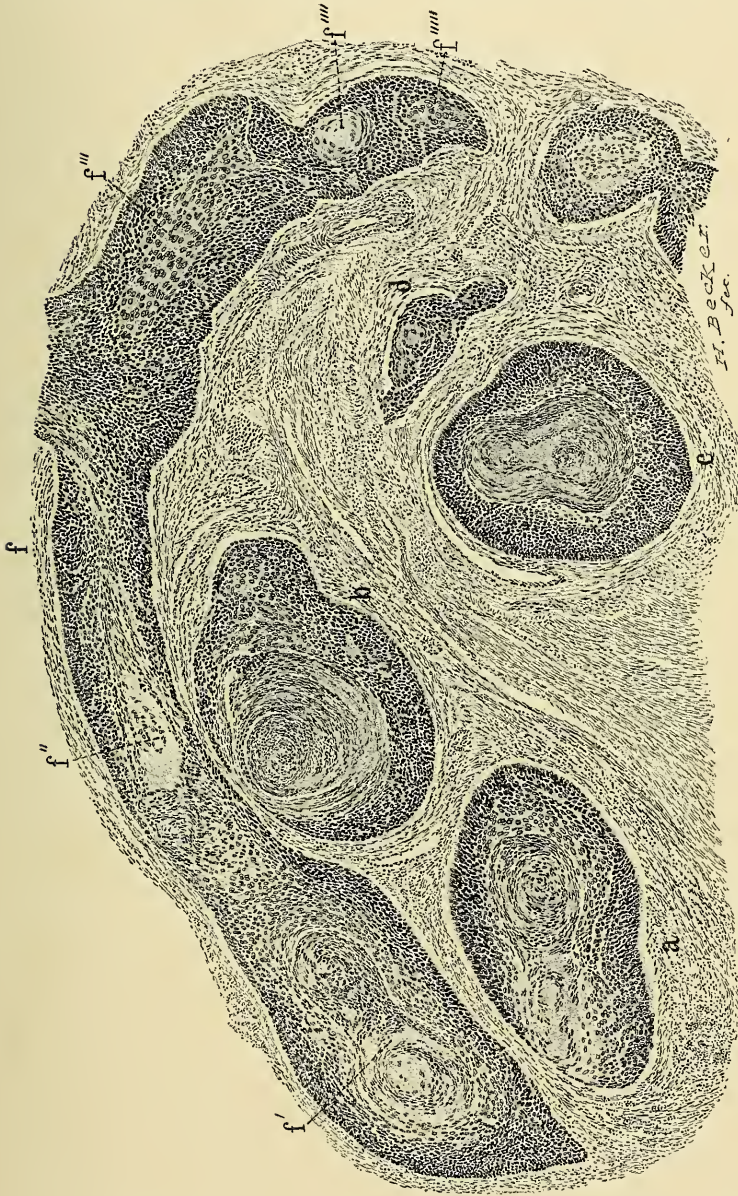
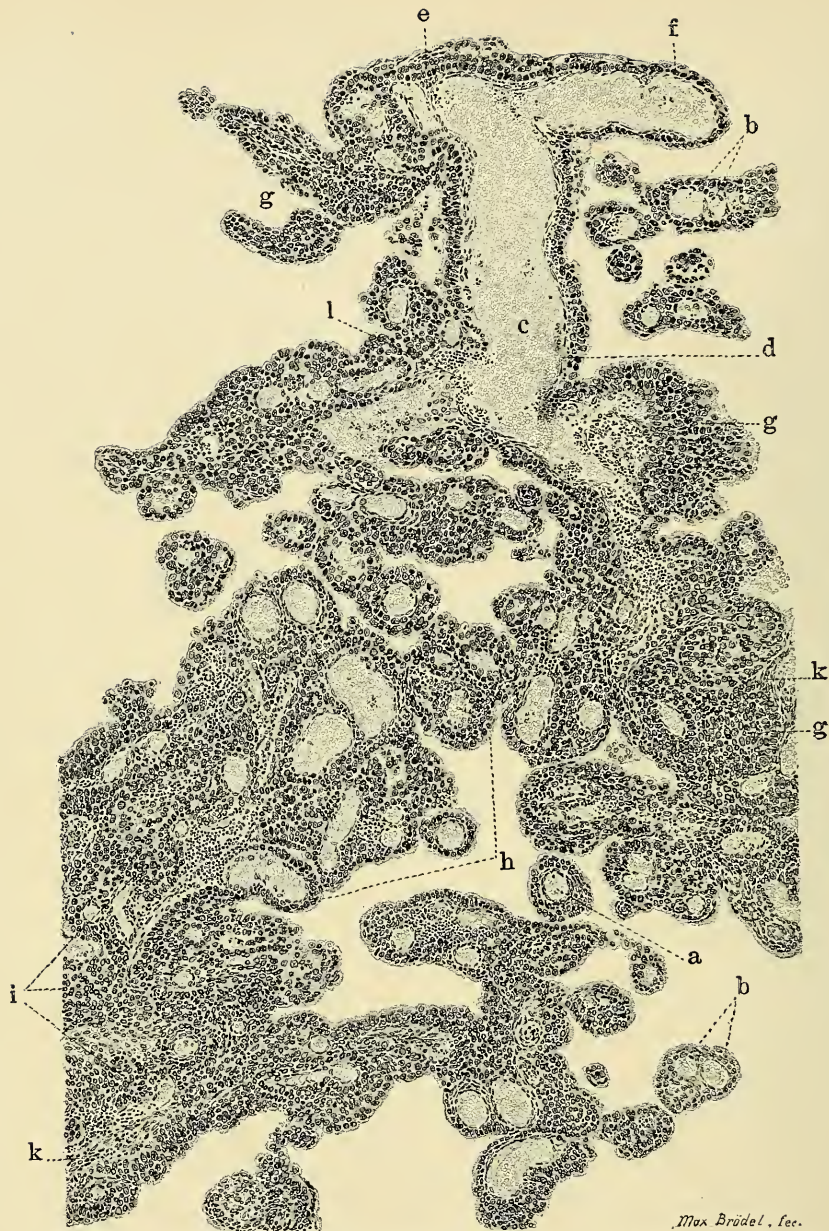
FIG. 55.—EPITHELIAL PEARLS. (70 diameters.)

Gyn.-Path. No. 1,147. *a, b, c* are typical pearls, and can be readily divided into two distinct zones: an outer portion consisting of cells having nuclei of a uniform size and staining somewhat deeply, and a central zone in which the nuclei are spindle-shaped and concentrically arranged. In *a* and *b* some of the nuclei in the outer zone are vesicular. *c* has two central points around which the spindle-cells cluster. *d* is a cell-nest with just a suggestion of horny epithelium near its centre. *e* shows the oval vesicular nuclei near the centre, but no distinct horny epithelium. The long cell-nest, *f* shows admirably the various steps of the formation of pearls. Commencing at *f'''* with a few oval vesicular nuclei, it gradually becomes more and more perfect in *f''*, *f'*, and *f'*, until the typical pearl is seen at *f'*. The stroma of the specimen consists of connective-tissue cells with spindle-shaped nuclei. There is no small-round-cell infiltration.

more intensely to the stain. The alteration is marked in Fig. 42 (p. 58), and the large deeply staining nuclei of Fig. 43 (p. 59) leave no doubt whatever as to the malignant character of the growth, the diagnosis being based almost entirely



Max Brödel, sec.

FIG. 36.—CROSS SECTIONS OF THE FINGER-LIKE GROWTHS IN SQUAMOUS-CELL CARCINOMA OF THE CERVIX. (70 diameters.)

Gyn.-Path. No. 2,890. The section is from the curetting of the surface of a cauliflower-like outgrowth; fully one third of the field consists of cross or longitudinal sections of blood-vessels. *a* indicates a delicate capillary, which is surrounded by from two to three layers of squamous epithelium, and appears in a cross section of a typical finger-like outgrowth. At *b* is a finger of tissue containing two blood-vessels, or possibly two sections of the same vessel, if it has been a very tortuous one. *e* is a large blood-vessel. Note the very fragile walls, consisting of a layer of endothelium (*d*), and external to this a few young connective-tissue cells. Covering the surface of this vessel are a varying number of layers of squamous cells; at *e* three or four layers, the one next the vessel being cuboidal; at *f* only one layer. *g* indicates solid areas, rich in epithelial cells. In some places blood-vessels are scattered sparingly throughout them. *i* indicates cell-nests, which render the diagnosis of squamous-cell carcinoma fairly easy. *k* is the stroma of the growth, very scanty in amount and consisting of a few spindle-shaped cells, but principally of small round cells. At point *l* in the large vessel (*c*) is a clump of polymorphonuclear leucocytes. The entire picture bears a striking resemblance to angiosarcoma, more especially the area inclosed by *h*.

From this drawing it is readily seen how free hæmorrhage can follow even gentle handling of the cauliflower outgrowth.

on the relative size of the cell and its increased amount of chromatin. Occasionally, especially when nearly all traces of the normal cell have disappeared and large masses of protoplasm of the new growth are forming channels through the stroma of the cervix, correspondingly large and irregular masses of chromatin will be found (Fig. 77, *d*, p. 139).

Finger-like Projections.—We now direct our attention to those portions of the cervix where appear the delicate finger-like projections, or the cauliflower-like masses formed by them. With slight magnification of Fig. 45 (p. 62) we obtain Fig. 46, showing the rounded extremities of the fingers projecting from the surface. Further examination with a higher power reveals the fact that the projections are usually single and spring directly from the stroma. Fig. 51 (p. 81) represents a longitudinal section of such a finger. It contains a large central blood-vessel with a very delicate wall of endothelium, and is covered externally by many layers of squamous epithelium. In the lower half of the field are cross sections of two fingers with a third flattened between them. Fig. 48 (p. 68) represents a finger taken from Fig. 47 at point 1. Its centre is occupied by a large delicately walled blood-vessel, around which are a few small round cells, and more externally many layers of squamous epithelium. In this particular instance the epithelial cells are very uniform in size, although, as a rule, they are not only subject to great variations in this respect, but often contain much chromatin. Fig. 53 (p. 84) represents the tips of four finger-like projections in cross section, and strongly suggests an angiosarcomatous growth. In each of three of the folds one vessel is seen, while the fourth contains three. The exceedingly delicate walls and the small round cells externally are to be noted. The outer covering of these projections consists of many layers of epithelial cells; the cells of one finger have coalesced with those of the one adjoining. The nuclei of the epithelial cells vary considerably in size, and some contain an increased amount of chromatin. Fig. 36 (p. 50) represents a curetting from the surface of a cauliflower mass. Everywhere are seen large blood-vessels which have very delicate walls and are covered by a varying number of layers of epithelial cells. Thus, at *f* there is only one layer, while at *e* the covering is formed by at least four layers. The finger-like projections are much broader at their bases, as is seen in Fig. 62 (p. 103) and Fig. 38, C (p. 54). Here the stroma is abundant and contains a rich blood supply. The outer surface shows the same epithelial covering. While these finger-like processes usually spring separately from the stroma, there is occasionally seen a tree-like projection giving off secondary or terminal fingers (Fig. 55, p. 91).

From what has been said, then, it appears that (1) squamous-cell carcinoma of the cervix consists of an ingrowth and branching of the squamous epithelium of the part; (2) coincident with the ingrowth there is generally a branching outgrowth of the stroma and epithelium, forming a cauliflower or mushroom-like tumour. The general scheme is represented in Fig. 37 (p. 52).

The stroma consists of the normal cervical tissue. Between the cell-nests it generally shows a slight or moderate amount of small-round-cell infiltration. This

is usually abundant along the advancing margin of the growth and where there is also an increased blood supply. It is somewhat difficult to determine the exact origin of the small round cells. Some of them—in fact, in many instances the majority—are mononuclear eosinophiles, and have undoubtedly wandered out

from the blood-vessels. A few appear to be connective-tissue cell derivatives. It is exceptional to detect nuclear figures in the stroma.

Lubarsch,* in a critical review of the literature on carcinoma in general, refers particularly to the views of various investigators concerning the stroma. Klebs does not consider it as a secondary growth, but thinks that it goes hand in hand with the epithelium. Hanau and Hansemann believe that a connective-tissue growth may be lacking, the latter pointing out that the stroma in carcinoma does not consist entirely of connective tissue, but also of adipose tissue, smooth muscle fibre, etc. Stroebe states that a malignant

growth penetrating the tissue acts in the same manner as a foreign body, producing an irritation. This theory would account for the small-round-cell infiltration so frequently noted along the periphery of a carcinomatous growth.

Hausser, according to the same reviewer, found mitoses only rarely in the stroma, in the proportion of about eight to five hundred in the epithelial cells. Hansemann finds the explanation for this in the fact that the mitotic cycle for connective-tissue cells lasts a much shorter time than that for epithelial cells.

A study of our cases has shown that where the growth was rapid, the amount of infiltration was usually small, but in those cases in which the progress was slow,

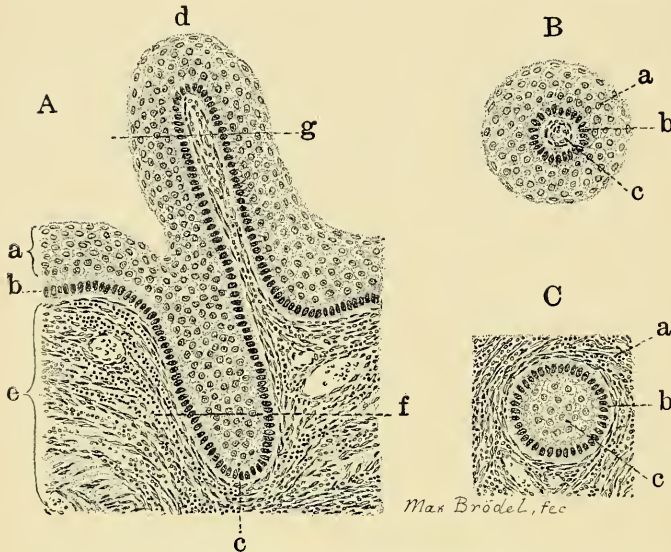


FIG. 37.—A SCHEME DEMONSTRATING THE MANNER IN WHICH SQUAMOUS-CELL CARCINOMA OF THE CERVIX DEVELOPS.

A. The section is from the vaginal portion of the cervix. *a* indicates the polygonal layers of squamous cells. *b* is the deep or cuboidal layer. At *c* the epithelium is penetrating the underlying stroma. *d* is an outgrowth from the cervix, consisting of a central stem of the stroma, carrying the various layers of squamous epithelium before it. Schematically it represents the earliest stage in the cauliflower outgrowth.

B is a cross section of the outgrowth *d*, Fig. A, taken at point *g*. The outer surface is covered by several layers of squamous epithelium, *a*, and an inner or cuboidal layer, *b*. The centre consists of the stroma, *c*.

C is a cross section of the downgrowth *e*, Fig. A, taken at *f*. Here the condition is naturally reversed; the cuboidal layer, *b*, forms the outer margin of the nest; the squamous epithelium, *a*, the centre.

* Lubarsch, O. *Ergebnisse der allgemeinen pathologischen Morphologie und Physiologie des Menschen und der Tiere*. Lubarsch und Ostertag, Wiesbaden, 1895, S. 430.

a marked reaction had taken place. In specimens hardened in the ordinary way I have rarely been able to find connective-tissue cells dividing.

In the finger-like projections there has undoubtedly been a new formation of connective tissue, rich near the bases of the fingers but scanty toward the apices.

As has been noted, the stroma, especially along the advancing margin of the growth, usually has a very good blood supply. In the older portions where necrosis has taken place, the vessels are also numerous, but are frequently filled with thrombi.

Stage 2. Moderate Disintegration of the Cervix.—An examination at this stage shows that the line of invasion is still further advanced; in other respects the

margin presents the same appearance as was noted in the early stage. On passing inward, however, toward the older portions of the growth, the surface is found covered by necrotic material, blood, and polymorphonuclear leucocytes, held together by a mesh-work of fibrin. The tissue lying directly beneath shows a considerable degree of coagulation necrosis, and many of the cell-nests have been invaded by polymorphonuclear leucocytes. At first the leucocytes are few in number, having wandered in here and there between the squamous cells (Fig. 61, p. 102; Fig. 57, p. 95). They are easily recognised by the horseshoe shape of their nuclei. In other cell-nests they become more abundant until the entire centre is filled, as in Fig. 38. Here the leucocytes have wandered in and loosened up

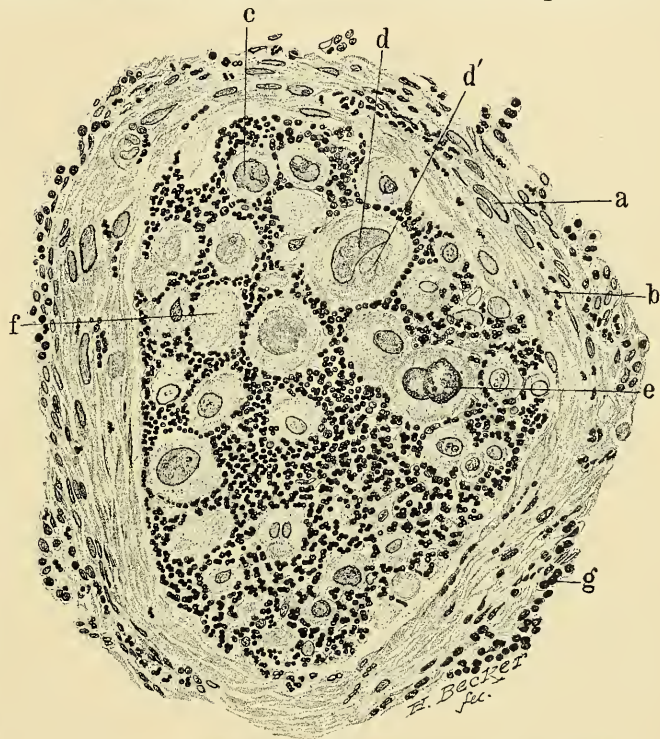


FIG. 38.—A CELL-NEST SHOWING DISINTEGRATION OF ITS CENTRE.
(360 diameters.)

Gyn.-Path. No. 1,090a. The outer layers of squamous cells are still preserved, but are flattened; their nuclei, as seen at *a*, are elongate oval and vesicular. Lying between the cells of the outer layers are a moderate number of polymorphonuclear leucocytes, especially numerous at *b*. The entire central portion of the nest is filled up with polymorphonuclear leucocytes and isolated epithelial cells. The nucleus of the cell *e* is irregular and has ragged margins. One of the large cells contains hyaline droplets, *d'*, and the nucleus, which is half-moon shaped, is pushed toward the side of the cell. *e* is a cell containing two deeply staining nuclei. In the cell *f* all trace of the nucleus is gone. Surrounding the cell-nest are small fragments of stroma, as seen at *g*.

the cement substance and separated the cells from one another. The cells around the margin, however, are still fairly well preserved. With such a loosening

ing-up, or rather liquefaction, of the tissue, it is readily understood that the cervix rapidly disintegrates. Fig. 63 (p. 107), on cursory examination, appears to be similar in character to Fig. 38, the margins of the alveoli being lined by many squamous cells, the centres filled with pus cells and detritus. Now it can readily be understood that if the leucocytes came from the vessels in the stroma of the part, they must needs have passed between the epithelial cells to reach the centre; but such could hardly have been the case, inasmuch as practically none are found between the squamous cells.

This section was taken from near the surface of the growth where numerous elevations and depressions were present. The spaces represent the depressions, and the pus covering the surface of the cervix has naturally found its way into the pockets between the ridges.

In this stage the finger-like outgrowths are still to be made out, and they also show more infiltration by polymorphonuclear leucocytes and small round cells.

Cell Degeneration.—Although some cell alteration is present in the early stage, it is much more marked when the growth has gained considerable headway. This change consists chiefly in hyaline degeneration, which affects not only the cell protoplasm but also the nucleus. There is also an increased tendency toward the formation of giant cells. The protoplasm of the large nucleus to the left in Fig. 107 (p. 209) has retracted from its outer membranous covering, and is clinging to the degenerated nucleus. In Fig. 38 (p. 53), at *d*, the nucleus contains several vacuoles which stain faintly with eosin. Fig. 75, B (p. 137), represents a large oval cell, the relative size being determinable from the polymorphonuclear leucocyte above it. The nucleus *a* is lobulated, half-moon shaped, and pushed to one side, while the protoplasm at *b* and *b'* forms spherical globules that stain more intensely with eosin and give the usual hyaline reaction. The protoplasm has retracted, leaving the empty space *c*.

Changes in the Nuclei.—In Fig. 75, D, the nuclei are irregular in shape, and the chromatin in *c*, *d*, *e*, and *f* forms a regular skein composed of fine granules, while several of the intervening spaces contain large hyaline droplets. In Fig. 75, C, the cell protoplasm is obscured by the size of the nucleus, which in turn is itself distended by three large hyaline droplets. The nuclear chromatin accommodates itself to the chinks between the droplets.

Fig. 76 (p. 138) shows one of the largest nuclei I have ever seen. Its immense size can be appreciated by comparing it with *a*, which represents the average size of the nucleus of the neighbouring cancer cells. The protoplasmic outline of the cell cannot be definitely determined. The chromatin of the nucleus is abundant, but unevenly distributed, while scattered throughout it are droplets (*g*) giving the hyaline reaction. The smaller droplets within the larger ones give a more intense reaction. The large cell in Fig. 38, *B* (p. 54), shows not only the droplets (*d*) in the nucleus and the loss of the chromatin, but also the invasion of the protoplasm and nucleus by polymorphonuclear leucocytes (*b*, *c*).

Stage 3. Extensive or Complete Involvement of the Cervix.—The third stage shows the results of a gradual intensification of the preceding changes. Here, also, the surface is covered by pus and blood. The underlying tissue shows much necrosis, and the cell-nests contain many more polymorphonuclear leucocytes.

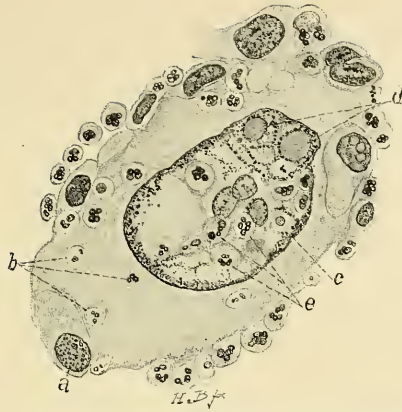


FIG. 38 B.—INVASION OF A VERY LARGE CANCER CELL BY POLYMORPHONUCLEAR LEUCOCYTES. (630 diameters.)

Gyn.-Path. No. 216. The entire picture is composed of one large cancer cell with numerous smaller epithelial cells and polymorphonuclear leucocytes clinging to its margins. *a* is a cancer cell that has embedded itself in the margin of the large cell. Scattered throughout the protoplasm of the large cell are numerous pale hyaline droplets and polymorphonuclear leucocytes, as seen at *b*. *c* is the nuclear membrane. *d* shows some of the droplets lying in the nucleus. The nucleus also contains numerous polymorphonuclear leucocytes, as indicated by *e*.

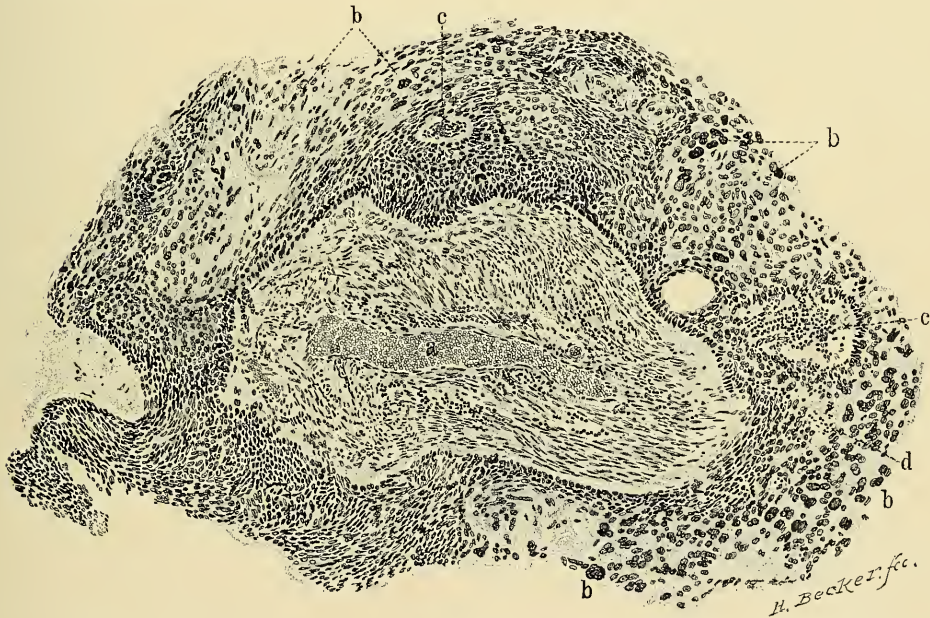

FIG. 38 C.—AN OBLIQUE SECTION OF A FINGER-LIKE PROCESS NEAR ITS BASE. (90 diameters.)

Gyn.-Path. No. 1699. The drawing is from a squamous-cell carcinoma of the cervix. Occupying the centre is the blood-vessel *a*, surrounded by an abundance of stroma. This consists mainly of cells containing spindle-shaped nuclei, but has scattered throughout it numerous small round cells. Covering it are many layers of epithelial cells. Those adjoining the stroma manifest a tendency to be cuboidal, and at numerous points the nuclei are small, irregular, and stain uniformly. At *b, b* they are, however, much increased in size, and contain a marked excess of chromatin. In none but a malignant growth do we expect to find the epithelial cells containing such large and deeply staining nuclei. *c, c* are cross sections of small papillae. At *d* some small round cells have wandered in between the epithelial cells.

Furthermore, many of the epithelial cells show disintegration of the nuclei, the nest being filled with necrotic and fragmented nuclei and pus cells.

CASES ILLUSTRATING THE VARIOUS STAGES OF SQUAMOUS-CELL CARCINOMA OF THE CERVIX

In the preceding pages we have attempted to make clear the main gross and histological features of squamous-cell carcinoma of the cervix. There still remain, however, many minor points that can only be fully appreciated by a thorough study of the individual cases; in fact, it is only from carefully following up the records of many cases that one can gain an adequate idea of the pathological changes.

In order to emphasize the more essential points, a summary of each case precedes the general description.

Gyn. No. 2,590

Squamous-cell carcinoma of the cervix (Figs. 39 and 40) with a cauliflower-like outgrowth. Early changes in the squa-

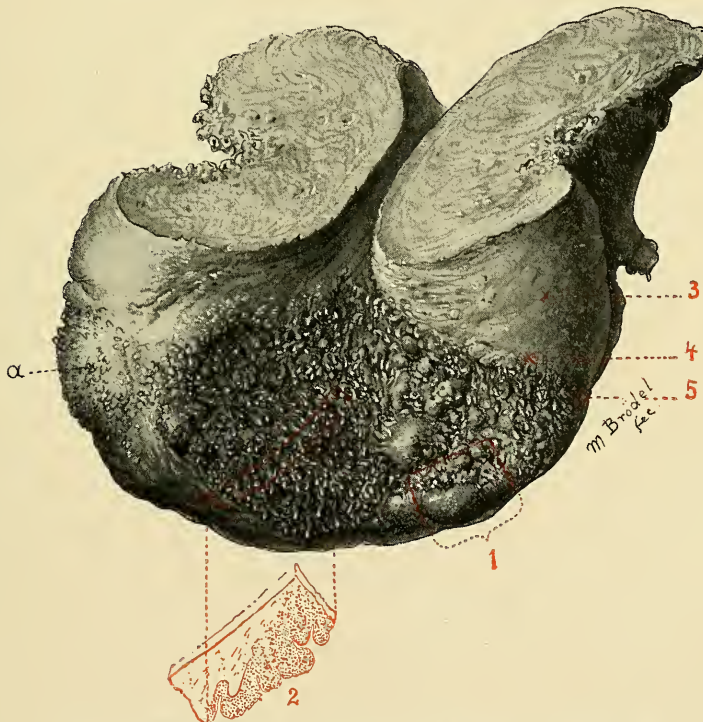


FIG. 39.—SQUAMOUS-CELL CARCINOMA OF THE CERVIX. (Natural size.)

Gyn.-Path. No. 169. Viewed from below. The cauliflower-like mass has been curetted away, but springing from the enlarged and thickened cervix are delicate finger-like outgrowths, which in a few places have coalesced, forming smooth masses. The advancing margin of the growth is irregular, and appears to be sharply defined. At *a*, over an area 1 × 1.5 centimetres, is a slight elevation covered by very delicate knobs or finger-like projections. This specimen shows very well how the carcinoma may appear in the earliest stage. The cervical canal has been invaded for a short distance.

mous epithelium (Fig. 41); transition of normal into carcinomatous epithelium (Fig. 42); early involvement of the cervical glands (Fig. 43); the manner in which the cervix is invaded (Fig. 44); vaginal hysterectomy; recovery. Local recurrence. Death nine months after operation.

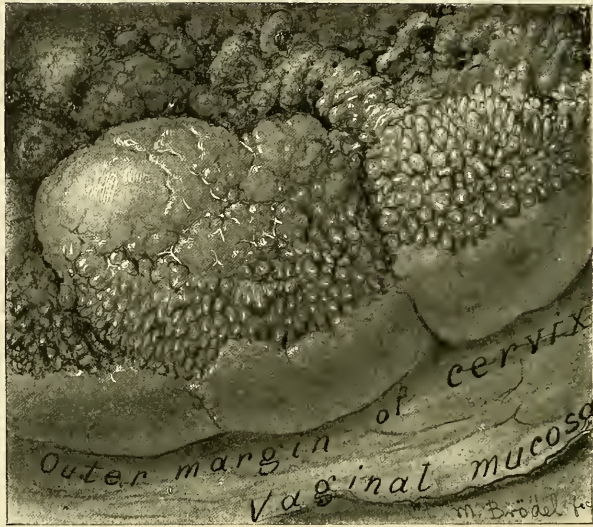

FIG. 40.—SQUAMOUS-CELL CARCINOMA OF THE CERVIX SHOWING THE ADVANCING MARGIN AND THE KNOB-LIKE PROJECTIONS FROM THE SURFACE. (6 diameters.)

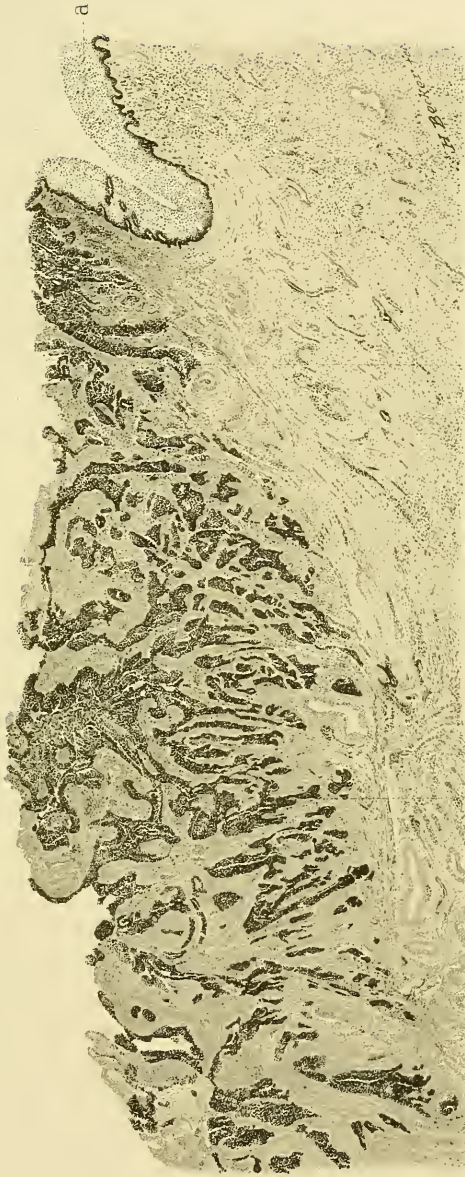Gyn.-Path. No. 169. The section is from Fig. 39 at point 1, and has been six times enlarged. The upper part consists of necrotic tissue; beneath is a dome-like, slightly elevated, and apparently firm mass. Along the advancing margin is a zone of small knob-like projections. The outer limit of the growth, although irregular, is sharply defined. In the neighbourhood of this section the outer portion of the cervix is still intact and the vaginal mucosa normal.

L. W., aged thirty-one; white. Admitted February 13, 1894. Complaint: constant uterine hæmorrhage. Her maternal grandfather died of carcinoma: otherwise the family history is negative.

The patient has had one normal labour, but no miscarriages. For fourteen years she has been troubled with asthma. Her menses commenced at fourteen, lasted from five to six days, were free, and usually preceded by considerable pain. For seven months there has been a slight increase in the menstrual flow, and three months ago she had a copious discharge. Latterly, the slightest exertion has been sufficient to cause free hæmorrhage. At no time has she complained of pain in the region of the uterus.

The patient is well nourished; the mucous membranes are of a good colour; the appetite is good; the bowels are regular; during the last two weeks, however, she has suffered considerably with hæmorrhoids. There is a constant desire to micturate. The vaginal outlet is relaxed, and springing from the cervix is a fungating mass, bleeding freely on manipulation, which fills the entire upper part of the vagina. The uterus is small and freely movable; no involvement of the broad ligaments can be detected.

PLATE I.



X 8

Squamous-cell carcinoma of the cervix showing its point of junction with the normal mucosa of the vaginal portion.

Operation, February 15, 1894. The fungating mass was first curetted away with the finger and the anterior and posterior lips were sutured together. The vaginal vault was ringed as far away from the diseased tissue as possible, and as the growth had involved the left side, a catheter was introduced into the left ureter. This was readily done without elevating the pelvis, and enabled the operator to go farther toward the left side than he would otherwise have dared to do. The uterus was then removed in the usual manner, and a gauze drain introduced into the vagina. For the two days following the operation the patient complained bitterly of pain in the lower part of the abdomen, and was

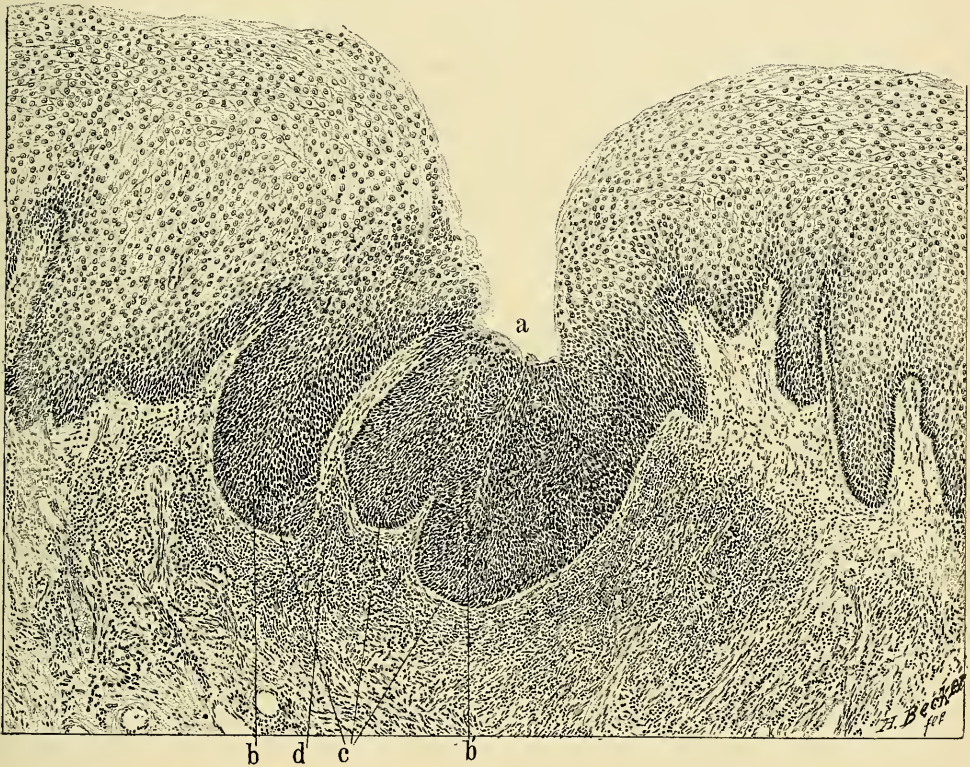

FIG. 41.—SUSPICIOUS CHANGES IN THE EPITHELIUM ALONG THE OUTER MARGIN OF A SQUAMOUS-CELL CARCINOMA OF THE CERVIX. (55 diameters.)

Gyn.-Path. No. 169. The section is from point *3*, Fig. 39, at least 1 centimetre from the margin of the growth. The squamous epithelium on both sides is perfectly normal, but at *a* the superficial layers have dropped off, while the deeper portions have proliferated and extend a short distance into the depth at *b* and *b'*. The cells of the downgrowth are closely packed together, and their nuclei stain more intensely. Along the advancing margin the cuboidal layer of epithelium *c* can still be distinctly made out. The stroma immediately beneath the downgrowth *b* and *b'* is richly infiltrated with small round cells, which are especially abundant at *d*.

nauseated. By the seventh day all the symptoms had disappeared, and the patient was discharged (March 8th) feeling perfectly well.

Gyn.-Path. No. 169. The specimen consists of the uterus to which a portion of the left vaginal wall is attached. The uterus measures $10 \times 6 \times 5$ centimetres.

Both anteriorly and posteriorly it is covered by peritoneum. The cervix appears to be greatly enlarged. Occupying the posterior lip, a portion of the anterior lip, and also the vaginal vault on the left side, is a new growth (Fig. 39). This is sharply demarcated from the surrounding cervical tissue. It presents a worm-eaten appearance, and on being carefully torn apart is found to consist of delicate

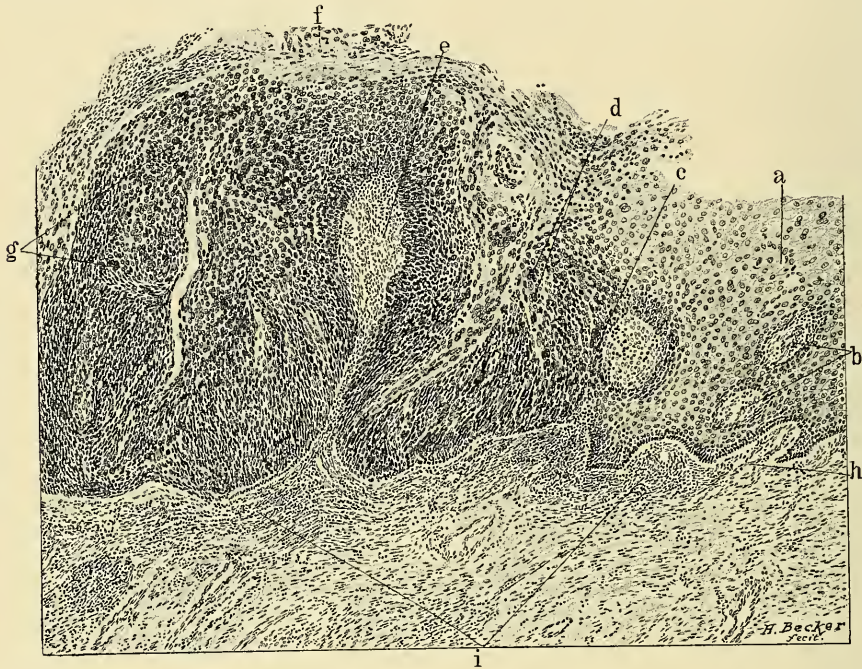

FIG. 42.—TRANSITION OF NORMAL INTO CARCINOMATOUS EPITHELIUM IN SQUAMOUS-CELL CARCINOMA OF THE CERVIX. (80 diameters.)

Gyn.-Path. No. 169. The section is taken from Fig. 39 (p. 55) at point 5. *a* represents the normal squamous epithelium of the vaginal portion of the cervix. *b* shows two cross sections of papillae. *c* is the point at which the normal cells merge into the carcinomatous epithelium. Here the cells are very closely packed, the nuclei stain deeply, and at *d* and *g* they not only contain an increased amount of chromatin, but are also enlarged. *e* is an elongated papilla. *f* shows necrotic tissue on the surface. The stroma (*h*) underlying the normal mucosa shows no alteration, but in that beneath the carcinomatous portion considerable small-round-cell infiltration appears, as indicated by *i*. The gradual transition from the normal to the pathological cell could hardly be more typically represented than in this section.

filaments or little knob-like masses with slender pedicles (Fig. 40), and of irregular, broken masses which probably represent *débris* caused by the curette. On section, the growth can be traced for 5 or 6 millimetres into the underlying tissue (Fig. 39, 2), and in some places for fully 1 centimetre. The uterine walls average 2 centimetres in thickness; the mucous membrane is 1 to 2 millimetres thick, and is smooth and glistening.

HISTOLOGICAL EXAMINATION.—The most instructive pictures are those obtained along the advancing margin of the neoplasm. Just external to the growth one sees the normal squamous epithelium of the vaginal portion of the lip. On tracing this a short distance inward the epithelial cells seem more closely packed together, their nuclei are darker in colour, and the epithelium dips slightly into

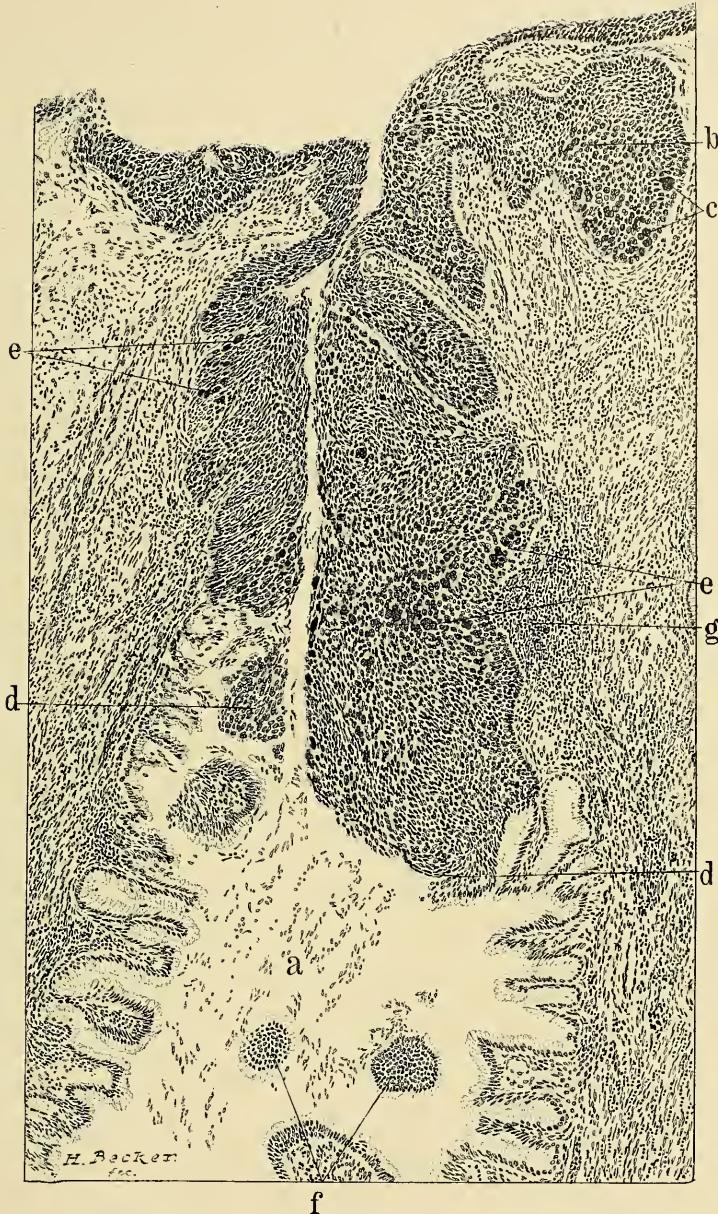


FIG. 43.—PARTIAL OBLITERATION OF A CERVICAL GLAND BY SQUAMOUS-CELL CARCINOMA OF THE CERVIX. (90 diameters.)

Gyn.-Path. No. 169. The section is taken from Fig. 39 at point 4. *a* is the upper third of a normal cervical gland. At *b* the stroma of its walls has been invaded by squamous epithelium. The nuclei of this epithelium stain very deeply, and several of them (*e*) are large and contain a marked excess of chromatin. The epithelium has extended a considerable distance into the gland, reaching to *d* and *d*. It is also much altered, the nuclei being closely packed together and staining deeply. Many of them are enlarged, irregular (see *e* and *e*), and contain much chromatin. At *g* the stroma is abundantly infiltrated with small round cells. *f* represents cross sections of two normal gland folds. The character of the squamous epithelium in this specimen renders the diagnosis of carcinoma certain. (See Fig. 56, p. 93.)

the stroma (Fig. 41). At these points the underlying stroma shows considerable small-round-cell infiltration. In some sections (Fig. 42) it is actually possible to follow the direct transition of the normal epithelium into the carcinomatous. On advancing still further, the squamous epithelium is seen extending down into and partially obliterating some of the cervical glands (Fig. 43). A more pronounced change can now be seen in this epithelium, the nuclei here and there being two or three times larger than normal, and staining very deeply. The invasion of the gland may not be uniform, the epithelium extending down farther on one side.

Over the more central portion of the growth the surface is found covered by fibrin and blood, and invading the stroma everywhere are finger-like ingrowths of squamous epithelium (Plate I). Fortunately many of these have been cut lengthwise, so that one is able to follow the branchings that take place. From one stem it is sometimes possible to trace at least a dozen terminal branches (Fig. 44). Numerous large, deeply staining nuclei are seen in the epithelial cells, especially in those situated along the advancing margin of the growth. The stroma of the cervix in its superficial portion has an exceedingly rich blood supply, and the tissue in various places shows a marked small-round-cell infiltration. The growth, which is a typical squamous-cell carcinoma of the cervix, appears to have been entirely removed. The uterine mucosa has an intact sur-

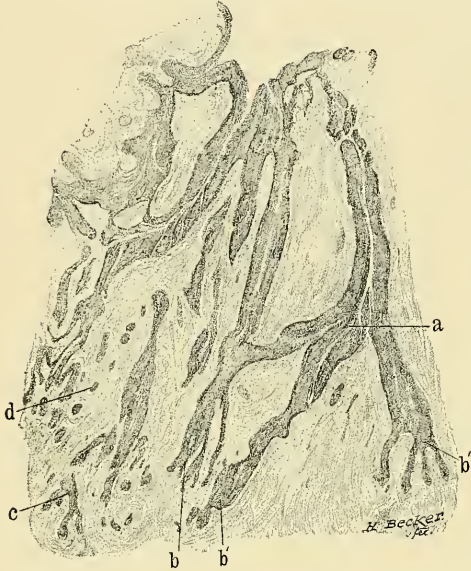


FIG. 44.—SQUAMOUS-CELL CARCINOMA OF THE CERVIX; MODE OF EXTENSION. (15 diameters.)

Gyn.-Path. No. 169. This section demonstrates well the manner in which the cervix is invaded. Note the downgrowth *a*, dividing into three branches, *b*, *b'*, and *b''*, which again subdivide into several terminal branches. *c* is an oblique section of one of the downgrowths. *d*, the cross section of one of the rootlets. It forms one of the smaller cell-nests.

face epithelium; its glands present the usual appearance, but the stroma is slightly edematous.

Diagnosis.—Squamous-cell carcinoma of the cervix with extension to the vaginal vault. There was a return of the growth, and the patient died about nine months after operation.

Gyn. No. 2,411

Squamous-cell carcinoma of the cervix; great thickening of the cervical lips; involvement of the right broad ligament; curettage.

A. P., aged thirty-nine; white. Admitted November 16, 1893. Complaint: pain in the lower part of the back; frequent uterine hæmorrhages; a non-offensive, watery vaginal discharge.

The patient has been married twelve years, and has had two normal labours and a miscarriage. Her family history is negative. For twelve months she has had frequent uterine hæmorrhages, and during the last few months has experienced considerable pain in the lower part of the abdomen and back. For four weeks there has been a watery vaginal discharge. The patient is markedly cachectic, presenting a whitish-yellow, waxy appearance. Her appetite is good, but she suffers somewhat from constipation. When the bowels are very constipated she has noticed an increased tendency toward uterine hæmorrhage. During the last few days she has lost flesh rapidly and has become very weak. This may be accounted for by the hæmorrhages, which now average two a week. The lower part of the abdomen is rather sensitive; the vaginal outlet is relaxed; the cervix is greatly thickened and indurated, and around the external os shows considerable loss of tissue.

The right broad ligament appears to be involved, the left seems to be free. The case had advanced too far for radical operation; it was only possible to remove part of the carcinomatous tissue by means of the curette.

The patient was discharged December 1, 1893, slightly improved.

Gyn.-Path. No. 89. The specimen consists of a large, indurated cervical lip.

Histological Examination.—The squamous epithelium covering the vaginal portion of the cervix can be traced for a short distance; apart from being slightly thicker than usual and showing some polymorphonuclear infiltration it is unaltered. After tracing it a short distance, however, the cells assume a totally different type; the nuclei are larger, more vesicular, and take the hæmatoxylin stain with avidity, while on the other hand the protoplasm stains less intensely with eosin. The cervical stroma is everywhere invaded by this altered epithelium, which penetrates in all directions, and is recognised as alveoli, oval, round, branching, or in fact assuming any form. In many places the cells of the new growth form a regular network. The centres of some of the alveoli are filled with necrotic material, scattered throughout which are polymorphonuclear leucocytes, which in many places have wandered in between the epithelial cells. The stroma of the cervix shows marked small-round-cell infiltration, and in places has a very rich blood supply.

Diagnosis.—Squamous-cell carcinoma of the cervix.

Gyn. No. 4,143

Squamous-cell carcinoma of the cervix with a cauliflower-like growth springing from the anterior lip (Figs. 45 and 46); abdominal hysterectomy; recovery.

The hæmorrhages returned within a month, and the patient died just two months after operation.

M. E., aged thirty-three; white. Admitted February 11, 1896. Complaint: uterine hæmorrhage. The patient has been married seventeen years; has had seven children and one miscarriage. The miscarriage occurred six weeks ago. Her menses commenced at fourteen and were regular until three years ago, since which time they have occurred at irregular intervals. The family history is good.

Six months ago the patient first noticed a bloody vaginal discharge. In the beginning this was scanty, but has been continually increasing in amount. Occa-

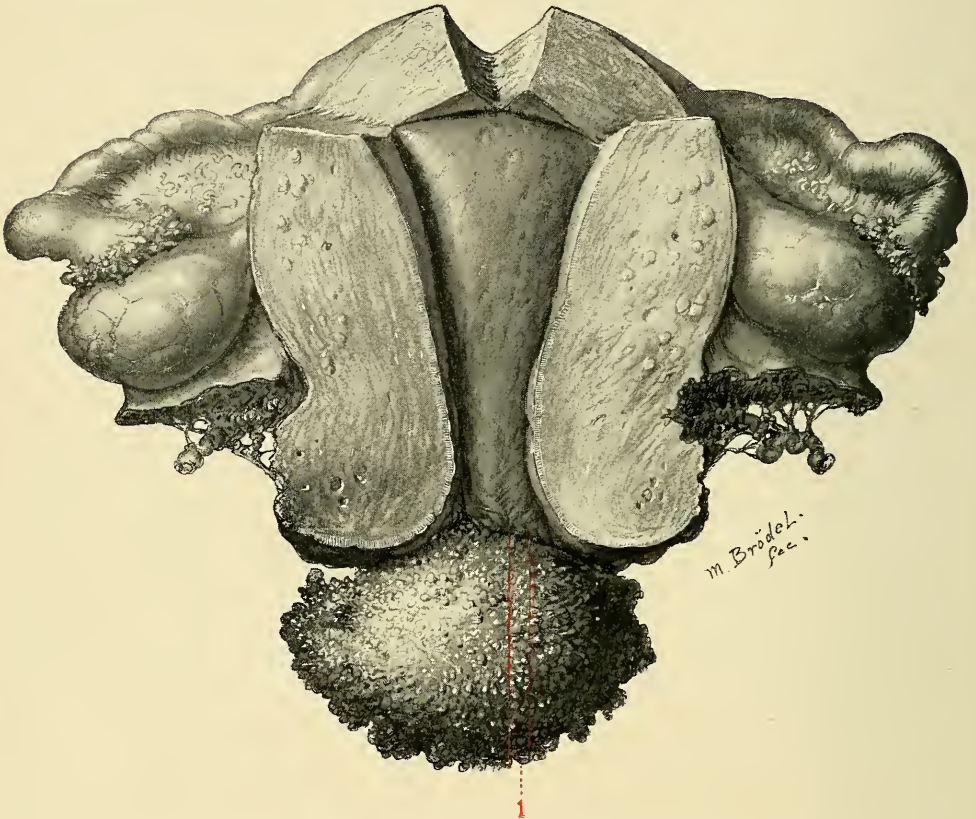

FIG. 45.—SQUAMOUS-CELL CARCINOMA OF THE CERVIX; CAULIFLOWER-LIKE MASS SPRINGING FROM THE ANTERIOR LIP. ($\frac{1}{8}$ natural size.)

Gyn.-Path. No. 1,070. As can be seen from the relative positions of the tubes and ovaries, the uterus has been opened posteriorly. Arising from the anterior lip is a large cauliflower mass. Its basal attachment is sharply defined, and the growth consists of myriads of delicate projections having rounded knob-like structures. There has been only slight breaking-down of the cervix. The uterus is normal in size, and its mucosa is of the usual appearance. Both the tubes and ovaries are normal. The uterine arteries have been dissected out, tied off near their points of origin, and removed with the uterus.

sionally, instead of being sanious, the discharge is yellowish-white, profuse, and offensive. The patient is fairly well nourished, but is very anæmic, and her skin has a sallow appearance. Her appetite is good, the bowels are constipated, and for some days she has been suffering with hæmorrhoids. The vaginal outlet is relaxed. Springing from the cervix is a fungating friable mass about as large as an orange. The uterus is movable, and the broad ligaments appear to be free.

Operation, February 15th. Abdominal hysterectomy. Before the administration of the anæsthetic, bougies were laid in the ureters. The operation was then completed in the usual way. Four glands were removed from each side

of the pelvis. The operation was rendered somewhat difficult on account of the obesity of the patient. Before she was taken back to the ward 1,000 cubic centimetres of normal salt solution were infused into the breasts. On March 7th she complained of pain throughout one limb. No swelling could be made out. On March 20th it was noticed that the limb was quite edematous, but of normal colour. On deep pressure some pain could be elicited in the popliteal space; the tenderness, however, was most pronounced over the femoral canal. The patient was discharged March 25, 1896, feeling well. On this date there was no swelling in the leg, and walking caused no discomfort.

Gyn.-Path. No. 1,070. The specimen comprises the uterus, its appendages, and several pelvic lymph glands. The uterus is 10.5 centimetres in length, 7 centimetres broad, and 4 centimetres in its antero-posterior diameter. It is free from adhesions. The cervix is hypertrophied, the lips averaging 2.5 centimetres in thickness. Springing from the anterior lip is a cauliflower-like excrescence $7 \times 5 \times 4$ centimetres (Fig. 45). This is composed of small semi-translucent papillæ varying from a pin-point to 3 millimetres in size. On examining the specimen, after hardening in Müller's fluid, the individual elements of the cauliflower mass are more sharply defined, and are found to consist of long and short finger-like masses having rounded or knob-like extremities (Fig. 46). Surrounding the neoplasm is a zone of apparently normal mucosa varying in breadth from .6 to 2 centimetres. The posterior lip over its vaginal portion presents an ulcerated surface, which extends to within 1 millimetre of the cut surface. Attached to the uterus on each side are portions of the broad ligament, averaging fully 4 centimetres in breadth. The cervical mucosa over the posterior lip

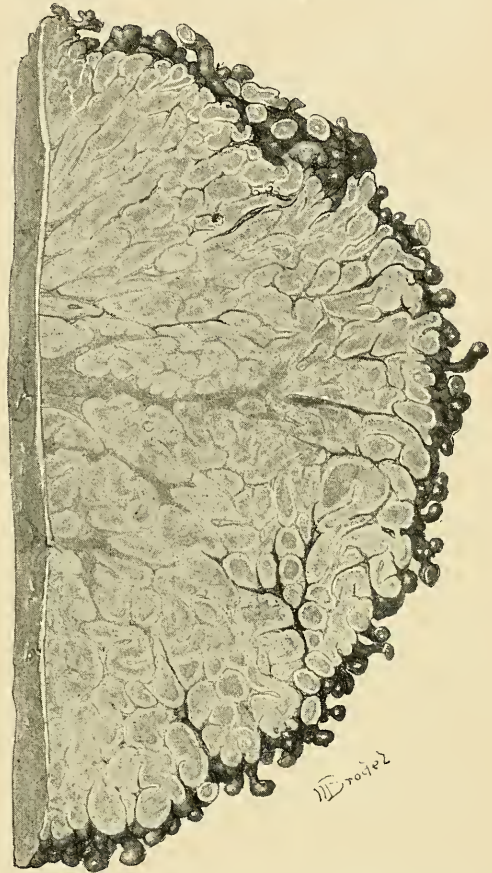


FIG. 46.—A SECTION OF THE CAULIFLOWER-LIKE MASS SEEN IN FIG. 45. (3 diameters.)

Gyn.-Path. No. 1,070. This section was taken from Fig. 45 at 1. Projecting from the surface are the rounded and knob-like extremities of the finger-like outgrowths. In the depth these fingers are cut transversely, obliquely, and, in fact, at all angles. Their white outer covering is composed of many layers of squamous epithelium; the dark central portions, of the stroma and blood supply. It is readily seen that the entire growth consists of these finger-like projections. (See Fig. 36, p. 50; Fig. 38 C, p. 54; Fig. 48, p. 68; Fig. 51, p. 81; Fig. 53, p. 84; Fig. 62, p. 103.)

just within the external os is slightly

eroded, and shows some dilatation of its glands; otherwise the mucosa throughout the cervical canal presents the usual appearance. The uterine cavity is 3.5 centimetres in length. Its mucosa averages 4 millimetres in thickness; it is somewhat corrugated, but smooth, and shows slight hæmorrhages in its superficial portions. The appendages are apparently normal. The pelvic lymph glands vary from .5 to 2 centimetres in diameter.

Histological Examination.—Sections from the cauliflower mass springing from the anterior lip show quite a number of the finger-like projections in cross section, and also several cut longitudinally (Fig. 46). Each has a central stem rich in young connective-tissue cells, and an exceedingly abundant blood supply, anywhere from two or three to twenty or more blood-vessels being recognisable. Of these, one is usually larger than the rest. Surrounding the central clump of connective tissue are many rows of epithelial cells whose nuclei are oval and vesicular. Between these cells are quite a number of polymorphonuclear leucocytes and small round cells. The deeper portions of the tissue are everywhere traversed by large, irregular, branching islands of epithelial cells. These islands communicate freely with one another, forming a regular network. The central portions of many of them contain fat droplets, fragmented nuclei, and polymorphonuclear leucocytes; in some the centres are completely filled with the leucocytes. The stroma of the tissue is everywhere made up of young connective-tissue cells. On passing toward the margin of the growth, it is seen to merge gradually into normal vaginal mucosa. The underlying stroma along the advancing margin of the growth shows marked dilatation of the veins, the tissue presenting an angiomatous appearance. Sections from the posterior lip show that the vaginal portion has been involved to a depth of 2 millimetres, the growth here being practically confined to the surface and extending upward to a point just within the external os. The cervical mucosa above this, except for some slight dilatation of the glands, is normal. It seems probable, from the sections examined, that the entire growth has been removed, but it must be said that the cancerous tissue extends alarmingly close to the cut surface along the vaginal vault.

The picture is that of a typical squamous-cell carcinoma. The uterine mucosa is normal and the appendages are unaltered. The pelvic lymph glands are somewhat enlarged, and show areas of hæmorrhage. They are not involved in the carcinomatous process.

Diagnosis.—Squamous-cell carcinoma of the cervix.

January 10, 1900. Dr. Haddaway, of Bethlehem, Md., writes me that the hæmorrhages continued from the time the patient reached home until her death, two months after operation.

Gyn. No. 2,627

Squamous-cell carcinoma of the cervix; a large cauliflower growth springing from the anterior lip; extension to the vagina; carcinomatous nodule, 2 centimetres in diameter, in left broad ligament. Vaginal hysterectomy; recovery from operation, but death eight months later from "asthenia."

M. E., aged fifty-three; white. Admitted March 5, 1894. Complaint: indefinite feeling of oppression throughout abdomen; moderate leucorrhœal discharge.

The patient has been married thirty-four years; has had nine children. All the labours were difficult, the first was instrumental; twelve years ago she had a miscarriage, followed by free hæmorrhage.

Her mother and one brother died of tuberculosis. The patient herself has always been in good health, with the exception of an attack of rheumatism three years ago. Her menses ceased June, 1893. Four months ago she had a free hæmorrhage which persisted for several hours, and three weeks ago a second one, which was freer than the first. After the hæmorrhages she felt weak, but experienced no pain. On admission, the patient was well nourished and of a good complexion. Her appetite was normal, her bowels were constipated, and defecation was somewhat painful. She had a moderate leucorrhœal discharge.

Operation, March 6, 1894: Vaginal hysterectomy. The anterior lip of the cervix was converted into a large fungating mass. Situated in the left broad ligament was a carcinomatous nodule about 2 centimetres in diameter. In dissecting this out the ureter was laid bare for a distance of 3 centimetres.

During convalescence the patient was entirely free from pain, but had a constant desire to urinate.

She was discharged April 3, 1894. Eight months later she died of gradual asthenia.

Gyn.-Path. No. 198. The specimen consists of the uterus, a cauliflower-like mass which was removed from the cervix before operation, and of the right tube and ovary. The uterus measures $7 \times 5 \times 4$ centimetres. Both anteriorly and posteriorly it is smooth and glistening. On cutting open the uterus, the lower half of the cervix is represented anteriorly by a mere shell, and its vaginal portion presents a worm-eaten appearance. Posteriorly the outer portion of the cervix does not appear to be implicated. The new growth extends upward through the cervix in the form of a wedge, and is very hard and unyielding. The fungating mass which was found springing from the anterior lip measures $6 \times 6 \times 3$ centimetres. It presents nothing characteristic, but after hardening in alcohol cuts like cheese. The cervical mucosa is pale and glistening, and contains a few small cysts, whose contents are transparent. The uterine walls average 2 centimetres in thickness, and the mucosa is of a dark red colour. A small portion of the left side of the vagina is found to contain a nodule 2 centimetres in diameter, just beneath its mucous covering. The nodule is very hard, and on section presents a homogeneous appearance.

The tube presents nothing of importance, but the ovary is covered by numerous delicate adhesions.

HISTOLOGICAL EXAMINATION.—Sections from the cauliflower-like mass show the tissue everywhere invaded by large alveoli filled with squamous epithelial cells. Between many of the cells polymorphonuclear leucocytes are found, and often the central portion of an alveolus is filled with them. The stroma between the alveoli is very scanty, and is composed of spindle-shaped cells; scattered throughout it also are numerous polymorphonuclear leucocytes.

Sections through the cervix reveal several layers of squamous epithelium over the outer vaginal portion, but as one approaches the cervical canal, this epithelium becomes much thicker and dips down considerably, while here and there beneath the surface are alveoli filled with epithelial cells. Sections from the nodule to the left of the uterus, and also from the broad ligament, contain epithelial nests. The new growth has not been entirely removed.

The cervical glands are numerous; their epithelium is intact, but, as one might expect, their cavities frequently contain polymorphonuclear leucocytes. Here and there a gland is dilated and its epithelium flattened. The uterine mucosa is unaltered. The tube and ovary are normal.

Diagnosis.—Squamous-cell carcinoma of the cervix with extension into the left broad ligament and to the vaginal vault.

Gyn. No. 3,059

Squamous-cell carcinoma of the cervix; cauliflower growth of the consistence of brain tissue filling the vaginal vault; extension to the vagina; partial fixation of the uterus in pelvis; curettage.

M. S., aged thirty-seven; white. Admitted September 24, 1894. Complaint: pain in the lower abdomen and constant uterine hæmorrhage.

The patient has been married eight years, and has had three children; all of the labours were instrumental. Her family history is unimportant. In 1890 her spine became somewhat curved, but her general health continued to be good. About three months ago she experienced severe pain in the left iliac region; this was increased on walking, or in fact on any exertion. For a year she has had a constant, thick, copious, non-offensive discharge. This ceased two months ago, since which time the hæmorrhages have been continuous. At present her general health is good; the bowels are somewhat constipated. The vaginal outlet is relaxed, the cervix is bilaterally lacerated, and springing from it is a cauliflower-shaped fungating mass, which fills the upper part of the vagina. The growth is of the consistence of brain tissue, breaks down on the slightest touch, and bleeds profusely. The disease also extends to the vaginal vault. The fundus of the uterus is partially fixed, and both broad ligaments are infiltrated by the new growth.

Operation, September 26, 1894. The carcinomatous tissue was easily removed by the finger; copious hæmorrhage followed, but decreased somewhat after the underlying carcinomatous tissue had been curetted away. The vagina was tightly packed to prevent oozing. The patient was discharged October 2d, her general condition being somewhat improved.

Gyn.-Path. No. 453. The specimen consists of uterine scrapings, the largest piece of which is 3 centimetres long and .5 centimetre in thickness. It is very friable.

Histological Examination.—The greater part of the tissue consists of alveoli, which are round, oval, finger-like, or branching. The majority of these communicate with one another, and are filled with cells having large, oval nuclei in which nucleoli are visible. Not a few of the cells contain nuclear figures, and some have large, irregular, deeply staining nuclei. In parts of the specimen the

cells are separated from one another by polymorphonuclear leucocytes, and the centres of many of the alveoli are filled with them. The stroma, which appears as small islands of tissue, is composed of spindle-shaped cells. It shows considerable small-round-cell and polymorphonuclear infiltration.

Diagnosis.—Squamous-cell carcinoma of the cervix.

Gyn. No. 3,930

Squamous-cell carcinoma of the cervix with a cauliflower outgrowth (Fig. 47); histological picture of a finger-like outgrowth (Fig. 48); abdominal hysterectomy; recovery. The patient was lost sight of.

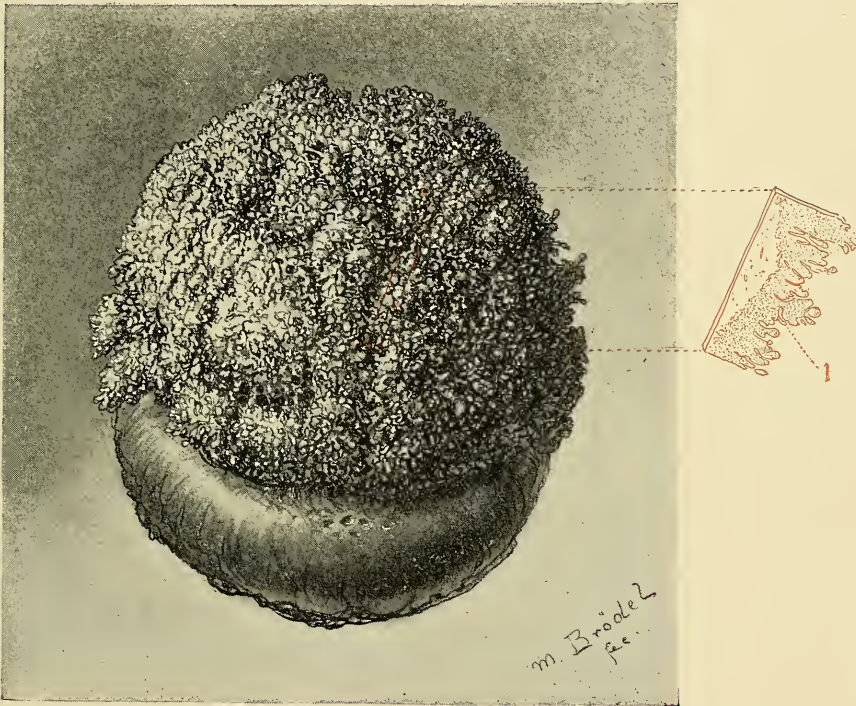


FIG. 47.—A TYPICAL CAULIFLOWER GROWTH SPRINGING FROM THE ANTERIOR CERVICAL LIP IN SQUAMOUS-CELL CARCINOMA OF THE CERVIX. (Natural size.)

Gyn.-Path. No. 957. The uterus is seen from below, and hence only the cervix appears in the figure. The anterior lip is occupied by a circular and elevated growth, presenting a fine, shaggy appearance, due to the presence of myriads of delicate finger-like processes. No breaking down of tissue is to be seen. The thickness of the growth, as determined with the eye, is indicated by the projection 1. The anterior lip is enlarged and intact.

M. K., aged forty-four; white. Admitted November 3, 1895.

The patient has been married twenty-nine years; has had five children and three miscarriages. Her menses commenced at fifteen, and were regular until two years ago. Her family history is unimportant.

In June of this year she noticed that the menstrual flow was becoming more

or less constant, one period merging into the next. She has lost a good deal of blood, and at present the discharge

is brownish in colour and very offensive. Her weight has diminished about twenty pounds during the last year. Her appetite is good; the bowels are constipated. There is a sense of heat in the vagina. Filling the vaginal vault is a fungating mass about the size of a foetal head. This bleeds on the slightest touch. The growth has extended out into the vaginal vault; laterally it apparently involves the broad ligaments as far out as the ureters.

Operation, November 7th. Abdominal hysterectomy. Before the administration of ether, a bougie was inserted into each ureter. When the operation was commenced the pulse was 130, and the patient was very pale. The cervix was curetted, and the major operation was carried out in the usual way. The lateral lymphatics were apparently not enlarged, not being palpable. During the entire operation the patient did not lose an ounce of blood, and at the close the pulse was 108. Five hundred cubic centimetres of salt solution were transfused into each breast, and an enema of salt solution was given.

The patient made an excellent recovery, and was discharged December 3, 1895.

Gyn.-Path. No. 957. The specimen consists of the uterus with its appendages intact. The organ is 10 centimetres in length, 5.5 centimetres in breadth, and 4 centimetres in its antero-posterior diameter. Its peritoneal covering is devoid of adhesions. Attached to the uterus on each side is a strip of the broad ligament fully 2 centimetres in breadth. The posterior cervical lip averages 1 centimetre in thickness; the mucosa covering its vaginal portion is intact. The anterior lip is represented by a large cauliflower-like mass

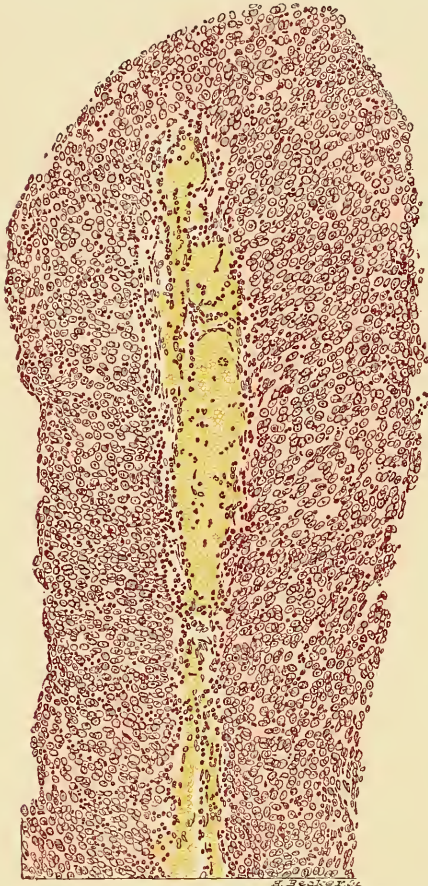

FIG. 48.—A LONGITUDINAL SECTION OF ONE OF THE MANY FINGER-LIKE OUTGROWTHS WHICH FORM THE CAULIFLOWER GROWTH OF FIG. 47. (130 diameters.)

Gyn.-Path. No. 957. The section has been taken from Fig. 47 at the point projected to the right and indicated by *I*. Traversing the centre, and running parallel with the long axis of the process, is a large blood-vessel with exceedingly delicate walls, which show considerable small-round-cell infiltration. Covering the outer surface are, approximately, from sixteen to eighteen layers of squamous cells. The nuclei in these are uniform in size, vesicular, and do not stain deeply. Between the epithelial cells are numerous small round cells. (Compare this drawing with Fig. 51, p. 81; Fig. 53, p. 84; Fig. 36, p. 50.)

measuring $6.5 \times 4 \times 2.5$ centimetres (Fig. 47). This varies considerably in colour, being deep red, bluish, or yellow. It presents a rough, worm-

eaten appearance, is very friable, and appears to be composed of granules varying from 2 to 3 millimetres in diameter. Examination of the same mass, after hardening in Müller's fluid, is much more satisfactory. It is seen to consist of papillary-like masses, which may reach 1 centimetre or more in diameter, although they are usually smaller. These papillary-like masses have slender pedicles, and are invariably made up of delicate finger-like processes.

The cervical mucosa is somewhat injected, and many of its glands are dilated, one reaching 3 millimetres in diameter. The uterine cavity is 5 centimetres in length; its mucosa is for the most part smooth and glistening. In some places, however, dark bluish-red areas are seen. The mucous membrane varies from 1 to 3 millimetres in thickness.

The right tube and ovary present the normal appearance. The left tube is unaltered, but the ovary contains a corpus luteum 3.5 centimetres in diameter.

Histological Examination.—Each of the small finger-like processes composing the papillary mass consists of a central blood-vessel, which is very large in proportion to the size of the process (Fig. 48). The vessel wall consists merely of one layer of endothelium, external to which are a few small round cells, apparently young connective-tissue cells. Surrounding the vessel is a large zone of epithelial cells, which have oval vesicular nuclei, in nearly all of which the nucleoli are visible. In the deeper portions of the cauliflower-like growth, the epithelial cells occur in islands scattered throughout the stroma. They present the same general appearance, but many of them contain nuclear figures, while in some places irregular plaques of protoplasm are seen containing four, five, or more nuclei. Along the advancing margin of the growth the cells form delicate finger-like projections. Lying between the epithelial cells, especially in the vicinity of the surface of the cauliflower-like growth, are polymorphonuclear leucocytes. The stroma of the growth shows considerable small-round-cell infiltration; its blood-vessels are dilated, and hæmorrhage has taken place into the tissue. The entire outer portion of the anterior lip is involved by the growth, which is a squamous-cell carcinoma. The cervical mucosa of the anterior lip is still intact, and both the vaginal and cervical portion of the posterior lip are normal. The growth appears to have been entirely removed.

The uterine mucosa shows considerable hæmorrhage in its superficial portions. It is on the whole normal. The appendages present the usual appearance.

January 1, 1900. Patient cannot be found.

Gyn. No. 3,126

Squamous-cell carcinoma of the cervix with cauliflower outgrowths; involvement of vaginal vault; abscess between uterus and rectum; dilatation of uterine glands; marked extension of normal uterine glands into the underlying muscle; combined vaginal and abdominal hysterectomy followed by melancholia; recovery.

Death, which took place two months after the patient left the hospital, was due to exhaustion.

H., aged fifty-six; white. Admitted October 21, 1894. Complaint on admission: moderate uterine hæmorrhage; pain in the lower part of the back and rectum.

The patient has been married twenty years and has had five children. During the first labour the perineum was torn; the tear was, however, immediately repaired. She began to menstruate at sixteen, and says that previous to marriage she suffered from membranous dysmenorrhœa. The menstrual flow was usually profuse; the catamenia ceased at fifty-three. In July last she noticed a yellowish vaginal discharge, and in August suffered considerably with pain in the lower bowel; there was some swelling in the legs at this time. Latterly the bowels have been obstinately constipated, and defecation brings on uterine hæmorrhage. The patient is fairly well nourished; the mucous membranes are pale and anæmic. She suffers considerably from insomnia. Her mother died of carcinoma of the uterus, and probably also her maternal grandmother.

Operation, October 27, 1894. Combined vaginal and abdominal hysterectomy. Before commencing the operation a bougie was laid in the left ureter, the cauliflower-like mass was removed with the finger, and the cervix ringed and peeled up on all sides. In the cellular tissue between the uterus and rectum was a small abscess containing about two drams of pus. The patient was placed in the Trendelenburg position, and the operation finished through the abdomen. Had it not been for the bougie the left ureter would certainly have been tied. The pelvis was washed out, and the denuded areas were approximated by two layers of sutures. The peritoneum from the posterior pelvic wall was then united with that from the anterior, and the abdomen closed. The patient was discharged November 28th, showing considerable improvement. She was, however, very much depressed mentally, and declared that she was no better.

Gyn.-Path. No. 493. The specimen consists of the uterus with the appendages intact. The uterus measures $8 \times 6 \times 3$ centimetres, and both anteriorly and posteriorly is smooth and glistening. Occupying the outer portion of the cervix both anteriorly and posteriorly is a worm-eaten and in part papillary-like surface. In the latter portion the little elevations are found to consist of small finger-like or knob-shaped processes, some of which apparently branch. Anteriorly the growth extends out to the vagina, while posteriorly it involves the vault for at least 1.5 centimetres. On section, it is found that only the outer portion of the cervix is implicated, and that the cervical mucosa for a distance of 2.5 centimetres is still intact. Several of the cervical glands are dilated, and projecting into the canal is a small polyp. The uterine cavity is 3 centimetres long; its mucosa, which appears to be less than 1 millimetre in thickness, is smooth and glistening. Situated on the left side of the cavity is a pale bluish-white polyp, 1 centimetre long, 1.2 centimetres broad, and 4 millimetres thick.

The tubes and ovaries present their usual appearance.

Histological Examination.—The worm-eaten cervix shows considerable necrosis on its surface; the underlying tissue is everywhere infiltrated by masses of cells having a finger-like or branching arrangement. Some of these have been cut across and appear as circular nests. Scattered throughout the alveoli are numerous areas in which the cell protoplasm stains intensely with eosin; the concentric arrangement of the cells is suggestive of epithelial pearls. The new growth appears to extend nearly to the margin of the incision; whether

or not it has been removed entirely, it is impossible to say. The tissue surrounding the alveoli shows marked small-round-cell infiltration, especially along the advancing margin of the growth.

The cervical glands just within the external os are normal, but as one approaches the internal os many of them are dilated.

The uterine mucosa near the internal os, and also throughout the cavity, shows considerable dilatation of its glands, and scattered throughout the stroma are numerous small round cells. Penetrating the muscle, in many places to a depth of 9 millimetres, are bunches of very small glands, which are separated from each other and also from the muscle by the usual amount of stroma. They are abnormal dippings down of the mucosa, which do not, however, show the least sign of malignancy.

The uterine polyp consists of mucosa, and a few of its glands are dilated. The uterine wall shows some hyaline degeneration, and in one place contains a myoma 4 millimetres in diameter.

The appendages are practically normal.

D i a g n o s i s.—Squamous-cell carcinoma of the cervix.

January 6, 1900. Dr. McCoy, of Jackson, Tenn., informs me that the patient died from "exhaustion" about sixty days after leaving the hospital.

Gyn. No. 3,229

Squamous-cell carcinoma of the cervix; cauliflower growth filling the vaginal vault; curettage.

M. T., aged forty-two; white. Admitted December 10, 1894. The patient has been married twenty-two years; she has had one child and two miscarriages. There is a tuberculous family history, but the patient herself has always been well. Since February last the menses, hitherto regular, have been very frequent, recurring on an average every two weeks, and have been accompanied by sharp pain in the lower part of the abdomen. On admission, the patient is fairly well nourished; the mucous membranes are of a good colour. When the bowels are constipated, defecation is painful. The vaginal discharge is at present thin and watery. The outlet is relaxed, the cervix is low down in the vagina, and springing from it is a large cauliflower excrescence which fills the vaginal vault.

Operation, December 13, 1894. The cauliflower mass was curetted away. The patient was discharged on December 26.

Gyn.-Path. No. 521. The specimen consists of a considerable amount of white friable tissue.

Histological examination of one of the pieces shows that it is virtually composed of one mass of cells, with here and there irregular islands of stroma scattered throughout it. The cells composing the new growth have large, oval or round, vesicular nuclei; nuclear figures are occasionally visible. Between the individual cells numerous small round cells, and in a few places polymorphonuclear leucocytes, are found. The islands of stroma are composed of connective-tissue cells; they have a rich blood supply, and in places contain alveoli filled with cells of the new growth. The tissue undoubtedly comes from a squamous-cell carcinoma of the cervix.

Gyn. No. 3,813

Squamous-cell carcinoma of the cervix with a cauliflower growth the size of an orange; abdominal hysterectomy; recovery. Local recurrence noted ten months after operation.

R. P., aged forty-four; coloured. Admitted September 21, 1895. Complaint: frequent bloody vaginal discharge; pain in the back.

Patient has been married twenty-three years; has had ten children and three miscarriages. Her menses commenced at thirteen, and have always been regular until within one and a half years. Her family history is good, and she herself has always been healthy.

In July, 1894, the menses ceased, and four months later there was a sudden escape of watery fluid from the vagina. At this time the patient had a feeling of weakness. In January, 1895, she had severe uterine hæmorrhages, and the discharge was at times clotted. Since that time she has had frequent hæmorrhages.

The patient is well nourished; the mucous membranes are anæmic; the appetite is good; the bowels are regular. Locomotion occasions some pain in the abdomen and back. On vaginal examination, the outlet is relaxed. Springing from the cervix and also involving the vaginal vault is a fungating mass about the size of a large orange. This is very friable, and breaks down on the slightest touch. The broad ligaments are apparently not involved.

Operation, October 3, 1895. Abdominal hysterectomy.

The patient was discharged November 1.

Gyn.-Path. No. 890. The specimen consists of a large amount of uterine scrapings which vary considerably in size, the largest measuring $7 \times 7 \times 2.3$ centimetres. They are composed of a yellowish-white friable material, which in places contains smooth, white, glistening areas varying from 1 to 2 centimetres in diameter. The greater part of the tissue presents an eaten-out appearance, and is composed of minute semi-translucent granules.

Histological Examination.—Along one margin of the tissue normal squamous epithelium can be made out, and after tracing this a short distance it is seen penetrating the underlying stroma, its cells forming oblong or club-like masses. This downgrowth of cells is directly continuous with other masses of cells which penetrate the stroma in all directions. On taking a general view of the specimen, it is seen to be everywhere infiltrated by large and small groups of cells, which form oblong, round, or oval masses, or they may branch in all directions. Returning to the point at which the squamous epithelium dips into the stroma, a direct transformation of the normal cells into those of the new growth may be seen. The nuclei become large, but are otherwise similar to those of the surface epithelium. The cells composing the new growth have large, oval, vesicular nuclei, in which one or two dark masses of chromatin may be made out. Their fine nuclear network is also visible. On the whole the nuclei are uniform in size; some, however, are smaller than others, while here and there are large, irregular, deeply staining nuclei, or large cells showing karyorhexis. Occasionally a mass

of protoplasm is seen, which contains four or five nuclei which overlap one another. These differ from the surrounding nuclei only in staining more deeply. Where the cell-nests are very small, they stain deeply.

Nearly all, if not all, of the alveoli have been invaded by polymorphonuclear leucocytes, which have wandered in between the individual epithelial cells. The central portions of some of the alveoli are filled with these leucocytes. The stroma between the alveoli is very scanty in proportion to the amount of epithelial elements. It is composed of spindle-shaped connective-tissue cells, and shows localized areas of small-round-cell infiltration. In some parts the entire tissue has undergone coagulation necrosis.

Diagnosis.—Squamous-cell carcinoma of the cervix.

August 17, 1896. On examination a recurrence was noted—ten and a half months after operation.

Gyn. No. 4,176

Squamous-cell carcinoma with cauliflower growth from cervix; slight vaginal involvement; commencing papilloma of right ovary; abdominal hysterectomy. Rapid local return of growth; death seven months after operation.

K. Le C., aged thirty-eight; white. Admitted February 27, 1896. Complaint: constant uterine hæmorrhage.

The patient has been married twenty-three years, and has had four children. The third labour was instrumental. She has also had four miscarriages. Until the present illness her menses have been regular. Her mother died of carcinoma of the left breast.

About ten weeks ago she first noticed a bloody vaginal discharge. This appeared suddenly, and has been present almost daily until admission. When not hæmorrhagic, the discharge is yellowish-white in character. The patient is fairly well nourished; her appetite is good; the bowels are regular. She complains of some pain in the left iliac region, also of backache. The cervix is occupied by a fungating but rather firm mass, which laterally involves the vaginal wall for about 1 centimetre. The uterus is normal in size, freely movable; the broad ligaments do not appear to be involved.

Operation, February 29, 1896. Abdominal hysterectomy. The cervix was curetted and cauterized before commencing the abdominal operation. A bougie was inserted into the right ureter before the anæsthetic was given. As, however, it would not pass very far, further attempts to introduce it were abandoned. The uterus was then removed in the usual way. None of the pelvic glands could be palpated. At the close of the operation 1,000 cubic centimetres of normal salt solution were infused into the breasts, and 1,000 cubic centimetres were given as a rectal enema.

The patient's recovery was uninterrupted, and she was discharged April 4, 1896. On June 21, 1896, she was seen at the hospital; at that time she felt perfectly well, and was absolutely free from pain.

Gyn-Path. No. 1,090. The specimen consists of the uterus with intact appendages. The uterus measures $9 \times 5.5 \times 5$ centimetres. Over both its anterior and posterior surfaces it has a smooth peritoneal covering. The cervix is greatly

enlarged, and on the left side presents a worm-eaten excavated area, fully 4 centimetres in diameter. This excavation extends into the vaginal mucosa for a short distance. The growth involves the cervix to within 1 centimetre of the internal os, and laterally extends to within a short distance of the broad ligament. Just beneath the vaginal mucosa it is seen reaching as far as the cut surface, and has not been entirely removed. The right half of the cervix is hypertrophied, but still intact. The uterine mucosa is smooth, but presents a slightly undulating surface. The appendages are unaltered.

Histological Examination.—At the extreme margin of the vaginal portion of the cervix the squamous epithelium is in places still intact, but on tracing it a short distance, it becomes thicker and commences to invade the underlying stroma. Here the epithelium appears as large or small nests of cells. Many of these nests are broken down and contain polymorphonuclear leucocytes or small round cells. The growth has extended to the cut surface, and has undoubtedly advanced beyond the line of incision, involving the vaginal vault. The stroma of the cervix along the advancing margin of the growth shows considerable small-round-cell infiltration. The uterine mucosa has a rather wavy outline; its glands are abundant, and in their superficial portions they are considerably convoluted. The gland epithelium is intact. In two or three places, glands with their accompanying stroma extend fully 7 millimetres into the underlying muscle, and are very suggestive of similar areas found in adeno-myomata.

Both tubes and the left ovary are normal. The right ovary contains a minute papilloma, and scattered throughout the superficial portions of its stroma are several small calcified areas.

Diagnosis.—Squamous-cell carcinoma of the cervix. Commencing papilloma of right ovary.

Her son informs me that shortly after her second visit to the hospital her sufferings became intense, and death took place seven months after the operation.

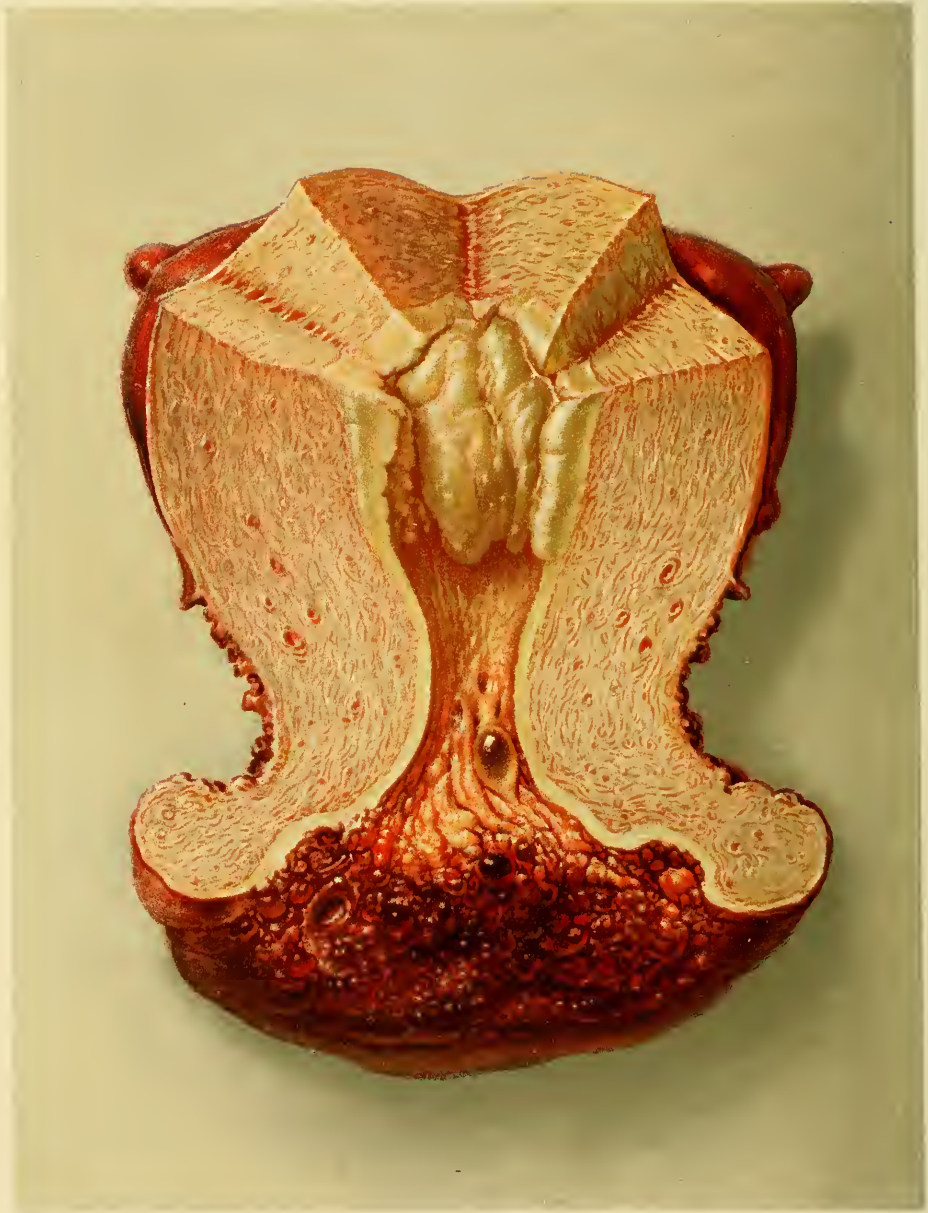Gyn. No. 2,041

Squamous-cell carcinoma of the cervix; vagina nearly filled by a large cauliflower mass; curettage.

M. C., aged forty-one; white. Admitted June 13, 1893. Complaint: profuse uterine hæmorrhages; offensive watery vaginal discharge; pain in the lower abdomen and back.

The patient has been married sixteen years, and has had three children; one labour was instrumental. Her family history is negative, and she has always been healthy until the present illness.

Since December, 1892, she has had almost constant uterine hæmorrhage, accompanied by severe dull aching pain in the abdomen, back, and thighs. The patient is an anæmic and poorly nourished woman; she is very nervous, and has an anxious expression. She has been losing in weight recently; the appetite is poor; the bowels are regular. The vaginal outlet is relaxed, and the vagina is nearly filled with a large fungating mass representing the cervix. There is some induration in the right broad ligament.



Fresh specimen of squamous-cell carcinoma of the cervix.
Polypoid formation of the uterine mucosa.

November 21st. She has steadily improved and is well. (Killing of Gyn.-Path. No. 2,706.) The cervix was much enlarged, and the greater part of it was occupied by a new growth. This presents a slightly excavated surface, is dark red in colour, and consists of many small dome-like elevations. These, in reality, are masses of delicate finger-like outgrowths which are held together by blood and mucus. After hardening, they stand out as individual projections. The advancing margin of the growth along the vaginal portion of the cervix is sharply defined. Upward, the carcinoma extends about 1.5 centimetres above the external os. The advancing margin is irregular, but is clearly recognisable as dark-red (carcinomatous) tissue, sharply contrasted with the orange yellow of the cervical mucosa. The carcinoma, on section, is whitish yellow, and has penetrated the cervical tissue for a distance of 2 or 3 millimetres. The cervical mucosa, above the point of the growth, is orange yellow in colour, and presents numerous longitudinal folds. It is practically normal, save for a dilated cervical gland, 1 centimetre in length and 6 millimetres in breadth, which stands out as a clear translucent cyst. The body of the uterus is about twice its usual size; on either side is the stump of the Fallopian tube. The uterine walls are much thickened. Projecting from the cut surface are numerous blood-vessels. The uterine mucosa, near the internal os, is normal, and averages 1.8 millimetres in thickness. In the entire upper part of the cavity it is greatly thickened, suggesting polypoid growths, and forms longitudinal folds, which are subdivided by numerous transverse depressions. This thickened mucosa, although undulating, has a smooth surface. It is of a lemon-yellow colour, semi-translucent, and varies from 3 to 6 millimetres in thickness. At no point does the mucosa appear to penetrate the muscle, the line of demarcation being sharply defined.

PLATE II.—SQUAMOUS-CELL CARCINOMA OF THE CERVIX; POLYPOID FORMATION OF THE UTERINE MUCOSA. (Natural size.)

Gyn.-Path. No. 2,706. The cervix is much enlarged, and the greater part of it is occupied by a new growth. This presents a slightly excavated surface, is dark red in colour, and consists of many small dome-like elevations. These, in reality, are masses of delicate finger-like outgrowths which are held together by blood and mucus. After hardening, they stand out as individual projections. The advancing margin of the growth along the vaginal portion of the cervix is sharply defined. Upward, the carcinoma extends about 1.5 centimetres above the external os. The advancing margin is irregular, but is clearly recognisable as dark-red (carcinomatous) tissue, sharply contrasted with the orange yellow of the cervical mucosa. The carcinoma, on section, is whitish yellow, and has penetrated the cervical tissue for a distance of 2 or 3 millimetres. The cervical mucosa, above the point of the growth, is orange yellow in colour, and presents numerous longitudinal folds. It is practically normal, save for a dilated cervical gland, 1 centimetre in length and 6 millimetres in breadth, which stands out as a clear translucent cyst. The body of the uterus is about twice its usual size; on either side is the stump of the Fallopian tube. The uterine walls are much thickened. Projecting from the cut surface are numerous blood-vessels. The uterine mucosa, near the internal os, is normal, and averages 1.8 millimetres in thickness. In the entire upper part of the cavity it is greatly thickened, suggesting polypoid growths, and forms longitudinal folds, which are subdivided by numerous transverse depressions. This thickened mucosa, although undulating, has a smooth surface. It is of a lemon-yellow colour, semi-translucent, and varies from 3 to 6 millimetres in thickness. At no point does the mucosa appear to penetrate the muscle, the line of demarcation being sharply defined.

November 21st. She has steadily improved and is well. (Killing of

Gyn.-Path. No. 2,706.) The cervix was much enlarged, and the greater part of it was occupied by a new growth. This presents a slightly excavated surface, is dark red in colour, and consists of many small dome-like elevations. These, in reality, are masses of delicate finger-like outgrowths which are held together by blood and mucus. After hardening, they stand out as individual projections. The advancing margin of the growth along the vaginal portion of the cervix is sharply defined. Upward, the carcinoma extends about 1.5 centimetres above the external os. The advancing margin is irregular, but is clearly recognisable as dark-red (carcinomatous) tissue, sharply contrasted with the orange yellow of the cervical mucosa. The carcinoma, on section, is whitish yellow, and has penetrated the cervical tissue for a distance of 2 or 3 millimetres. The cervical mucosa, above the point of the growth, is orange yellow in colour, and presents numerous longitudinal folds. It is practically normal, save for a dilated cervical gland, 1 centimetre in length and 6 millimetres in breadth, which stands out as a clear translucent cyst. The body of the uterus is about twice its usual size; on either side is the stump of the Fallopian tube. The uterine walls are much thickened. Projecting from the cut surface are numerous blood-vessels. The uterine mucosa, near the internal os, is normal, and averages 1.8 millimetres in thickness. In the entire upper part of the cavity it is greatly thickened, suggesting polypoid growths, and forms longitudinal folds, which are subdivided by numerous transverse depressions. This thickened mucosa, although undulating, has a smooth surface. It is of a lemon-yellow colour, semi-translucent, and varies from 3 to 6 millimetres in thickness. At no point does the mucosa appear to penetrate the muscle, the line of demarcation being sharply defined.

The cervix was much enlarged, and the greater part of it was occupied by a new growth. This presents a slightly excavated surface, is dark red in colour, and consists of many small dome-like elevations. These, in reality, are masses of delicate finger-like outgrowths which are held together by blood and mucus. After hardening, they stand out as individual projections. The advancing margin of the growth along the vaginal portion of the cervix is sharply defined. Upward, the carcinoma extends about 1.5 centimetres above the external os. The advancing margin is irregular, but is clearly recognisable as dark-red (carcinomatous) tissue, sharply contrasted with the orange yellow of the cervical mucosa. The carcinoma, on section, is whitish yellow, and has penetrated the cervical tissue for a distance of 2 or 3 millimetres. The cervical mucosa, above the point of the growth, is orange yellow in colour, and presents numerous longitudinal folds. It is practically normal, save for a dilated cervical gland, 1 centimetre in length and 6 millimetres in breadth, which stands out as a clear translucent cyst. The body of the uterus is about twice its usual size; on either side is the stump of the Fallopian tube. The uterine walls are much thickened. Projecting from the cut surface are numerous blood-vessels. The uterine mucosa, near the internal os, is normal, and averages 1.8 millimetres in thickness. In the entire upper part of the cavity it is greatly thickened, suggesting polypoid growths, and forms longitudinal folds, which are subdivided by numerous transverse depressions. This thickened mucosa, although undulating, has a smooth surface. It is of a lemon-yellow colour, semi-translucent, and varies from 3 to 6 millimetres in thickness. At no point does the mucosa appear to penetrate the muscle, the line of demarcation being sharply defined.

PLATE II.—*Scymnus-tribe (Anisomyia) OF THE GENUS - POLIPOID FORMATION OF THE*
LYCONE MEXICANA (Natural size)

Gym. Publ. No. 2706. The body is much enlarged, and the greater part of it is occupied by a new growth. This presents a highly excavated surface, is dark red in colour, and consists of many small finger-like growths. The legs are healthy, and masses of delicate finger-like outgrowths which are best seen by light and under a microscope. After hatching, they stand out as individual projections. The advancing margin of the larva which is at the ventral portion of the body is sharply defined. The larva is about 1.5 mm. long, and is covered above the extremities with a thin, advancing margin, is irregular but is clearly recognizable as dark red (cartilaginous) tissue, sharply outlined with red, yellow of the central process. The cartilage on section is whitish yellow, and is covered by a thin, yellowish film. The cartilage is yellow in colour, and presents numerous cervical processes. The body is yellowish, and is covered by a thin, yellowish film. The body is longitudinally lobed. It is practically normal size for a dilated cervical gland, 1 centimetre in length and 6 millimetres in breadth, which is a clear transverse cyst. The body of the uterus is about twice its normal size; on either side of the stump of the Fallopian tube. The uterine walls are much thickened. Projecting from the cut surface are numerous blood-vessels. The uterine process, on the internal side, is normal and averages 1.8 millimetres in thickness. In the entire upper part of the ovary, it is greatly thickened, suggesting polyoid growth, and forms longitu and folds, which are subdivided by numerous transverse depressions. The thickened mucosa, although translucent, has a smooth surface. It is of a lemon-yellow colour, semi-translucent, and varies from 2 to 6 millimetres in thickness. At no point does the mucosa appear to penetrate the muscle, the line of demarcation being sharply defined.

Operation, June 17, 1893. The cervix was thoroughly curetted and a large amount of friable carcinomatous tissue removed; the vagina was then packed with iodoform gauze. The patient was discharged June 28, 1893, little, if at all, improved. The uterine discharge was profuse and watery, and the pains were still severe.

Gyn.-Path. No. 14. The specimen consists of uterine scrapings.

Histological Examination.—The greater part of the tissue is composed of oval, elongated, or branching islands of epithelial cells. The individual cells have oval or irregularly oval nuclei; in some there is karyokinesis. In many places polymorphonuclear leucocytes have wandered in between the epithelial cells. The stroma of the cervix shows marked small-round-cell infiltration.

Diagnosis.—Squamous-cell carcinoma of the cervix.

Gyn. No. 6,492

Squamous-cell carcinoma of the cervix (Plate II); glandular hypertrophy of the endometrium, with polypoid formation; small-round-cell infiltration of the mucosa; vaginal hysterectomy; recovery. No evidence of recurrence thirteen months after operation.

McA., aged twenty-eight; white; married. Admitted November 4, 1898. Complaint: laceration of the cervix.

The patient commenced to menstruate at eleven, and has always been regular. The flow lasts four days, and is unaccompanied by pain. The patient was married at fourteen, and has had one normal labour, but no miscarriages.

The family and previous history are unimportant.

In July last the patient began to have a painless, pinkish, vaginal discharge; this gradually increased in amount, and finally consisted of pure blood. Two weeks previous to admission the discharge became offensive.

The patient's general condition is good, but there is slight anæmia.

November 5th. The uterus was removed *per vaginam*.

November 21st. She has steadily improved, and to-day is sitting up.

Gyn.-Path. No. 2,706. The specimen consists of the uterus, which is 10 centimetres long and 7 centimetres broad. The cervix is 6 centimetres in diameter. Its vaginal portion is replaced by a new growth made up of delicate papillary or thread-like outgrowths (Plate II). Some portions of the growth are excavated and covered by necrotic material. The advancing margin is somewhat raised and is sharply defined; surrounding it is a vaginal cuff, varying from .5 to 1 centimetre in breadth. The growth, on section, is yellowish-white in colour and granular in appearance. The advancing margin is well defined, and on the left and posterior portion of the cervix it has extended to within 4 millimetres of the cut surface. Upward the cervix has been invaded for a distance of 1.5 centimetres. The mucosa in the upper half of the cervix presents the usual appearance.

The uterine cavity is 5 centimetres long, 4 centimetres in breadth at the fundus; its mucosa varies from 1 to 6 millimetres in thickness, is yellowish in colour, translucent, and gathered up into several longitudinal elevations with intervening

depressions; in other words, the mucosa appears to form polypi. Its surface is perfectly smooth.

Histological Examination.—The squamous epithelium over the outer and vaginal portion is in some places still intact. The surface of the growth is covered by blood, fibrin, and many polymorphonuclear leucocytes. In some places the surface consists almost entirely of granulation tissue, rich in capillaries. The cervical tissue at the site of the growth is everywhere infiltrated by nests of epithelial cells. These appear irregular and branching, oblong, oval, or circular, according to the way in which they are cut. The individual epithelial cells are polygonal in shape, and have oval or slightly irregular, rather vesicular nuclei. Numerous nuclear figures are seen, and occasionally a large, irregular, deeply staining mass of chromatin. Lying between the epithelial cells in many places are small round cells and polymorphonuclear leucocytes. The great majority of these are eosinophiles. The stroma between the nests of the growth shows marked small-round-cell infiltration, many of these small round cells being also eosinophiles. The polymorphonuclear leucocytes are quite numerous. Along the advancing margin there is considerable small-round-cell infiltration. The growth is a squamous-cell carcinoma of the cervix. Whether it has been entirely removed or not, it is difficult to say.

The cervical mucosa near the internal os is practically normal, but here and there the stroma shows considerable small-round-cell infiltration, and occasionally a stray nest of cancer cells is visible.

The mucosa in the cavity of the uterus, as noted macroscopically, is much thickened; the surface epithelium is everywhere intact, and apart from a slight infiltration of small round cells is normal. The glands, especially in their superficial portions, present a convoluted and wavy appearance; they are slightly dilated, and have a rather pale-staining epithelial lining. In the deeper portions they present a normal appearance. The majority of the glands contain a small amount of granular material, and in a few are seen desquamated epithelium, small round cells, and occasionally polymorphonuclear leucocytes. The stroma of the mucosa in the superficial portions shows slight swelling of its nuclei and a moderate amount of small-round-cell infiltration. In the deeper portions of the mucosa the stroma presents a normal appearance. The thickening is due to a moderate gland hypertrophy, accompanied by some small-round-cell infiltration.

Right side. The tube at the uterine cornu has an intact epithelial lining, but between the epithelial cells are a few small round cells.

Left side. The tube at the cornu presents the same picture.

Diagnosis.—Squamous-cell carcinoma of the cervix. Gland hypertrophy with polypoid formation of the endometrium.

December 13, 1899. Examination of the vaginal vault gives no evidence of a return of the growth. The patient's general condition is good. Length of time since operation, thirteen months.

Gyn. No. 2,624

Squamous-cell carcinoma of the cervix; the cervix a mere shell (Fig. 49); extension to the vagina on the left

side; vaginal hysterectomy; forceps left on to control left uterine artery; recovery. Rapid local recurrence; death eight months after operation.

E. O., aged fifty-three; white. Admitted March 2, 1894. Complaint: frequent uterine hæmorrhages; sharp, shooting pains throughout abdomen.

The patient has been married thirty-five years, and has had nine normal labours. The menopause occurred five years ago. Her father died of tuberculosis; her previous history is unimportant. About a year ago the patient noticed that at times she would be rather languid after any special exertion; this feeling of weakness continued; on December 12th she had a severe hæmorrhage,

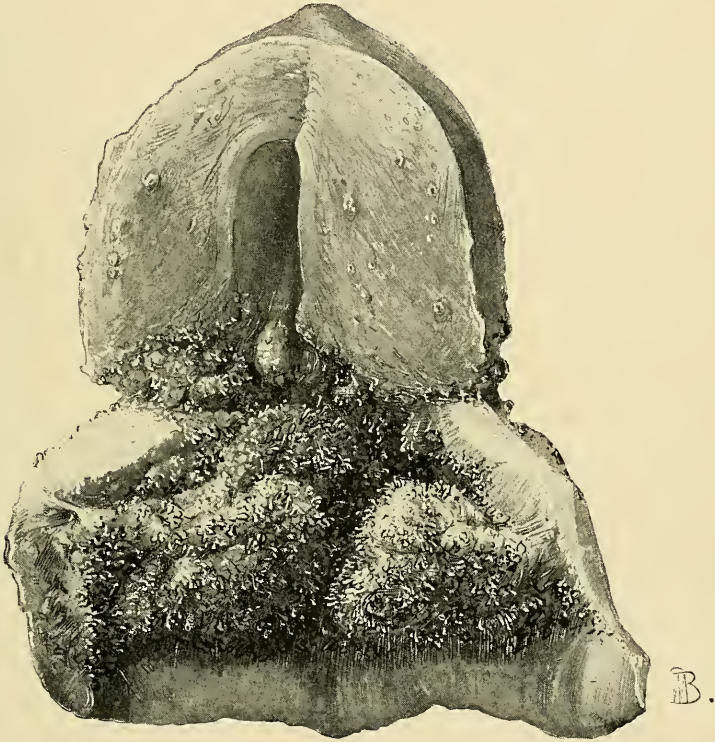


FIG. 49.—SQUAMOUS-CELL CARCINOMA OF THE CERVIX. (Natural size.)

Gyn.-Path. No. 192. The cervix is entirely obscured by myriads of delicate finger-like projections, which have extended for a short distance into the vaginal walls. Upward, these projections can be traced to within 2.5 centimetres of the fundus. Laterally the growth, as seen macroscopically, does not appear to have reached the broad ligament. The mucosa in the upper part of the cavity is of the usual thickness, and is apparently normal. (After H. A. KELLY.)

lasting about six hours. Two weeks ago she had a second hæmorrhage, and since then there has been an almost constant bloody discharge. This is not offensive, but irritates the parts considerably. When the hæmorrhage ceases for a day or two, in its place there is a yellowish discharge.

The patient is fairly well nourished, but sallow in appearance. The mucous membranes are slightly anæmic. Her appetite is good, her bowels are constipated,

and defecation causes considerable pain. The vaginal outlet is greatly relaxed, and the cervix is flush with the vault. The lips are roughened, eroded, and excavated, and break down on the slightest manipulation. The fundus is freely movable, and is not enlarged; the broad ligaments do not appear to be involved.

Operation, March 3, 1894. Vaginal hysterectomy. The cervix was given a wide berth in the enucleation, the vagina being ringed about 1 centimetre from the cervical margin. The enucleation was continued in the usual manner, considerable difficulty being experienced, since the cervix was converted into a mere shell and broke down even when the gentlest traction was exerted. To control hæmorrhage, it was necessary to leave an artery forceps on the left broad ligament, and two clamps on the right side. At the expiration of thirty hours the clamps were removed; there had been very little hæmorrhagic discharge, and the abdomen was perfectly flat. The patient did well, and was discharged April 6, 1894.

Gyn.-Path. No. 192. The specimen consists of the uterus, the left tube and ovary, and a portion of the vaginal vault. The uterus measures $10 \times 5 \times 3$ centimetres. Anteriorly and posteriorly it is covered by adhesions. The cervix, especially in the vicinity of the external os, presents an uneven, worm-eaten appearance (Fig. 49). On the right side the margin is sharply defined, but on the left side the new growth has extended over into the vaginal vault. On examining the advancing portions little tufts of finger-like folds are visible. On cutting open the uterus, the entire cervix and part of the body are found to be occupied by the new growth. Within the cervix the fine finger-like projections are seen to much better advantage. Eight or nine may spring from one stem. They usually end in club-like extremities. Laterally the growth extends alarmingly near the broad ligament, and in places appears to have reached the cut surface. The uterine walls average 2.5 centimetres in thickness; in the portions which are left, the mucosa is 1 millimetre thick, and is pale and velvety. The left tube is bound down to the ovary by numerous adhesions, and the fimbriated extremity is occluded. Nothing of interest is seen in the ovary.

HISTOLOGICAL EXAMINATION.—The squamous epithelium covering the outer vaginal portion of the cervix is in places preserved. The small finger-like projections of the growth consist of central stems of connective tissue, containing one or more small blood-vessels, and surrounded by many layers of cells having oval, vesicular nuclei. The tissue composing the surface of the growth consists almost entirely of these cells, which also penetrate the underlying tissue in all directions. Traversing the tissue everywhere are branching, oval or irregular alveoli, completely filled with similar cells.

The growth on the right side extends outward to the broad ligament; it also invades the body of the uterus far up into the cavity, and, penetrating the mucosa, extends to the surface epithelium. Along the advancing margin the cells of the new growth are very active; their nuclei are twice or three times the size of those of the surrounding cells, and stain very deeply. Some of them are irregular in contour. The alveoli in the superficial portions of the growth show quite a number of polymorphonuclear leucocytes between their cellular elements. Wherever the tissue is invaded by the new growth, there is considerable small-round-cell infiltration.

The cervical glands, where still preserved, are normal, and the uterine mucosa in the upper portions of the cavity present the usual appearance.

The tube, apart from being covered by adhesions, is normal. The growth has commenced in the cervix, extended to the vagina, and involved the right broad ligament.

Diagnosis.—Squamous-cell carcinoma of the cervix.

There was a rapid recurrence in the vaginal vault and laterally. The patient died November, 1894, about eight months after the operation.

Gyn. No. 2,405

Squamous-cell carcinoma of the cervix (Fig. 50). Histological structure of the finger-like outgrowths (Fig. 51). Omental adhesions to the fundus; hysterectomy; death on the fourth day.

C. S., aged forty-three; white. Admitted November 10, 1893. Complaint: uterine hæmorrhages; a heavy bearing-down sensation along the course of the rectum.

The patient has been married twenty-four years, and has had two normal labours. Her father died of tuberculosis, but up to the time of the present illness she has always been well. Four years ago the patient began to experience pain in the small of the back; this was most pronounced at the menstrual period. About ten months later she began to lose her strength, and noticed a leucorrhœal discharge, which rapidly increased in amount and became very offensive. This was very persistent for over two years, but ceased one month before her admission. Since that time there has been considerable uterine hæmorrhage. In the preceding August she first began to complain of sharp, shooting, gnawing, or knife-like pains in the back; these would come on every few minutes, and frequently radiated down the thighs.

The patient is fairly well nourished; the mucous membranes are rather pale; the appetite is fair; the bowels are constipated; defecation is painful.

Operation, November 25, 1893. Hysterectomy. Immediately after the operation the patient began to vomit, and was nauseated throughout the first and second days. She also complained of a good deal of pain, and was very drowsy. The nausea continued on the third day; the urine was passed involuntarily, and much flatus was expelled. The patient died early on the morning of the fourth day.

Gyn.-Path. No. 94. The specimen consists of the uterus with its appendages intact. The uterus measures $10 \times 6 \times 4$ centimetres. The cervix is ragged and presents a worm-eaten appearance (Fig. 50). On examining the tissue carefully it is found in places to consist of delicate finger-like folds; in other portions are knob-like masses, some of which reach 2 centimetres in length and 1.5 centimetres in diameter. On examining the alcoholic specimen the growth is seen to have extended laterally and posteriorly as far as the cut surface of the specimen, and apparently has not been entirely removed. On cutting into the cervix the new growth is sharply defined from the normal tissue, being yellowish in colour. It extends as far as the internal os. Attached to the fundus are several omental adhesions, and

posteriorly the uterus is partially covered by vascular adhesions. The uterine walls average 2 centimetres in thickness. The appendages on both sides are covered by delicate adhesions.

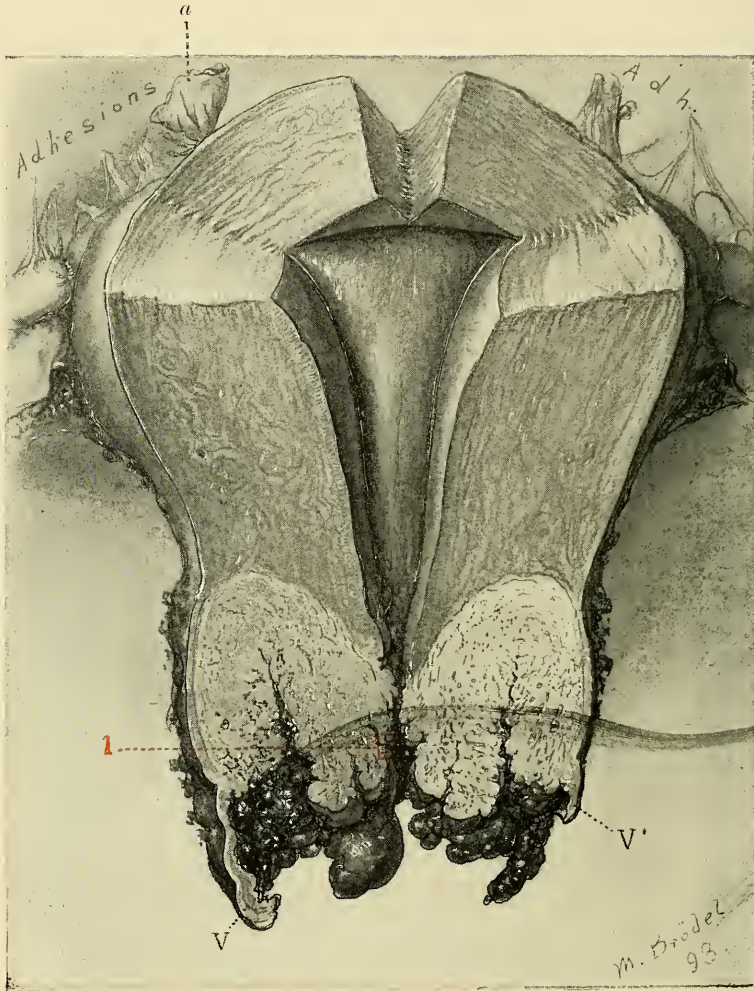


FIG. 50.—SQUAMOUS-CELL CARCINOMA OF THE CERVIX WITH LOSS OF THE CERVICAL LANDMARKS.
(Natural size.)

Gyn.-Path. No. 94. Attached to the outer surface of the fundus on both sides are numerous adhesions; at *a* is one of these containing adipose tissue. The entire cervix has been replaced by the new growth. The lower and ragged portion consists of large and small lobulated masses. The growth stands out in sharp contrast to the vaginal and uterine tissue, being much lighter in colour. Laterally, it extends to the vaginal attachments *V* and *V'*; upward, it reaches to the internal os. The uterus is considerably enlarged, and its walls are much thickened. The mucosa appears to be normal.

Histological Examination.—Each of the fine finger-like projections consists of a central blood-vessel, surrounded by a small amount of connective tissue, external to which are many layers of cells having oval, vesicular nuclei

(Fig. 51). These cells are directly continuous with those portions of the growth that extend into the cervical tissue. Scattered everywhere throughout the cervix and reaching out into the broad ligament are round, oval, or branching alveoli, which are filled with cells having oval, vesicular nuclei. These alveoli frequently branch and communicate with one another, forming an irregular network. The stroma between the alveoli shows marked small-round-cell and moderate polymorphonuclear leucocytic infiltration. The uterine mucosa has an intact surface epithelium; its glands are abundant, and here and there extend

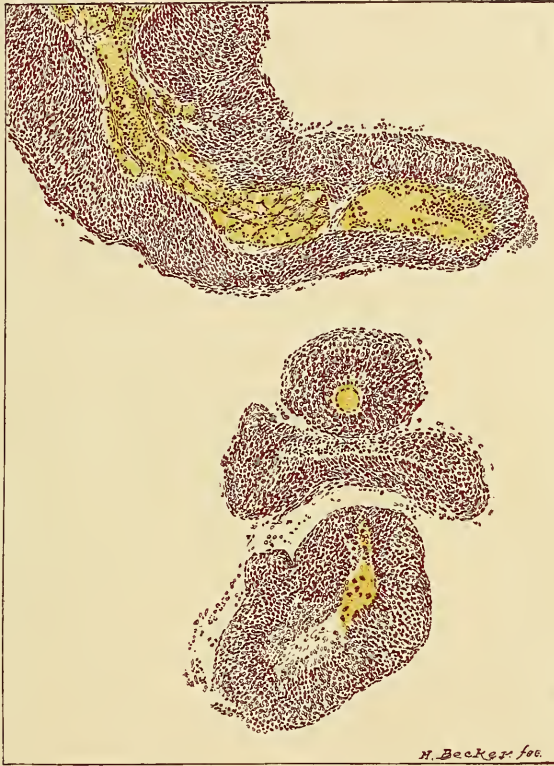

FIG. 51.—LONGITUDINAL AND CROSS SECTIONS OF FINGER-LIKE OUTGROWTHS IN SQUAMOUS-CELL CARCINOMA OF THE CERVIX. (150 diameters.)

Gyn.-Path. No. 94. The section has been taken from Fig. 50 at point 1. Situated in the upper half of the field is a longitudinal section of a finger-like projection. The central portion contains a large blood-vessel, practically devoid of supporting connective tissue except at its base. Covering the outer surface are many layers of squamous epithelium. Lying in the lower half of the field are cross sections of two similar projections, with a flattened finger between them. (Compare also Fig. 36, p. 50; Fig. 46, p. 63; Fig. 48, p. 68; Fig. 53, p. 84.)

a short distance into the muscle. When found in the muscle, they are usually accompanied by a moderate amount of stroma similar to that of the mucosa. The superficial portions of the mucosa show considerable hæmorrhage.

D i a g n o s i s.—Squamous-cell carcinoma of the cervix.

Gyn. No. 3,595

Squamous-cell carcinoma of the cervix (Fig. 52), with a cauliflower-like growth filling the vaginal vault. Extension to the vagina. Cross sections of delicate finger-like processes cut transversely and resembling an angio-sarcomatous growth (Fig. 53); vaginal hysterectomy with partial removal of the growth; subsequent attempt to remove the remaining nodules in the vaginal vault followed by a small vesico-vaginal fistula; temporary recovery.

I. W., aged thirty-six; white. Admitted June 19, 1895. Complaint: uterine hæmorrhages.

The patient has been married eighteen years, and has had two children. Her family history is good. She began to menstruate at nine years of age; for a time she was irregular, but since then has always had a normal menstrual flow. The last period occurred May 12, 1895.

Four months ago the patient had a hæmorrhage, which she at first thought was a return of the menstrual period. A short time afterward she had a second hæmorrhage; since that time she has been annoyed by an offensive, pinkish-yellow discharge. She is well nourished; the lips and mucous membranes are pale; the appetite is good; the bowels are regular. The outlet is relaxed; the vaginal vault is filled with a fungating mass, which springs from the cervix. The uterus is freely movable, and the broad ligaments are, apparently, not involved. An attempt to pass bougies into the ureters was unsuccessful.

Operation, June 22d. Vaginal hysterectomy. The uterus was removed in the usual way, and the patient made an uninterrupted recovery. On examining the vaginal vault, just previous to her discharge, a small, roughened area could be felt, which immediately aroused the suspicion that the diseased tissue had not been entirely removed.

She returned to the hospital November 9th, and as had been surmised, some of the carcinomatous tissue had been left behind. A bougie was inserted into the right ureter, and an attempt made to remove that portion of the vagina which was invaded by the new growth. This was, however, done with difficulty, as the disease had extended forward toward the bladder and backward toward the rectum. The vaginal vault was then, as far as possible, closed, to prevent intestinal prolapse. The pack, removed on the fifth day, had a distinct uriniferous odour; on examining the bladder a small vesico-vaginal fistula was found. On her discharge, November 24th, the fistula had nearly healed. The prognosis was unfavourable.

She was admitted for a third time January 14, 1896. After leaving the hospital her general condition had improved greatly. On vaginal examination a vesico-vaginal fistula 2×1 centimetre was seen, and on the vaginal vault, just above the fistulous opening, was a carcinomatous nodule about the size of a pea. Deep palpation of the broad ligament on the left side revealed similar pea-like nodules, and also at the brim of the pelvis on the right side several could be felt.

Operation, January 18th. The small nodule in the vaginal vault was removed; its central portion had broken down.

The vaginal fistula was repaired. On her discharge, on February 8, 1895, the patient was still suffering from some leakage of urine, but not nearly so much as formerly.

Gyn.-Path. No. 773. The specimen consists of the uterus and a portion of the vaginal vault. The organ measures $9 \times 5 \times 3.5$ centimetres, and both anteriorly and posteriorly has a smooth peritoneal covering. The anterior cervical

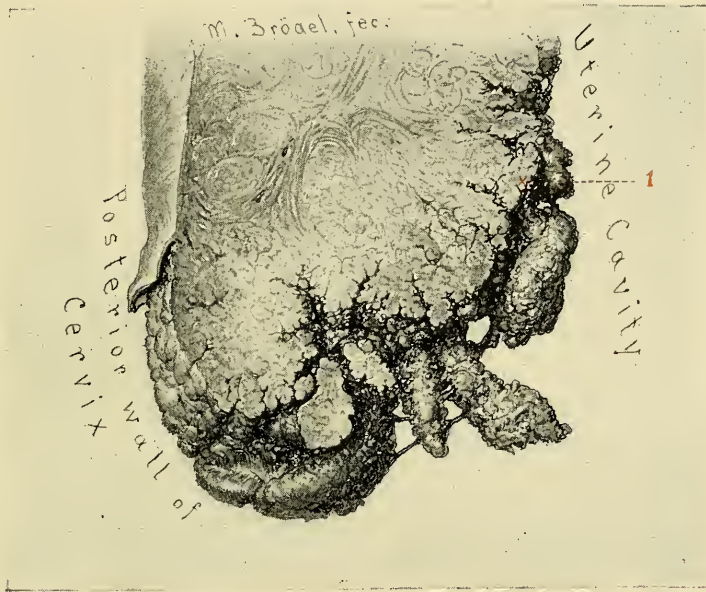
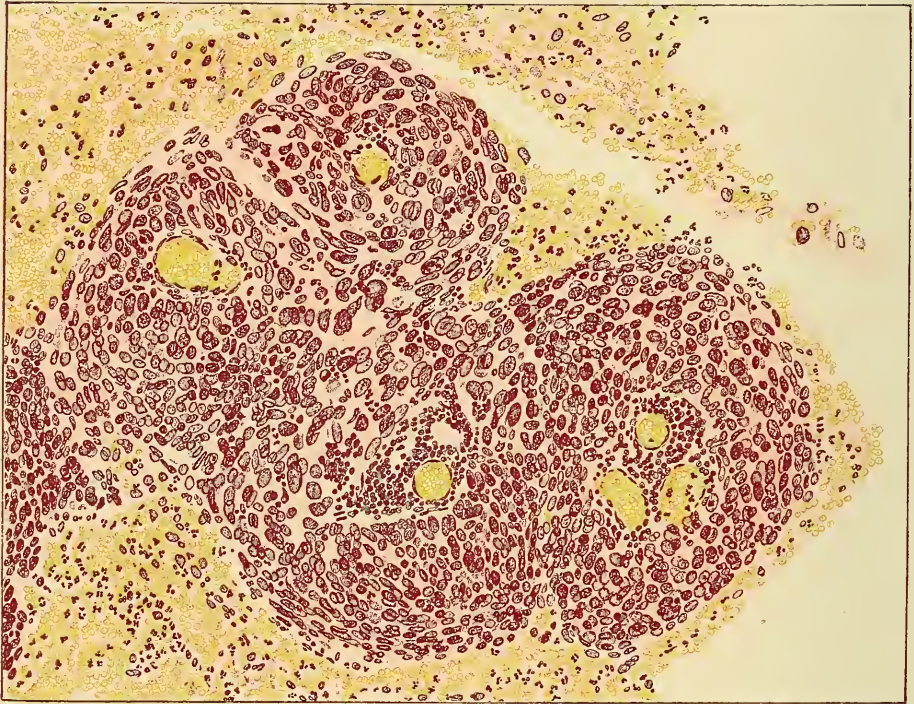


FIG. 52.—APPEARANCE ON SECTION OF SQUAMOUS-CELL CARCINOMA OF THE CERVIX. (3 diameters.)

Gyn.-Path. No. 773. The specimen consists of one lip of the cervix magnified three times. The under surface is ragged, consisting of polypoid-like masses of the growth slightly adherent to one another. Traversing the cut surface are darkened areas, which pass in and out in all directions, forming a regular network, and inclosing lighter foci. The darker portions correspond to the stroma, the lighter areas to the nests of cancer cells inclosed by the stroma.

lip is 4 centimetres broad and 3.5 centimetres in thickness. It presents a rough, slightly granular, bluish-red surface, and shows considerable excavation (Fig. 52). The outer portions of the cervical lip present a glazed appearance, but the growth can be traced for a short distance on the vaginal vault. The posterior lip is indurated, and at the junction of the cervical with the vaginal portion presents a worm-eaten appearance. On close examination this apparently worm-eaten area is found to consist of delicate, knob-like elevations, and at this point there is no loss of tissue. The cervix presents a stony hardness, and on section is found throughout its entire extent to be invaded by the new growth. The central portion of the cervix is excavated and looks worm-eaten. The solid portions of the growth are yellowish-white and waxy; even to the naked eye they are seen to consist of minute alveoli, many of which have translucent centres. Scattered irregularly throughout the growth are small yellow foci. The tumour extends laterally to the

cut surface and has evidently not been entirely removed. Upward it involves the uterus beyond the internal os. The uterine walls average 2 centimetres in thickness. The cavity is 3 centimetres long; its mucosa, which is yellowish-white and glistening, averages 2 millimetres in thickness.



H. Becker, Sec.

FIG. 53.—CROSS SECTIONS OF FOUR FINGER-LIKE OUTGROWTHS IN SQUAMOUS-CELL CARCINOMA OF THE CERVIX. (160 diameters.)

Gyn.-Path. No. 773. The section is taken from Fig. 52 at *L*. Three of these fingers contain one blood-vessel in the centre; in the fourth three are seen. The walls of those of the upper two fingers consist of a layer of endothelium lying directly against the epithelium. In the lower two, however, the vessels are surrounded by numerous young connective-tissue cells. Covering all the projections are many layers of squamous epithelium, the epithelial cells of one finger having coalesced with those of its neighbour. The nuclei of the epithelial cells are, as a rule, oval, uniform in size, and stain fairly deeply. Some, however, are fully three times as large as those of the adjoining cells. Surrounding the margins of the fingers is much blood, containing many polymorphonuclear leucocytes. The picture is very suggestive of an angiosarcoma, and it was the appearance of this section that led me to discover the frequency with which the finger-like processes are present in squamous-cell carcinoma of the cervix. (Compare with Fig. 51, p. 81; Fig. 48, p. 68; Fig. 62, p. 103; Fig. 38 *C*, p. 54.)

Histological Examination.—The squamous epithelium covering the vaginal portion of the cervix is in part intact, but at various points shows small-round-cell infiltration. Fortunately, it is possible to see where the normal epithelium ceases and the new growth commences. At such points the squamous cells are swollen, their nuclei have become more vesicular, and the basement layer, which is usually cylindrical, is somewhat flattened. A short distance farther on, the epithelial cells can be seen dipping down into the stroma.

As has been said, macroscopically the growth in some portions shows a papillary-like arrangement. These papillary-like masses are covered by several layers of squamous epithelium, and the sulci between such papillary masses likewise have a covering of several layers. On the surface of the specimen a few of these delicate papillary masses are seen on cross section. Some are almost entirely wanting in stroma, and consist of a central blood-vessel surrounded by several layers of epithelial cells. Where four or five such cross sections lie together there is a striking resemblance to an angio-sarcomatous growth (Fig. 53).

The stroma of the cervix is occupied by large and small cell-nests, sometimes oval, at other times round or irregular in contour. The nuclei of these cells are round or oval and have a vesicular appearance. In some of the cells nuclear figures are visible. Here and there, more especially along the margin of the alveoli, the cells are very large, and contain one large, deeply staining nucleus or several smaller ones. Not infrequently a few small round cells or polymorphonuclear leucocytes are found lying between the epithelial cells of the alveolus; occasionally an alveolus is filled with a necrotic laminated material, which looks very much like horny epithelium. The growth has extended laterally to the cut surface of the specimen, and has not been entirely removed. The stroma between the epithelial nests is markedly infiltrated with small round cells.

From the description it is evident that the growth is a squamous-cell carcinoma. Where the cervical glands are still preserved, they are normal. The uterine mucosa shows some slight glandular dilatation, and in its stroma are numerous small round cells. It is, however, practically normal.

Diagnosis.—Squamous-cell carcinoma of the cervix.

Gyn. No. 3,888

Squamous-cell carcinoma of the cervix with extension to the vaginal vault; pelvic peritonitis; complete torsion of the left tube accompanied by hydrosalpinx simplex; abdominal hysterectomy followed by slight incontinence of urine. The patient was lost sight of.

M. D., aged forty-eight; white. Admitted October 17, 1895. Complaint: a bloody vaginal discharge.

The patient has been married thirty-two years, has had eight normal labours and five miscarriages. Her family history is unimportant. Fifteen years ago she had hæmorrhages from the lungs and bowels.

For the last year the patient has suffered from backache and has noticed that her menstrual flow has become more profuse and lasted longer than usual. Since January there has been a continuous bloody discharge, at times amounting to profuse hæmorrhages. At present she has a copious yellowish, or bloody, offensive discharge. She is anæmic, but does not feel debilitated, nor has she lost flesh. Her appetite is good; her bowels are constipated. The vaginal outlet is relaxed, the cervix has entirely disappeared, and is represented by a deep, punched-out ulcerated area which extends upward to the internal os, outward to the broad ligament for a distance of at least 1.5 centimetres, and down-

ward upon the vaginal wall. The ureters seem to be involved in the carcinomatous process.

Operation, October, 1895. Abdominal hysterectomy. Before the administration of the anæsthetic, bougies were introduced into both ureters. The operation was difficult, as the cervix tended to tear away from the body of the uterus. The vaginal pack was removed October 24th, and had a decidedly ammoniacal odour. Later the bladder was carefully examined and the ureters were catheterized; no leakage could be detected. The patient was discharged November 26, 1895. There was still some slight incontinence of urine, but no leakage into the vagina.

Gyn.-Path. No. 924. The specimen consists of the uterus with its appendages intact. The uterus measures 9 centimetres in length, 5.5 in breadth, and 3.5 in its antero-posterior diameter. On the surface of the uterus are a few flakes of fibrin. The external os is represented by an irregular crater-like opening, 3.5 centimetres in diameter; the cervical lips are invaded by a new growth, which has extended over into the vaginal vault and into the broad ligament. On section the cervix, both anteriorly and posteriorly, is markedly excavated. The inner surface of this excavation is roughened, granular, and covered by a small amount of yellowish granular material, while the surrounding cervical tissue is exceedingly hard. The growth has extended upward to within 1 centimetre of the internal os. The uterine walls average 2 centimetres in thickness; the cavity is 3 centimetres in length; its mucosa is smooth. The right tube is covered by a few delicate adhesions, but the ovary presents the usual appearance. The left tube for a short distance from the uterus is twisted and is represented by a slender cord 2 millimetres in diameter; it gradually increases in size and terminates in an occluded fimbriated extremity, 2.3 centimetres in diameter. The ovary is covered by dense adhesions.

Histological Examination.—The squamous epithelium covering the vaginal portion of the anterior lip is intact, but just beneath it there is considerable small-round-cell infiltration. In passing inward toward the excavation, the epithelium disappears from the surface, but is seen invading the stroma in all directions. The epithelial cells are arranged in oval, round, or irregularly branching alveoli; their nuclei, twice the size of those of the normal epithelial cells, are oval or round, and stain deeply. Along the advancing margin of the growth the alveoli are much swollen, but the cells appear to be very active; the nuclei of some are large, oval or round, and stain very deeply. Not infrequently one sees large plaques of protoplasm containing irregular masses of chromatin or two or three deeply staining nuclei.

Laterally the growth extends almost, if not quite, to the cut surface. In other sections, many of the alveoli contain vacuoles, and in a few places there is a slight gland-like arrangement, reminding one somewhat of adeno-carcinoma. The growth is apparently a squamous-cell carcinoma. The mucosa covering the anterior wall of the cervix is to a great extent intact, but in several places the squamous epithelium at the mouth of a gland has proliferated, extended into, and partially obliterated it. The masses of the new growth extend upward beyond the internal os. Here tumour cells are seen lying in the stroma of the mucosa

between the uterine glands. The mucosa is atrophic, but is normal, considering the age of the patient.

The right tube and ovary are normal. Where the left tube is twisted, the lumen is completely obliterated; at its outer end it is the seat of a hydrosalpinx simplex.

Diagnosis.—Squamous-cell carcinoma of the cervix with apparent extension to the vaginal vault and broad ligaments. Complete torsion of the left tube with simple hydrosalpinx of its outer end.

January 1, 1900. The patient cannot be found.

Patient of Dr. Noble

Squamous-cell carcinoma of the cervix; removal of a piece for examination; difficulty in diagnosis on account of poor hardening of the specimen; vaginal hysterectomy; recovery. No evidence of return. Death from pneumonia, five months after operation.

H., aged fifty-three; married. She has had two children and three miscarriages. Menstruation was regular until March, 1895. In the following May she had a slight flow; since this time there has been no bloody discharge, but occasionally she has had moderate leucorrhœa. In December, 1895, she had severe pain in the pelvis; this has been continuous. On admission her general appearance is good, micturition is scanty, and there is considerable vesical irritability, with some œdema of the legs. The vaginal outlet is slightly torn, and the cervix, which is lacerated, is markedly indurated. The uterus is slightly enlarged and firm, and on its left side an inflammatory mass can be felt. A section of the indurated cervix was removed and examined microscopically.

Gyn.-Path. No. 770. The specimen consists of two pieces of the cervix, the larger of which measures $1.5 \times .5 \times .4$ centimetres. This, macroscopically, is apparently normal.

Histological Examination.—Portions of the cervical mucosa are normal, but in other places the squamous epithelium has entirely disappeared, and there is a granulating surface. The smaller piece of tissue has nests of epithelial cells scattered throughout its stroma. The nuclei of these cells are large, oval, and vesicular, and nuclear figures occasionally are seen. The cervical stroma shows considerable small-round-cell infiltration. While an absolute diagnosis of squamous-cell carcinoma can hardly be made, the condition is, nevertheless, so suspicious that hysterectomy is advisable.

Diagnosis.—Probable squamous-cell carcinoma of the cervix.

Vaginal hysterectomy was performed by Dr. Noble, of Philadelphia. For a few days after the operation there was some elevation of temperature, but the patient made a good recovery, and on June 6, 1896, was in excellent condition.

Gyn.-Path. No. 888. The specimen consists of the uterus and a portion of one tube. The uterus measures $7 \times 5 \times 4$ centimetres. Both anteriorly and posteriorly the surface is smooth and glistening. The cervix, which measures 4×4 centimetres, presents a rough, worm-eaten appearance. On section this is

even more striking, but the underlying tissue gives no evidence of being infiltrated. The uterine walls vary from 2 to 2.5 centimetres in thickness, and the uterine cavity is 3 centimetres in length. The mucosa averages 2 millimetres in thickness, and is smooth and glistening.

Histological Examination.—The specimen is only fairly well preserved. The cervical portion, which looks worm-eaten, is necrotic, but shows no inflammatory reaction. Scattered throughout the necrotic material are masses of cells cut crosswise or longitudinally. These are in part necrotic, but in most places stand out in striking contrast to the surrounding areas of necrosis. The cells forming those nests are closely packed together, and have oval, or almost round, uniformly staining nuclei. The alveoli do not appear to penetrate the cervical tissue for a distance of more than 3 millimetres laterally, and upward they have involved the cervix to a correspondingly limited extent. The growth is malignant, and appears to be a squamous-cell carcinoma, although sarcoma cannot be absolutely excluded.

The mucosa of the uterine cavity has not been sufficiently well preserved for examination.

Diagnosis.—A commencing malignant growth in the cervix, apparently squamous-cell carcinoma.

Dr. Noble informs me that the patient died December 14, 1896, from pneumonia. "There had been no recurrence of the disease, as I had examined her within a few weeks of her death."

Gyn. No. 2,847

Squamous-cell carcinoma of the cervix; cauliflower mass filling the upper part of the vagina; curettage.

A., aged forty-five; white. Admitted June 19, 1894. Complaint: profuse leucorrhœal discharge, aching in back and lower abdomen.

The patient has been married twenty-five years and has had four children. Labours normal, no miscarriages. The menstrual history is normal; the last period occurred about April 15, 1894. Family history good; previous history unimportant.

One year ago leucorrhœa commenced, since which time the patient has become weak and has lost flesh rapidly. She has had frequent backache, and for the last month has complained of sharp pains over both ovarian regions. She is poorly nourished and is anæmic; her appetite is good, the bowels are regular, micturition is frequent, scanty, and painful.

The vaginal outlet is relaxed. Filling the whole upper part of the vagina is a fungating, friable mass, which springs from the cervix. The uterus is freely movable, and although the growth is far advanced, it is impossible to make out any involvement of the broad ligament. The patient was anæsthetized and a large amount of growth curetted away; a radical operation was out of the question.

Gyn.-Path. No. 348. The specimen consists of several mushroom-like masses, the largest of which measures $5 \times 4 \times 1$ centimetres. On section these masses present a white homogeneous appearance closely resembling wax. They break with the utmost readiness, crumbling like cheese.

Histological Examination.—The tissue is composed of alveoli which may assume any shape, being finger-like, oval, branching, or irregular. All are filled with cells having large, oval, pale-staining nuclei. Some contain nuclear figures, others very large oval or half-moon-shaped nuclei, which stain intensely with the hæmatoxylin (Fig. 54, *b*). In many places the cells forming the cir-

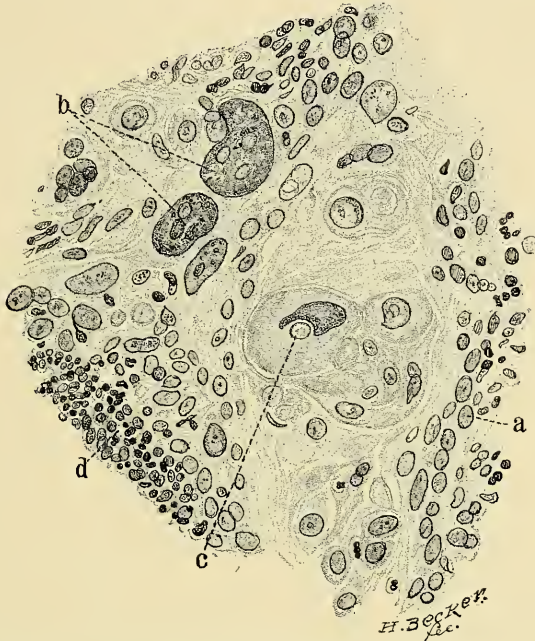

FIG. 54.—CELL CHANGES IN SQUAMOUS-CELL CARCINOMA OF THE CERVIX. (350 diameters.)

Gyn.-Path. No. 348. *a* shows the average size of the nucleus of an epithelial cell in this case. *b* indicates two large and rather deeply staining nuclei, both of which contain hyaline droplets. At *c* is a large epithelial cell with an irregular and deeply staining nucleus. Lying in the concave surface is a red blood corpuscle. At *d* are the stroma cells of the part, and scattered between them are the dark nuclei of the small round cells.

cumference of the alveoli stain more deeply, and to some extent resemble cylindrical epithelium. They remind one of the deepest layer of squamous epithelium. Scattered here and there between the cells in the alveoli are small round cells, and in not a few are areas of necrosis. Occasionally epithelial pearls are seen. The stroma is composed of connective tissue, whose cells contain spindle-shaped nuclei. The blood supply of the stroma is scanty. The picture is one of a typical squamous-cell carcinoma.

Diagnosis.—Squamous-cell carcinoma of the cervix.

Gyn. No. 2,997

Squamous-cell carcinoma of the cervix; curettage.

E. S., aged forty-two; coloured. Admitted August 13, 1894. Complaint: swelling in the left iliac region, associated with pain in the lumbar region, and in the thigh.

The menses have been regular up to one year ago; the last period commenced two weeks before admission and was associated with some pain. The patient has had five normal labours and one miscarriage. Her father died of carcinoma.

For the last year she has had a yellowish-white, non-offensive, vaginal discharge, and in February of this year experienced severe pain in the hip, knee, and calf of the leg. The pain disappeared for several months and then returned. On admission the patient is fairly well nourished; her tongue is coated; the bowels are constipated. She complains of dull, aching pain in the regions above mentioned.

On August 15th the uterus was curetted. The patient was discharged August 31, 1894.

Gyn.-Path. No. 419. The specimen consists of curettings to the amount of 15 cubic centimetres. The largest of these measures 2.5×1.5 centimetres; it presents a waxy-white appearance, and has small yellow specks scattered throughout it. The pieces are very friable, and immediately remind one of carcinomatous tissue.

Histological Examination.—The greater part of the tissue consists of islands of cells, which in many places run one into the other. The individual cells have oval, vesicular nuclei, not a few of which show nuclear figures; others of the cells are very large, and have correspondingly large, deeply staining nuclei. Between the cells of these islands are polymorphonuclear leucocytes. Some of the islands have become necrotic. The stroma of the tissue is composed of connective-tissue cells having spindle-shaped nuclei.

Diagnosis.—Squamous-cell carcinoma of the cervix.

Gyn. No. 3,243

Squamous-cell carcinoma of the cervix; branching tree-like outgrowths (Fig. 55). Cervical polyp. Vaginal hysterectomy. Recovery. Local recurrence. Death two and a half years after operation.

S. H. D., aged fifty-two; white. Admitted December 17, 1894. Complaint: uterine hæmorrhage associated with pain in the lower abdomen.

The patient has been married thirty-two years and has had seven children. Her menses ceased seven years ago. Her family history is good. Ever since the cessation of the menses the patient has never been thoroughly well.

Nine months ago she noticed a slight bloody discharge, and at first thought it was a return of the menstrual flow. Since then, over-exertion has been frequently followed by hæmorrhage, which has, however, never been free. The patient has been under treatment for some time, and is in better health than formerly. Her appetite is fair; the bowels are regular.

Operation, December 19, 1894. Vaginal hysterectomy. The diseased tissue was curetted away as far as possible, and the uterus removed in the usual way. The patient made a good recovery.

Gyn.-Path. No. 549½. The specimen consists of the uterus and a firm, rather lobulated mass, measuring $4 \times 2.5 \times 1$ centimetres. This piece of tissue is bright red in colour, and has small yellowish patches scattered throughout it. On section its cut surface is pale in colour, and the tissue is rather soft. The uterus

measures $7 \times 4 \times 2.5$ centimetres. Anteriorly and posteriorly the surface is smooth and glistening. Upon everting the cervical lips, the anterior one is seen to present a freshly cut surface, evidently the result of the removal of the above-

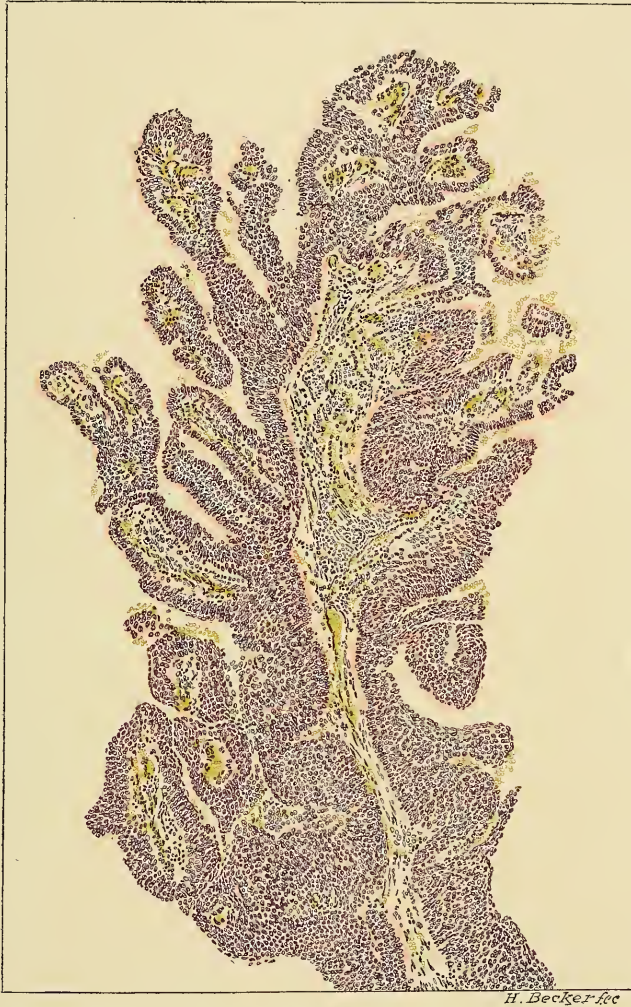


FIG. 55.—SQUAMOUS-CELL CARCINOMA OF THE CERVIX; FINGER-LIKE PROCESSES ARISING FROM A COMMON STEM. (80 diameters.)

Gyn.-Path. No. 549 $\frac{1}{2}$. Traversing the centre of the specimen is a delicate stem of connective tissue, in the centre of which is a blood-vessel. This stem gives off lateral branches, which likewise contain blood-vessels. The main stem is covered in some places by only one layer, in others by many layers of squamous epithelium. The epithelial cells next to the stroma tend to be cuboidal. The epithelial nuclei throughout are fairly uniform in size. Near the left lower corner are several cross sections of the terminal branches or fingers. These present a typical appearance.

mentioned mass. The cervical mucosa presents the usual appearance. The uterine walls vary from 1 to 1.3 centimetres, in thickness; the cavity is 2.5 centimetres in length. The uterine mucosa, from 1 to 2 millimetres in thickness, is pale yellow in colour, and presents a smooth surface.

Histological Examination.—The piece of tissue accompanying the uterus is evidently from the anterior lip of the cervix. The greater part of it is occupied by round, oval, or irregular alveoli, many of which are connected. They are continuous with the squamous epithelium, which covers the surface of the specimen. All of the alveoli are completely filled with cells, whose nuclei are large, oval, and vesicular. In many of the cells karyokinetic figures are visible; in fact so abundant are they that in numerous alveoli a complete karyokinetic cycle can be traced. The cells which form the outer lining of the alveoli manifest some tendency to be cylindrical, as is seen in the deepest layer of the skin. Here and there between the individual cells polymorphonuclear leucocytes may be seen, and in some places there has been slight hæmorrhage into the alveoli.

At one point a distinct papillary-like outgrowth is seen (Fig. 55). This consists of a central stem of connective tissue, which gives off numerous lateral branches or terminal fingers. Both the stem and the terminal branches are covered by many layers of squamous epithelium. The terminal branches form the typical finger-like processes.

The stroma of the tissue has a rather poor blood supply, and is everywhere infiltrated by small round cells. This infiltration is most marked along the advancing margin of the growth, which is sharply defined. The epithelium covering the vaginal portion of the posterior lip is in many places intact. The cervical glands, as a rule, present the usual appearance; some, however, are slightly dilated.

Situated a short distance within the external os is a cervical polyp, the glandular elements of which are identical with the cervical glands. The uterine mucosa is atrophic, but considering the age of the patient is normal.

Diagnosis.—Squamous-cell carcinoma of the anterior lip of the cervix.

December 22, 1899.—Dr. M. E. Robinson, of Goldsboro, N. C., writes that the patient did well for about eighteen months and then broke down completely. The pelvis was everywhere involved, and she became almost helpless. Death took place about two and a half years after operation.

Gyn. No. 2,572

Squamous-cell carcinoma of the cervix; beginning obliteration of the cervical glands (Fig. 56); cyst of the right ovary; vaginal hysterectomy; severe hæmorrhage from the left broad ligament; secondary hæmorrhage; transfusion; recovery. Local recurrence. Death three years and seven months after operation.

S. C., age unknown; coloured. Admitted February 6, 1894. The clinical diagnosis was carcinoma of the cervix.

Operation, February 17th. Vaginal hysterectomy.

During the removal of the uterus there was free hæmorrhage from the left side. A cyst of the right ovary, which presented itself at the vaginal vault, was tied off and removed. A few hours after the operation the patient was in a state of collapse; her face presented a drawn expression, her skin was blanched, and the pulse

scarcely perceptible. The breathing was shallow and laboured, and she complained of pain in the right hypochondriac region. On examining the dressings they were found to be soaked with a bloody discharge. At 7.30 p.m. the pulse could not be felt, the dyspnoea was more marked, and the patient complained of pain in the right chest. Clamps were applied to the left broad ligament, an opening was made in the radial artery, and about 500 cubic centimetres of normal salt solution were introduced. The artery was doubly ligated and cut between ligatures. The pulse was immediately perceptible, and in twelve hours the rate fell from 156 to 128, the volume steadily increased, and the breathing improved. The clamps were removed at the expiration of forty-eight hours. For several days the patient complained of severe abdominal pain and backache. She was discharged on February 19th; her appetite was excellent, and she was steadily gaining in strength.

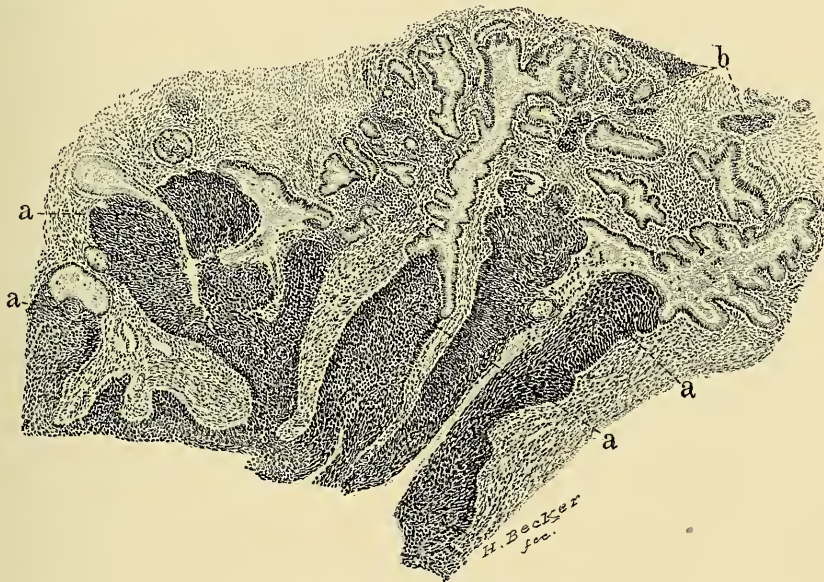

FIG. 56.—PARTIAL OBLITERATION OF THE CERVICAL GLANDS IN SQUAMOUS-CELL CARCINOMA OF THE CERVIX. (40 diameters.)

Gyn.-Path. No. 173. At *a* the squamous cells of the new growth are extending into and rapidly choking the normal cervical glands. Note the intense stain of the squamous cells, and how closely packed together they are. *b* indicates cell-nests of the growth in the depth of the cervix. (Compare with Fig. 43, p. 59.)

Gyn.-Path. No. 173. The specimen consists of the uterus and of a tumour of the right ovary. The uterus measures $11 \times 6 \times 4$ centimetres. Both anteriorly and posteriorly the surface is smooth and glistening. The cervix is on an average 2 centimetres in thickness. Its vaginal portion is smooth and glistening, but at the external os is a bright red granular zone, 1.5 centimetres in breadth. There is no breaking down of the tissue. On section the cervix on the left side is found to be invaded, to a depth varying from 1 to 1.5 centimetres, by a new growth. The cervical mucosa, where present, shows a slightly granular appearance, but on the right side of the canal it appears normal. The uterine walls

vary from 2.2 to 3 centimetres in thickness; the uterine mucosa is smooth and glistening, but slightly injected.

The right tube in general presents the usual appearance, but is bound down to the enlarged ovary by fan-like adhesions. The ovary is converted into a yellowish-white tumour, 5 centimetres in diameter. At the hilum of the tumour some ovarian tissue is still visible; in it are several Graafian follicles. The cyst on cursory examination reminds one of a dermoid.

Histological Examination.—Sections from the left side of the anterior lip show that the epithelium covering the vaginal portion is intact, but in other areas the cells are seen dipping down into the underlying tissue. Some project downward in finger-like masses, but other collections show considerable branching. Here and there a cervical gland is almost or completely choked by the cells (Fig. 56). The epithelium has penetrated the cervix in all directions, and in such a way that the cell-nests blend with one another, forming a regular network throughout the tissue. Along the advancing margin the epithelial cells occur in small clumps. As soon as the epithelium commences to dip into the tissue, it changes in appearance, the cell elements are very abundant, the nuclei stain deeply, and are sometimes irregular in contour and not infrequently are considerably enlarged.

From the above description it is manifest that the growth is a squamous-cell carcinoma. It appears to have been entirely removed, as there is a good margin of sound tissue before the cut surface is reached. The uterine mucosa has an intact surface epithelium and its gland elements are normal.

The tube is normal. The cyst of the ovary closely resembles those described as corpora-lutea cysts, and it probably belongs to this variety.

Diagnosis.—Squamous-cell carcinoma of the cervix. Cyst of right ovary, which has probably developed from a corpus luteum.

Dr. Nathan R. Gorter writes me that the patient had a return of the growth and died September 17, 1897.

Gyn. No. 2,509

Squamous-cell carcinoma of the cervix; slight extension to the vagina; involvement of the left broad ligament; giant cells in cell-nests (Fig. 57); curettage.

M. F., aged forty-five; white. Admitted January 12, 1894. Complaint: a dragging pain in the lower part of the back and in the hypogastric region; profuse leucorrhœal discharge; profound weakness.

The patient has been married twenty-one years, and has had eight children; the labours were slow and protracted, but non-instrumental. She has had four miscarriages. Her family history is negative, and up to the present illness she has always been well.

Two years previous to admission she began to feel tired and languid, and was rather nervous. Shortly afterward she noticed that the menstrual flow became more abundant, and that at times it would persist until the next period began. Five months before admission she first experienced a dragging or gnawing pain in the back and lower abdomen. This at times radiated down the right thigh to the knee. When the pa-

tient was not flooding, she had a thick, whitish, offensive vaginal discharge. The woman is very pale and anæmic. Her bowels are constipated, and defecation occasions pain. When walking she has pain throughout the lower pelvis. The

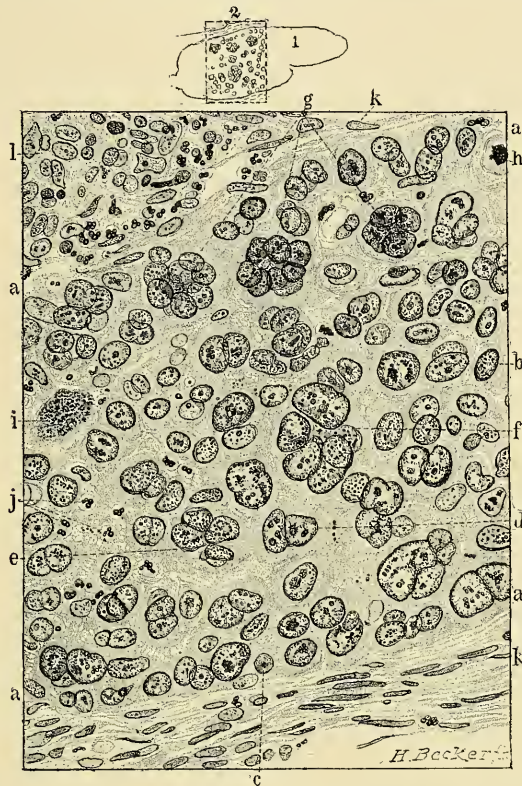

FIG. 57.—A PORTION OF A CELL-NEST SHOWING THE CHARACTERISTIC EPITHELIUM AND GIANT CELLS. (370 diameters.)

Gyn.-Path. No. 136. On referring to the small schema above the drawing, 1 indicates the entire cell-nest, and 2 the portion taken and magnified to form Fig. 57. *a a* indicate the upper and lower limits of the nest. *b* shows the average size of the epithelial cell, the nucleus being oval and staining fairly deeply. *c* is probably the cross section of a nucleus nearly as large as *b*. *d* is a large and slightly irregular cell, clearly outlined from its neighbours, and containing two somewhat irregular nuclei with large granules of chromatin in their interiors. The cell *e* contains at least five nuclei. *f* also contains several nuclei, which vary much in size, and tend to group themselves in the centre of the cell. At *g* are indicated three giant cells with smaller and more uniform nuclei. *h* is a nucleus undergoing degeneration. *i* shows a nucleus with marked karyorrhexis, the chromatin being seen as scattered clumps. Lying between the epithelial cells are numerous polymorphonuclear leucocytes (*j*). *k* is the stroma surrounding the cell-nest, and in the vicinity of *l* shows considerable small-round-cell and polymorphonuclear leucocytic infiltration.

vaginal outlet is greatly relaxed, and the cervix is converted into a friable, irregular mass, which extends outward for a short distance over the vaginal mucosa, and upward into the cavity of the uterus. The uterus is greatly enlarged, irregularly nodular, and is not very movable. The disease has apparently involved the left broad ligament.

Operation, January 17th. The carcinomatous tissue was curetted away with the finger, leaving nothing but the shell of the uterus. All the tissue that was

removed was foul smelling and necrotic. For the first few days after operation the patient complained greatly of pain. On her discharge from the hospital, July 25th, she did not look so anæmic, and her appetite was somewhat improved.

Gyn.-Path. No. 136. The specimen consists of three ounces of friable tissue, the largest piece of which measures 3×2 centimetres.

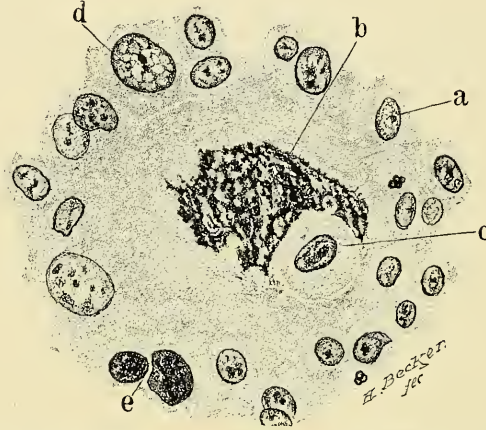

FIG. 58.—A VERY LARGE CELL CONTAINING A LARGE IRREGULAR MASS OF CHROMATIN. (625 diameters.)

Gyn.-Path. No. 136. *a* shows the average size of the nuclei. Occupying the centre of the drawing is a very large cell. On one side its outline is sharp; on the other it merges imperceptibly into the adjoining cells. Its nucleus, *b*, is very large, irregular in outline, and consists of large and small masses of chromatin. *c* is an epithelial cell apparently lying within the large cell. It is probable, however, that this cell has formed an indentation in the large cell from the other side, and the section at a higher level would then naturally give the present picture—that of an inclusion. *d* is a nucleus fully four times the average size. *e* is a cell containing two deeply staining nuclei, one of which is irregular.

Histological Examination.—Surrounding the specimen are small clumps of cells having oval, vesicular nuclei; scattered between these cells are a moderate number of polymorphonuclear leucocytes. The greater part of the specimen consists of irregular islands of cells similar to those described. Many of these cells, however, are very pale, and their nuclei are from twice to seven or eight times the size of the surrounding ones. These large nuclei appear to be vacuolated, and their chromatin is seen as delicate granules scattered sparingly throughout them (Fig. 57). In others of these pale cells are several small nuclei (Fig. 57, *e, f, g*), while here and there is a plaque of protoplasm containing fine chromatin granules (Fig. 57, *i*, and Fig. 58, *b*). These large cells appear to be the result of degenerative changes. The stroma of the tissue has an exceedingly rich blood supply.

Diagnosis.—Squamous-cell carcinoma of the cervix.

Gyn. No. 2,294

Squamous-cell carcinoma of the cervix; giant cells in the stroma (Fig. 59); gland hypertrophy of the uterine mucosa; vaginal hysterectomy; recovery. No return of the growth, six years and two months after operation.

H., aged forty-three; white. Admitted November 5, 1893.

The patient has had eight children, but no miscarriages. For two months she has had a profuse leucorrhœal discharge, and during the last twelve months her menstrual flow has been prolonged, lasting from twelve to fifteen days. She complains of intermittent pain in the right ovarian region. On admission she is extremely anæmic; the vaginal outlet is moderately relaxed, and springing from the cervix is a flat carcinomatous mass. The uterus is freely movable. No hæmorrhage followed the examination.

Operation November 8th. Vaginal hysterectomy was performed in the usual manner, and was attended with little difficulty. The patient steadily improved.

Gyn.-Path. No. 78. The specimen consists of the uterus, with the left tube and ovary attached to it. The uterus measures $9 \times 7 \times 3.5$ centimetres. The cervix is enlarged, and in places presents a worm-eaten appearance. Springing from the centre of the anterior lip, at the junction of the cervical with the vaginal mucosa, is a soft, friable, fungating mass, 1 centimetre in diameter. On section, the cervical

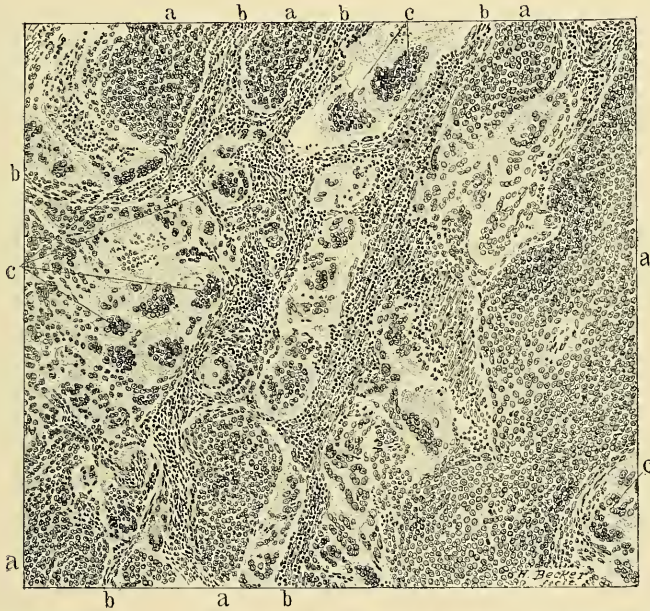


FIG. 59.—SQUAMOUS-CELL CARCINOMA OF THE CERVIX WITH GIANT CELLS IN THE CELL-NESTS AND LYING FREE IN THE STROMA. (100 diameters.)

Gyn.-Path. No. 78. *a* indicates longitudinal and cross sections of cell-nests. It will be noted that the nuclei are very regular in size. *b* is the stroma or tissue between the cell-nests, and shows much small-round-cell infiltration. *c* indicates giant cells. These consist of large, round, or irregular masses of protoplasm containing many nuclei, bunched principally in the centre of the cell. These nuclei are about the same size as those of the epithelial cells in the cell-nest. The giant cells are found lying free in the stroma, and also form portions of the cell-nests.

canal is found to be eaten out for a distance of 1 centimetre; the cervix has been invaded by the new growth as far as the internal os. Macroscopically, the growth does not appear to have extended to the broad ligament.

The uterine walls average 2.5 centimetres in thickness, and the mucosa lining the inner surface of the uterus is smooth and presents the usual appearance.

The left tube and ovary show nothing of interest.

Histological Examination.—The cervix is everywhere invaded by large and small masses of cells. These alveoli are round, oval, club-shaped, or branching, according to the angle at which they have been cut. The cells filling them have oval, vesicular nuclei. The central portions of many of the alveoli are filled with horny epithelium or contain epithelial pearls. Occupying the centre of the alveolus in some instances, or situated at the margin of the alveolus, and not infrequently lying perfectly free in the stroma of the cervix, are giant cells (Fig. 59). These consist of oval or irregular plaques of protoplasm, containing anywhere from four or five to as many as forty or fifty nuclei, which in form and size correspond to those found in the alveolus. The stroma of the cervix between the islands shows a slight amount of small-round-cell infiltration. The growth is a squamous-cell carcinoma, and, as far as can be made out from the sections, has not extended to the broad ligament.

The uterine mucosa is of the usual thickness; its surface epithelium is intact, but its superficial glands are dilated and markedly convoluted, presenting the typical appearance of glandular hypertrophy. The glands in the vicinity of the muscle are perfectly normal. The left tube and ovary are normal.

Diagnosis.—Squamous-cell carcinoma of the cervix. Hypertrophy of the uterine glands.

January 6, 1900. Dr. Charles Duffy, of Newberne, N. C., writes me as follows: "A few months after her return the scar seemed to show evidence of the growth, and I touched the granulations a few times with fused chromic acid, and there has been no appearance since of a suspicious growth. She has had no hæmorrhage since the time above referred to. Her general condition is fairly good; some dyspeptic and rheumatic trouble. Mrs. H. is, in my opinion, entirely free from cancer."

The suspicious area in the vaginal vault was doubtless due to the irritation around a silk ligature. Length of time since operation, about six years and two months.

Gyn. No. 2,599

Squamous-cell carcinoma of the cervix; normal and atypical division of the nuclei (Fig. 60); curettage.

P. B., aged forty-eight; white. Admitted February 19, 1894. Complaint: offensive vaginal discharge, bearing-down pain in the lower abdomen.

The patient has been married thirty-one years and has had ten children and two miscarriages. Her menses ceased five months ago. Her family history is tuberculous; her previous history good. For the last year she has had a profuse offensive vaginal discharge. This at times has contained "flesh-like" material, evidently clotted blood. Since the discharge appeared, the patient has been weak and languid.

Operation, February 21st. The cervix was found to be markedly involved by a new growth, and the disease had almost perforated the recto-vaginal septum. As much as possible of the diseased tissue was curetted away. Inspection of the bladder at the time of the operation showed on the left side of its base an area 3×5 centimetres, which was covered with translucent elevations of variable size. These looked very much like vesicles. After operation, the pain diminished somewhat, and the discharge was less offensive.

On leaving the hospital the patient was somewhat improved.

Gyn.-Path. No. 181. The scrapings are whitish red and crumbly.

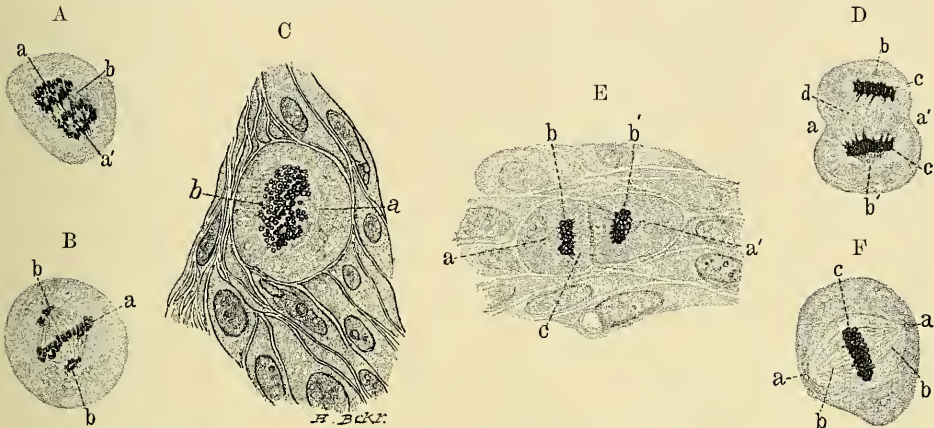


FIG. 60.—NUCLEAR DIVISION IN CANCER CELLS. (925 diameters.)

Gyn.-Path. No. 181. A represents a diaster stage seen more from the side. *a* and *a'* are the poles. *b* indicates the achromatic filaments.

B shows an abnormal or pathological division of the nucleus. The chromatin is gathered into two rows at *a*, but quite a number of the chromatin filaments still cling to the poles, *b* and *b*.

C shows a dividing cell seen from near its end. Only one pole (*a*) and the corresponding half of the chromatin (*b*) are visible.

D. *a* and *a'* show the indentation on both sides of the cell prior to its cleavage. *b* and *b'* are the poles. *c* and *c'* indicate the chromatin gathered to form the diaster. It will be noted, however, that considerable chromatin is still clinging to the achromatic filaments, not being gathered up into two sharply defined masses, as seen in E.

E shows a normal diaster stage. *a* and *a'* represent the poles. *b* and *b'* show two equal divisions of the chromatin filaments. *c* indicates the achromatic filaments of the spindle.

F shows a perfectly normal spindle. *a* and *a* are the poles. *b* indicates achromatic filaments. All the chromatin is gathered into two distinct rows of granules at *c*. (Hæmatoxylin and eosin.)

Histological Examination.—The specimen consists of non-stripped muscle; traversing it everywhere are irregularly oval, round, or branching, deeply staining areas composed of cells. These cells have oval, vesicular nuclei, and many of them contain nuclear figures (see Fig. 60). On the whole, they closely resemble squamous epithelium. Here and there polymorphonuclear leucocytes are found wandering in between the cells.

Diagnosis.—Squamous-cell carcinoma of the cervix.

Gyn. No. 2,689

Squamous-cell carcinoma of the cervix; attempted combined vaginal and abdominal hysterectomy.

M. E., aged thirty-four years; white. Admitted February 13, 1894. Complaint: profuse uterine hæmorrhages, painful micturition.

The patient has had two children; the last labour was instrumental. Her family history is good. Her previous history is unimportant. Her menses began in her seventeenth year, usually lasted four days, were free, but associated with considerable pain in the lower part of the abdomen and back. About six months ago the flow became very profuse, but still continued to be regular. For three months it has been still more profuse, and the periods have been so prolonged that at times one would only end a week before the next began. The blood is frequently clotted.

The patient is a large robust-looking, well nourished woman; the appetite is good, the bowels are regular. At times micturition is painful. It is worthy of note that with each stool there is some uterine hæmorrhage. The vaginal outlet is relaxed, the cervix is high up in the vagina, and its lips are much indurated, everted, and eroded. In some places there is distinct loss of tissue. Under anæsthesia several large, circumscribed masses can be felt in the broad ligaments.

Operation, February 15, 1894. The cervix was curetted and its lips brought together by sutures. After inserting a catheter into the left ureter, the cervix was ringed and liberated on all sides almost to the peritonæum. The patient was then placed in the Trendelenburg position and the abdomen opened. The masses in the broad ligaments were densely adherent to the pelvic walls, and appeared to be metastases. The operation was abandoned and the abdominal cavity closed. On February 20th two pieces of gauze were removed from the vagina and were found to be soaked with a bloody purulent discharge. The abdominal stitches were removed on February 23d, and the upper angle of the wound having been opened, a large quantity of pus escaped. The discharge from the abdominal incision gradually ceased, and the patient left the hospital March 15, 1894.

Gyn.-Path. No. 170. The specimen consists of uterine curettings. The largest piece of tissue, measuring 2.5×2 centimetres, is firm, and on section presents a yellowish-white mottled appearance.

Histological Examination.—The surface of the piece examined is covered by several layers of squamous epithelium, which shows considerable polymorphonuclear and small-round-cell infiltration. The tissue is everywhere invaded with alveoli, which on section are round or branching. The cells filling the alveoli have oval or elongate-oval, somewhat deeply staining nuclei, some nuclear figures being present. Scattered throughout the alveoli are many polymorphonuclear leucocytes, and the centres of some are completely filled with them. The stroma of the tissue is densely infiltrated with small round cells, and has a fairly abundant blood supply.

Diagnosis.—Squamous-cell carcinoma of the cervix.

Gyn. No. 2,728

Squamous-cell carcinoma of the cervix, only the rim of the cervix remaining; broad ligaments indurated; body of uterus somewhat fixed; curettage.

A. W., aged thirty-nine; coloured. Admitted April 17, 1894. Complaint: continuous uterine hæmorrhage, occasional uterine pain. The family history is

unknown. The patient has had two children and no miscarriages. She has always been healthy. In 1890 she had a hæmorrhage, since which there has been a constant bloody discharge, at times clotted. She complains a great deal of uterine pain.

The patient is fairly well nourished, the mucous membranes are pale, the appetite is good, the bowels are constipated. Micturition gives rise to a burning sensation, and locomotion is painful. On vaginal examination only the rim of the cervix is left. The greater part of the cervix and also the uterine cavity are represented by a rough, nodular mass, which breaks down under the finger. The broad ligaments are indurated, and the body of the uterus is somewhat fixed.

Operation, April 21st. Large quantities of necrotic tissue were curetted away, and the uterus was packed with iodoform gauze. The patient was discharged slightly improved.

Gyn.-Path. No. 268. The specimen consists of several large scrapings, which are reddish in colour and in places present a cheesy appearance. The largest piece measures 1.3 centimetres in diameter, and reminds one of carcinoma. The stroma of the tissue is composed of connective tissue, with here and there non-striated muscle fibres. Scattered throughout the stroma are numerous small, round cells. Invading the tissue in all directions are alveoli of various shapes; these are filled with cells having oval, vesicular nuclei, and often presenting nuclear figures. There is no retrograde change in the alveoli.

Diagnosis.—Squamous-cell carcinoma of the cervix.

Gyn. No. 2,939

Squamous-cell carcinoma of the cervix; curettage.

M. D., aged thirty-two; white. Admitted July 24, 1894. Complaint: a constant bloody vaginal discharge, and sharp, shooting pains through the lower abdomen and back.

The family history is good. The patient has had one child; the labour was normal. She has never had any serious illness.

The menses have always been regular. At the last period, which commenced July 17th, there was a flow only for two days, but it was very profuse. In April the menstrual flow appeared at the usual time, was very free, and lasted nearly the entire month. Shortly afterward she complained of a dull, heavy pain throughout the lower abdomen. Coincident with this she began to lose flesh, and became weaker. Since April there has been a slight bloody or whitish discharge. On admission the patient is poorly nourished, pale, and anæmic; her appetite is poor; the bowels are constipated; micturition is frequent and painful.

The uterus was curetted on July 28th, and the patient left the hospital August 3, 1894.

Gyn.-Path. No. 403. The specimen consists of numerous pieces of tissue from the uterus. The largest of these, measuring 2 centimetres in diameter, is whitish in colour and very friable. It immediately reminds one of carcinomatous tissue.

Histological Examination.—The squamous epithelium covering the vaginal portion of the cervix is in places intact. Further on, however, it soon becomes thin and stains very deeply. The underlying stroma at these points

shows marked small-round-cell infiltration. In other places the surface epithelium has entirely disappeared, and the underlying tissue is everywhere infiltrated by alveoli of an oval, round, or elongate form; these are filled with cells containing large, pale-staining nuclei. Some of the alveoli are partly filled with necrotic material, in which are a few polymorphonuclear leucocytes. Leucocytes have wandered in between the individual epithelial cells. The stroma of the cervix has many small round cells scattered throughout it.

Diagnosis.—Squamous-cell carcinoma of the cervix.

Gyn. No. 2,964

Squamous-cell carcinoma of the cervix (Fig. 61); cross sections of finger-like growths (Fig. 62); a dropping-out of portions of cell-nests producing a picture suggestive of adeno-carcinoma; pelvic peritonitis; combined vaginal and abdominal hysterectomy; recovery. Local recurrence. Death from pulmonary haemorrhages four years and two months after operation.

A. R., aged forty-one; white. Admitted August 6, 1894. Complaint: severe pain in the back, most marked at the menstrual period.

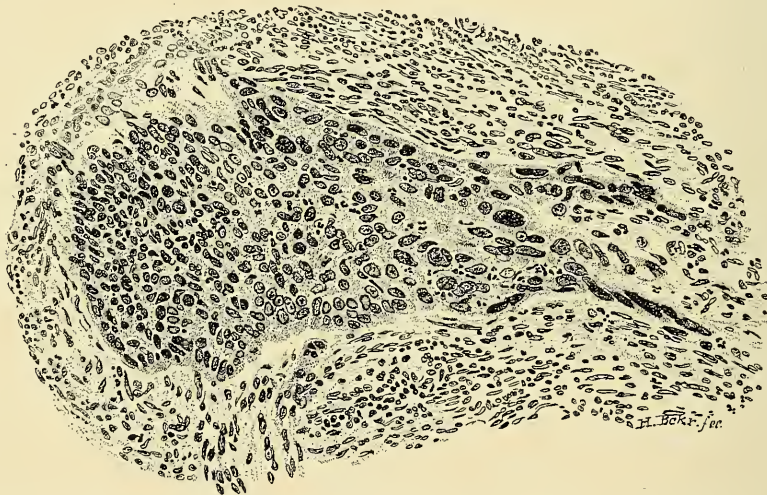


FIG. 61.—A CELL-NEST (FREQUENTLY SPOKEN OF AS THE ALVEOLUS) IN SQUAMOUS-CELL CARCINOMA OF THE CERVIX. (200 diameters.)

Gyn.-Path. No. 411. The cell-nest stands out in sharp contrast to the surrounding stroma. It is irregular in shape, and consists of cells having nuclei varying greatly in character. The majority of the nuclei are oval and vesicular, but some are small and stain deeply. The most important are the very large and deeply staining nuclei. These of themselves are sufficient to render the diagnosis of a malignant growth almost certain. Quite a number of polymorphonuclear leucocytes have already found their way in between the epithelial cells, and are recognised by their horseshoe shape. Surrounding the nest is the cervical tissue, showing slight small-round-cell infiltration.

She has been married twenty-three years, and has had four children and no miscarriages. Her menses began at fifteen, and were always normal; the last period ceased five days before admission. The family history is negative.

The patient's health was good until 1891, when she commenced to suffer with backache, and the menstrual flow became lighter in colour and was at times offensive. On admission she is well nourished, her mucous membranes are of a good colour; the appetite is good, the bowels are constipated. Micturition is frequent, scanty, and burning; locomotion is difficult and painful; the vaginal discharge is grayish red in colour.

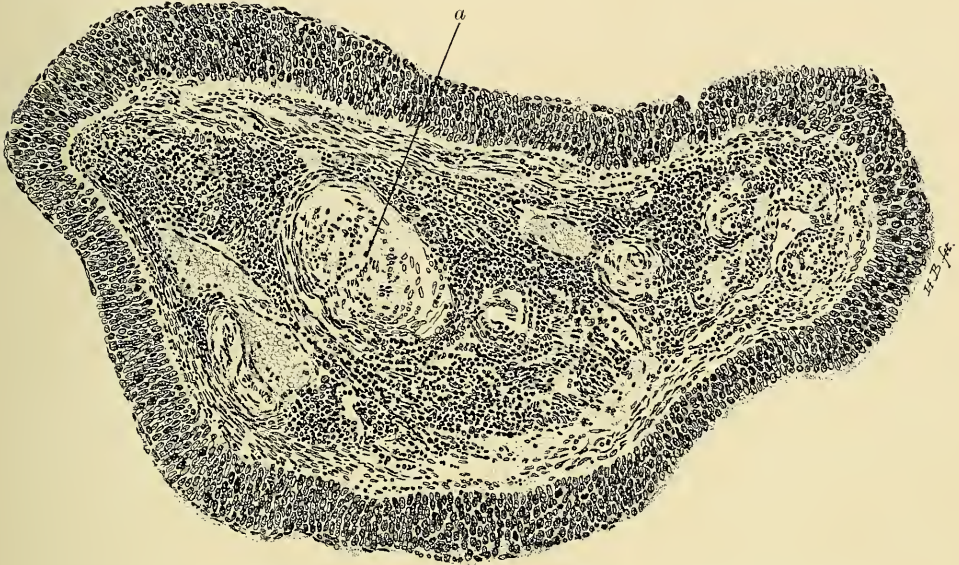


FIG. 62.—CROSS SECTION OF A FINGER-LIKE OUTGROWTH NEAR ITS BASE. (120 diameters.)

Gyn.-Path. No. 411. The stroma is very abundant, and to a great extent consists of small round cells. Along the margin, however, spindle cells are in evidence. Scattered through the stroma are many delicately-walled blood-vessels. The one at *a* contains a thrombus, which is already partly organized. Covering the outer surface of the finger are many layers of squamous epithelium. Note that the nuclei of the epithelial cells are on the whole uniform in size, but that a few are slightly enlarged and stain very deeply. (Compare with Fig. 38 *C*, p. 54.)

Gyn.-Path. No. 411. The specimen consists of small pieces of tissue removed from the cervix. The surface of the mucosa is of a dark colour, but further than this nothing can be made out.

Histological Examination.—The squamous epithelium over the vaginal portion is in places intact; it, however, ends abruptly, and the underlying stroma is everywhere infiltrated by round, oval, finger-shaped, or branching alveoli, which are filled with cells containing large, oval, deeply-staining nuclei of varying sizes. The alveoli stand out prominently, their individual elements staining much more intensely than the surrounding stroma (Fig. 61). A few of the alveoli contain polymorphonuclear leucocytes. The stroma of the cervix shows marked small-round-cell infiltration. The new growth, which is a typical squamous-cell carcinoma, is as yet limited.

Lying on the surface are several cross sections of finger-like outgrowths. Fig. 62 represents one of these, and the section is evidently through the base of the projection, as the stroma is abundant. This stroma consists almost entirely of

small, round cells. It contains many blood-vessels, and at *a* one of these is filled with a thrombus. The outer surface of the finger is covered by many layers of squamous epithelium.

The uterine mucosa is normal.

The scrapings, from the standpoint of technique also, are of considerable interest. They have not been very well hardened, and the central portions of many of the alveoli have accordingly partially or completely dropped out, leaving only one, or possibly two rows of cells around the margin. Such areas at first sight might be taken for adeno-carcinoma. Immediate removal of the uterus is advised.

Diagnosis.—Squamous-cell carcinoma of the cervix.

Operation, August 15th. Combined vaginal and abdominal hysterectomy. The cervix was first ringed. The peritonæum was opened, and the vagina packed with a sponge. The abdomen was then opened, and the operation completed in the usual manner. The patient made a good recovery and left the hospital September 6, 1894.

Gyn.-Path. No. 418. The specimen consists of the uterus, with the intact tubes and ovaries. The uterus measures $10 \times 6 \times 4.5$ centimetres. Its anterior surface is smooth and glistening, but posteriorly it is everywhere covered by delicate vascular adhesions. The cervix is 4 centimetres in diameter. Its lips are slightly scarred, and posteriorly there is some loss of tissue. The anterior lip is eroded over an area of 2.5×3 centimetres; here the tissue is bright red in colour, and in places presents minute elevations with corresponding depressions. The margins of the excavations are sharply defined.* The cervical mucosa in the upper half of the canal is smooth and glistening, but in one or two places its glands reach 2 millimetres in diameter. The uterine walls are 2.2 centimetres in thickness, and the mucosa, which is smooth and glistening, but shows some deep ecchymosis, appears to be 4 millimetres thick.

Both tubes and ovaries are enveloped in numerous adhesions.

Histological Examination.—The squamous epithelium covering the outer portion of the cervix is intact, but on passing inward toward the external os it disappears, and there is loss of tissue. Covering the surface of the excavated area is considerable blood. The underlying stroma contains many nests of cells, which occur as finger-like projections or as round or irregularly oval alveoli. The cells are closely packed together, and contain large oval nuclei. In some portions of the specimen, especially in the vicinity of the external os, the surface epithelium is still preserved, and from it these finger-like projections can be seen extending into the depth. As soon as the epithelial cells commence to penetrate, they take the hæmatoxylin stain with more avidity, and contrast sharply with those on the surface. Along the advancing margin of the growth the cells are much larger, and their protoplasm stains more deeply with eosin. The stroma of the cervix is infiltrated with small round cells. The cervical and uterine mucosæ are normal, and the tubes and ovaries, save for the adhesions on their surfaces, are unaltered.

* When studying the description of the cervix, it must be remembered that pieces of tissue have previously been cut out.

In this case the prognosis is very favourable. The diagnosis of squamous-cell carcinoma is confirmed.

Her son writes me that she died October 15, 1898. The growth had returned, and her death, which was accompanied by "awful agony," was due to hæmorrhages from the lungs. Whether these pulmonary hæmorrhages were caused by metastases or not it is difficult to say. The patient lived four years and two months after operation.

Gyn. No. 3,203

Squamous-cell carcinoma; crater-like excavation of the cervix; uterus twice its normal size; involvement of the left broad ligament; curettage.

E. D., aged fifty-six; white. Admitted November 21, 1894. Complaint: uterine hæmorrhages; bearing-down pain in the back.

The patient has had three children, two of the labours being difficult. The menses ceased two years ago. The family history is negative, and her previous history unimportant.

For several months the patient has had a profuse leucorrhœal discharge, which for at least eight weeks has been of a reddish colour, reminding her of the menstrual flow. For four months she has been troubled with occasional attacks of sharp, shooting pain over the site of the uterus; the pain is worse after exertion, and radiates to the back. The patient is debilitated, the mucous membranes are pale, the tongue is slightly coated and fissured, the appetite is poor, the bowels are constipated, and associated with both micturition and defecation is a bearing-down pain. The discharge at present is thin, watery, irritating, and very offensive.

On vaginal examination the posterior cervical lip presents a crater-like excavation, which extends almost through to the rectum. The anterior lip is only slightly involved. The body of the uterus is twice its normal size, and there is extensive infiltration of the left broad ligament.

Operation. Dilatation and curettement. The cervix was dilated and a great deal of broken-down tissue removed by means of a large curette. The patient was discharged December 5th, somewhat improved.

Gyn.-Path. No. 529. The specimen consists of uterine scrapings.

HISTOLOGICAL EXAMINATION.—The surface of the scrapings is covered by many layers of squamous epithelium, which in numerous places is seen dipping down into the underlying tissue. Throughout the stroma everywhere are irregular alveoli filled with these cells. The cells have large, oval, round, or irregular, vesicular nuclei; many of them contain nuclear figures and sometimes the cell is seen to have an exceedingly large, deeply staining nucleus. Here and there is a mass of protoplasm containing five or six nuclei. There is considerable karyorrhexis, and at one point is a mass of protoplasm, staining intensely with eosin, and containing an irregular, very deeply staining nucleus. The stroma between the alveoli shows a moderate amount of small-round-cell infiltration.

Diagnosis.—Squamous-cell carcinoma of the cervix.

Gyn. No. 3,265

Squamous-cell carcinoma of the cervix; curettage.

M. H., aged forty; white. Admitted January 7, 1895. Complaint: uterine hæmorrhages.

The patient has been married eighteen years, has had six normal labours and two miscarriages. Her menses commenced about the twelfth year, and were regular until September, 1894. Her family history is good, and she has always been well until the present illness.

Last September her menstrual period was prolonged, and several physicians, who examined her at that time, advised operation. There has been slight hæmorrhage ever since. Until a week ago this was clotted, but is now fluid; she has no pain whatever. The patient is anæmic; the appetite is good; the bowels are constipated; she has not lost in weight.

The uterus was curetted, and the patient left the hospital.

Gyn.-Path. No. 567. The specimen consists of a great deal of crumbly material, occurring in clumps, at least 1 centimetre in diameter.

Histological Examination.—Almost the entire specimen is made up of alveoli, which branch in all directions and communicate with one another, forming an irregular network. These alveoli are completely filled with cells having large, oval, vesicular nuclei. Here and there the cells contain nuclear figures, and in a few places are masses of protoplasm containing bunches of at least ten nuclei. The outer row of cells of the alveoli tend to be cylindrical, reminding one of the deepest layer of the skin. In a few places polymorphonuclear leucocytes have wandered in between the individual epithelial cells. The stroma is very scanty, and consists of spindle-shaped cells.

Diagnosis.—Squamous-cell carcinoma of the cervix.

Gyn. No. 3,525

M. H., aged forty-six; white. Admitted May 20, 1895. Complaint: uterine hæmorrhages.

The patient has been married twenty-three years and has had six children. In the last labour, thirteen years ago, version had to be performed. Her family history is good.

In July, 1894, her menses, which had previously been regular, became very profuse, the flow lasting for three weeks. In December she had a copious hæmorrhage, and since then has had an almost constant bloody discharge. This is at times pale in colour and frequently has an offensive odour. The patient is emaciated and anæmic; her appetite is poor; defecation at times causes pain throughout the abdomen. On vaginal examination the cervix was found to be so far involved by the carcinomatous process that the uterus could not be removed. The patient was curetted May 24th and discharged June 3d.

Gyn.-Path. No. 730. The specimen consists of a considerable amount of scrapings.

Histological Examination.—The epithelium covering the vaginal portion of the cervix has disappeared and the cervical stroma is infiltrated by alveoli, which are elongated, oval, or branching, and in some places round. The

alveoli are completely filled with cells, the nuclei of which are large, oval, and vesicular. Here and there between the cells is a small round cell or a polymorphonuclear leucocyte. The stroma of the tissue shows considerable small-round-cell infiltration, and in some portions contains cervical glands which are normal.

Diagnosis.—Squamous-cell carcinoma of the cervix.

Gyn. No. 2,963

Squamous-cell carcinoma of the cervix; filling-up of alveoli by polymorphonuclear leucocytes and detritus (Fig. 63); curettage.

M. D., aged forty-five; white. Admitted August 5, 1894. Complaint: dull aching pain throughout the vagina.

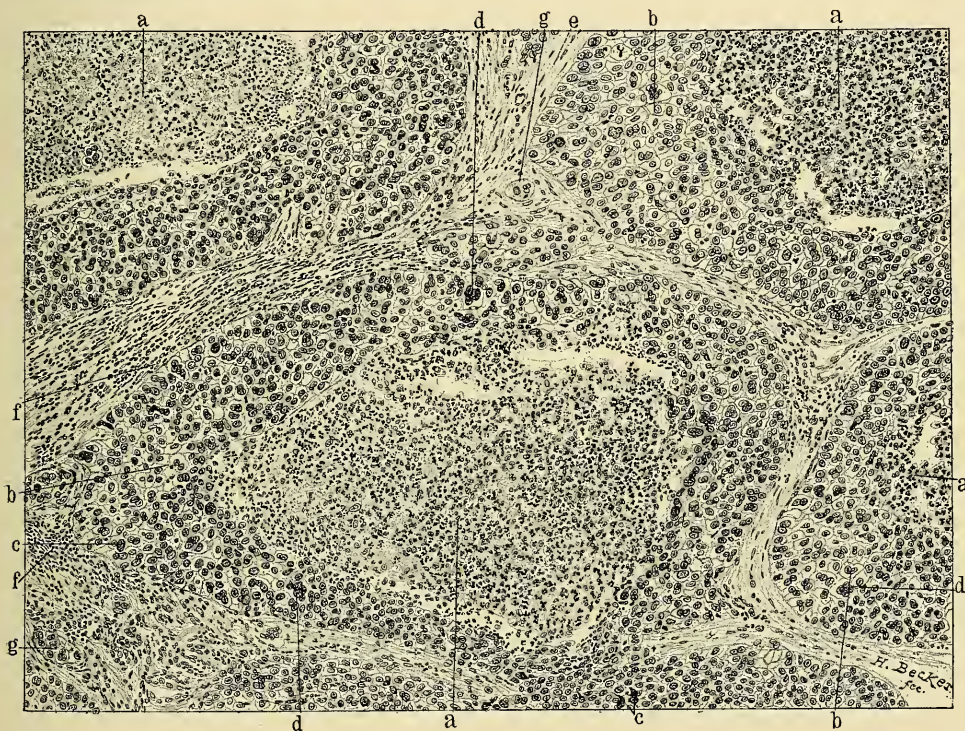


FIG. 63.—SQUAMOUS-CELL CARCINOMA OF THE CERVIX SHOWING FILLING UP OF THE DEPRESSIONS ON THE SURFACE WITH PUS CELLS AND DETRITUS. (100 DIAMETERS.)

Gyn.-Path. No. 415. At first sight *a* might seem to indicate the centres of cell-nests, as they are completely filled with polymorphonuclear leucocytes, exfoliated epithelium, and detritus. But on examination of the many layers of squamous cells lining these cavities, practically no leucocytes are found between them, as would be the case had pus cells wandered out from the vessels of the stroma; in fact, they could not reach the centre without first passing between the cells. This section has been taken from near the surface, which was in places uneven. The spaces correspond to the depressions between the elevations, and the pus from the surface has trickled down into them—an entirely different picture from that presented in Fig. 116. The epithelial cells are, on the whole, very uniform in size. *b* indicates the typical squamous cells. At *c* the nuclei are enlarged and stain deeply. At *d* giant cells are seen. The protoplasm is increased, and the nuclei, four or five in number, are bunched in the centres of the cells. *e* is the stroma, and shows moderate small-cell infiltration, as indicated by *f*. At *g* small isolated clusters of carcinomatous cells are present in the stroma.

The patient has had four normal labours; her menses, which were regular, ceased three months ago. Her father and her brother died of tuberculosis. She has been healthy up to the present illness.

Four months ago she first complained of a tired, languid feeling, but was entirely free from pain. One month later there was a free uterine hæmorrhage; this may, however, have been the menstrual flow, as it came on at the regular time. On admission, the patient is fairly well nourished; the mucous membranes are pale; the appetite is good; the bowels are regular. She has a reddish-white vaginal discharge.

The uterus was curetted on August 11th, and the patient left the hospital August 17, 1894.

Gyn.-Path. No. 415. The specimen consists of 300 cubic centimetres of tissue removed from the uterus by the curette. The largest piece, measuring 4 centimetres in diameter and 1 millimetre in thickness, is very friable, presents a granular appearance, and in places contains small foci of pus. The smaller pieces are much firmer.

Histological Examination.—The greater part of the tissue is composed of oval, round, or irregular alveoli, filled with large cells, whose nuclei are oval and vesicular. A good many of the cells contain nuclear figures; here and there is a very large cell with from eight to ten nuclei bunched in its centre. In some of the alveoli polymorphonuclear leucocytes are wandering in between the epithelial cells, and the centres of some are completely filled by them (Fig. 63). The stroma, on the whole, is scanty in amount, and consists of cells having spindle-shaped nuclei. It shows considerable small-round-cell infiltration, and at some points has been invaded by polymorphonuclear leucocytes. The entire picture is one of advanced squamous-cell carcinoma.

Diagnosis.—Squamous-cell carcinoma of the cervix.

SCIRRHOUS SQUAMOUS-CELL CARCINOMA OF THE CERVIX

Occasionally squamous-cell carcinoma of the cervix is found where the stroma is far in excess of the epithelial elements. In these cases the cell-nests are very small, look flattened, and are surrounded by but little protoplasm (Fig. 64). Examination of such areas would not enable one to make a very satisfactory diagnosis, but in other portions of the specimen typical areas of squamous-cell carcinoma are to be seen, the excess of stroma not being uniform. In many places it looks just as if the stroma had gotten the upper hand and was squeezing the epithelial cells out of existence.

We have had only two cases presenting this picture. Wagner, in his long series of carcinomata, limited almost entirely to the cervix, only saw one case which was of this character.

Gyn. No. 4,038

Scirrhous squamous-cell carcinoma of the cervix (Fig. 64). Complete destruction of the posterior lip; the anterior lip is a mere shell. Apparently slight involvement of the

broad ligaments; attempted vaginal hysterectomy. Profuse hæmorrhage from the uterine arteries; 18 centimetres of the bougie in the left ureter broken off and not removed on account of patient's weakness. Death on the sixth day.

S., aged fifty-seven; white. Admitted December 25, 1895. Complaint: uterine hæmorrhage; offensive vaginal discharge.

The patient has been married twenty-four years, and has had ten children. All of the labours were difficult, but non-instrumental. One of her sisters died of carcinoma of the stomach, otherwise she has a good family history. The patient had purpura hæmorrhagica when twelve years of age, and malaria twenty-seven years ago. Her menses ceased at fifty-two. One year ago the patient had a bloody discharge which lasted for several hours. Of late there have been numerous slight hæmorrhages, and in the intervals a scant watery discharge. The patient at times experiences slight backache, and tenderness in the abdomen. She weighs two hundred and twenty-five pounds. The mucous membranes are of good colour; the appetite is good; the bowels are slightly constipated. The vaginal outlet is relaxed, and the cervix almost completely destroyed by a new growth, the posterior lip having entirely disappeared, the anterior remaining as a mere shell. The broad ligaments are apparently only slightly involved.

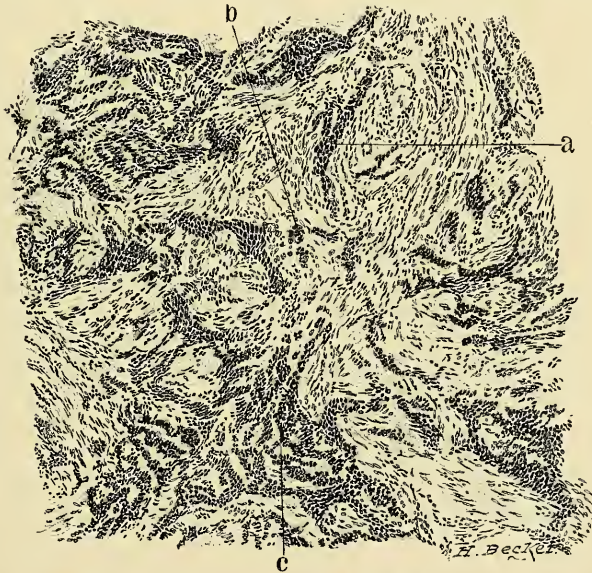


FIG. 64.—SCIRRHOUS SQUAMOUS-CELL CARCINOMA OF THE CERVIX. (130 diameters.)

The dark areas represent the masses of epithelial cells. At *a* a cell-nest is seen on longitudinal section. *b* indicates a similar cell-prolongation on cross section. At *c* the masses of cells wind in and out in all directions. The stroma is very abundant, and consists of cells having spindle-shaped nuclei.

Operation, December 27th. Attempted vaginal hysterectomy. On account of the excessively thick abdominal walls Dr. Kelly did not consider abdominal hysterectomy possible. The patient was placed in the dorsal position, and futile attempts were made to introduce bougies into the ureters. The patient having been placed in the knee-breast position, the bladder distended immediately, and

the bougies were introduced without difficulty. The cervix was curetted and three traction sutures placed in the crater-like lips. The disease had advanced farther than was anticipated, and in trying to place ligatures in the right broad ligament, about four out of every five would cut through the tissues.

The right uterine artery bled profusely and was with difficulty controlled by artery forceps; a similar experience was met with on the left side. By this time the patient had lost about 800 cubic centimetres of blood, and the operation was abandoned, as she was growing weak. It was necessary to leave six artery forceps in the vagina. The right ureteral bougie was removed, but the left had been broken, probably by forceps; part was removed, but 17.5 centimetres still remained in the ureter. The patient's condition did not warrant the abdominal operation necessary for the removal of the bougie, and she was returned to the ward. A few hours after operation there was great restlessness, and a continual desire to urinate. On the second day the urine was dark brownish-red in colour; the patient was constantly moaning, and complained of pain in the lower part of the abdomen and back. On the fourth day she vomited a good deal, and toward evening some slight abdominal distention was noticed. Within the following twenty-four hours this distention increased, the patient became more restless, and complained of a burning sensation throughout the abdomen. She died January 2, 1896.

Gyn.-Path. No. 1,022. The specimen consists of a moderate amount of uterine scrapings.

HISTOLOGICAL EXAMINATION.—The greater part of the tissue examined consists of single or double rows of cells, which have oval, vesicular nuclei. These rows are separated from one another by masses of connective tissue very poor in nuclei. Some of the cells of the new growth are distorted and have become smaller. It looks as if the connective tissue in contracting was crushing out and destroying the cells of the new growth (Fig. 64). In other portions of the specimen the typical picture of squamous-cell carcinoma is seen.

Diagnosis.—Scirrhus squamous-cell carcinoma of the cervix.

CARCINOMATOUS MASSES IN LYMPH SPACES

It is generally asserted that carcinomata are transmitted to distant points by way of the lymph channels, and one is always on the lookout for the presence of masses of cancer cells in the lymphatic system. Frequently it is possible to detect small masses of tumour cells lying in spaces apparently lined by one layer of spindle-shaped cells, but one is often at a loss to tell whether these masses are actually in lymph spaces or have just forced their way into the tissue, and during the process of hardening have contracted, leaving a space between them and the surrounding tissue. Where a mass of cells is lying in a large space beside one or two blood-vessels, and when this space is lined by one layer of endothelium and contains many mononuclear leucocytes, the appearance is due to an

extension of the neoplasm into a lymph channel. Such a picture is represented in Fig. 65 (Case 2,452).

In Fig. 65, *a* is the cross section of a flattened artery; *b*, the lymph space, has for its walls merely a layer of endothelium and the neighbouring connective tissue. Clustered round its margins are many mononuclear leucocytes and a few cells containing oval or round, vesicular nuclei. Occupying the greater part of the cavity, and apparently lying free, is a mass of cancer cells. This mass, as demonstrated on serial section, was attached to the vessel wall and projected into the lumen. The section we are examining was made near the tip of the projection; the nuclei are fairly uniform in size, and vesicular. A few stain deeply, and some contain nuclear figures. Note the spindle shape of the nuclei along the margin. Several vacuoles are scattered throughout the cell-nests; some contain epithelial cells; others pus cells.

Seelig also gives a good illustration of a similar condition.

Gyn. No. 2,452

Squamous-cell carcinoma of the cervix, with extension to the posterior vaginal vault; group of carcinomatous cells in a lymph channel (Fig. 65); vaginal hysterectomy; severe haemorrhage from the right uterine artery only controlled by leaving on the artery forceps; recovery; patient well six years after operation.

M. D., aged sixty; white. Admitted December 9, 1893. Complaint: continuous offensive vaginal discharge.

The patient has been married thirty-seven years, and has had ten children; all the labours were normal. Her menses ceased at fifty. Her family history is unimportant, and she has always been healthy.

In April last the patient noticed a bloody vaginal discharge, which has persisted until the present time. This is non-irritating, and has never had an offensive odour. She is well nourished, feels perfectly well, and has come to the hospital solely on account of the discharge. On vaginal examination the outlet is moderately relaxed, the cervix is crater-like, the excavation being most marked on the posterior lip. The uterus seems to be retroflexed; no thickening can be detected in the broad ligaments.

Operation, December 11, 1893. Vaginal hysterectomy.

Before commencing the operation a rubber bougie was passed into the left ureter. The uterus was removed in the usual manner. Bleeding was so profuse from the right broad ligament that about a dozen artery forceps had to be left in the vagina. On catheterizing the patient immediately after the operation, the urine was blood-stained. As the disease was far advanced, it appeared doubtful whether all the carcinomatous tissues had been removed. At the end of forty-eight hours the forceps were carefully withdrawn; no bleeding followed, and the gauze pack was changed.

The patient was discharged December 24th, as she was especially anxious to get home, and as she promised to be back in a week to have the stitches removed.

Gyn.-Path. No. 109. The specimen consists of the uterus to which both tubes are attached. The uterus measures $8 \times 5 \times 3$ centimetres. The cervix is converted into a spongy, worm-eaten, friable mass. The growth, which involves it, extends upward to the internal os and outward into the posterior vaginal wall

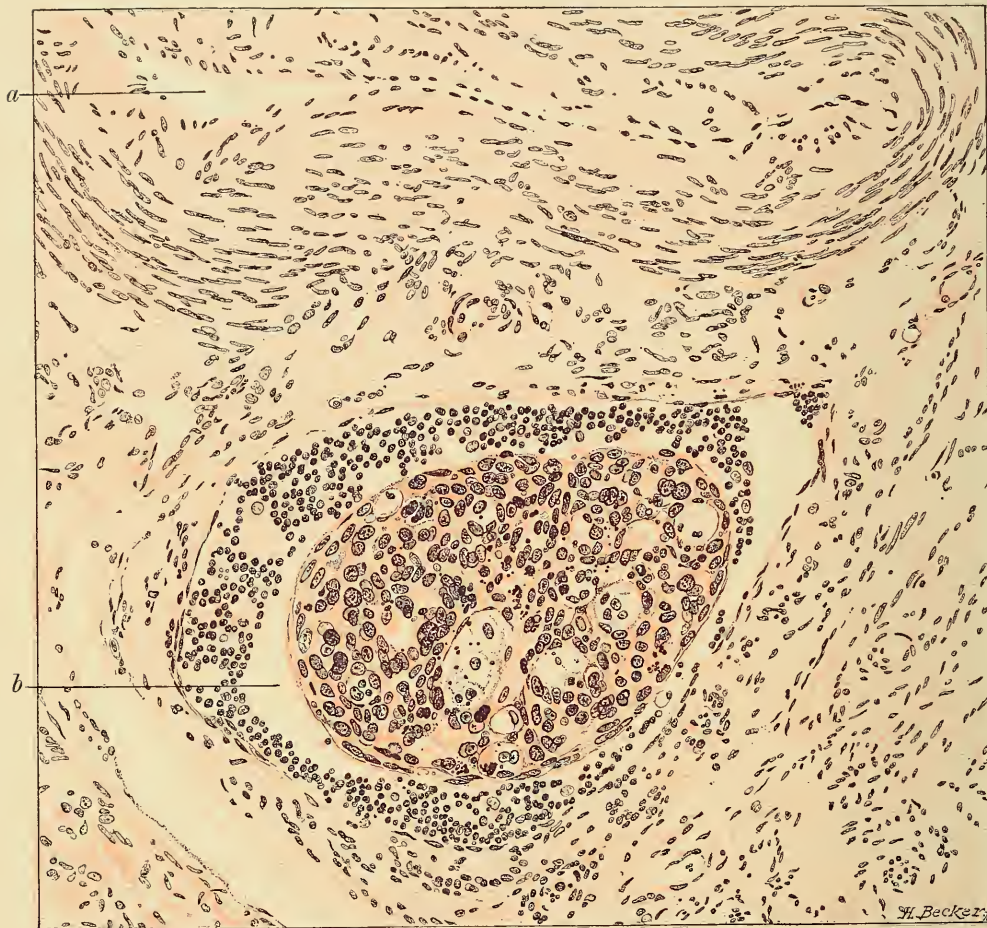


FIG. 65.—A MASS OF CANCER CELLS LYING IN A LYMPH VESSEL. (365 diameters.)

Gyn.-Path. No. 109. *a* is a cross section of a flattened artery; *b*, of a lymph vessel. Clinging to the wall of the latter are many mononuclear leucocytes, intermingled with which are a few cells with vesicular nuclei. The greater part of the vessel, however, is occupied by a mass of cancer cells. This mass is apparently lying free in the lymph channel, but serial sections revealed the fact that it was firmly attached to the wall at one point and that it projected into the lumen. Thus, this section is from the neighbourhood of the tip of the projection. The nuclei in the outer portion of the growth are elongate-oval or spindle-shaped, but the majority are oval and vesicular. Some contain nuclear figures; others stain deeply. There are a few clear spaces or vacuoles, some containing polymorphonuclear leucocytes; in others are cancer cells. The lymph vessel has simply a layer of endothelial cells separating it from the stroma of the broad ligament.

for a distance of 4 centimetres. The uterine walls average 2 centimetres in thickness. The mucous membrane is smooth and glistening, but presents numerous patches of ecchymosis. Both tubes are of normal appearance, save for the presence of a few small cysts just beneath their peritoneal coverings.

Histological Examination.—The cervix is everywhere invaded by alveoli, which are round, irregular, or elongate. Many of them are branching, and form a regular network. All of these alveoli are completely filled with cells which have oval, vesicular nuclei. In the superficial portions of the cervix the cells in the centres of the alveoli appear to be somewhat swollen, and stand out prominently, their protoplasm staining bright red with eosin. Here and there a nucleus stains deeply, and may be two or three times as large as those surrounding it. In a few alveoli are plaques of protoplasm containing nine or ten nuclei bunched in the centre. Occasionally one sees a single cell, the protoplasm of which stains intensely with hæmatoxylin, which brings it out sharply. The growth extends laterally to the broad ligaments, and there is hardly the slightest possibility that it has been entirely removed.

The growth on the vaginal vault is identical with that seen in the cervix, and at two points a very interesting picture is presented. In close proximity to two blood-vessels are oval masses of tumour cells lying in distinct vessels which they only partly fill; the vessel walls consist of one layer of endothelium (Fig. 65), and lying between the wall and the carcinomatous mass, in each instance, are myriads of small round cells, which morphologically are identical with mononuclear leucocytes. There is little doubt but that these are lymph spaces which have been invaded by the carcinomatous process.

The cervical glands have almost entirely disappeared. Some of those that remain appear normal, but in others the cells of the new growth are seen projecting into their cavities, partially obliterating them. The uterine mucosa has an intact surface epithelium. The glands are abundant, and are small and round on cross section; many of them, however, are dilated; their epithelium has become cuboidal or almost flat, and they are partially or almost completely filled with hyaline droplets. The prognosis in this case is exceptionally unfavourable.

Diagnosis.—Squamous-cell carcinoma of the cervix, with involvement of the vaginal mucosa.

January 1, 1900. This patient lives within a few doors of the hospital and has been under constant observation. She is at present perfectly well and actively engaged in household duties. It is over six years since the uterus was removed.

CONDITION OF THE UTERINE MUCOSA IN SQUAMOUS-CELL CARCINOMA OF THE CERVIX

J. Elischer,* in 1891, reported eight cases of carcinoma of the cervix in which a careful microscopic examination of the uterine mucosa was made. In four he found an interstitial endometritis † with atrophy, and in one, glandular endome-

* Elischer, J. *Ueber Veränderungen der Schleimhaut des Uterus bei Carcinom der Portio Vaginalis. Zeitschr. f. Geburtsh. u. Gynäk.*, 1891. Bd. xxii, S. 15.

† The term endometritis is often used loosely, the operator saying that the patient has endometritis without making a histological examination of the tissue. Again, gland hypertrophy and atrophy are frequently spoken of as endometritis. We reserve the term endometritis for those

tritis. Our results do not correspond with his, and we firmly believe that in the early stages of the carcinoma, unless there has been a previous inflammation or a blocking up of the cervix causing pyometra, the mucosa is perfectly smooth, and on microscopical examination presents nothing abnormal.

Of course there are occasional exceptions, as seen in Case 6,492, Plate II. Here the mucosa in the body of the uterus was yellowish in colour, translucent, and gathered up into several longitudinal elevations, with intervening depressions—in other words, it had formed polypi. The surface, although wavy, was intact and smooth. Microscopical examination showed an intact surface epithelium, slight gland hypertrophy, and a stroma, with some small-round-cell infiltration in the superficial portions. In this case the small round cells between the epithelial cells lining the tube were indicative of some previous tubal trouble.

The muscle of the body is as a rule invaded by the carcinoma much earlier than the mucosa. The latter is at times, however, studded with large or small carcinomatous masses, usually recognisable with the naked eye.

J. Pfannenstiel* reports the case of a woman, fifty-three years of age, who had had six children and two miscarriages. The cervix was the seat of a squamous-cell carcinoma, while situated in the body of the uterus was a nodule about 2.5 centimetres in diameter. This, on histological examination, was identical with the cervical tumour, and Pfannenstiel naturally concluded that the growth was primary in the cervix.

Benckiser† reports a most interesting case of squamous-cell carcinoma of the cervix in a woman fifty-nine years old. The disease was of considerable duration, and a portion of the body of the uterus had already been destroyed. The mucous membrane of the body was everywhere intact, but showed numerous slight elevations and depressions. These were from 1 to 2 millimetres in diameter, whitish in appearance, and had a finely granular look. On histological examination the epithelium over them was found to be several layers in thickness. The glands were diminished in number, and at one point a polyp situated in the body was almost entirely involved by the carcinoma. Benckiser, in commenting on the case, speaks particularly of the fact that the growth in the body was limited to the superficial portions of the mucosa. In Case 4,489 of our series a somewhat similar extension upward of the squamous epithelium was noted, and, as will be seen from Fig. 296 (p. 584), the inner part of the cervix and lower half of the body were involved by a carcinoma, which was of the squamous-cell type. The disease had also extended to the fundus at *b*. At point *I* the mucosa appears to be smooth, offering nothing unusual; but a section at this point, as represented by Fig. 298 (p. 586), shows that the surface epithelium has been

cases showing evidence of distinct inflammatory change, namely, in the acute stage, the presence of polymorphonuclear leucocytes; in the chronic stage, of small round cells or new connective-tissue formation.

* Pfannenstiel, J. *Beitrag zur pathologischen Anatomie und Histogenese des Uteruskrebses auf Grund eines weiteren Falles von doppeltem Carcinom an der Gebärmutter. Centralbl. f. Gynäk.*, 1893, Bd. xvii, S. 414.

† Benckiser, A. *Ueber eine seltene Art von secundärem Carcinom des Uteruskörpers. Zeitschr. f. Geburtsh. u. Gynäk.*, 1891, Bd. xxii, S. 337.

replaced by many layers of squamous epithelium, *a*. A papilla projects from the stroma at *c*, and a similar one is seen just to the left. The uterine glands, *d* and *d'*, are normal and contain desquamated epithelium. The stroma of the mucosa shows considerable round-cell infiltration at *e*; *f* is a rather poorly circumscribed lymph nodule. In this case the squamous cells of the tumour have extended upward along the surface, showing little tendency to invade the mucosa or muscle.

PYOMETRA OCCURRING IN CONJUNCTION WITH SQUAMOUS-CELL CARCINOMA OF THE CERVIX

Occasionally, where the growth does not break down rapidly and occupies nearly the entire circumference of the cervix, the canal becomes obliterated and the uterine secretion is dammed back. A portion, at least, of the carcinomatous tissue is usually invaded by organisms, and the dammed-up secretion becomes infected; polymorphonuclear leucocytes wander out, and a regular pus cavity soon results. The size of these cavities will of course depend upon the duration of the closure, and also upon the amount of the exudate. The cavity may be only slightly dilated (Fig. 67, p. 117, and Fig. 87, p. 167), or be sufficiently large to contain 500 to 600 cubic centimetres of fluid. On palpating the inner surface of such a cavity, the lower surface corresponding to the internal os is rough, nodular, and friable, while the uterine walls show a varying degree of thinness according to the amount of distention. The inner surface is smooth, and reminds one of the inner surface of an abscess sac (Fig. 126, p. 243). On opening such a cavity, pus escapes; this is at times grayish-white or yellow, or may be tinged with blood. Gas not infrequently develops (Fig. 66, p. 116), and often comes out with a distinct gush when the uterus is opened.

On microscopical examination, if the process be recent and little pressure has been exerted, one still expects to find the surface epithelium intact, but the mucosa is freely infiltrated by polymorphonuclear leucocytes. In later stages the inner surface may consist of granulation tissue, all the epithelium having disappeared (Fig. 126).

Bürckle* reports 227 cases of carcinoma of the uterus, in which pyometra was present seventeen times. Statistics on this point are, however, of little value, as in some groups of cases the disease is far advanced, while in others it is detected earlier.

In Case 3,114 (Fig. 67, p. 117) both lips of the cervix are involved, the carcinoma having encroached upon the body; as a result of the occlusion of the canal there has been a slight damming back of the secretions.

Fig. 87 (p. 167) represents the condition found where the pyometra is of moderate size. The cervix and lower part of the body have been occupied with a new growth. The cervical canal is not patulous, and hence the secretions have collected in the uterine cavity. Anteriorly the cervical growth has invaded the bladder. It will be interesting to follow this case and study the conditions that were found at autopsy several years after this sketch was made.

* Bürckle, J. *Ueber das Verhalten der Operirten nach vaginaler Totalexstirpation des carcinomatösen Uterus. Inaug.-Diss.*, Berlin, 1893.

Fig. 126 (p. 243) shows very clearly what the inner surface of Fig. 161 (p. 313) would have looked like had the pus been removed. In Fig. 126 (p. 243) the cervix was roughened and hard, and the uterus was the size of that of a three-months' pregnancy, and had an elastic feel. The cervix was curetted, and suddenly 520

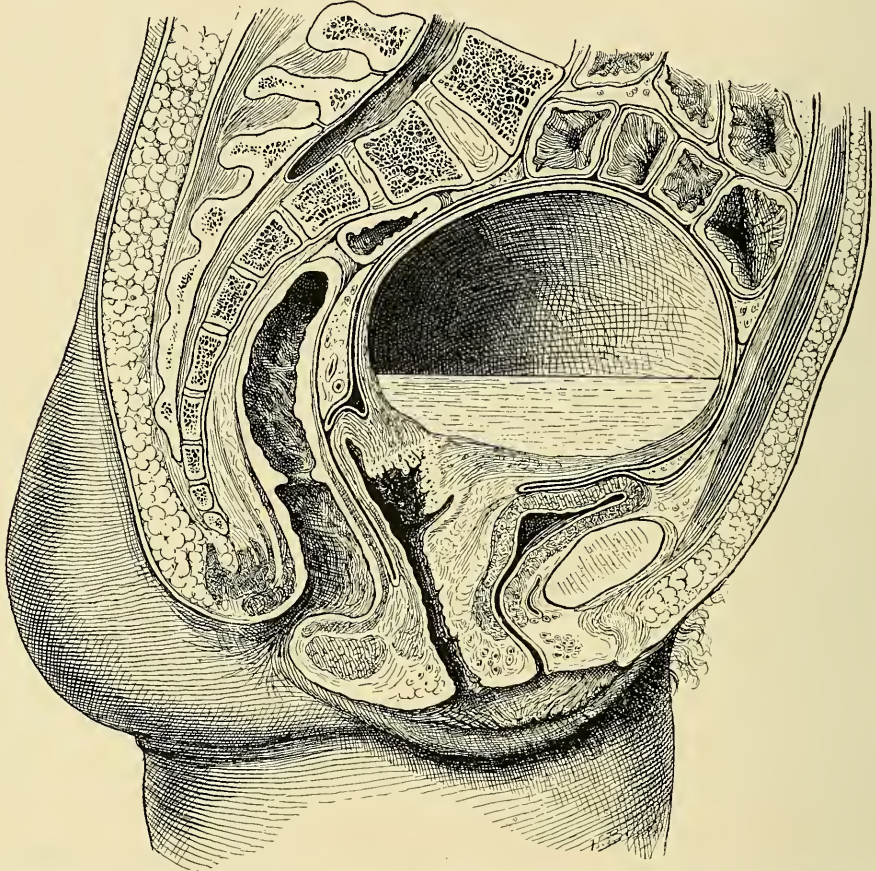


FIG. 66.—PYOMETRA AND PHYSOMETRA DUE TO CLOSURE OF THE CERVICAL CANAL IN SQUAMOUS-CELL CARCINOMA OF THE CERVIX.

The cervix has been involved to a limited extent. The cervical canal is obliterated. The uterine cavity is greatly distended, and for about one third of its capacity filled with pus. The upper two thirds contained gas; otherwise the whole organ would not have been so large. Note the extreme thinness of the uterine walls. (After H. A. KELLY.)

cubic centimetres of thick, yellowish pus, of a peculiar sickening, sweetish odour, escaped from the cavity. Note the rapidity with which the finger-like processes have grown over the curetted area in less than two weeks. *a* and *a'* indicate little abscesses in the uterine walls. The mucosa presents an undulating appearance, consisting of small dome-like elevations in the neighbourhood of the fundus. On histological examination the endometrium presented the picture of typical granulation tissue.

Fig. 66 represents the uterus partially filled with pus, while the remaining portion is occupied by gas—a pyophysometra.

EXAMPLE OF PYOMETRA

Gyn. No. 3,114

Squamous-cell carcinoma, the cervix being a mere shell; involvement of the left broad ligament; commencing pyometra (Fig. 67); vaginal and abdominal hysterectomy incomplete, due to tearing off of the cervix; passive involvement of the uterine glands by the squamous-cell growth (Fig. 69); giant cells (Fig. 68).

The growth reappeared two months after the patient's discharge. Death occurred one month later.

E. E., aged fifty; white. Admitted October 16, 1894. Complaint: uterine hæmorrhages.

The patient has been married thirty-three years, and has had seven children and one miscarriage. At the time of the miscarriage some of the membranes

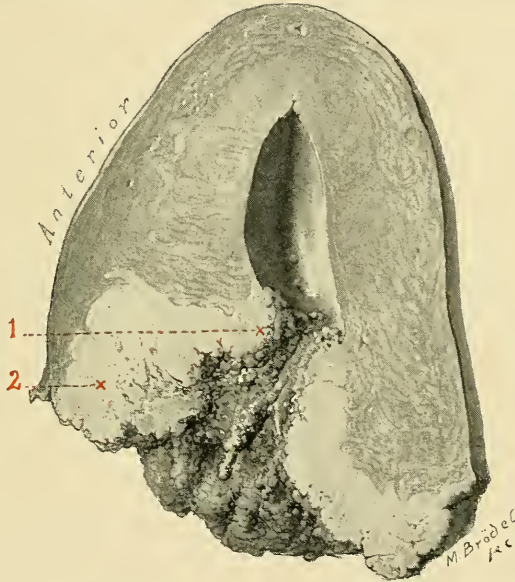


FIG. 67.—SQUAMOUS-CELL CARCINOMA OF THE CERVIX WITH COMMENCING PYOMETRA. (Natural size.)

The lower part of the cervix tore off during the removal of the uterus; hence only its upper part, together with the body of the uterus, are seen. The lower part of the specimen presents a necrotic surface, but near the uterine cavity small elevations are seen springing from the growth. The cervical canal was blocked by the carcinoma, and a pyometra had gradually developed. The line of demarcation between the carcinoma and the muscle is sharply defined. Anteriorly and posteriorly the carcinoma extends practically to the peritoneal surfaces. Fig. 69 is taken at 1; Fig. 68 at 2.

were retained, and she had to remain in bed five or six weeks. Her menses up to the time of the miscarriage had been normal, but, after that time, became somewhat irregular. They ceased when she was thirty-eight.

Her father died probably of carcinoma of the stomach. The patient had yellow fever in 1877, otherwise she has always been well.

On January 18, 1894, she had a severe uterine hæmorrhage, and continued to lose blood for about three months. Soon after the bleeding commenced the patient experienced a burning, gnawing pain in the upper part of the vagina. In July she saw a surgeon, who diagnosticated carcinoma of the uterus, but refused to operate, considering the disease too far advanced. The hæmorrhages have continued ever since.

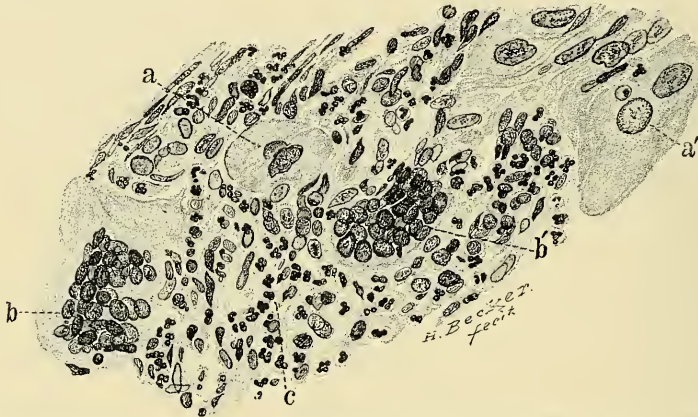


FIG. 68.—GIANT CELLS OCCURRING IN SQUAMOUS-CELL CARCINOMA OF THE CERVIX. (420 diameters.)

Gyn.-Path. No. 481. The section is taken from Fig. 67 at 2. *a* is a large cancer cell lying free in the stroma, and containing two nuclei, one of which is irregular. *a'* is a somewhat larger cancer cell. The giant cell (*b*) consists of a large plaque of protoplasm, containing over thirty oval nuclei bunched in its centre. These stain somewhat deeply. *b'* is a similar giant cell. Some of its nuclei stain intensely. *c* indicates the polymorphonuclear leucocytes scattered through the stroma.

On admission, the patient is stout; the lips and mucous membranes are very pale; the appetite is good; the bowels are very constipated. When the patient holds her water for a considerable time, she has some difficulty in voiding it. Apart from the hæmorrhages there is no vaginal discharge.

Operation, October 18th. Vaginal and abdominal hysterectomy (incomplete). The cervix was converted into a mere shell, and the disease had extended to the left side. The cervix was cauterized and ringed; the abdomen was then opened, and, as the walls were very thick, the peritoneum was temporarily sewed to the skin to facilitate inspection of the pelvic viscera. The vessels of both broad ligaments were controlled, and an attempt was made to raise the uterus; but the cervix broke off just below the vesical junction, and no alternative was left but to amputate at this point. The infiltrated crater-like cervix was then curetted with the finger, and turned into the vagina by means of three traction ligatures. The peritoneum from the anterior wall was then united with that of the posterior wall, leaving a clean pelvic cavity. A drain was placed in the lower angle of the abdominal incision and the wound closed.

The abdominal incision broke down, discharging thick, creamy pus, which, as the cultures showed later, contained *Staphylococcus pyogenes aureus*. On November 9th the cervical stitches were removed and the cervix was cauterized. In the right vaginal fornix was a deep excavated bleeding area, which was thoroughly cauterized. A number of suspicious points in the left fornix were treated in a like manner.

The patient was discharged November 17th. She was rather weak, and an unfavourable prognosis was given.

Gyn.-Path. No. 481. The specimen consists of part of the uterus to which the tubes and ovaries are attached (Fig. 67). During operation the greatly enlarged cervix, which presented a crater-like appearance, was torn off. The portion of uterus obtained is 6 centimetres long, 6.5 broad, and 9 centimetres in its antero-posterior diameter. Anteriorly it is smooth and glistening, but posteriorly it is covered by a few delicate adhesions. The under cut surface, which corresponds to the point where the cervix was torn off, is 5 centimetres in diame-

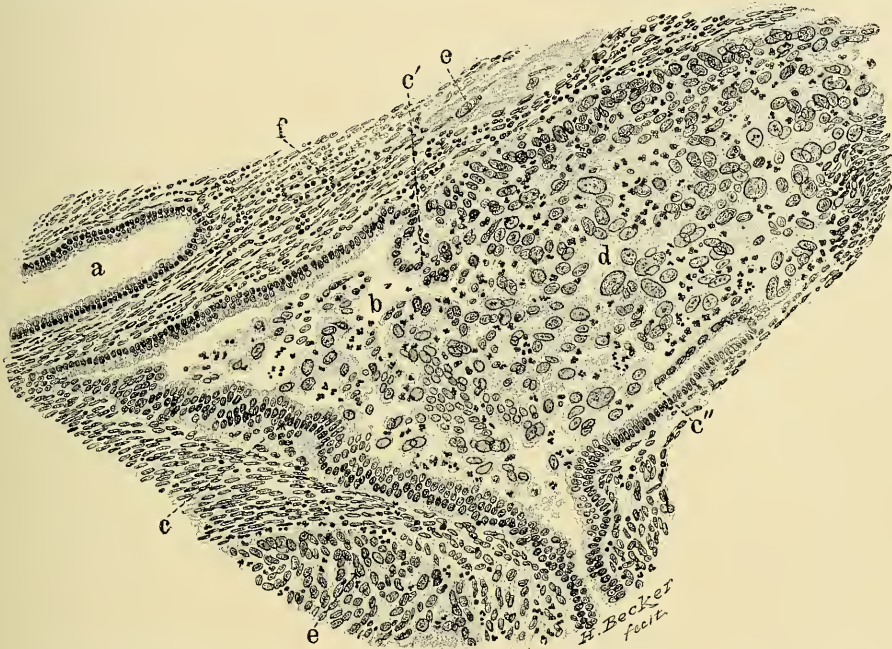

FIG. 69.—PASSIVE INVOLVEMENT OF A UTERINE GLAND IN SQUAMOUS-CELL CARCINOMA OF THE CERVIX. (180 diameters.)

Gyn.-Path. No. 481. The section is taken from Fig. 67 at point 1. The uterine gland (*b*) has been invaded by the nest of squamous cells (*d*). The nuclei in these cells vary greatly in size, some being fully four times as large as others in their vicinity. The majority are vesicular, and none stain very deeply. Scattered everywhere between the cells are the horseshoe-shaped nuclei of the pus cells. The margins of the cell-nests are in part sharply defined, but at *c'* and *c''* the cancer has broken into the gland, pushing the epithelium before it. Note the atrophy of the gland epithelium at these points, and especially at *c''*, showing beyond a doubt that it is in no way stimulated to activity by the growth of the squamous cells. The gland is almost filled by cancer cells. At *c* the gland epithelium appears thickened, owing to the obliquity of the section. *a* is a normal gland. *e* indicates other nests of cancer cells. *f*, small round cells scattered throughout the stroma.

ter; it presents a friable appearance, and has little finger-like masses springing from it. The uterine wall is invaded by the new growth to within 4 centimetres of the fundus. The advancing margin of the growth is yellowish-white and waxy; it presents a sharply defined margin, and stands out distinctly from the uterine muscle. Anteriorly and on the left side the growth has extended out to the cut surface, and evidently involves the broad ligament. The diseased tissue

in the anterior wall projects backward into the uterine cavity, and almost, if not completely, blocks the canal. This was a favourable site for the development of pyometra. The uterine cavity above the growth is considerably dilated, being 3.5 centimetres long and 1.7 centimetres in diameter. Its mucous membrane is exceedingly thin, and yellowish-white in colour; here and there one of its glands is slightly dilated.

The appendages are free from adhesions, and are senile.

Histological Examination.—The surface of the eroded cervix shows some necrosis, and the underlying muscle is everywhere infiltrated by elongate alveoli, cut either longitudinally or transversely. In many places they communicate with one another. They are composed of cells whose nuclei are large, oval, and stain faintly. In some, nuclear figures can be made out; occasionally a very large mass of protoplasm, with a correspondingly large nucleus, is seen. Some of these masses of protoplasm contain eight to thirty or more nuclei (Fig. 68). In many places the cells of the new growth are separated from one another by polymorphonuclear leucocytes, and the central portions of some of the alveoli are necrotic. The new growth extends to the cut surface laterally, and has evidently not been entirely removed. The stroma between the alveoli shows considerable small-round-cell infiltration. This is most marked along the advancing margin of the growth, which is sharply defined. The picture presented is one of typical squamous-cell carcinoma. The uterine mucosa shows considerable small-round-cell infiltration, and some of its glands are dilated. In the body of the uterus, carcinomatous masses are seen invading the glands (Fig. 69), but the latter take no part whatever in the process, their cylindrical cells remaining unaltered or showing some atrophy. In the vicinity of the internal os the uterine wall is to some extent invaded by the new growth.

Both tubes and ovaries are normal.

Diagnosis.—Squamous-cell carcinoma of the cervix.

January 10, 1900.—Dr. J. H. Wolff, of Sylvania, N. C., writes me that the growth reappeared two months after the patient left the hospital, and that she died one month later.

SQUAMOUS-CELL CARCINOMA OF THE CERVIX ASSOCIATED WITH PROLAPSUS

John Williams,* of London, in his work on Cancer of the Uterus, published in 1888, reports the case of a woman, aged sixty-seven, who for thirteen years had a prolapsed uterus. A small squamous-cell carcinoma developed on the cervix and adjacent vaginal mucosa; amputation was performed.

G. Pomtow † reports a case occurring in the practice of Olshausen, and reviews the literature. He was able to collect twenty-nine cases; in all but one the prolapse preceded the carcinoma.

* Williams, J. *On Cancer of the Uterus, being the Harveian Lectures for 1886.* 119 pp., 18 pl., 8vo. London, 1888, p. 19.

† Pomtow, G. *Carcinoma uteri prolapsi. Inaug.-Diss.,* Berlin, 1893.

Kurtz,* in 1894, published a case of von Saxinger's, the patient being fifty-eight years of age. The cervix was amputated, and recovery followed.

It will be seen that the coincident appearance of the two conditions may be regarded as accidental. It is hardly probable that prolapsus in itself predisposes to the development of carcinoma.

Should cancer develop when such a condition is present, the exposure will render an early diagnosis possible; furthermore, on account of the lax condition of the parts, hysterectomy can be much more easily performed.

SIMULTANEOUS APPEARANCE OF SQUAMOUS-CELL CARCINOMA OF THE CERVIX AND TUBERCULOSIS OF THE UTERUS

Wagner,† in his exhaustive work on carcinoma, speaking of the relation of tuberculosis of the lungs to carcinoma of the uterus, says that in at least half of the cases there was tuberculosis, either recent or a rekindling of an old process. In the majority of our cases the uterus was either removed or curetted, and the patient returned home; hence the condition of the lungs at a later period could not be ascertained.

In the accompanying case the uterus was removed on account of the carcinoma, and, as will be seen, there was a general tubercular peritonitis, the uterus and appendages being covered by a mantle of small tubercles.

Gyn. No. 3,666

Squamous-cell carcinoma of the cervix (Fig. 70); glandular uterine polyp; tuberculous peritonitis; abdominal hysterectomy; recovery. Local recurrence. Death two years and seven months after operation.

S. D., aged sixty-two; white. Admitted July 20, 1895. Complaint: uterine hæmorrhages.

The patient has been married thirty-seven years; has had four children, no miscarriages. Menstruation ceased at fifty-five. The family history is unimportant.

Four months ago, without any apparent cause, she had a free uterine bleeding, and since then any exertion, as, for instance, walking, or lifting moderately heavy weights, has been sufficient to bring on hæmorrhage. For a month she has been compelled to remain in bed on account of the free oozing. When the hæmorrhages first commenced, she experienced considerable pain; latterly, however, there has been none. On admission, the patient says she has become a great deal thinner, and is much weaker than heretofore. She is very anæmic; the appetite is poor; the bowels are regular. The lungs are negative.

The vaginal outlet is relaxed, and the entire cervix is involved by a new growth which projects slightly into the vagina and bleeds on the slightest touch.

* Kurtz, W. *Ueber Carcinom am prolabierten Uterus. Inaug.-Diss.*, Tübingen, 1894.

† Wagner, Ernst. *Der Gebärmutterkrebs, eine pathologisch-anatomische Monographie*, vi, 169 pp., 2 Taf., 8vo. Leipzig, 1858.

The uterus is normal in size, and is movable. The broad ligaments appear to be only slightly involved.

On July 22d the cervix was thoroughly curetted.

Operation, July 24th. Abdominal hysterectomy. The peritoneum was everywhere studded with small tubercles, and the abdominal cavity contained a moderate amount of straw-coloured fluid. The uterus and its appendages were removed in the usual way, and the abdominal cavity was closed. On August 2d it was noted that the patient had made steady improvement in her general condition.

She made a good recovery, and was discharged August 19, 1895.

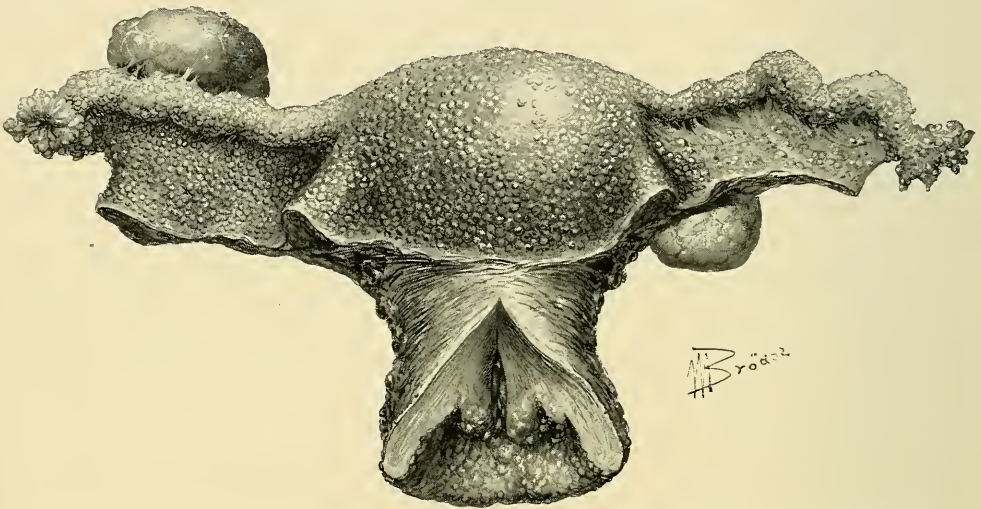


FIG. 70.—TUBERCULOUS PERITONITIS ASSOCIATED WITH SQUAMOUS-CELL CARCINOMA OF THE CERVIX.
($\frac{2}{3}$ natural size.)

The cervix presents an excavated appearance due to the recent curetting. Its general outline is, however, still preserved. Covering the outer surfaces of the uterus, tubes, broad and round ligaments, is a mantle of tubercles, averaging 1 millimetre in diameter. The right ovary is slightly adherent to the tube; otherwise both ovaries appear to be normal. (After H. A. KELLY.)

Gyn.-Path. No. 813. The specimen comprises the uterus with its intact appendages. The uterus measures $8 \times 6 \times 3.5$ centimetres (Fig. 70). The anterior and posterior surfaces are covered by a thin membrane, which laterally extends out over the broad ligaments, tubes and ovaries. This membrane shows myriads of small, yellowish-white, translucent nodules averaging 1 millimetre in diameter, scattered throughout it. Over the fundus they are scanty, in other places very abundant. The membrane is less than 1 millimetre in thickness, and can be stripped off from the surface of the uterus with difficulty. The cervix is 4.5 centimetres in diameter, and its lips vary from .3 to 1.5 centimetres in thickness. The external os is represented by a crater-like opening 3 centimetres in diameter, and the walls of this cavity present a worm-eaten appearance. On section, the cervical lips are of a pearly-white colour, and are exceedingly firm, having the consistence of gristle. There is no distinct line of advancement to the growth. Near the internal os the mucosa is still intact, and some of its glands reach 4

millimetres in diameter. The uterine walls vary from 1.5 to 2 centimetres in thickness; the cavity is 4 centimetres in length. Its mucosa is whitish-yellow, and is apparently not more than 1 millimetre thick. It contains numerous minute translucent cysts. Springing from the left side of the uterine cavity, about its middle, is a pedunculated polyp 5 centimetres long, varying from .2 to 1 centimetre in diameter. It diminishes in size as it passes downward, and near the internal os is constricted. Below this it again broadens out, and terminates in a club-like extremity, 6 millimetres in diameter. The polyp near its base is pinkish-white, smooth, and glistening, but from the internal os downward it is hæmorrhagic. Throughout its entire extent are small cysts.

The right tube and ovary are covered by numerous tubercles, and the ovary contains a cyst 2 centimetres in diameter. The walls of this vary from 1 to 2 millimetres in thickness; the inner surface is smooth and glistening. The left tube and ovary, apart from being covered by tubercles, present nothing of importance.

HISTOLOGICAL EXAMINATION.—The cervix is everywhere infiltrated by branching, oblong, or oval alveoli, completely filled with cells. These cells are closely packed together, and have somewhat deeply staining, oval, vesicular nuclei. In some of the alveoli the central portion stains very poorly; the cells are arranged concentrically, and are somewhat laminated. These areas resemble epithelial pearls. The central portions of other alveoli contain cavities, in which a few desquamated fatty epithelial cells and some small round cells are visible. The growth has extended laterally to the cut surface and has not been entirely removed; upward it has advanced to within a short distance of the internal os. It is a squamous-cell carcinoma.

The cervical glands are abundant, and, apart from occasional dilatation, are normal. The uterine mucosa has an intact surface epithelium. The majority of the glands are slightly dilated, and some of them reach a diameter of at least 1.5 millimetres. The epithelium of these dilated glands is either cuboidal or flat. The stroma of the mucosa shows considerable œdema. The uterine polyp consists of mucosa, and, as was noted macroscopically, many of its glands are dilated.

The mantle covering the surface of the uterus, involving the surface of the appendages and extending everywhere over the broad ligament, is composed of typical tubercles. The tuberculous process in the tube is limited almost entirely to the peritoneal covering and fimbriæ, sections through various portions of the tube showing little, if any, evidence of tubercles in the mucosa. The small cyst of the right ovary is lined by cylindrical ciliated epithelium.

DIAGNOSIS.—Squamous-cell carcinoma of the cervix. Dilatation of cervical and uterine glands. Cystic glandular uterine polyp. Tuberculous peritonitis, involving surface of uterus, tubes, and ovaries. Commencing tuberculosis of both tubes. A small cyst of the right ovary.

Her son writes me that the hæmorrhages returned, and that the patient died January 25, 1898, about two years and seven months after operation. There was evidently a return of the growth.

CHAPTER V

SQUAMOUS-CELL CARCINOMA OF THE CERVIX (*continued*). EXTENSION TO ADJOINING STRUCTURES. CONDITION OF THE TUBES AND OVARIES. INVOLVEMENT OF THE LYMPH GLANDS. AUTOPSY FINDINGS

1. Involvement of the broad ligaments.
2. Extension to the blood-vessels.
3. Extension to the vaginal vault.
4. Reports of cases illustrating extension of squamous-cell carcinoma to the vaginal vault.
5. Extension of squamous-cell carcinoma of the cervix to the bladder.
6. Cases of carcinoma showing extensive bladder involvement.
7. Extension of squamous-cell carcinoma of the cervix to the rectum.
8. Cases illustrating rectal involvement.
9. Involvement of the urethra in squamous-cell carcinoma of the cervix.
10. Squamous-cell carcinoma of the cervix with extension to the pelvic bones.
11. Condition of the tubes and ovaries in squamous-cell carcinoma of the cervix.
12. A case showing carcinomatous infiltration of one Fallopian tube.
13. Lymph glands involved in squamous-cell carcinoma of the cervix.
14. Cases illustrating the extension of squamous-cell carcinoma of the cervix to the lymph glands.
15. So-called acute hypertrophy or acute swelling of the lymph glands.
16. General appearance of the body at autopsy in cases of squamous-cell carcinoma of the cervix.
17. Thrombosis of the pelvic veins.
18. Condition of the kidneys in advanced squamous-cell carcinoma of the cervix.
19. Dilatation of the ureters.
20. Carcinoma of the liver secondary to squamous-cell carcinoma of the cervix.
21. Condition of the lungs at autopsy in patients dying of squamous-cell carcinoma of the cervix.

INVOLVEMENT OF THE BROAD LIGAMENTS IN SQUAMOUS-CELL CARCINOMA OF THE CERVIX

THE growth in the cervix, while extending inward, downward, and upward, naturally advances outward, and gradually implicates the broad ligament by continuity. The invasion of the broad ligament, or, more properly speaking, of the peri-uterine tissue, is of great practical importance from a clinical stand-point; if it be much involved the patient is doomed. On examining the uterus in cases in which the process is advanced, the growth may be traced out to the broad ligament attachment; gradually it extends beyond, and gives to the examining finger a hard, board-like sensation. The growth presents the same yellowish-white, waxy appearance as that which characterizes it in the uterus. After a varying length of time the carcinoma reaches the ureters and eventually completely encircles one or both. If the patient live long enough, both broad ligaments show marked thickening due to the new growth, and to the touch have a board-like consistence. When such a condition is present, the uterus is wedged firmly in between masses of the growth and is immobile. Occasionally the carcinomatous process extends along the lymphatics upward and toward the brim

of the pelvis; the growth can then be traced outward as firm cords. Winter and Ruge* mention this in their recent text-book, but only rarely have we seen it extending in such a manner.

Extension of the Carcinoma to the Blood-Vessels.—In the examination of many cases we have only once been able to see the carcinoma growing directly into a blood-vessel. This is shown in Fig. 164 (p. 317).

EXTENSION OF SQUAMOUS-CELL CARCINOMA OF THE CERVIX TO THE VAGINAL WALL

The length of time elapsing between the commencement of the disease and the vaginal involvement will depend upon two factors: (1) the starting point of the growth, whether near the external os or in the vicinity of the vaginal vault, and (2) the rapidity with which it grows. The disease usually involves the entire thickness of the vaginal wall, penetrating the underlying connective tissue as well as appearing on the surface. Along the advancing margin the growth is sharply defined, forms a distinct eminence, and is very hard. The mucosa along the margin looks pale, this appearance being due to the fact that the underlying tissue is usually involved before the surface is affected. Occasionally isolated submucous nodules may be felt and seen at some distance from the primary growth (Plate III); these are probably due to an extension along lymph channels. At times, although rarely, the surface of the vagina is implicated before the deeper tissues are invaded. Seelig,† in nine cases of carcinoma of the cervix, in only one found the growth superficial, the deep tissues not being affected. In our experience the deeper tissues are generally invaded. One case, however, showed a striking example of the superficial involvement, namely, No. 2,415 (Fig. 71, p. 127). In this instance the fine papillary growth had extended directly over the surface of the vagina. There were also several isolated and superficial nodules at some distance from the cervical growth.

W. Thorn‡ reports the following very instructive case: A woman, forty-six years of age, had a carcinoma of the cervix; on the left vaginal wall was a crater-like cavity, which fitted the cervical growth like a cover would a pot. The vaginal mucosa between this ulcerated area and the carcinomatous cervix was normal. The probability is that in this case the growth from the cervix was implanted on the vaginal wall. Two possibilities must, however, not be forgotten: (1) extension from the original growth by way of the lymph channels: (2) the independent and coincident development of a vaginal carcinoma. We have had a precisely similar case in the Johns Hopkins Hospital.

Cases of Squamous-cell Carcinoma of the Cervix with Extension to the Vagina

Gyn. No. 2,415. Squamous-cell carcinoma of the cervix with extension to the vagina (Fig. 71); combined vaginal

* Winter u. Ruge. *Lehrbuch der gynäkologischen Diagnostik*, Leipzig, 1896.

† Seelig, A. *Virchow's Archiv*, 1895, Bd. cxl. S. 80.

‡ Thorn, W. *Zur Infektiosität des Carcinoms*. *Centralbl. f. Gynäk.*, 1894, Bd. xviii, S. 228.

and abdominal hysterectomy with removal of a portion of the vagina; removal of recurrent nodules in the vaginal vault several months later. Death from pneumonia a few weeks after the second operation.

F. M. M., aged forty-eight; white. Admitted November 18, 1893. Patient has had three normal labours. The menses were regular until a year ago, but since that time there have been numerous hæmorrhages. Her family history is unimportant.

During the greater part of the last year the patient has been troubled with uterine hæmorrhages, and has suffered considerable inconvenience from a purulent or watery discharge. For the last month she has experienced a dull pain in the hypogastric region. The patient is well nourished, and, apart from the discharge and moderate pain, appears to be well. The vaginal outlet is somewhat relaxed, the cervix is large, infiltrated, and nodular; it does not, however, show any loss of substance. On the left side of the vaginal vault are three nodules about the size of grains of wheat. Posterior to the cervix are several somewhat larger nodules. The uterus is anteflexed and movable.

Operation. Combined Abdominal and Vaginal Hysterectomy. The greater part of the operation was done from above; only the latter part through the vagina. In controlling the left uterine artery, the ureter was caught in the ligature and constricted, notwithstanding the fact that especial care was taken to avoid it. The ligature was cut and reapplied. After removing the uterus, the upper part of the vagina, which was studded with nodules, was carefully excised. In order to completely control the hæmorrhage, which had been severe, it was necessary to leave several forceps in the vagina. The pelvic cavity was then shut off from the vagina and the abdominal wound closed. After operation, several hæmorrhoids were injected with a strong solution of carbolic acid. The patient made a good recovery, and was discharged December 23rd. She re-entered the hospital July 21, 1894. Up to within a short time of her return she had been feeling perfectly well. On July 25th a portion of the vaginal vault was excised. In one angle of the vault was a soft mass, 2.5×1 centimetres, which proved to be a small abscess. A small carcinomatous nodule, just behind the symphysis, was dissected out, and the free oozing that followed was controlled by a pack. The perinæum was then repaired. The patient was discharged August 4, 1893.

Gyn.-Path. No. 93. The specimen consists of the uterus and its appendages together with a portion of the vaginal wall. The uterus measures $11 \times 6 \times 5$ centimetres (Fig. 71). The cervix as such is not present, but is represented by a cavity, the walls of which present a shaggy appearance. On examining this shaggy material it is found to be composed of delicate finger-like projections which closely resemble placental villi. In a few places there are finger-like projections of tissue, some of which are 1 centimetre in length and about 3 millimetres in diameter. The growth extends laterally almost, if not quite, to the broad ligament. The vaginal mucosa in the vicinity of the uterus is also involved. In some places the invasion has been by continuity, the surface of the mucosa being covered over by a wart-like growth, which on close inspection is seen to be com-

posed of delicate fibrils similar to those found in the cervical growth. At one point in the vaginal mucosa is a circumscribed nodule 9 millimetres in diameter. The uterine walls vary from 2 to 2.5 centimetres in thickness; the mucosa is

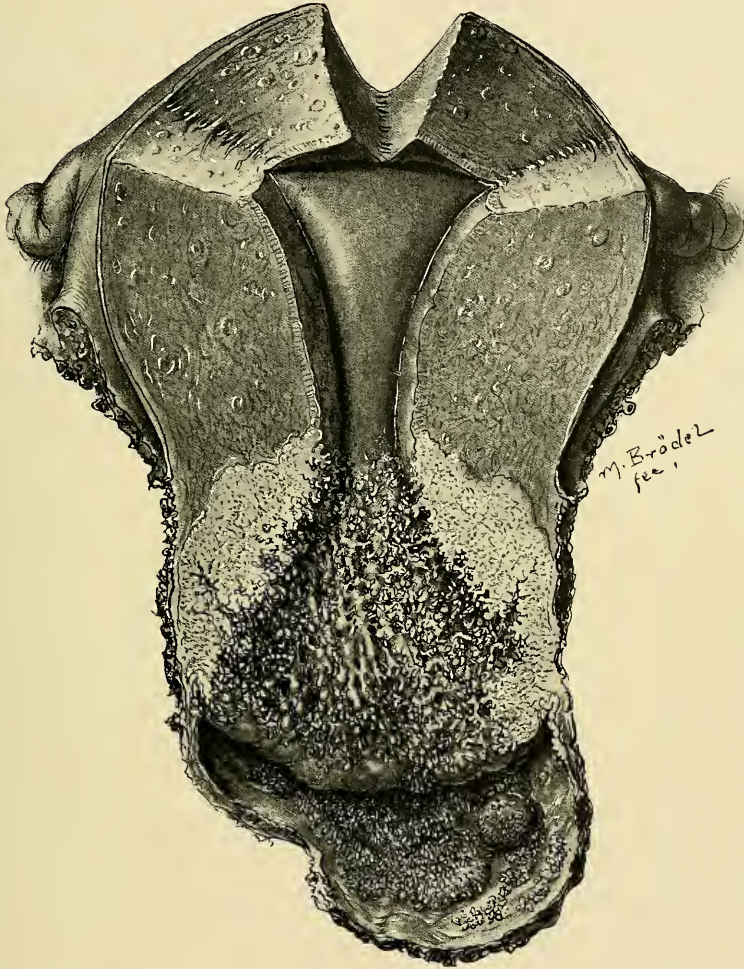

FIG. 71.—SQUAMOUS-CELL CARCINOMA OF THE CERVIX WITH EXTENSION TO THE VAGINA. (Natural size.)

Gyn.-Path. No. 93. The outline of the vaginal portion of the cervix is still intact, but the entire cervix and a small part of the body of the uterus are occupied by a new growth. The surface of this is, for the most part, covered by delicate finger-like processes, but in some places these have coalesced to form smooth longitudinal ridges. Laterally the growth has extended to the cut surface and does not appear to have been entirely removed. Upward, the advancing margin of the growth is irregular and sharply defined, the differentiation in colour between the carcinomatous tissue and the normal muscle being marked. Attached to the lower part of the cervix is a portion of the posterior vaginal vault. In the vicinity of the cervix the vaginal mucosa is covered by little tufts or bunches of finger-like processes, while at a distance from the cervix isolated fingers spring from the mucosa. This early extension to the vagina is most instructive. The growth has evidently followed the surface of the vaginal mucosa, instead of attacking the underlying stroma. The body of the uterus is slightly enlarged. Attached to its sides are the proximal portions of the tubes and round ligaments. The uterine walls are slightly thickened. The mucosa lining the uterine cavity is of the usual thickness, and appears to be perfectly normal.

dark red in colour, but is smooth and glistening. Both tubes and ovaries are apparently normal.

Histological Examination.—Each of the fine finger-like projections of the growth consists of a central blood-vessel, which has a wall composed of one layer of endothelium. External to the vessel are a few small round cells, while in some places is a delicate zone of connective tissue. External to the connective tissue are several layers of cells having large, oval, vesicular nuclei. In a few of these nuclear figures are visible. On examining other portions of the field, the cells of the new growth show no definite arrangement, but form large masses occupying almost the entire field. At these points some of the cells contain deeply staining nuclei, which are about four times the size of the surrounding ones; there are also large masses of protoplasm containing fragments of chromatin. Traversing the cervical tissue everywhere are large and small epithelial nests. Many of these alveoli contain polynuclear leucocytes scattered between the individual cells. The tissue surrounding the alveoli shows marked small-round-cell infiltration.

The vaginal growth is similar to that found in the cervix. Here we have been fortunate in getting longitudinal sections of the small finger-like masses, and find that the zone of large cells surrounding the central blood-vessel is a reduplication of the squamous epithelium.

We do not believe that the growth has been entirely removed; it has probably extended out into the broad ligament, and also appears to have invaded the vaginal vault as far as the cut surface. The cervical glands, where still preserved, are normal. The uterine mucosa has an intact surface epithelium, and its glands present the usual appearance. The superficial portions of the mucosa, however, show considerable hæmorrhage, and the vessels are dilated. The appendages are normal.

Diagnosis.—Squamous-cell carcinoma of the cervix, with extension to the vaginal mucosa.

Gyn. No. 6,388

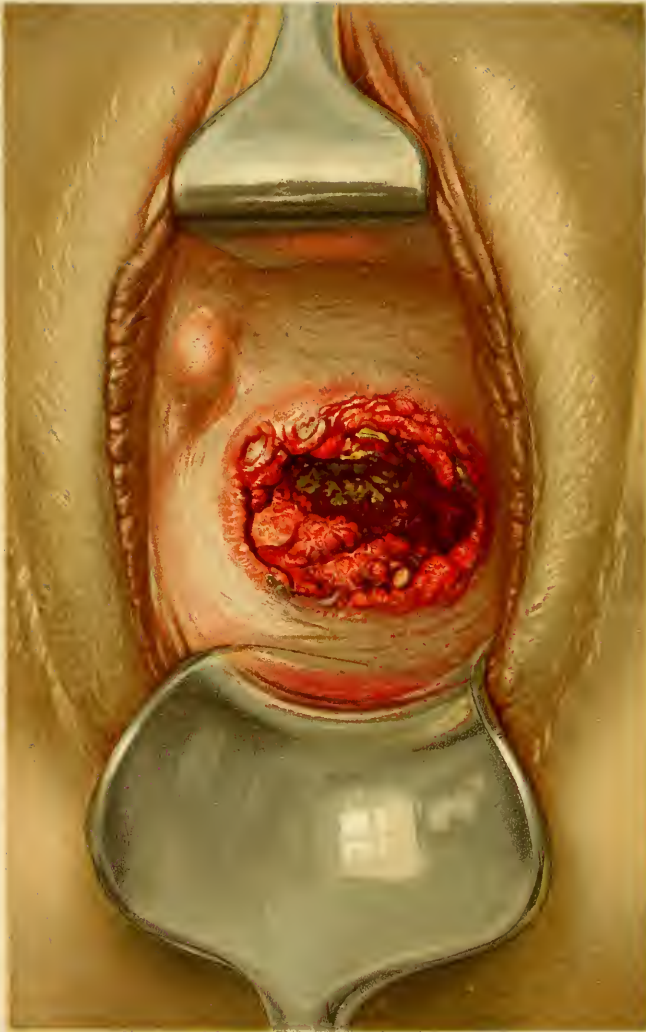Squamous-cell carcinoma of the cervix, with cauliflower outgrowth. Pyometra; curettage and evacuation of pus. Clinical appearances (Plate III). Extension to broad ligaments; secondary nodule in vaginal wall (Plate IV); invasion of the pelvic and retroperitoneal lymph glands; acute general purulent peritonitis; ovarian abscess; double hydronephrosis and hydronephrosis. Death on the fourteenth day.

E. N., aged thirty-nine; coloured. Admitted September 27, 1898.

The patient began to menstruate at fourteen. The flow was regular, lasting three days and accompanied by much pain. Her last period began on September 24th. She has been married nineteen years; has had one child and one miscarriage. Her labour was normal.

When a child she had diphtheria, pneumonia at twenty-five, and pleurisy nine years ago; otherwise she has always been healthy.

Three months ago she was seized with severe pain in the left hip, sharp and cutting in character, but not continuous. For the last month there has been



Advanced squamous-cell carcinoma of the cervix.

conspicuous pain in the lower part of the abdomen. The woman's age is 60 years, and she is very much emaciated, much debilitated, and in fact, has not been able to stand. The present condition is rapid, and it is very probable that the disease is a carcinoma of the cervix. The cervix is very red and swollen, and the surface is very rough and irregular.

The cervix is very much enlarged, and the surface is very rough and irregular. The cervix is very much enlarged, and the surface is very rough and irregular. The cervix is very much enlarged, and the surface is very rough and irregular.

Operation, October 2, 1898. The cervix is very much enlarged, and the surface is very rough and irregular. The cervix is very much enlarged, and the surface is very rough and irregular. The cervix is very much enlarged, and the surface is very rough and irregular.

PLATE III.—SQUAMOUS-CELL CARCINOMA OF THE CERVIX. (Natural size.)

Gyn. No. 6,388. All trace of the cervix is lost, but occupying the vaginal vault is an ulcerated area 3.5 centimetres in breadth and 3 centimetres in its antero-posterior diameter. The surface is composed of small lobulations, varying from 4 to 5 millimetres in diameter; bright red in colour, and clearly defined. Covering the surface in some places are yellowish-green, green, or greenish-brown sloughs. The margin of the ulcerated area is irregular, elevated, and deeply injected. Above and to the right is a smooth nodule beneath the mucous membrane. It appears to be about 1.5 centimetres in diameter, and later examination will undoubtedly show that it is composed of carcinomatous tissue. Plate IV shows the organ removed and opened.

The surface is composed of small lobulations, varying from 4 to 5 millimetres in diameter; bright red in colour, and clearly defined. Covering the surface in some places are yellowish-green, green, or greenish-brown sloughs. The margin of the ulcerated area is irregular, elevated, and deeply injected. Above and to the right is a smooth nodule beneath the mucous membrane. It appears to be about 1.5 centimetres in diameter, and later examination will undoubtedly show that it is composed of carcinomatous tissue. Plate IV shows the organ removed and opened.

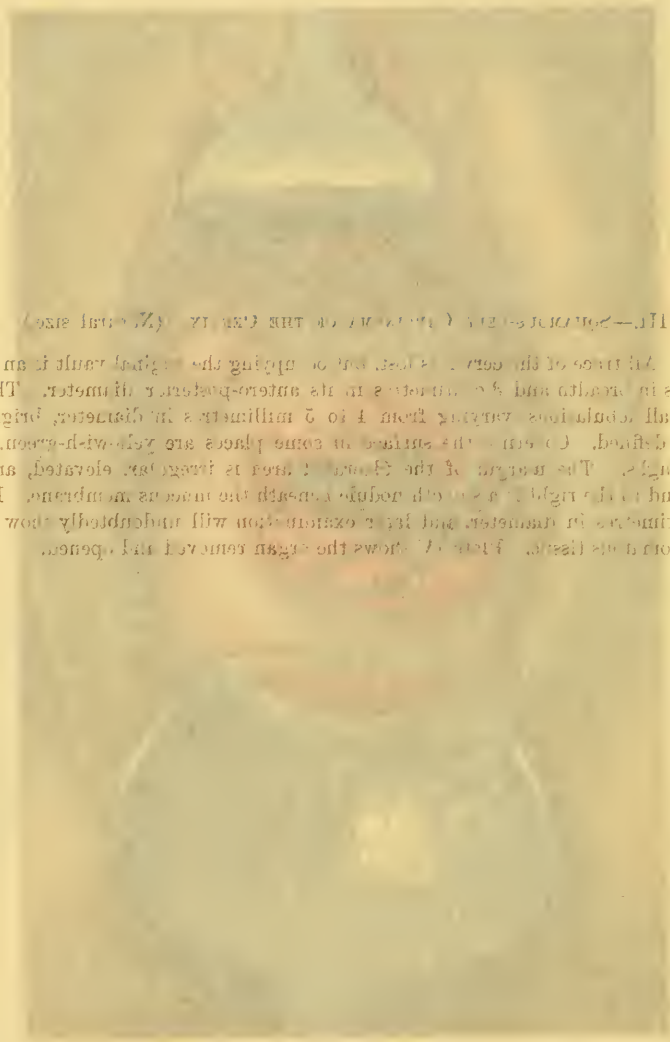


PLATE III.—SPHINCTER (FROM THE CASE OF THE GUY'S HOSPITAL)

GUY'S No. 6888. The base of the organ is 4.5 centimetres in length and 4.0 centimetres in its antero-posterior diameter. The surface is composed of small papillations varying from 1 to 2 millimetres in diameter, bright red in colour, and clearly defined. Between the papillae in some places are yellowish-green, or greenish-brown spots. The margin of the flange is irregularly elevated, and deeply indented. Above and below the right margin a small white, cartilaginous mass is apparent. It appears to be about 1.5 centimetres in diameter, and its excision will undoubtedly show that it is composed of cartilage. Figure 1 shows the organ removed and the general

considerable pain in the lower part of the abdomen. Three weeks ago she first noticed a thin, watery, non-irritating, odourless discharge from the vagina; this has never been blood-tinged. At present the woman is much emaciated; her lips and mucous membranes are pale; the tongue is very red and fissured. Her bowels are regular; micturition is normal. The heart and lungs are negative.

On examination under ether, Dr. Ramsay found the outlet well lifted up. The cervix was the seat of a cauliflower growth measuring about 4 centimetres in diameter. This was very friable, broke down readily under the examining finger, and on the left side extended to the vaginal vault. The uterus was enlarged, elastic, and apparently filled with fluid.

Operation, October 3, 1898. Curettement. The cauliflower growth was broken down with the finger and then curetted away, leaving a large, irregular excavation. As it was impossible to find the cervical canal, the finger having been introduced into the rectum and the thumb into the vagina, while an assistant pushed the uterus downward, scissors were plunged into the uterus at a point where the cervical canal would normally have been found. About three ounces of pus escaped, and the uterus immediately contracted to about one third its former size. The opening was dilated and the cavity packed with gauze. The patient's temperature on September 30th had reached 102.5°; for two days after operation it remained nearly normal, but gradually rose again. On October 7th she complained of abdominal pain, gradually grew weaker, her temperature became subnormal, and death occurred on October 17, 1898.

Gyn.-Path. No. 2,624. The specimen consists of large pieces of tissue curetted from the cervix.

Histological Examination.—Round or oval masses of tissue are found lying perfectly free on the surface of the curettings. In the centre of each of these is a blood-vessel with very delicate walls. Surrounding the vessel are many layers of epithelial cells, fairly uniform in size, and having oval, vesicular nuclei. Here and there is a deeply staining nucleus four or five times the size of surrounding ones. The curettings are composed of solid nests of epithelial cells, separated from one another by a small amount of stroma. The cell-nests vary greatly in size and shape, according to the way in which they have been cut; some appear as small round masses of cells, others form oval or oblong bodies, while many show marked branching. Occasionally a mass of epithelial cells is so large that under the low power it occupies fully half the field. The epithelial cells forming the cell-nests are polygonal in shape, and have oval or slightly irregular, vesicular nuclei. These nuclei are, relatively speaking, uniform in size, but occasionally a cell is met with containing two or three nuclei bunched in its centre. A few very large cells are visible, showing karyorrhexis, numerous nuclear figures representing the different stages being seen. The cells forming the outermost layer of the nests tend to become cuboidal, and their nuclei stain more deeply. Occasionally small round cells have wandered in between the individual epithelial cells of the nests, but the specimen is remarkable for the slight amount of breaking-down. Along one margin polymorphonuclear leucocytes are wandering in between the epithelial cells. The stroma of the tissue, as before mentioned, is scant. It consists of spindle-shaped connective-tissue cells loosely arranged. In places it shows slight polymorphonuclear and small-

round-cell infiltration. At one point along the margin of the specimen, surrounded by cell-nests, are several perfectly normal cervical glands. From the above description the *diagnosis* of squamous-cell carcinoma is readily made.

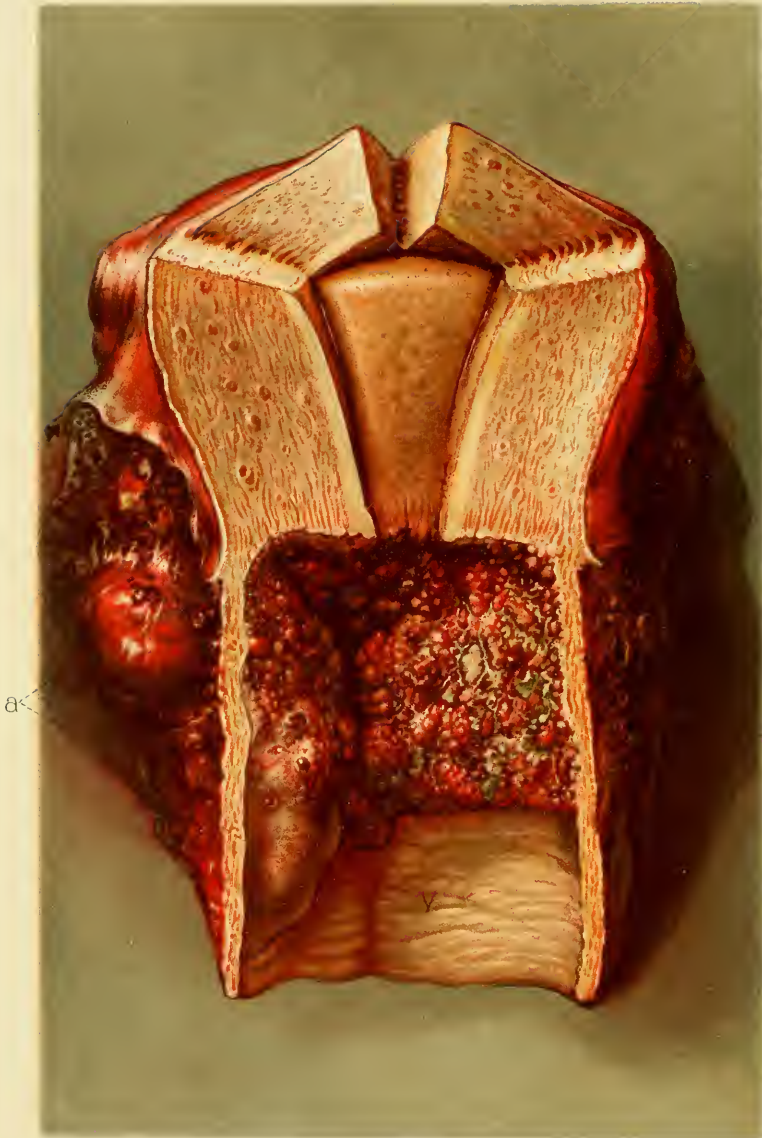
Autopsy No. 1,171. October 17, 1898. Anatomical diagnosis: Squamous-cell carcinoma of cervix uteri; extension to the broad ligaments; invasion of the lymph glands; acute general purulent peritonitis; ovarian abscess; hydro-ureter; hydronephrosis.

The body is moderately well developed, but emaciated. The left leg is œdematous. Subcutaneous fat is almost absent; the muscle is very thin. The peritoneal cavity contains several hundred cubic centimetres of pus, and the intestines are congested and lightly adherent to one another. The pelvis is occupied by a large globular mass about the size of an orange. This on incision is found to contain much creamy pus, and appears to be an ovarian abscess. The left side of the pelvis is occupied by a large white tumour mass, moderately firm, but friable. It extends above the crest of the ilium, and is intimately attached to the bone, which is roughened. The pelvic structures were removed *en masse* for further study. The retroperitoneal lymph glands along the abdominal aorta are generally enlarged, but in one only is found a metastatic nodule; this is the size of a pea. One of the pelvic glands is as large as a marble and contains a secondary growth. Both ureters are dilated, more especially the left, and there is a corresponding dilatation of the pelves of the kidneys. The renal capsules peel off readily; the surfaces of the kidneys are pale and mottled, the striæ indistinct, and the glomeruli pale—in other words, there is the general picture of anæmia. The liver, spleen, pancreas, adrenals, bladder, lungs, and heart, offer nothing of interest.

Gyn-Path. No. 2,658. The specimen consists of the pelvic organs. The uterus measures $4 \times 4 \times 3.5$ centimetres. Its surface is smooth. The cervix has been entirely destroyed, and is represented by a crater-like excavation, 4 centimetres in diameter and 3.5 centimetres in depth, lined by a fungating growth which extends to the vaginal vault (Plate IV). The advancing margin of the growth presents a scalloped outline, is slightly raised, and has undermined edges. On examining the ragged surface of the growth more closely, it is found to consist of finger-like, irregularly dome-shaped or ragged excrescences, with corresponding depressions. This tissue is for the most part bright red in colour, but is speckled with fine yellow dots, and in places is necrotic. Upward the growth has extended to the internal os. The uterine cavity measures 3.5 centimetres in breadth at the fundus. Its mucosa is pale, smooth, and averages 2 millimetres in thickness.

The left broad ligament is thickened, nodular, and breaks down easily on the slightest manipulation. On the right side, between the cervix and bladder, is a tumour nodule, 2 centimetres in diameter. It is impossible to describe the tubes and ovaries, as their identity has been lost in the carcinomatous tissue.

Histological Examination.—It is most interesting to note the changes that have taken place along the margins of the crater-like cavity, resulting from the recent curetting. At such points the surface is covered by blood,



Squamous-cell carcinoma of the cervix. Autopsy specimen.

fibrous, small round cells, and polymorphous cellular leucocytes; the capillaries immediately surrounding are so dilated and engorged that the red corpuscles of the blood supply takes up fully one half of the space. In some of the picture in many places is produced, but some of the cells are small. Along the advancing margin of the growth there is a moderate small-round-cell infiltration, but at many points it is entirely wanting. In the portions of the growth the cell proliferation has contracted and become so condensed that the cell-nests contain numerous clear spaces that might very readily be mistaken for glands. This picture is in part evidently due to the dropping out of the partially hemmed epithelium, but the appearances are mainly, it would seem, attributable to post-mortem changes, as some thin sloughs before the tissues were placed in hardening fluid. Sections from one of the lumbar glands show a typical secondary growth with quite marked

PLATE IV.—SQUAMOUS-CELL CARCINOMA OF THE UTERUS. (AUTOPSY SPECIMEN.) (Natural size.)

Autopsy 1,171. In studying this specimen it must be borne in mind that the growth had been curetted away as far as possible just a few days before this drawing was made. The cervix as such is not recognisable, but occupying its position is a growth composed of small elevations, which are oval and smooth, and vary from a pin-head to 3 or 4 millimetres in diameter. Many of them are dark red in colour; others are light red. Covering the surface, in some places, are light- or dark-green sloughs. It will be readily seen that the growth has been thoroughly curetted, as it does not appear to penetrate deeply into the tissue. The point at which it merges into the body of the mucosa of the uterus is, however, well marked. The margin is slightly elevated and bright red in colour, in contrast to the paler appearance of the mucosa. The point of extension along the vaginal vault is sharply defined, the advancing margin being elevated and of a deeper colour. In the right wall of the vagina, and covered over by the mucous membrane, is a nodule fully 2 centimetres in length. This is directly continuous with the growth in the vaginal vault, and with a similar nodule in the right broad ligament. Both nodules are indicated by *a*. The upper part of the body of the uterus is of the normal size. Its muscular walls present the usual appearance, and the mucosa lining the uterine cavity is unaltered. and upper surface of the bladder. Below this point—*b*, over the lower half of the uterus—there is only a moderate amount of connective tissue separating the lower segment of the uterus and the cervix from the muscular coats of the bladder. Thus it is easily seen that before the carcinoma is far advanced, the outer coats of the bladder may be involved (Fig. 80), the process extending precisely in the same manner as in the uterus, and gradually reaching the mucosa, which it for some time pushes before it (Figs. 73 and 80). At this stage it will often be possible to detect these nodules on examination with the cystoscope. They vary from 2 millimetres to 1.5 centimetres or more in diameter, have sharply circumscribed margins, and project from 2 to 8 millimetres, or more, above the surface. They are usually situated near the trigonum. In one case we found a ureter emerging from the centre of a carcinomatous nodule (Figs. 81 and 82). The nodules gradually breaking down a fistulous opening is established between the bladder and vagina—a vesico-vaginal fistula (Figs. 82 and 88). The cystoscope shows the opening to be invariably round, with ragged and irregular margins covered with pus, and frequently with shreds of necrotic material (Fig. 82). Surrounding the opening is the elevated mound of carcinomatous tissue: external to it the mucosa is thinned out, but gradually shades off into normal uncanal membrane.



PLATE IV.—SQUAMOUS-CELL CARCINOMA OF THE UTERUS. Autopsy Specimen. (Natural size).

Autopsy 1171. In studying this specimen it must be borne in mind that the growth had been excised away as far as possible just a few days before this drawing was made. The cervix as such is not recognizable, but occupying its position is a growth composed of small elevations, which are oval and smooth, and vary from a pin-head to 3 or 4 millimetres in diameter. Many of them are dark red in colour; others are light red. Covering the surface in some places are light- or dark-green streaks. It will be readily seen that the growth has been thoroughly cutted, as it does not appear to penetrate deeply into the tissue. The point at which it merges into the body of the mass of the uterus is, however, well marked. The margin is slightly elevated and bright red in colour, in contrast to the paler appearance of the mucosa. The point of extension along the vaginal vault is sharply defined, the advancing margin being elevated and of a deeper colour. In the right wall of the vagina, and covered over by the mucous membrane, is a nodule fully 2 centimetres in length. This is directly continuous with the growth in the vaginal vault and with a similar nodule in the right broad ligament. Both nodules are indicated by a. The upper part of the body of the uterus is of the normal size. Its muscular walls present the usual appearance, and the uterine cavity is unaltered.




PLATE V.—SQUAMOUS-CELL CARCINOMA OF THE UTERUS. Autopsy Specimen. (Natural size).

fibrin, small round cells, and polymorphonuclear leucocytes; the capillaries immediately underlying are so dilated and engorged that the representation of the blood supply takes up fully one half of the field. Apart from this, the picture in many places is practically the same as that offered by the scrapings. Along the advancing margin of the growth there is frequently some small-round-cell infiltration, but at many points it is entirely wanting. In some portions of the growth the cell protoplasm has contracted and become so distorted that the cell-nests contain numerous clear spaces that might very readily be mistaken for glands. This picture is in part evidently due to the dropping out of the partially hornified epithelium, but the appearances are mainly, it would seem, attributable to post-mortem changes, as some time elapsed before the tissues were placed in hardening fluid. Sections from one of the lumbar glands show a typical secondary growth with quite marked kerato-hyaline change of the central cells of the nests.

EXTENSION OF SQUAMOUS-CELL CARCINOMA OF THE CERVIX TO THE BLADDER

Since the carcinomatous process extends in all directions, it must in time involve the bladder. If the growth be situated on the anterior cervical lip we would expect the bladder to be implicated much earlier than when the posterior lip is the starting point. Before considering this question further, it is advisable to study the relation of the uterus, and especially of the cervix, to the bladder.

The uterus is situated directly behind the bladder. Its upper portion is entirely free, but in its lower half it is in close connection with the bladder, especially when the viscus is empty (Figs. 1 and 3, pp. 5 and 7). The peritoneum covering the anterior surface of the uterus is reflected over upon the posterior and upper surface of the bladder. Below this point—that is, over the lower half of the uterus—there is only a moderate amount of connective tissue separating the lower segment of the uterus and the cervix from the muscular coats of the bladder. Thus it is easily seen that before the carcinoma is far advanced, the outer coats of the bladder may be involved (Fig. 83), the process extending precisely in the same manner as in the uterus, and gradually reaching the mucosa, which it for some time pushes before it (Figs. 73 and 80). At this stage it will often be possible to detect these nodules on examination with the cystoscope. They vary from 2 millimetres to 1.5 centimetres or more in diameter, have sharply circumscribed margins, and project from 2 to 8 millimetres, or more, above the surface. They are usually situated near the trigonum. In one case we found a ureter emerging from the centre of a carcinomatous nodule (Figs. 81 and 82). The nodules gradually breaking down, a fistulous opening is established between the bladder and vagina—a vesico-vaginal fistula (Figs. 82 and 88). The cystoscope shows the opening to be invariably round, with ragged and irregular margins covered with pus, and frequently with shreds of necrotic material (Fig. 82). Surrounding the opening is the elevated mound of carcinomatous tissue; external to it the mucosa is thinned out, but gradually shades off into normal mucous membrane.

From Wagner* we learn that the part of the bladder mucosa not involved by the carcinoma may show a catarrhal, croupous, or diphtheric inflammation. The bladder, when a fistulous opening is present, is usually contracted, and may not be larger than a walnut. The contents differ according to the condition of the mucosa, the ureters, and kidneys, so that it may be normal, purulent, or bloody. In Case XX, reported by Wagner, the pelvis of the left kidney was the size of a hen's egg; the bladder was distended with a watery fluid, and contained a coagulum as large as a man's fist. In this case there was a carcinoma of the anterior cervical lip, and 1 centimetre within the inner urethral orifice, a small ulcer. A second and a most instructive case is the one of Credé, also incorporated in Wagner's monograph. The upper part of the vagina and lower part of the uterus were occupied by an advanced carcinomatous growth. The bladder had been perforated, a fistulous opening, 2 millimetres in diameter, communicating with the vagina. Both the ulcerated carcinomatous area and the vaginal mucosa were covered with a uric-acid calcified deposit.

In the advanced stages subperitoneal carcinomatous nodules are at times seen. These vary considerably in size, being, as a rule, not more than 1 centimetre in diameter (Fig. 73, p. 135).

As might be supposed, in cases coming to operation, no vesico-vaginal fistula would be found; hence we have few to report. At autopsies, however, bladder involvement is frequent. R. Williams, † in 1896, reported the findings in seventy-eight autopsies; fifty-six showed extension of the carcinoma to the bladder, while in twenty-nine cases a vesico-vaginal fistula had formed.

Cases of Squamous-cell Carcinoma of the Cervix showing Extensive Bladder Involvement

Gyn. No. 5,092. Umbilical hernia; squamous-cell carcinoma of the cervix (Fig. 72) extending to the vagina, body of the uterus, bladder (Fig. 73), rectum, broad ligaments, tubes and ovaries (Fig. 78), and forming metastases in the pelvic, inguinal, retroperitoneal, mesenteric and bronchial glands; also in the lungs, pleurae, and on the serosa of the intestines. Interstitial and subperitoneal uterine myomata; double hydroureter; anaemia of all the organs; focal fatty degeneration of the liver; interstitial nephritis; sudden death due to copious uterine haemorrhages.

L. S., aged fifty-four; coloured. Admitted March 11, 1897. Complaint: frequent uterine haemorrhages; offensive uterine discharge.

The patient has been married twenty years, and has had two children and one miscarriage. Her menses commenced at thirteen, were regular and profuse, lasting three or four days, and very painful. Seven years ago the periods diminished in number, occurring every three or four months, though there was fre-

* Wagner, E. *Der Gebärmutterkrebs, eine pathologisch-anatomische Monographie*, vi. 169 pp., 2 Tafeln, Leipzig, 1858.

† Williams, R. *On the Morphology of Uterine Cancer*. *Brit. Gyn. Journal*, 1895-'96, vol. xi, p. 529.

quently a bloody discharge. In August, 1895, the bloody discharge reappeared, was constant, but not excessive, and continued until January, 1896. Since then she has had copious hæmorrhages, and after the one in January, 1896, she fainted. The last severe hæmorrhage prior to her admission was in September, 1896. Since

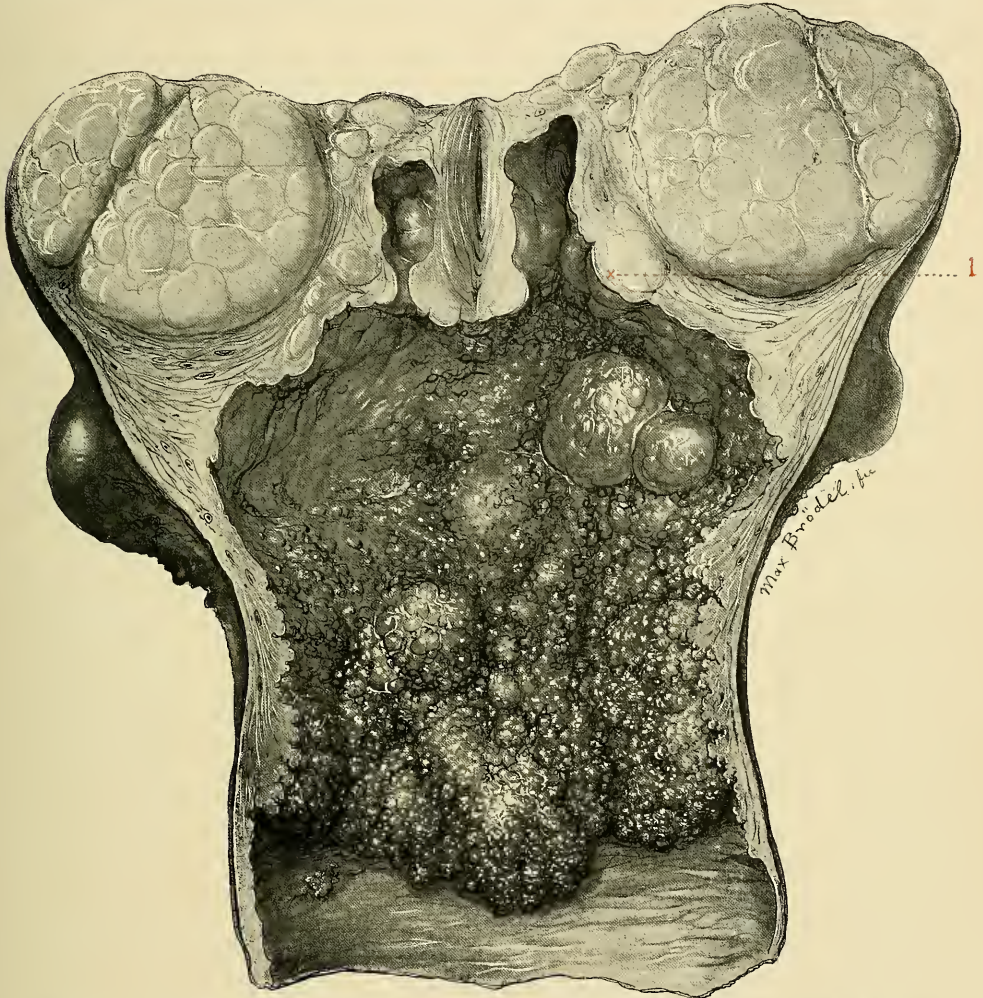


FIG. 72.—SQUAMOUS-CELL CARCINOMA OF THE CERVIX ASSOCIATED WITH MULTIPLE UTERINE MYOMATA.
($\frac{5}{7}$ natural size.)

Gyn.-Path. No. 1,631. The uterus is greatly enlarged. Projecting from its surface are numerous large and small bosses, which, on section, are seen to consist of subperitoneal, interstitial, and possibly submucous, myomata. Note how prominent the myomatous nodules are on section, owing to the recession of the uterine muscle. The lower part of the vagina presents a normal appearance, but occupying the upper part of the vagina, the site of the cervix, and also the greater part of the body of the uterus, is a ragged and friable-looking growth, composed of smooth dome-like elevations, varying from a pin's head to 2 centimetres in diameter. The larger ones are slightly lobulated. Over the smooth inner surface the tissue is almost entirely necrotic. The uterine walls have been invaded nearly to the peritoneal surface, and present a very ragged outline. The small nodules in the muscle of the fundus are myomata. The growth, on microscopical examination, is found to have penetrated the muscle between them, and at 1 has invaded the small myomatous nodule. (See Fig. 74, p. 136.) (After H. A. KELLY.)

then she has at times had a bloody discharge, slight in amount, accompanied by no pain, but very offensive and irritating.

On admission the discharge was yellowish-white and profuse.

The family history is negative.

Her previous history is unimportant save for the fact that in the summer of 1896 she had no stool for two weeks.

Present trouble: The patient did not know that she had an abdominal tumour until so informed by her physician; she thinks that the growth is diminishing in size. There has been little pain in the abdomen except after the accumulation of flatus. Enlargement of the inguinal glands was first noticed in June, 1896. These, she says, have not increased in size, but during the last four weeks have been very painful. She has lost much in weight, although she has a very good appetite. The bowels are costive, and defecation is accompanied by much pain, and occasionally by bleeding from hæmorrhoids. Micturition is sometimes burning in character, and occasionally the urine is blood-tinged (Fig. 73).

Abdominal Examination: The abdomen is dome-shaped, the most prominent point being the umbilicus. The patient has an umbilical hernia, the pouch being 3 centimetres in diameter, and projecting 3.5 centimetres from the surface, while the hernial ring easily admits the end of the index finger. On manipulation several nodules about the size of peas can be felt in the pouch; they are hard, and freely movable.

Measurements: Distance from pubes to umbilicus, 20 centimetres; from umbilicus to xiphoid process, 17 centimetres; from right anterior superior spine to umbilicus, 19 centimetres; from left anterior superior spine to umbilicus, 19 centimetres; circumference at umbilicus, 88 centimetres.

The abdominal tenderness is most marked below and to the left of the umbilicus. Over an area about 5 centimetres in diameter in this vicinity, the tissue is very œdematous, and pits readily on pressure. Owing to the tenderness, it is rather difficult to outline the abdominal tumour. It is, however, very smooth, and does not extend above the umbilicus in the median line. In both inguinal regions the glands are as large as walnuts, and are movable. Those on the right side are tender.

The right leg is much swollen, and pits on pressure, especially below the knee. The left leg is also swollen. The glands of the neck and the epitrochlears are palpable.

Vaginal Examination: The outlet is considerably relaxed, and the upper part of the vagina is occupied by a necrotic, offensive tissue, which readily breaks down under the examining finger. Further examination is impossible on account of extreme tenderness.

March 27th.—The patient had a profuse uterine hæmorrhage this morning, and, as nearly as could be estimated, lost about one pint of blood. So far as the pulse and respiration were concerned, the loss of blood caused little change, but there was a slight tendency to drowsiness. At 3.30 p. m. she had a second hæmorrhage, more profuse than the first, was restless, complained of severe pain in the back, and had a pulse of 136. The mucous membranes were quite pale. The respirations

were not increased. Morphine was given with good effect. At 11.15 P. M. she had a third haemorrhage, much more severe than the two preceding. The pulse was 140, and at 1 A. M. the patient was unconscious and gasping for breath. She died at 2.40 A. M.

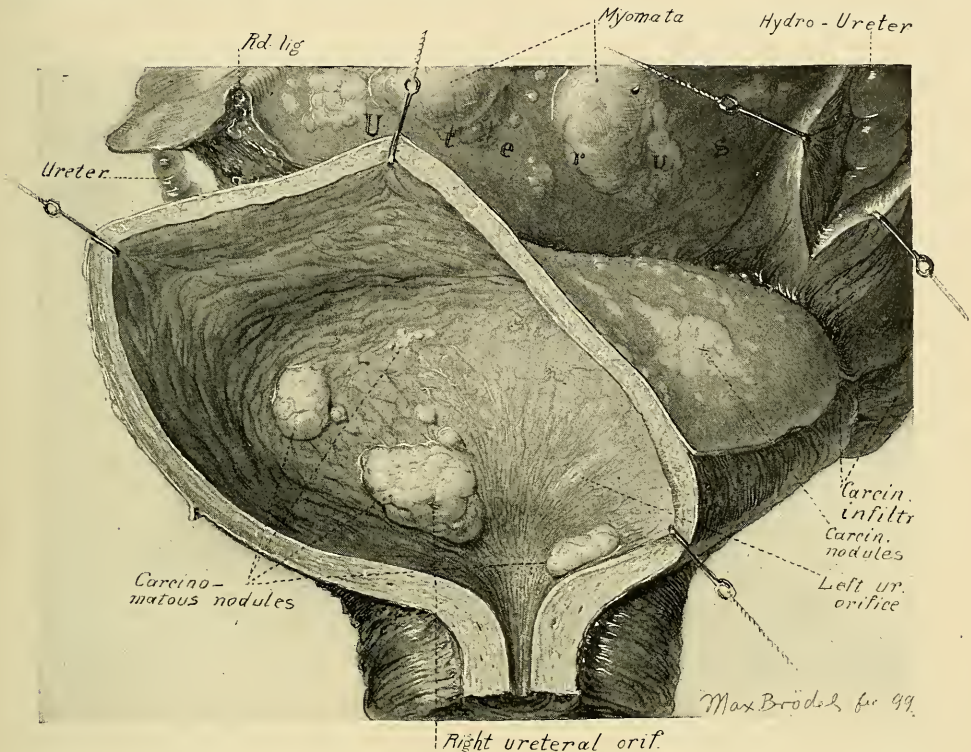


FIG. 73.—CARCINOMA OF THE BLADDER SECONDARY TO SQUAMOUS-CELL CARCINOMA OF THE CERVIX.
($\frac{5}{8}$ natural size.)

Gyn.-Path. No. 1,631. Scattered over the peritoneal surface of the bladder are many small, white, flat, isolated carcinomatous nodules. Some also have united to form conglomerate masses. The bladder walls are of the usual thickness. Just within the inner urethral orifice is an elongate nodule, about 1 centimetre in length, which rises abruptly from the surface, is sharply defined, and presents slight lobulations. The left ureteral orifice is normal, but the right is situated in the centre of a lobulated carcinomatous nodule, nearly 2 centimetres in length. Behind this are several other carcinomatous outgrowths, some of which are not more than 1 millimetre in diameter. The bladder mucosa, except where it is involved in the carcinomatous nodules, is normal. Above the bladder is the enlarged myomatous uterus, with two myomata on its surface, and numerous small, flat, carcinomatous nodules covering the peritoneum. To the right is the dilated right ureter. The left ureter is also distended, being constricted below by the carcinomatous infiltration.

Autopsy 926. Anatomical Diagnosis: Squamous-cell carcinoma of the cervix extending to the vagina, body of the uterus, bladder, rectum, broad ligaments, tubes and ovaries, and forming metastases in the pelvic, inguinal, retroperitoneal, mesenteric and bronchial glands; also in the lungs, pleuræ, and on the serosa of the intestines. Interstitial and subperitoneal uterine myomata. Hydroureter (double). Anæmia of all organs. Fatty degeneration of the liver (focal). Interstitial nephritis.

The body is of a coloured woman, small in stature and somewhat emaciated. In both inguinal regions are prominent nodular swellings, the largest about the size of a hen's egg; all are freely movable, and the largest gives slight fluctuation. Extending upward to the inguinal rings are indurated masses.

The right lung is bound by fibrous adhesions to the chest wall at about the middle third, and again posteriorly near the base. The parietal pleura on the

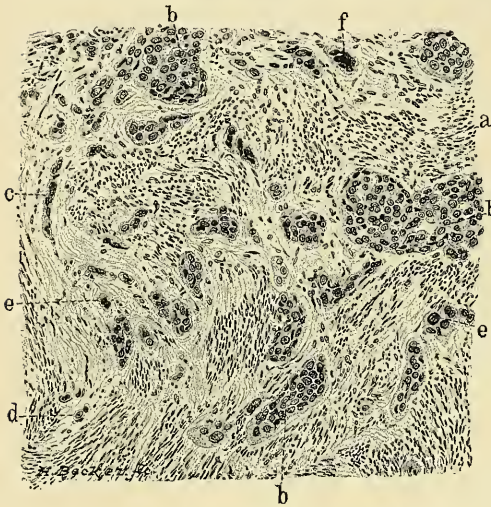


FIG. 74.—INVASION OF A MYOMA BY SQUAMOUS-CELL CARCINOMA OF THE CERVIX. (90 diameters.)

Gyn.-Path. No. 1,631. The section is taken from Fig. 72 (p. 133) at point *I*. It is composed of typical myomatous tissue, the bundles of muscle fibres being cut longitudinally or transversely, and being separated from one another by a connective tissue which is poor in nuclei. At *a* the muscle fibres are cut obliquely. At *b, b, b* typical nests are seen, composed of cells, as a rule, uniform in size, and containing vesicular nuclei. At *c* is a row of six cancer cells lying isolated in the stroma between muscle bundles. A cross section of such a row gives the picture seen at *d* and *e*, where single cancer cells are visible. The growth also forms giant cells, as seen at *f*, where there is a large irregular plaque of protoplasm, containing a lobulated, deeply staining mass of chromatin. The extension to the myoma has been by continuity.

Both ureters are dilated, especially the left, which along its lower third is nearly 1 centimetre in diameter; at the junction of the lower and middle third is a kink, above which the dilatation is not so marked.

On opening the abdomen a portion of the somewhat fatty omentum was found in the small hernial orifice at the umbilicus; it was readily withdrawn by gentle traction. The orifice was 1.5 centimetres in diameter.

Both layers of peritoneum are smooth in the upper abdomen, save for nodules about the size of peas, which here and there stud the surface of the intestines.

right side shows a grayish-white nodule, 6 millimetres in diameter, and there are small groups of similar nodules on the surface of the diaphragm. Where the lung is bound down at its base posteriorly there is a marked induration, due to superficial metastatic tumour deposits. These form a conglomerate mass of small round nodules, which are beginning to undergo softening in their centres. On section they are of a uniformly pale yellow colour. The surface is dry, but the central portions are soft and can be readily squeezed out. There are also five similar nodules scattered over the surface of the lung.

The left lung has several nodules, each about 1 centimetre in diameter, scattered over its surface.

The anterior mediastinal glands are not enlarged, but the bronchial glands are much increased in size, owing to metastatic deposits.

Spleen negative.

The liver contains no metastases.

The kidneys are of moderate size; the capsules strip off with slight difficulty, while scattered over the surface of each kidney are minute clear cysts.

The prominent and enlarged fundus is slightly adherent to the parietal peritoneum in the median line below the umbilicus. The peritoneum in the lower part of the abdomen is studded with single or grouped, whitish nodules, some of which are as large as beans; the tissue on both sides of the pelvic brim is much thickened, and has nodules over its entire surface.

The iliac glands are enlarged, one on the left side reaching about 4 centimetres in diameter, and in its centre containing a clear, odourless, straw-coloured

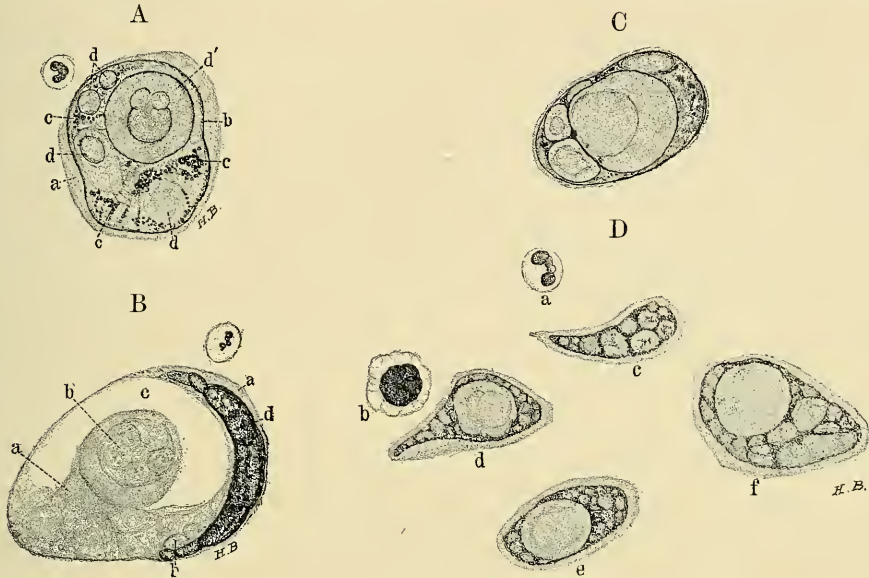


FIG. 75.—CELL DEGENERATIONS OCCURRING IN SQUAMOUS-CELL CARCINOMA OF THE CERVIX. (700 diameters.)

Gyn.-Path. No. 1,631. A. A large cancer cell. Its relative size is easily determined by comparison with the accompanying polymorphonuclear leucocyte. The cell outline is fairly regular. The nucleus is large for the size of the cell, its outline (*b*) being somewhat wavy. The chromatin is gathered up into small droplets at *c*, while occupying more than half of the nucleus are the hyaline droplets *d* and *d'*. *d'* apparently contains secondary hyaline droplets, but these are probably areas in which the degeneration is more marked.

B. To estimate the size, compare with the polymorphonuclear leucocyte. The cell protoplasm has retracted from its outer membrane at one point, leaving the clear space *e*. Throughout it are scattered numerous hyaline droplets, as indicated by *b*. The nucleus (*d*) is very large, lobulated, and stains deeply. Through pressure it has been pushed to one end and become horseshoe-shaped.

C. Another cancer cell. The nucleus is so large that the surrounding protoplasm is scarcely visible. The greater part of the nucleus is occupied by three irregular hyaline droplets, each containing within it an area that takes the eosin stain more intensely. The chromatin is situated principally in the chinks between large droplets.

D. *a* is a polymorphonuclear leucocyte. *b* represents a small cancer cell with crenated margins and a slightly lobulated, deeply staining nucleus. *c*, *d*, *e*, and *f* are cancer cells. In *c* the nucleus is irregularly triangular, contains numerous hyaline droplets, which vary little in size, and between which is the granular chromatin network. In *d*, *e*, and *f* the nuclei are also large and somewhat irregular; each contains a very large hyaline droplet.

fluid looking much like urine. The smaller glands are softened in their central portions. The largest inguinal gland on the left side contains a fluid material resembling creamy-white pus. The glands at the bifurcation on the aorta are 4 centimetres in diameter, and necrotic. The mesenteric glands are enlarged and

necrotic, as are also the retroperitoneal glands. The stomach and the large intestine have small white nodules scattered over their peritoneal surfaces.

Frozen sections from the small nodule in the posterior mediastinum show it to consist of dense fibrous tissue infiltrated with broad irregular plugs of epithelial cells. These plugs show a tendency to break down in their central portions.

The liver shows considerable fatty degeneration, especially about the periphery of the lobules.

Examination of the Pelvic Organs (Gyn.-Path. No. 1,631): The uterus is converted into a large nodulated tumour mass, approximately $21 \times 17 \times 15$ centimetres. Projecting from the fundus anteriorly is a large rounded boss, 8 centimetres in diameter. Both the anterior and posterior surfaces also present similar, but less prominent, elevations. On pressure these nodules are firm and resistant. Studding the surface of the uterus are small flattened tumours or confluent masses of a whitish, soft material. Covering the large nodules are tags of adhesions. On cutting open the uterus a large, irregular cavity is found (Fig. 72); this is 14 centimetres in length, 8 centimetres in its greatest diameter, and includes the upper part of the vagina, the broken-down cervical canal, and the greatly enlarged uterine cavity. The cervix is represented by a deep excavation, whose walls consist of a greenish necrotic material,

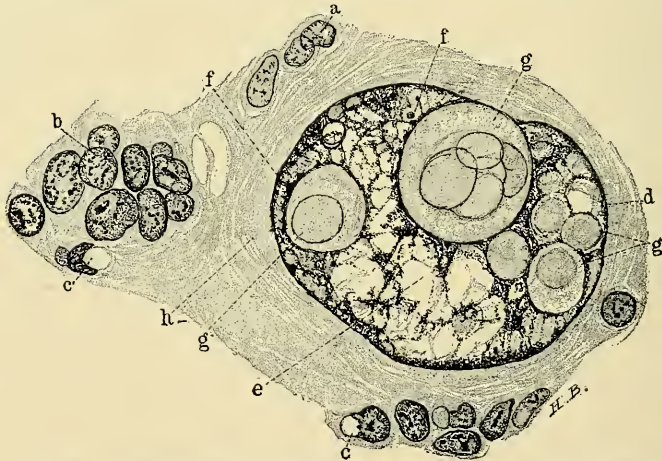


FIG. 76.—A VERY LARGE CARCINOMATOUS CELL SHOWING CHARACTERISTIC DEGENERATION.
(700 diameters.)

Gyn.-Path. No. 1,631. The section is from a squamous-cell carcinoma of the cervix. *a* shows the average size of the cancer cells in this case. At *b* the chromatin of the nuclei forms coarse droplets. The nuclei (*c*) contain spherical empty spaces, and it looks as if something, probably hyaline droplets, had fallen out. Occupying the greater part of the picture is a very large cell, whose outline cannot be determined, as its protoplasm merges into that of the adjoining cells. The nuclear outline (*d*) is, however, sharply defined. Scattered throughout the chromatin network are large and small clear spaces, indicated by *e*. The chromatin is freely deposited around the circumference of the nucleus and at *f, f*, where the hyaline droplets (*g*) seem to have pushed it up into little heaps. All of the hyaline droplets contain secondary spherical droplets.

but in a few places, where the degenerative process is not so advanced, a papillary arrangement of the tissue can be easily recognised. The new growth, which has evidently originated in the cervix, has extended to the vaginal vault, and has

involved to a moderate degree the rectum and bladder. Projecting into the uterine cavity are several irregular, dome-shaped nodules, varying from 1 to 5 centimetres in diameter. The entire cavity is lined by necrotic tissue, but here and there, as in the cervix, fine papillary outgrowths are occasionally visible. The broad ligaments, mesosalpinx, tubes and ovaries, are studded with isolated or confluent masses, which are whitish in colour, very soft, and correspond with those covering the surface of the uterus. The ovaries are nearly twice their normal size. The bladder mucosa is everywhere smooth, but in the region of the trigonum is a whitish elevation, 2 centimetres in diameter, to the left of which is a second but smaller one. Both of these are tumour growths (Fig. 73).

Histological Examination.—The squamous epithelium lining the vagina is in part preserved, but the walls of the cavity representing the vaginal vault, cervix, and uterine body consist almost entirely of necrotic material. Beneath this the tissue is everywhere infiltrated by masses of epithelial cells. These masses are large, irregular, and frequently branching, or they consist of long, narrow rows of cells. The cells of the growth vary greatly in size and form. The majority are large, and contain large, oval, vesicular, but well-stained nuclei. Many cells, however, are several times larger than the surrounding ones, and contain correspondingly large, oval, irregular, and deeply staining nuclei. Nuclear figures are abundant, sometimes regular, at other times asymmetrical. There are numerous large cells containing mulberry-like masses of oval nuclei. In many of the cells hyaline degeneration has occurred. Thus, in Fig. 75, B, the protoplasm (*a*) has contracted from the cell membrane, and at *b* has formed numerous hyaline droplets that stain intensely with eosin. The nucleus (*d*) is horseshoe-shaped and pushed to

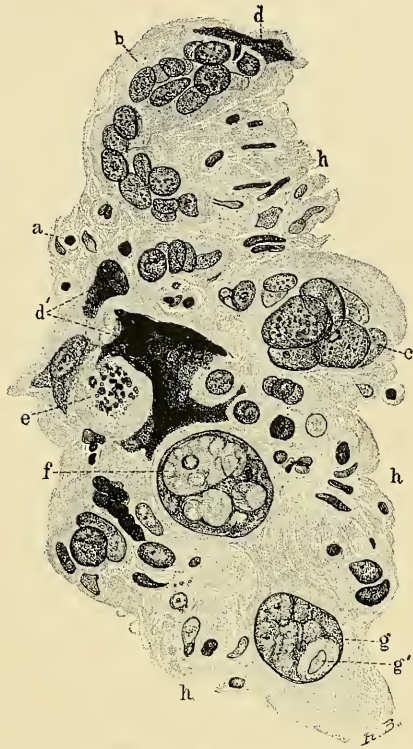

FIG. 77.—ATYPICAL CELL FORMATION IN SQUAMOUS-CELL CARCINOMA OF THE CERVIX. (375 diameters.)

Gyn.-Path. No. 1,631. *a* is a mononuclear leucocyte in the stroma. *b*, a giant cell containing fully nineteen oval nuclei, which are fairly uniform in size and distributed at about equal intervals. *c* is a giant cell containing nuclei fully four times as large as those in *b*. *d* is an elongate, irregular mass of chromatin apparently attached to the giant cell *b*. *d'* represents large, irregular, and deeply staining masses of chromatin, all semblance of the nucleus being lost. At *e* is a large spherical cell in which the nuclear membrane has almost disappeared, while the chromatin is gathered up into coarse droplets. *f* represents a very large nucleus, containing several irregular hyaline droplets. At *g* the enlarged nucleus contains the cell *g'*. It may be an inclusion, but the picture is probably due to the cell *g'* having formed an indentation on the under surface of *g*. Hence a section at a higher level would give the appearance of an inclusion. *h* is the stroma, poor in cell elements.

one side. Similar nuclear changes are also found (see Figs. 75, D, 75, C, and 77), the nuclei containing numerous hyaline droplets. In Figs. 75, A, and 77 not only are there many droplets, but some of these contain secondary droplets in their interiors. Fig. 76 shows a most exquisite example of nuclear degeneration; the cell outline is difficult to determine, the protoplasm of the various cells merging into it. The nuclear membrane (*d*) is, however, sharply defined; the chromatin network is clearly seen, and contains numerous empty spaces, *e*; *f* indicates the heaping up of the chromatin along the margins of the hyaline droplets, *g*.

Many of the cells have undergone hornification, and in some of the larger alveoli the central portions have dropped out. The large nodules scattered throughout the uterus are myomata. The uterine muscle has been penetrated in

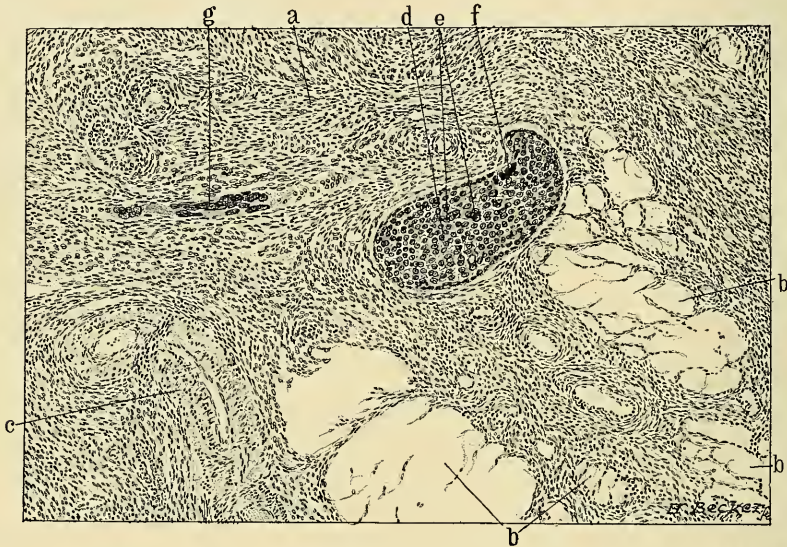


FIG. 78.—CARCINOMA OF THE OVARY SECONDARY TO SQUAMOUS-CELL CARCINOMA OF THE CERVIX. (85 diameters.)

Gyn.-Path. No. 1,631. The normal stroma of the ovary is indicated by *a*. At *b* are pale *corpora fibrosa*. *c* is a thick-walled blood-vessel. *d* shows a nest of cancer cells which has separated slightly from the surrounding stroma, and consists of polygonal cells containing oval, vesicular nuclei. At *e* the cells are somewhat larger, and contain from three to five nuclei, similar in character to those of the surrounding cells. At *f* several nuclei contain an increased amount of chromatin. *g* is a portion of the new growth, where the cell outlines are obscured. Here there is a large mass of protoplasm containing elongate, oval, deeply staining nuclei, irregularly bunched together.

all directions, the growth reaching the peritoneal surface, and the small friable masses found on the surface of the uterus present the same appearance as the uterine growth. The myomata have been invaded by the growth at many points. Fig. 74 represents a section taken from Fig. 72 at 1. It shows the squamous-cell carcinoma scattered throughout the typical myomatous tissue.

Covering the surface of the tubes are small masses of the growth, while penetrating the muscular coats in all directions are sharply defined clumps of tumour cells. These are contained in spaces lined by endothelium, and between the cell mass and the surrounding wall it is often possible to detect small round cells and

polymorphonuclear leucocytes. The spaces evidently belong to the lymphatic system. The cells of these tumour masses resemble the parent tumour, and the centres of some of these clumps show slight hornification.

The ovaries are covered by tumour masses, and in the substance of the left ovary at one point is a small tumour metastasis (Fig. 78).

The lymph glands show typical involvement by the growth, the lymphoid elements having almost entirely disappeared. The outer portion consists of fibrous tissue internal to which is a zone composed of cells of the new growth, while the entire central portion consists of necrotic tissue.

Diagnosis.—Squamous-cell carcinoma of the cervix.

Gyn. No. 3,463

Scirrhus squamous-cell carcinoma of the cervix, with extension to the vagina, broad ligaments (Fig. 79), bladder (Fig. 80), and rectum; pelvic peritonitis; chronic interstitial nephritis; hydronephrosis of left kidney; chronic adhesive pleuritis on both sides; healed tuberculosis of both lungs; chronic adhesive perisplenitis; healed inflammatory processes in caecum, colon, and rectum (syphilitic?); uraemia; death.

F. L., aged forty-four; white. Admitted April 25, 1895. Complaint: uterine hæmorrhages; pain in the lower part of the abdomen.

The patient has had three children and two miscarriages. All the labours were difficult, the first being instrumental. One cousin died of carcinoma. Her family history on the whole is good, and, apart from frequent attacks of rheumatism, she has always been healthy.

About one year ago what she supposed to be her menses began to occur twice a month, and the amount of the flow was considerably augmented. At present the bleeding is almost constant. The abdominal pain first manifested itself in December, 1894. It is sharp and shooting in character, and almost constantly present.

The patient is very anæmic and debilitated. Her appetite is poor; the bowels are constipated; micturition is frequent and burning. She has a copious, thick, yellowish vaginal discharge, which is both irritating and offensive. The vaginal outlet is relaxed; the upper third of the vagina and the cervix are occupied by a sloughing ulcerative process. The growth has extended forward into the bladder and backward into the rectum; the broad ligaments have a board-like consistence, and the pelvic lymphatics seem to be involved. The possibility of even a palliative operation is out of the question. The patient was transferred to the isolating ward, where she remained two months suffering most intense agony, notwithstanding the large doses of morphine she was receiving. For three weeks previous to her death there were marked signs of uræmia. She suffered constantly with nausea; there was a decrease in the urinary excretion, and a uriferous odour to the breath.

Autopsy No. 684. Gyn.-Path. No. 795. Anatomical Diagnosis: Carcinoma of the uterus with metastases in the bladder and on the peritoneum.

Chronic interstitial nephritis. Hydronephrosis of the left kidney. Chronic adhesive pleuritis on both sides. Healed tuberculosis of both lungs. Chronic adhesive perisplenitis. Healed inflammatory process in cæcum, colon, and rectum (syphilitic?).

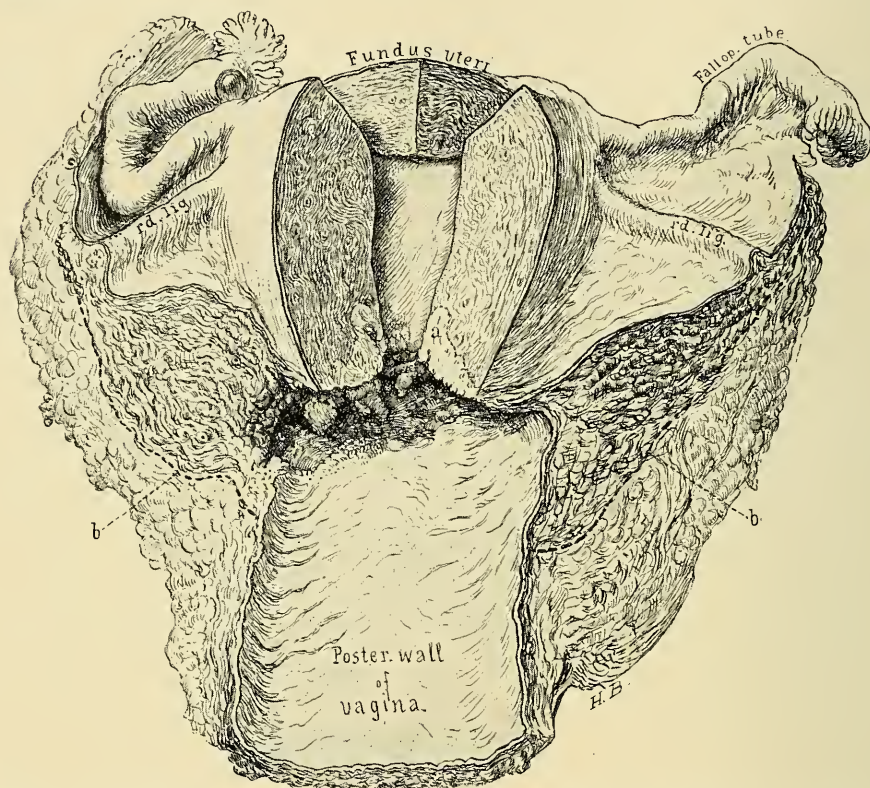


FIG. 79.—INVOLVEMENT OF THE BROAD LIGAMENTS IN SQUAMOUS-CELL CARCINOMA OF THE CERVIX. (Natural size.)

Autopsy 684. Gyn.-Path. No. 795. The specimen was hardened in alcohol, and the shallow vaginal ulcers, noted in the text, have become indistinct. The cervix has entirely disappeared. Occupying the upper part of the vaginal vault is an eaten-out, ulcerated-looking area. The greater portion of the growth in the uterus has broken down, but at *a* the irregular advancing margin of the carcinoma is clearly outlined. Laterally, the broad ligaments have been greatly infiltrated, the carcinoma extending outward as far as the dotted lines *b, b*. The body of the uterus is smaller than usual. The tubes, save for a small subperitoneal cyst on the right side, are normal. Anteriorly the growth has extended to the bladder. (See Fig. 80.)

The uterus at the fundus is 4 centimetres in breadth and 3 centimetres in its antero-posterior diameter. Anteriorly it is smooth and glistening, but near the round ligament on either side it is loosely adherent to the peritoneum covering the bladder. Posteriorly it is attached to the rectum and also to the right ovary. Just posterior to the commencement of the left tube, and immediately beneath the peritoneum, are two yellowish-white nodules which project slightly from the surface, the larger measuring 8 millimetres in diameter. On section these are found to present a grayish-white homogeneous surface. The vagina near the outlet is normal, but about 5 centimetres within the opening an irregular, sharply

defined ulcer, 2 centimetres in diameter, is seen on the anterior wall. It is surrounded by a bluish-red rim, has a creamy-yellow margin, and presents a worm-eaten appearance. The upper portion of the anterior vaginal wall presents throughout a rough, worm-eaten surface, covered by a greenish-yellow fetid pus. In the posterior vaginal wall is an ulcerated area, 5 millimetres in diameter. The cervix has entirely disappeared, its place being occupied by a cavity which everywhere has a dirty grayish surface and is covered by pus. The line where the ulcerated area joins with the healthy uterine muscle is uneven but sharply defined.

Laterally the ulceration has extended to the broad ligaments (Fig. 79, *b*), and the vagina is walled off from the pelvic cavity merely by delicate adhesions between the peritoneum covering the bladder and that on the anterior surface of the uterus. The broad ligaments contain a great deal of fat, into which the growth has extended, appearing there as a firm, white, glistening tissue.

In the uterine cavity about 2 centimetres of the mucosa still remains unaltered; here it is thin, pinkish in colour, and perfectly smooth. The right tube is unaltered, but the ovary is covered by a few adhesions, which bind it down to the posterior surface of the broad ligament, to the rectum and uterus. The left tube is also normal, but the ovary is partially hidden by rectal adhesions. The bladder is contracted. Situated in its peritoneum are many flat, whitish nodules, varying from 1 to 5 millimetres in diameter. These are more abundant on the left side; on section they present a waxy-white, smooth surface, and are very firm. The bladder walls average 8 millimetres in thickness; the surface of the mucosa is intact. Situated just to the left of the median line, however, and near the orifice of the left ureter, are several yellowish-white, slightly raised nodules, varying from 1 to 7 millimetres in diameter. Posterior to the ureteral orifices are several other carcinomatous nodules (Fig. 80, *b*).

Histological Examination.—The vaginal epithelium in the vicinity of the ulcerated areas is intact, but between its cells are a few polymorphonuclear leucocytes. In several places the epithelium projects downward, showing a decided tendency to invade the stroma. The superficial portions of the ulcerated areas are necrotic, but there is no inflammatory reaction. A short distance beneath the surface of the ulcer, the tissue is everywhere invaded by nests of cells, which occur principally in single rows or small bunches. Not infrequently, however, equally large alveoli completely filled with cells, and occasionally individual cells, are found scattered throughout the stroma. The nuclei of the cells are round, oval, or irregularly oval; they show a fine network, and not infrequently contain nuclear figures. Where the cells occur singly, the nuclei are drawn out, tending to become somewhat flattened. Such areas at first sight might be taken for sarcomatous tissue. Masses of tumour cells have penetrated the vaginal wall and extend into the underlying adipose tissue.

Sections from the uterus show that the cervical landmarks have entirely disappeared, and that the ulcerated areas, although entirely necrotic, are not infiltrated by polymorphonuclear leucocytes or by small round cells. On passing upward the uterine muscle is seen to be studded with oblong or round masses of tumour cells. In the vicinity of the internal os they have extended outward into

the broad ligament; upward they involve the body of the uterus to within 1 centimetre of the fundus. The mucosa shows equal involvement with the muscle, and the carcinomatous masses stand out in sharp contrast to the normal uterine glands. Professor Welch, in examining the areas, which somewhat resemble sarcoma, thought that the changes were due to increase in the amount of connec-

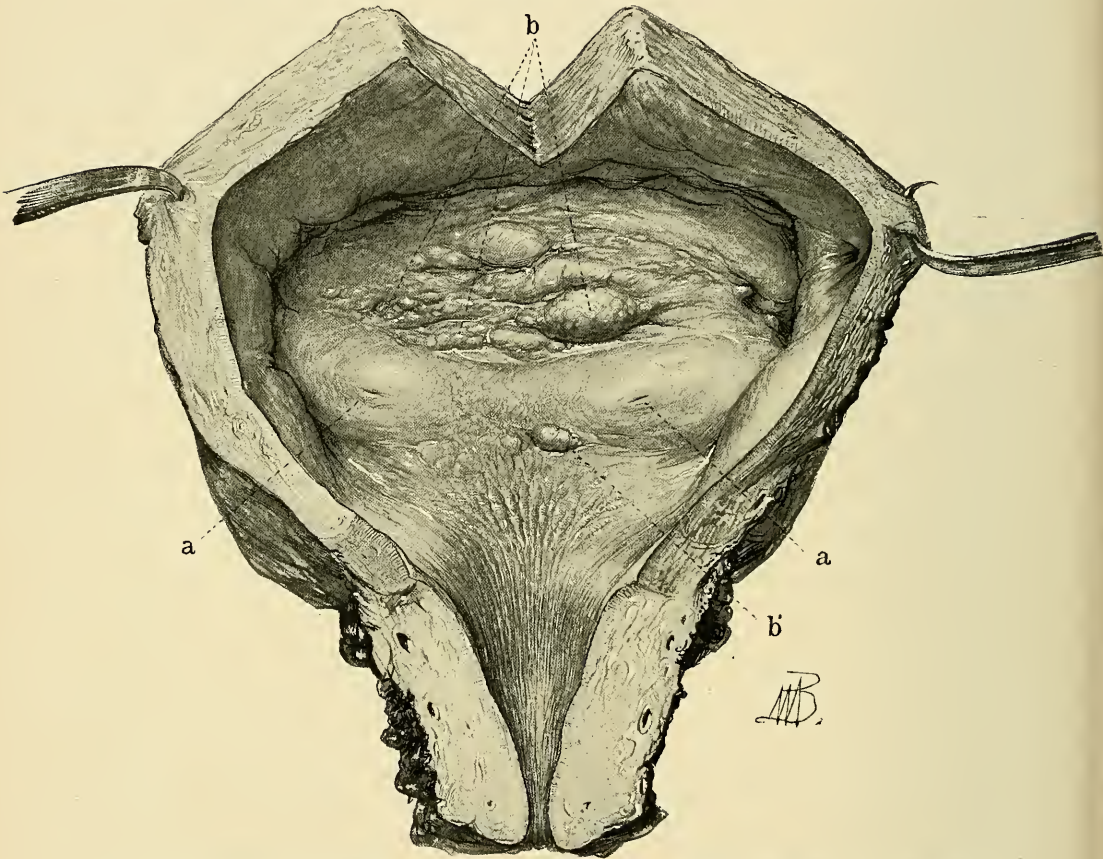


FIG. 80.—CARCINOMA OF THE BLADDER SECONDARY TO SQUAMOUS-CELL CARCINOMA OF THE CERVIX.
(Natural size.)

Gyn.-Path. No. 795. The bladder is of the usual size. The urethral and vesical mucosæ, on the whole, present the normal appearance. Just anterior to the ureteral orifices and slightly to the left of the median line, however, is an elevated smooth nodule, *b'*. Several similar elevations, varying from 1 to 8 millimetres or more in diameter, are indicated by *b*. All of these were yellowish white in colour, and are covered by mucosa. Histological examination showed them to consist of squamous-cell carcinoma identical with that invading the cervix. (After H. A. KELLY.)

tive tissue, and pointed out the resemblance between these areas and the so-called scirrhus cancer of the breast. The growth is a squamous-cell carcinoma which has most probably originated in the cervix. Examination of the mesenteric lymph glands is negative.

Diagnosis.—Scirrhus squamous-cell carcinoma probably originating in the cervix, possibly, however, in the vagina. Extension to the broad ligaments.

Gyn. No. 4,491

Squamous-cell carcinoma of the cervix (Fig. 81); invasion of the vagina, bladder (Fig. 82), and perirectal fat; vesicovaginal fistula; double hydronephrosis and hydroureter; fatty degeneration of the heart muscle; cloudy swelling of the liver; oedema and congestion of the lungs; cholelithiasis; uraemic convulsions; death.

M. L., aged fifty-one; white. Admitted July 1, 1896. Complaint: "bladder trouble"; retention of urine; pain in the lower part of the abdomen.

The patient, who has been married thirty-four years, has had nine normal labours. Her menses ceased four years ago. The family history is negative and her previous history unimportant.

For the last year she has had moderate uterine hæmorrhages, which at first were thought to be a return of the menstrual flow. During the past four months the hæmorrhages have been more abundant. Three months previous to admission she first complained of severe burning pain in the bladder immediately prior to and during micturition. On admission, the patient is well nourished; her appetite is poor; the bowels are regular. She is nervous, and sleeps very poorly. For several days subsequent to her entrance to the hospital she had to be catheterized. She gradually grew weaker, and died July 21, 1896. Shortly before death she had several convulsions.

Autopsy, No. 824. An abstract from the protocol is as follows: The body is strongly built and is not emaciated. The peritoneal cavity contains a small amount of clear, light yellow fluid. The fat lining the parietal peritoneum, that of the mesentery, and occasionally the peritoneum itself, show small, irregular patches of grayish-black pigment. The gall-bladder is irregularly contracted, and contains a small quantity of thick yellowish-green pus and three gall-stones.

Gyn.-Path. No. 1,262. The right kidney is covered by a large quantity of fat, which is in most places readily stripped off, but here and there is adherent. On section, the pelvis is seen to be fully 6 centimetres in length; it is dilated in all directions, and corresponding to the calices are little hollows. The pelvic lining is smooth and glistening. The cortical portion, which varies from 5 to 6 millimetres in thickness, has a yellowish tinge. The capsule of the left kidney is easily stripped off. The organ presents a mottled appearance, is slightly lobulated, and at one extremity contains two small cysts filled with a clear, transparent fluid. This kidney is not so large as that on the opposite side, but presents the same general appearance. Both ureters are dilated, averaging 1.2 centimetres in diameter. The bladder mucosa presents the usual appearance, but immediately within the inner opening of the urethra the bladder wall has been invaded by a new growth extending over an area 4×4.5 centimetres (Fig. 82). This is whitish-yellow in colour, and has sharply defined elevated and convoluted margins, which are injected. Around the outer margin of the growth the mucosa has been pushed upward, but still covers the tumour. Over an area $1.5 \times .8$ centimetres the growth has broken down, and there is a direct communication with the vagina.

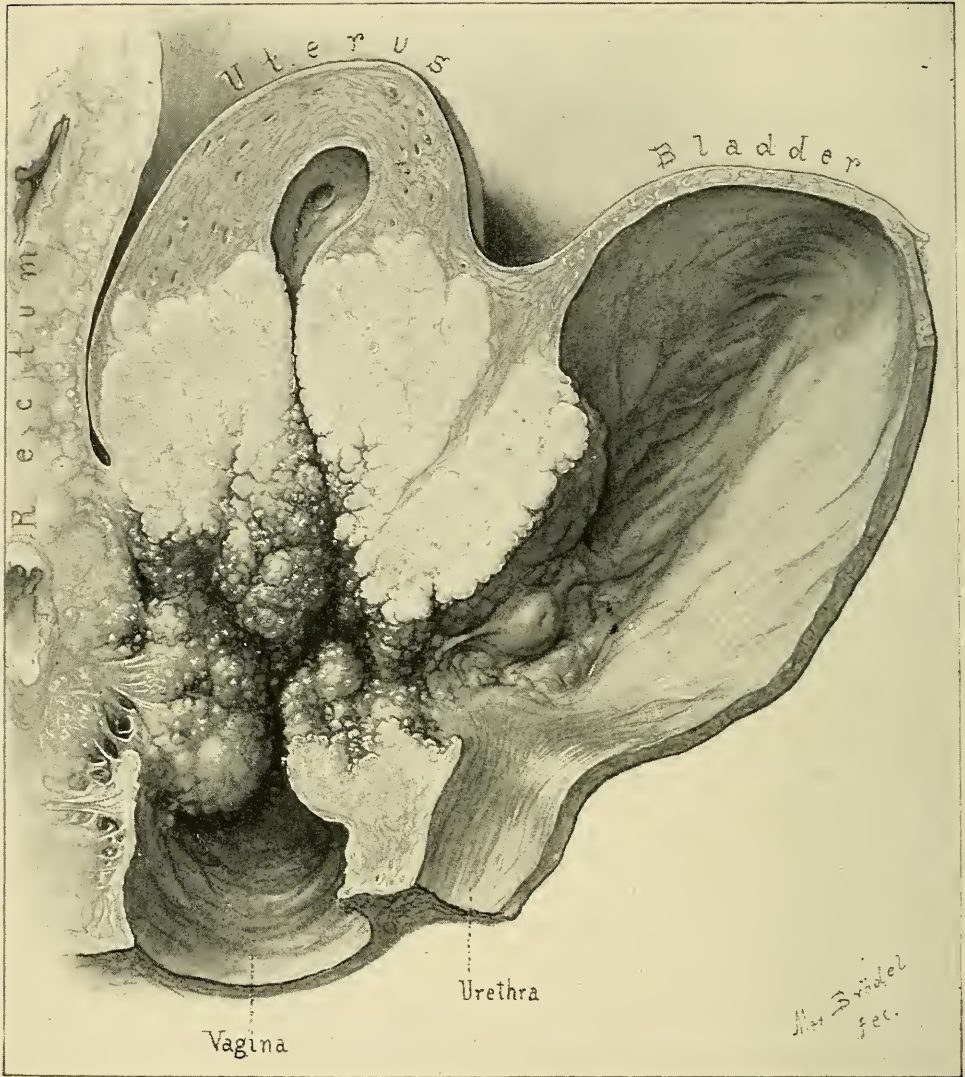

FIG. 81.—SQUAMOUS-CELL CARCINOMA OF THE CERVIX WITH EXTENSION TO THE BLADDER AND RECTUM. VESICO-VAGINAL FISTULA. (Natural size.)

Autopsy 824. The picture represents a sagittal section of the bladder, uterus, and rectum. The cervical landmarks are entirely obliterated. The upper part of the vagina and the greater portion of the body of the uterus are occupied by a new growth. At the cervical site the growth is broken down, presenting a coarsely granular appearance. Its upper limit is irregular, but sharply defined, standing out clearly from the uterine muscle, which is much darker in colour. The growth along the lower or vaginal limit is considerably elevated, and overhangs the normal mucosa. Anteriorly the carcinoma has implicated the inner surface of the bladder. Here it measures over 1 centimetre in thickness, and extends downward to the inner urethral orifice. At the trigonum the bladder has broken down, and there is, accordingly, a vesico-vaginal fistula 1.5 centimetres in diameter and with very ragged margins. A short distance within the inner urethral orifice is a little mound with an opening in its centre. This represents the mouth of the ureter, which opens on a hillock of carcinomatous tissue. It is exceptional to find the bladder as large as in this case, when a vesico-vaginal fistula exists, since the viscus naturally becomes much contracted from lack of the usual distention.

The right ureteral orifice emerges from the tumour mass; that on the left side springs from a small tuft, that is on all sides surrounded by tumour tissue.

The vaginal mucosa is in part smooth and glistening, but is deeply injected. The upper portion of the vagina, what remains of the cervix, fully two thirds of the uterus, and the adjacent portions of the bladder wall have been invaded by a new growth, which in the cervical region has broken down and appears as a mushy, friable material (Fig. 81). Where it invades the vagina the advancing margin is sharply defined and presents a slightly elevated surface. The growth in the uterine wall, where not yet broken down, is whitish-yellow and very soft.

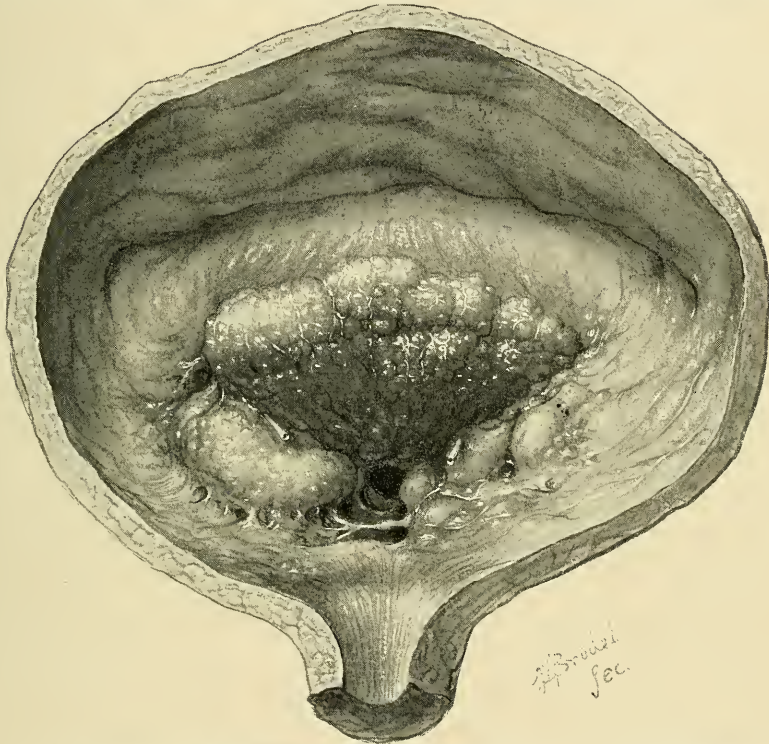

FIG. 82.—A VESICO-VAGINAL FISTULA SEEN FROM ABOVE, RESULTING FROM A SQUAMOUS-CELL CARCINOMA OF THE CERVIX. (Natural size.)

Autopsy 824. This drawing represents Fig. 81, viewed from the bladder. The inner urethral orifice is normal, but just posterior to it, and occupying the entire trigonum, is a new growth. This has elevated and clearly outlined margins, and consists of small bosses. The ureteral orifices are indicated by the small catheters, and are seen opening directly on the surface of carcinomatous tissue. Just on a line with the inner urethral orifice, and almost in the centre of the carcinomatous tissue, is an opening which communicates with the vagina. It has been caused by a breaking down of the carcinomatous tissue, and is a vesico-vaginal fistula.

The uterine walls are invaded from the mucosa to the peritoneal surface; posteriorly the growth has extended into the subperitoneal fat separating the uterus from the rectum. The latter is not involved. The uterine cavity for 2.5 centimetres, although its surface is still intact, is slightly dilated and filled with brownish-yellow pus. The appendages present the usual appearance.

Histological Examination.—The growth presents the typical appearances of a squamous-cell carcinoma. The tumour cells appear to be very active, many of their nuclei being large, oval, and deeply staining; in some places the cells contain two or more nuclei. There is considerable karyorrhesis, and epithelial pearls are abundant.

EXTENSION OF SQUAMOUS-CELL CARCINOMA OF THE CERVIX TO THE RECTUM

Involvement of the rectum is less frequent and occurs at a much later period than extension to the bladder. This fact is easily explained by the anatomical relations (Fig. 3). The cul-de-sac of Douglas is found deep down in the pelvis, usually reaching a point below the level of the cervix. Thus, as a rule, the rectum becomes involved only by extension from the vagina, although in some instances, when the growth extends through the cervix to the peritoneum and the uterus becomes adherent to the rectum, direct invasion may take place. The formation of adhesions between the lower part of the uterus and the rectum is well shown in Fig. 88. Here the disease is far advanced; a large fistulous opening exists between the vagina and the bladder; the uterus has been eaten through posteriorly, but the pelvis is walled off by the adhesions to the rectum. The peri-rectal fat has been invaded, but as yet the rectum is not involved, notwithstanding the advanced stage of the disease.

In Fig. 83 (p. 151) the cervix is still intact, but the growth has extended anteriorly to the outer vesical coats, while posteriorly the rectum is infiltrated over a wide area, as indicated by the dotted lines.

Wagner, in a collection of 189 cases, found the rectum involved in 16 per cent; in two thirds of those cases a recto-vaginal fistula had formed. Williams, in 78 cases, reports 19 with rectal growths, 10 of which had perforated. After the carcinoma has extended to the peri-rectal fat, it soon invades the various coats of the rectum and gradually pushes the rectal mucosa in front of it. At this stage, the growth, on rectal examination, can be felt as a large nodular mass just beneath the mucosa, and its continuity with the vaginal thickening is easily made out. When the disease has advanced thus far, the broad ligaments are usually very firm and the entire pelvic contents are fixed. Not infrequently in such cases the rectoscope will give valuable aid in helping us to determine the true condition.

Wagner states that inflammation of the colon occurs very frequently in the later stages of squamous-cell carcinoma of the cervix, and is present in about one third of all cases. These figures do not correspond with those of the present day, from the fact that many of the cases are submitted to radical procedures sufficiently early to prevent this implication, whereas at that time (1858) operations were only rarely successful, since they consisted in merely amputating the cervix. This inflammation, according to Wagner, occurs frequently as an acute catarrh, with or without swelling of the follicles. Occasionally the mucosa may become gangrenous, but the reason for the occurrence of this condition is unknown.

The mucosa is soon invaded by the growth, which gradually becomes necrotic, disintegrates, and leaves a fistulous opening between the rectum and vagina.

This opening is usually irregular, has hard, friable, elevated margins, and through it the fæces escape into the vagina.

The Formation of a Cloaca.—Where the patient withstands the disease a long time, and recto-vaginal and vesico-vaginal fistulæ develop, a cloaca may form, the fæces and urine collecting in the large and excavated channel, formed by the vagina and the cavity representing the site of the cervix. Into this occasionally are poured pelvic exudates, or the contents of enlarged pelvic glands, which have suppurated. Such a cavity might then contain urine, fæces, pus, and necrotic material. Wagner claimed that this condition was present in about three to four per cent of all cases of carcinoma of the cervix.

Cases of Squamous-cell Carcinoma of the Cervix, with Rectal Involvement

Gyn. No. 2,449

Squamous-cell carcinoma of the cervix; extension to the broad ligaments, bladder, and rectum; recto-vaginal fistula; compression of the ureteral orifices; pyelonephrosis on the right side, with presence of colon bacilli; hydronephrosis on the left side; chronic perisplenitis; calcification of mesenteric glands; death with uraemic symptoms.

B. M., aged forty-two; white. Admitted December 6, 1893.

The patient has been married twenty-one years, and has had seven children. In the second labour version had to be performed. During the last two pregnancies her feet and ankles became edematous, and she had spells of giddiness with some dimness of vision. Her menses ceased four years ago, but the patient says that whenever she is worried or excited there has been a free uterine hæmorrhage. Her family history is unknown.

Two years ago the patient, who kept a market stall, noticed that she could not stand so long as formerly, was continually tired, and suffered from pain in both lumbar regions. Dyspnœa was a marked feature, even the slightest exertion being sufficient to cause it. Five weeks ago she noticed that the urine was passing involuntarily, and she would sometimes wake up to find the bedding saturated. The woman has become much thinner during the last year. On admission, she is emaciated; the skin is waxy-looking; the mucous membranes are pale; the appetite is poor; the bowels are regular. At present she has considerable abdominal pain. On January 19th it was noted that there was incontinence of urine and fæces, and that she was much paler than when admitted. Death occurred January 31, 1894.

Gyn.-Path. No. 105. The specimen consists of a moderate amount of whitish, friable tissue.

Histological Examination.—The surface of this tissue is in some places covered by delicate, finger-like or dome-shaped, projections. Those that are finger-like have a central blood-vessel, which is surrounded by a moderate amount of connective tissue. External to the connective tissue are many layers of cells having oval, vesicular nuclei. The dome-like masses consist of connective tissue

covered over by several layers of cells similar to those described. Scattered everywhere throughout the tissue are tongue-like, oval, or branching masses of cells having oval, vesicular nuclei. In many places the cells forming the outermost layer of the alveolus appear to be cylindrical. The stroma between the nests of cells shows considerable small-round-cell infiltration.

Diagnosis.—Squamous-cell carcinoma of the cervix.

Autopsy No. 490. Anatomical diagnosis: Squamous-cell carcinoma of the cervix; invasion of the peri-uterine tissue, bladder, and rectum; compression of the ureteral orifices; pyelonephritis on the right side, with presence of the colon bacillus; hydronephrosis on the left side; chronic perisplenitis; calcification of mesenteric glands.

The following is an abstract from the protocol: The body is much emaciated and shows no œdema. The vagina, which contains a creamy pus, in its upper portion has been reduced to an ulcerated area, the margins of which are markedly infiltrated. The cervix and the lower portion of the body of the uterus have disappeared, and are represented by a ragged and uneven excavation. Above the point of excavation the uterine tissue is invaded by a new growth. Posteriorly the tumour involves the rectum, and the process of ulceration has advanced so far that there is a recto-vaginal fistula. Laterally the soft tissues are involved. The appendages are apparently normal; the bladder walls are greatly thickened, and between this viscus and the uterus are firm adhesions. Where the ureters enter the bladder the latter is greatly thickened, evidently somewhat obstructing the flow of urine. Both ureters are tortuous and widely distended; these features are more marked on the left side than on the right. The pelvis of the left kidney is dilated and filled with clear fluid. That of the right is also dilated, and contains a mucopurulent material; its lining is much thickened. On section, the right kidney is found to contain many abscesses, varying in size from a millet-seed to a small bean.

Histological Examination.—The uterus is everywhere invaded by alveoli, some of which are long and narrow, others more oval or round. These are completely filled by large cells, which have large, round, deeply staining nuclei. In some places the cells in the central portion stain poorly; or between the epithelial cells are polymorphonuclear leucocytes, which occasionally are so abundant that the entire central portion of the alveolus is filled with them. The growth in the broad ligaments is a continuation of that in the uterus.

The entire right kidney is converted into large and small abscess cavities. The walls of these are formed by renal tubules, which appear as ragged tags springing from the margins. Polymorphonuclear leucocytes invade the surrounding tissue in all directions. There is marked increase of connective tissue, and where the tubules are still present they are dilated and their epithelium is flattened. The left kidney is the seat of much connective-tissue increase. The glomeruli are little altered, but the convoluted tubules are dilated and their epithelium is flattened.

Gyn. No. 4,374

Seen first at autopsy. Squamous-cell carcinoma of the cervix with enormous cell-nests (Fig. 83); extension to the vagina, broad ligaments, bladder, rectum, and iliac lymph glands; hydrosalpinx; involvement of the ureters in adhe-

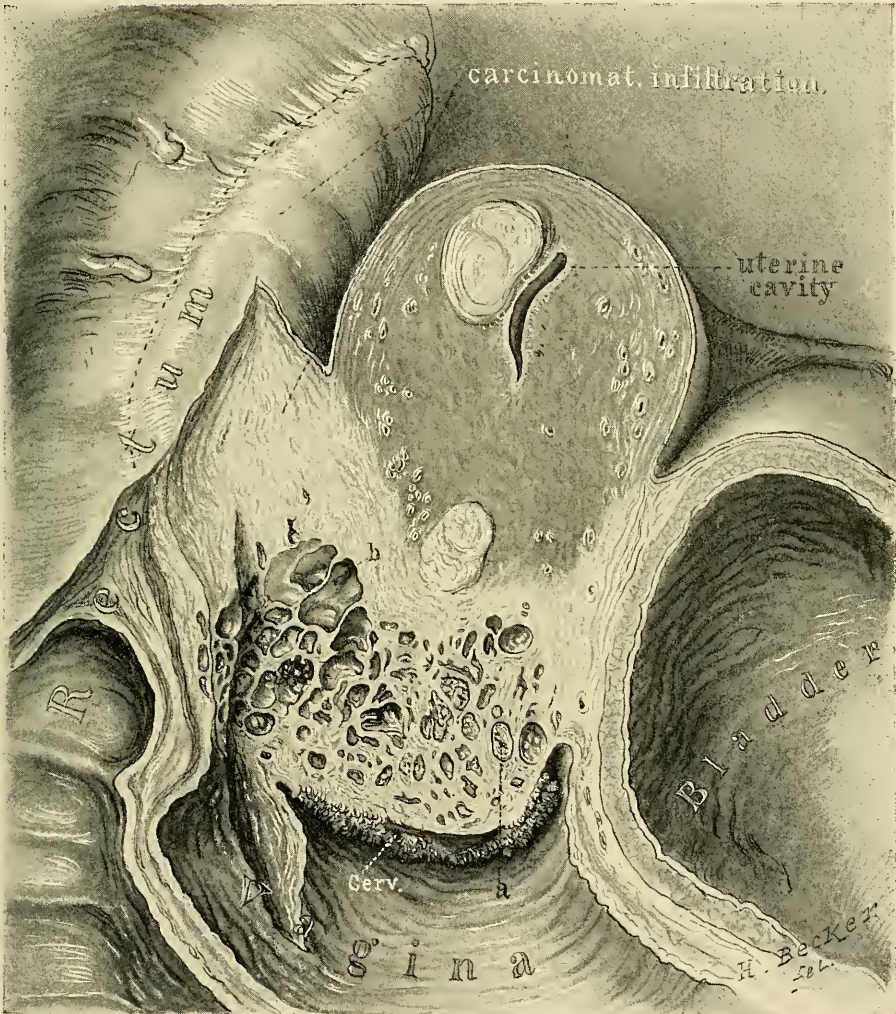


FIG. 83.—REMARKABLY LARGE CELL-NESTS IN SQUAMOUS-CELL CARCINOMA OF THE CERVIX.
(Natural size.)

Autopsy 810. Gyn-Path. No. 1,203. The cervical outline is intact, but covering the greater part of the vaginal portion is a shaggy growth, consisting of delicate finger-like processes. The cervix is literally riddled with large and small smooth-walled spaces, which have been filled with masses of epithelial cells. Some of these are fully 1 centimetre in length (*b*). *a* indicates one of the cell-nests which has not dropped out. Anteriorly, the growth has extended to the peri-vesical tissue. Posteriorly, the rectum has been encroached upon, and over the area indicated by the dotted line is infiltrated with the cancerous growth.

sions; hydroureter and pyoureter; pyonephrosis; chronic diffuse nephritis; diverticulum of vermiform appendix; cyst of adrenal gland.

C. H., aged forty-seven. Autopsy, May 29, 1896.

Autopsy No. 810. Gyn.-Path. No. 1,203. The entire cervix is occupied by a new growth, which has extended downward upon the vagina. Secondary tumour masses are found in the vicinity of the uterus; the largest of these is just behind the iliac vessels on the left side; it measures $5 \times 3 \times 2$ centimetres, and evidently corresponds to an enlarged lymph gland. Other lymph glands in this region are also enlarged. The glands on the right side show less involvement. On histological examination the enlargement of the lymph glands is seen to be due to metastatic deposits from the uterine growth.

The chief point of interest in this case lay in the honeycombed appearance of the cervix. This condition was confined to the part occupied by the squamous-cell growth. The spaces varied from 1 millimetre or less to fully 8 millimetres in diameter. Some were filled with a granular material, others were empty and had smooth walls. On examining these honeycombed areas the spaces were found to be filled almost entirely with epithelial masses. Where the nests were small, the epithelium not infrequently filled the entire space; but where the nests were very large, only the outer three or four layers were still preserved, the central portion being necrotic. In not a few places the whole central portion had dropped out, and only a few epithelial cells remained clinging to the wall. In no other instance have we seen such gigantic epithelial nests.

INVOLVEMENT OF THE URETHRA IN SQUAMOUS-CELL CARCINOMA OF THE CERVIX

This is a rare occurrence, and one which we have not seen. Wagner, in his long series, reports a single case (XIV) in which the carcinoma of the cervix had invaded the bladder and extended by continuity to the urethra. He says "the mucosa of the urethra, as well as of the neck of the bladder, was studded with carcinomatous finger-like processes." In Wagner's Case XXVIII the bladder was involved and a vesico-vaginal fistula had formed. The urethra in this case had become obliterated, evidently from non-use.

SQUAMOUS-CELL CARCINOMA OF THE CERVIX INVOLVING THE PELVIC BONES

The patient usually dies before there has been sufficient time for extension to the bones to take place. Some cases, however, have been observed. The anterior surface of the sacrum and the inner surface of the innominate bone are the parts most likely to be involved, the process reaching them by continuity. Wagner reported two cases (XXXIII and XXXIV), observed by Credé, in which the pelvic bones were eroded. In Case 6,388 (p. 128) of our series the left broad ligament was occupied by a large, white, friable tumour mass. This extended above the crest of the ilium and was intimately adherent to it, the bone being somewhat eroded.

CONDITION OF THE TUBES AND OVARIES IN SQUAMOUS-CELL CARCINOMA OF THE CERVIX

The literature on squamous-cell carcinoma of the uterus contains very little bearing on this point. In our own cases we have had some difficulty in getting the necessary data, owing to the fact that in numerous instances the uterus has been removed *per vaginam*, the tube and ovary on one side, and not infrequently on both, being left behind. A study of the accompanying table of thirty-one cases of squamous-cell carcinoma in which the tubes and ovaries were examined gives, however, a fairly adequate idea of the conditions usually present.

Cases of Squamous-cell Carcinoma of the Cervix in which the Condition of the Tubes and Ovaries was studied

NAME AND GYN. No.	Operation or autopsy.	Complication.	CONDITION OF TUBES AND OVARIES.			
			Right tube.	Right ovary.	Left tube.	Left ovary.
D., 2,885...	Autopsy.	Vesico-vaginal fistula.	Normal.	Normal.	Adherent.	Adherent, involved by continuity.
M., 2,415...	Combined abdominal and vaginal hysterectomy.	Normal.	Normal.	Normal.	Normal.
H., 4,374...	Autopsy.	Hydrosalpinx.	Hydrosalpinx.
L., 3,463...	Autopsy.	Normal.	Slightly adherent.	Normal.	Slightly adherent.
J.,	Autopsy (701).	Vesico-vaginal fistula.	Normal.	Normal.	Normal.	Normal.
L., 4,491...	Autopsy.	Vesico-vaginal fistula.	Normal.	Normal.	Normal.	Normal.
J., 4,328...	Hysterectomy.	Moderately adherent; secondary involvement by the carcinoma.	Moderately adherent.	Moderately adherent.	Moderately adherent.
H., 3,609...	Abdominal hysterectomy.	Normal.	Normal.	Normal.	Dermoid cyst 2.5 centimetres in diameter.
C., 4,430...	Abdominal hysterectomy.	Delicate adhesions.	Delicate adhesions.	Delicate adhesions.	Delicate adhesions.
M., 2,695...	Attempted hysterectomy.	Densely adherent.	Densely adherent.	Densely adherent.	Densely adherent.
M., 2,725...	Ligation of internal iliaes.	Fan-like adhesions.	Fan-like adhesions.	Fan-like adhesions.	Fan-like adhesions.
D., 2,452...	Vaginal hysterectomy.	Normal.	Not removed.	Normal.	Not removed.
E., 3,114...	Combined abdominal and vaginal hysterectomy.	Normal.	Normal, senile.	Normal.	Normal, senile.
E., 4,143...	Abdominal hysterectomy.	Normal.	Normal.	Normal.	Normal.
Le C., 4,176	Abdominal hysterectomy.	Normal.	Small papilloma.	Normal.	Normal.
D., 3,888...	Abdominal hysterectomy.	Slightly adherent.	Normal.	Torsion, hydrosalpinx.	Adherent.

Cases of Squamous-cell Carcinoma of the Cervix—(continued)

NAME AND GYN. NO.	Operation or autopsy.	Complication.	CONDITION OF TUBES AND OVARIES.			
			Right tube.	Right ovary.	Left tube.	Left ovary.
C., 2,572...	Vaginal hysterectomy.	A few adhesions.	Corpus luteum cyst 5 centimetres in diameter.	Not removed.	Not removed.
E., 2,627...	Vaginal hysterectomy.	Normal.	Numerous delicate adhesions.	Not removed.	Not removed.
O., 2,624...	Vaginal hysterectomy.	Numerous adhesions.	Normal.	Not removed.	Not removed.
K., 3,930...	Abdominal hysterectomy.	Normal.	Normal.	Normal.	Normal.
S., 2,405...	Hysterectomy.	Delicate adhesions.	Delicate adhesions.	Delicate adhesions.	Delicate adhesions.
H., 2,294...	Vaginal hysterectomy.	Not removed.	Not removed.	Normal.	Normal.
W., 2,728...	Combined abdominal and vaginal hysterectomy.	Normal.	Small transparent cyst 2.5 x 2 centimetres.	Normal.	Normal.
D., 3,666...	Abdominal hysterectomy.	Tubercular peritonitis.	Commencing tuberculosis.	Small cyst.	Commencing tuberculosis.	Normal.
R., 2,964...	Combined abdominal and vaginal hysterectomy.	Covered by adhesions.	Covered by adhesions.	Covered by adhesions.	Covered by adhesions.
H., 3,126...	Combined abdominal and vaginal hysterectomy.	Normal.	Normal.	Normal.	Normal.
P., 5,959...	Combined abdominal and vaginal hysterectomy. Resection of a portion of the bladder.	Normal.	Slightly adherent.	Slightly adherent.	Normal.
H., 3,348...	Hysterectomy.	Normal.	Normal.	Normal.	Normal.
H., 3,369...	Hysterectomy.	Normal.	Normal.	Normal.	Normal.
S., 5,092...	No operation.	The tubes and ovaries are covered with conglomerate tumour masses, and the ovaries are nearly twice the normal size.			
V., 4,228...	Curettement.	On histological examination, carcinoma was found in the substance of the left ovary (Fig. 78). The identity of the tubes and ovaries is lost in the carcinomatous tissue.			

Total number of cases examined, 31.

Total number of cases in which the tubes and ovaries were normal, 10.

Condition of the Tubes.—From the table it will be seen that out of the thirty-one cases, in fourteen both tubes were normal. In two cases the tube on one side was adherent, while that on the opposite side was free.

In four cases where only one tube was removed, two were free from adhesions and two were adherent. Six cases showed adhesions on both sides. In one case there was double hydrosalpinx, in another hydrosalpinx on one side. Both tubes in a case of tubercular peritonitis showed commencing tuberculosis. Thus in thirty-one cases nearly half the tubes were perfectly normal, and those that were

affected showed merely slight, or at most dense, adhesions. The presence of the tuberculosis may be looked upon merely as a coincidence. Case 4,328 exhibited an unusually instructive picture, the right tube being involved in the carcinomatous process (Fig. 84). As will be noted from the description of the gross specimens, the appendages were enveloped in adhesions and no carcinomatous involvement was suspected, but on microscopic examination the growth was found not only just beneath the peritoneal covering of the tube, but could be traced as cell-nests penetrating the muscular coats and folds of the mucosa almost as far as the fimbriated extremity.

From such a small list of cases it is not wise to make any dogmatic statement, but I think we may safely conclude that the carcinoma only rarely affects the tubes.

Condition of the Ovaries.—In over half of these cases both ovaries were free from adhesions, and on microscopic examination revealed nothing abnormal. The remainder were covered by adhesions, some of which were very delicate, others being dense, and binding the organ down firmly to the surrounding structures. In case 4,176 the right ovary contained a small papilloma. Case 2,572 showed a corpus luteum cyst of the right ovary, 5 centimetres in diameter. In Case 2,728 the right ovary contained a transparent thin-walled cyst, 2.5×2 centimetres.

A dermoid cyst, 2.5 centimetres in diameter, was found in the left ovary in Case 3,609.

In three cases—namely, 2,885, 5,092, and 4,228—there was carcinomatous involvement of the ovary, but, as will be noted from the table, all of these were inoperable cases, and the invasion of the ovary was by continuity from the original growth. Fig. 78 (p. 140), taken from Case 5,092, demonstrates very well the appearance of squamous-cell carcinoma in the ovary. Scattered throughout the ovarian stroma are the corpora fibrosa, *b*; *c* is a blood-vessel; *d* is a nest of cancer cells. The nuclei of these are, as a rule, uniform in size, but at *e* are giant cells, and at *f* the nuclei contain an increased amount of chromatin; *g* indicates another group of cancer cells.

From these results we can safely say that in operable cases of squamous-cell carcinoma of the cervix involvement of the ovary is rare.

A Case showing Carcinomatous Infiltration of One Fallopian Tube

Gyn. No. 4,328. Squamous-cell carcinoma of the cervix; extension to the vagina; secondary invasion of the left Fallopian tube (Fig. 84); pelvic peritonitis; hysterectomy. Recovery. Patient lost sight of; probably dead.

A. J., aged forty-five; white. Admitted April 25, 1896. Complaint: slight uterine hæmorrhage; a burning sensation in the vagina.

The patient has been married twenty years, and has had two normal labours. Her menses have always been regular; the last period commenced three days before admission. One paternal aunt died of carcinoma; otherwise the family history is good.

Three years ago she noticed a thin, watery discharge. This occurred at frequent intervals and continued to be of the same character until a year ago, when it became much thicker. Last summer she was troubled with an ill-defined weakness, suffered from insomnia, and had no appetite. Four months ago, when walking, she had a sensation as if something were dropping out of the vagina, and thought that there was a lump there. Although she had no pain she consulted a physician, who told her that she had carcinoma. She is somewhat anæmic; the appetite is fair; the bowels are constipated. The vaginal outlet is relaxed, and the cervix is occupied by a flat, eroded growth, which extends backward into the vaginal vault and involves the vagina anteriorly.

The fundus is freely movable, and the appendages appear to be normal.

Operation, April 29th. As preliminary treatment, all the redundant portions of the growth were removed with a sharp curette. Hysterectomy was subsequently performed, and the patient left the hospital June 25, 1896.

Gyn.-Path. No. 1,184. The specimen consists of the uterus with intact appendages. The organ measures $9 \times 6 \times 6.5$ centimetres; the anterior surface is smooth and glistening; the posterior aspect is covered by a few delicate, vascular adhesions. The cervix on pressure gives a sensation of stony hardness; the lips are thickened and everted, and the vaginal portion has a whitish or bluish, glazed appearance. On the right side the mucosa has disappeared over an area 2×1.5 centimetres; here the surface presents an ulcerated appearance, the irregularity extending to the cut margin. On the left side the mucosa is also wanting, and in its place are delicate semitranslucent papillæ. The external os is 2 centimetres in width, and presents a somewhat eaten-out appearance. On cutting into the cervix, the lower portion, for 1 centimetre, is found to be covered by delicate papillary-like masses, and the tissue in all directions has been invaded by a new growth, which extends upward at least as far as the internal os. Its advancing margin appears to be sharply defined. On the left side it has penetrated the entire thickness of the cervical wall, and over an area 2×3 centimetres involves the adipose tissue just above the vaginal vault. The uterine cavity is 4.5 centimetres in length; its mucosa, which is smooth and glistening but slightly hæmorrhagic, averages 4 millimetres in thickness.

The appendages on both sides are covered by a moderate number of adhesions.

Histological Examination.—The squamous epithelium covering the vaginal portion of the cervix is to some extent intact, but after tracing it for a short distance is found to dip into the underlying stroma. Where such an invasion has taken place, the cells have become larger. Involving the cervical tissue in all directions are irregular alveoli or bunches of small alveoli, filled with cells which have oval, round, or irregular nuclei that stain fairly deeply. Some of the nuclei are exceedingly large and may be composed of coarse granules, giving to the nucleus a mulberry-like appearance. Others of the cells contain two or more nuclei. Upward the alveoli can be traced beyond the internal os; outward, especially along the left side, they reach the cut margin of the specimen. Portions of the growth have without a doubt been left behind.

In this case the stroma of the tissue shows little, if any, small-round-cell infiltration. This observation is not rare in those cases in which the growth is exceedingly rapid. Those of the cervical glands which are still preserved are normal. The uterine mucosa has an intact surface epithelium; its glands are scanty, but present the usual appearance; the stroma shows considerable small-round-cell infiltration.

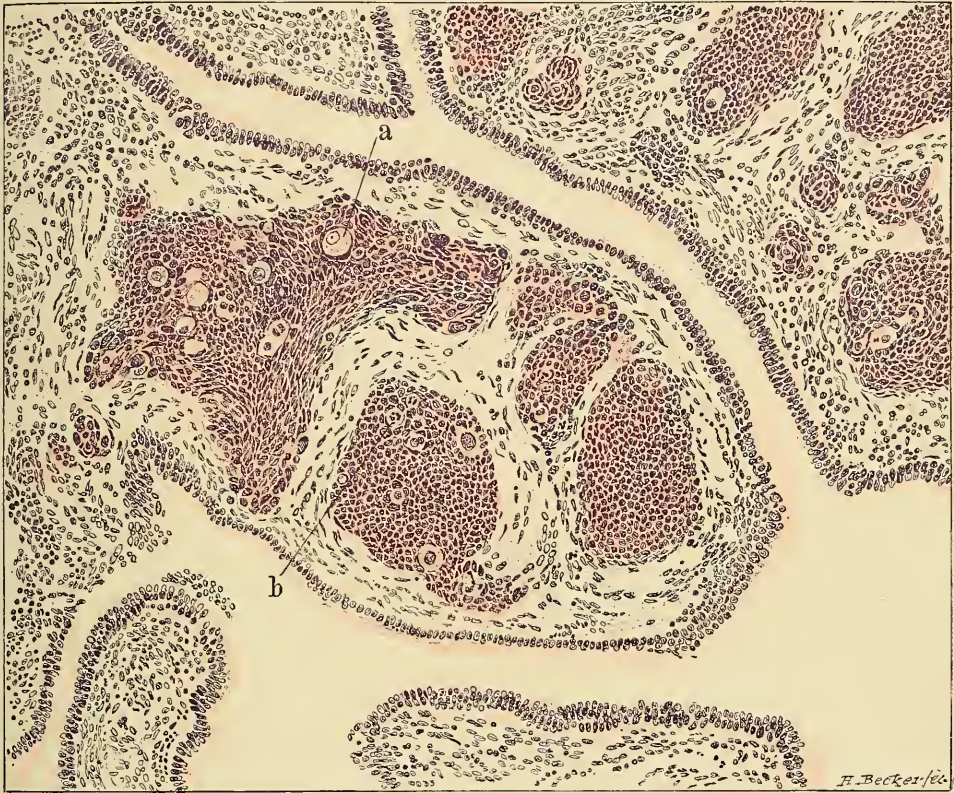


FIG. 84.—CARCINOMA OF THE FALLOPIAN TUBE, SECONDARY TO SQUAMOUS-CELL CARCINOMA OF THE CERVIX. (175 diameters.)

Gyn.-Path. No. 1,184. The section is taken from the right tube at a point midway between the uterus and fimbriated extremity. Occupying the central portion of the field is a greatly enlarged tubal fold, surrounding which are portions of other folds. They are covered by a single layer of low cylindrical epithelium, although in many places, owing to the obliquity of the section, there appear to be several layers. The stroma of the folds consists of cells having oval, or spindle-shaped, vesicular nuclei, and in some places shows infiltration with small round cells. Scattered throughout the stroma of the large fold, and that occupying the upper right corner, are large and small dark areas, composed of masses of cancer cells. The nuclei of these are in most places fairly uniform in size, although somewhat irregular in contour, probably because they are so closely packed together. At some points they are large and irregular, and contain much chromatin. At several points are vacuoles containing isolated epithelial cells. A typical example is seen at *a*. Some of the vacuoles contain polymorphonuclear leucocytes; for example, *b*. No breaking down of tissue has taken place.

On the right side the tube at the uterine cornu is normal. A section midway between the uterus and the fimbriated extremity, however, just beneath the peritoneum, at one point shows a large irregular area composed of cells of the new

growth, and in the vicinity of the fimbriae both the muscular coats and the folds of the tubal mucosa are studded with nests of carcinomatous cells (Fig. 84). Portions of the right ovary examined are negative, as are also sections from the left tube and ovary.

Diagnosis.—Squamous-cell carcinoma of the cervix. Extension to the left broad ligament. Secondary involvement of the right tube.

January 1, 1900. The patient cannot be found.

LYMPH GLANDS INVOLVED IN SQUAMOUS-CELL CARCINOMA OF THE CERVIX

From the description of the normal distribution of the lymphatics of the uterus (p. 15) we should expect to find the gland on each side of the cervix involved, should it be present, after which we should look for secondary growths in the iliac glands. As a matter of fact the glands are not often involved, at any rate only very rarely before the disease has advanced so far that the case has become inoperable. Winter,* who has paid much attention to recurrence of carcinoma of the cervix, says that the lymph glands are involved very late. Thus, in forty-four autopsies on patients where the disease was still confined to the uterus, the glands were involved only in two cases. One of these was a carcinoma of the cervix showing secondary growths in the iliac glands, the other a carcinoma of the body with metastases in the lumbar glands. According to Winter, the carcinoma first commences to invade the lymph glands when it has extended into the broad ligaments. The glands may be only slightly enlarged or reach the size of an apple. They usually have an intact capsule. From our experience with those cases in which operation was feasible, only one showed any glandular involvement. In Case 4,070 (p. 160) several small nodules were found near the pelvic wall. These were hæmorrhagic and firm, and on histological examination were found to contain metastases. On examining Fig. 86 (p. 161) it is interesting to see how closely the secondary growth resembles the primary one. Not only are the cells similar, but in the outer layer still show a cuboidal shape.

Fig. 85 is from a case in which hysterectomy was attempted but abandoned. The iliac glands were enlarged, and on histological examination showed metastases. The section is particularly interesting from the fact that typical epithelial pearls are seen in the lymph gland, the metastatic growth being a faithful copy of the primary tumour.

Even in those cases in which no operation had been performed and the patients came to autopsy, only three showed secondary growths in the lymph glands. These were the Cases Nos. 518, 4,374, and 5,092. In Case 518 the pelvic and mesenteric glands were enlarged and microscopic examination revealed carcinomatous involvement. In Case 4,374 (p. 151) the iliac glands on both sides were enlarged, one measuring $5 \times 3 \times 2$ centimetres. On histological examination the increase in size was found to be due to metastatic deposits.

* Winter, G. *Ueber die Recidive des Uteruskrebses, insbesondere über Impfredidive.* *Zeitschr. f. Geburtsh. u. Gynäk.* (1893), Bd. xxvii, S. 101.

Case 5,092 (p. 132) showed a most remarkable glandular involvement, the iliac and inguinal glands being nearly as large as hens' eggs. The central portions of these glands had become necrotic, and on histological examination only the capsule and a small zone of carcinomatous tissue were still preserved. The retroperitoneal, mesenteric, and bronchial glands were also involved.

It is highly probable that in the early stages of squamous-cell carcinoma of the cervix the glands are rarely involved. This conclusion is borne out by our present studies, although as yet the number of glands examined does not warrant us in speaking positively. By a systematic examination of the glands in all cases in which the radical operation is performed this question can very soon be settled.

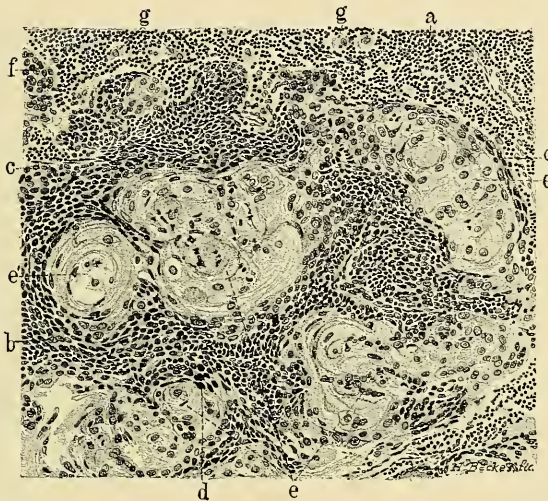


FIG. 85.—METASTASES IN A PELVIC LYMPH GLAND FOLLOWING SQUAMOUS-CELL CARCINOMA OF THE CERVIX. (120 diameters.)

Gyn.-Path. No. 1,700. *a* indicates the normal lymphoid tissue. *b* is the carcinomatous growth. *c* shows the line of junction between the gland tissue and the carcinoma. The nuclei of the cancer cells are oval or triangular, and stain uniformly; but occasionally a nucleus is a little larger than its fellows and stains intensely. At *e, e'* typical epithelial pearls are visible, in some places showing the flattened squamous cells. At other points the concentric or pearl-like arrangement is seen. *f* is a small nest of the growth. *g* indicates isolated and slightly swollen cells, so frequently noted in the gland in which some inflammatory process exists, but in which carcinoma can be excluded. They are not epithelial cells. This section is particularly interesting on account of the fidelity with which the tumour has reproduced itself in the secondary growth, even the pearls being present.

We know that in the majority of cases of carcinoma of the breast metastases to the axillary glands occur early, and the question may justly be asked, Why are not the iliac glands soon involved in cancer of the cervix? In answer to this it may be pointed out that in the breast the lymphatics are not only exceedingly abundant and active, but the carcinomatous cells are frequently small, and hence they could easily enter the lymph radicals and be swept on to the lymph glands. In the uterus, on the other hand, the epithelial cells are on an average much larger, too large, in all probability, to enter the lymph radicals. Hence the growth must extend out into the broad ligament and break into a large lymph channel before the cells can reach a lymph gland.

Cases illustrating the Extension of Squamous-cell Carcinoma of the Cervix to the Lymph Glands

Gyn. No. 4,070

Squamous-cell carcinoma of the cervix; extension to the pelvic lymph glands (Fig. 86); hysterectomy. Death.

E. P., aged forty-three; white. Admitted January 11, 1896. Complaint: constant bloody vaginal discharge; pain in the lower part of the abdomen and across the bladder.

The patient has been married twenty-six years, but has never been pregnant. Her menses began at thirteen, and have always been regular and moderate in amount; the last period began January 1, 1896. Her family history is unimportant.

Two years ago she had a sharp cutting pain in the left side of the abdomen just above the pubes, which has frequently recurred. The pains may be sharp and shooting, or dull in character. When they come on, the patient invariably flexes the thigh on the abdomen, as she experiences some relief in this position. During the two years she has had an almost constant aching sensation in both lumbar regions. For a number of years there has been a profuse, yellowish-green, irritating vaginal discharge, which since the beginning of this illness has been tinged with blood, and is at times of a bright-red colour. Latterly the flow has been watery.

Two weeks before admission the cervix was curetted; the patient has lost flesh, but is fairly well nourished; her appetite is good; the bowels are constipated; micturition is frequent and followed by pain and burning, and there is also pain if she holds her urine for any length of time.

The vaginal outlet is intact; the cervix is converted into a mere shell, with jagged, ulcerated margins. The uterus is freely movable; the broad ligaments are apparently not implicated, but considerable pain in the left ovarian region follows examination.

Operation, January 15th. Abdominal hysterectomy. Immediately after operation the patient became almost pulseless, her face was cyanosed, and the extremities were cold. Stimulants were administered hypodermically, the foot of the bed was elevated, and hot-water bags were placed around her. On the 19th her condition had materially improved, and the vaginal pack was removed. January 22d.—For three days she has complained of incontinence of urine; her temperature and pulse have been slightly elevated, and she has been decidedly drowsy. January 24th.—The incontinence is very marked, the vulva is excoriated and swollen, the circulation poor, and the urine blood-stained. February 1st.—The incontinence continues about the same. The bladder is being irrigated with boric-acid solution.

The patient gradually became weaker, and died on the twenty-ninth day after operation.

Gyn.-Path. No. 1,036. The specimen consists of the uterus, tubes and ovaries, broad ligaments, and a small cuff of vaginal mucosa. The cervix has been completely destroyed by the new growth, which posteriorly has extended to the vaginal vault. The growth terminates abruptly at the junction of the cervix and body; the broad ligament does not appear to be involved except on the right side

near the pelvic wall, where there were several minute nodules, the largest of which measures about 5 millimetres in diameter. On section these appear slightly hæmorrhagic. The appendages present nothing of importance.

On histological examination the growth is found to be a typical squamous-cell carcinoma of the cervix. The largest of the nodules found near the pelvic wall in the right side is a small lymph gland, which is occupied by several nests of epithelial cells (Fig. 86). These are cut transversely or longi-

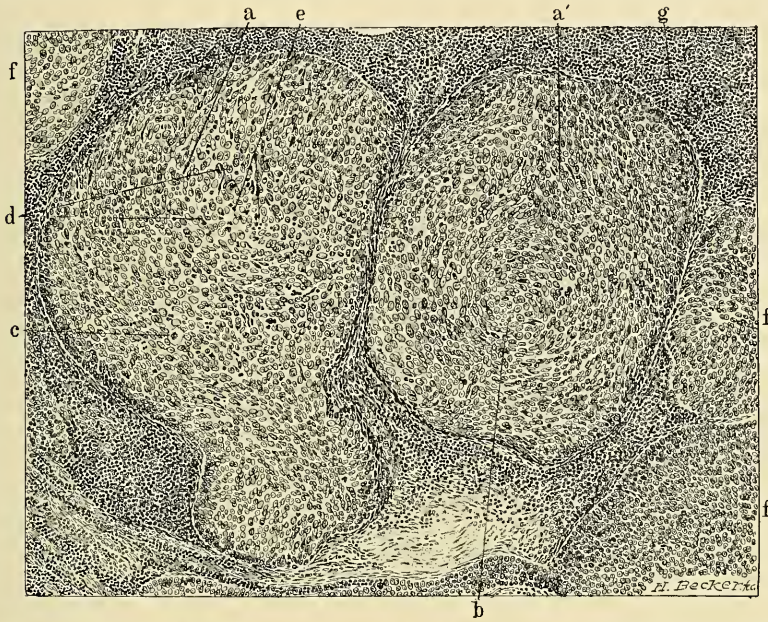


FIG. 86.—CARCINOMA OF A PELVIC LYMPH GLAND SECONDARY TO SQUAMOUS-CELL CARCINOMA OF THE CERVIX. (125 diameters.)

Gyn-Path. No. 1,036. Occupying almost the entire field are two epithelial nests, *a, a'*. The majority of the nuclei are oval, vesicular, and uniform in size. In *a* the outermost layer of epithelium still shows a tendency toward the cuboidal type. At *b* the nuclei show a slight tendency to form whorls. *c* is a cell showing nuclear division. At *d* the nuclei are slightly enlarged, and contain an excess of chromatin. Polymorphonuclear leucocytes and small round cells have wandered in between the epithelial elements, as is indicated at *e*. Portions of other cell-nests are seen at *f*. *g* is the normal lymphoid tissue of the gland, consisting of myriads of small round cells.

The cell-nests here depicted are typical, and the condition could not be mistaken for any inflammatory process. For the formation of epithelial pearls, see Fig. 85.

tudinally, the outermost layer being arranged at right angles to the cavity, the epithelium being of the low cylindrical type. The cells in the central portion are closely packed together, have oval, deeply staining nuclei, and are comparatively uniform in size. Some cells contain nuclear figures, and occasionally a small round cell has wandered in between the epithelial elements. In the centre of some of these nests the cells tend to form whorls; in others they have become somewhat flattened and afford an appearance suggestive of hornification. The surrounding lymph cells are practically unaltered. It is interesting to note this faithful reproduction of the mother type in the metastases in the lymph glands.

Gyn. No. 518

F. D. Autopsy No. 178. March 11, 1891. Squamous-cell carcinoma of the cervix; implication of the bladder and posterior mesenteric glands. Hydronephrosis. Chronic nephritis. Pneumonia in the posterior parts of lower lobes of both lungs. Slight pleurisy.

Microscopical examination of the pelvic and mesenteric lymph glands shows carcinomatous involvement.

SO-CALLED ACUTE HYPERTROPHY OR ACUTE SWELLING OF THE LYMPH
GLANDS

Walshe,* in his book on *The Nature and Treatment of Cancer* (1846), says that the lumbar glands are much more rarely diseased and are often enlarged and red without containing a particle of carcinoma. He gives Bayle credit for having noted this fact. Wagner, in 1858, stated that this hypertrophy is very frequent, and probably occurs in all cases. It usually affects the lumbar, and more rarely the pelvic glands. The enlargement is due to an abnormal absorption of lymph, and to an increase in the size of the blood-vessels.

In one of our cases an iliac gland, fully 2.5 centimetres in diameter, was dissected out after a hysterectomy, on the supposition that it was carcinomatous. Its substance was soft, yellowish, and looked somewhat like fat; on microscopic examination it contained not the slightest trace of carcinoma.

The endothelium of the blood-vessels is swollen, and in places has proliferated. There is also an increase in the size of the lymphoid cells.

It is quite natural that with the absorption from the necrotic and sloughing surface of the growth the glands should show some reaction. Dr. Sydney Cone † has been much interested in the condition of the lymph glands in carcinoma of the breast; he finds that a similar glandular enlargement frequently takes place without carcinomatous involvement.

GENERAL APPEARANCE OF THE BODY AT AUTOPSY IN SQUAMOUS-CELL
CARCINOMA OF THE CERVIX

Wagner, who had rare opportunities of seeing these cases at autopsy, states that in the majority the skin is of a dirty gray or yellowish colour, and that when the disease has not advanced very far, there may be considerable and, in some instances, even large quantities of fat.

This has been our experience not only at autopsy, but with the living patients, some being very thin, others exceedingly stout. It is necessary to give only a few illustrations.

In Case 2,885 at autopsy there was some œdema of the ankles, and the omentum was richly loaded with fat, notwithstanding that the disease had advanced far enough for the production of a vesico-vaginal fistula.

In Autopsy No. 701, on the contrary, the body was emaciated.

* Walshe, W. H. *The Nature and Treatment of Cancer*, London, 1846.

† Personal communication.

In Case 4,491 there was also a vesico-vaginal fistula, but the body was "strongly built and not emaciated." Thus it will be seen that no hard-and-fast statement can be made, the body being sometimes emaciated, at other times containing much adipose tissue.

Wagner found that in quite a number of cases bedsores occurred. Virchow reports in one case of carcinoma of the cervix the existence of an enormous bed-sore over the coccyx, which had involved the soft parts to a great depth. The uterus was adherent to the rectum, and the spermatic vein on the left side was occluded, as far as its entrance into the renal vein, by an organizing thrombus. Fortunately, in recent years so much attention has been paid to measures for the prevention of bedsores that they are now very rarely met with.

THROMBI IN THE VEINS WHERE SQUAMOUS-CELL CARCINOMA OF THE CERVIX EXISTS

We have not had a sufficient number of autopsies to reach any definite conclusion as to the frequency of venous thrombi in squamous-cell carcinoma. Wagner, however, claimed that they are present in about one third of all fatal cases, and that the vessels most frequently thrombosed are the utero-vaginal and the vesical plexus. In his Case XXXI—extensive carcinoma of the cervix and vagina, with secondary involvement of the pelvic, retroperitoneal, anterior and posterior mediastinal, supraclavicular and inguinal glands—there was a thrombus in the inferior vena cava, which contained large quantities of pigment, and carcinoma cells similar to those of the neoplasm in the uterus. In Wagner's Case XV—an advanced carcinoma of the cervix involving the vagina and bladder—the vena cruralis on each side contained a clot. That on the left side filled the vessel completely, and in places was grayish-yellow and friable. Virchow's* case, in which the patient had a large bed-sore and thrombosis of the left spermatic vein, has already been referred to elsewhere. R. Burk,† in a case of von Säkinger's, found purulent infection in the veins of the pelvis. The patient died of metastatic pneumonia.

CONDITION OF THE KIDNEYS IN ADVANCED SQUAMOUS-CELL CARCINOMA OF THE CERVIX

As might be surmised from the foregoing study of the ureters, the kidneys are often altered. The most frequent pathological changes found are:

1. Hydronephrosis.
2. Pyonephrosis.
3. Chronic diffuse nephritis.

Hydronephrosis.—On account of the ureteral constriction the pelvis of the kidney is gradually dilated, the calices also sharing in the distention and unfolding, until the kidney is converted into a smooth, oval cyst, reaching 10 centimetres or more in diameter. The inner surfaces of such cavities are usually smooth and glistening, and the urine is normal. Wagner frequently found such a condition

* Virchow, R. *Monatshr. f. Geburtskunde u. Frauenkrankh.* 1857, Bd. x, S. 244.

† Burk, R. *Pyämie bei Carcinom des Uterus. Inaug.-Dissert., Tübingen, 1893.*

present, and, as before mentioned, R. Williams, in seventy-eight autopsies, met with hydronephrosis in sixty-seven cases. In all of our nine cases the kidneys were altered, and in six of them hydronephrosis was present (*cf.* Nos. 2,885 (p. 166), 3,463 (p. 141), 518 (p. 162), 4,491 (p. 145), 6,388 (p. 128), Autopsy 333 (p. 173)).

Pyonephrosis.—Given a hydronephrosis, it is very easy to understand how, with the stagnation and damming back, to which is frequently superadded a vesico-vaginal fistula, the urine in the ureter may become infected, after which the inflammatory process is conveyed to the pelvis of the kidney, with the result that it is converted into a virtual pus sac. Nay, more, the purulent infection may extend along the tubules and give rise to large and small abscesses throughout the kidney parenchyma. It is not unusual to find the pelvis of one kidney filled with pus, while that of the other contains normal urine. In Case 4,374 there was a pyonephrosis, and Autopsy No. 701 showed small abscesses throughout the kidney.

Nephritis.—As a result of the damming back of urine, and again from the pyonephrosis, there is a chronic inflammatory change started in the kidney. This is chiefly characterized by the increased amount of connective tissue and the small-round-cell infiltration.

Thus it is evident that in advanced squamous-cell carcinoma of the cervix renal disease is invariably present. Williams said that in all of his cases the kidneys were extensively involved.

Chronic Nephritis, with the Formation of Miliary Abscesses in the Course of Squamous-cell Carcinoma of the Cervix

A. J. Autopsy No. 701. August 1, 1895. Anatomical diagnosis: Squamous-cell carcinoma of the cervix extending to the vagina and bladder; vesico-vaginal fistula; left chronic interstitial nephritis; right acute pyelonephritis with multiple miliary abscesses; fatty degeneration and cloudy swelling of the liver and kidneys.

Abstract from protocol: The body is slightly built and is emaciated. Over the sacrum are three small bedsores, and over the right trochanter is a fourth. The peritoneum is smooth and glistening; the abdominal cavity is dry. The cervix is infiltrated with a soft fungating new growth, which springs from its outer surface. The portion of the growth projecting from the right lip lies free in the vagina, while that on the left side is adherent to the vaginal wall, which is involved from the vault almost to the vulva. Through the centre of this mass is a channel, which communicates with the bladder. The appendages are apparently normal. The mucous membrane of the anterior and lateral portions of the bladder is deeply congested and somewhat thickened. The posterior wall, from the base of the trigonum to the summit, is occupied by a fungating mass, measuring 5×3 centimetres. The mass is raised above the level of the mucosa, is of a brain-like consistence, and has a circular opening which communicates with the vagina. The right ureter is

dilated to the size of a lead pencil, and the kidney is dotted over with numerous yellowish-white, pin-head areas, which are slightly elevated and in various places surrounded by a zone of congestion. Throughout the cervix are numerous similar areas. The pelvis of the kidney is somewhat dilated. On histological examination the cervical growth presents the typical appearance of squamous-cell carcinoma, and the tumour cells show fatty degeneration.

Cover-slips from the miliary abscesses in the kidney brought out (1) short, plump bacilli, (2) small cocci in pairs, (3) a few fine bacilli. After repeated cultivations it was possible to isolate only one organism; this responded to the reactions for *B. coli communis*.

DILATATION OF THE URETERS ACCOMPANYING ADVANCED SQUAMOUS-CELL CARCINOMA OF THE CERVIX

This is very common, and usually takes place where the morbid process advances far laterally. Dilatation may be unilateral or bilateral, and may follow several conditions:

1. Inflammatory reaction along the advancing margin of the growth, giving rise to adhesions and binding the ureter down.
2. Pressure of the growth or of an enlarged carcinomatous gland, partially obliterating the lumen of the ureter.
3. The involvement of the ureter by continuity.
4. Extensive involvement of the bladder in the vicinity of the ureteral orifices, partially occluding them.

5. Pressure on a ureter by a constricting band; a rare occurrence, but well shown in Case 2,885. Here, a short distance from the kidney, the ovarian vein (Fig. 90) crossed and markedly constricted the ureter. The point of constriction, as Wagner points out, is usually near the bladder. The dilatation is greatest at the point of constriction, and decreases as one approaches the kidney. Wagner says that at times the ureter may reach the size of the small intestine, and in our Case 2,885 the right ureter was 3 centimetres in diameter (Fig. 89). In some instances there is an elongation of the ureteral mound, and there may be a distinct ureteral prolapse. The ureteral dilatation, in Wagner's statistics, occurred in one third of the cases. Williams, who gives the records of 78 autopsies, found 67 instances of hydronephrosis, 57 of which were bilateral. We may conclude, therefore, that in the majority of his cases the ureters were dilated, as ureteral constriction is generally the cause of hydronephrosis.

In the 8 autopsies, from which I have had the opportunity of examining specimens, all showed either dilatation of the ureters or of the pelves of the kidneys.

Simple constriction of the ureter produces dilatation above the point of narrowing, with a damming back of the urine, which presents the usual colour. In some cases, from the passage upward of organisms which is very apt to occur in these cases, since a vesico-vaginal fistula is so often present, the ureteral tract becomes infected, and instead of being normal, the urine is mixed with pus, and we have a pyonephrosis. In these cases the ureter on one side may contain pus, while that of the opposite side, although dilated, contains normal urine. When

the ureter has been invaded by the carcinoma, the usual process of disintegration follows and a fistula results. The opening rarely takes place into the peritoneal cavity, but more often into the vaginal vault, with a resulting uretero-vaginal fistula.

Case of Double Hydroureter due to Compression caused by a Squamous-cell Carcinoma of the Cervix

Gyn. No. 2,885

June, 1894. Squamous-cell carcinoma of the cervix; pyometra (Fig. 87); invasion of the broad ligaments; curettage, with evacuation of one ounce of pus from the uterine cavity.

March, 1896. Extension of the carcinoma to the vagina and bladder; vesico-uterine fistula (Fig. 88); double hydro-nephrosis and hydroureter (Figs. 89 and 90); arteriosclerosis; cardiac hypertrophy; recent vegetative endocarditis; emphysema of the lungs.

M. D., aged sixty-two; white. Admitted June 29, 1894. Complaint: uterine hæmorrhages; bearing-down pain in the back and in the lower abdomen.

The patient has been married forty-two years, and has had eight labours, all of which were normal. The menopause occurred four years ago. Her family history is tuberculous, but she herself, until the present illness, has always been well and active.

For the last two years the patient has at times experienced cramp-like pains in the back and legs. In August, 1898, she noticed an occasional, slight, bloody discharge from the vagina. This continued until February of this year, when there was a profuse hæmorrhage, associated with labour-like pains and the expulsion of large clots. Since then there has sometimes been a slight hæmorrhage; the pain in the back and lower abdomen has steadily increased, and occasionally radiates down the left thigh.

The patient is fairly well nourished and has a good complexion; she sleeps poorly and is nervous at times; her appetite is good, but her bowels are constipated.

On vaginal examination the outlet is found to be considerably relaxed; the cervix is flush with the vaginal vault. The os is patulous, and on examination a roughened friable surface is met with. On introducing the finger into the uterine cavity there was a discharge of about one ounce of pus. The uterus was immovable, and the disease had extended out into both broad ligaments. The examination occasioned considerable hæmorrhage. The uterus was curetted and then packed with gauze. The patient left the hospital July 10, 1894, feeling fairly well.

Gyn.-Path. No. 365. The specimen consists of uterine scrapings, one piece of which measures 3 millimetres in thickness. Springing from the surface of the piece examined is a slightly branching papillary-like fold, which is covered externally by two or more layers of cylindrical epithelium. Projecting from it

are younger papillary folds. The immediately subjacent tissue contains a number of small gland-like spaces lined in most places by two or more layers of epithelium, but in some places by a single layer. In the stroma are alveoli filled with oval, somewhat deeply staining nuclei. Some of these alveoli are sharply cut; in the majority the cells seem to be scattered through the alveolus, not completely filling it. In some places they lie just along the margins, the central

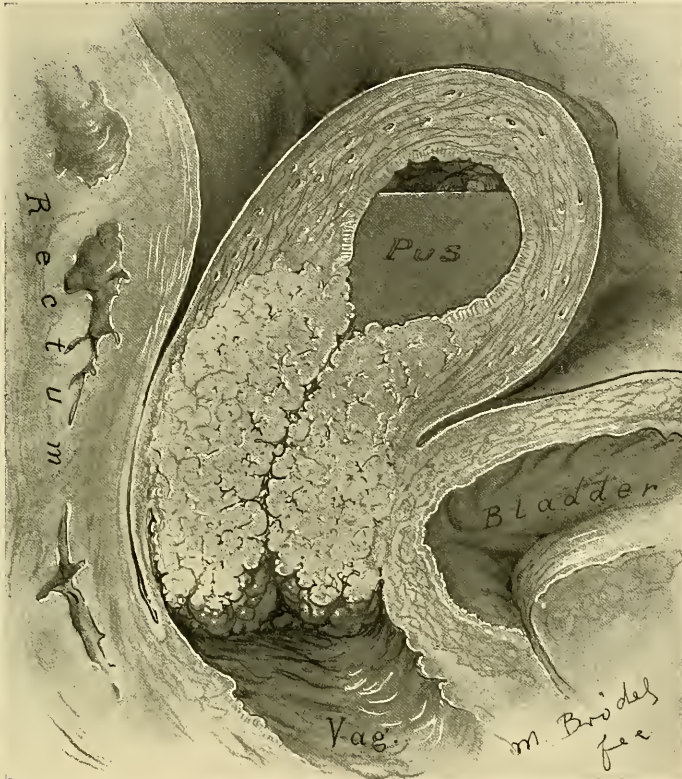

FIG. 87.—PYOMETRA COMPLICATING SQUAMOUS-CELL CARCINOMA OF THE CERVIX. (Natural size.)

Gyn.-Path. No. 365. This is a schematic representation of the conditions found in Case 2,885. The entire cervix and part of the body are occupied by the new growth. The cervical canal is obliterated, and the small uterine cavity is partially filled with pus—a pyometra. The growth is still limited to the uterus. See Fig. 88 for the subsequent extension.

portions being empty. The stroma shows considerable small-round-cell infiltration. From the description it is seen that the growth is a carcinoma, but whether it be a squamous-cell cancer or an adeno-carcinoma it is difficult to say. Taking into consideration the presence of the papillary-like masses with the underlying glands, and the fact that the alveoli are only partly filled with cells, we are inclined to classify it as an adeno-carcinoma.

Diagnosis.—Probable adeno-carcinoma of the cervix. Subsequent examination, as will be seen, proved that we were incorrect in our supposition, as the growth was a squamous-cell carcinoma.

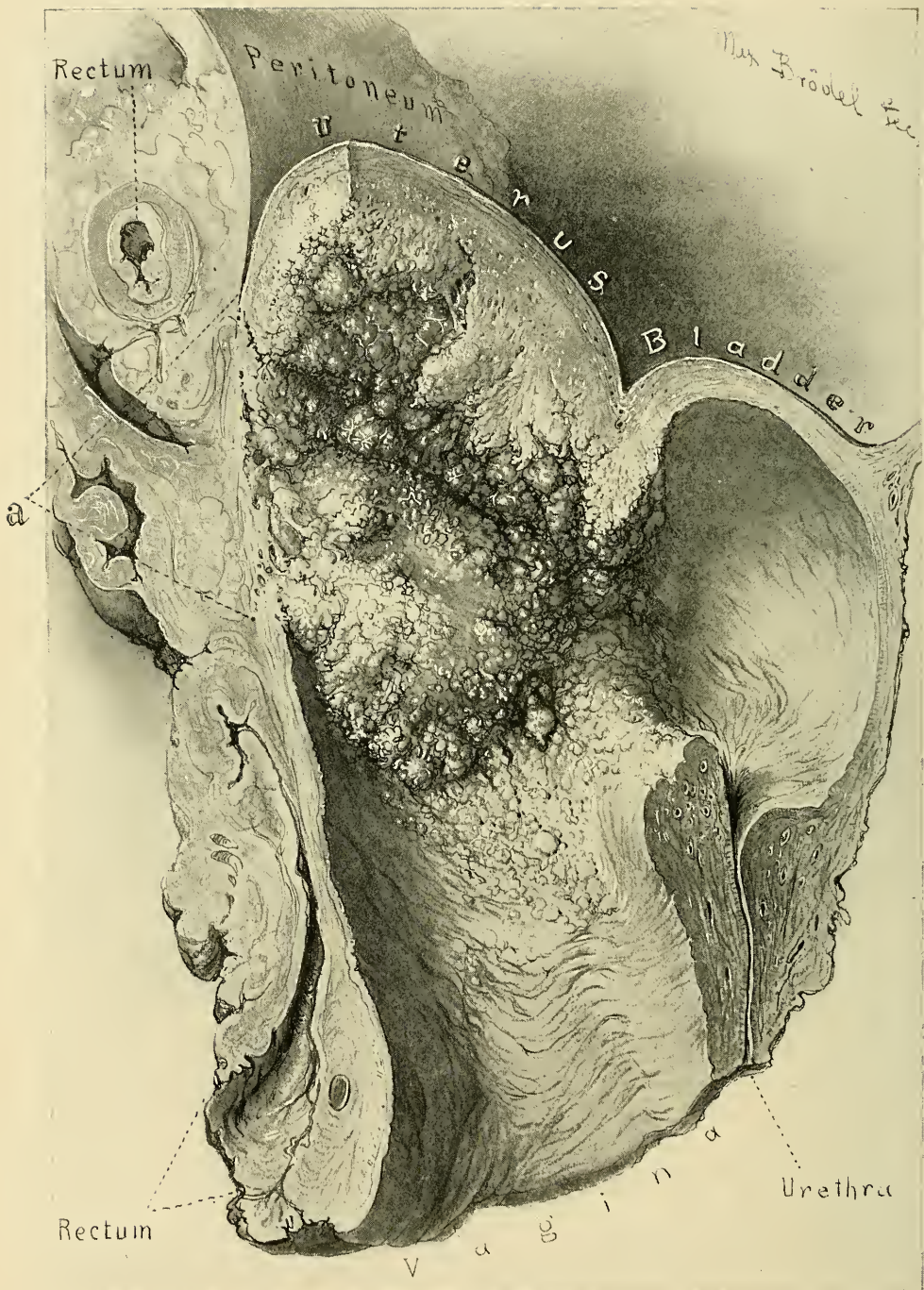

FIG. 88.

Readmission, January 2, 1896. Since leaving the hospital she has never been entirely well. In June, 1895, micturition became frequent and painful, and the patient thinks that at times there was some blood in the urine. During the last year she has lost considerable flesh, and has complained of pain in the epigastrium. Three weeks ago she had a thin, blood-stained, vaginal discharge, and had a similar flow three days before admission. The patient's condition became gradually worse, and she died March 2, 1896.

Autopsy, No. 779. Anatomical diagnosis: Squamous-cell carcinoma of the cervix involving the vagina and bladder; vesico-uterine fistula; double hydro-nephrosis and hydroureter; arteriosclerosis; heart hypertrophy; recent vegetative endocarditis; emphysema of the lungs.

An abstract from the protocol is as follows: There is some œdema of the ankles. The omentum covers the entire anterior portion of the abdominal cavity and is richly loaded with fat. The uterus is slightly enlarged; both anteriorly and posteriorly it is covered by a few adhesions. The lower portion of the vagina is smooth, but after passing upward a short distance, the left side presents a roughened and worm-eaten appearance. The cervix has entirely disappeared, and the uterus appears as a mere shell (Fig. 88). Occupying this excavated area is broken-down friable tissue. The growth has extended laterally almost to the peritoneal surface of the uterus, and anteriorly has eaten through the bladder wall, there being a fistulous opening into the bladder about 2 centimetres posterior to the internal orifice of the urethra, the sinus communicating with the uterus at a point corresponding to the internal os. Posteriorly the growth has extended entirely through the uterus, but adhesions have formed between the peritoneum of Douglas's cul-de-sac and the posterior surface of the uterus, thereby preventing any communication between the uterine and pelvic cavities.

The appendages on the right side are little altered; those on the left are bound down by adhesions, and have been implicated in the extension of the growth.

FIG. 88.—A LATE STAGE OF SQUAMOUS-CELL CARCINOMA OF THE CERVIX. (Natural size.)

Gyn.-Path. No. 1,092. A sagittal section of the pelvic organs. Without the bladder and rectum for landmarks a recognition of the uterus would be impossible. The cervix and the greater part of the body have entirely disappeared, being replaced by a friable and crumbly-looking growth with many delicate finger-like processes springing from its surface. Upward, the growth has extended to the fundus, and is fairly well outlined from the narrow zone of normal muscle. Downward, the vaginal extension is seen in the form of large and small wart-like elevations. Along the advancing margin small isolated foci are present. Anteriorly, the carcinoma has made great inroads upon the bladder. Almost its entire floor has not only been infiltrated, but has broken down, leaving a fistula, fully 2.5 centimetres in diameter, and with ragged walls, communicating with an irregular cavity in the uterus and also with the vagina—a vesico-uterine and a vesico-vaginal fistula. Note the contraction of the bladder walls due to non-use. Posteriorly, the uterine wall has become adherent to the rectum over an area about 4 centimetres in length, represented by *a*. It is at this point that extension to the rectum has taken place. This area of adhesions is particularly interesting from a clinical standpoint, as it has prevented free communication between the necrotic portion of the uterus and Douglas's sac. The clinician will readily see from the drawing that the slightest manipulation—for example, by manual examination—would be sufficient to separate the carcinomatous shell from the rectum, and allow the free escape of fluid into the abdominal cavity. It behooves one to be most gentle in his manipulation in all cases of advanced cancer; otherwise this complication will not infrequently arise.

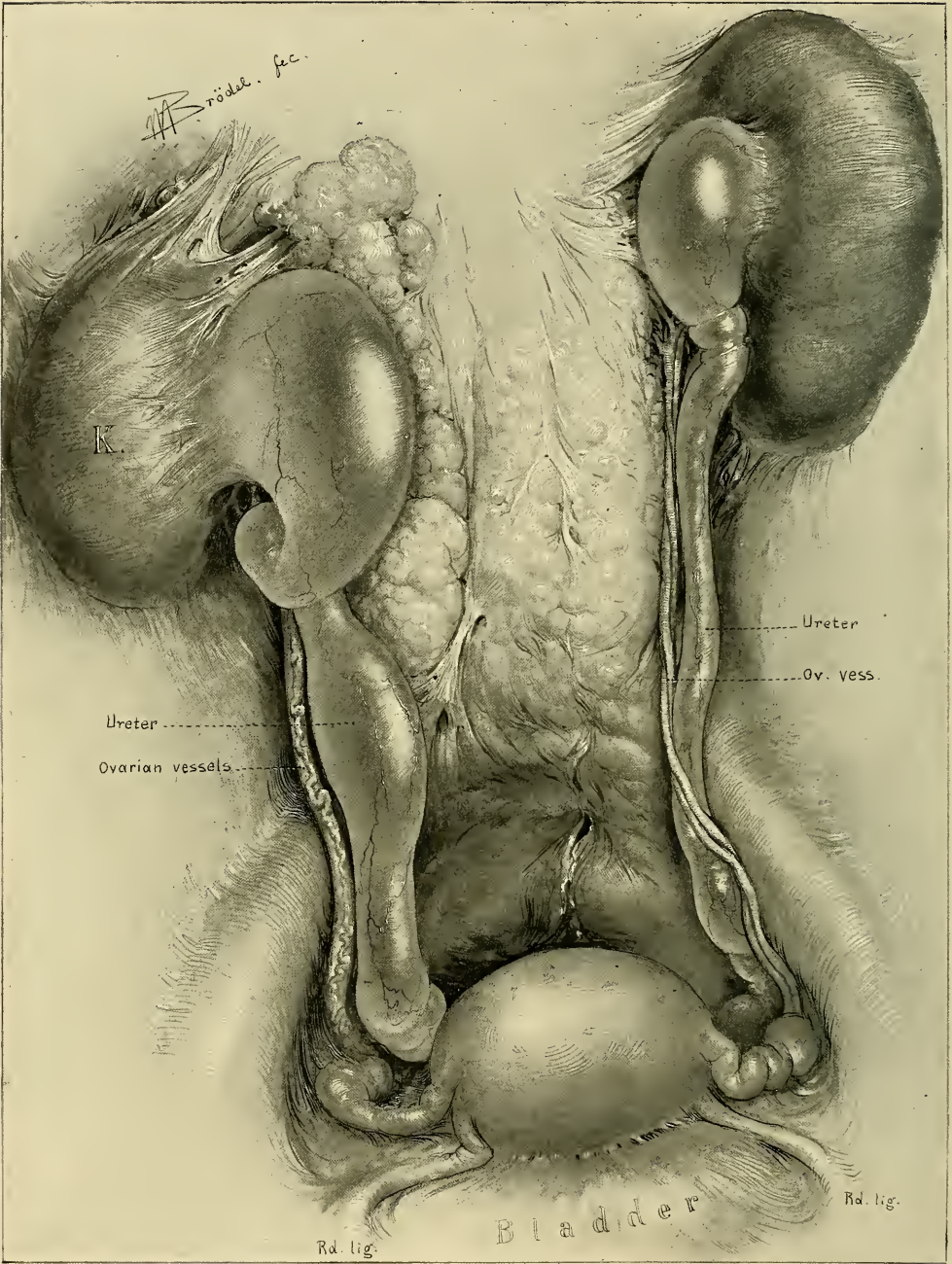


FIG. 89.—DOUBLE HYDROURETER DUE TO PRESSURE EXERTED BY A SQUAMOUS-CELL CARCINOMA OF THE CERVIX. ($\frac{3}{4}$ natural size.)

Autopsy No. 779. For the uterine growth, see Fig. 88 (p. 168). The uterus anteriorly is slightly adherent to the bladder. The right tube is normal, but the left is somewhat enlarged. The right ureter has been obstructed low down in the pelvis. Throughout its entire extent it is much enlarged. At the pelvic brim it measures 1 centimetre in transverse section, and near the pelvis of the kidney is so distended that it reaches 3 centimetres in diameter. This marked dilatation in the upper portion is due to constriction by the ovarian vein, which passes over it (Fig. 90). Over the surface of the ureter run its delicate blood-vessels. The left ureter is also dilated, but to a more limited extent. (After H. A. KELLY.)

The right kidney measures $11 \times 6 \times 3.5$ centimetres. It shows commencing hydronephrosis, and scattered throughout the renal substance are numerous small cysts varying from 1 to 4 millimetres in diameter. The right ureter, in the vicinity of the kidney, is 3 centimetres in diameter (Fig. 89); it gradually diminishes in calibre, until at a point 5 centimetres below the kidney it measures only 1 centimetre. Here it is crossed by the ovarian vein, which has

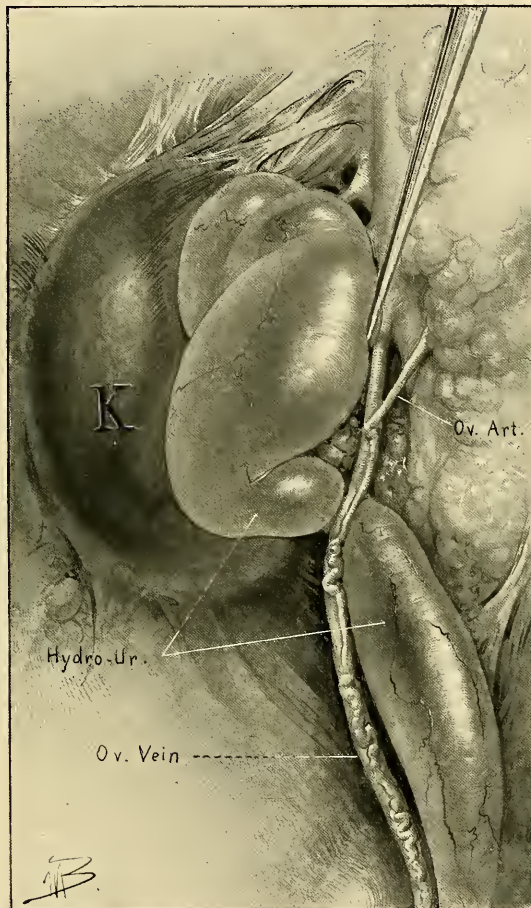


FIG. 90.—HYDROURETER CAUSED BY A SQUAMOUS-CELL CARCINOMA OF THE CERVIX. (Natural size.)

Autopsy 779. For the entire length of the ureter, see Fig. 89. Crossing the dilated ureter, a short distance below the kidney, is the ovarian vein. This causes a partial constriction, and the ureter, which was already enlarged, now becomes distended to double its former size. (After GEORGE BLUMER.)

produced considerable constriction (Fig. 90). From this point to its termination the ureter averages 1.5 centimetres in diameter. The left kidney is the seat of commencing hydronephrosis. The ureter is also dilated, but not to the extent observed on the right side.

Histological Examination.—The superficial portions of the growth both in the uterus and bladder are necrotic, but the underlying tissue is every-

where infiltrated by nests of epithelial cells, and presents the characteristic appearance of squamous-cell carcinoma.

From the condition of the uterus in this case a valuable clinical point may be gleaned: Had the clinician examined the patient shortly before death and attempted to manipulate the uterus, he would undoubtedly have sundered the adhesions between its posterior surface and the lower portion of Douglas's pouch, and there would then have resulted a direct communication between the necrotic and sloughing uterine cavity and the pelvic cavity. Peritonitis must have inevitably followed.

CARCINOMA OF THE LIVER, SECONDARY TO SQUAMOUS-CELL CARCINOMA OF THE CERVIX

The formation of metastases in the liver after primary growth in the cervix is exceptionally rare, and we have never had the opportunity of observing them. R. Williams, in his collection of seventy-nine autopsies, reports seven cases in which the liver was involved, but from his report it is impossible to tell definitely whether the primary growths were derived from the squamous epithelium alone, or whether they included all varieties of carcinoma of the uterus.

Wagner found hepatic involvement in four cases. The secondary growth usually occurs as scattered nodules, but in a few cases they have been so abundant that previous to the examination of the pelvic organs a primary carcinoma of the liver might have been suspected. In Case XXXVII, reported by Wagner, the liver was three times its normal size, and was studded with large and small carcinomatous nodules.

In Case 5,092 of our series, although the metastases were widely distributed, no secondary growth could be detected in the liver.

CONDITION OF THE LUNGS AT AUTOPSY IN PATIENTS DYING OF SQUAMOUS-CELL CARCINOMA OF THE CERVIX

Very little bearing upon this subject is to be found in the literature. In our eight autopsies, six showed some pulmonary alteration. In Case 2,885 and in Autopsy No. 333 there was moderate emphysema. In Autopsy No. 261 there was bronchitis, bronchiectasis, broncho-pneumonia, and œdema; the last-named condition was also present in Case 4,491. Case 3,463 had a chronic adhesive pleurisy, and Case 518 had pneumonia of the posterior lower lobes. Thus one would expect to find some congestion or a slight pneumonia, as in many other slowly wasting diseases.

Autopsy No. 261

M. L. December 15, 1891.

Carcinoma of the cervix; bronchitis; bronchiectasis; broncho-pneumonia; œdema of the lungs.

Autopsy No. 333

L. A. August 19, 1892.

Squamous-cell carcinoma of the cervix and vagina; hydronephrosis on the right side; pelvic peritonitis; emphysema of the lungs; anæmia; gastritis; chronic tuberculous ulcer of the larynx.

Carcinoma of the lungs secondary to squamous-cell cancer of the cervix is very rare, and occurs only in the latest stages. The nodules are few in number and are present in both lungs. One case was observed by Wagner.

In Case 5,092 (p. 132), where there was an advanced carcinoma of the cervix; secondary growths were found in both lungs. The right lung was bound down to the chest wall by fibrous adhesions about its middle third, and posteriorly near the base. In the latter situation the surface of the lung was covered by a conglomerate mass of small, round, tumour nodules. These, on section, were of an uniformly pale yellow colour, and showed slight softening in their central portions. Five similar nodules were found distributed over the surface of the lung. A small nodule, 6 millimetres in diameter, was found on the parietal pleura, and several on the diaphragm.

CHAPTER VI

CLINICAL ASPECTS IN SQUAMOUS-CELL CARCINOMA OF THE CERVIX

1. Age.
2. Number of pregnancies.
3. Miscarriages.
4. Menstrual history.
5. Symptoms in 1. Stage I.
 2. Stage II.
 3. Stage III.
6. Squamous-cell carcinoma of the uterus in the coloured race.

Age.—In all cases of suspected carcinoma the age of the patient deserves some consideration. The maximum incidence is found between the fortieth and fiftieth years, but squamous-cell carcinoma may occur as early as the twenty-fifth year, or as late as even the seventy-fifth year. In fifty-two of our cases the following ages were noted. The youngest patient was thirty-one years old, the oldest, sixty-two years.

Between 31 and 35.....	5 cases.
" 35 " 40.....	7 "
" 40 " 45.....	19 "
" 45 " 50.....	6 "
" 50 " 55.....	7 "
" 55 " 60.....	4 "
" 60 " 62.....	4 "

From the above table it would appear that the disease is most common about the menopause, an observation which coincides with the experience of most investigators.

The Number of Pregnancies.—It is rare to find a nullipara suffering from squamous-cell carcinoma of the cervix; when such is the case, the patient has usually been submitted to some previous instrumental treatment. Kelly has reported three instances, in one of which the cervix had been previously dilated. Emmet likewise reports one case in a nullipara; here also dilatation had been performed. In fifty of our cases it has been possible to get accurate data as to marriage, the number of children, and of miscarriages, when they had occurred.

In every instance the patient was married, and forty-nine of the fifty had borne children.

1 woman had had.....	no children.
3 women " ".....	1 child each.
8 " " ".....	2 children each.
6 " " ".....	3 " "
7 " " ".....	4 " "
5 " " ".....	5 " "
3 " " ".....	6 " "
4 " " ".....	7 " "
4 " " ".....	8 " "
5 " " ".....	9 " "
4 " " ".....	10 " "

Thus in nearly every case the woman had had offspring, and in at least half of the cases was the mother of five or more children.

Miscarriages.—In the fifty cases, seventeen women—or about one third—had miscarried, a percentage not much, if any, above the general average of miscarriages.

Menstrual History.—The menses in all but two of our cases were practically regular until the carcinoma commenced, or until the menopause had been reached. In going through the records it is particularly striking to see the regularity with which a normal menstrual history is recorded. Case 3,126 is one of the exceptions. This patient in early life had suffered from membranous dysmenorrhœa, which, however, did not give any trouble in later life. Case 2,449 was subject to free hæmorrhage at any time when unduly excited or worried.

One would hardly expect to find any relation between menstruation and squamous-cell carcinoma of the cervix, as the former has to do with the endometrium, the latter with a totally foreign part.

In our description of the pathology of squamous-cell carcinoma, the process, for the sake of clearness, was divided into three stages; here also the same divisions will be observed.

I. Hardness and induration of the cervix, but without any loss of tissue.

II. Moderate disintegration of the cervix.

III. Extensive or complete involvement of the cervix.

The symptoms of the disease in the first stage are those most important to us, but, as will be seen later, they are unfortunately somewhat indefinite.

Stage I.—The first symptom noticed by the patient is usually a bloody discharge. In women who have not yet reached the menopause this is generally attributed to a prolongation of the period, and in those past the climacteric, to a return of the menstrual flow. The hæmorrhages vary greatly in frequency, in some cases occurring every few weeks, in others at intervals of several months. They are influenced greatly by the patient's surroundings; coitus tends to bring on bleeding, while in some women the lifting of heavy weights is sufficient to produce it. The explanation of this is very simple, when we remember the delicate structure of the fine finger-like outgrowths found in the early stages. The large capillaries being practically devoid of any surrounding stroma, and having merely a few layers of friable squamous epithelium forming their external support, the slightest disturbance, whether caused by coitus or by the examining finger, is naturally sufficient to break off the tops of these processes and start bleeding. Again, any increased arterial tension, such as might be produced by lifting heavy weights, could readily cause rupture of these delicate vessels (see Fig. 46, p. 63; Fig. 51, p. 81; Fig. 48, p. 68; Fig. 53, p. 84).

Often in these cases there is very little to arouse suspicion in the mind of the patient, or even of her physician, since the general condition appears to be excellent, and there is little, if any, vaginal discharge.

Vaginal examination in the first stage may show a slightly enlarged, very firm, glazed-looking cervix, with a few fine, finger-like processes projecting from its surface. The examining finger is usually covered by a little blood. In the majority of these cases, however, the upper part of the vagina

is found filled by a cauliflower-like growth which is very friable, breaks down readily under the examining finger, and bleeds profusely. On tracing this growth upward it is found to spring from one, and occasionally from both cervical lips (see Fig. 31, p. 42; Fig. 32, p. 43; Fig. 47, p. 67; Fig. 45, p. 62; Fig. 46, p. 63). The vaginal mucosa is normal. There is no thickening in the broad ligament; the uterus is usually freely movable, but may be firmly fixed on account of a previous independent inflammatory process.

Stage II.—As the disease progresses, there is a gradual breaking down of the older portions of the growth; the hæmorrhages become more and more frequent and are usually larger in quantity, at times amounting to from 300 to 500 cubic centimetres, and occasionally to a litre of blood. These may come on without warning or after some extra exertion, or they may follow coitus.

In the intervals between the hæmorrhages a vaginal discharge is now noticed. This, though at first thin and watery, generally has a penetrating, offensive odour, and causes itching or scalding of the external genitals. In rare instances the discharge is without odour and is non-irritating. This vaginal flow is due to the disintegration of the carcinomatous tissue, and, as the disease progresses, often becomes thick and yellow, owing to the presence of an abundance of polymorphonuclear leucocytes.

Nevertheless, some patients look the picture of health; others, however, begin to be rather pale, and their mucous membranes show distinct signs of anæmia. Some lose rapidly in weight, feel languid, have no appetite, and become costive. A few have painful defecation.

Pain.—In this stage many patients complain of no discomfort whatever; others, however, have a dull, gnawing pain in the lower abdomen and back.

It will readily be seen from the foregoing that the only constant symptoms are the hæmorrhages and the vaginal discharge.

Vaginal Examination in the Second Stage.—The cauliflower growth which was present in the first stage has gradually broken down and disappeared. The cervical lips are enlarged, and over a limited or extensive area a rough and uneven, eaten-out surface is felt (see Plate II, Fig. 70, p. 122; Fig. 106, p. 208; Fig. 67, p. 117; Fig. 50, p. 80). The floor of this eaten-out area is very hard, but small pieces of tissue can readily be brought away with the finger. The margins of the growth are raised and exceedingly hard. The induration can frequently be felt extending out to the vaginal vault, and there is often much thickening in one or both broad ligaments. Examination with the speculum shows that the surface of the growth is ragged, and covered by blood and necrotic-looking tissue. The advancing margin is usually recognised by a slightly irregular ridge covered by mucosa. The major part of the information is obtained from digital examination, and not from the use of the speculum. The body of the uterus may be of the normal size, enlarged, or atrophied. If there be involvement of the broad ligament, its mobility will of course be limited. Occasionally the body of the uterus is elastic, as large as that of a three or four months' pregnancy, and reaches as far as the pelvic brim. Where such a condition is present, an accumulation in the uterine cavity must be thought of, since a pyometra occasionally occurs (see Fig. 126, p. 243; Fig. 161, p. 313).

Stage III.—With the advance of the disease the patient's strength begins to fail; the skin often, though by no means always, has the whitish-yellow or cachectic appearance which is so characteristic of malignant disease. Klemperer,* from his studies on metabolism in carcinomatous patients, comes to the conclusion that the cachexia is due to the fact that more nitrogen leaves the body than is received. The bowels, if not already costive, often become so, and there is painful defecation, the loaded intestine pressing upon the growth. The hæmorrhages are liable to be more frequent and more abundant, as the carcinomatous surface is now greater in extent. The discharge is profuse and exceedingly offensive, having a smell that is so characteristic that it can hardly be mistaken for anything else. Accompanying the advancement in the growth, there is frequently much pain—cramp-like, darting, or knife-like—in the lower abdomen and uterus. Often a dragging or radiating pain in the back and dull aching along the rectum are complained of. Where the growth has extended far laterally, there may be pressure on the nerves, giving rise to pain in the hips, knees, and calves of the legs.

The involvement of the bladder is often heralded by blood in the urine. Examination with the cystoscope will then immediately reveal the presence of the carcinomatous nodules, while, coincident with the breaking down of these, the dribbling of urine into the vagina will speak for the presence of a vesico-vaginal fistula. It must be remembered, however, that a carcinomatous ureter may break down and allow the urine to escape into the vagina through a uretero-vaginal fistula. Again, the urinary deposit may form a crust over the surface of the fistula and of the vagina, as in Credé's case, cited by Wagner,† which has already been referred to. Occasionally on exploring the vaginal vault, the examining finger will break through the carcinomatous tissue and enter a cavity, from which pus and gas may escape. This, as has been made clear in the pathological description, is due to the presence of a pyometra caused by obliteration of the cervical canal.

A vaginal examination in the third stage reveals a characteristic state of affairs. All trace of the cervix has disappeared, and occupying the vaginal vault may be a small, puckered, ulcerated, hard, and nodular area, covered by a necrotic, brown or greenish-looking, slough (see Plate III). The surrounding vaginal vault frequently has an intact mucosa, but the underlying tissue is indurated, owing to extension of the growth, while isolated nodules may be found lying just beneath the mucosa. In other cases the entire vaginal vault is much increased in size, and is lined by necrotic and friable carcinomatous tissue. Covering the surface of the vaginal mucosa are little shaggy tufts of the growth. In the advanced stages (see Fig. 81) all anatomical relations are lost; the entire upper part of the vagina is filled by the growth, and urine trickles down into the vagina through a vesico-vaginal fistula. In other cases, when the rectum is involved, fæces also pass *per vaginam*. In these advanced cases, where even a palliative operation is out of the question, it is not advisable to make a bimanual

* Klemperer, G. *Stoffwechselversuche an Krebskranken. Charité-Annalen*, xvi. Jahrgang, S. 138.

† Wagner, Ernst. *Op. cit.*

examination, as the slightest tension may be sufficient to establish an opening between the necrotic cavity and Douglas's cul-de-sac (see Fig. 88).

Late in the disease defecation becomes more and more painful, and in a small percentage of cases a recto-vaginal fistula forms, allowing the fæces to pass out into the vagina. By the time the process has advanced thus far, the patient's strength has been greatly reduced. Food is retained with difficulty, there being considerable tendency toward nausea and vomiting. Knife-like pains are frequent in the lower abdomen, and the patient sleeps very little. Inflammation of the colon sometimes occurs, the patient passing large quantities of mucus; or, as Wagner has observed, the lower bowel may become gangrenous. Œdema of the extremities occasionally follows as a result of pressure on the veins, and in rare instances bedsores develop. The patient continues to lose ground, and not infrequently has a slight temperature due to absorption of septic material from the sloughing and necrotic surface of the growth. Death is due to some intercurrent affection, usually to pneumonia or extensive renal disease. Shortly before the end the pain occasionally becomes so severe that morphine cannot control it.

SQUAMOUS-CELL CARCINOMA OF THE UTERUS IN THE COLOURED RACE

The general impression that the negress is free from carcinoma of the uterus is well known, and it was not until recently that the authenticity of this view has been questioned. J. Whitridge Williams,* in a brief review of the literature, quotes Emmet, who had dwelt upon the rarity of the disease in this race, and had stated that in his large practice he had seen only one case. Other authorities had had the same experience. Williams reported two cases then under observation at the Johns Hopkins Hospital. Both were in full-blooded negroes, and the disease was beyond operation.

The uterus of the negress differs in no way from that of the white woman. Even on histological examination it is impossible to distinguish that of the white from the black, the elements being identical. Of the patients coming to our coloured wards many are full-blooded negroes, but fully one half have a mixture of the white element. That the prevailing view is erroneous will be readily seen, as in our group of cases four belong to the negro race, viz., Nos. 3,813, 2,997, 2,728, and 2,572—not a small percentage when it is remembered that the white patients outnumber the coloured in the ratio of six to one. Furthermore, during the last six months, and since these cases have been tabulated, there have been four other cases of carcinoma of the uterus in the coloured ward, three squamous-cell carcinomata and one an adeno-carcinoma. The histological picture of squamous-cell carcinoma in the negress, as might be supposed, coincides exactly with that in the white race.

* Williams, J. Whitridge. *Carcinoma of the Cervix Uteri in the Negress*. *Johns Hopkins Hospital Reports*, 1890. ii, p. 224.

CHAPTER VII

DIFFERENTIAL DIAGNOSIS IN SQUAMOUS-CELL CARCINOMA OF THE CERVIX

1. Abnormal extension downward of the cervical mucosa.
2. Eversion of the cervical mucosa—the so-called erosion.
3. Erosion or ulceration of the cervix.
4. Simple ulcerations of the cervix due to prolapsus.
5. Apparent ingrowths of squamous epithelium due to a fold in the mucosa.
6. Hypertrophy of the cervix.
7. Thickenings of the vaginal portion of the cervix due to dilatation of the cervical glands.
8. Small tags of scar tissue on the cervix.
9. Stellate laceration of the cervix in pregnancy.
10. An appearance clinically somewhat resembling squamous-cell carcinoma produced by the irritation of old silk ligatures.
11. Cervical polypi.
12. Submucous myomata.
13. Sloughing submucous myoma.
14. Interstitial cervical myomata.
15. Condylomata of the cervix.
16. Syphilitic ulceration of the cervix.
17. Tubercular ulceration of the cervix.
18. Sarcoma of the cervix.
19. Malignant growths of the cervix, concerning which, even on histological examination, a positive diagnosis is difficult.
20. Adeno-carcinoma of the cervix.
21. Endothelioma of the cervix.

IN this chapter we have endeavoured to include all pathological conditions of the cervix that might be mistaken for squamous-cell carcinoma. Some present clinical similarities; others, while differing clinically, show certain more or less definite points of resemblance on histological examination. Hypertrophies, eversion of the cervical mucosa, inflammatory changes, infectious granulomata, myomata, and sarcomata are discussed in the order mentioned.

The most complete consideration of the differential diagnosis in squamous-cell carcinoma of the cervix is to be found in the work of Winter and Ruge,* to which we are indebted for many points in this chapter.

ABNORMAL EXTENSION DOWNWARD OF THE CERVICAL MUCOSA

IN nulliparæ it is not infrequent to find a reddened and sharply defined zone surrounding the external os. This varies from 2 millimetres to 1 centimetre or more in breadth, and appears to be a continuation of the cervical mucosa outward. On touching such a surface it gives a slightly granular sensation, but is not firm, nor does it usually show any tendency to bleed. Sections through such

* Winter u. Ruge. *Lehrbuch der gynäkologischen Diagnostik*, Leipzig, 1896.

areas make it clear that the condition is due to the fact that the cervical mucosa extends beyond the external os; the surface is covered by one layer of characteristic high cylindrical epithelium, and the underlying stroma presents the usual appearance. The red colour stands out in sharp contrast to the bluish-white, or pinkish, vaginal portion. In the reddened area the blood-vessels of the stroma are covered by only one layer of epithelium, whereas in the other portions numerous layers obscure to a great extent the red colour of the vessels.

EVERSION OF THE CERVICAL MUCOSA—THE SO-CALLED EROSION

The examination of multiparæ often shows a unilateral or bilateral laceration of the cervix, the os being dilated and the cervical mucosa everted. On bringing the cervical lips together the normal appearance is approximately reproduced, but on letting them go again the cervical mucosa is again exposed. This mucosa is bright red in colour, and presents an arborescent appearance; it shows little or no tendency to bleed, and is not in the least indurated. The line of demarcation between the cervical mucosa and that of the vaginal portion is irregular, but sharply defined. Histological examination of such tissue usually shows practically normal cervical mucous membrane; at times, however, there is some hypertrophy, the folds having become abnormally long, and appearing as little knob-like papillæ; or masses of mucosa may be partially thrown off, forming cervical polypi. In such cases there may be no symptoms whatever, except that a moderate leucorrhœal discharge is often present. The everted portion shows no more tendency toward bleeding than is observed in the cervical mucosa in its normal position.

Plate V gives a typical picture of the so-called erosion. One can readily see that the surface, although red and somewhat lobulated, is everywhere unbroken, and that the red appearance is due to an eversion of the mucosa normally lining the cervical canal. In many of these cases the attending physician, on the supposition that he is dealing with an ulcerated surface, applies tincture of iodine or a solution of zinc. These applications cause a distinct proliferation of the cylindrical epithelium, which is normally only one layer in thickness. With the increase in the number of the epithelial layers, the tissue assumes the bluish or pinkish colour, which is normally present over the outer or vaginal portion, where the epithelium is always many layers in thickness. Shortly after the treatment is stopped the newly formed epithelium is exfoliated, and the physician naturally concludes that the "ulceration" has returned. In reality there has been no loss of substance whatsoever, and no local applications were indicated.

EROSION OR ULCERATION OF THE CERVIX

The term ulceration or erosion has been used very loosely, being applied to almost any cervix showing redness. Thus, eversion of the cervical mucosa and abnormal extension downward of the mucosa have been classed under this head. Erosion signifies a loss of substance, and the

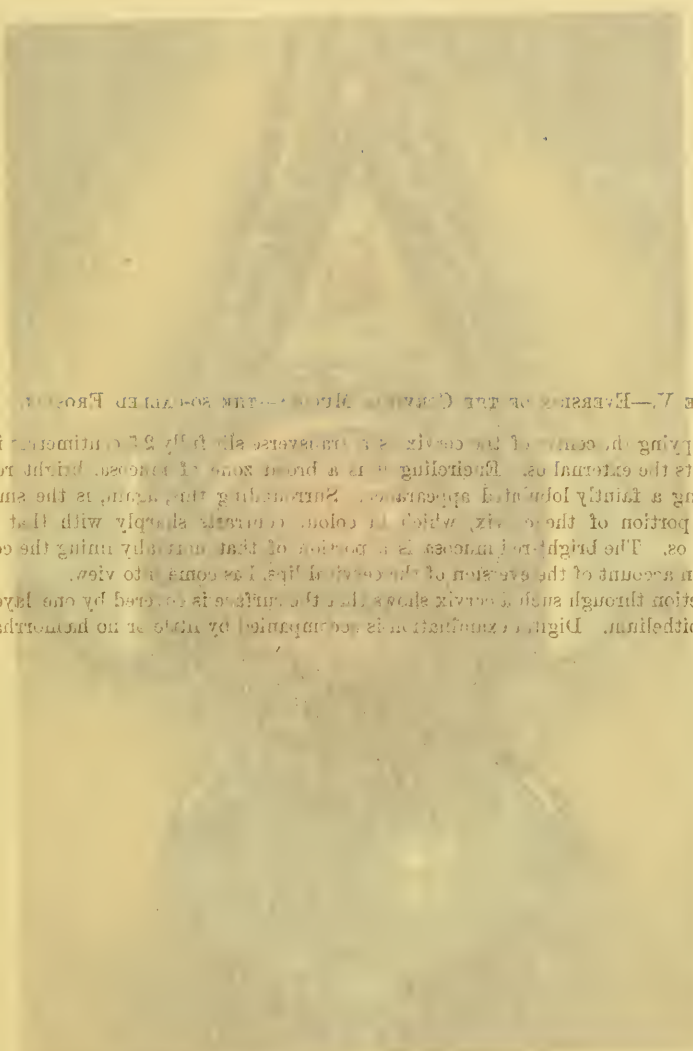


PLATE 7.—REVERSE OF THE CERVICAL BLIND—THE SO-CALLED PROSTATE (NATURAL SIZE)

Occupying the centre of the cervix is a transverse slit 2 1/2 centimetres in breadth. This represents the external os. Radiating from a broad zone of areolar tissue in colour and presenting a faintly lobulated appearance. Surrounding this again is the smooth, blue-black vaginal portion of the cervix, which in colour generally slightly with that surrounding the external os. The bright red masses is a portion of that normally uniting the cervical canal, but which, on account of the eversion of the cervix at the time of the operation, is seen as a *prolapsus*.

A section through such a cervix shows that the interior is covered by one layer of high cylindrical epithelium. Light *condemnation* is accompanied by mucus or no haemorrhage.

... under the conditions of the experiment... the cervical mucosa... the external os... the vaginal portion of the cervix... the bright-red mucosa... the smooth, bluish-pink vaginal portion...

PLATE V.—EVERSION OF THE CERVICAL MUCOSA—THE SO-CALLED EROSION. (Natural size.)

The examination of the cervix... the external os... the bright-red mucosa... the smooth, bluish-pink vaginal portion... the bright-red mucosa... the smooth, bluish-pink vaginal portion...

PLATE V.—EVERSION OF THE CERVICAL MUCOSA—THE SO-CALLED EROSION. (Natural size.)

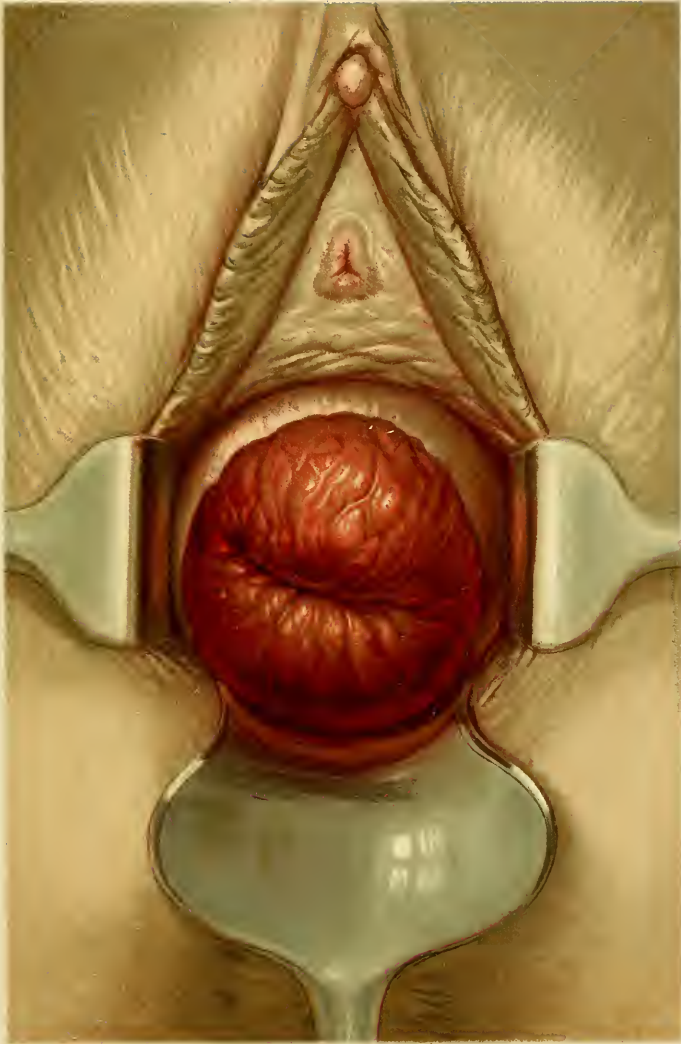
Occupying the centre of the cervix is a transverse slit fully 2.5 centimetres in breadth. This represents the external os. Encircling it is a broad zone of mucosa, bright red in colour, and presenting a faintly lobulated appearance. Surrounding this, again, is the smooth, bluish-pink vaginal portion of the cervix, which in colour contrasts sharply with that surrounding the external os. The bright-red mucosa is a portion of that normally lining the cervical canal, but which, on account of the eversion of the cervical lips, has come into view.

A section through such a cervix shows that the surface is covered by one layer of high cylindrical epithelium. Digital examination is accompanied by little or no hæmorrhage.

Part of the cervical portion... the external os... the bright-red mucosa... the smooth, bluish-pink vaginal portion... the bright-red mucosa... the smooth, bluish-pink vaginal portion...

ANATOMY OF THE CERVIX OF THE RAT.

The cervix... the external os... the bright-red mucosa... the smooth, bluish-pink vaginal portion... the bright-red mucosa... the smooth, bluish-pink vaginal portion...



Eversion of the cervical mucosa - the so-called "erosion"

use of the term should be restricted to the cases in which this condition is present.

Occasionally, from mechanical or other injury, the cervix may present an ulcerated area on the vaginal portion or at its junction with the cervical portion. Here there is a distinct loss of tissue. The margins of the ulcer are usually sharply defined; the broken-down portion presents a finely granular appearance, and may or may not be covered by pus or necrotic material. On microscopical examination the squamous epithelium around such an area shows small-round-

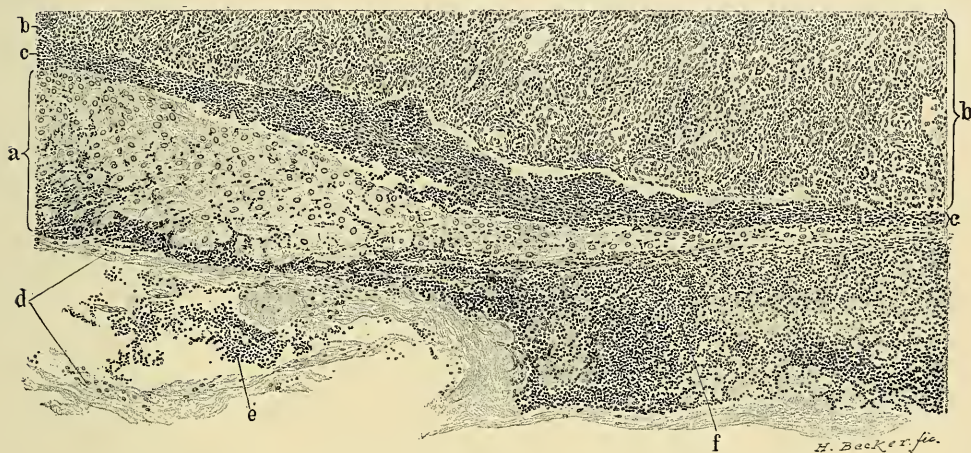


FIG. 91.—MARGIN OF AN ULCER IN THE VAGINAL PORTION OF THE CERVIX. (75 diameters.)

Gyn.-Path. No. 627. On the left the section merges into normal mucosa; on the right it takes in part of the floor of an ulcer. *a* is the squamous epithelium, containing many polymorphonuclear leucocytes and small round cells between the individual elements. *b* is the underlying stroma, consisting of many young capillaries and showing much small-round-cell infiltration. Separating the epithelium from the stroma are many pus cells, *c*. These have found their way in from the edge of the ulcer, and have gradually loosened up the epithelium. Covering the surface is considerable fibrin, indicated by *d*. In its meshes are polymorphonuclear leucocytes and small round cells, *e*. Directly over the surface of the ulcer are quantities of small round cells, *f*. It is rather remarkable that so few polymorphonuclear leucocytes appear at this point. From the above description it is seen that the specimen presents the ordinary picture of an ulceration.

cell and polymorphonuclear infiltration, which increases in intensity as the ulcer is approached (Fig. 91). The floor of the ulcer itself is composed of typical granulation tissue, many new-formed connective-tissue cells, leucocytes, and small round cells (Fig. 238, p. 455). The tissue has a rich capillary blood supply.

Fig. 238 presents a typical erosion or ulceration of the cervix. The section was taken from the cervix in a case in which the body of the uterus contained several myomata and an adeno-carcinoma. The lower part of the body was the seat of a typical endometritis. As seen from the cervix, almost the entire tissue is composed of enlarged and dilated capillaries, showing a swollen endothelium, and surrounded by polymorphonuclear leucocytes and small round cells. Were it not for the cervical gland *a*, the section might readily be taken for granulation tissue from the inner lining of an abscess sac.

An erosion is nothing more than a loss of substance with the usual inflammatory reaction, a condition not likely to be

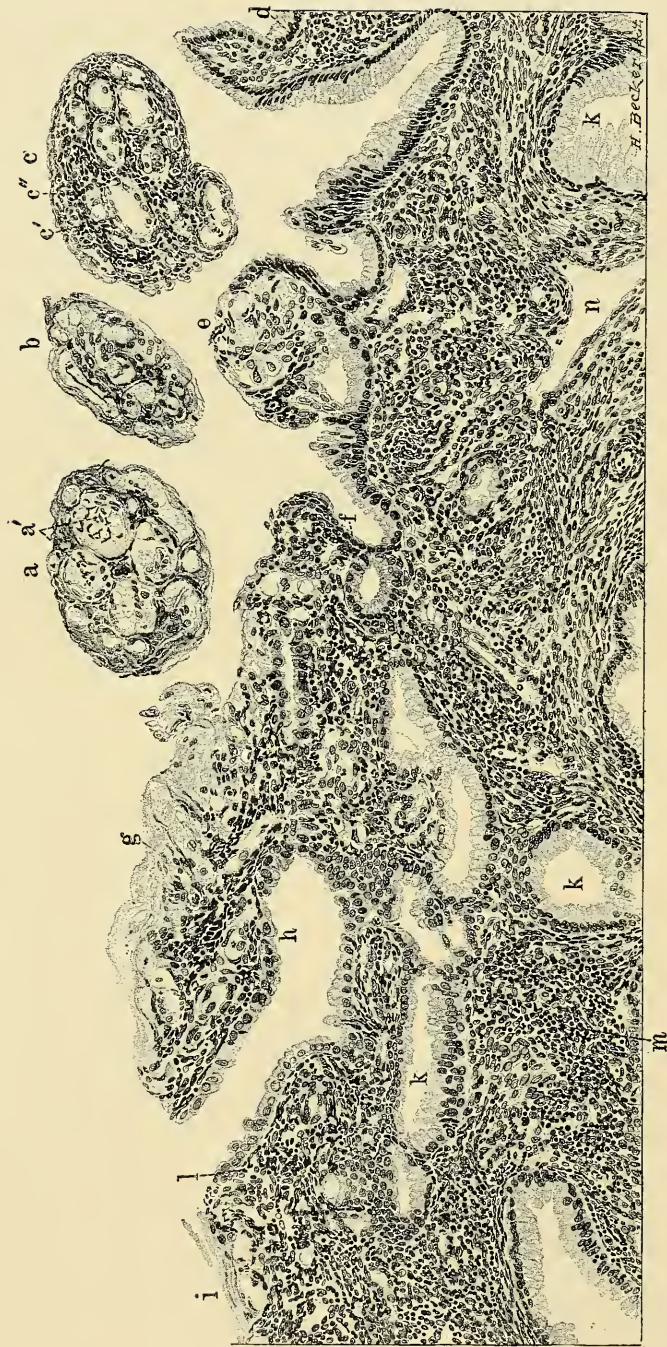

FIG. 92.—SLIGHT EROSION OF THE CERVICAL PORTION OF THE CERVIX. (180 diameters.)

Gyn.-Path. No. 2397. *a, b, c* are cross sections of folds of the cervical mucosa. The epithelial covering has entirely disappeared. In *a*, the capillaries, *a'*, have undergone obliterative endarteritis, and the stroma is dense. The endothelium of the capillaries in *c* is swollen, as indicated by *c'*. The stroma, especially at *c''*, shows much small-round-cell infiltration. The fold *d* is intact, and its epithelium is normal. *e* has lost its epithelium in the more exposed portions, and a cross section near its tip would correspond very well with *b*. At *f* the epithelium has become euboidal, and in still more protected places is perfectly normal. At *g* all trace of cervical epithelium is gone, and in the superficial portions of the stroma even the suggestion of a nucleus is lacking. On the protected side of *g*, the epithelium *h*, although somewhat flattened and swollen, is still intact, but where the surface is again exposed, as at *i*, the epithelium is entirely wanting. *k* indicates cervical glands in the depth, which show little or no deviation from the normal. The stroma at *l* is slightly infiltrated with polymorphonuclear leucocytes, and at many points contains small round cells. These are particularly abundant at *m*. *n* is a blood-vessel.

It will be seen that the inflammatory process is a comparatively old one, and that the epithelial cells, when changed at all, have undergone atrophy. Although the cervix, from which such a section has been taken, presents a red appearance and may bleed slightly on manipulation, the histological examination shows no suggestion whatever of carcinoma.

mistaken for squamous-cell carcinoma, and even when clinically doubtful is easily differentiated microscopically. Any portion of the cervix is liable to loss of substance, and in cases in which the cervical mucosa is everted or extends farther downward than normal, it is not uncommon for the tips of the folds to lose their epithelial coverings, and become the seat of a moderate inflammatory process (Fig. 92).

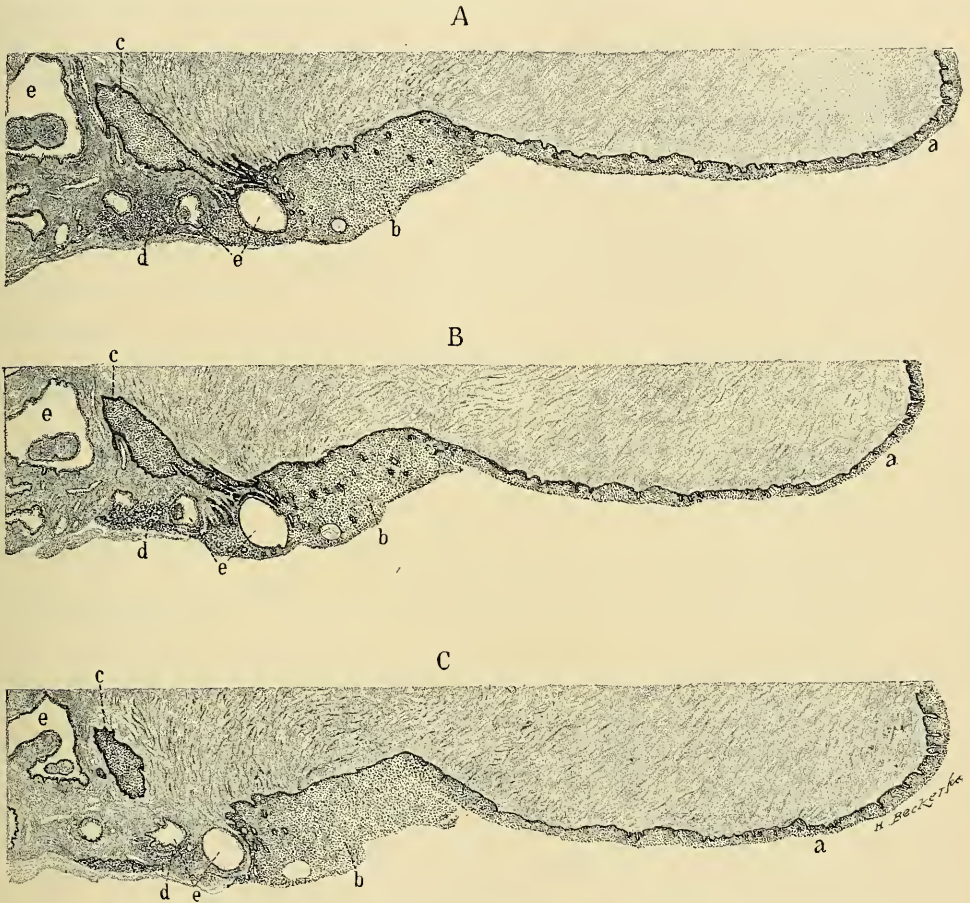


FIG. 93.—AN APPARENT CELL-NEST DUE TO A FOLD IN THE MUCOSA. (12 diameters.)

Gyn.-Path. No. 1,924. At *a*, in A, the epithelium is of the normal thickness, but at *b* it is greatly thickened. This is evidently due to the obliquity of the section, since the papillæ are, for the most part, cut transversely instead of longitudinally. *c* is an apparent growth into the stroma, but can be readily accounted for by an indentation from the under surface. The epithelium throughout is normal. At *d* the stroma shows slight inflammatory reaction. *e* indicates cervical glands. In B the projection *e* is more constricted, and in C it forms a so-called cell-nest. Although the epithelium *e* is apparently deep down in the stroma, one would not for a moment suspect a carcinomatous process.

SIMPLE ULCERATIONS OF THE CERVIX DUE TO PROLAPSUS

These occasionally result from the external influences to which the prolapsed uterus is subjected. The cervix is usually considerably hypertrophied, and the squamous epithelium tends to become horny on account of the friction caused by

the clothes, and also from exposure to the air. The loss of substance may be limited to one area, or there may be two, three, or even more ulcers. These pre-

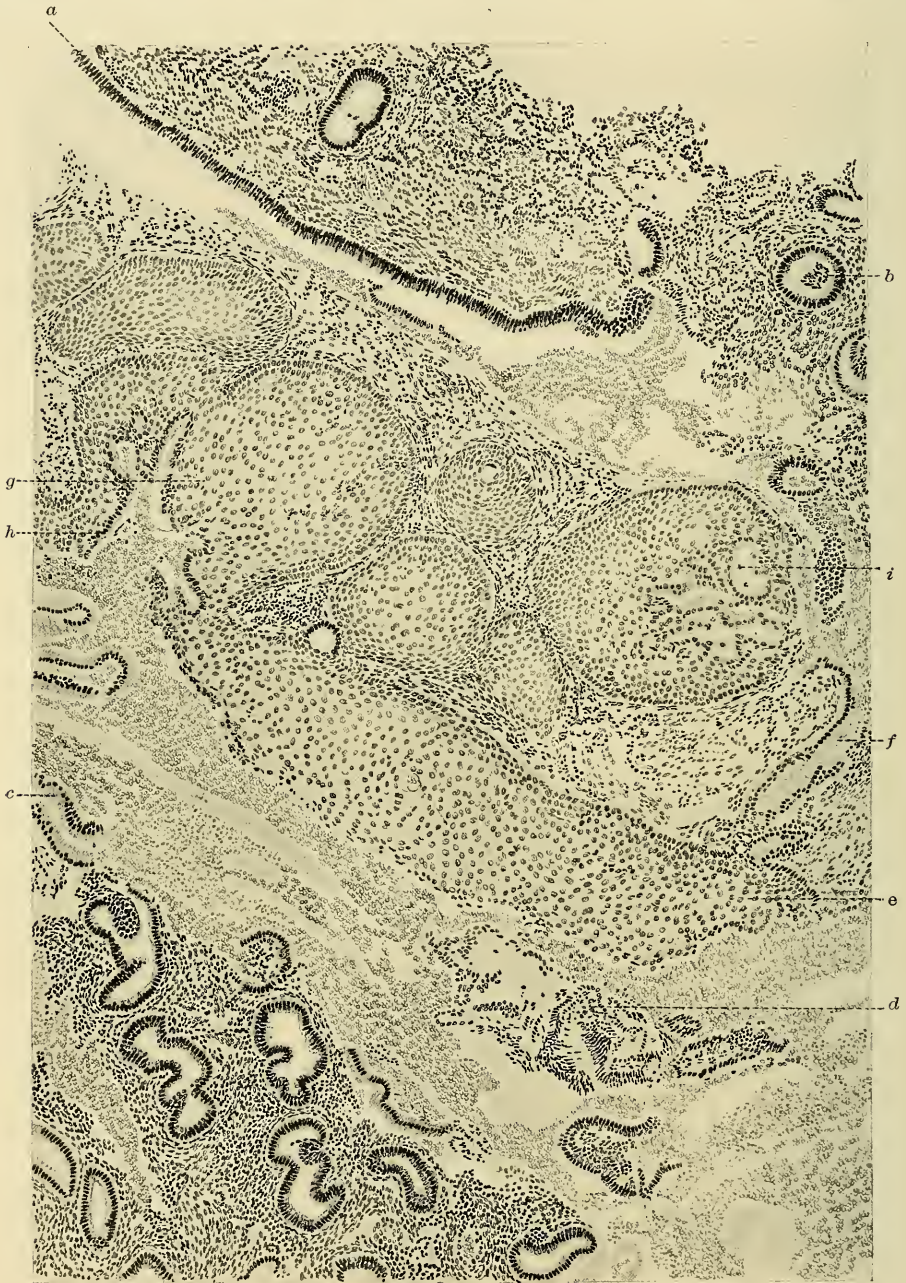

FIG. 94.—A PICTURE SOMEWHAT RESEMBLING SQUAMOUS-CELL CARCINOMA DUE TO DISTORTION OF THE EPITHELIUM BY THE CURETTE. (90 DIAMETERS.)

Gyn.-Path. No. 1,509. The picture is from a scraping. In the upper and lower portions of the field is seen normal endometrium. In the centre appears tissue from the cervix. The epithelium covering the

sent a punched-out appearance, are irregular in contour, and frequently have crenated margins. The edges are not elevated, and the surrounding tissue shows little inflammatory reaction. The floor is usually pink in colour, and presents the typical picture of a granulating surface. The ulcers are usually soft, not giving the slightest sign of induration. They are readily dissected out, and are very shallow.

APPARENT INGROWTHS OF SQUAMOUS EPITHELIUM DUE TO A FOLD IN THE MUCOSA

At times the mucosa of the vaginal portion of the cervix, instead of presenting a smooth surface, is gathered up into little hills and hollows, which give it a wrinkled or puckered appearance. On section, the squamous epithelium will be cut in some places at right angles, at other points obliquely, giving such a picture as is seen in Fig. 93. Fortunately, we are here able to trace the continuity of the cell-nest with the surface, while it can be seen that the epithelium throughout preserves its normal type. Thus we can immediately exclude carcinoma.

A somewhat analogous appearance may be due to distortion of the squamous epithelium, produced by the curette. Fig. 94 represents a scraping from the body of the uterus, but in the withdrawal of the curette some of the flat epithelium of the vaginal portion has been brought away, and, being thin, has become folded. Owing to this fact sections may give pictures strongly suggestive of cell-nests. On careful scrutiny, however, it will be seen that the epithelial cells are normal in size, regularly arranged, and show uniform staining properties. Hence squamous-cell carcinoma can readily be excluded.

HYPERTROPHY OF THE CERVIX

Occasionally the cervix, although retaining its normal contour, is much enlarged, and on histological examination the mucosa may present such a picture as that seen in Fig. 95. Here there is marked thickening of the squamous epithelium, together with elongation and branching of the papillæ, but no extension of the epithelium into the depth. The apparent small cell-nests (*f*) are in real-

surface of the endometrium is normal, as seen at *a*, and the underlying gland is unaltered. At *b* a gland contains a little stem of stroma. The uterine glands in the lower part of the section are slightly convoluted, but normal. *c* indicates a cervical gland, which can be recognised by its very high cylindrical and faintly staining cells with the nuclei situated at their bases. *d* is a conglomerate mass of epithelial cells scraped out by the curette. *e* is the squamous epithelium of the vaginal portion of the cervix, and is perfectly normal. To the left, at *g*, it apparently involves the stroma, and contains a few polymorphonuclear leucocytes. *h* is the cylindrical cervical epithelium of a gland opening out on the surface of the squamous epithelium. At *i* is a similar picture, the convolutions of the gland having been cut near the gland base. Scattered throughout the stroma are oval and circular areas filled with epithelial cells. *f* is a normal cervical gland. The entire central portion of the picture bears some resemblance to squamous-cell carcinoma; but when it is remembered that only a thin strip of the mucosa of the vaginal portion was accidentally scraped off during the removal of the curette, it is easily seen how it could have become convoluted or distorted, giving the appearance here presented. Furthermore, the absolute uniformity in the size of the epithelial cells leaves no doubt as to the benign nature of the tissue.

ity not downgrowths, but result from a slight fold or indentation of the mucosa at a lower level.

The even surface, the absence of an excess of chromatin, together with the

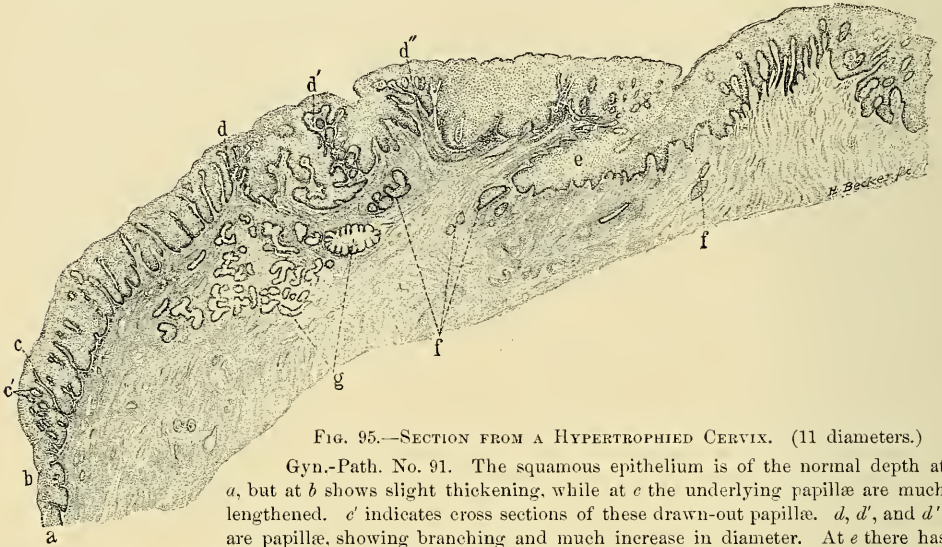


FIG. 95.—SECTION FROM A HYPERTROPHIED CERVIX. (11 diameters.)

Gyn.-Path. No. 91. The squamous epithelium is of the normal depth at *a*, but at *b* shows slight thickening, while at *e* the underlying papillæ are much lengthened. *e'* indicates cross sections of these drawn-out papillæ. *d*, *d'*, and *d''* are papillæ, showing branching and much increase in diameter. At *e* there has been a slight fold in the mucosa, making it appear as if the epithelium were penetrating the stroma. Continuations of such folds produce the small cell-nests, *f*. *g* indicates normal cervical glands. The stroma of the cervix presents the usual appearance. A key to the origin of these apparent cell-nests is given in Fig. 93.

uniformity in size of the epithelial cells, exclude the possibility of a malignant growth.

THICKENING OF THE VAGINAL PORTION OF THE CERVIX DUE TO DILATATION OF THE CERVICAL GLANDS

It is a common occurrence to find a few of the cervical glands dilated and occluded, forming the so-called Nabothian follicles. Some of these are seen through the squamous epithelium as whitish or bluish cysts, averaging 4 to 5 millimetres in diameter; on puncture, they are found to contain a glairy, tenacious mucus, an accumulation of the normal cervical secretion. If seven or eight of these glands enlarge at the same time, one or both lips of the cervix will be increased in size, so that on digital examination the cervix will appear enlarged, hard, and nodular. Such a condition is not often mistaken for carcinoma, since the cervix, although hard and nodular, is perfectly smooth, and shows no tendency to bleed. Furthermore, it is impossible to dig pieces of the cervical tissue away with the finger, as would be the case in squamous-cell carcinoma. Occasionally, however, a case is met with in which considerable doubt arises. In a patient recently operated upon by Dr. Kelly at his private hospital, the cervix was enormously enlarged, hard, and nodular; there was an offensive uterine discharge, and hæmorrhages had occurred. The diagnosis of carcinoma of the cervix appeared to be so certain that the uterus was removed. To the operator's

surprise, however, no carcinoma was present, but the cervix showed marked dilatation of the glands, some reaching nearly 1.5 centimetres in diameter. The clinical symptoms present had been due to an adeno-carcinoma of the body of the uterus, a condition that had not for a moment been suspected.

The dilated glands are usually lined by one layer of cylindrical epithelium, conforming to the cervical type, and the gland contents consist of desquamated epithelium, a few polymorphonuclear leucocytes, and mucus (Fig. 96). The surrounding stroma, except for some slight small-round-cell infiltration, is unaltered.

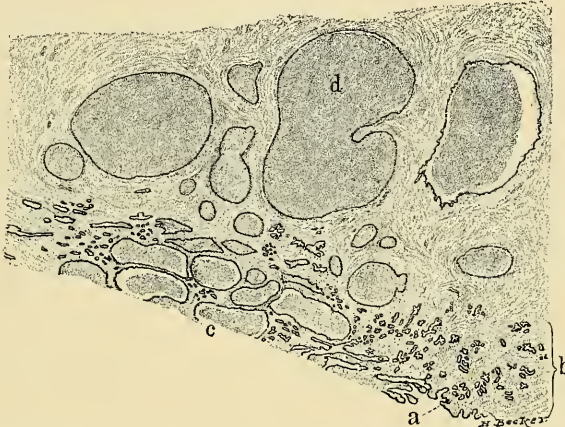

FIG. 96.—DILATATION OF THE GLANDS OF THE CERVIX. (3 diameters.)

Gyn.-Path. No. 452. *a* indicates the slightly undulating surface of the cervical mucosa. *b* is a group of normal cervical glands. At *c* the glands are moderately dilated. At *d* they show marked distention. Even with this low magnification it is clear that there is no proliferation of the epithelium.

Thus it is clear that under the microscope there is not the slightest possibility of confusing the squamous-cell carcinoma with dilatation of the cervical glands.

SMALL TAGS OF SCAR TISSUE ON THE CERVIX

It is a common thing to feel one or two small shot-like bodies in the cervix just external to the os, more particularly in those cases in which there has been some laceration. These might for a moment suggest carcinoma, but careful examination shows them to be covered by mucosa, and to shade off gradually into the normal cervical tissue. Again, it is impossible to tear them off with the finger, and the cervix shows no tendency to bleed, whereas, if we had to deal with a squamous-cell carcinoma, the piece could be easily torn off, the surrounding tissue would show infiltration, and bleeding would follow the examination. It is well to remember that these small shot-like bodies are sometimes in reality shot, the operator having failed to remove one or two sutures after repair of the cervix.

STELLATE LACERATION OF THE CERVIX IN PREGNANCY

Now and again this condition may at first sight be mistaken for squamous-cell carcinoma of the cervix, as is shown by the following case:

Gyn.-Disp. No. 9,072. A. D. was admitted, complaining of a profuse menstrual discharge. She had been married fifteen years, and had had six children. On vaginal examination the cervix was found low down, stellately lacerated, some of the clefts extending backward to the vaginal wall. The cervical tissue was soft and smooth, but gave the sensation of being friable; it was, however, impossible to dig pieces away. The uterus was the seat of a two-and-a-half months' pregnancy. In this case carcinoma was instantly thought of, on account of the hæmorrhages and of the friable sensation imparted to the examining finger. Had carcinoma of the cervix been present, however, the tissue would have been hard, and not so smooth; furthermore, small pieces of the growth could have been brought away with the finger.

AN APPEARANCE CLINICALLY SOMEWHAT RESEMBLING SQUAMOUS-CELL CARCINOMA PRODUCED BY THE IRRITATION OF OLD SILK LIGATURES

This is a rather unusual condition, but one which the physician must be prepared to meet with. Unfortunately, the history of this patient could not be obtained, but there had evidently been a previous operation on the cervix. It can readily happen that one or two silk sutures may be left behind, as cervical stitches are quite difficult to expose, and must often be removed by aid of the touch alone, especially when the perinæum has been repaired at the same time.

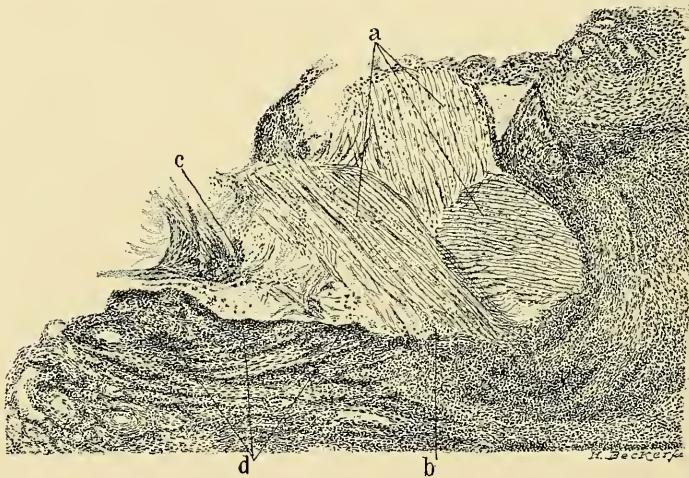


FIG. 97.—CROSS SECTION OF A SILK LIGATURE. (36 diameters.)

Gyn.-Path. No. 655. *a* gives the histological picture of the three strands of the silk ligature cut obliquely. Each strand is subdivided into numerous fine parallel threads. Small round cells have wandered in between the individual fibres. At *b* there is a little colony of polymorphonuclear leucocytes. At *c* the tissue has been compressed and distorted by the foreign body. The stroma surrounding the ligature shows much small-round-cell infiltration, which is especially well marked at *d*.

Gyn. Disp. No. 10,931 (Gyn.-Path. No. 655). M. C. This patient was seen in the dispensary April 4, 1895, and as the cervix was indurated and presented a suspicious appearance, a small piece was cut out for further study.

On histological examination, the surface epithelium is in places intact, but between the individual epithelial cells are polymorphonuclear leucocytes. In other places the epithelium has disappeared, and the surface is covered by polymorphonuclear leucocytes, beneath which is typical granulation tissue, composed of newly formed connective-tissue cells and leucocytes. Ramifying through the tissue in all directions are delicate capillaries, around which one frequently finds zones of polymorphonuclear leucocytes. At two points, about 3 millimetres beneath the epithelium, are cross sections of silk ligatures (Fig. 97). Between the individual fibres of the ligatures are a few polymorphonuclear leucocytes, and surrounding them is much small-round-cell infiltration.

Diagnosis.—Erosion of cervix; silk ligatures in the cervical stroma.

CERVICAL POLYPI

These frequently give rise to uterine hæmorrhages, and when they project from the cervix may bleed slightly on manipulation. A careful examination will show that they usually spring from a point a short distance within the external os, and that the cervical lips are intact. The polyp itself is rather firm; it has no finger-like projections, nor does it consist of friable tissue, as does the carcinoma. Should the diagnosis still be in doubt, a piece of tissue should be removed for microscopical examination. The polypi are usually covered by one layer of high cylindrical cervical epithelium, and contain typical cervical glands. They do not in any way resemble squamous-cell carcinoma. (For a complete description of cervical polypi, see Differential Diagnosis of Adeno-carcinoma of the Cervix, p. 339.)

SUBMUCOUS MYOMATA

These have their pedicle in the uterine cavity or upper part of the cervix, and are gradually extruded. Accompanying their expulsion there is often considerable hæmorrhage, which might suggest a diagnosis of carcinoma of the cervix. Where the myoma is large, there is no difficulty in recognising the condition, since the large, globular tumour mass can immediately be felt. On the other hand, when the myoma is small and projects only for a short distance, the diagnosis is not so easy, especially if the presenting part of the tumour be slightly ulcerated. On palpation the tumour usually feels soft and velvety, owing to its covering of mucous membrane, and it is possible to run the finger around it on all sides. The cervical walls are felt as a ring encircling the tumour; if the latter be small, they are usually soft, but if it be large, they are hard and rigid. A very brief examination is usually sufficient to differentiate between this condition and squamous-cell carcinoma. If doubt still exists, however, a section from the convex and prominent surface of the myoma will show an outer covering of uterine mucosa, usually much atrophied, and frequently containing small round cells or polymorphonuclear leucocytes, while the underlying tissue is composed entirely of non-stripped muscle. The histological picture in no way resembles that of squamous-cell carcinoma.

SLOUGHING SUBMUCOUS MYOMA

Patients occasionally come presenting a sallow or cachetic appearance, and complaining of hæmorrhages and a profuse offensive discharge. In these cases one might be tempted, on clinical grounds alone, to make a diagnosis of carcinoma, since the symptoms are identical with those produced by a malignant condition. On vaginal examination, the parts are found bathed in an offensive,

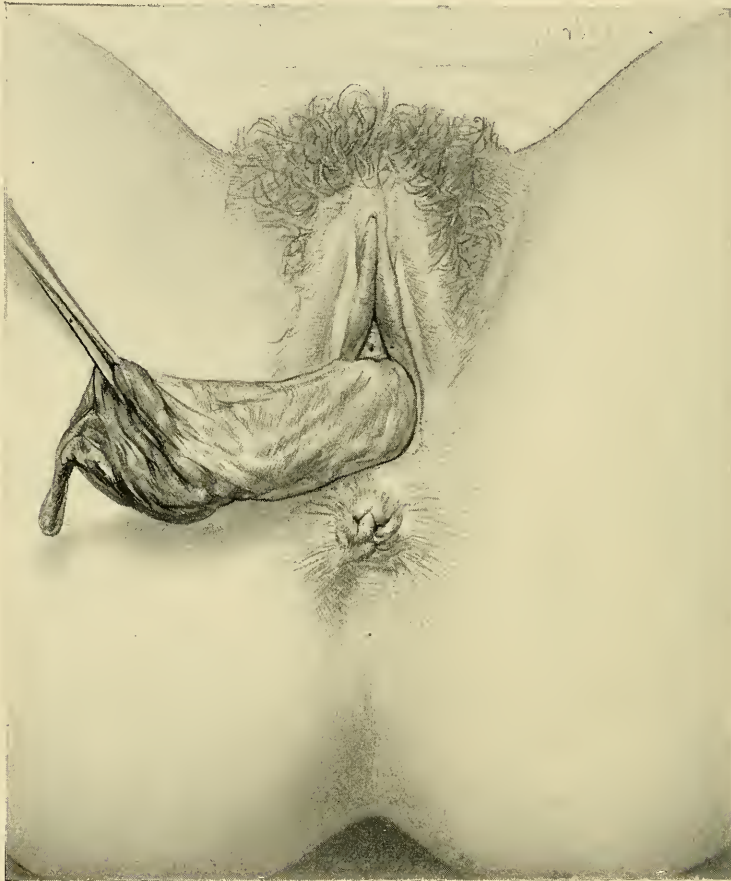

FIG. 98.—SLOUGHING SUBMUCOUS MYOMA.

Projecting from the vagina is a long, lax, flabby piece of a sloughing myoma. This presented a necrotic appearance, but was very tough. It could be traced upward to the cervix, and was found projecting from the external os. The cervical lips were intact.

A section from such tissue would show necrotic, non-stripped muscle fibres, but no epithelial elements. (After H. A. KELLY.)

watery, purulent, or bloody discharge, while projecting through the cervix are shreds or long pieces of a soft tissue. It will be found, however, that this is tough, resembling beef that has long macerated in water (Fig. 98), and that it is almost impossible to tear it; nor is it at all friable, as is that of squamous-cell carcinoma. Again, examination of the uterus will invariably reveal enlargement,

due to the remaining part of the submucous myoma and frequently to the presence of other myomata. The cervix itself usually presents the normal appearance, but should any doubt still remain, a piece is to be removed for examination, since we know that myoma and squamous-cell carcinoma may be present in the same uterus.

INTERSTITIAL CERVICAL MYOMATA

These are usually associated with myomata in other parts of the uterus, and consequently are sometimes accompanied by frequent hæmorrhages. On vaginal examination, if the myoma be situated in the stroma of the vaginal portion of the cervix, the mucosa, although subjected to tension, will be everywhere intact and smooth, while the tissue will not show the slightest tendency to bleed. A microscopical examination to distinguish the condition from squamous-cell carcinoma will not be necessary, but, as will be mentioned in a subsequent chapter, where adeno-carcinoma is suspected, some difficulty may be experienced in making the differential diagnosis.

CONDYLOMATA OF THE CERVIX

These may also be mistaken for squamous-cell carcinoma. They are very rare, and we have had only one such case in the history of the hospital (Figs. 99, 100, and 101). Here the outer part of the cervix was covered by tongue-like elevations, which were firm and smooth. On histological examination, these presented a branched appearance, were covered by many layers of squamous epithelium, and had central stems of connective tissue. They presented the typical picture of condylomata, as found in other parts of the body. Scattered throughout the stroma of the condylomata were characteristic tubercles, a part of a general tubercular infection. Condylomata were also present on the vaginal vault immediately surrounding the cervix.

Winter and Ruge merely mention condylomata. They occur most frequently during pregnancy. The growth does not look unlike a cockscomb, and is white or reddish in colour. It is narrow, and usually consists of a long base with flat epithelial outgrowths springing from it. The tissue at the bottom of the growth shows no thickening. On histological examination, the stroma is found to be composed of spindle-shaped cells, the outer surface being covered by several layers of squamous epithelium. It is evident, then, that the condylomata are distinct outgrowths from the cervix, that the squamous epithelium covering them is of the normal type, and, further, that there is no extension of the epithelium into the stroma of the cervix. These points are, in themselves, sufficient to exclude squamous-cell carcinoma.

SYPHILITIC ULCERATION OF THE CERVIX

Since no case has come under my observation, I shall content myself here with giving a free translation of Winter and Ruge's remarks on this point. Syphilitic ulcerations occurring on the vaginal portion of the cervix may assume three forms, and may appear:

1. As the initial sclerosis.
2. As broken-down papules.
3. As gummata.

1. The ulcerated and broken-down initial lesion is usually single, and is characterized by the density of its base. The ulcer often has a convoluted margin, and is covered by an adherent, dirty grayish-yellow deposit. Neumann has found these ulcerations far up in the cervical canal in multiparæ, where the cervical lips have been lacerated and are gaping.

2. The papulary ulcers are slightly elevated above the level of the cervix, and are covered with whitish or yellowish necrotic tissue. They are usually multiple; non-ulcerated papules are also found in the vagina, and especially on the vulva.

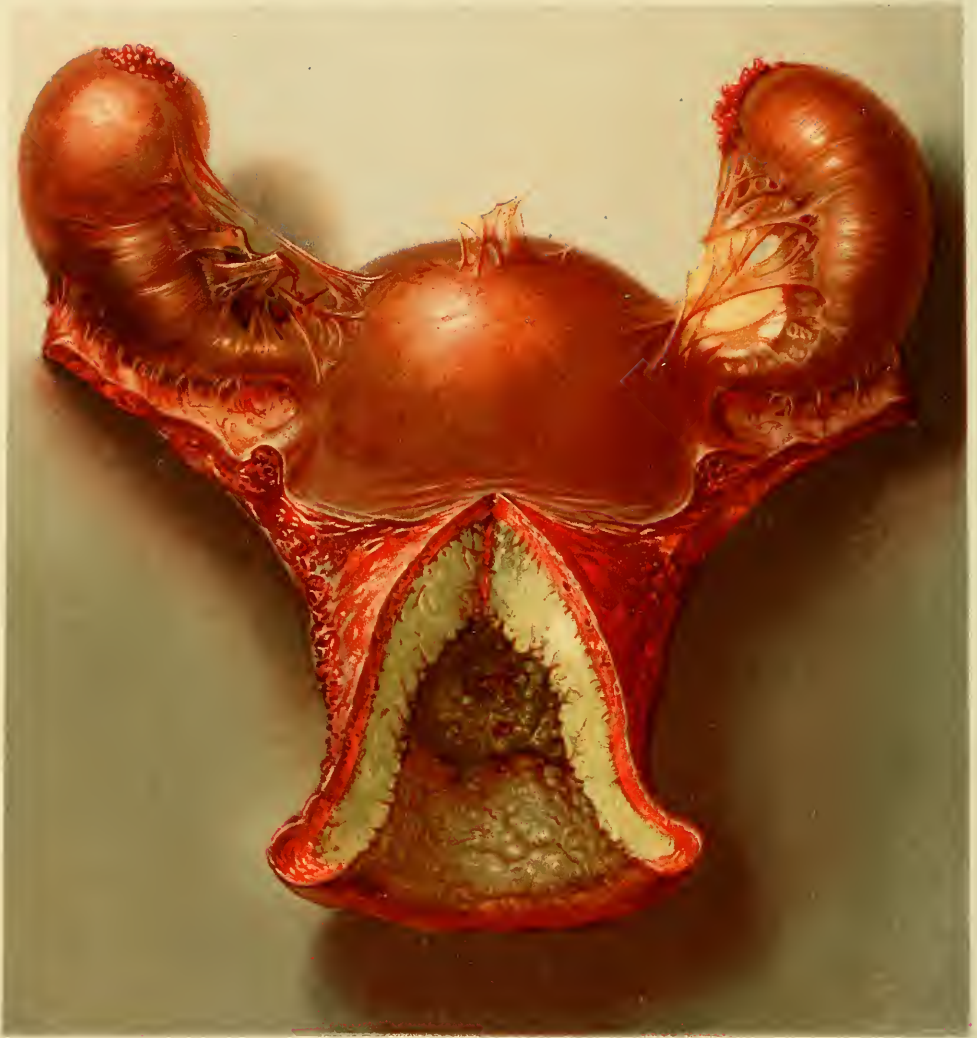
3. Gummata of the vaginal portion of the cervix are very rare. The ulcers resulting from them are elliptical, sharply defined, and are usually covered with a yellowish, puriform deposit. After this has been cast off, there often develop very vascular, sponge-like granulations. Much information can usually be obtained from the history of the case, the rapid disintegration of tissue, and the serpiginous margin. The prompt yielding to antisyphilitic treatment will clinch the diagnosis. If there still remains the slightest doubt, a small piece of tissue should be removed, when the typical appearance of a syphilitic growth will be found. This is totally different from that of squamous-cell carcinoma, the epithelium taking practically no part in the process.

TUBERCULOUS ULCERATION OF THE CERVIX

This rare condition, clinically, might readily be mistaken for squamous-cell carcinoma of the cervix. The process usually surrounds the external os, or it may appear as an ulceration on one side. The ulcer is well defined, has sharply cut, often undermined edges, while the surrounding tissue may be studded with a few miliary tubercles. The floor of the ulcer presents an eaten-out appearance, and may be covered by pus or partially broken-down caseous material. The margins of such an ulcer show a striking contrast to squamous-cell carcinoma, in that they are usually undermined instead of being elevated and indurated; again, the floor is rather soft, in contrast to the hard and nodular condition invariably made out in a carcinoma. The clinical picture will aid one materially, this condition usually being a local manifestation of a general tubercular process, or being secondary to a genital tuberculosis. For a positive diagnosis it is only requisite to remove a small piece of the wall of the ulcer for examination.

On histological examination, the margins will usually show some small-round-cell and probably polymorphonuclear infiltration; the underlying tissue presents some tubercles, while the floor of the ulcer shows in its superficial portions caseous material, in its deeper parts, typical tuberculous tissue. An accurate diagnosis can usually be made from the clinical appearances.

In Autopsy No. 970 the patient had died of a general tuberculosis. The uterus (Plate VI) at first sight strongly suggests a carcinomatous growth, but on histological examination it is seen that the epithelial elements have disappeared, so that cancer is at once excluded.



Tuberculosis of the uterus and tubes.

Autopsy No. 970. Gyn.-Path. No. 1,847. The outer or vaginal portion of the cervix is markedly injected. Through the external os a yellowish growth can be seen occupying the cervical canal. On opening the uterus, the cervical canal is found to be dilated. In the lower portion the tissue is grayish yellow and friable, but in the vicinity of the internal os it is necrotic and dark green, with reddish-brown depressions. The cervical walls, to a depth of from 5 to 10 millimetres, are involved by the new growth, which is whitish yellow in colour and cheesy in appearance. The growth involves the cervix uniformly, and stands out in marked contrast to the outer cervical walls, which are fiery red, owing to the great vascularity. The body of the uterus is comparatively smooth, except for a few adhesions at the fundus in the median line and laterally, where the tubes are attached to it by fan-like adhesions. The right tube is normal in size at its uterine end, but rapidly becomes larger, reaching 2.5 centimetres in diameter at its round fimbriated extremity. Projecting from the extremity are a few of the fimbriae, which appear to be partially constricted. The picture is characteristic of tuberculosis of the tubes. In pyosalpinx or hydro-salpinx the fimbriae are rarely seen. The tube is probably adherent both to the uterus and to the broad ligament. The left tube presents practically the same picture as the right. In this case the uniform involvement of the cervix, the comparatively smooth surface, and the whitish-yellow appearance, are all against carcinoma. The presence of the brownish and green slough, however, is suggestive of a malignant growth. The histological examination, of course, clears up the diagnosis immediately, as the new growth is found to consist almost entirely of necrotic material and the advancing margin of typical tuberculous tissue. No epithelial elements remain.

PLATE VI.—TUBERCULOSIS OF THE UTERUS AND TUBES. (Natural size.)

Autopsy No. 970. Gyn.-Path. No. 1,847. The outer or vaginal portion of the cervix is markedly injected. Through the external os a yellowish growth can be seen occupying the cervical canal. On opening the uterus, the cervical canal is found to be dilated. In the lower portion the tissue is grayish yellow and friable, but in the vicinity of the internal os it is necrotic and dark green, with reddish-brown depressions. The cervical walls, to a depth of from 5 to 10 millimetres, are involved by the new growth, which is whitish yellow in colour and cheesy in appearance. The growth involves the cervix uniformly, and stands out in marked contrast to the outer cervical walls, which are fiery red, owing to the great vascularity. The body of the uterus is comparatively smooth, except for a few adhesions at the fundus in the median line and laterally, where the tubes are attached to it by fan-like adhesions. The right tube is normal in size at its uterine end, but rapidly becomes larger, reaching 2.5 centimetres in diameter at its round fimbriated extremity. Projecting from the extremity are a few of the fimbriae, which appear to be partially constricted. The picture is characteristic of tuberculosis of the tubes. In pyosalpinx or hydro-salpinx the fimbriae are rarely seen. The tube is probably adherent both to the uterus and to the broad ligament. The left tube presents practically the same picture as the right. In this case the uniform involvement of the cervix, the comparatively smooth surface, and the whitish-yellow appearance, are all against carcinoma. The presence of the brownish and green slough, however, is suggestive of a malignant growth. The histological examination, of course, clears up the diagnosis immediately, as the new growth is found to consist almost entirely of necrotic material and the advancing margin of typical tuberculous tissue. No epithelial elements remain.

Autopsy No. 970. Gyn.-Path. No. 1,847. The outer or vaginal portion of the cervix is markedly injected. Through the external os a yellowish growth can be seen occupying the cervical canal. On opening the uterus, the cervical canal is found to be dilated. In the lower portion the tissue is grayish yellow and friable, but in the vicinity of the internal os it is necrotic and dark green, with reddish-brown depressions. The cervical walls, to a depth of from 5 to 10 millimetres, are involved by the new growth, which is whitish yellow in colour and cheesy in appearance. The growth involves the cervix uniformly, and stands out in marked contrast to the outer cervical walls, which are fiery red, owing to the great vascularity. The body of the uterus is comparatively smooth, except for a few adhesions at the fundus in the median line and laterally, where the tubes are attached to it by fan-like adhesions. The right tube is normal in size at its uterine end, but rapidly becomes larger, reaching 2.5 centimetres in diameter at its round fimbriated extremity. Projecting from the extremity are a few of the fimbriae, which appear to be partially constricted. The picture is characteristic of tuberculosis of the tubes. In pyosalpinx or hydro-salpinx the fimbriae are rarely seen. The tube is probably adherent both to the uterus and to the broad ligament. The left tube presents practically the same picture as the right. In this case the uniform involvement of the cervix, the comparatively smooth surface, and the whitish-yellow appearance, are all against carcinoma. The presence of the brownish and green slough, however, is suggestive of a malignant growth. The histological examination, of course, clears up the diagnosis immediately, as the new growth is found to consist almost entirely of necrotic material and the advancing margin of typical tuberculous tissue. No epithelial elements remain.

Autopsy No. 970. Gyn.-Path. No. 1,847. The outer or vaginal portion of the cervix is markedly injected. Through the external os a yellowish growth can be seen occupying the cervical canal. On opening the uterus, the cervical canal is found to be dilated. In the lower portion the tissue is grayish yellow and friable, but in the vicinity of the internal os it is necrotic and dark green, with reddish-brown depressions. The cervical walls, to a depth of from 5 to 10 millimetres, are involved by the new growth, which is whitish yellow in colour and cheesy in appearance. The growth involves the cervix uniformly, and stands out in marked contrast to the outer cervical walls, which are fiery red, owing to the great vascularity. The body of the uterus is comparatively smooth, except for a few adhesions at the fundus in the median line and laterally, where the tubes are attached to it by fan-like adhesions. The right tube is normal in size at its uterine end, but rapidly becomes larger, reaching 2.5 centimetres in diameter at its round fimbriated extremity. Projecting from the extremity are a few of the fimbriae, which appear to be partially constricted. The picture is characteristic of tuberculosis of the tubes. In pyosalpinx or hydro-salpinx the fimbriae are rarely seen. The tube is probably adherent both to the uterus and to the broad ligament. The left tube presents practically the same picture as the right. In this case the uniform involvement of the cervix, the comparatively smooth surface, and the whitish-yellow appearance, are all against carcinoma. The presence of the brownish and green slough, however, is suggestive of a malignant growth. The histological examination, of course, clears up the diagnosis immediately, as the new growth is found to consist almost entirely of necrotic material and the advancing margin of typical tuberculous tissue. No epithelial elements remain.

Am. J. Path. 1970, 95: 247. The first individual portion of the testis is normally
insect. The second the external as a yellowish, smooth, and be seen a surface to certain, dark.
On opening the uterus the external, and is found to be divided. In the upper portion the tissue
is gray, yellow and friable, but in the lower portion it is reddish and dark gray
with red-brown, and brown. The external wall is a light gray, and the internal
involved. The lower portion is white, yellow, and brown, and shows an appearance. The
growth involves the outer and inner walls, and the internal wall is the outer par-
walls, which is the outer wall of the testis. The internal wall is the inner par-
tively smooth, and the outer wall is the outer wall of the testis. The internal wall is
the internal wall of the testis, and the outer wall is the outer wall of the testis.
end, but appears to be a normal, and is found to be a normal, and is found to be a
extremity. The internal wall is the internal wall of the testis, and the outer wall is
contracted. The internal wall is the internal wall of the testis, and the outer wall is
salpinx the normal, and is found to be a normal, and is found to be a normal, and
broad, and is found to be a normal, and is found to be a normal, and is found to be
the uniform, and is found to be a normal, and is found to be a normal, and is found to be
appearance of a normal, and is found to be a normal, and is found to be a normal, and
is suggested of a normal, and is found to be a normal, and is found to be a normal, and
diagnosis, and is found to be a normal, and is found to be a normal, and is found to be
and the abdominal wall of the testis, and is found to be a normal, and is found to be a

In Case 6,564, where the cervix and vaginal vault were studded with condylomata (Figs. 99, 100, 101), tuberculosis was at first not suspected, and was only revealed on histological examination. In this case the diagnosis lay between carcinoma of the cervix and condylomata.

Autopsy No. 970

General tuberculosis, including tuberculosis of the uterus, tubes and ovaries.

July 23, 1897. The patient died of general tuberculosis.

The uterus measures 7 centimetres in length, 4.5 centimetres in breadth, 4.5 centimetres in its antero-posterior diameter. The fundus is smooth, but the remaining portion of the body is completely hidden from view, being densely adherent to the bladder in front, to the rectum behind, and laterally to the tubes and ovaries. Situated in the left vaginal fornix is an ulcer, 1.5 centimetres in diameter and 1 centimetre in depth. This has sharply defined margins, and presents a smooth base, studded with minute yellowish-white dots varying from a pin-point to 1 millimetre in diameter. The cervix projects 3 centimetres into the vagina, and averages 2.5 centimetres in diameter. There is a slight transverse laceration. The lips are very red and injected, but present an intact surface (Plate VI). The outer surface of the cervix, 1 centimetre from the os, both on the right and left sides, presents a raised appearance, the tissue being whitish yellow in colour and showing an irregular, eaten-out appearance, the small ulcers varying from 1 to 3 millimetres in diameter. On opening the cervix a cavity 1.5 centimetres in diameter is found, beginning at a point 1.5 centimetres above the external os. This contains a dirty, necrotic material; its walls are ragged, eaten-out and irregular, and are made up of neoplastic tissue, which invades the cervical and uterine walls to within 3 millimetres of their outer surfaces. This tissue is whitish yellow in colour, softish, and stands out in sharp contrast to the injected uterine walls. Upward, the growth extends to the body of the uterus; downward, to within 3 millimetres of the external os. Both tubes at their uterine extremities are small, but rapidly increase in size, so that at the fimbriated extremities, which are still open, they measure 2 centimetres in diameter. Both ovaries are converted into necrotic, sloughing, caseous masses.

Histological Examination.—(Gyn. No. 1,847.) The cervix, even at the external os, where it presents a markedly injected appearance, has lost its epithelium, and is to a considerable depth represented by a necrotic caseous material. The bright-red colouration was due to marked dilatation of the underlying vessels. The cervical glands are nowhere recognisable; the entire canal from the external os upward is lined by caseous material. The tissue beneath this shows marked small-round-cell and polymorphonuclear infiltration; the blood-vessels are greatly dilated. In one or two places in the depth typical tubercles can be made out. These consist of a central giant cell surrounded by epithelioid cells, while external to these again are small round cells. The outer surface of the cervix to a considerable depth is also caseous. From the appearance one would not hesitate to make a diagnosis of tuberculosis. Specimens stained with fuchsin show the caseous areas fairly teeming with tubercle bacilli, some fields containing fully two hundred of them.

Gyn. No. 6,564

Attempted vaginal hysterectomy for condylomata and tuberculosis of the cervix. The autopsy revealed tuberculosis of the endometrium, tubes and ovaries; miliary tuberculosis of the lungs; tuberculous pleuritis; tuberculous ulceration of the intestines; tuberculosis of the spleen and kidneys; solitary tubercles in the brain.

B. B., aged seventeen; coloured. Admitted December 3, 1898.

The patient complains of pain in the abdomen and back. She had diphtheria, measles, and mumps when a child, but had always been strong until March, 1895, when she was admitted to an industrial home; since then she has never been well. Her menses began when she was thirteen years of age; were always regular; lasted from two to four days, and were accompanied by much pain. The patient has not menstruated for over a year. Her father, sister, and brother died of tuberculosis.

Present illness: In January, 1898, she began to notice a profuse, offensive, leucorrhœal discharge. In March she had a fever, which lasted about three weeks and was accompanied by pain in the back, abdomen, head, and chest. There was no cough. Since then she has never been perfectly well; she has had fever at times, and has suffered with much abdominal pain. The patient is well nourished; the chest is symmetrical, and expansion is good; the pulmonary and cardiac sounds are clear. The abdominal examination is negative. The urine shows little change.

December 12th: Examination under anæsthesia. The outlet is intact, the vagina is much elongated, and far back on the right is an elevation which at first appears to be the cervix. On further examination, however, it is found that the entire cervix and the surrounding vaginal vault are occupied by firm, smooth, polypoid elevations (Figs. 99, 100, 101). These are pinkish in colour, and do not show the slightest tendency to bleed. Several of the small polypoid masses were removed for examination. On December 18th the patient developed an otitis media on the left side, and the ear was syringed out twice daily with a warm saturated solution of boric acid. The discharge soon ceased entirely. The patient for some time had been presenting a characteristic tuberculous temperature, the fever rising every evening to 102° or 103° F.

December 21st: The cervix was amputated by Dr. Kelly. It was ringed with much difficulty and separated from the bladder. On account of the dense character of the tissue and of the surrounding infiltration, it was found impossible to remove the uterus. The cervix was accordingly amputated, quite severe hæmorrhage being met with during the operation. Some bleeding points, which could not be controlled by ligature, were clamped. The forceps occasioned much pain, and were removed at the end of seventy-two hours. The vaginal packs were removed on December 29th, and by January 6th the patient was able to sit up for a short time every day. She still showed some fever in the afternoon. On January 9th the temperature was 104° F. at 8 A. M., although the cervical wound presented a healthy appearance. On January 13th there was a slight cough, and

some blood-stained sputum. On the left side there was a suggestion of a pleuritic friction rub. The pulmonary symptoms gradually increased, the respirations became very laboured, and the patient died January 22, 1899.

Gyn.-Path. No. 2,775. December 4, 1898. The specimen consists of numerous small, smooth, firm, polypoid masses, removed from the vaginal portion of the cervix and the vaginal vault in its immediate vicinity.

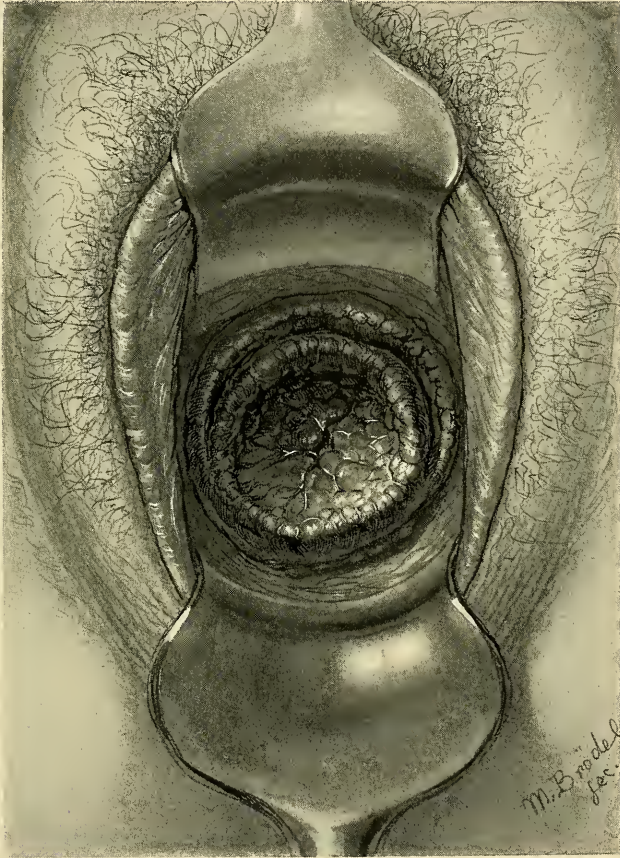


FIG. 99.—CONDYLOMATA AND TUBERCULOSIS OF THE CERVIX AND VAGINAL VAULT. (Natural size.)

Gyn. No. 6,564. The entire cervix presents a rough, uneven appearance, due to coarse lobulations. Its outer margin is represented by an elevated ridge which also shows lobulations, while the vaginal vault surrounding it forms a secondary ridge in front and to the sides. On digital examination the projections were found to be very firm; they slipped easily under the finger and no bleeding followed the manipulation. From the sketches (Figs. 100 and 101) it will be seen that the cervix was invaded only for a short distance, and that no breaking down had occurred.

Histological Examination.—These projections are covered over by many layers of squamous epithelium. The individual epithelial cells are practically normal, but at numerous points polymorphonuclear leucocytes and small round cells have wandered in between the epithelial elements. The stroma of these projections to a great extent resembles that of the cervix, but at many

points shows considerable small-round-cell and polymorphonuclear infiltration. Many of the polymorphonuclear leucocytes have been drawn out and distorted, forming the so-called *Abschnürungsvorgänge*. The most interesting feature is

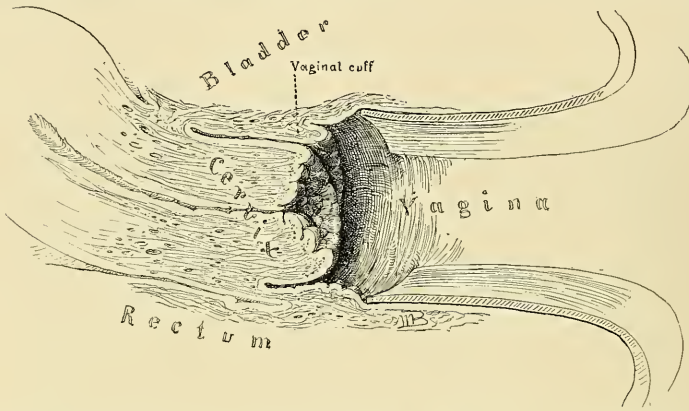


FIG. 100.—CONDYLOMATA AND TUBERCULOSIS OF THE CERVIX. ($\frac{4}{7}$ natural size.)

Gyn. No. 6,564. This figure is a schematic representation of Fig. 99 on longitudinal section. The smooth surface of the lobulation and the vaginal cuff, which partially surrounded the cervix, are clearly seen. There is no loss of substance in the cervix.

the presence of some typical tubercles in the stroma, some being found in the depth, others in close proximity to the epithelium.

Gyn.-Path. No. 2,792. December 12th. The specimen consists of larger pieces of tissue from the same cervix, including, of course, some from within the external os. On histological examination, evidences of previous curetting are very marked. The surface is covered by fibrin, broken-down cells, and a few polymorphonuclear leucocytes, while the underlying tissue presents the typical picture of a granulating surface. The cylindrical epithelium lining the cervical canal is nearly everywhere intact, and the cervical glands are, on the whole, normal, but the stroma of the cervix contains many tubercles, consisting chiefly of epithelioid cells with a surrounding zone of small round cells. Some of the tubercles have undergone caseation, and in the caseous material polymorphonuclear leucocytes are demonstrable. Tubercle bacilli are readily found.

The polypoid condition of the cervix and surrounding vaginal mucosa, as has been shown from the description, is due to the presence of condylomata. Such growths of the cervix are rarely met with, and this is the first case that we have seen in the Johns Hopkins Hospital. The presence of tuberculous tissue in the stroma of these condylomata is particularly striking, but must be considered merely as a coincidence. As the accompanying autopsy report shows, the patient was suffering from a general tuberculous infection.

Clinically, the age of the patient, the absence of the bleeding on manipulation, and the firm character of the polypoid masses, are all against cancer of the cervix. The histological examination is even more convincing, as the epithelium forms a uniform layer, and shows absolutely no tendency to invade the underlying stroma; furthermore, the epithelial cells themselves are uniform in size, and show no increase in the amount of chromatin.

Autopsy No. 1,257. January 24, 1899.

Anatomical diagnosis: Tuberculosis of the cervix uteri, of the endometrium, and Fallopian tubes; miliary tuberculosis of the lungs; tuberculous pleuritis; tuberculous ulceration of the intestines; tuberculosis of the spleen and kidneys; solitary tubercles in the brain.

The body is 163 centimetres long, and shows pigmented scars over both shins.

The peritoneal cavity contains only a small amount of fluid. The liver is bound to the parietal peritoneum and diaphragm by firm adhesions; the stomach is adherent to the transverse colon. The intestinal loops are lightly bound together by old adhesions. The urinary bladder has become adherent to the rectum, thus completely hiding the uterus and its appendages. The spleen is bound down by a few old adhesions, and contains several small tuberculous nodules. The kidneys also contain small tubercles, and the retroperitoneal and mesenteric glands are large, firm, and caseous. The heart shows no important change. The pleural cavities are traversed by a few adhesions, while studding the costal pleura and that covering the surface of the lungs and the diaphragm are numerous conglomerate yellow tubercles. The left pleural cavity is almost entirely obliterated, and at one point in the adhesions is a caseous mass 1.5 centimetres in diameter. Both lungs are large, and on section are seen to be studded from apex to base with small conglomerate tubercles, each of which shows a yellowish, opaque central point. The bronchi are markedly congested; the bronchial and tracheal glands are caseous. Throughout the lower two thirds of the ileum are several nodular elevations in the mucosa and four small hæmorrhagic and punched-out ulcers. Two similar ulcers are found in the colon just below the cæcum. Several tubercles are scattered throughout the brain substance. The uterus, tubes, and ovaries are bound together in a mass of adhesions. A portion of the cervix has been removed, and the surface of the part remaining shows superficial necrosis. The cavity of the uterus is lined with a yellowish, cheesy material; the uterine walls are pale. The tubes are twisted on themselves, and both contain caseous material. The right ovary is situated just above the uterus; it is involved in firm fibrous adhesions, and in the vicinity of the tube has become caseous. Between the ovary, the body of the uterus, and the tube on the right side, is a space walled off by adhesions and communicating by a tortuous sinus with the rectum, 20 centimetres from the anus. The rectal opening of the sinus is 4 millimetres in diameter, and is surrounded by a group of ulcers. The left ovary contains a cyst filled with dark-red tenacious contents.

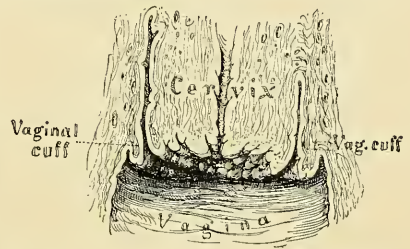


FIG. 101.—CONDYLOMATA AND TUBERCULOSIS OF THE CERVIX. ($\frac{2}{7}$ natural size.)

Gyn. No. 6,564. This represents the posterior half of the cervix from Fig. 99. The cervical outlines are still perfectly preserved, and the cervical canal is intact.

SARCOMA OF THE CERVIX

Sarcoma of the cervix occurs with much less frequency than squamous-cell carcinoma.

J. Whitridge Williams,* in an excellent *resumé*, has collected quite a number of cases. He refers in detail to the "grape-like" sarcoma of the cervix, first described by Spiegelberg in 1879. In a patient seventeen years old the anterior cervical lip was thickened and enlarged, while covering its margins and surface were oval, yellowish-brown outgrowths, 1 or 2 centimetres in length. These

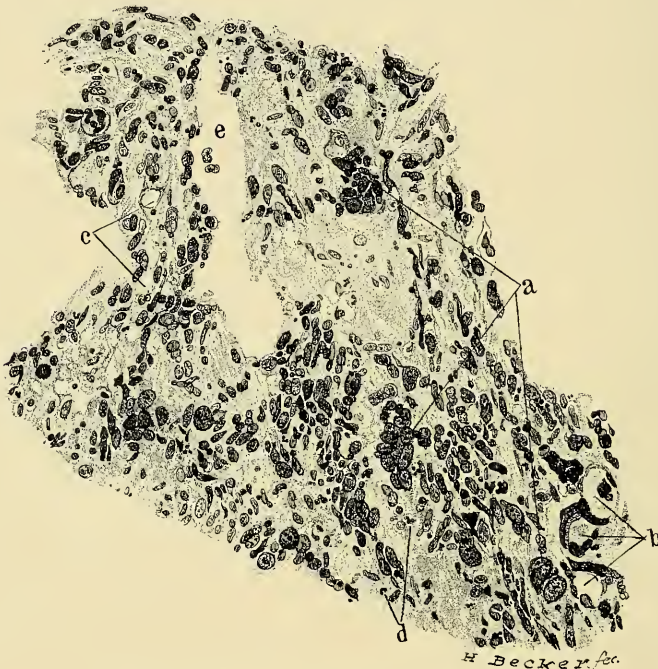

FIG. 102.—SARCOMA OF THE CERVIX. (200 diameters.)

Gyn.-Path. No. 1761. A casual glance is sufficient to convince the reader that the tissue forms a homogeneous mass, there being no differentiation into stroma and epithelium as in carcinoma. The cell outlines are not demonstrable. The nuclei, as a rule, are oval, and stain somewhat deeply, but at points indicated by *a* are gathered up into clumps, with the formation of giant cells. At *b* the protoplasm of the cells contains vacuoles, and the nuclei, which stain intensely, are pushed to the cell margin, assuming irregular half-moon shapes. Other vacuoles are seen at *c*. Scattered throughout the growth are polymorphonuclear leucocytes, as shown at *d*. There are also numerous small round cells. The space *e* is an artefact, due to tearing by the curette.

looked like transparent cysts, were readily crushed, and contained a thick, sticky fluid. The girl returned nine months later with the entire vagina filled by a growth, which resembled a hydatidiform mole. Weigert, who examined the tissue microscopically, found these cyst-like masses covered by a single layer of cylindrical epithelium, while internally they were composed of large, round, spindle-

* Williams, J. Whitridge. *Contributions to the Histology and Histogenesis of Sarcoma of the Uterus*. *Am. Jour. Obstetr.*, 1894, vol. xxix.

shaped and branching cells, separated from one another by clear spaces, which were traversed by fine threads. Williams states further that, in the majority of the cases collected, the disease manifested itself before the twentieth year or after the menopause. In only three cases had it occurred between these periods.

The clinical diagnosis between squamous-cell carcinoma of the cervix and this grape-like sarcoma is comparatively easy, as the former is exceedingly rare before the twentieth year, and occurs most frequently just before the menopause. On examining the uterus in squamous-cell carcinoma, such grape-like bunches of cysts are never found springing from the cervix, and on histological examination the pictures are totally different.

Williams, besides this group of grape-like sarcomata, found in the literature eighteen other cases of sarcoma of the cervix. These differed greatly from one another, both macroscopically and microscopically.

It is a safe rule to lay down (leaving out the grape-like variety), that a positive diagnosis between squamous-cell carcinoma and sarcoma of the cervix cannot be made without a microscopic examination. The records of Cases 3,348 (p. 205) and 3,370 (p. 203) show that even then it is at times impossible to reach a clear diagnosis.

A clinical examination of Case 5,308 showed a cervix extensively invaded by a malignant growth, which, however, apart from an unusual hardness of the tissue, in no way differed from carcinoma. A glance at Figs. 103 and 104 shows that the histological picture varies materially from that found in squamous-cell carcinoma. The cell-nests with the intervening stroma are entirely missing, the growth being composed of one apparently homogeneous mass of cells. Furthermore, these individual cells are in many places spindle-shaped, and tend to arrange themselves around the blood-vessels. In carcinoma we usually expect to find the blood-vessels traversing the stroma, but here (Fig. 104) the delicate capillaries pass between the cells of the growth, there being no intervening stroma. This is one of the cases in which the diagnosis between carcinoma and sarcoma is easily and conclusively made.

Fig. 102 is from a second case of sarcoma of the cervix occurring in the Johns Hopkins Hospital. Here, although macroscopically the process showed no points by which it could be differentiated from a squamous-cell carcinoma, the microscopical picture is decisive for sarcoma. There is no tissue that could be spoken of as stroma, and the cells of the growth, although varying greatly in size, form a homogeneous mass.

Gyn. No. 5,308

Sarcoma of the cervix (Figs. 103 and 104). Extension to the vaginal vault posteriorly.

C., aged thirty-eight. Admitted June 3, 1897. Complaint: hæmorrhage and watery discharge from the uterus for the past four months; pain in the back and left inguinal region; painful defecation.

The patient has been married twenty-one years, and has had eight children: the last labour occurred eight months ago. All the labours were non-instrumental, but during the second the cervix was lacerated. The menses commenced at fourteen, were always regular, lasted four days, and were not accompanied by any

pain. After the birth of the first child there was some dysmenorrhœa. Following the last labour, menstruation reappeared in six weeks. Her family and previous history are unimportant.

Present illness: In February, 1897 (four months before admission), she suddenly began to have copious uterine hæmorrhages; these continued for about ten days, gradually ceased, and were followed by a watery discharge. There was no pain, but some uneasiness was felt in the pelvis. For the last two months there has been almost constant loss of blood with an accompanying watery discharge.

Present condition: The patient is not emaciated, but is very pale and anæmic; the mucous membranes are pale; the tongue is clean; the appetite is fairly good; she is easily fatigued; the pulse is rather feeble and of poor volume; the heart and lung sounds are normal.

On vaginal examination, the cervix is found to be the seat of a new growth. This is hard and nodular, filling the entire vaginal vault. It has also extended down to the left side of the vagina.

Operation, June 7, 1897. A bougie was introduced into the left ureter and a large handful of the growth cut off from the left side of the vagina. The lower part of the cervix was then removed with the forceps, and a large, flat, green, sloughing plaque of tissue was curetted from the recto-vaginal septum, one finger being introduced into the rectum to protect its mucosa from injury. It was found that the disease had extended to the base of the bladder, and on the left side half-way down the vagina. Several spurting blood-vessels were controlled by catgut sutures.

Ten days after the operation the patient had a severe chill, and the temperature reached 104° F. She was discharged June 25, 1897, slightly improved.

Gyn.-Path. No. 1,773. Diagnosis: Large spindle-celled sarcoma of the cervix uteri.

The specimen consists of four pieces of tissue removed from the cervix; they vary from 2 to 6 centimetres in diameter, and consist of a soft succulent tissue, which on section presents a perfectly smooth surface, showing none of the granular appearance so commonly noted in carcinoma. Moreover, it is impossible to see any trabeculae dividing the growth into smaller areas.

On histological examination, there are still a few cervical landmarks. At one point the squamous epithelium of the vaginal portion of the cervix is intact, and except for moderate polymorphonuclear infiltration is but little altered (Fig. 103). Immediately beneath this are a few cervical glands. These are somewhat distorted and dilated, their epithelium is flattened, and they contain fragmented nuclei, polymorphonuclear leucocytes, and mucus. The stroma immediately surrounding them presents considerable small-round-cell infiltration, and then ends abruptly in a new growth which occupies the greater part of the section. This growth consists for the most part of spindle-shaped cells which form whorls, or run in almost every direction, making up an exceedingly dense tissue (Figs. 103 and 104). These cells have nuclei which are irregularly oval, spindle-shaped, or sometimes round, the shape depending a good deal on the way in

which the sections are cut. The nuclei stain uniformly, and it is often possible to see in a single field three or four nuclear figures (Fig. 104, *h*). The blood supply is apparently fairly abundant, although it is difficult to speak with

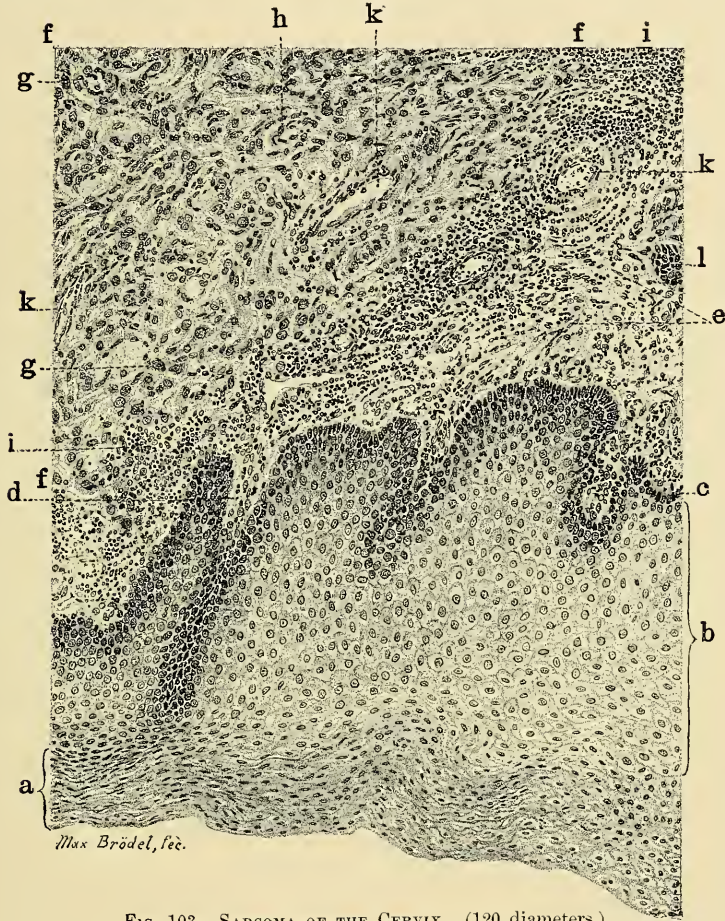

FIG. 103.—SARCOMA OF THE CERVIX. (120 diameters.)

Gyn.-Path. No. 1,773. The surface is covered by squamous epithelium. *a* indicates the horny layer. *b*, polygonal cells. *c*, the deep or cuboidal layer. *d* is the base of one of the papillae. The average size of a normal stroma cell is seen at *e*. The triangular area occupying the left upper corner of the picture, and included by the letters *f, f, f*, differs greatly from the normal stroma, and forms a portion of the new growth. The majority of the cells are spindle-shaped, have spindle-shaped or oval nuclei, and tend to form whorls (*h*). The central portions of these whorls are blood capillaries. Some of the cells contain enlarged, irregular, and deeply staining nuclei, as shown at *g, g*. Where the new growth joins the stroma there is much small-round-cell infiltration, especially pronounced at *i*. *k* indicates capillaries. *l* is a small nest of sarcoma cells.

This growth could not be confused with an adeno-carcinoma, since no gland-like arrangement exists. Again, there is not much likelihood of mistaking it for a squamous-cell carcinoma, since the squamous epithelium is normal and the cells of the growth are spindle-shaped, form a homogeneous mass, and tend to arrange themselves around the delicate capillaries.

certainty on this point, since the specimen has been hardened in alcohol. The centres of many of the whorls are evidently the seats of blood-vessels. At one point a cervical gland is seen opening on the surface; the surrounding

stroma has been almost entirely replaced by areas of new growth (Fig. 104, *a*). At a few points there are localized infiltrations with polymorphonuclear leucocytes. The surface of the section at one point shows considerable necrosis, the limits are sharply defined, the process ending somewhat abruptly. The necrotic tissue shows slight polymorphonuclear infiltration. There is no possibility of mistaking this growth for carcinoma.

Sarcoma of the body of the uterus projecting through the external os.

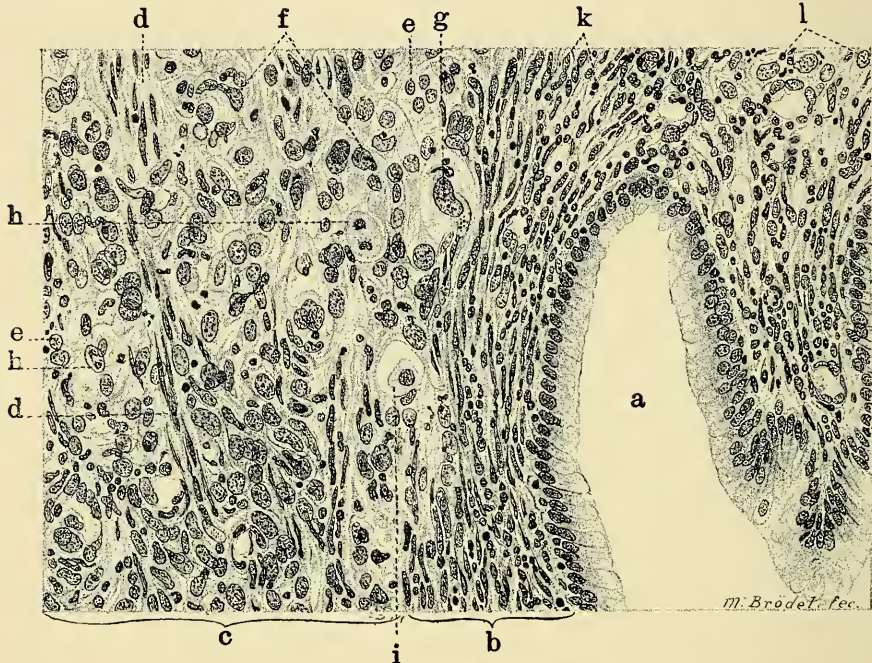


FIG. 104.—SARCOMA OF THE CERVIX. (240 diameters.)

Gyn.-Path. No. 1,773. *a* is the cavity of a normal cervical gland. *b*, the typical cervical stroma. *c*, a portion of the growth. This growth is composed of cells forming an almost homogeneous mass, being subdivided into smaller areas only by delicate capillaries (*d*), recognised by the double row of spindle-shaped cells, the capillary endothelium. *e* shows the average size of the nucleus of the sarcoma cell, which is round, or slightly oval, and vesicular. The nuclei at *f* are larger, and irregular in form. At *g* they are still larger. An oval cell containing a diaster is seen at *h*. The cell has contracted during the hardening and a clear space is left. The stroma of the cervix contains numerous small round cells, as indicated by *k*. At *l* are a few isolated sarcoma cells. In carcinoma such a homogeneous arrangement of the cells is rarely met with, and the capillaries do not, as a rule, pass in and out between the individual cells of the growth.

Occasionally, as seen in Fig. 287 (p. 556), a sarcoma of the body of the uterus will project through the cervix, presenting the clinical picture depicted in Fig. 288 (p. 557). In such a case the lobulated surface of the growth does not look unlike a squamous-cell carcinoma, but the fine finger-like processes are lacking. A digital examination will show that the cervical lips are intact, and that the growth springs from a point within the external os. The histological examination will at once show the usual differences between sarcoma and squamous-cell carcinoma.

MALIGNANT GROWTHS OF THE CERVIX, CONCERNING WHICH, EVEN ON HISTOLOGICAL EXAMINATION, A POSITIVE DIAGNOSIS IS DIFFICULT

Gyn. No. 3,370

A malignant growth of the cervix, probably adeno-carcinoma, although squamous-cell carcinoma or sarcoma cannot be excluded. Abdominal hysterectomy. Local recurrence, followed by death several months later.

H., aged thirty-three. Admitted March 13, 1895. A pregnancy was complicated by carcinoma of the cervix. Dr. Kelly was called in during labour to determine whether Cæsarean section was necessary. The patient was immediately brought to the hospital; the cervix was widely dilated by the ordinary dilators, the Tarnier forceps applied, and the child delivered. No hæmorrhage followed. The placenta was extracted, and the anterior lip of the cervix, which was badly torn and completely involved by the carcinoma, was amputated. The patient returned subsequently for removal of the uterus.

Gyn.-Path. No. 709. The specimen consists of the uterus and appendages intact. The anterior surface of the uterus over its upper half is smooth and glistening, while the posterior surface is covered by delicate adhesions. The organ measures $10 \times 7 \times 4.5$ centimetres. The posterior cervical lip is converted into a glazed, elevated nodule 4×3 centimetres, which projects 2.5 centimetres into the vagina. The surface of the growth is bright red in colour. Near the vaginal junction it is slightly eaten out. The anterior cervical lip, which is 2 centimetres in thickness, is reddened and slightly corrugated; on section, it is found to be invaded to a depth of at least 5 millimetres. The cut surface of the nodule in the posterior lip presents a waxy appearance and is yellowish white in colour. In the superficial portions the tissue is homogeneous, but in the vicinity of the normal tissue it is divided up, by delicate white trabeculæ, into small alveoli. The line of advancement is irregular, but sharply defined. The mucosa covering the upper part of the posterior cervical lip has been pushed forward by the growth; it is yellowish white in colour, and longitudinally corrugated. The uterine walls vary from 1 to 2 centimetres in thickness; the cavity is 4 centimetres in length, and at the fundus is 3.5 centimetres broad. The mucosa is bright red in colour, presents a finely granular or worm-eaten appearance throughout its entire extent, and varies from 1 to 2 millimetres in thickness.

HISTOLOGICAL EXAMINATION.—The squamous epithelium over the outer portion of the posterior lip is in many places intact and presents the normal appearance, but that covering the prominent portion of the tumour is considerably altered. It now consists of only three or four layers; the individual cells contain less protoplasm and some are slightly vacuolated, while between the epithelial cells and also on the surface are numerous polymorphonuclear leucocytes. The thickened portion of the cervix is, for the most part, composed of cells closely packed together. The nuclei are oval, vesicular, and fairly uniform in size; here and there, however, are large oval, deeply staining nuclei, some of which are dividing, while scattered everywhere throughout the tissue are nuclear

figures, and occasionally an oval mass of protoplasm, containing four or five oval, somewhat deeply staining nuclei.

The stroma of the new growth is scant, and consists chiefly of the walls of delicate blood-vessels, which pass in between the individual cells. There is no evidence of necrosis in the tissue. On leaving the more prominent part of the tumour the growth can be seen invading the tissue as delicate finger-like projections; the cells of the advancing portion seem to be more active, and some of them contain large masses of protoplasm and not infrequently four or five nuclei.

In direct proportion with the distance from the most prominent part of the nodule, the fewer the finger-like outgrowths which are seen. The stroma of the cervix, just beneath the surface epithelium, shows considerable small-round-cell infiltration; the small blood-vessels in the vicinity contain irregular masses of tumour cells. The growth can be traced laterally as far as the broad ligament, where a small tumour nodule can be seen on either side of an artery. These nodules are almost perfectly round, the larger being composed of cells identical with those of the original tumour, some of which contain nuclear figures. This nodule has separated somewhat from the wall of its containing cavity, so that it is possible to see that this has an endothelial lining composed of one layer of spindle cells. The cavity is probably a lymph space. The anterior lip of the cervix shows very little involvement, but small tumour masses are scattered throughout its stroma. This tumour at the time of its examination was looked upon as a sarcoma of the round-cell variety. The diagnosis of sarcoma was based upon several points:

1. Macroscopically, the growth occurred as a single nodule, having a comparatively smooth surface which showed only slight disintegration at one point.
2. On histological examination it was found to be covered by squamous epithelium.
3. The cellular elements of the growth preponderated, there being an exceedingly small amount of stroma.
4. Blood capillaries were present between masses of tumour cells.
5. No necrosis could be made out.

Squamous-cell carcinoma could not, however, be absolutely excluded, as the squamous epithelium at one point might have penetrated into the depth and there spread out without giving rise to much superficial involvement. Such an explanation, however, is not very satisfactory.

On examining the specimen two years after, it is found that in some of the alveoli there is a faint gland-like arrangement. It looks as if, owing to the superabundant growth of glands, the cells have become pressed one against the other, until at almost every point the glands are so distorted that they are hardly any longer recognisable as such. In one or two places, however, the typical gland-like arrangement has been preserved.

While sarcoma cannot be excluded, we are inclined to regard the growth as an adeno-carcinoma. It is one of those cases in which competent observers will differ, and no criticism would be justified should the pathologist make a diagnosis of sarcoma, adeno-carcinoma, or squamous-cell carcinoma. Happily for the surgeon the question is of little importance, as all these conditions require the same operative treatment.

It may be mentioned that the uterine mucosa showed considerable small-round-cell infiltration, and that the appendages were normal.

Dr. S. W. Seldner, of Baltimore, in answer to my inquiry concerning the subsequent history, writes me that "the vagina was studded with cancerous growths." The exact date of death is unknown.

Gyn. No. 3,348

Squamous-cell carcinoma of the cervix (Fig. 105), in places resembling an alveolar sarcoma. Extension to the broad ligaments; abdominal hysterectomy.

H., aged fifty-eight. Menstruation ceased ten years ago.

Operation, hysterо-salpingo-oöphorectomy, March 13, 1895.

Gyn.-Path. No. 625. The specimen consists of the uterus and appendages intact. The uterus measures 5.5 centimetres in length and 7 centimetres in breadth. It is covered by peritoneum both anteriorly and posteriorly; the under surface is represented by a ragged mass of tissue 7 × 5 centimetres. On section, the entire lower portion of the uterine cavity is filled by a ragged-looking growth, above which there remains 1.5 centimetres of the uterine cavity. The mucosa covering this portion is 4 millimetres in thickness, smooth and glistening, and covered with blood.

On histological examination, the lower and ragged portion of the uterus is found to be composed of non-striped muscle fibres, and is everywhere

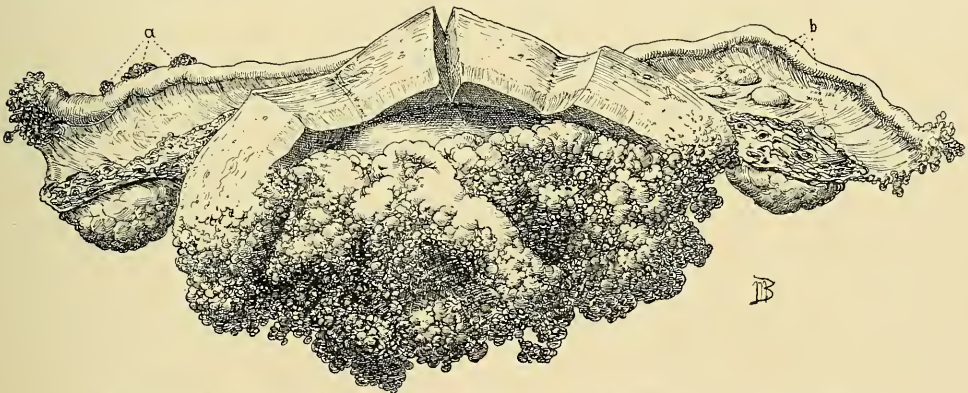


FIG. 105.—ADVANCED SQUAMOUS-CELL CARCINOMA OF THE CERVIX. ($\frac{2}{3}$ natural size.)

Gyn.-Path. No. 625. The cervix has entirely disappeared, and the greater part of the uterus is replaced by a new growth, the surface of which shows many fine, smooth, dome-like elevations. Little of the uterine mucosa remains, and the point of junction with the new growth is sharply defined. Attached to the surface of the right tube are several subperitoneal cysts (*a*), and situated in the left tubo-ovarian ligament are four small oval nodules (*b*). These are apparently phleboliths. The left tube and both ovaries are normal. (After H. A. KELLY.)

infiltrated by branching and finger-like alveoli, many of which are very slender. They are completely filled with cells, containing oval or round nuclei, which stain somewhat deeply. In many places signs of hæmorrhage appear between the individual cells, and occasionally an alveolus is traversed by one or more blood-vessels, which have merely an endothelial lining, separating them from the tumour cells. There is slight small-round-cell infiltration between the tumour cells;

but little, if any, breaking down is seen. On passing upward toward the fundus and along the advancing margin of the growth, the alveolar arrangement is to a great extent lost, and the tumour is composed of a homogeneous tissue whose cells have elongate-oval, and sometimes round, deeply staining nuclei. Scattered everywhere throughout this tissue are nuclei two or three times as large as their fellows, round, oval, or half-moon shaped, and staining very deeply. Here and there nuclear figures are visible. There also occur, especially between the epithelial cells, large and small blood-vessels with very delicate walls. The line of junction between the new growth and the uterine muscle is very sharply defined, and the muscle, especially along the line of advancement, is in many places infiltrated with small round cells.

The uterine mucosa at the fundus is greatly altered; its surface epithelium is in most places intact, but is swollen. Proliferation has also taken place, so that there are now three or four layers, which under the low power look very much like squamous epithelium. The glands are few in number, small, round on cross section, and have an intact epithelium; a few are slightly dilated. The stroma of the mucosa is greatly altered; the nuclei of its cells are smaller than usual, and in one or two places the superficial portions of the mucosa are occupied by masses of cells similar to those of the new growth. These cells show rapid division, and merge directly into the stroma cells. Blood-vessels are also seen passing directly from the stroma of the mucosa into the new growth. It would appear that the new growth at this point had arisen from a metamorphosis of the stroma cells, but it is evidently an extension upward of the general process. The disease has extended laterally into the broad ligament and has not been entirely removed.

The presence of blood-vessels in the alveoli, the absence of the characteristic epithelial cells in many places, and the tendency toward the formation of large homogeneous areas having a rich blood supply, together with the small amount of degeneration, are strongly suggestive of sarcoma. Indeed, were it not for sections from other portions of the growth in which the squamous-cell origin is clear, one would be justified in making a diagnosis of sarcoma.

The right ovary contains small gland-like areas, otherwise the appendages on both sides are normal.

Diagnosis.—Squamous-cell carcinoma of the cervix, in places resembling an alveolar sarcoma; extension to the body of the uterus and laterally to the broad ligaments; atrophy of the uterine mucosa; subperitoneal cysts on the surface of the right tube; small gland-like cavities in the right ovary.

In this case, macroscopically, one could not decide between sarcoma and squamous-cell carcinoma, and even on histological examination some difference of opinion might arise. Here again the differential points raised are of practical interest only to the pathologist, as they in no way influence the operator in his treatment.

ADENO-CARCINOMA OF THE CERVIX

When considering the normal histological appearances of the cervix, it was seen that although the squamous epithelium usually ends at the external os, it may sometimes extend almost, if not quite, to the internal os. Furthermore, we know that wherever squamous epithelium is found, squamous-cell carcinoma may develop. Thus it is clear that a squamous-cell growth may occasionally start within the external os, and may occupy the usual site of adeno-carcinoma of the cervix (Fig. 106). Again, it has been seen that the cylindrical epithelium of the cervix may extend abnormally far downward; hence adeno-carcinoma may commence at or without the external os (Fig. 150). In all cases where the growth commences at the external os, it is advisable to make no absolute diagnosis from the gross examination, but to await the results to be obtained with the microscope.

As the histological appearances of adeno-carcinoma have not yet been described, the reader is referred to Chapter XII for the differential diagnosis between this form and squamous-cell carcinoma of the cervix.

The following case might clinically have readily been mistaken for an adeno-carcinoma, as the growth was situated almost entirely within the external os.

Gyn. No. 3,698

Squamous-cell carcinoma of the cervix, showing little involvement of the vaginal portion, but extensive growth in the cervical portion. Extension to the vaginal vault and broad ligaments; vaginal hysterectomy; recurrence.

A. N., aged forty-three; white. Admitted August 2, 1895. Complaint: uterine hæmorrhages.

The patient has been married twenty-six years, and has had nine normal labours. Her family history is good, and up to the time of the present illness she has always been well.

For three years the patient has been losing flesh, and two years ago noticed that the menstrual flow was becoming prolonged, and that between the periods there was a leucorrhœal discharge, frequently tinged with blood. Coincidentally with the appearance of the discharge she began to suffer with backache, and occasionally with a slight amount of abdominal tenderness. The bloody discharge has steadily increased, and one month ago she had a copious hæmorrhage. The patient is debilitated; her appetite is poor; the bowels are constipated. The discharge is at present thick, yellowish, and blood-stained. The cervix is in the axis of the vagina; the lips are everted, indurated, and ulcerated; they bleed freely upon the slightest touch. The ulceration extends outward upon the vaginal mucosa on the right side for a considerable distance. The uterus is freely movable, and the broad ligaments do not appear to be involved.

Operation, August 5, 1895. Vaginal hysterectomy.

The patient was placed in the elevated dorsal position and the ureters were catheterized. The uterus was then removed in the usual manner, and the vaginal

vault in the central portion was closed. Both angles were, however, left open to allow of free drainage from the pelvis.

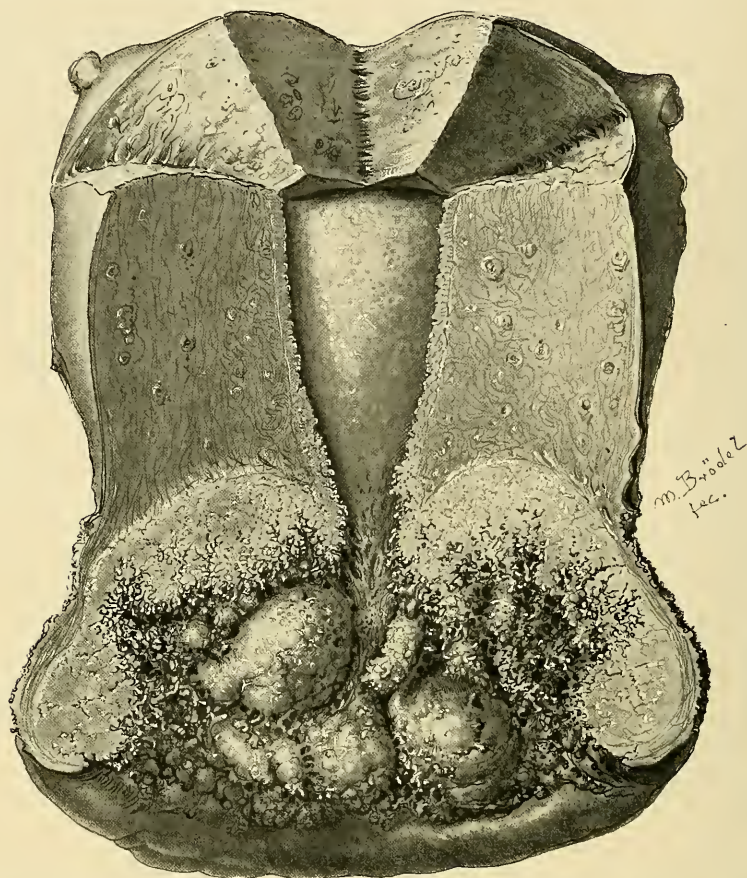


FIG. 106.—SQUAMOUS-CELL CARCINOMA OF THE CERVIX, SUGGESTING ADENO-CARCINOMA ON ACCOUNT OF ITS SITUATION. (Natural size.)

Gyn.-Path. No. 832. The cervix is greatly enlarged. The lips are thickened, but are smooth, except anteriorly, where there is some extension to the vagina. The external os measures 3.5 centimetres in diameter. The entire cervix and a small segment of the body are occupied by a new growth, which stands out sharply from the uterine muscle. It presents a friable appearance, and its inner surface is composed of myriads of delicate, finger-like projections, which in the posterior lip have coalesced to form three or four lobulated, dome-like elevations, on the surfaces of which are a few of the slender, finger-like outgrowths. Laterally, the growth is seen extending almost to the cut surface. The body of the uterus is much enlarged. Its walls are thickened, but the mucosa lining the uterine cavity presents the normal appearance.

On examination of the specimen, it was found that the growth had extended out into the broad ligaments, and that it had not been entirely removed. On August 8th the patient complained of a burning sensation about the external genitals and buttocks; this was due to excoriation of the parts, and was partially relieved by the application of powdered bicarbonate of soda. She was discharged August 24th, an unfavourable prognosis being given.

The patient was readmitted February 18, 1896. Her general condition had materially improved, and she had gained fifteen pounds since leaving the hospital.

Vaginal examination, however, revealed a return of the growth in the scar in the vaginal walls.

The patient was again examined May 6, 1896. The vaginal vault was indurated all directions, and distinct nodules could be made out posteriorly. Some of the nodules had commenced to ulcerate, and the rectum was involved.

Gyn.-Path. No. 832. The uterus measures $12 \times 7 \times 4.5$ centimetres. Both anteriorly and posteriorly it is free from adhesions. The cervix is 4.5 centimetres in diameter; over an area of 3.5×2 centimetres on the anterior surface it presents a worm-eaten, granular appearance. The remaining portion of the cervix is glazed, but still intact. On pressure, the cervix is exceedingly firm. The external os is 3.5 centimetres in diameter. The cervical canal is 5.5 centimetres in length. Throughout its entire extent the walls are invaded by a new growth (Fig. 106). This is yellowish or deep red in colour, and in its superficial portions

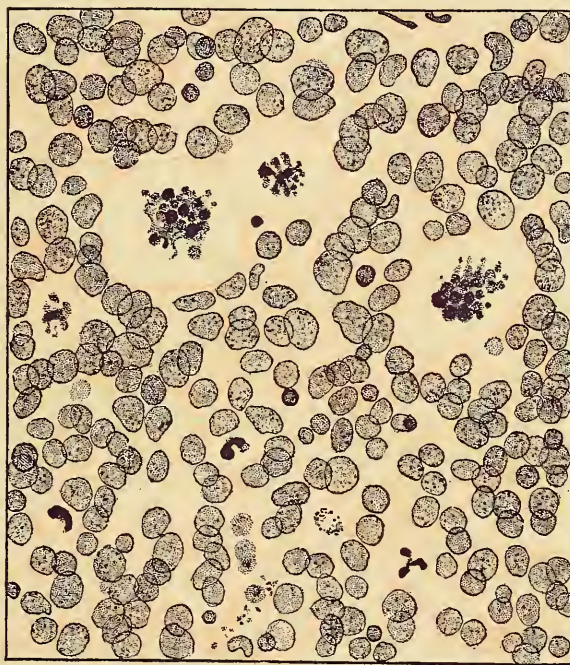


FIG. 107.—EPITHELIAL CELLS IN SQUAMOUS-CELL CARCINOMA OF THE CERVIX. (400 diameters.)

Gyn.-Path. No. 832. In the lower part of the picture isolated epithelial cells can be made out. These are oval or circular. The nuclei, as a rule, are uniform in size and vesicular. A few of them are irregular in contour. The horseshoe-shaped nuclei belong to polymorphonuclear leucocytes. The small, round, deeply staining nuclei are those of small round cells. Situated in the upper part of the field are three large cells. Their protoplasm stains faintly, and their nuclei are represented by large masses of chromatin gathered up into little balls. These cells are undergoing karyorrhexis.

presents a worm-eaten appearance, due to myriads of small papillæ lying one against the other. Covering some portions of the growth is a dirty, greenish, necrotic material. The growth extends upward 5 millimetres above the internal os, and its advancing margin is sharply defined. The uterine walls average 2.5

centimetres in thickness; the cavity is 5 centimetres in length, and its mucosa, which varies from 1 to 4 millimetres in thickness, presents a granular appearance.

Histological Examination.—The squamous epithelium covering the vaginal portion of the cervix is to some extent intact, but on being traced inward toward the external os it becomes thicker, stains more deeply, and tends to invade the underlying stroma. Where the growth is at all pronounced, cross sections of the finger-like masses are seen on the surface. Each of these consists of a central blood-vessel enveloped in a small amount of connective tissue, while surrounding the whole are several layers of squamous epithelium. The cervical tissue is everywhere infiltrated by large and small masses of epithelial cells, whose nuclei are oval and vesicular. Here and there is a large plaque of protoplasm containing irregular bunches of chromatin (Fig. 107). Numerous of these karyorrhetic figures are seen, and occasionally a cell containing two or more nuclei is found. The central portions of quite a number of the alveoli have broken down and are seen as necrotic areas. The stroma of the tissue shows abundant small-round-cell infiltration. The growth is a squamous-cell carcinoma; it is highly probable that portions of it have been left behind, as in the vicinity of the internal os it extends, even macroscopically, almost to the cut surface. In this case, from the slight involvement of the vaginal portion of the cervix and from the advanced growth throughout the cervical canal, one would immediately suspect adeno-carcinoma. There is some dilatation of the uterine glands, and scattered throughout the stroma are many small round cells; otherwise the mucosa is normal.

Diagnosis.—Squamous-cell carcinoma of the cervix.

ENDOTHELIOMA OF THE CERVIX

This is an exceedingly rare condition, not more than half a dozen cases having been reported. As will be seen from case Gyn.-Path. No. 1,405 (p. 349), a differential diagnosis between this and squamous-cell carcinoma was impossible clinically.

On histological examination the difference is at once clear, the squamous epithelium being intact, instead of penetrating the underlying tissue, while the growth in the depth consists of spaces lined by one or more layers of cells, instead of forming solid nests of cells. Where the cells have so proliferated that the cavities are obliterated, there is a marked resemblance to the nests in squamous-cell carcinoma, but in the squamous growth the cells forming the outer layer of the nest usually show a tendency to be cuboidal or cylindrical in form, while the nuclei, as a rule, are more vesicular. Occasionally the central portions of the cell-nests in squamous carcinoma drop out (see Case 2,885, p. 166), and one might readily mistake the growth for an endothelioma. Examination of further sections, however, will prevent any error.

CHAPTER VIII

TREATMENT OF SQUAMOUS-CELL CARCINOMA OF THE CERVIX

1. Gradual development of the radical operation.
2. Preparation of the patient for hysterectomy.
3. Insertion of ureteral catheters.
 1. A case in which the ureters could not be catheterized on account of carcinomatous involvement of the broad ligaments.
4. The necessity of using fresh instruments after curetting the carcinomatous uterus.
5. Preparation of the patient on the table.
6. Abdominal hysterectomy.
 1. Care of the patient after abdominal hysterectomy.
 2. Untoward symptoms occurring during the operation.
 3. Method of infusing salt solution.
 4. Complications arising during abdominal hysterectomy.
 5. Injury to the bladder during abdominal hysterectomy.
 6. Report of cases in which the bladder was torn during abdominal hysterectomy.
 7. Injuries to the ureters during hysterectomy.
 8. Treatment of injured ureters.
 9. Causes of death following abdominal hysterectomy.
 10. A case in which death was due to the accidental ligation of a ureter during abdominal hysterectomy.
 11. Examples of cases in which the abdominal operation had to be abandoned.
7. Vaginal hysterectomy.
 1. Injuries to the bladder during vaginal hysterectomy. Cases exemplifying such lesions.
 2. Injuries to the ureters during vaginal hysterectomy.
 3. Hæmorrhage following vaginal hysterectomy.
 4. Causes of death after vaginal hysterectomy.
 5. Prolapse of intestines after vaginal hysterectomy. Death.
 6. Remote sequelæ of vaginal hysterectomy.
8. Attempt to check the malignant process by ligation of the internal iliac arteries. Illustrative cases.
9. Palliative treatment.
10. Local applications.

FROM the preceding chapters we have gained an insight into the manner in which squamous-cell carcinoma develops, and have learned through what avenues it is likely to extend and what structures are secondarily involved. It still remains to devise some means by which this carcinomatous tissue can be removed in such a manner as to prevent a possibility of return.

It is interesting to notice the improvements in operative procedures which have followed our gradual progress toward a more thorough knowledge of the disease. Schroeder and his contemporaries either curetted or amputated the cervix, and this plan of treatment was in vogue until twenty-five years ago. As will readily be seen from the cases we have studied, the disease often advances far beyond the cervix, both upward and laterally, so that it is not to be wondered at that satisfactory results were rarely obtained. Abdominal hysterectomy, introduced by Freund* in 1878, marked a new era in the treatment, and with

* Freund, W. A. *Zu meiner Methode der totalen Uterus-Extirpation.* *Centralbl. f. Gynäk.*, 1878, Bd. ii, S. 265.

slight modifications has been in continual and general use up to the present time. His method, in brief, consisted in applying three sutures in each broad ligament, removing the uterus, and then bringing down the sutures through the vagina. A distinct advance was made when Pawlik,* of Prague, on December 18, 1888, first introduced a catheter into the left ureter previous to commencing the operation. The patient was placed in the knee-elbow position, the catheter introduced, and one end placed in a drainage tube in order to collect the urine. Vaginal hysterectomy was then performed, and the patient made a perfect recovery. In a second case vaginal hysterectomy was performed without the insertion of the catheters, and a utero-vaginal fistula resulted. In a third case both ureters were catheterized and the uterus was removed *per vaginam*. Recovery was uninterrupted.

It is rather astonishing that this preparatory catheterization of the ureters should have fallen into disuse, but we hear no more of it until Kelly, in 1892, unaware of the cases reported by Pawlik, commenced to catheterize the ureters as a routine procedure previous to performing a hysterectomy for carcinoma; it is due mainly to him that this method has come into general use. In 1894 A. Mackenrodt advised the removal of the broad ligaments with the uterus.

The radical operation in cancer of the mamma, namely, the removal of the axillary glands and of the pectoral muscles, as practised by Halsted † in all breast cases, has led several investigators to make use of a somewhat similar method in the treatment of carcinoma of the uterus.

Ries, ‡ in 1895, published a radical method for the removal of the uterus. He spoke of the necessity of removing the lymph glands, and predicted a better prognosis if his plan were carried out. The steps in the operation were as follows :

- (a) Curetting of the cervix.
- (b) Disinfection of the vagina.
- (c) Ringing of the vagina and closure of the flaps over the cervix.
- (d) Abdominal incision.
- (e) Hysterectomy, giving the disease as wide a berth as possible.
- (f) Slitting the peritoneum back to the posterior pelvic wall to the point at which the common iliac artery divides.
- (g) Removal of the pelvic lymph glands with the surrounding adipose tissue.
- (h) Closure of the vaginal vault.
- (i) Closure of the abdomen.

Ries was not positive that the pelvic peritoneum would live after having been dissected back, and decided to try some experimental work bearing on this point on dogs. From these investigations, in which large pieces of peritoneum, which had been dissected off one part of the abdominal cavity and then implanted at

* Pawlik, K. *Extirpation des Uterus und des Beckenzellgewebes*. *Internat. klin. Rundschau*, Wien, 1889, iii, 1,072.

† Halsted, W. S. *The Results of Operations for the Cure of Cancer of the Breast performed at the Johns Hopkins Hospital, from June, 1889, to January, 1894*. *Johns Hopkins Hospital Reports*, vol. iv, 1895, No. 6.

‡ Ries, E. *Eine neue Operationsmethode des Uteruscarcinoms*. *Zeitschr. f. Geburtsh. u. Gynäk.*, 1895, Bd. xxxii, S. 266.

another point, were found to grow, he concluded that in the human being the peritoneum would retain its vitality. As Ries remarks, all his investigations up to the time of the publication of his method had been on autopsy cases, so that he had not had the opportunity of testing its practicability on the living subject.

John G. Clark* had for some time been endeavouring to devise an operation whereby more of the broad ligament could be removed with the uterus, and in the *Bulletin* of the Johns Hopkins Hospital (July, August, 1895), reported his results under the title *A More Radical Method of Performing Hysterectomy for Cancer of the Uterus*. He dwelt upon the disadvantages of the older operations, and reported two cases operated upon according to his method.

SUMMARY OF STEPS IN CLARK'S OPERATION

1. Insert bougies under the local effects of cocaine, thus saving the patient's vital powers for the operation.

2. Make abdominal incision of sufficient length to insure free manual movements.

3. Ligate upper portion of broad ligament with ovarian artery; divide vesico-uterine peritoneum around to opposite side; push bladder off and spread layers of ligament apart, exposing uterine artery.

4. Dissect uterine artery out for 2.5 centimetres from uterus beyond its vaginal branch, and tie (Figs. 119 and 120).

5. Dissect ureter free in the base of the broad ligament.

6. Ligate remainder of broad ligament close to iliac vessels and cut it away from its pelvic attachment.

7. Carry dissection well down below carcinomatous area even though cervix alone seems to be involved.

8. Proceed on the opposite side in the same manner as on the first side.

9. Perforate vagina with sharp-pointed scissors, making strong traction on uterus with small volsella forceps, so as to pull the vagina up and make its walls tense; then ligate in small segments (1 centimetre) and cut each segment as it is tied.

10. Insert iodoformized gauze from above into raw space left by the hysterectomy; draw vesical and rectal peritoneum over this with a continuous fine suture.

11. Irrigate pelvic cavity and close abdomen without drainage.

The dissecting out and tying of the uterine artery near its origin, as advocated by Clark, is a decided advantage over Ries's operation, but Clark did not remove the pelvic lymph glands. To Ries is due the credit for recommending the systematic removal of the glands. It is true that others had occasionally removed enlarged glands before this time, Rumpf being the first to carry out this procedure upon a living subject. As is usually the case, several men were independently following the same trend, and Rumpf † read a paper before the Gesellschaft für Geburts-

* Clark, John G. *A More Radical Method of Performing Hysterectomy for Cancer of the Uterus*. *Johns Hopkins Hospital Bull.*, July, August, 1895.

† Rumpf. *Zeitschr. f. Geburtsh. u. Gynäk.*, 1895, Bd. xxxiii, S. 212.

hülfe und Gynäkologie in Berlin on June 28, 1895, describing essentially the same method, which he had devised and employed three weeks previous to the meeting. On account of the breaking-down of the tissue, the cervix was first curetted. In doing this operation he took especial care to avoid the ureters. After ligating the spermatic vessels at the innominate line, the broad ligament was split, the ureter was sought for and easily found, being traced from the psoas to its insertion into the bladder. It was more difficult to separate it from the overlying connective tissue and vessels. The uterine vessel was tied at its point of origin, and thus the entire contents of the parametrial space lying over the ureter were loosened, to be removed with the uterus. After carrying out the same procedures on the opposite side, the bladder was dissected backward, while the uterus, which had been already freed, was drawn strongly upward and the parametrial space below the ureters dissected out. Finally the packets of glands lying on the iliac vessels on both sides were removed. They were grayish-red and swollen. In order to avoid danger of inoculation of the healthy tissue by the carcinoma, the uterus was removed through the vagina. Wishing to speedily terminate the operation, Rumpf burnt through to the vagina all round the cervix. After the introduction of iodoform gauze into the vagina, the peritoneal flaps were brought together so as to completely shut off the peritoneal cavity. The patient recovered, and Olshausen, in the discussion which followed the report of the paper, praised the method highly. Rumpf, in concluding his remarks, hoped that through the employment of his method the prognosis in carcinoma might be rendered better, and considered the operation analogous to that performed in carcinoma of the breast.

In March, 1896, Clark* reported eight cases operated upon by the radical method. These operations were performed by Dr. Kelly and himself. Accompanying the article is a complete description of the operation, all the important points being well illustrated.

PREPARATION OF THE PATIENT FOR HYSTERECTOMY

We will first consider those cases in which the disease is not far advanced, and where there is not sufficient breaking-down of the tissue to necessitate a preliminary curetting of the uterus. The patient is at once put on a tonic consist-

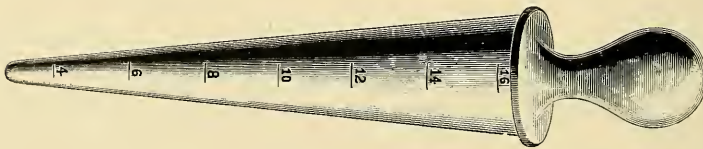


FIG. 108.—KELLY'S URETHRAL CALIBRATOR AND DILATOR.

The numbers indicate the diameters in millimetres.

ing usually of the tincture of *nux vomica* with some preparation of iron, and receives from one to two ounces of malt three times a day. The bowels are kept

* Clark, J. G. *Ten Cases of Cancer of the Uterus Operated upon by a More Radical Method of Performing Hysterectomy.* *Johns Hopkins Hospital Bull.*, 1896, vii, 1, 37.

regular, as it is exceedingly important that they be thoroughly emptied before operation. A vaginal douche, consisting of warm water or a half saturated boric-acid solution, is given night and morning to cleanse the parts as thoroughly as possible. Any odour that may be present is best controlled by a douche consisting of 1 per cent creolin in water or of 1 per cent permanganate of potash. The most convenient douche apparatus consists of an ordinary fountain syringe suspended about six feet from the ground, the nozzle being supplied by a curved glass tube or a glass catheter. Both the bag and nozzle can be thrown into water and are easily sterilized.

On the afternoon prior to the operation the patient is given an enema consisting of 1 litre of soapy water, which, if not effectual, is repeated. When the first enema has not yielded the desired result, an ounce of glycerine or half an ounce of turpentine may be added to the second. Two ounces of Epsom salts are administered, being divided into two doses, given two hours apart. The patient is shaved from the ensiform cartilage to the perinæum. A green-soap poultice is then applied to the abdomen

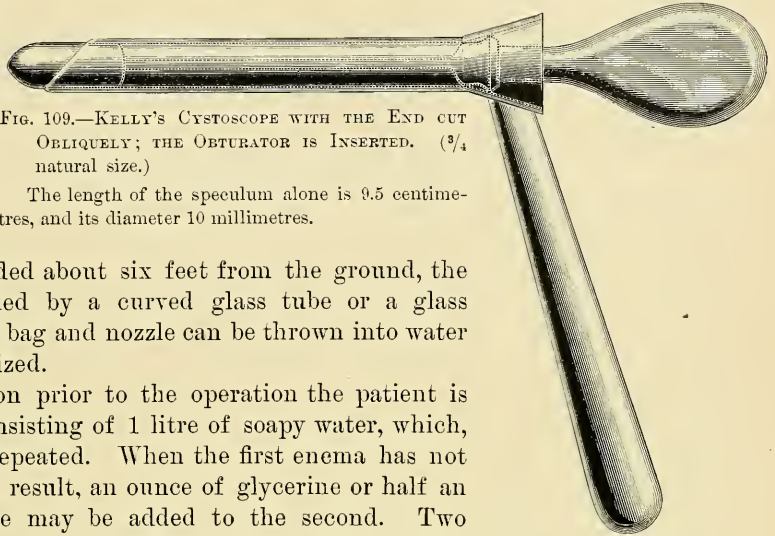


FIG. 109.—KELLY'S CYSTOSCOPE WITH THE END CUT OBLIQUELY; THE OBTURATOR IS INSERTED. ($\frac{3}{4}$ natural size.)

The length of the speculum alone is 9.5 centimetres, and its diameter 10 millimetres.

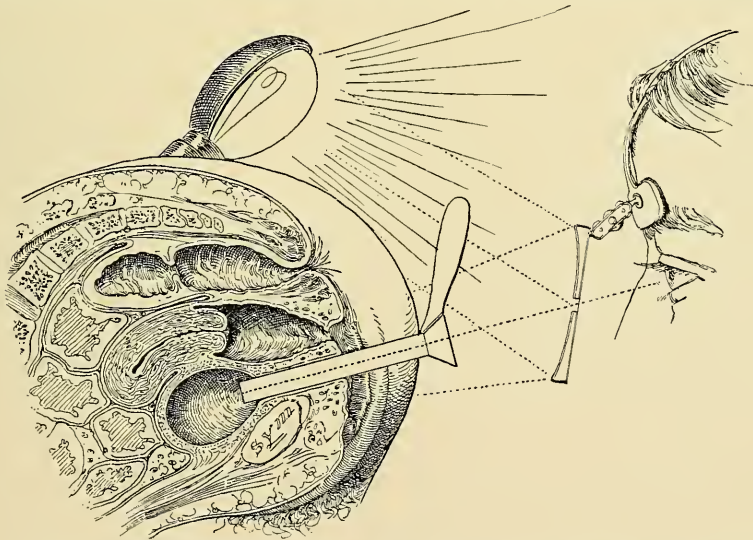


FIG. 110.—EXAMINATION OF THE BLADDER WITH THE PATIENT IN THE KNEE-CHEST POSTURE.

The right ureteral orifice is seen just above and a little beyond the end of the speculum. (After H. A. KELLY.)

and perinæum and allowed to remain on ten minutes, after which it is removed and the parts are thoroughly scrubbed.

The evening meal consists of light diet, soft toast, an egg, some custard, and probably a cup of cocoa or coffee, the object being to have as little residue as possible in the intestine. At 8 P. M. and at midnight chicken or beef broth is given, but milk is avoided, as it tends to produce flatulency. No nourishment is given after midnight, except an ounce of sherry at six in the morning. A simple enema is given at 6 A. M., and is repeated until the water comes away clear. Should the fluid be retained, it is siphoned off. A 1-per-cent carbolic vaginal douche is administered, and the parts are then thoroughly cleansed in the following manner :

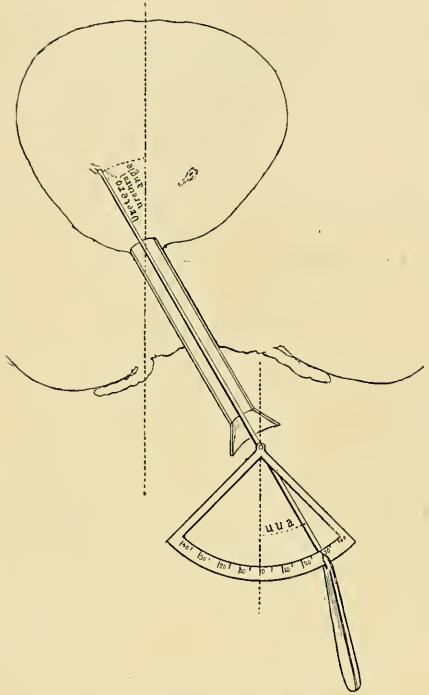


FIG. 111.—USING THE GONIOMETER.

To determine the angle made by the axis of the urethra with a line drawn from the ureter to the internal urethral orifice. (After H. A. KELLY.)

suction apparatus; ureteral searchers (Fig. 112); ureteral catheters (1.5 and 2 millimetres); curved blunt tenaculum; applicator; long bladder forceps; head mirror; and an electric or coal-oil lamp.

The abdomen and perinæum are scrubbed with green soap and water, rinsed off with sterile water, washed with ether, followed by alcohol, and again by sterile water. A compress of 95-per-cent alcohol is then applied to the abdomen and perinæum; this is covered with sterile gauze, kept in place by a scultetus bandage. The patient is now ready to go to the operating room, but just before anæsthetization the bladder is emptied.

INSERTION OF URETERAL CATHETERS

Instruments Required for Catheterizing the Ureters.

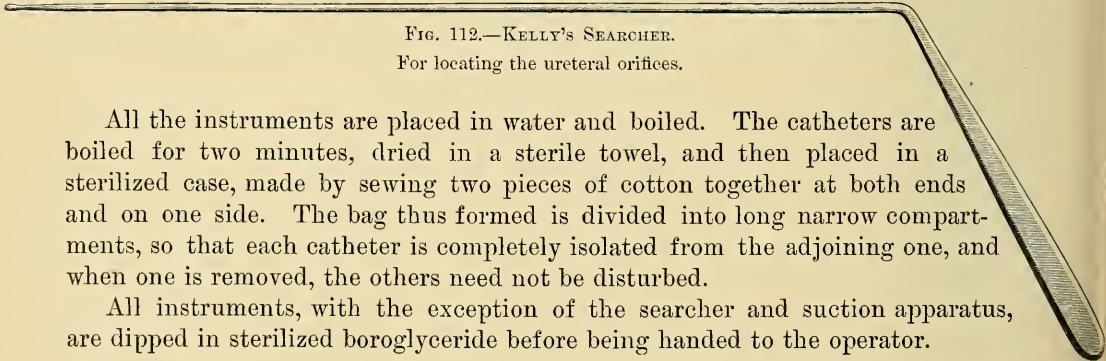
—A Sims speculum; urethral calibrator (Fig. 108); bladder specula, Nos. 8, 9, and 10 (Fig. 109);

FIG. 112.—KELLY'S SEARCHER.

For locating the ureteral orifices.

All the instruments are placed in water and boiled. The catheters are boiled for two minutes, dried in a sterile towel, and then placed in a sterilized case, made by sewing two pieces of cotton together at both ends and on one side. The bag thus formed is divided into long narrow compartments, so that each catheter is completely isolated from the adjoining one, and when one is removed, the others need not be disturbed.

All instruments, with the exception of the searcher and suction apparatus, are dipped in sterilized boroglyceride before being handed to the operator.



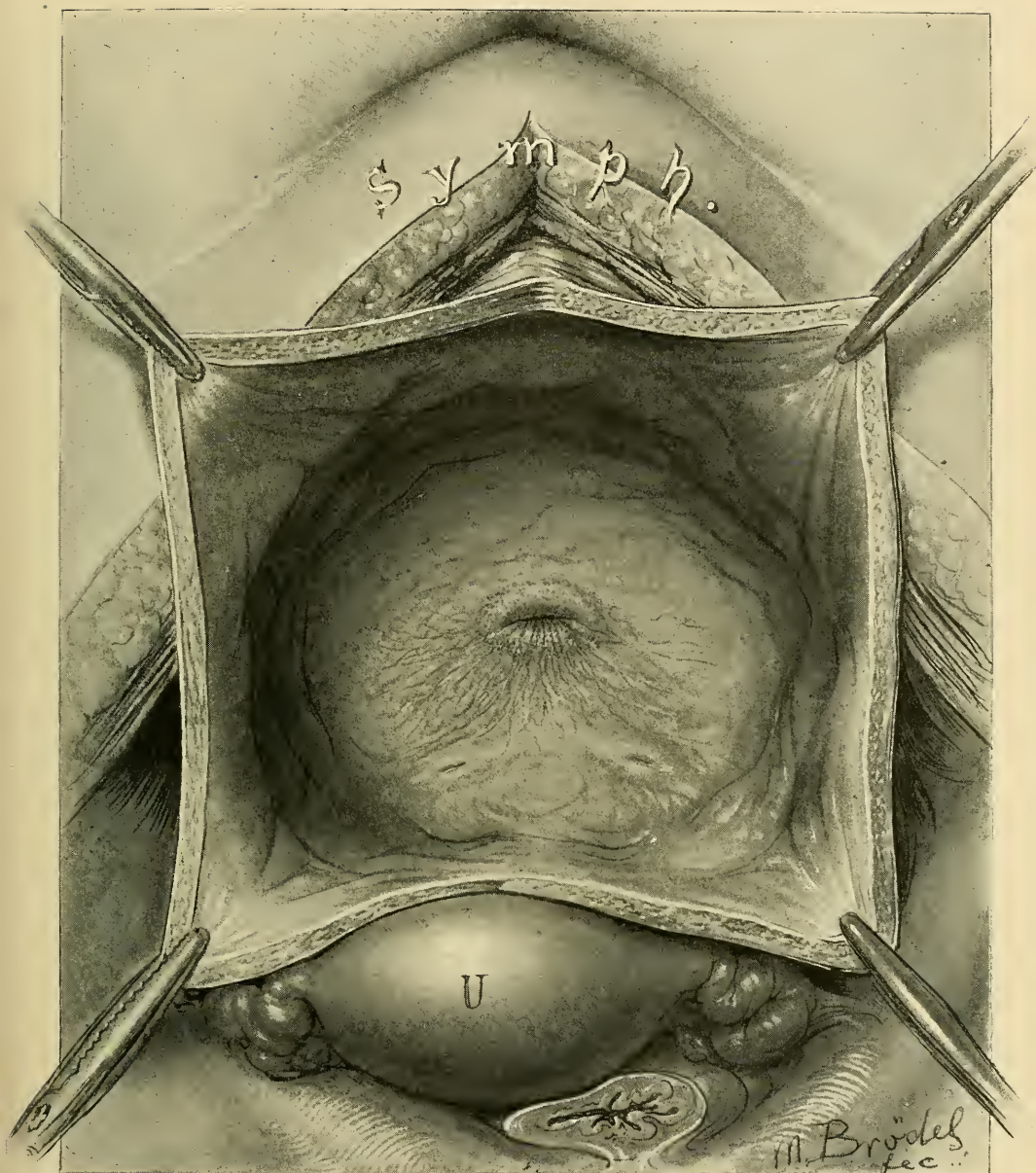


FIG. 113.—INNER SURFACE OF THE BLADDER AS SEEN FROM THE ABDOMINAL CAVITY.

The bladder has been incised in the median line anteriorly, and the walls are reflected laterally. In the middle of the field is the inner urethral orifice, seen as a transverse slit, and surrounded by slightly raised margins. About 2 centimetres posterior to this, and 1 centimetre to either side of the median line, are the slit-like orifices of the ureters, slightly raised and running obliquely upward and outward. The bladder mucosa is somewhat wrinkled, but is not abraded. The walls are of the normal thickness. Posterior to the bladder is the uterus with the tubes passing off laterally. Pressed against the sacrum is the rectum, in this case farther to the right than usual. (After H. A. KELLY.)

After the patient is thoroughly under the anæsthetic the bougies are passed. It is desirable to have the room somewhat darkened, so that the artificial light may appear more brilliant.

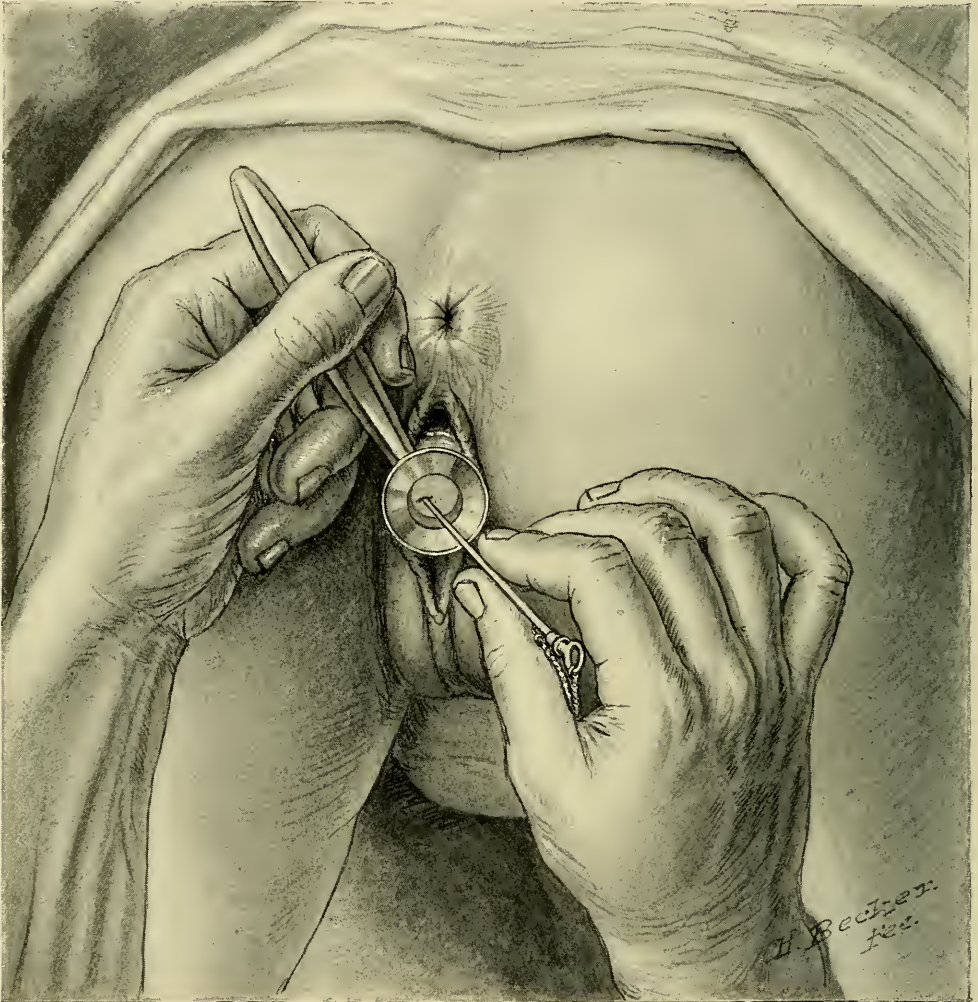


FIG. 114.—PASSING A METAL URETERAL CATHETER INTO THE LEFT URETERAL ORIFICE, WHICH IS EXPOSED IN THE LUMEN OF THE SPECULUM.

The patient is in the knee-chest posture. (After H. A. KELLY.)

The vagina and surrounding parts are thoroughly cleansed; the patient is placed in the knee-chest posture, the shoulders resting on two sand pillows, the buttocks being supported by one or two assistants. After the urethral area has been thoroughly cleansed by means of a boric-acid pledget, the urethral calibrator is introduced, both to dilate the urethra and to determine the size of the speculum required. Speculum No. 9 or 10 is most commonly needed. After this has been introduced, on looking at the inner surface of the bladder, it will often be

noted that the posterior wall lies directly in contact with the speculum. It will then be advisable to insert into the vagina a Sims speculum, so that enough air may enter the vagina and bladder to distend both. It will often also be necessary for the operator to push the patient away from him, thus allowing the intestines to gravitate still farther toward the diaphragm. If this is done,

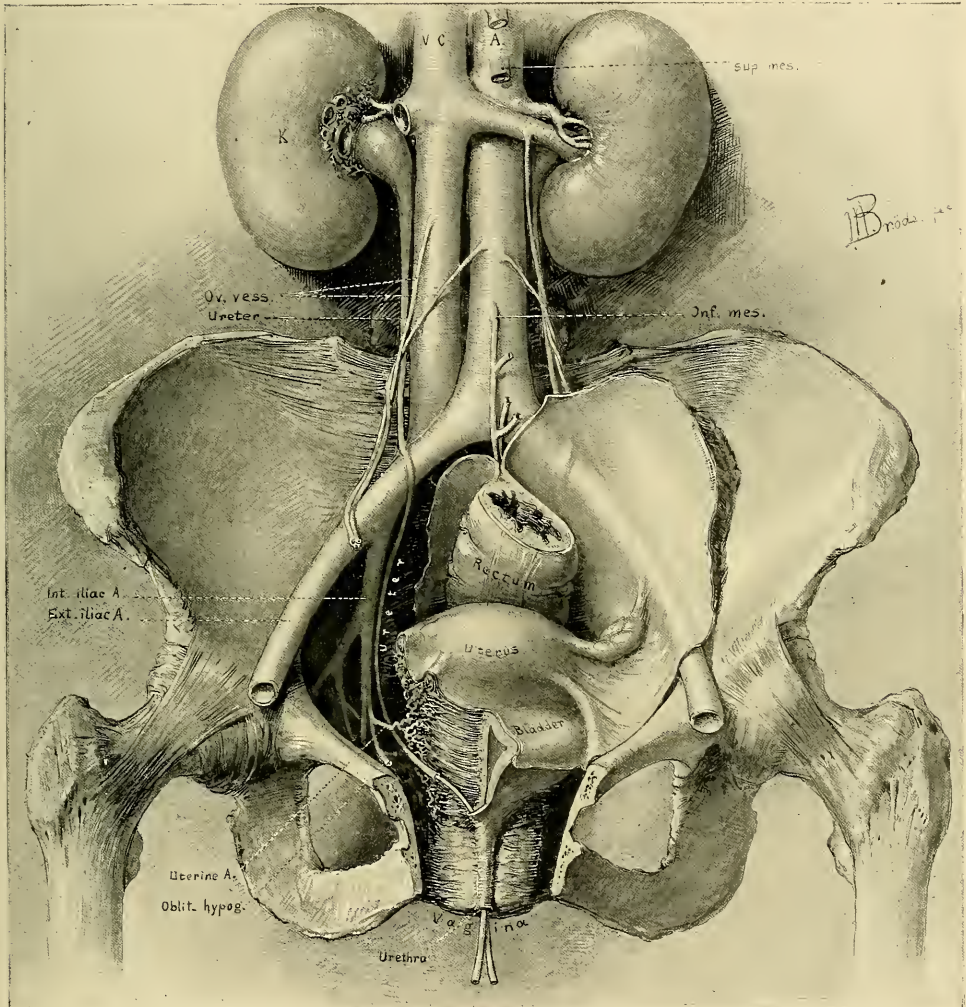


FIG. 115.—THE CATHETERIZATION OF THE URETERS IN HYSTERECTOMY FOR CANCER OF THE CERVIX.

The ureters are both catheterized in order to make them curve outward and stand out prominently during the enucleation. On the right side the peritoneum has been removed and the bladder divided, in order that the relations of the ureter to the uterine and pelvic vessels may be seen. Part of the pelvic rami have also been removed to afford better exposure. (After J. G. CLARK.)

the bladder almost invariably becomes inflated, and there is an interval of at least 2 to 3 centimetres between the inner orifice of the urethra and the opposite bladder wall. The residual urine is now removed with the suction apparatus.

As the patient is virtually turned upside down, we must look upward for the ureteral orifices. These are situated at either angle of the trigonum, and appear as delicate slit-like openings (Figs. 110 and 113). The speculum is introduced in a straight line and is then swept to the left or right at an angle of about thirty-five degrees (Fig. 111). The ureteral orifices are usually situated about 1 to 2 centimetres within the inner urethral orifice (Fig. 110). Often the orifice is situated on a little mound—the ureteral mound, or mons—and is then very easily located; at other times no eminence is present, and the small slit is almost unrecognisable. It is advisable to go directly to the spot where the

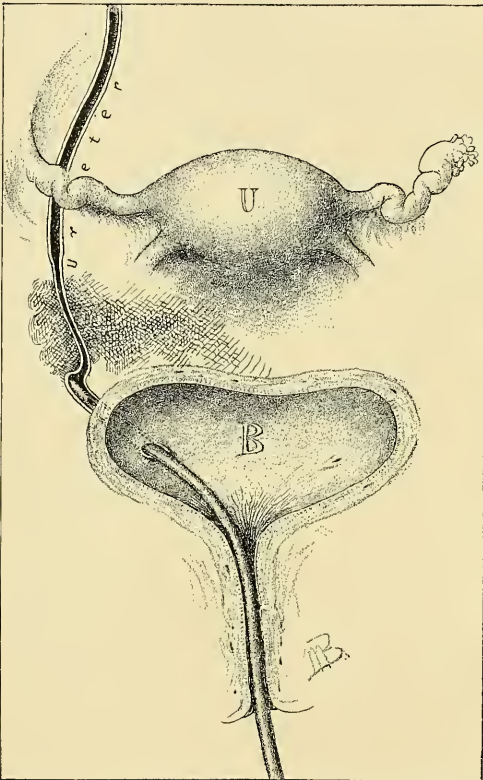


FIG. 116.—DIAGRAM SHOWING A CASE OF CARCINOMA OF THE CERVIX IN WHICH THE BOUGIE CANNOT BE MADE TO PASS INTO THE URETER.

On the introduction of the catheter the ureter usually yields, allowing the instrument to curve outward and upward; but in this instance the carcinoma has extended to the broad ligament and holds the ureter rigid, rendering it immobile, so that there is formed an impassable barrier to the catheter. It is important, however, to insert the bougie as far as possible. (After H. A. KELLY.)

orifice is usually found, since the searcher will often enter when the opening as such is not visible.

The ureter may sometimes be located by a little stream of urine spurted from it, and when it has just been catheterized, its site is readily again determined from the air bubbles that collect around the orifice. When the opening has been found, a ureteral catheter, 1.5 to 2 millimetres in diameter, is introduced. For the beginner it is advisable to leave the searcher in the ureter until the catheter, with the stylet pushed to the end, has been introduced into the bladder and is at the ureteral orifice. Great care must be exercised not to contaminate the catheter. The far end is caught by an assistant, whose hands, as well as those of the operator, are protected by sterile rubber gloves. When introducing the catheter into the left ureter, the instrument is passed over the operator's right shoulder; when the right ureter is catheterized the instrument is introduced over the left shoulder. The end of the catheter is now inserted and the stylet is slowly withdrawn by an assistant. As the catheter is pushed in, it is always well to follow its introduction with the eye, as the instrument occa-

sionally does not enter the ureter, but curls up in the bladder. After one ureter has been catheterized the speculum is withdrawn,

and reinserted to the side of the catheter. The catheterized ureter is sought for and the speculum is swung around to the opposite side at the same level. In this way the orifice is, as a rule, readily found, and the catheter is introduced in the same manner. After the speculum has been withdrawn both catheters are tied together, and in turning the patient over, great care must be exercised not to dislodge or pull them out.

FAILURE TO PASS ONE OR BOTH BOUGIES

Occasionally one ureteral orifice is so obscured that it cannot be located, and further search has to be abandoned. Another difficulty, and a more serious one, is the involvement of the ureter in the carcinomatous growth. In such cases the tube is so rigid that it cannot yield sufficiently to allow the catheter to pass through it (Fig. 116). It can sometimes be inserted .5 to 1.5 centimetres, and then meets with an insurmountable impediment. A previous vaginal examination will doubtless have given a clue to the situation, the broad ligament on that side being infiltrated and thickened. Both ligaments may be greatly involved, and in that case it may be impossible to catheterize either ureter.

After the catheters are inserted they can, on bimanual examination, be traced outward and upward, skirting the pelvic wall until the brim is reached; beyond this point they cannot be palpated.

A Case in which the Ureters could not be Catheterized on Account of Carcinomatous Involvement of the Broad Ligaments

Gyn. No. 4,090

Squamous-cell carcinoma of the cervix. Extension to the broad ligaments; impossible to pass ureteral catheters over 5 millimetres beyond the ureteral orifices; curettage.

M. J., aged fifty; white. Admitted January 18, 1896. Complaint: pain in the lower part of the abdomen; irregular uterine hemorrhages.

The patient has been married twenty-nine years; has had six normal labours and one miscarriage. Her menses ceased two years ago. One sister died of carcinoma of the uterus. The patient has always been healthy.

Eight months ago she first complained of pain in the small of her back, and at the same time noticed a bloody vaginal discharge; both have been of frequent occurrence up to the present time. The patient has lost no flesh, has a good colour, and is fairly well nourished. Her bowels are regular, but there is considerable straining at stool. The entire vaginal vault is involved by a new growth; the cervix has completely disappeared, its site being occupied by nodular excrescences. On January 26th an attempt was made to catheterize the ureters, but after the bougie had been passed through the ureteral orifices about 5 millimetres into the canals, decided resistance was met with and the instruments could not be introduced farther. As the disease was so far advanced, a radical operation was impossible. The uterus was curetted and the vagina packed with gauze. After

the curettement the patient complained of little or no pain. She left the hospital on February 9, 1896, feeling much better in every way.

Gyn.-Path. No. 1,049. The specimen comprises a large amount of uterine scrapings, the pieces varying from .2 to 1.5 centimetres in size. They present a finely granular appearance.

On histological examination, the stroma of the tissue is everywhere invaded by round, oval, or irregularly branching alveoli, which are filled with cells that stand out prominently, staining much more deeply than the surrounding tissue. The cells filling these alveoli have oval, elongate oval, or irregular nuclei, which stain somewhat deeply. In the outermost layer of the alveolus the cells tend to be cylindrical. In nearly all of the alveoli can be seen one or more exceedingly large, oval nuclei, which stain intensely; occasionally one sees a cell containing a large number of small nuclei, so many, in fact, that they form a regular rosette. The stroma is composed of spindle-shaped connective-tissue cells, certain areas showing small-round-cell infiltration. The general picture is that of squamous-cell carcinoma.

Diagnosis.—Squamous-cell carcinoma of the cervix.

FRESH INSTRUMENTS TO BE USED AFTER CURETTING THE CARCINOMATOUS UTERUS

In those cases of abdominal hysterectomy in which, on account of the advanced condition of the growth, it has been found necessary to curette the cervix, and in all cases in which vaginal hysterectomy is performed, it is imperative that extreme care be exercised not to introduce cancer cells or masses of cells into the sound tissue. For example, one must not take a pair of bullet forceps that have been embedded in the carcinomatous cervix and immediately afterward grasp healthy tissue with them. The danger lies in the possibility of implanting carcinoma cells in healthy tissue, for should such implantation take place, although the entire primary growth might have been removed, the disease might go on afresh as a result of the want of care in the technique. So convinced is Hahn* of such a possibility that he insists on having all instruments that have come in contact with carcinomatous tissue laid aside before the wound is closed, or when healthy tissue is to be handled. Winter† also thinks that this procedure is advisable. A like precaution is observed by Halsted‡ in breast operations. The carcinomatous tissue is given a wide berth, and when it is accidentally cut into, the surfaces are immediately approximated to prevent any carcinoma cells from contaminating the field of operation. The knife used is immediately discarded. Nicaise,* in 1883, saw a subcutaneous nodule develop after the uterus

* Hahn, E. *Ueber Transplantation von carcinomatöser Haut. Berlin. klin. Wochenschr.*, 1888, xxv, 413.

† Winter, G. *Ueber die Recidive des Uteruskrebses, insbesondere über Impfredidive. Zeitschr. f. Geburtsh. u. Gynäk.*, 1893, Bd. xxvii, S. 101.

‡ Halsted, W. S. *Johns Hopkins Hospital Reports*, vol. iv, No. 6.

* Nicaise. *De la greffe cancéreuse. Rev. de chir.*, 1883, iii, 841.

had been punctured *per abdomen* for diagnostic purposes. Subsequent examination proved that the growth was a sarcoma.

Schopf,* in 1889, performed vaginal hysterectomy for carcinoma of the uterus, and on account of the narrow vagina had to incise both sides. Three months later carcinomatous nodules were detected in both scars. These nodules soon broke down and ulcerated. Hofmeier,† in 1895, reported a similar case. Still another example is that related by Leopold ‡ in 1895. A vaginal hysterectomy was performed in a case of squamous-cell carcinoma of the cervix, and during the operation the right labium majus was bruised; it did not bleed, however, and required no sutures. One year later the patient returned with a hard movable nodule, the size of a walnut, situated exactly at the site of the injury. It was ulcerating, and on microscopical examination proved to be a squamous-cell carcinoma. Leopold, while not claiming positively that it was due to implantation from the original growth, thought the recurrence highly suggestive.

While papillomatous tumours of the ovary cannot be classed with the carcinomata, yet they have distinct points of resemblance. A case came under my notice in the hospital, in which the patient had been tapped before her admission. At operation papillomatous masses were found scattered throughout the abdominal cavity. At autopsy I had the opportunity of obtaining a piece of the abdominal wall, including the area formerly pierced by the needle, and was astonished to find that the growth had at this point followed the track of the needle and involved the tissue almost to the skin. For a complete description of this case see page 662.

From this very significant evidence it will be well for us in our manipulations to assume that such implantation is possible, and accordingly to use all the necessary precautions.

PREPARATION OF THE PATIENT ON THE TABLE

The preparations in the operating room are just as thorough as if no preparatory cleaning up had been carried out in the ward. The external genitalia and the vagina are washed with green soap and water, 10 per cent creolin, 1 to 1,000 bichloride, and then rinsed off with sterile water. The bladder is catheterized to remove any urine that has recently accumulated, and also to evacuate the air left in after the patient has been in the knee-chest posture. Flannel stockings are then drawn on, the legs are fastened to the table, and the abdomen is washed. Soap and water are first applied, to be followed by absolute alcohol, ether, 1 to 1,000 bichloride, and, lastly, sterile water. A blanket covers the lower extremities, and protecting the patient's gown above is a rubber cloth, which also holds

* Schopf, F. *Uebertragung von Carcinom auf frische Wunden in einem Falle von vaginaler Totalexstirpation des Uterus.* *Wien. klin. Wochenschr.*, 1891, Bd. iv, S. 840.

† Hofmeier, M. *Zur Anatomie und Therapie des Carcinoma corporis uteri.* *Zeitschr. f. Geburtsh. u. Gynäk.*, 1895, Bd. xxxii, S. 171.

‡ Leopold, G. *Arbeiten aus der Königlichen Frauenklinik in Dresden.* Leipzig, 1895, Bd. ii, S. 203.

the arms in place across the chest. The lower as well as the upper margin of the field of operation is protected by sterilized towels, and the diaphragm sheet is applied. This covers the patient from below the knees to the shoulders, and

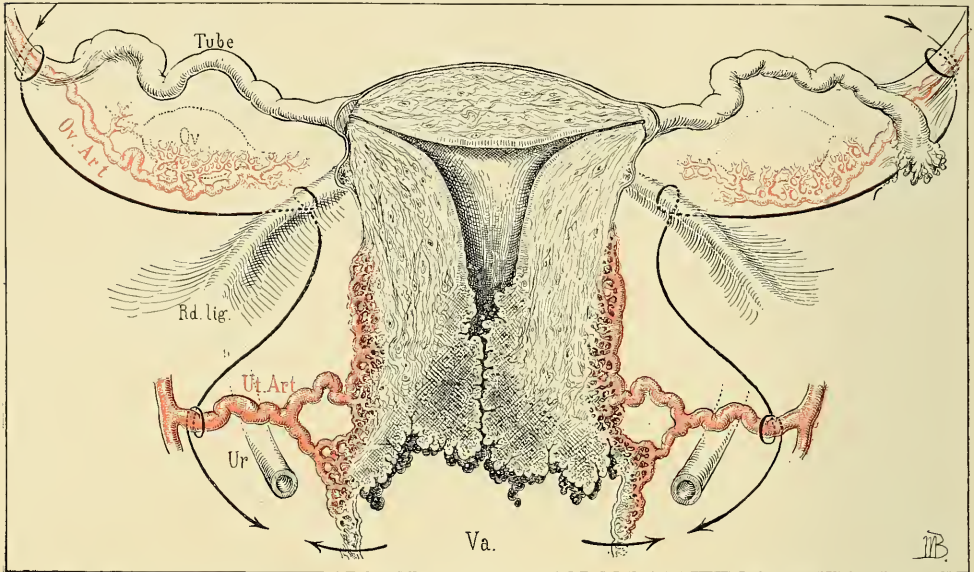


FIG. 117.—SCHEME SHOWING THE STEPS IN THE RADICAL OPERATION FOR CANCER OF THE CERVIX.

The incisions are made in the directions indicated by the arrows following the black lines. The loops indicate the positions of the three important ligatures on either side. The vagina should be opened from below after the abdomen has been closed. *Ur* is the ureter, beyond which the uterine artery is tied. (After H. A. KELLY.)

over the abdomen has an opening 35 centimetres long and 15 centimetres broad. Covering the lower and upper parts of the diaphragm are sterilized towels, which are changed as often as they are soiled.

ABDOMINAL HYSTERECTOMY

This operation should be preferred in all cases when the patient is not too stout. But to employ it in very fat individuals is unsatisfactory, both on account of the large quantity of adipose tissue in the abdominal wall, which materially increases the distance to the pelvic floor, and on account of the deposition of fat between the folds of the broad ligament and beneath the peritoneum of the pelvic floor, which renders the free dissection of the ureters and uterine arteries exceedingly difficult.

The radical operation, as described by Ries, Rumpf, and Clark, is without doubt a great advance in the operative technique, but in employing this method

there is still considerable risk of a subsequent peritonitis, since the abdominal hand is continually coming in contact with the surface of the carcinoma. Again, there is also great danger of implanting carcinomatous cells in the healthy tissue. Lastly, it is often impossible to remove a wide vaginal cuff with the uterus. Werder, of Pittsburg, being impressed with these disadvantages, devised a procedure whereby these defects could be overcome. In March, 1898, he published a paper entitled *A New Operation for the Radical Treatment of Cancer of the Cervix, consisting of the Removal of the Uterus and Vagina en masse by the Suprapubic Method*. Werder opens the abdomen and frees the uterus, tubes, and ovaries, as in an ordinary hysterectomy; he then dissects out the ureters, and con-

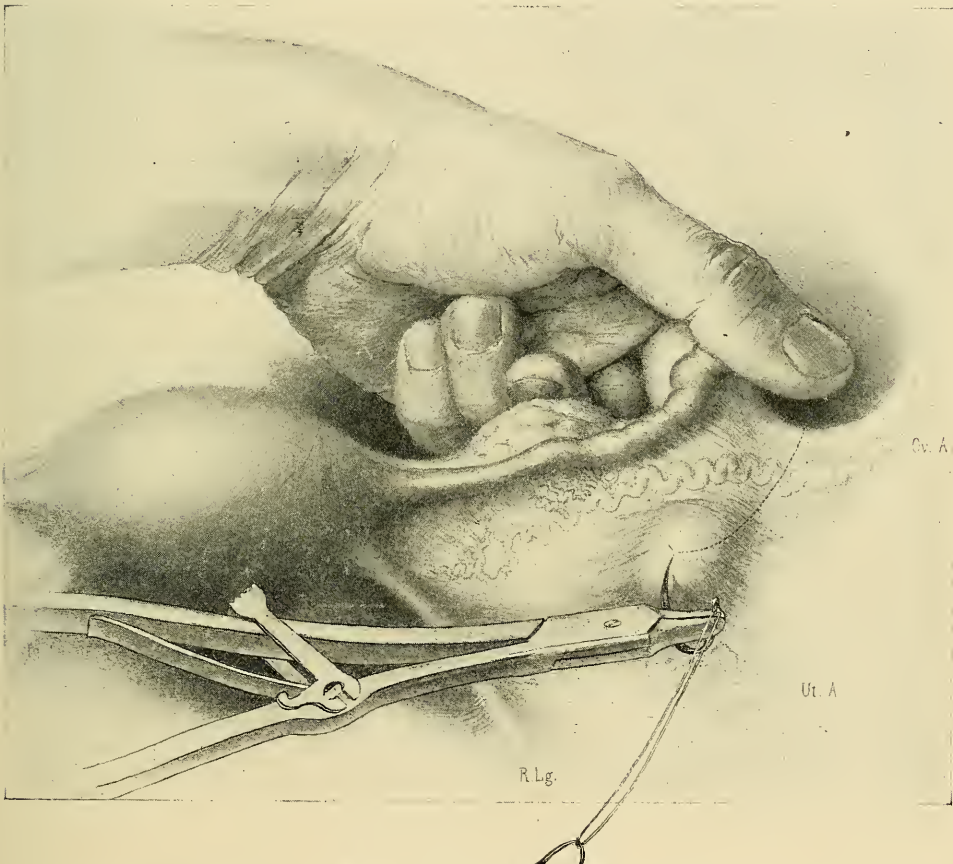

FIG. 118.—THE CLEAR SPACE.

As has been pointed out by Kelly, a clear space always exists in the broad ligament at a point approximately indicated by the tip of the finger. Here the broad ligament consists merely of the two peritoneal layers. The ligature can be passed at this point without fear of injury to any of the blood-vessels—a great advantage, since every operator knows by experience that a prick in these vessels causes free bleeding and obscures the field; and, further, that the escaping blood finds its way between the folds of the broad ligament toward the pelvic wall, often giving rise to a troublesome hæmatoma.

trols the uterine arteries near their sources of origin. The bladder is entirely freed not only from the uterus, but also from the vagina for a considerable dis-

tance. The rectovaginal space is then opened, and the posterior vaginal wall is stripped from the rectum as far down as necessary. Finally, the lateral vaginal attachments are loosened.

The uterus and vagina having thus been entirely freed, the uterus can be pushed down into the pelvic outlet, the vagina being inverted by making trac-

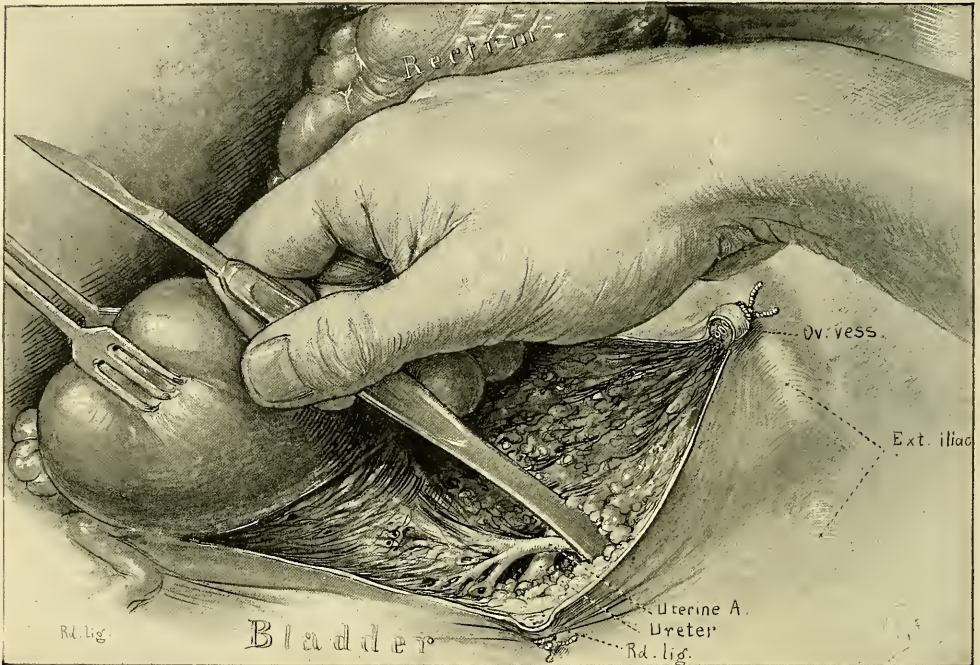


FIG. 119.—ABDOMINAL HYSTERECTOMY FOR CANCER OF THE CERVIX.

The stump of the left ovarian vessels is seen at the pelvic brim. That of the round ligament is in front near the bladder. The uterus is grasped by meso-forceps and drawn forcibly to the right, while the uterine artery is being traced to its origin. The ureter held rigid by a bougie is plainly seen and felt on the pelvic floor just beneath the uterine artery. (After J. G. CLARK.)

tion from below. The peritoneum from the anterior pelvic wall is united with that covering the rectum, and the abdomen is closed. The vaginal vault is now ringed, and the uterus, together with a vaginal cuff of the desired size, is removed. All this can be done without touching the diseased cervix with the fingers, or allowing it to come in contact with any wound surface, thereby absolutely excluding the possibility of inoculating healthy tissue with cancer elements. Werder has described the different steps in his operation so clearly, that I quote him in detail. "The patient having been anesthetized, the whole vaginal portion was very easily removed by a sharp spoon curette, as it was completely broken down by the disease. The remaining bleeding surface was seared over with the thermo-cautery. The patient was then prepared for laparotomy. Both ovaries and tubes were found adherent, and the left tube distended with about an ounce of creamy pus. After the ovarian arteries were secured, the bladder was separated not only from the uterus, but also from the broad ligaments on either side as far as possible,

so as to get the ureters out of the way. This opened up both broad ligaments, and the uterine arteries could be easily traced over to near the pelvic bones, where they were tied without difficulty. An assistant having inserted two fingers into the vagina as guides, the dissection between bladder and vagina was then carried down to within about an inch of the vulva. The sacro-uterine ligaments were then divided with scissors, the rectum was separated from Douglas's pouch, and with two fingers the dissection extended down to the lower half of the vagina. The lateral walls of the vagina were then freed from their attachments. The uterus and vagina were now only held by the base of the broad ligaments, which were very firmly bound to the vaginal fornices, the separation of which formed the only really difficult part of the operation. This having been accomplished and the broad ligaments completely divided, the finger could be passed all around the uterus and vagina, and at no place had the vaginal tube been opened. The loss of blood during the whole operation was insignificant. The uterus and vagina were then pushed down into the pelvic outlet, and the bladder, with its peritoneal flap drawn across the pelvic cavity, stitched over the rectum to the posterior wall of

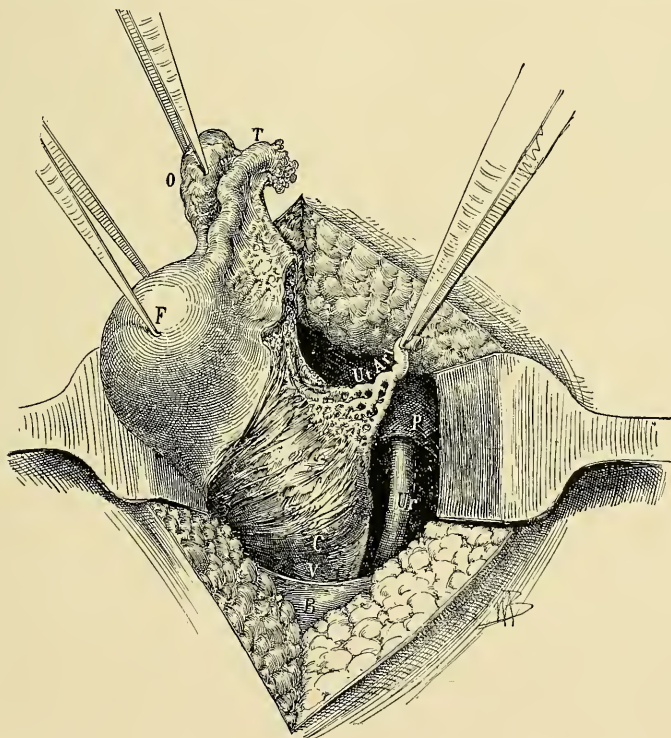


FIG. 120.—ABDOMINAL HYSTERECTOMY FOR CARCINOMA OF THE CERVIX.

The uterus (*F*) being pulled far to the right, the uterine artery is tied and dissected away from the ureter (*Ur*) with a mass of pelvic cellular tissue. *P* is a posterior layer of peritoneum; *B*, the bladder; *C*, the cervix; *V*, the vagina. (After J. G. CLARK.)

the pelvis, thereby completely shutting off the pelvis from the general peritoneal cavity, and covering up all raw surfaces with peritoneum. The abdomen was

closed in the usual manner. The operation having been done in the Trendelenburg posture, the patient was now replaced into the ordinary lithotomy position. The uterus, which was protruding at the vulva, was seized with volsella forceps and drawn completely out of the vulvar orifice with the inverted vagina. With the finger in the rectum and the sound in the bladder as safeguards against

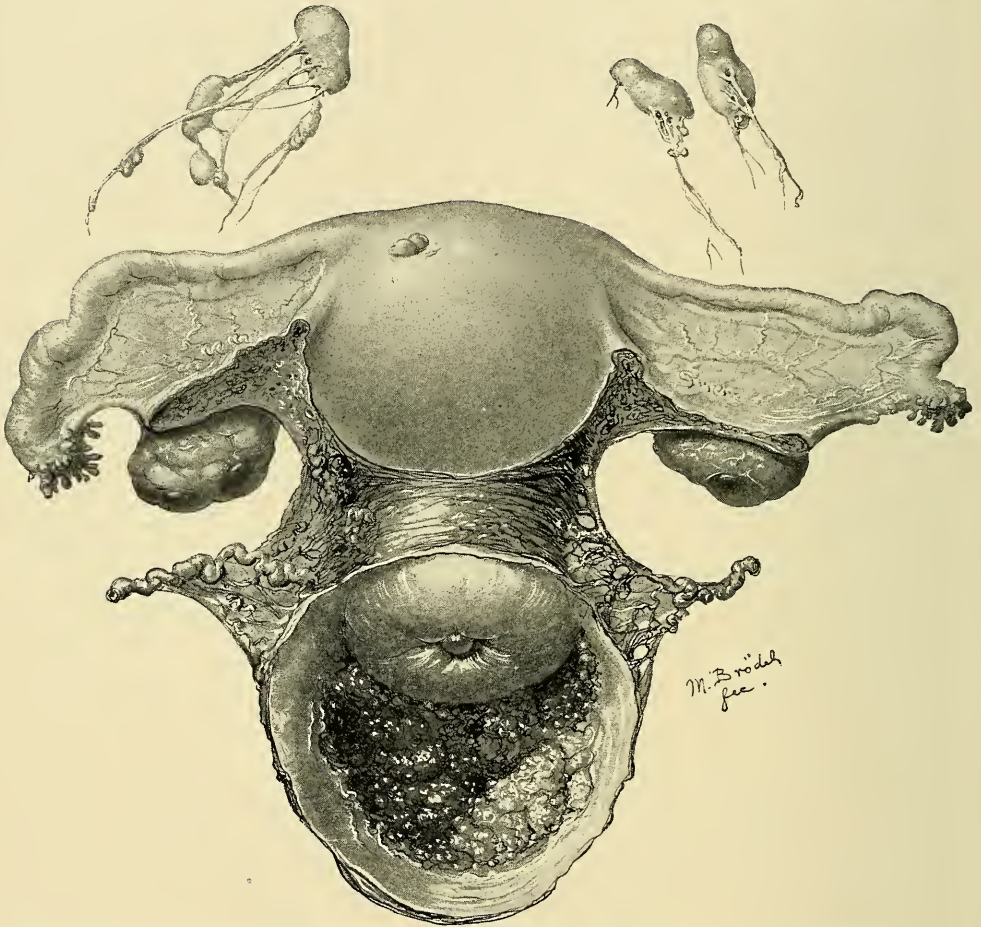


FIG. 121.—THE UTERUS AND GLANDS AS REMOVED IN THE RADICAL OPERATION. ($\frac{5}{7}$ natural size.)

The carcinoma appears to be limited to the posterior cervical lip and the adjoining vaginal mucosa. A large section of the vaginal vault has been removed, and laterally the uterine arteries with the accompanying parametrial tissue. Springing from the anterior surface of the fundus are two small subperitoneal myomata. The body of the uterus and the appendages are normal. The iliac lymph channels have been removed, as seen above, four glands from the right and two from the left side. (After H. A. KELLY.)

injuring these organs, the inverted vagina was amputated with the thermocautery. An inspection of the pelvis showed a large raw cavity, lined in front and above by the bladder, behind by the rectum, about four inches of which was completely exposed, and below by a very short vagina. The cavity was lightly packed with gauze. Duration of operation two hours. Examination of the pelvis on the tenth day showed a very small cavity above the remaining vagina covered



The figure is a detailed anatomical drawing of a human torso, showing the internal organs. The drawing is oriented vertically on the page. The text is written in Latin and is arranged in a column to the right of the figure. The text describes the anatomical features shown in the drawing, including the stomach, liver, and intestines. The drawing is a classic scientific illustration, likely from an 18th-century medical text.

Tab. III. - *Figurae Anatomicae*.
 Tab. III. - *Figurae Anatomicae*.

(1776)

posed to the usual manner. The operation being finished, the Transverse colon passed, the peritoneum was retracted into its ordinary anatomical position. The uterus was then completely removed, and carried into a suitable receptacle and drawn completely out of the pelvic cavity with the iliac vessels. With the finger in the rectum and the hand in the vagina, the removal of the uterus

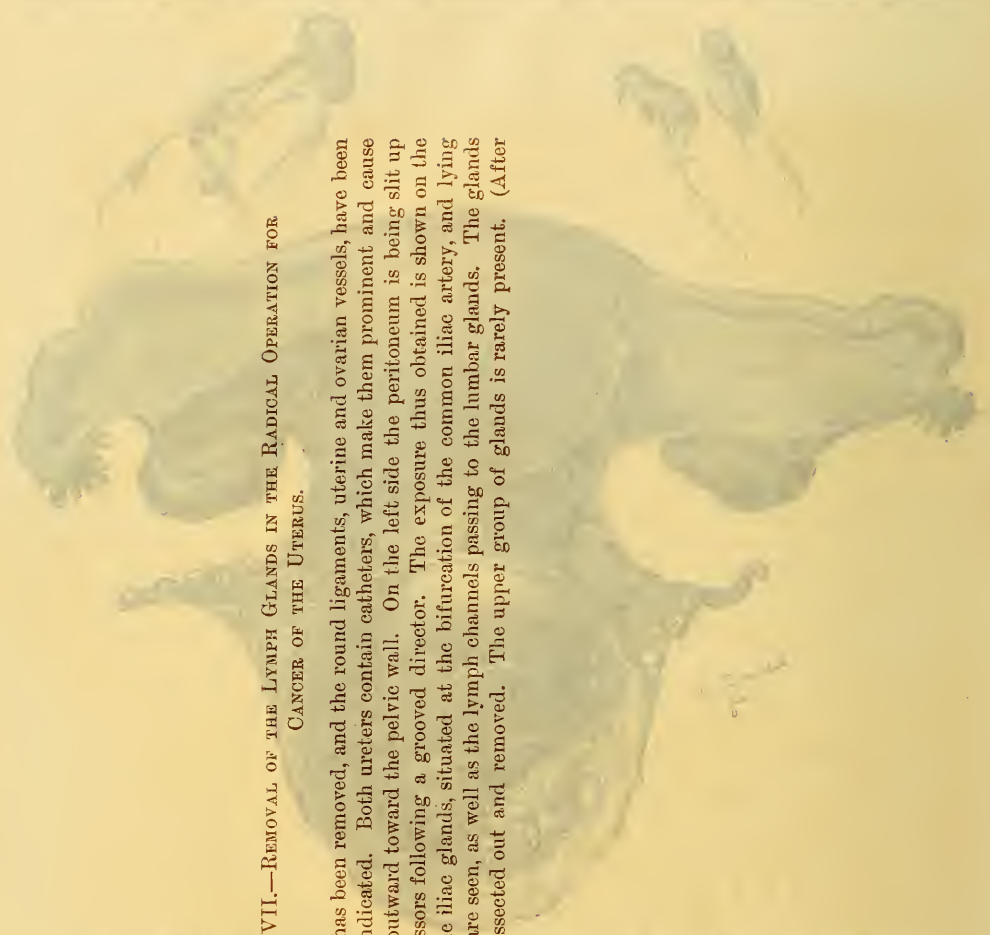
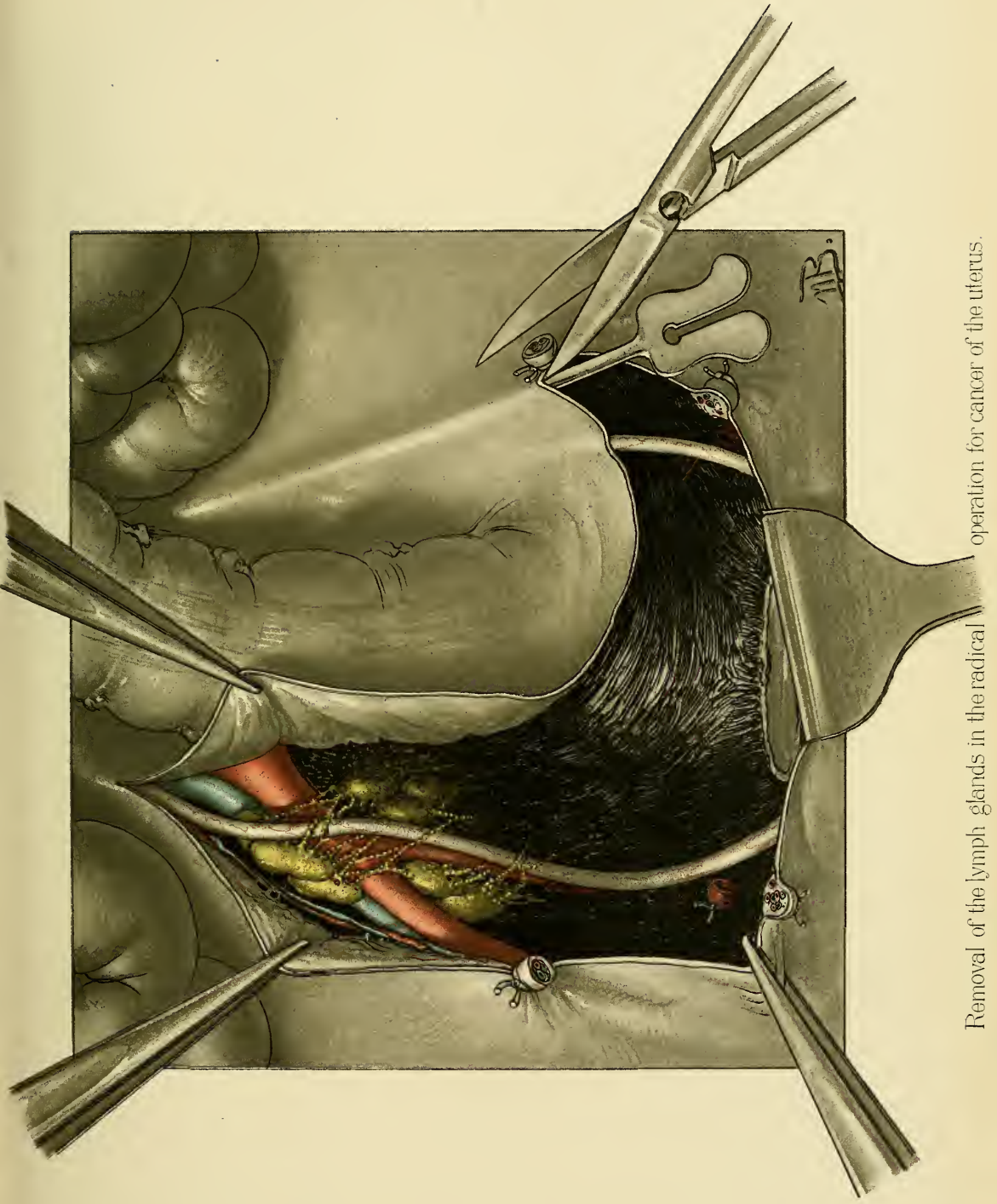


PLATE VII.—REMOVAL OF THE LYMPH GLANDS IN THE RADICAL OPERATION FOR CANCER OF THE UTERUS.

The uterus has been removed, and the round ligaments, uterine and ovarian vessels, have been controlled, as indicated. Both ureters contain catheters, which make them prominent and cause them to curve outward toward the pelvic wall. On the left side the peritoneum is being slit up by a pair of scissors following a grooved director. The exposure thus obtained is shown on the right side. The iliac glands, situated at the bifurcation of the common iliac artery, and lying on its surface, are seen, as well as the lymph channels passing to the lumbar glands. The glands are carefully dissected out and removed. The upper group of glands is rarely present. (After J. G. CLARK.)

The following description of the operation is taken from the report of the author, J. G. Clark, M.D., in the *Annals of the New York Academy of Medicine*, vol. 1, p. 100, 1892. The operation was performed on a patient who had been suffering from cancer of the uterus for several years. The patient was a woman of 45 years of age, who had been married for 20 years, and had borne five children. She had been suffering from a discharge from the uterus for several months, and had lost considerable weight. The operation was performed on the 15th of July, 1892, and was successful. The patient recovered from the operation, and was discharged on the 10th of August, 1892. She has since remained well, and has borne two children.

operation being complete the incision was completed with the Metzenbaum forceps. The incision of the rectum closed a few days, and was treated and cured by the surgeon, followed by a treatment of four weeks of which was complete recovery. The patient was discharged on the 10th of August, 1892. The operation was performed by the author, J. G. Clark, M.D., and was successful. The patient recovered from the operation, and was discharged on the 10th of August, 1892. She has since remained well, and has borne two children.



Removal of the lymph glands in the radical operation for cancer of the uterus.

with healthy granulations, in which the bladder and rectum were no longer recognisable. The operative technique I found much easier than I had anticipated, and not more difficult than a total abdominal hysterectomy. After a little experience I think it should not consume more time than the latter operation. I would suggest the use of rubber gloves for the preliminary curettement, to keep the hands aseptic, and to avoid contact with cancerous tissue, thereby not only preventing any danger of septic contamination, but also excluding with absolute certainty the possibility of inoculation."

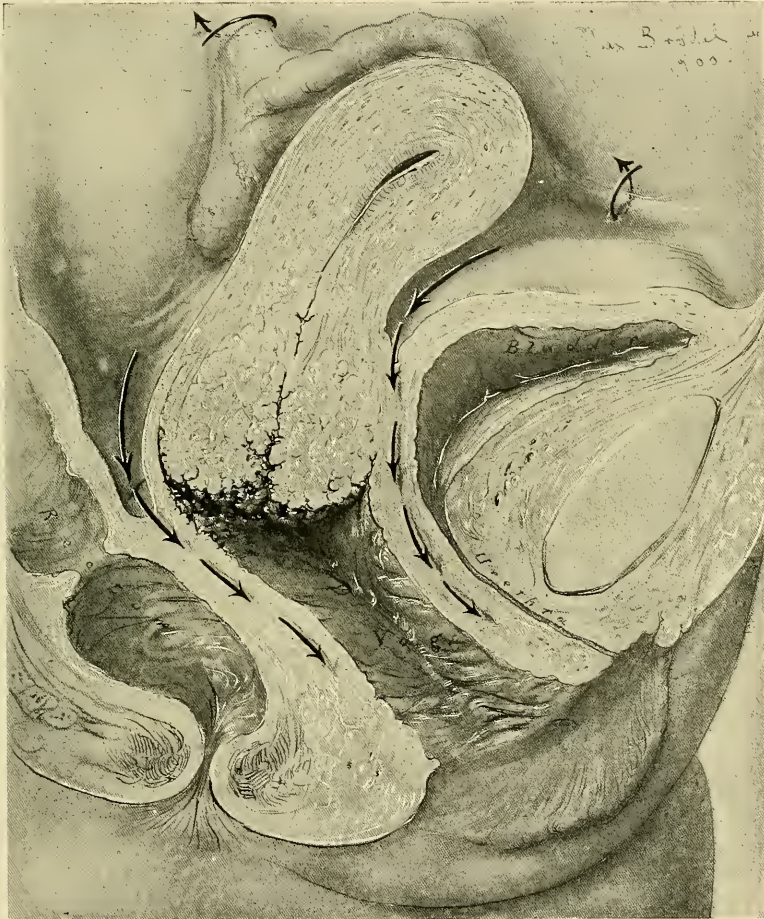

FIG. 122.—A SEMI-DIAGRAMMATIC ILLUSTRATION OF THE FIRST STEP IN WERDER'S OPERATION.

The appendages on both sides are liberated from their attachments as near the pelvic wall as possible, and the uterus is separated from the bladder anteriorly. The dissection is then carried down into the vaginal vault to within 1 or 2 centimetres of the outlet, as indicated by the arrows. Posteriorly, the vagina is freed from the rectum to within a short distance of the outlet.

My colleague, Dr. Russell, has recently employed Werder's method, and finds that the operation is not a very difficult one in suitable cases, and further that, if necessary, a very broad vaginal cuff can be removed with ease. This method

appears to be a most promising one, allowing, as it does, such a wide removal of the vaginal mucosa with its underlying connective tissue. It will naturally commend itself to most operators, and will undoubtedly find a wide field of employment.

The various steps in the abdominal operation now are :

1. Removal of broken-down carcinomatous cervical tissue, preferably a few days before.
2. Insertion of ureteral bougies, if desired.
3. Ligation of the ovarian vessels and round ligaments.
4. Freeing of the bladder from the uterus and broad ligaments.
5. Opening of broad ligaments, location and freeing of ureters to the points at which they enter the bladder.
6. Ligation of uterine vessels near their points of origin.
7. Dissection of bladder free from vaginal vault (Fig. 122).
8. Dissection of rectum from vaginal vault.
9. Removal of pelvic lymph glands.
10. Freeing of vaginal fornices.
11. Closure of pelvic cavity by uniting the vesical peritoneum with that of the rectum, an assistant meanwhile making strong traction on the cervix from below.
12. Closure of the abdomen.
13. Ringing of vaginal vault with a thermocautery or knife, thus freeing the uterus and its surrounding vaginal mucosa (Fig. 123).
14. Application of a light gauze pack to the space left in the vaginal vault.

After all abdominal operations it is our routine treatment to give an enema consisting of one litre of salt solution, to which, if the patient be weak, two ounces of brandy and twenty-five grains of carbonate of ammonium are added. This procedure was advocated by Clark,* who published an article, in 1896, laying especial stress upon its importance. He referred to Russell's † report on the analysis of urine following gynæcological operations, in which the vesical irritability, so often noted after operation, was attributed to the retention in the bladder of small quantities of highly concentrated urine. Clark, from a comparative study of those cases receiving saline enemata with those in which they were omitted, showed that in the former not only was the urine increased in amount, and there was less vesical pain, but the thirst was also greatly diminished.

At the conclusion of the operation, and before the abdominal dressings are applied, the patient is elevated to the medium Trendelenburg posture. A stiff rectal tube is then inserted well up into the sigmoid flexure, and the fluid is gradually poured into the glass funnel, which is held three or four feet above

* Clark, J. G. *Prevention of Thirst Following Abdominal Operations.* *Maryland Med. Jour.*, 1896, xxxv, 116.

† Russell, W. W. *Urinalysis in Gynæcology.* *Johns Hopkins Hospital Reports*, 1894, vol. iii, p. 433.

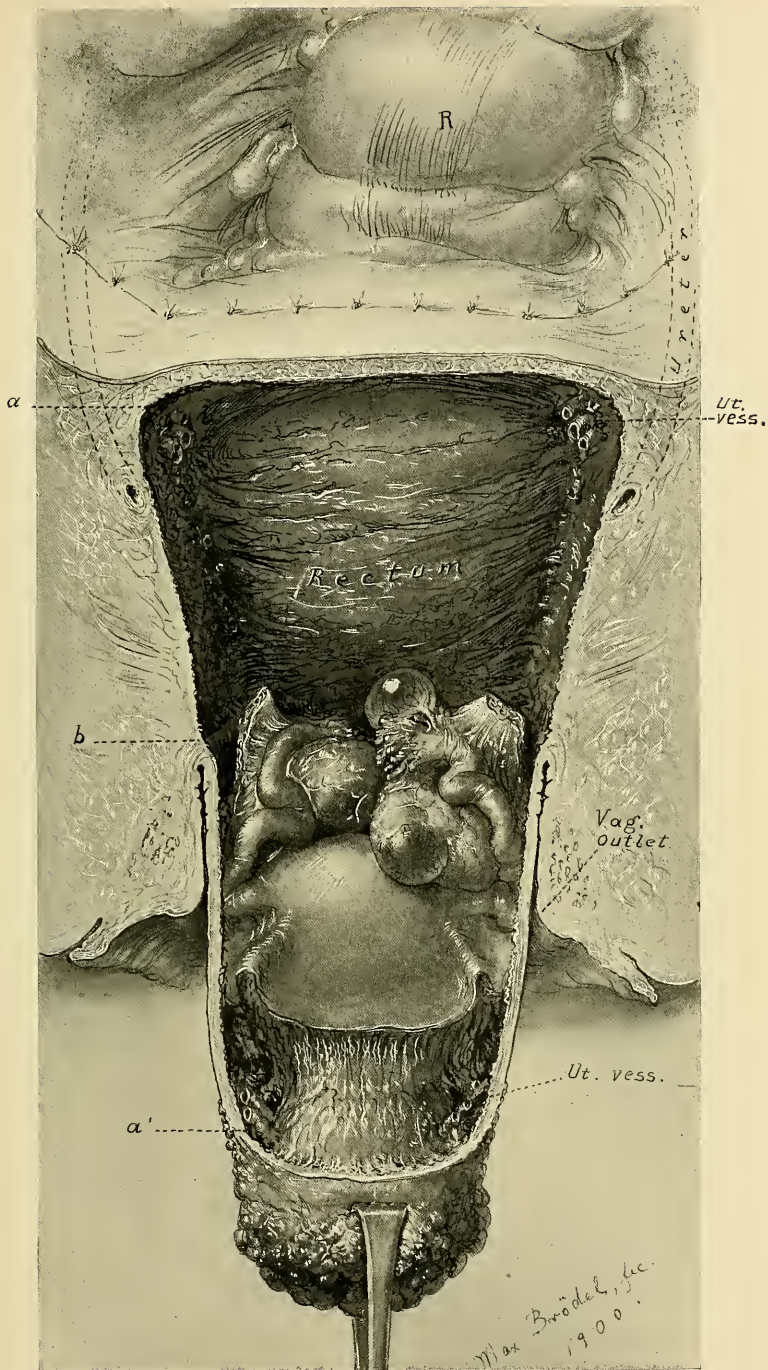


FIG. 123.—THE SECOND STEP

IN WERDER'S OPERATION.

The uterus has been drawn strongly down, the organ are presenting through the vulva. has been united with that of the rectum, thus men has been closed. Between the pelvic floor the upper angles of this are the stumps of the ment of *a'*; thus the area *ab* corresponds to *b a'*.

ward by an assistant, until at least two thirds of The peritoneum from the anterior pelvic wall shutting off the floor of the pelvis. The abdomen and the uterus is a space of several inches; in uterine vessels. *a* indicates the former attachment. The great advantage of this method is readily seen, as the operator at no time comes in direct contact with the carcinomatous tissue. With the uterus in this position, and all the important vessels tied, it is only necessary to ring the vaginal vault with a knife or the thermo-cautery, removing as much of the vaginal mucosa as is necessary.

the patient's buttocks. For the retention of this enema it is necessary that the patient be under the influence of the anaesthetic, otherwise it will be expelled.

CARE OF THE PATIENT AFTER ABDOMINAL HYSTERECTOMY

The temperature is taken every six hours, the thermometer being usually placed in the mouth, since it is deemed advisable that any close contact with the site of the operation should be avoided. As a general thing the temperature is below 100° F., unless some infection is present. This, unfortunately, is more likely to occur after hysterectomy for carcinoma than for other troubles; first, because of the necrotic and sloughing surface, which under the most careful precautions is so difficult to render clean; secondly, because there are occasionally small accumulations of pus above the point reached by the curette, whose presence has not been suspected, until during the enucleation they are suddenly opened up.

In connection with the urine two points must always be borne in mind:

- (a) The retention of urine.
- (b) The amount of urine.

To avoid undue retention, the bladder is catheterized every eight hours until the patient is able to void her urine, which usually occurs about the third day. She should always be encouraged to micturate, and occasionally is able to do so from the time of operation. The estimation of the amount of urine is exceedingly important, and in those cases in which it has been feasible to catheterize only one ureter, it is possible to obtain a fairly accurate idea as to whether or not the non-catheterized ureter has been occluded by a ligature. Five to eight hundred cubic centimetres of urine is sufficient for the first twenty-four hours.

The presence of blood in the urine for several days after the passage of ureteral catheters is quite common, and need not necessarily occasion any alarm.

The pulse is recorded every hour for the first six hours, and then four times daily. Not infrequently it suddenly reaches 140, or even 160, in less than half an hour after operation, especially in weakly patients. Elevation of the foot of the bed and the application of an ice-cap over the heart will soon bring it down to 120 or 112 beats to the minute. Provided the colour is good and the lips are not blanched, hæmorrhage need not be feared. Strychnine is given in $\frac{1}{16}$ -grain doses every two hours for the first day and subsequently every four hours, until the sixth or seventh day, when it is replaced by tincture of nux vomica and malt. If the patient complains of great discomfort immediately after operation, $\frac{1}{8}$ grain of morphine sulphate is ordered, and repeated if no relief is obtained in half an hour. This is practically the only time that morphine is given. It is a rule that no patient is to be awakened for medicine, sleep being more important.

Nausea is a frequent and at times a troublesome condition following the operation. To control it, all nourishment by the mouth is stopped, and hot water is given frequently. This does good in any case. If it be retained, it stimulates and quiets; on the other hand, if it is expelled, some relief is obtained, since a considerable amount of mucus comes away with the water. Champagne

in teaspoonful doses seems to have a sedative effect, and is often more satisfactory than the various medicines. A hot-water bag to the stomach and ice applied over the œsophagus will often afford relief, probably by controlling the reflex centres. Occasionally one or two drops of a 1-per-cent solution of cocaine hydrochlorate, or a drop of carbolic acid mixed with a little lime water, will check the vomiting. As a last resort it may be necessary to wash the stomach out.

Thirst, which was so frequently complained of after abdominal sections, is to a great extent prevented by giving the saline enema immediately after operation. Should the thirst, however, manifest itself while the patient's stomach is still in a state of unrest, a second enema of salt solution may be administered.

General Treatment.—First day: The patient receives nothing until midnight, save probably a little hot water. She is turned on her side, her back being supported by pillows.

Second day: Early in the morning egg-albumen is given, the patient receiving at first from two to four drams; the amount is gradually increased until, by the end of the day, from two to four ounces are taken at a time. As albumen is the most important nourishment given in the early days, a knowledge of the method of preparing it is of practical importance. The white of an egg is taken and some crushed ice added, then a pinch of salt and (unless champagne is indicated) a little lemon juice; the whole is thoroughly shaken, strained, and is then ready for use. One ounce of champagne is generally administered with the albumen. If nausea be still present, only champagne is allowed. It is admissible to give a little broth should the patient have an antipathy to the albumen. For a few hours after, as before the operation, milk by the mouth is avoided. If the stomach refuses all nourishment, nutritive enemata, consisting of four ounces of milk, the whites of two eggs, one ounce of whisky, and part of the contents of a peptonizing tube, are given every six hours. Commencing with the second day, the patient receives a daily sponge bath, no matter how ill she may seem, and is afterward gently rubbed with alcohol. About 10 P. M. one grain of calomel is administered, and at 11 P. M. a similar dose is given. Toward evening the patient is usually very uncomfortable, restless, and the temperature generally reaches 100°.

Third day: On the third morning the patient may still be uncomfortable, but is invariably relieved after a large simple enema, which, if not effectual, is to be followed by a second, if need be, siphoned off. After this the bowels are to be moved freely every second day. The desired effect is usually obtained by giving half an ounce to one ounce of Epsom salts at night, followed by an enema in the morning. As soon as the bowels have been well evacuated any liquid diet may be selected, the patient receiving albumen, milk punch, beef or chicken broths, egg-noggs, strained soups, and jellies.

Fourth and fifth days: The liquid diet, as commenced on the third day, is continued.

Sixth day: Soft diet, consisting of custards, soft toast, rice, eggs, fish, and oysters, is now allowed. Food is taken in increasing quantities until the tenth day, when the patient receives a diet preferably consisting of chicken, chops, steak, but in fact of anything excepting coarse vegetables, condiments, and indigestible foods.

UNTOWARD SYMPTOMS OCCURRING DURING THE OPERATION

A rapid and weak pulse causes the most anxiety. This is generally due to the length of the operation or the loss of blood, but occasionally to the frail condition of the patient. On the first intimation of a weak pulse, $\frac{1}{40}$ of a grain of strychnine is administered hypodermically, to be followed, if necessary, by a second injection in a few minutes.

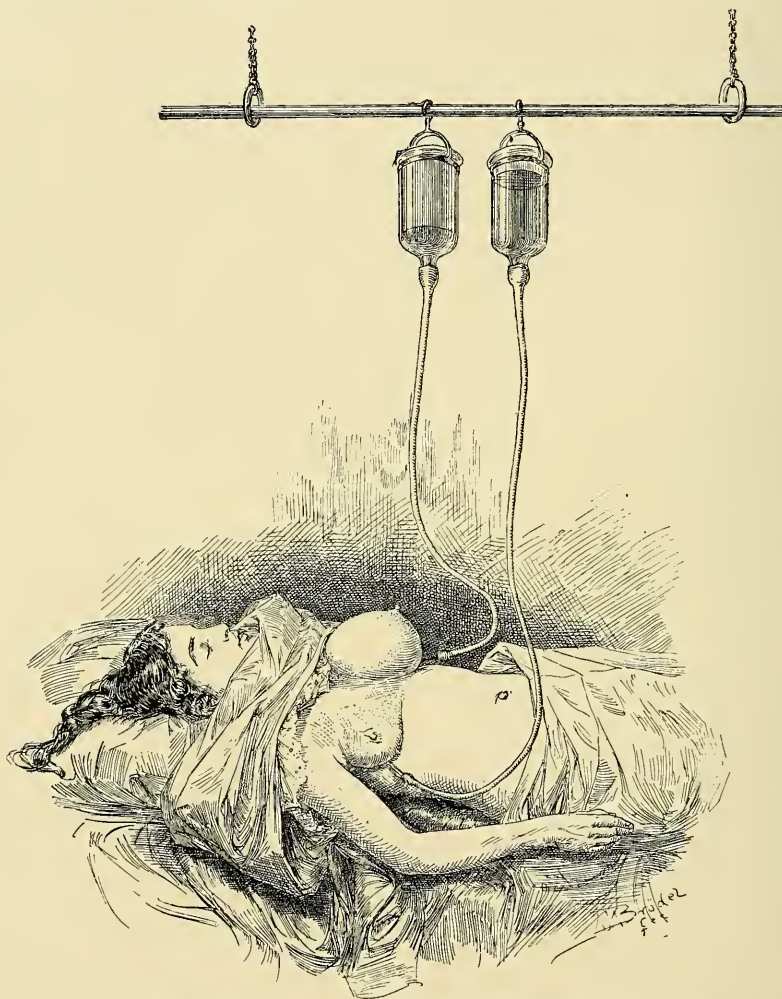


FIG. 124.—INTRODUCING NORMAL SALT SOLUTION UNDER THE BREASTS.

The form of the breast prior to injection is seen on the right side, where the trocar has just been introduced beneath the gland. On the left side the breast is fully distended by 500 cubic centimetres of the solution. (After H. A. KELLY.)

Salt solution has been shown to be the best stimulant under these conditions. Where much blood has been lost, it re-establishes the normal amount of fluid in the vessels. Formerly, as a study of Cases 2,248 (p. 275) and 2,572 (p. 92), will

show, it was customary to open the radial artery, introduce 500 to 1,000 cubic centimetres of salt solution, and doubly ligate the vessel. The effect on the pulse was instantaneous, it becoming fuller and less rapid. For the last two years Edebohl's method of infusing salt solution beneath the breast has been employed; and during this time, as reported by Clark,* 41 out of 225 cases of abdominal section have received the submammary infusion.

METHOD OF INFUSING SALT SOLUTION

Graduated glass infusion jars of 1,000 cubic centimetres' capacity are used as reservoirs. These bottles are connected by five feet of rubber tubing to a long slender infusion needle, which is 2 millimetres in diameter, and similar to an aspirating needle. The entire apparatus is sterilized and kept in a sterile covering. Before the infusion is given, the breast is carefully disinfected, especially in its dependent area. It is then grasped with one hand and lifted well up from the thorax, while the needle with the fluid flowing from it is quickly thrust beneath the gland. Simple elevation of the reservoir is usually sufficient to force the fluid into the loose cellular tissue, and the breast quickly begins to distend, until even a flabby and atrophied organ will reach the size of a puerperal breast. If the fluid does not flow by its own pressure, it can be effectually forced in by stripping the tube. Seven hundred cubic centimetres of solution may be injected under each breast. As this plan of treatment is so simple, it is adopted in all cases in which the pulse shows even a moderate degree of weakness. It was employed in Cases 4,430 (p. 250), 3,930 (p. 67), 4,176 (p. 73), and 4,143 (p. 61), the last receiving 1,000 cubic centimetres in each breast.

COMPLICATIONS ARISING DURING ABDOMINAL HYSTERECTOMY

After opening the abdomen it is always well to carefully survey the field, as the disease is at times much farther advanced than would be inferred from vaginal examination. If the process has extended far laterally, it will be advisable to close the abdomen at once, since the radical operation is practically hopeless, and the dangers attending partial enucleation are great.

The operator is at times greatly deceived as to the extent of the growth, even after the abdomen is opened. Thus in our case No. 4,976, on vaginal examination the condition was considered on the "border line." I proceeded to a radical operation; the ureters were well outlined, but on account of the extensive lateral involvement the uterine arteries could not be located near the uterus, so that it became necessary to follow the internal iliac down to the point of origin of the uterine artery. The latter was then traced toward the uterus.† The vessels were doubly ligated and gentle traction was made on the body, when the top tore off, revealing the fact that a mere shell of uterine muscle remained. No other alternative was left but to remove as much of the necrotic tissue as

* Clark, J. G. *Submammary Infusions of Salt Solution*. *Am. Jour. Obstet.*, 1897, xxxv, 769.

† This will prove a useful plan in any case in which the artery is not easily located.

possible, turn the carcinomatous cervix down into the vagina, and draw the bladder peritoneum over the stump, uniting it with that of Douglas's sac. The patient died on the twelfth day. At autopsy the cervix was found to be necrotic, and in the angles, where the uterine vessels had been controlled, were small accumulations of pus—a condition that might naturally have been expected as a consequence of contamination with the foul necrotic cervix. Cases 2,591 (p. 265) and 3,114 (p. 117) are very good examples of extensive involvement, and it might be expected that such uteri should give way when traction is made upon them.

Hæmorrhage.—On account of the close proximity of the large vessels to the uterus, it is little wonder that, during the prolonged and far-reaching dissection required to insure a thorough removal of the disease, they are occasionally wounded. Indeed, it is surprising that the accident does not occur more frequently. During the freeing of the bladder there is often capillary oozing, and during the dissecting out of the uterine arteries these vessels may be ruptured. Thus, in Case 3,616 (p. 297), during the enucleation, the right uterine artery and vein were torn and a copious hæmorrhage followed, the blood filling the pelvis more rapidly than it could be sponged out. The vessels were controlled by three pairs of artery forceps, which were gently removed on the sixth day.

When a large vessel, such as the iliac artery or vein, is injured, the field of operation is instantly obscured, and to quickly control the bleeding vessel requires coolness and rapidity of action. The accident may occur during the removal of the iliac glands, should too great traction be made, or if a sharp instrument be used. In Case 2,568½, during the ligation of the left internal iliac artery, the vein was injured. The record of the accident is instructive on account of the way in which the hæmorrhage was controlled, and also because serious consequences followed the ligation. The vessel injured was either the common iliac or the external iliac vein.

In a recent case operated upon by Dr. Kelly at his private hospital, a radical operation was attempted, but as the disease had extended far laterally, the dissection proved to be very difficult. The posterior branch of the internal iliac artery was torn, and the blood spurting several feet into the air. The tissue at this point was instantly grasped with the hand, and after the application of several artery forceps, it was found that the bleeding had been checked. The pelvis was sponged out, the vessels were ligated, and the operation was abandoned. The abdomen was closed without drainage. The patient recovered sufficiently to travel several hundred miles. Naturally, the prognosis was most unfavourable.

Copious Hæmorrhage due to Injury of the Left Internal Iliac Vein

Gyn. No. 2,568½

Squamous-cell carcinoma of the cervix with cauliflower outgrowth. Ligation of the left internal iliac artery (Fig. 125); copious hæmorrhage from injury to the left iliac vein, which after much difficulty was controlled and ligated. Ligation of the right internal iliac artery; gangrene

of the left leg necessitating amputation on the eighth day. Marked sloughing of the carcinomatous growth; death during the eighth week.

M. F., aged sixty; white. Admitted March 20, 1894. Complaint: offensive uterine discharge; backache; dull, aching pain along the rectum.

The patient has been married thirty-four years, and has had five children and two miscarriages. Her menses, which were always regular, ceased seven years ago. Her uncle died of carcinoma of the lip; the family history is otherwise good, and she has always been healthy.

In November, 1893, the patient began to complain of a dull, tired feeling after any slight exertion, and occasionally noticed a very faintly blood-tinged discharge. From that time on, at frequent intervals, she has had slight hæmorrhages, which are most likely to occur after any undue exertion. At night she experiences a moderate amount of backache.

The vaginal outlet is relaxed; the upper third of the vagina and the entire cervix are occupied by fungating masses, which are firm, but which nevertheless bleed readily. The upper part of the uterus is normal in size and is freely movable; no induration can be made out in the broad ligaments.

Operation, March 24th. The new growth was as far as possible curetted away with the finger, leaving a wide, raw surface. The patient was then placed in the Trendelenburg position and an incision made through the thick, abdominal walls. The peritoneum on either side was drawn outward and sutured to the tissue just beneath the skin, thereby hiding the subcutaneous fat, and materially assisting the operator. The omentum, sigmoid flexure, and small intestines, all of which contained large masses of fat, were with difficulty pushed upward toward the diaphragm, and kept out of the field of operation.

The meso-sigmoid at the brim of the pelvis was snipped with a pair of scissors, and the incision enlarged; the external and internal iliac arteries were then easily palpable. The internal iliac was dissected out of its bed of adipose tissue and ligated 1 centimetre below the point of bifurcation and just above its division into the anterior and posterior branches (Fig. 125).

Copious venous hæmorrhage followed the passage of the ligature, and was only controlled by continued pressure at different points with the finger. This procedure did not, however, avail, as the fingers soon became paralyzed. After about six minutes the vein, which was 1 centimetre in diameter, was successfully ligated. On the right side, the internal iliac artery was more easily exposed; it also was tied 1 centimetre below the point of bifurcation. On the afternoon of the same day the left leg was cold, and from the knee to the tips of the toes the skin was of a bluish tinge; the patient complained of excruciating pain in the extremity. The condition of the leg gradually grew worse, and on April 1st it was amputated by Dr. Finney, as it had become gangrenous. The following note was made on April 22d:

The patient's general condition has gradually improved since the amputation; the growth about the cervix has a peculiar softish feel and breaks down easily;

examination, however, occasions little hæmorrhage. In the right vaginal vault the mass has sloughed away, leaving a cavity that extends upward almost to the

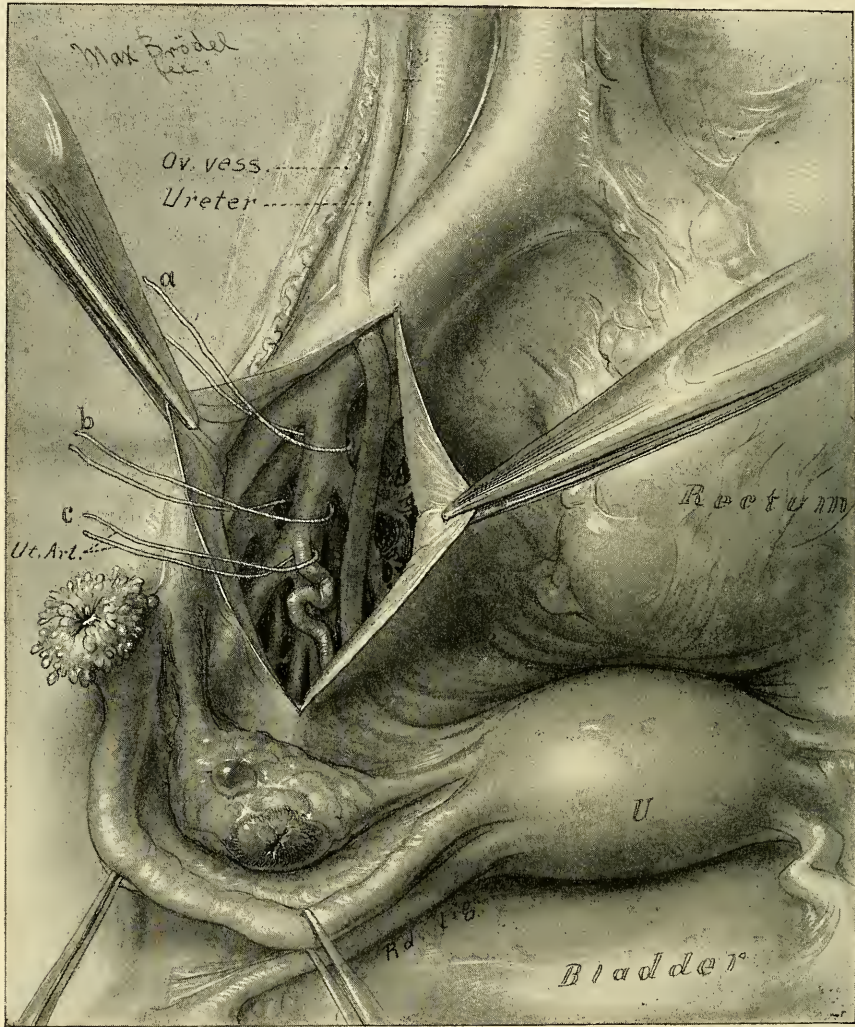


FIG. 125.—LIGATION OF THE INTERNAL ILIAC OR UTERINE ARTERIES. (Natural size.)

In the upper part of the picture are the ovarian vessels, the ureter, inferior vena cava, and aorta, in the order mentioned. The aorta divides into the common iliacs, and each of these into an external and an internal iliac artery. The ureter crosses the common iliac, and lies on the inner side of the internal iliac. The peritoneum has been split for a distance of several centimetres, and at *a* the ligature has been thrown around the internal iliac, just before it divides into the anterior and posterior branches. As noted in the history, the accompanying vein was injured when this ligature was being applied. To check the blood supply to the uterus, the ligature may be applied to the anterior branch of the internal iliac, as indicated at *b*; or the uterine artery itself may be dissected out and ligated, as shown at *c*. For the distribution of these blood-vessels, see Fig. 146.

internal os. May 11th: Little change is noted; 3 centimetres within the outlet on the anterior wall, however, is a small nodule about the size of a bean. As one

advances into the uterus, the sloughing becomes more marked, and one receives the impression that the entire body of the uterus is necrotic.

Shortly after this date the patient had daily chills, the temperature rising to 103° or 104°, and she suffered almost constantly from nausea and vomiting. The leg healed very slowly, but the granulations looked fairly healthy. At the last examination it appeared as if all the pelvic organs were sloughing away. She died May 18th.

Gyn.-Path. No. 260. The specimen consists of pieces of mushy friable tissue, the largest of which is 2.5 centimetres in diameter.

HISTOLOGICAL EXAMINATION.—These pieces of tissue are composed almost entirely of oval, irregular, elongated, or branching alveoli filled with cells having oval, vesicular nuclei. Some of the cells have very large oval, or half-moon-shaped, nuclei. Many nuclear figures are found, and there is considerable karyorrhexis. In numerous places polymorphonuclear leucocytes appear between the individual cells of the growth, the centres of many of the alveoli also being filled with them. The stroma between the alveoli is very scant, and is made up of spindle-shaped cells. There is considerable small-round-cell infiltration. The picture is that of a typical squamous-cell carcinoma exceedingly rich in epithelial elements.

Diagnosis.—Squamous-cell carcinoma of the cervix.

INJURY TO THE BLADDER DURING ABDOMINAL HYSTERECTOMY

The bladder is rarely injured during abdominal hysterectomy, but should it be torn, the rent is very easily sutured, and, as was demonstrated by the accompanying cases, need cause little uneasiness. In Case 3,609 the bladder was very closely adherent to the uterus, and during its liberation was torn for a distance of 2.5 centimetres. The vesical rent was closed with mattress sutures of catgut. Death in this case was evidently due to infection from the growth.

While operating on Case 5,959 (p. 242) it was found necessary to remove a portion of the base of the bladder, as it had been infiltrated by carcinomatous tissue. The bladder opening was closed by five catgut sutures and the vaginal drain introduced. No leakage followed.

In Case 2,248 (p. 275) the bladder was evidently torn during the operation, as a vesico-vaginal fistula followed. This was successfully repaired four months later.

While from these cases it is seen that a tear in the bladder is easily sutured, one must always remember, when working at the base of the bladder, that the ureteral orifices lie in the vicinity and may easily be included in the ligature.

Cases in which the Bladder was Torn during Abdominal Hysterectomy

Gyn. No. 3,609

Squamous-cell carcinoma of the cervix; extension to the vagina, broad ligaments, and body of the uterus; dermoid cyst in the left ovary; combined abdominal and vagi-

nal hysterectomy; accidental rent 2.5 centimetres long in the bladder wall, closed with catgut sutures; right ureter dissected out of the carcinomatous tissue; death on the fourth day.

M. H., aged thirty-seven; white. Admitted June 26, 1895. The patient has been married seventeen years, and has had three non-instrumental labours. Her family history is unimportant, and she has always had good health. Her menses up to this illness have always been regular; since then they have been very profuse, and have occurred at irregular intervals.

In April, 1894, she consulted a physician for uterine hæmorrhages. He operated, removing a portion of the cervix. The hæmorrhages ceased for a time, but since last fall have been increasing in amount, and for two months have been almost constant. The patient is debilitated; the mucous membranes are somewhat pale; the appetite is good; the bowels are regular. At times she complains of some pain in the left ovarian region. The vaginal outlet is relaxed; springing from the vaginal vault is a nodular mass, about 5 centimetres in diameter. In the centre of this is a deep, conical excavation. The vaginal wall, posteriorly, is involved in the new growth. After introducing bougies into both ureters, it is possible with the examining finger to trace the right ureter through the carcinomatous mass. On the left side the ureter passes to the outer side of the growth, and does not appear to be involved.

The greatest difficulty, therefore, in the enucleation will be on the right side.

Operation, June 29th. Abdominal hysterectomy. The patient was placed in the elevated dorsal position, and bougies were introduced into both ureters. This was done with ease, requiring only three minutes and a half. An incision, 15 centimetres in length, was made through the abdominal wall. The omental fat was pale and yellowish in colour, resembling that so often seen in carcinomatous cases. The enucleation was commenced on the left side, since it was less involved than the right.

After opening the broad ligaments, the bougies could be felt as tense cords well out toward the pelvic wall. One centimetre from the point of entrance to the bladder the left ureter could be felt in close relation to the uterine artery. This vessel was easily ligated, there being no danger whatever of tying the ureter. The bladder was very closely adherent to the uterus, and in the attempt to liberate it, was torn for a distance of 2.5 centimetres. The vesical rent was closed with mattress sutures of catgut. On the right side the ovarian vessels were controlled, and the ureter was cut down upon. It was surrounded by carcinomatous tissue, from which it was carefully dissected out. The uterine artery was felt on the outer side of the ureter, and was ligated under touch. An incision was now made in the vagina, and the bleeding, which was slight, controlled as the tissues were cut. After removing the uterus, the vaginal vault was closed and the abdominal sutures were inserted. No drain was used. On the second day the patient was considerably nauseated, and vomited a greenish fluid. Her pulse was rapid, and she complained of considerable abdominal pain. On the morning of the third day the temperature was 102°, the pulse 140; the hands and feet were cold. In

the evening she was much weaker, her extremities were bathed in cold perspiration, and she had an anxious expression. Her temperature had reached 105.6°, her pulse was 160. She died early on the morning of the fourth day.

Gyn.-Path. No. 784. The specimen consists of the uterus to which the appendages are attached. The uterus measures $9.5 \times 6 \times 4.5$ centimetres, and both anteriorly and over its upper surface is covered by delicate adhesions. The cervix is 5 centimetres in breadth and 4.5 in its antero-posterior diameter. The tissue around the external os is invaded by a new growth, which has extended into the vaginal mucosa. The outer vaginal portion of the cervix is thickened, and presents a glazed appearance. On section, the entire cervix is seen to be occupied by a new growth, which in its central portions has broken down and looks worm-eaten. The solid areas are yellowish white in colour, and are to a great extent composed of minute granules, whose central portions are semitranslucent. The tumour extends upward into the uterine cavity, and here presents a stony hardness. The cavity of the body is 5 centimetres in length; its mucosa is bluish red in colour, presents a rough granular appearance, and at the fundus reaches 7 millimetres in thickness. The appendages on the right side present the usual appearance. The left tube is normal, but the ovary contains a cyst, 2.5 centimetres in diameter, in whose wall, which averages about 1 millimetre in thickness, are minute cysts; filling the cyst cavity is a grayish-white, lard-like material, immediately reminding one of the contents of a dermoid cyst.

Histological Examination.—The squamous epithelium covering the vaginal portion of the cervix is in places intact, but as one passes inward, the cells suddenly assume a different type, stain more deeply, and are seen invading the underlying tissue. Scattered everywhere throughout the stroma of the cervix are large and small areas, composed of masses of cells. These areas are elongate-oval or irregular in contour. Laterally they extend to the broad ligament and vagina; upward they invade the uterine mucosa. Their individual cells have small, round, deeply staining nuclei. Some, however, are spindle-shaped, and in many places are seen very large nuclei—four or five times the average size—which are round, oval, or irregular in contour and stain very deeply. The centres of some of these areas have become necrotic, and in this necrotic material are fragmented nuclei. There is practically no polymorphonuclear infiltration.

The cervical stroma throughout shows abundant small-round-cell infiltration. The uterine mucosa just within the internal os is, throughout its entire thickness, occupied by the new growth. The glands that still remain, are small and round on cross section; they appear normal. The rough, uneven appearance of the mucosa, noted macroscopically, appears to be the result of mechanical injury. A few of the uterine glands are dilated, but the majority are normal. The thickening of the mucosa is due to small-round-cell infiltration of its stroma and to hæmorrhage. The right tube and ovary are normal. The small cyst of the left ovary is of the dermoid variety.

Diagnosis.—Squamous-cell carcinoma of the cervix; extension to the vagina, broad ligaments, and body of the uterus; dermoid cyst of the left ovary.

Gyn. No. 5,959

Squamous-cell carcinoma of the cervix; pyometra; extensive chronic endometritis; slight pelvic peritonitis; combined abdominal and vaginal hysterectomy; resection of a portion of the base of the bladder; recovery. No evidence of recurrence one year and nine months after operation.

P., aged fifty-nine; white. Admitted March 19, 1898. Complaint: a bloody vaginal discharge.

The menses commenced at eighteen, were regular, unaccompanied by pain, and lasted about a week. The menopause occurred at about forty-seven. The patient has been married thirty years, and has borne five children. The labours were normal.

Her family and previous history are unimportant.

Present illness: The patient cannot say definitely when the trouble commenced, but is certain that it has existed more than a year. The first sign was a slight bloody discharge, which sometimes was intermittent in character, disappearing for months, while at other times it was more continuous. The hæmorrhages have never been abundant. Later she began to experience pain in the suprapubic region, and in the back and lower extremities. The pain was increased by walking or by distention of the bladder. It became so severe that three weeks ago she consulted a physician. For the last two or three weeks there has been a profuse, offensive, and irritating vaginal discharge, yellowish in colour, and at times tinged with blood. The patient has gradually grown weaker, but does not know whether there has been any loss in weight. She is markedly anæmic, and presents a cachectic appearance.

Vaginal Examination.—The outlet is relaxed, the cervix is roughened, and bleeds readily; the os is patulous; the uterus, which is the size of that of a three-and-a-half months' pregnancy, is soft, cystic, and has a smooth outer surface. On curetting the cervix, the uterine cavity was suddenly opened up, and 520 cubic centimetres of a thick yellow pus escaped. This had a peculiar sickening sweetish odour.

April 2, 1898. Combined abdominal and vaginal hysterectomy. In removing the uterus it was necessary to excise a portion of the base of the bladder. The vesical wound was closed by five catgut sutures and a vaginal drain introduced. The abdominal incision was then closed. Following operation there was some suppuration of the abdominal incision. The patient, however, made a good recovery, and was discharged May 21, 1898.

Gyn.-Path. No. 2,263. The uterus is 10.5 centimetres long, 7 centimetres broad, and 4.5 centimetres in its antero-posterior diameter. Posteriorly, it is smooth and glistening, but clinging to the anterior surface are a few adhesions. The cervix is 4.5 centimetres in diameter, and presents a markedly eaten-out appearance; its walls are very friable, and, in the vicinity of the internal os, are so thin that they tore through during removal of the uterus. The growth has extended from the vaginal portion of the cervix to a point 2 centimetres beyond

the internal os. The inner surface of the excavated area consists of delicate thread-like or papillary outgrowths, or of a roughened, granular surface. It is most interesting to note these delicate papillary outgrowths, as the cervix was thoroughly curetted ten days ago. The upper portion of the uterine cavity is

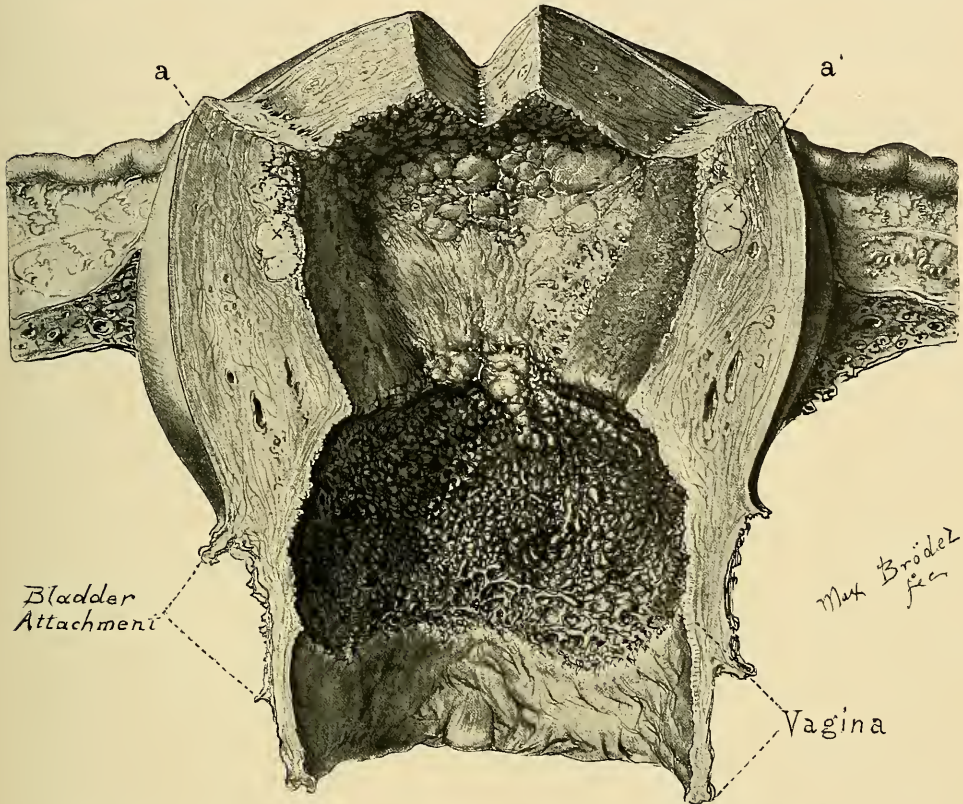


FIG. 126.—SQUAMOUS-CELL CARCINOMA OF THE CERVIX; DILATATION OF THE UTERINE CAVITY DUE TO A PYOMETRA. (Natural size.)

The carcinomatous cervix was curetted ten days before the hysterectomy was performed, and yet in this short time the finger-like processes are again lining the excavation, which extends downward to the vagina and upward beyond the internal os. The uterine cavity is dilated, and its mucosa, especially at the fundus, presents flattened elevations with intervening depressions, which are due to the contraction of the uterus after curettage of the cervix had allowed of the escape of the pus. The appearance is very similar to that presented by the inner surface of the wall of an ovarian abscess. On microscopical examination, little more than granulation tissue was found to be present, the normal endometrium having practically disappeared. *a a'* are portions of an abscess in the uterine wall.

lined by thickened, corrugated mucosa, which is markedly injected, presents a roughened surface, and is apparently the seat of an inflammatory process. In the anterior uterine wall, just beneath the mucosa, is a yellowish, caseous focus, evidently an abscess.

The right tube is 8.5 centimetres long, and averages 5 millimetres in diameter. The ovary measures $3.5 \times 1.2 \times .9$ centimetres. It is covered by a few adhesions.

The left tube is 9 centimetres in length, 5 millimetres in diameter; it is covered by a few adhesions. The ovary is of the fœtal type, measuring 6.5 centimetres in length, 1 centimetre in breadth, and .9 centimetre in thickness.

Histological Examination.—Sections from the vaginal portion of the cervix show that the surface is covered by fibrin containing red blood-corpuscles and polymorphonuclear leucocytes in its meshes. Projecting from the surface and penetrating the stroma to a considerable depth are masses of epithelial cells. In some places these form oblong or irregular nests, while at other points distinct branching of the cell-nests is visible. The individual epithelial cells have, for the most part, oval, deeply staining nuclei. They are, as a rule, fairly uniform in size, but here and there is a nucleus four or five times as large as its neighbours. Such nuclei stain intensely. At some points the cells in the centre of the nests are larger, paler, show a slightly concentric arrangement, and are apparently undergoing hornification. The surrounding stroma shows considerable small-round-cell and polymorphonuclear infiltration. The same picture is to be noted in sections taken from all parts of the cervical canal, and in the protected portions some finger-like processes are still visible. The growth, as was noted macroscopically, has extended very close to the cut surface posteriorly and laterally. It is a squamous-cell carcinoma of the cervix. To ascertain whether it has been entirely removed, it will be necessary to await clinical developments.

Sections from the mucosa of the body of the uterus show a much altered picture. The surface is in some places covered by fibrin. The superficial epithelium has disappeared, the glands are few in number, and are for the most part small and round on cross section. The stroma of the mucosa consists almost entirely of small round cells, intermingled with many newly formed capillaries—in other words, the mucosa in many places might be easily mistaken for granulation tissue. It is the seat of a severe chronic endometritis. Where the process is most marked the underlying muscle shows much small-round-cell infiltration, and at such points the superficial portions of the mucosa contain many polymorphonuclear leucocytes. Here and there the protoplasm of the small round cells is markedly increased, owing to the taking up of brown pigment resulting from an old hæmorrhage.

Sections from the uterine end of the right tube show that it is normal. The ovary contains a few small gland-like spaces, but otherwise presents the usual appearance.

Sections from the uterine cornu show that the left tube is normal at that point. The ovary is also normal.

Diagnosis.—Squamous-cell carcinoma of the cervix; pyometra; chronic endometritis; slight pelvic peritonitis.

December 22, 1899. Dr. Hurdon has just seen this patient and reports her perfectly well, nearly one year and nine months after operation.

INJURIES TO THE URETERS DURING HYSTERECTOMY

Where both ureters have been catheterized, there is little chance of wounding them, as they are easily located, being felt as firm cords skirting the pelvic wall. But not infrequently it is possible to catheterize only one ureter, and then the other may be in considerable danger, as we have seen that our line of dissection lies directly over its course. Most operators of large experience have at some time ligated the ureter. In the Johns Hopkins Hospital several have been tied, but in all the cases, with one exception, the ligated ureter was detected during the operation and liberated. In Case 1,134 the uterus was removed through the abdomen, and the patient soon died with some signs of uræmia. At autopsy the right ureter was found included in the ligature, and the urine had been dammed back, forming a hydroureter.

During vaginal or abdominal hysterectomy the ureter is occasionally nicked, and the escaping urine soon finds its way into the vagina, a uretero-vaginal fistula developing, as in case Gyn.-Path. No. 1,414 (p. 424). In other instances, the ureter may in its lower part be completely enveloped in carcinomatous tissue, and a portion of it must be resected. Again, it may be partially cut across during operation and require suturing, as in the case reported by Russell.

In Case 3,693 (p. 588), in the course of an abdominal hysterectomy, the right ureter was apparently included in the ligature. It was dissected out as far as possible, slit longitudinally, and the sound introduced. The ureter being included in the ligature, the latter was cut, but it was found impossible to pass the sound farther up. The bladder was then opened, the sound was introduced into the ureteral orifice, and passed readily up toward the kidney, showing that the ureter was patent. The openings into the ureter and bladder were closed by mattress sutures with a perfect result.

TREATMENT OF INJURED URETERS

When the ureter has been tied and its inclusion in the ligature has been detected, the proper procedure will of course be to cut the ligature. This, as a rule, is all that is necessary, the ureter having been protected to some extent by the tissue surrounding it. When it has been partially severed, the cut surfaces are to be approximated with the most delicate silk sutures, or the ureter may be cut completely in two and the lateral anastomosis made. On November 5, 1896, Russell had a very instructive case (Gyn. No. 4,682), in which the ureter was accidentally cut. Both ureters had been catheterized and a wide lateral dissection had been made. But when the right ovarian vessels were being cut, the ureter slipped between the fingers and was transversely injured, the knife severing two thirds of the calibre. The catheter was allowed to remain in until the mattress sutures had been introduced and was then pulled out through the opening. After tying the sutures, the peritoneum laterally was united, but a free opening into the vagina was left, in order to facilitate drainage should there be any leak. The gauze drain was laid from the ureter down into the vagina. The patient made a good recovery.

Van Hook, of Chicago, devised the plan of implanting the upper end of a cut ureter into the side of the lower end. This procedure he carried out successfully in the dog. The accompanying drawing (Fig. 127) shows the result of a similar operation on the dog, performed by my

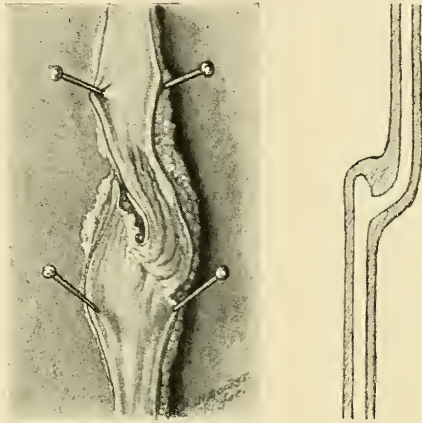


FIG. 127.—LATERAL URETERO-URETERAL ANASTOMOSIS IN THE DOG. (Natural size.)

The ureter has been laid open. The direction of the lumen and the little diverticulum above the point of anastomosis are shown in the sketch on the right. (After J. C. BLOODGOOD.)

operator took it for a vein, ligated it, and cut it in two. A sound passed down into the bladder and another up to the kidney, after cutting the ligature, at once demonstrated the error. After removing the uterus the upper end of the ureter was anastomosed into the lower portion in the following manner: The lower end was tied with silk close to its cut extremity, and then a slit, about 1 centimetre long, was made lengthwise in the ureter just below the ligature (Fig. 128, p. 247). The upper end was cut obliquely, to avoid too great contraction of its orifice, and was drawn down, by means of a fine silk traction suture, snugly into the slit so as to project into the lower end, where it was held by fine interrupted silk sutures, each of which grasped the edge of the cut and the wall of the intussusception (Fig. 129, p. 248). The loose peritoneum in the anterior part of the pelvis was now drawn over the field of operation and attached to the posterior surface of the cervical stump and the broad ligament by a continuous suture, except at the point where the ureter was united. Here two pieces of gauze were laid over the anastomosed ends and brought out at the lower angle of the abdominal wound to insure drainage of urine in case the operation was unsuccessful. There was no leakage. The drain was removed on the third day, and the patient made a perfect recovery.

If the ureter be very small and cut near the bladder, the lower end may be tied and dropped, while the upper end is to be anastomosed into the bladder. For a complete description of an operation where such a plan was carried out, see Case 2,990 (p. 286).

Where the growth involves one ureter, it will also be advisable to cut the ureter off low down, removing that portion of it with the growth and anastomosing the upper end into the bladder. If this is not done, there is great likelihood that the growth will return. Occasionally it may be necessary, on account of bilateral extension of the process, to remove the lower ends of both ureters with the growth, anastomosing their upper ends into the bladder.

In cases of uretero-vaginal fistula it may be found convenient to turn the fistulous opening into the bladder, the new viscus then consisting of the old bladder plus the portion of the vaginal vault where the fistula opened.

Gyn.-Path. No. 1,414. Case P. (p. 424) offers a most brilliant illustration of such a procedure. Shortly after the hysterectomy a uretero-vaginal fistula developed. Several weeks after the operation the abdomen was opened and the apparently constricted left ureter tied off low down and anastomosed into the bladder, as the fistula appeared to be in the left ureter. The union was not perfect, and leakage followed. Subsequent examination showed that the original fistula was in the right and not in the left ureter, although at the time of operation both Dr. Kelly and myself were positive that the trouble was on the left side. After this second operation both ureters communicated with the vaginal vault by fistulous openings (see Fig. 225, p. 428). As soon as the patient was sufficiently strong, Dr. Kelly made a plastic operation, turning the fistulous openings in the vaginal vault into the bladder (Fig. 226) with a perfect result.

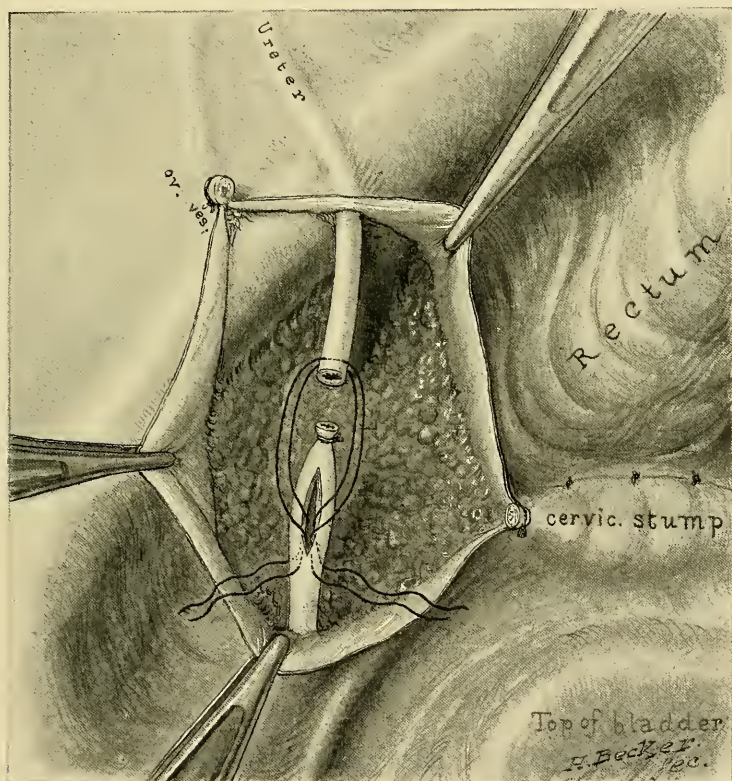


FIG. 128.—URETERO-URETERAL ANASTOMOSIS.

Showing the ureter divided, and the lower end tied and split anteriorly ready to receive the upper end, which is drawn down by two traction ligatures. (After H. A. KELLY.)

Should the ureter be injured high up, and there be no possibility of anastomosing it into the lower half or into the bladder, nothing of course remains but

to bring it out through the flank, producing a urinary fistula, or to remove the kidney. It will thus be seen that there are several methods of repairing the damage done to the ureter.

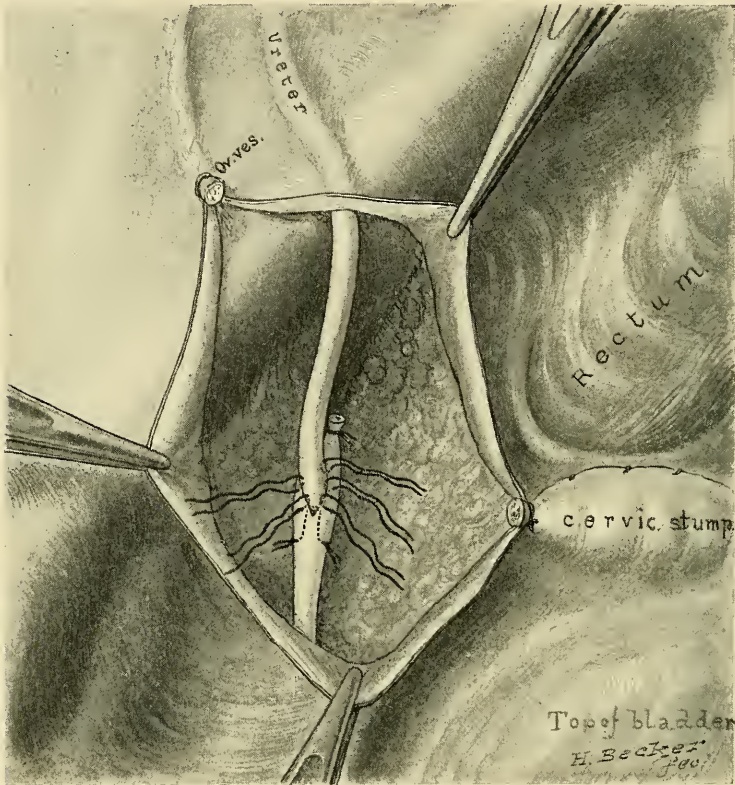


FIG. 129.—URETERO-URETERAL ANASTOMOSIS.

Showing the ureter held in place by traction ligatures which have been tied. The five untied sutures will unite the entering ureter to the cut edges of the lower portion of the ureter. (After H. A. KELLY.)

1. End-to-end anastomosis, when the ureter has been partially or completely severed.
2. Lateral anastomosis, which is always to be preferred where expedient.
3. Anastomosis into the bladder.
4. Turning the fistulous opening into the bladder.
5. Bringing the ureter out laterally, establishing a urinary fistula.

CAUSES OF DEATH FOLLOWING ABDOMINAL HYSTERECTOMY

1. Infection.
2. Ligation of a ureter.

The reader will often have noted, in the pathological descriptions of the accompanying histories, that, notwithstanding the scrupulous measures adopted to remove all necrotic and sloughing tissue prior to the radical operation, a cer-

tain amount is invariably left, and also that in numerous instances small abscesses are situated deep down in the tissue, which are only brought to light by the tearing of the uterus during its removal. As might be anticipated, pelvic peritonitis, or occasionally general peritonitis, develops, and the patient dies. Of our patients operated upon for carcinoma of the cervix, Cases 2,928 (p. 272), 2,405 (p. 79), 4,430 (p. 250), and 4,038 (p. 108) died with signs of infection. In Case 2,928 the patient's condition was good until the third day, when the vaginal pack was removed (combined abdominal and vaginal operation). On the fourth day there occurred several small liquid movements, with nausea, restlessness, and a pulse of 120. On the eighth day the tongue was dry, the skin hot, and there were twitchings; the patient slept heavily, and wandered considerably. On the ninth day there were involuntary movements, soon followed by death.

Case 2,405 had nausea and vomiting immediately after operation, and on the second day was drowsy, but complained of considerable pain. On the third day the nausea continued, and there were involuntary evacuations from the bowels and bladder. She died early on the fourth day. In Case 4,430, on the day of operation, there was shortness of breath and a pulse of 132. On the second day the temperature reached 102° in the morning and 104° at night; the respirations increased to 40. The patient gradually grew weaker, and died on the tenth day. At autopsy there was a moderate amount of pus in the pelvis. Case 3,609 had nausea, vomited a greenish fluid, and complained of abdominal pain. On the third day the temperature rose to 105.6° in the evening, and the pulse to 160. She died early on the fourth day.

In the above cases, nausea, vomiting, abdominal pain, a gradual rise of temperature, and a high pulse-rate were the chief symptoms, death occurring between the fourth and the tenth days.

Ligation of a Ureter.—Under such circumstances the patient may recover, but if she be rather old, the strain of the operation, together with the sudden disuse of one kidney, are liable to be followed by death. Should she be able to preserve her forces for two or three weeks a uretero-vaginal fistula may form, as the urine will instinctively work its way through along the track of the recent operation. In Case 1,134, where one ureter was found tied at autopsy, the patient died several days after operation, with signs of uræmia. Of course, where both ureters are occluded, as in a case reported by Binswanger, the patient will soon die with signs of uræmia.

A Case in which Death was due to Accidental Ligation of a Ureter during Abdominal Hysterectomy

Gyn. No. 1,134

Autopsy No. 273. February 3, 1892. The uterus had been removed *per abdomen* for carcinoma of cervix. At autopsy, inclusion of the right ureter in a ligature was found. There were remains of a carcinomatous growth in the pelvis. There was endarteritis of the aorta with thrombosis, and, as might have been expected, hydronephrosis on the right side.

*Examples of Cases in which the Abdominal Operation had to be Abandoned***Gyn. No. 4,430**

Squamous-cell carcinoma of the cervix; extension to the right broad ligament; impossible to catheterize the ureter on this side; very difficult abdominal hysterectomy. Death on the eleventh day with signs of peritonitis. Autopsy showed acute peritonitis; double lobar pneumonia; acute pleurisy; acute haemorrhagic cystitis and intracapillary glomerulitis.

C., aged forty-two; white. Admitted June 5, 1896. Complaint: a bloody vaginal discharge; aching and burning in the lower abdomen.

The patient has been married twenty years, and has had four children and one miscarriage. Her menses commenced at thirteen, and have been comparatively regular, but during the present spring she missed a period, and has complained of dull aching pain in the lower abdomen. The last period occurred one week ago. For over a year there has been a moderate yellowish-white leucorrhœal discharge, which during the last three months has been tinged with blood. In January, 1896, she had her first hæmorrhage. Since then they have come on with increasing frequency, lasting two or three days, and usually occurring once or twice a week. She thinks that with each hæmorrhage there is a loss of about half a cupful of blood. Since October, 1895, there has been an aching and burning sensation in the lower abdomen; this was at first intermittent, but is now continuous, and involves the entire lower abdomen. Her family history is negative and her own previous history good. The patient has lost some flesh, but is still fairly well nourished; her appetite is poor; the bowels are regular.

The cervix presents a ragged appearance immediately suggesting carcinoma. Even slight examination occasions considerable local pain.

Operation, June 8th. Abdominal hysterectomy. The pulse throughout the operation was very rapid. A bougie was introduced into the left ureter, but the right could only be catheterized for a distance of 3 or 4 centimetres. The cervix was curetted and the abdomen then opened. Enucleation was made from left to right, but proved to be very difficult owing to the dense adhesions, and to the fact that the right ureter could not be well outlined, not having been catheterized. On account of the rapid and weak pulse, salt solution was infused under each breast; a considerable quantity was left in the abdomen, and was also given as a rectal injection. On the following day, about 5 A. M., she awoke complaining of intense thirst, nausea, and shortness of breath; the pulse was 132, the temperature 102.4°. Shortly afterward a stimulating enema was given, and 500 cubic centimetres of salt solution were infused under the right breast. By 6 P. M. the temperature was 104°, pulse 142, respirations 40, while the nausea and vomiting had reappeared at intervals throughout the day. During the night she was very restless; the temperature had dropped slightly, but the pulse was still rapid and the respirations remained about the same. This condition continued until the 11th, when she complained of a great deal of pain in the left side

and coughed considerably. The patient gradually grew weaker, and died on June 18, 1896.

Gyn.-Path. No. 1,211. The specimen consists of the uterus with its appendages. It is everywhere covered by dense vascular adhesions. The cervical lips are somewhat thickened and markedly hæmorrhagic; the vaginal portion of the anterior lip, which has been curetted, presents a raw surface. On opening the uterus, the mucosa of the cervix is seen to be gathered up into folds, which on the anterior lip form distinct polypi. The uterine cavity is 5 centimetres in length, and its mucosa varies from 1 to 3 millimetres in thickness. Throughout it is hæmorrhagic, and in some places is gathered up into small polypi. The appendages are covered by vascular adhesions and are considerably mutilated.

On histological examination, typical epithelial nests are found scattered throughout the superficial portions of the stroma of the anterior cervical lip. They are not very abundant, but the stroma surrounding them shows marked small-round-cell infiltration. The growth is a very early one, and gives the characteristic appearance of squamous-cell carcinoma. The cervical glands are normal; the uterine mucosa, save for hæmorrhage in the superficial portions, is unaltered. The appendages, apart from being covered by adhesions, are normal.

Autopsy No. 812. Anatomical diagnosis: Infection of the external abdominal wound and pelvic cavity at the site of the operation. Acute peritonitis. Double lobar pneumonia. Acute pleurisy. Acute hæmorrhagic cystitis. Adenoma of the thyroid. Adenoma of the liver. Slight chronic nephritis. Intracapillary glomerulitis. Acute splenic tumour.

Abstract from the autopsy report: The body is well nourished; the abdomen is moderately distended, and commencing 6 centimetres below the umbilicus is a linear incision covered by silver foil and united with silkworm-gut sutures. The edges of the incision are easily separated; the whole tract is covered with grayish tenacious pus. The peritoneal cavity is closed off from this by independent sutures. The loops of small intestine in the pelvis are somewhat injected, but their serous covering is not at all clouded. In the cul-de-sac between the rectum and bladder is an accumulation of thick yellow pus.

Pus from the abdominal wound contains many encapsulated diplococci; these are also found in the pus from the pelvis and in the lung. Dr. Flexner came to the conclusion that they were probably pneumococci.

Gyn. No. 2,695

Squamous-cell carcinoma of the cervix; extension to the broad ligaments; attempted abdominal hysterectomy; ligation of the uterine arteries and veins.

B. M., aged thirty-one; white. Admitted April 4, 1894. Complaint: pain in the uterus; continuous uterine hæmorrhage. The patient has never been pregnant. Her family history is good, and previously she has always been well. Her menses heretofore have been regular.

About four months ago she commenced to have a great deal of pain in the uterus, and noticed that she was losing much blood at each menstrual period. In a short time the bloody discharge became constant. The patient is a large, well-

nourished woman; the mucous membranes are of a good colour; the appetite is good; the bowels are regular; defecation is somewhat painful.

The cervix has been invaded by a new growth, and is now represented by a mere shell.

Operation, April 7th. Attempted abdominal hysterectomy. The patient was placed in the Trendelenburg posture, and, after the abdominal incision had been made, the peritoneum on either side was attached to the skin to facilitate exposure of the pelvic viscera.

The appendages on both sides were enucleated from dense adhesions and removed; the uterine arteries and veins on either side were ligated; but the operation had now to be abandoned, as the carcinomatous mass had extended so far laterally. On April 17th the abdominal stitches were removed and the union was found to be perfect.

From the 19th to the 24th there was some vesical irritation. On her departure from the hospital the growth in the cervix presented the same appearance as when she entered.

Gyn.-Path. No. 244. The specimen consists of 300 cubic centimetres of a grayish-white crumbling material, the pieces of which vary from minute particles to some measuring $.8 \times 3$ centimetres. Some portions appear slightly pedunculated, being not unlike small pieces of a cauliflower. On section, the tissue is waxy white and presents a somewhat striated appearance, while scattered here and there throughout it are minute yellow dots. The tubes and ovaries are too much mutilated for description.

Histological Examination.—The crumbly cauliflower-like masses are composed of alveoli, which are filled with cells having large, oval, vesicular nuclei. The alveoli are oval, round, cylindrical, or may branch in any direction. Between the individual cells are a moderate number of polymorphonuclear leucocytes. The stroma between the alveoli is very scant, and shows considerable small-round-cell infiltration.

Apart from being covered by adhesions, the tubal and ovarian structures, so far as they can be examined, are normal.

Diagnosis.—Squamous-cell carcinoma of the cervix.

Gyn. No. 3,322

Squamous-cell carcinoma of the cervix(?); extension to the vagina; combined abdominal and vaginal hysterectomy; only partial removal of the growth. Death, eighteen months after operation.

A. K., aged forty-three; white. Admitted February 11, 1895. Complaint: abdominal distention; frequent uterine hæmorrhages.

The patient has been married twenty-three years, and has had nine children. All the labours were difficult, the last being instrumental. Her menses commenced at eleven and were always regular, the last period occurring three weeks ago. Her family history is negative, and her previous history unimportant.

After the birth of her child, four months ago, her abdomen did not decrease as much in size as she thought it should; four weeks after the child was born her menstrual flow reappeared.

At irregular intervals she has had profuse uterine hæmorrhages, which are particularly severe after any exertion. She suffers considerably with pain in the right hypochondriac region when in the recumbent position, and in walking has pain in the right leg.

The patient is well nourished; her appetite is fair; the bowels are regular; at present there is no vaginal discharge. The cervix is replaced by a granulating mass, which involves the vaginal wall over an area 2.5×3 centimetres.

Operation, March 2, 1895. Abdominal hysterectomy. It was found impossible to enucleate all the diseased vaginal tissue, working from above, and the operator intimated that in the next case he would commence enucleation through the vagina. Abdominal and vaginal drainage was used. Several days after the operation the diseased tissue which still remained in the vagina was thoroughly cauterized. The patient was discharged April 7th, feeling very well; there was some doubt, however, as to whether the disease had been entirely eradicated.

The patient was readmitted January 20, 1896. She had experienced great relief after the operation, and not until three months ago was there much return of the pain. In October, 1895, the bloody vaginal discharge reappeared, and since then there have been frequent slight hæmorrhages. Eleven days ago she lost a pint of blood. The patient has gained in weight since the operation, is well nourished, and of a good colour. Her appetite is good; her bowels are regular. On vaginal examination there is found to be a return of the growth over an area 2×2.5 centimetres, and there is some thickening on the left side.

On January 27th the upper part of the vaginal vault was ringed, and an attempt made to dissect away the carcinomatous tissue, but on account of the extensive involvement of the parts the operation had to be abandoned. The incision was closed with catgut sutures. The patient promptly recovered, and was discharged February 16, 1896.

Dr. N. D. Baker, of Martinsburg, W. Va., writes me that the patient had a return of the growth about twelve months after operation. The disease appeared in the bladder and vagina, and death, which took place eighteen months after operation, was directly due to hæmorrhages.

VAGINAL HYSTERECTOMY

This operation has been so clearly described in all its details by Dr. Kelly that I will give his description almost verbatim. In all cases in which there is any breaking down of the tissue, it is, of course, necessary to curette and remove the carcinomatous tissue as far as possible several days previous to the radical operation; otherwise there will in all likelihood be an infection from the offensive, foul-smelling discharge so common in these cases.

Operation.—The patient is brought to the edge of the table in the lithotomy position, with the limbs well flexed and the buttocks resting on a perineal pad. The assistant then shaves the external genitals, washing them well, together with the vagina. The posterior vaginal wall is then retracted with a large Sims or Simon speculum, exposing the vault of the vagina and the cervix. If the vagi-

nal outlet is narrow, hindering a view of the cervix, a greater degree of dilatation may be secured by boring in the hand with the tips of the fingers held together,

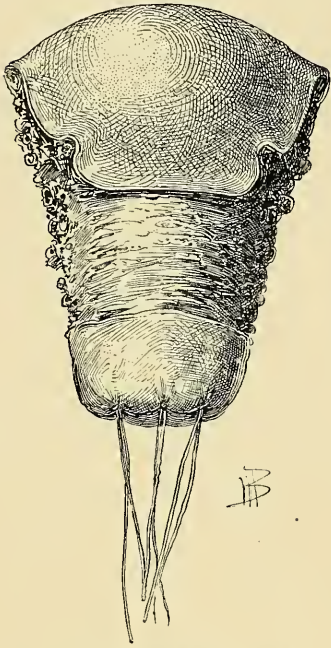


FIG. 130.—UTERUS ENUCLEATED
PER VAGINAM.

The tubes and ovaries and broad ligaments have been left behind. To appreciate the decided advantages offered by an abdominal hysterectomy, see Fig. 45. (After J. G. CLARK.)

down near the outlet, and to keep pulling it farther and farther down, delivering it gradually as its attachments are severed. The cervix is first drawn toward the vaginal vault as far as it will come, often outside; the assistant on either side holds back the lateral vaginal walls with the retractor, so as to prevent them from hiding the field of operation. The operator, pulling on the traction sutures, now makes a circular incision around the cervix and through the entire thickness of the vaginal vault not less than 2 centimetres ($\frac{3}{4}$ inch) beyond the margin of the disease. Moderate bleeding may be disregarded until the close of the operation. Profuse bleeding should be controlled at once by ligatures passed through the vaginal walls so as to grasp the vessels.

making a conical dilator; or, better still, by using a conical rectal dilator. If the rigidity cannot be overcome in this way, one or two deep lateral incisions through the posterior commissure, extending around one or both sides of the rectum and up into the vaginal sulci, will give the necessary enlargement.* The hæmorrhage from the surfaces thus incised is rarely severe enough to call for the use of forceps or ligatures. Continuous irrigation is used to keep the field clear of blood during the first part of the operation, until the peritoneum is opened. The vault of the vagina and the cervix being exposed, as described, the anterior lip of the cervix is caught by tenaculum forceps and drawn out. The posterior lip is also caught, and a stout needle is passed through the anterior and posterior lips, carrying a heavy silk ligature about 40 centimetres (16 inches) long. Three or four of these ligatures are passed, and each one is tied tightly, drawing the lips firmly together, completely closing the cervical canal, and covering the diseased area, to prevent the escape of any of the intrauterine contents over the wound surface during the enucleation; the ligatures are left long, to serve as tractors and enable the operator to hold the uterus



FIG. 131.—THREE SIZES
OF SILK USED.

Fine, intermediate, and heavy.

* One must hesitate, however, in making an incision in the perinæum, remembering that several cases of implantation and secondary growth are apparently attributable to portions of the carcinomatous growth having become lodged in such wounds.

The knife or scissors are now laid aside, and the operator begins to push up and pull back the cellular tissue from its attachments in front and behind the cervix with the index and middle fingers. There is usually no resistance, and rarely any serious hæmorrhage, for the important blood-vessels lie in the broad ligaments at the sides. Care must be taken, in pushing it back and freeing it, to keep the ball of the finger always directed toward the cervix. If the separation is carelessly performed and this precaution neglected, there is danger of

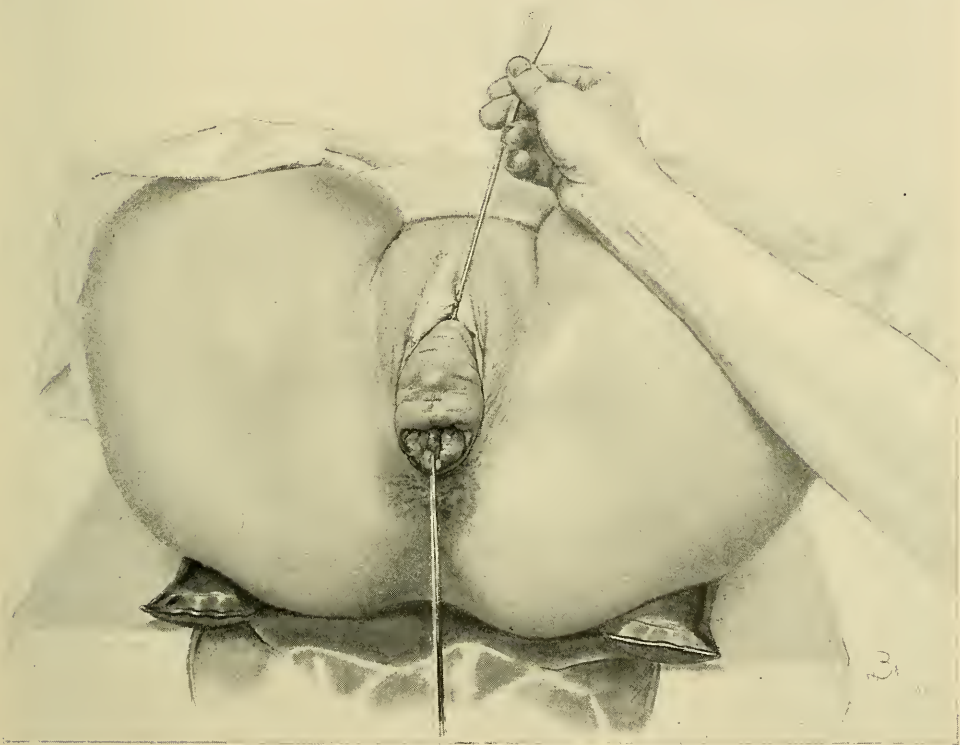


FIG. 132.—PARTIAL PROLAPSE OF THE UTERUS AND VAGINA WITH AN ELONGATED AND LACERATED CERVIX.

The sound is introduced into the bladder to show the altered direction of the urethra and the vesical diverticulum in the sac. The light spot plainly shows the position of the end of the sound in the bladder. This picture demonstrates well the ease with which the bladder may be opened in vaginal hysterectomy, unless much care is exercised. (After H. A. KELLY.)

perforating the bladder or entering the peritoneum, especially when the disease has extended in either of these directions. As soon as the peritoneum behind the uterus is reached, the fact is readily recognised by the fluctuation of a little fluid in Douglas's cul-de-sac, or by the smooth anterior and posterior surfaces gliding over each other. It is opened by catching a fold of it with forceps and making a small cut into it with scissors. One index finger is then thrust in, enlarging the opening, and then the other index finger is introduced, tearing the

incision as wide as possible from side to side, well out to the bases of the broad ligament. As soon as the peritoneum is laid open the irrigation must cease. A

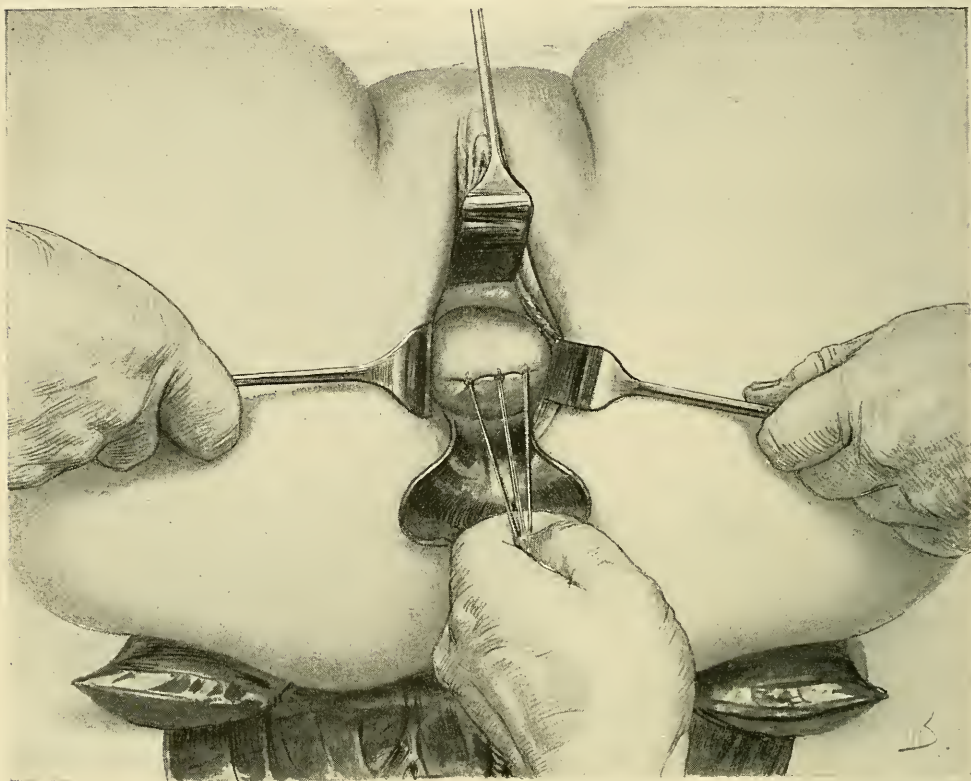


FIG. 133.—VAGINAL HYSTERECTOMY.

The uterus and cervix have been thoroughly curetted. The cervix has been sewed up with stout silk ligatures left long for traction. The field of operation is exposed by retractors. (After H. A. KELLY.)

sterilized sponge or pledget of gauze, with a string attached to it, is now pushed into Douglas's cul-de-sac, to prevent the entrance of fluids or the escape of *débris* from the field of operation up into the peritoneal cavity. A pair of artery forceps clamped on the ends of the string distinguishes it at once from the ligatures applied to the broad ligaments. The anterior vesico-uterine fold of peritoneum is next reached in like manner after completely detaching the bladder from its uterine connections. It is also recognised by the gliding of its peritoneal surfaces over each other. An opening is made by pushing in a pair of sharp-pointed scissors under the guidance of the index finger, spreading the handles, and withdrawing them. The index fingers are then introduced, as just described, and the hole is enlarged out to the broad ligaments on either side. This leaves the uterus hanging in the pelvis, attached by the broad ligaments. The anterior peritoneal fold may sometimes be more readily reached after the lower parts of the broad ligaments have been ligated and severed from the cervix, permitting a greater downward displacement of the uterus, and making this part of the peritoneum

more accessible. The accident of pushing the finger through the bladder wall will be avoided by frequently introducing a sound into the bladder, as the operation progresses, to determine its exact position and the thickness of the intervening tissue. An accidental rent in the viscus at once reveals itself by a sudden gush of urine into the vagina. This is most apt to occur when the disease has progressed through the cervix into the bladder. A fistula made in this way should be closed, after paring the edges to remove the diseased tissue, with interrupted silk sutures, when the enucleation of the uterus is completed. If this operation is performed immediately, it is usually successful. The next step in the enucleation is to tie off the broad ligaments with stout silk sutures introduced with a strongly curved blunt aneurismal needle. In introducing the first ligature, say on the right side, the cervix is drawn strongly to the left, and the right vaginal wall held out of the way with a retractor. The left index finger is placed outside the cervix behind the broad ligament, and the aneurismal needle armed with the liga-

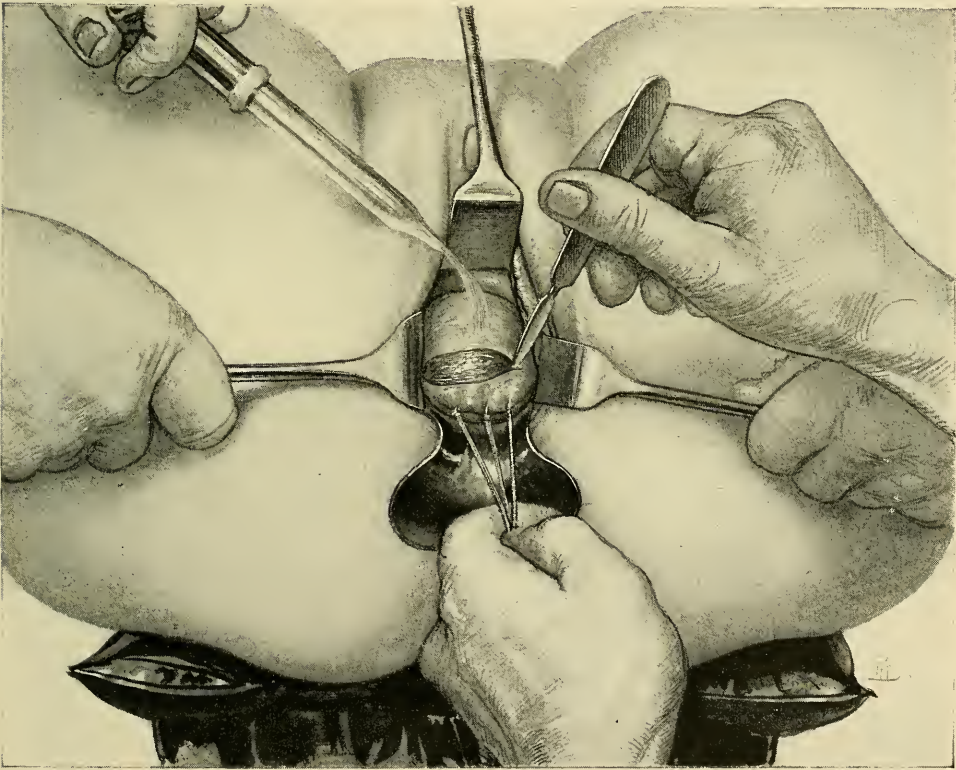


FIG. 134.—VAGINAL HYSTERECTOMY.

The operation is begun by cutting the cervix loose from the vaginal vault under continuous irrigation. (After H. A. KELLY.)

ture is passed through from before backward on the tip of the finger. This ligature, including a bunch of tissue about 1 centimetre in diameter, is entered about 1 centimetre distant from the cervix and is directed outward toward the pelvic

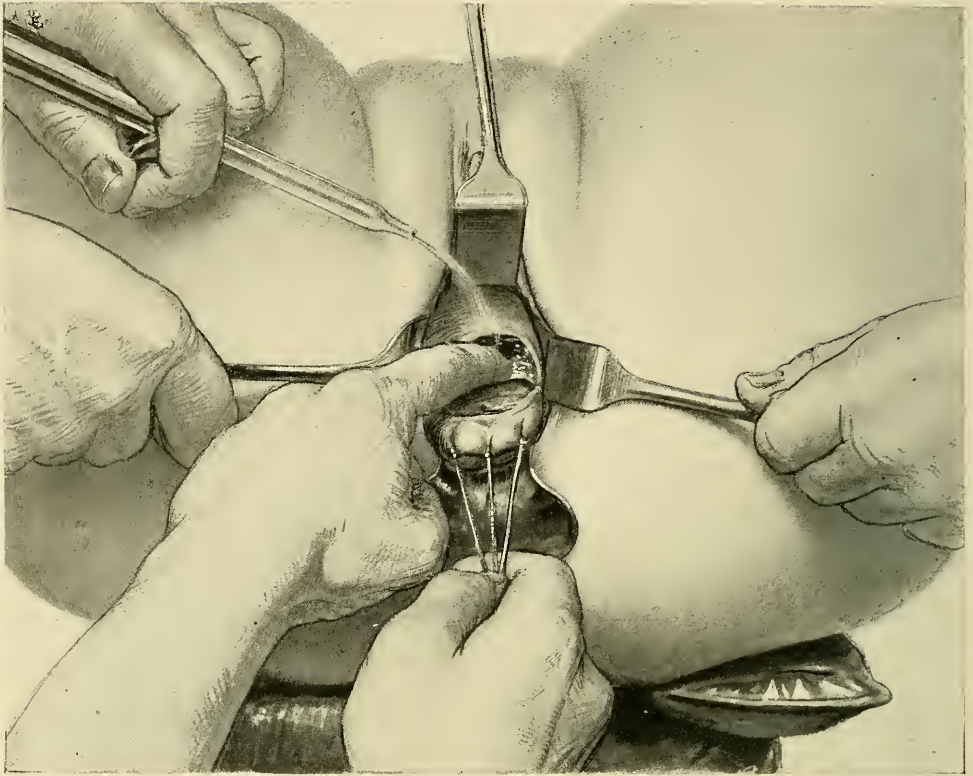


FIG. 135.—VAGINAL HYSTERECTOMY.

The finger is engaged in pushing up the bladder, detaching it from the cervix. (After H. A. KELLY.)

wall. The loop of the ligature is caught with a blunt tenaculum, pulled out, and the needle is withdrawn. The ligature is tied at once as tightly as possible and

drawn aside, and the broad ligament is divided between the ligature and uterus, nearer the latter. All cutting is done with scissors, and the tissues of the broad ligament are carefully snipped as they are drawn forward on the index finger. As soon as a little oozing of blood is seen to follow a cut, we know that an area of tissue is uncontrolled, and another ligature must be inserted in a similar manner just above the last. The assistant must use the retractor with care, so as not to pull on the ligatures already tied. After introducing two or three ligatures in this way, one above the other, the cervix is drawn to the opposite wall and the base of the left broad ligament ligated and severed in like manner.



FIG. 136.—BLUNT ANEURISMAL NEEDLE WITH LEFT CURVE.

For passing ligatures through the broad ligaments in vaginal hysterectomy.

An extensively infiltrated cervix occupies a considerable space in the narrow pelvis, and in consequence lies in close contact with the ureters. In all cases it is advisable that both ureters should be catheterized. Their exact positions are thus constantly evident to the fingers throughout the enucleation, so that injury to them

is avoided with ease and certainty. In one patient, after removing a large cancerous uterus, Kelly found a separate mass in the left broad ligament, which he proceeded to enucleate with forceps and scissors, dissecting it off the ureter, which was bared for 7.5 centimetres (3 inches) without injury, it being plainly defined the whole time by a bougie 2.5 millimetres in diameter. Moderate traction upon the ligature, when tied, will assist in exposing the area to be divided by the scissors; but as soon as the division is effected all traction must cease at once, lest the ligatures be pulled off. The uterine artery should be included in the second or third ligature applied. As soon as the peritoneum is opened, the index finger will find the artery pulsating outside the cervix near the internal os. Its exact position, once fixed, serves as a guide in estimating the amount of tissue to be included in the ligatures in order to catch it in the second or third.

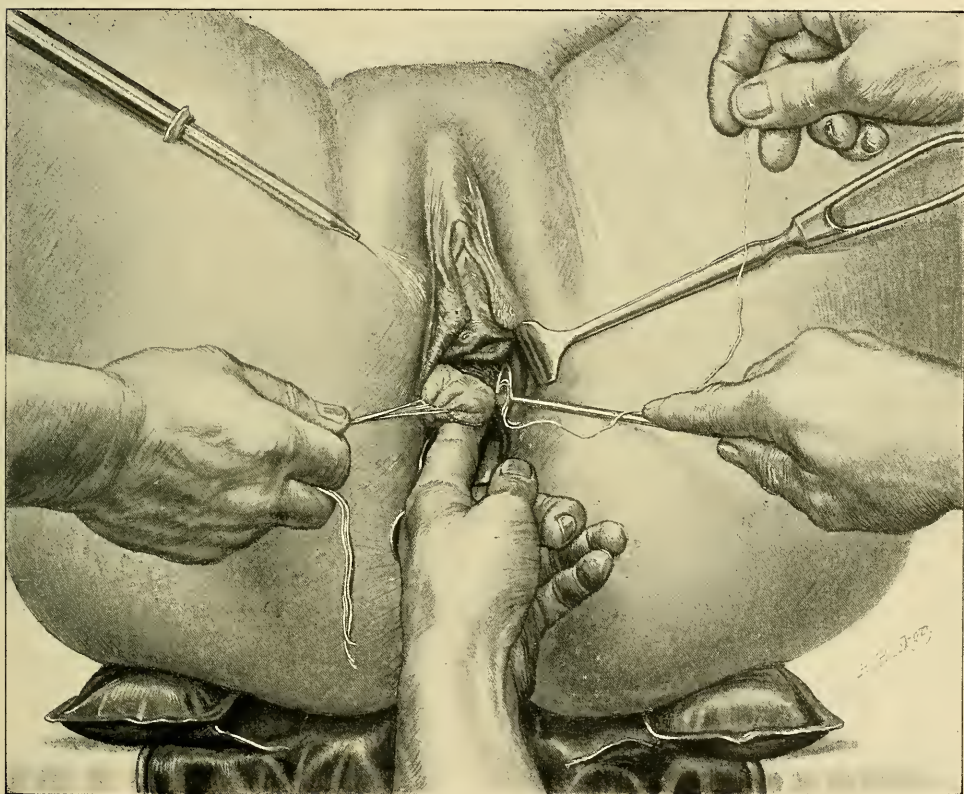


FIG. 137.—VAGINAL HYSTERECTOMY.

After freeing the bladder in front and opening the cul-de-sac behind, the base of the left broad ligament is exposed by pulling the cervix to the right, and is tied off by stout silk ligatures passed by means of an aneurismal needle. (After H. A. KELLY.)

The artery, when laid bare, is easily distinguishable as a large, white, tortuous trunk with a lumen 2 to 3 millimetres in diameter, strongly pulsating on its proximal side. As soon as the uterine vessels on one side have been secured and severed from the uterus, the operator continues to tie off the remainder

of the broad ligament on that side. When near the top of the broad ligament the finger is passed over the tube close to the uterine cornu, which is hooked down into view and tied. If the cancer affects the body of the uterus, or if a pyosalpinx or some other pelvic inflammatory disease is also present, the ligature should be placed on the outer pelvic side of the ovaries and tubes, which



FIG. 138. — END OF THE STOUT BLUNT TENACULUM.

Used in catching the ligature and drawing it down in vaginal hysterectomy.

are removed together with the uterus. It is more difficult to complete the operation in this way with the removal of the ovaries and tubes, because the ligatures placed nearer to the pelvic wall are not so easily tied and are more apt to slip off. The ligature at the top of the broad ligament must be tied with especial care, and the tissue caught at a distance from it to avoid the risk of its slipping off. As soon as the whole of the right side of the uterus is free, two fingers are inserted, the fundus is caught from behind, and the body of the uterus slowly and carefully delivered sidewise through the opening in the vaginal vault, down through the vagina and out into the vulvar cleft, where it hangs attached by the upper part of the left broad ligament. The enucleation is now completed by tying off the opposite side from above downward with two or more ligatures. It is possible, by removing the uterus in this way from

above downward, to apply the ligatures at a safe distance from the side which is most diseased. For this reason, in cases of advanced disease, it is best not to apply more than a single ligature below on the worse side. As soon as the uterus has been removed, the operator takes the sponge from the pelvis and separates the ligatures into right and left groups, holding them without traction, while an assistant pours sterilized normal salt solution (43.3° C., 110° F.) into the vagina and cleanses the lower pelvis with a sponge held in the forceps. The irrigation is continued until the water returns perfectly clear. If any omentum or a loop of intestine fall into the vagina it must be carefully pushed back. While washing out the lower pelvis the surgeon must thoroughly inspect the peritoneum, in order to discover and remove any coagula lodging there.

The next step is the investigation of the condition of all the ligatures and a search for bleeding points. A slight traction on the upper ligatures, aided by a sponge pushed into the peritoneum and then partially withdrawn, brings the broad ligament forward and exposes first one and then another. Any ligature which seems loose must at once be replaced by transfixing the broad ligament at that point. A few small silk sutures are usually required to control small vessels under the first ligatures just below the base of both broad ligaments. A persistent flow from a hæmorrhoidal vessel in the rectal vaginal septum must also be controlled by a ligature placed beneath the bleeding point. The wound area underlying the base of the bladder rarely bleeds. The ligatures on either side are now tied in two bunches, and the ends are caught off just within the vagina. As a final step the pelvis is dried with a small sponge, and a dressing, consisting of strips of iodoform or sterilized gauze, 45 centimetres (18 inches) long by 5 centimetres (2 inches) in breadth, is applied. To insert the gauze, the operator, taking the packer, pushes a strip in between the ligatures until the whole space between the broad ligaments is loosely filled out. The vagina below is also packed

with gauze somewhat firmly to prevent the intestines from escaping in this direction. This packing of gauze supports the small intestines, omentum, rectum, and bladder, and drains off any fluid into the vagina. Too tight a pack does not drain well. Too loose a pack, on the other hand, favours prolapse of the bowel into the vagina. Kelly once lost a patient from peritonitis, because a loose pack had allowed a knuckle of intestine to come down and become infected. It is a good plan to unite the peritoneum in the middle by one or two sutures, thus leav-

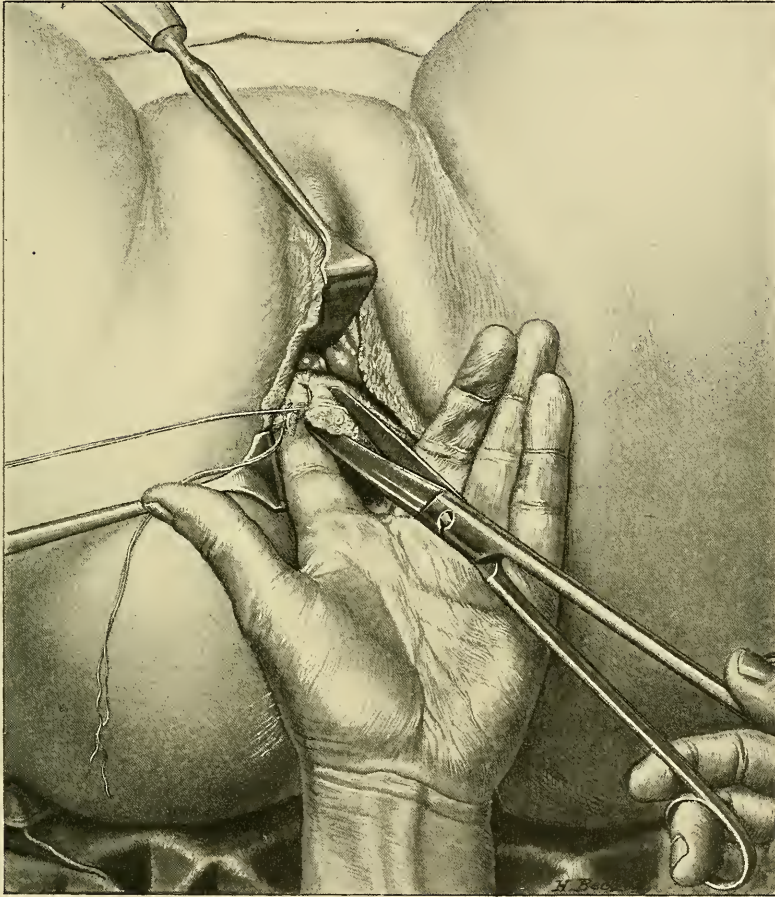


FIG. 139.—VAGINAL HYSTERECTOMY.

The uterus is being freed from the right broad ligament. The cervix lies to the left. The first ligature to the base of the broad ligament has been tied and hangs loose. The second ligature, including the uterine artery, has been tied a short distance above the first. The scissors are just about to divide the broad ligament between the ligature and the right border of the uterus. (After H. A. KELLY.)

ing a little opening on either side for drainage, supporting the intestines, and lessening the liability to prolapse. The urine is now drawn, and, if clear, conveys the assurance that the bladder has not been injured. Bloody urine may indicate an injury to the bladder or ureter. A roll of sterilized absorbent cotton is applied over the vulva and held in place by a T bandage.

After-treatment.—When the effects of the anæsthetic have worn off, it is not necessary to keep the patient on her back. She will be greatly relieved from time to time by being gently turned over on one side or the other. After a

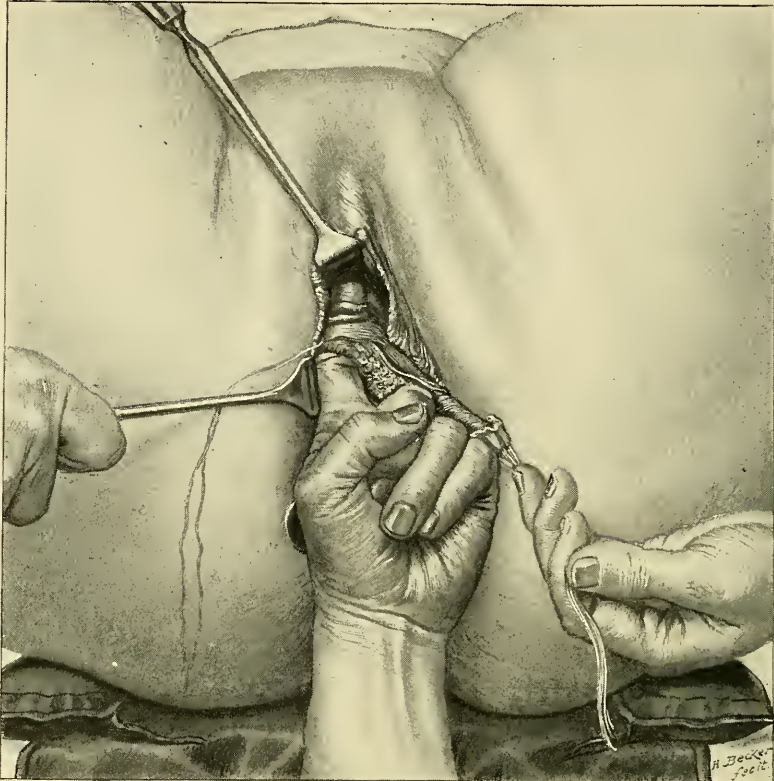


FIG. 140.—VAGINAL HYSTERECTOMY.

The cervix and uterus are pulled well over to the left. The right broad ligament has been tied all the way up to the top, which will be tied next. The index finger is hooked behind the top of the broad ligament, pulling it down into view for the application of the last ligature. The round ligament and the tube are seen at their uterine ends. (After H. A. KELLY.)

few days she may turn on her face and urinate in that posture. At first the catheter should be used three or four times daily. The bowels should be moved on the third day by a laxative, followed by a warm enema of oil and soap-suds or of glycerine (1 ounce) and oil (6 ounces). During evacuation all straining must be avoided. If the fecal matter does not easily pass out, the nurse must assist it with the finger. There must be a movement every day. During convalescence the diet for the first two or three days should consist of liquids, followed by soft foods, nourishing soups, toast, soft-boiled eggs, and various starchy foods. Pain following an operation is often entirely absent and is rarely unbearable. Hypodermics of morphine should be used sparingly, and only to relieve severe pain during the first twenty-four hours. If there is no discharge from the vagina and the pack continues dry, it may be left for five days or longer. To remove the pack,

the patient is brought with the buttocks to the edge of the bed, and the thighs flexed. The operator slips a narrow Simon speculum into the vagina, retracting the posterior wall, and with dressing forceps draws the strips of gauze out from between the ligatures. As soon as the strips are removed the vaginal vault must be cleansed with pledgets of absorbent cotton and a fresh pack inserted. No vaginal douche of any kind should be used until two weeks have passed, when a 3-per-cent warm carbolized injection, or one of boric-acid solution, may be given once or twice daily. A short nozzle should be used, and great care should be taken not to push it too far in. When silk ligatures are used, the discharge is sure to become odorous sooner or later, and the vagina must be cleansed more frequently. The ligatures loosen and come away with a little traction, in bunches, in from four to six weeks. It is a good plan not to wait until they

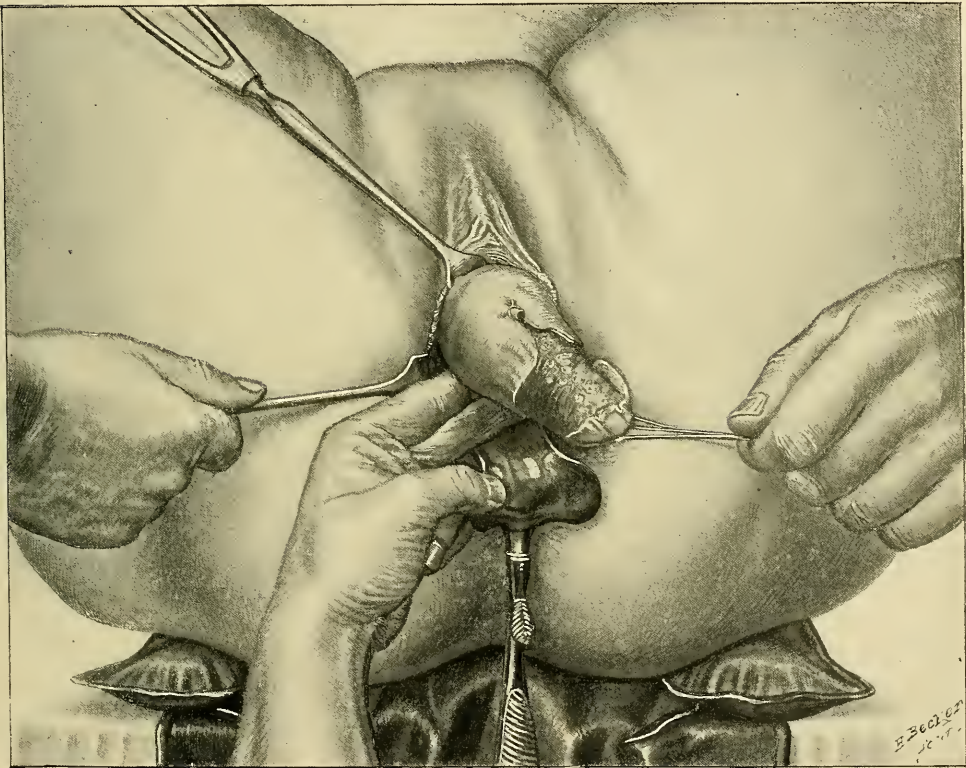


FIG. 141.—VAGINAL HYSTERECTOMY.

The uterus is entirely freed on the right side, and is being brought out of the vulva. The remainder of the left broad ligament is now tied from above downward. (After H. A. KELLY.)

become detached, but in the course of three weeks to expose and remove them with forceps and scissors. This procedure can best be carried out with the patient in the knee-breast or the Sims posture.

In eighteen days the patient may sit in a reclining chair a little while each day, and gradually increase the time, until at the end of four weeks she will be

able to be up all day. An examination will now show that the vaginal vault is closed, and the wound area has contracted down to a transverse granulating linear scar, with the granulations more abundant at each end. After six or eight months this whole line is contracted still more, until only a thin white cicatrix remains, closing the vault. After a hysterectomy the patient should avoid hard work, heavy lifting, and prolonged exertion for several months. Recovery of

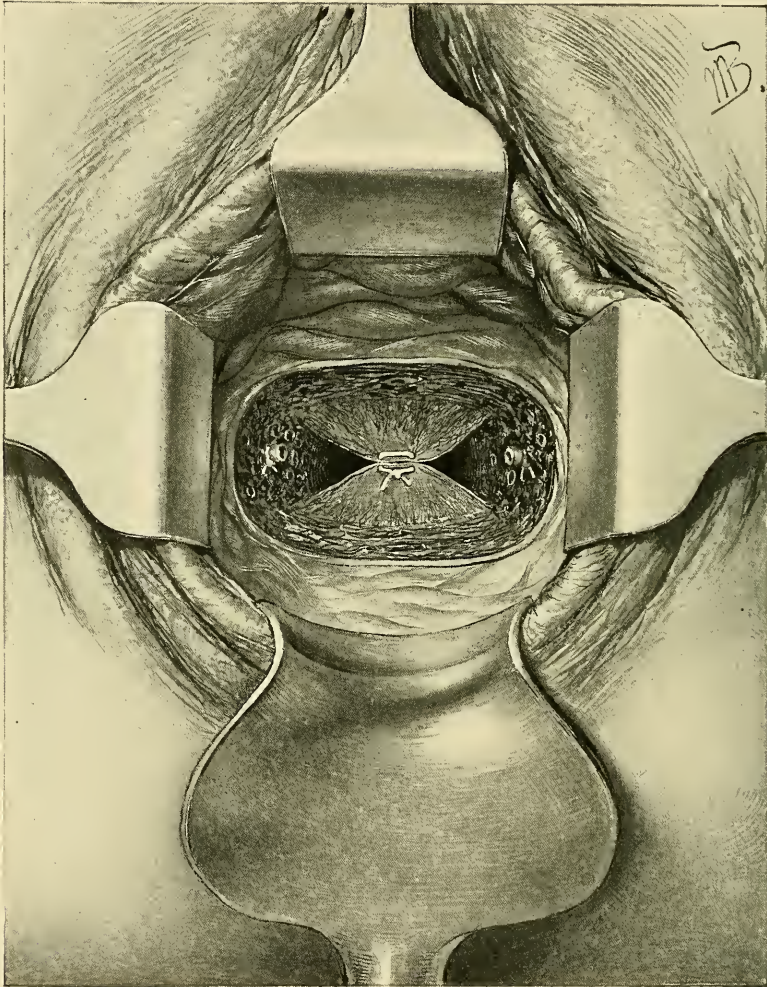


FIG. 142.—VAGINAL HYSTERECTOMY.

The uterus has been removed. The ligatures on the uterine arteries are seen on either side. The anterior and posterior peritoneal layers are brought together in the middle line by one suture. The long ligatures on the broad ligaments are omitted in this picture. (After H. A. KELLY.)

health is usually rapid. Within a few months a pale, emaciated woman often regains all her lost vigour. But the surgeon still has a duty to perform in continuing to watch these cases, examining them at first at intervals of two or three months, and later every six months, in order to detect at once any recurrence of

the disease. It will occasionally be necessary to cut out a small area in the vaginal vault, when an early return of the growth has taken place. In two instances in which the uterus was enucleated without removing the tubes or ovaries, Kelly found at a later date the vault of the vagina occupied by dark-red fungus-like masses, which at first sight suggested a rapid return of the disease. On removing them, however, they proved to be the inverted and congested Fallopian tubes which were projecting through the vaginal vault.

INJURY TO THE BLADDER DURING VAGINAL HYSTERECTOMY

This accident is not likely to occur if the uterus be carefully dissected off from the base of the bladder, but occasionally a small opening is made into the viscus. If the aperture be noticed at once, several catgut sutures are applied and the rent is closed, as in Case 2,591; often, however, it remains unrecognised until the following day, when dribbling of urine appears. As soon as the patient's health has been restored, the small fistulous opening may be closed in the usual way (see Case 3,595, p. 82). Case 5,327 (p. 268), three years before she came to the hospital, had had a vaginal hysterectomy performed in a neighbouring State on account of carcinoma. When we saw her, in June, 1897, there was a passage fully 1.5 centimetres in diameter between the bladder and vagina, and also a fistulous opening into the rectum. This condition had persisted since the operation, and was no doubt due to the fact that portions of both the bladder and rectum had been removed with the uterus.

Cases illustrating Injury of the Bladder during Vaginal Hysterectomy

Gyn. No. 2,591

Squamous-cell carcinoma of the cervix with a cauliflower growth (Figs. 143 and 144). Vaginal hysterectomy; accidental rent in the bladder closed by six catgut sutures. Local recurrence; death three and a half months after operation.

N. C. J., aged forty-nine; white. Admitted February 14, 1894. Complaint: frequent uterine hæmorrhages. The patient has been married thirty-one years, has had five normal labours and one miscarriage. Her menses ceased eight years ago. Her family history is decidedly tuberculous, but with the exception of an attack of jaundice twenty-six years ago, she herself has always had good health.

About two years ago there occurred a bloody discharge, which she looked upon as a return of the menstrual period; it was not accompanied by any pain. Nine months before admission she began to feel tired and weak, and had a severe hæmorrhage, shortly after which she was compelled to give up her work. The bleeding has recurred frequently. Five months ago the uterine cavity was curetted.

The patient is well nourished; the appetite is fair; the bowels are constipated; defecation is accompanied by considerable pain; micturition is frequent, but not painful; there is no abdominal tenderness.

On vaginal examination, the cervical lips are found to be enlarged and indurated. Projecting through the external os is a fungating mass having a pedi-

cle 1 centimetre in diameter. The uterus is somewhat enlarged, but is freely movable; no induration can be felt in the broad ligaments.

Operation, February 17th. Vaginal hysterectomy. As the outlet was very small, it was necessary before commencing the enucle-

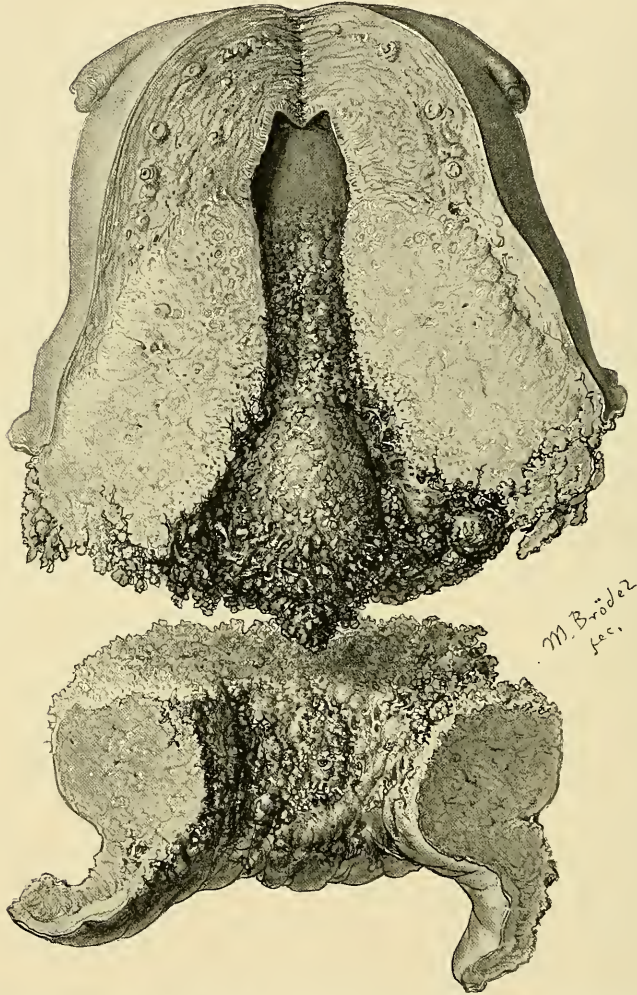


FIG. 143.—ADVANCED SQUAMOUS-CELL CARCINOMA OF THE CERVIX. (Natural size.)

Gyn.-Path. No. 172. The uterus is nearly twice its normal size. The cervix and the greater part of the body are the seat of a new growth, which is friable and much lighter in colour than the uterine muscle. Downward, it extends to the vagina, so that it is impossible to determine just where the cervix ends and the vagina commences. Laterally, the carcinoma extends to the broad ligament, no normal muscular tissue remaining. Upward, the growth has advanced to within 2.5 centimetres of the fundus. The inner surface of the growth, which corresponds to the combined cervical and uterine cavity, is covered with myriads of delicate finger-like outgrowths. The mucosa in the upper 1 centimetre of the uterine cavity appears to be normal, and its line of junction with the carcinoma is clearly defined.

This case (see also Fig. 144) is particularly interesting from a clinical stand-point. The initial step in the removal of the cervix *per vaginam* was the insertion of traction sutures into the cervix. It was found that the slightest tension was sufficient to sever the cervix from the body, as nothing remained but the friable squamous cells of the growth.

ation to deeply incise the perineum on the right side. The uterus was then removed in the usual manner; considerable difficulty was, however, experienced, as it tore very readily, being virtually nothing but a shell (Fig. 143). A rent in the bladder was closed by six sutures, and an iodoform gauze drain introduced into the vagina. Convalescence was uninterrupted, and the patient left the hospital March 21, 1894. Her daughter, writing December 7, 1894, said her mother had suffered with excruciating pains in the back, and that she had died on June 3d.

Gyn.-Path. No. 172. The specimen consists of the uterus, which measures $12 \times 7 \times 4$ centimetres. The cervical portion has, however, been entirely separated from the body during the operation (Fig. 144). The mucosa covering the vaginal portion of the cervix is to a great extent intact, but the posterior lip is, nevertheless, 2.5 centimetres in thickness. On opening the cervix from the external os upward, the tissue surrounding the canal is found to be everywhere occupied by a neoplasm, which as yet has broken down very little. On examining the growth closely, the superficial portions are made up of little papillary-like projections. There is a central stem, with secondary branchings which end in small knob-like extremities. The growth extends upward, involving the uterine wall to within less than 1 centimetre of the summit of the cavity. Laterally it apparently extends outward to the cut surface of the specimen. It is little wonder that the lower portion of the cervix had been broken away during the operation, as the tissue near the internal os is almost entirely composed of this friable new growth. The surface of the uterus is smooth and glistening; the walls average 2 centimetres in thickness, and the mucosa of the body, where still preserved, presents the usual appearance.

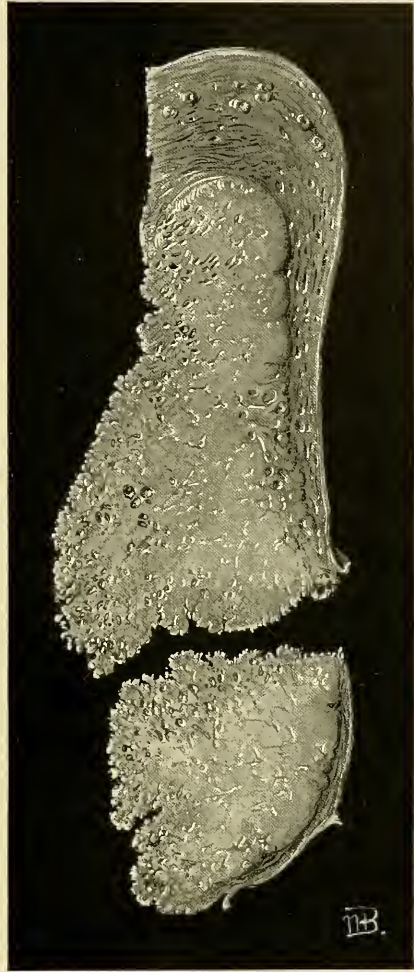


FIG. 144.—ADVANCED SQUAMOUS-CELL CARCINOMA OF THE CERVIX. (Natural size.)

Gyn.-Path. No. 172. This is a sagittal section of the posterior wall of the uterus represented in Fig. 143. The prominent elevation from the surface corresponds to the dome-like projection into the cavity, seen in Fig. 143. Springing from the surface everywhere are delicate finger-like outgrowths. Upward, the uterine muscle has been invaded to a greater depth than the mucosa. Posteriorly, little remains of the muscle, and it is not surprising that the cervix could not withstand any traction.

Histological Examination.—The squamous epithelium over the vaginal portion of the cervix is for the most part intact, but in the vicinity of the external os it has disappeared, and the surface is covered by blood, fibrin, and masses of tumour cells. The cervical stroma is everywhere infiltrated by islands of cells, which stand out very distinctly, staining deeply with hæmatoxylin. These islands are round, oval, tongue-shaped, or branching; their individual cells have round, oval, or elongate-oval, somewhat vesicular nuclei. Some of the nuclei show karyokinesis, and a few of the cells have very large, oval, deeply staining nuclei, which are apparently very rich in chromatin. Not infrequently polymorphonuclear leucocytes are found wandering in between the cells; occasionally the central portion of an island is completely filled with them. The new growth appears to have extended laterally into the broad ligament, and has in all probability not been entirely removed. The stroma of the cervix shows considerable small-round-cell infiltration. The growth is a squamous-cell carcinoma of the cervix.

Were one to examine the specimen only macroscopically, he would undoubtedly diagnose adeno-carcinoma of the cervix, since the greater part of the growth is confined to the vicinity of the internal os and the body of the uterus. The assertion that the cylindrical epithelium commences at the external os is generally accepted. It has been our experience, and that of others, however, that the squamous epithelium frequently extends beyond this point, at times lining the cervical canal almost as far as the internal os. In this case it is only necessary to assume that such a condition existed.

There was a local return of the growth in the vaginal scar soon after the patient left the hospital. She died June 3, 1894, just three and a half months after operation.

Gyn. No. 5,327

Carcinoma of the uterus. Vaginal hysterectomy, with (apparently) accidental removal of portions of the bladder and rectum. Subsequent severe cystitis, as a result of the faeces entering the bladder. Gradual occlusion of the ureters from scar tissue around their orifices. Death four years later from uraemia due to complete closure of the ureteral orifices (Fig. 145).

E. B., aged fifty-three. Admitted June 15, 1897. Complaint: urinary and faecal fistulae following vaginal hysterectomy three years ago.

The patient was married at nineteen, and during the next eleven years had five children and two miscarriages. The last two labours were instrumental.

The menses were regular until four years ago, when they became profuse; in the intervals also there were hæmorrhages. The patient was told she had cancer of the uterus, and the uterus was removed (in an adjoining State) six months after the hæmorrhages had commenced. Immediately following the operation there was a discharge of urine and faeces from the vagina.

The patient on admission to the hospital appears to be very ill. The lips and mucous membranes are very pale. The pulse is rather rapid, but of good volume. The tongue is clean; she has no appetite. There is no cough; no

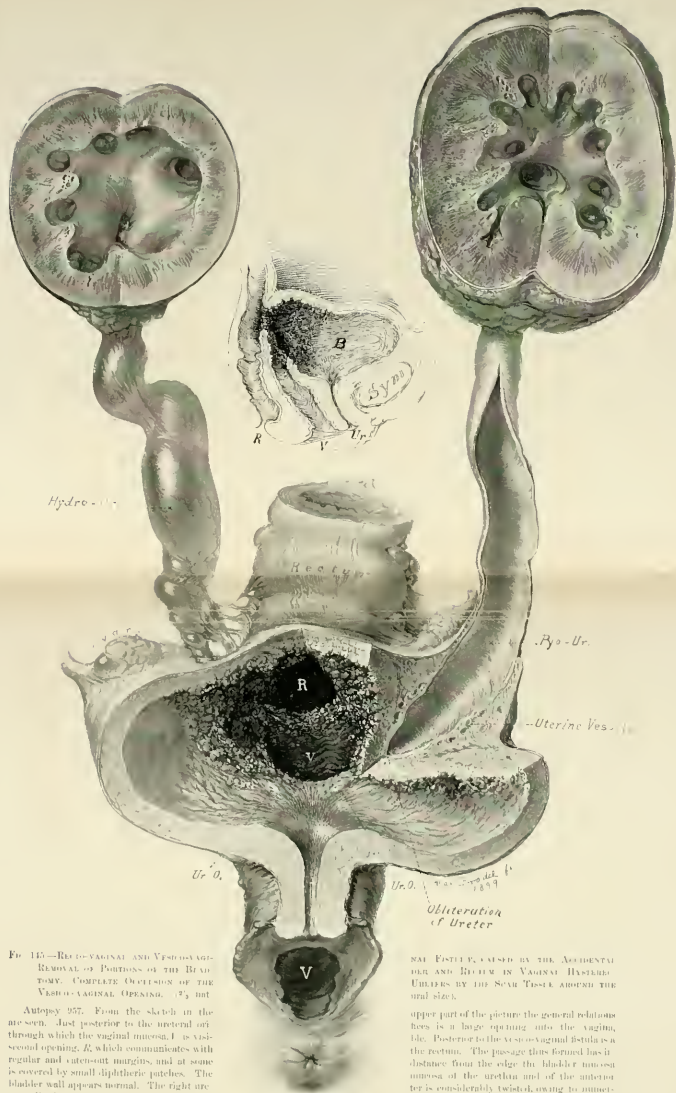

FIG. 145.—REDO-VAGINAL AND VESICO-VAGINAL. REMOVAL OF PORTIONS OF THE HEAD-TUBE. COMPLETE OPENING OF THE VESICO-VAGINAL OPENING. 7 $\frac{1}{2}$ INT.

Autopsy 957. From the sketch in the air seen. Just posterior to the ureteral orifice through which the vaginal mucosa, *F*, is viscerosed opening, *B*, which communicates with regular and cutaneous margins, and at some is covered by small epithelial patches. The bladder wall appears normal. The right ureteric adhesions. It is occluded at its lower end nearly 2 centimetres in diameter. The left ureter has been completely obliterated 15 centimetres from its exit into the bladder (the walls are much thickened); the lumen was filled with thin pus. The abscesses in the left kidney are not seen in this section.

SEE FIGURE 145 FOR THE ACCIDENTAL UTERINE AND ECTOPIC IN VAGINAL HEMORRHOIDAL BY THE SCAR TISSUE ABOVE THE URAL SIZE.

upper part of the picture the general relations here is a large opening into the vagina, *Id.* Posterior to the vesico-vaginal fistula is a the rectum. The passage thus formed has a distance from the edge the bladder mucosa of the urethra and of the anterior is considerably twisted, owing to numerous and rapidly dilates, forming a hydro-pyosis of the kidney is somewhat distended bladder; above this point it is much dilated (the left kidney are not seen in this section.

œdema of the extremities. The patient says she has been confined to bed for a year.

Examination under anæsthesia. The vaginal vault is hard and indurated, especially over the base of the bladder. Situated in the vault and communicating with the bladder is a fistulous opening, 2 centimetres in diameter, through which it is possible to palpate almost the entire inner surface of the viscus (Fig. 145). On cystoscopic examination, the upper and anterior portions of the bladder are found to have practically normal mucosa; but at the base and around the fistulous opening it is granular, and bleeds slightly. Situated in the anterior wall of the rectum, some distance from the anus, is a fistulous opening, 1.5 centimetres in diameter.

The patient gradually became weaker, developed distinct signs of uræmia, and died June 28, 1897.

Autopsy No. 957. Anatomical diagnosis: Recto-vesico-vaginal fistula, diphtheric cystitis. Occlusion of right ureter, hydroureter, and hydronephrosis. Occlusion of left ureter, pyoureter, pyonephrosis. Chronic adhesive pleurisy. Atheroma of the aorta and coronary arteries.

The body is that of a well-nourished woman, 150 centimetres long. The subcutaneous fat is moderate in amount; the muscles are dark red in colour. The omentum is bound down to the cæcum by dense adhesions. The small intestines are bound to the tubes and ovaries and bladder by old adhesions. The urethra is normal, but a short distance within the internal meatus is a rough, circular opening in the bladder floor (Fig. 145). This measures approximately 1.5 centimetres in diameter, and communicates directly with the vagina. The bladder is everywhere acutely inflamed, is of a dirty-black colour, and covered with a purulent material. The inflammatory process is so severe and the discoloration so marked that the mucosa appears gangrenous. There is a foul odour. High up on the posterior wall, in the most intensely inflamed part, is an irregular opening allowing free communication between the rectum and bladder. The rectal mucosa, in the vicinity of the fistulous opening, shares in the acute inflammatory process and is likewise greatly discoloured.

The right ureter is occluded near its vesical opening; above this point it measures 2 centimetres in diameter, and is filled with a watery fluid.

The right kidney is smaller than the left. The capsule is densely adherent, the cortex is thinner than normal, and the apices of the pyramids are replaced by large, cup-shaped cysts. Situated in the medullary region are eight cyst-like spaces, averaging 1.5 centimetres in diameter.

The left ureter is occluded 2 centimetres above its opening into the bladder. Above this point it reaches 1.5 centimetres in diameter, and passes up in a tortuous manner to the kidney. It is filled with a thin, purulent fluid. The left kidney weighs 250 grammes. The capsule is thickened and moderately adherent, and, on being stripped off, discloses several small abscesses from which creamy-yellow fluid exudes. The ovaries and tubes are bound down by old adhesions. There is no evidence of a return of the carcinomatous process.

The diphtheric and intense inflammatory changes in the base of the bladder were undoubtedly due to the constant irritation and infection by the feces. This irritation was followed by new connective-tissue formation, which involved

the ureteral orifices, and, owing to gradual contraction, constricted the lumina, producing double hydronephrosis. The left ureter and kidney have most probably been infected from the bladder, as noted in the history. The patient died with signs of uræmia, due, as was proved by the autopsy, to complete occlusion of the ureters at their points of entrance into the bladder.

INJURIES TO THE URETERS DURING VAGINAL HYSTERECTOMY

Bürckle,* who collected two hundred and twenty-seven vaginal hysterectomies, reported four cases in which the ureters were injured. Two of the patients developed a uretero-vaginal fistula in the third week. Sängner,† in 1883, cited a case in which the uterus was removed *per vaginam*, and a ureter was tied. A uretero-vaginal fistula developed subsequently. From time to time reports appear of the ligation of one ureter during an operation, but rarely of both. Binswanger ‡ in one case found at autopsy both ureters included in the ligatures. With the advent of the ureteral catheter, the danger of injuring the ureters has been greatly diminished, and there is no better illustration of their value than that afforded by Pawlik's three cases. In the first, one catheter was inserted and neither ureter was injured; the second case was operated upon without catheters and a uretero-vaginal fistula resulted; in the third case, both ureters were catheterized and the operation was a perfect success. Our group of cases contains one in which a ureter was tied, but on account of the insertion of the catheter the accident was detected in time. In Case 2,415 (p. 125), while controlling the left uterine artery, the ureter was caught in the ligature and constricted; the ligature was cut and reapplied, and the patient made a good recovery. Case 4,038 (p. 108) is a unique one, and demonstrates one of the disadvantages of the ureteral catheter. Both ureters were easily catheterized, the bougies serving to outline their course perfectly. The right catheter was removed without difficulty at the close of the operation, but the left had been broken, probably by a pair of artery forceps. A portion was removed, but 17.5 centimetres still remained in the ureter. The patient's condition did not warrant the operator in making the necessary abdominal section for its removal, and she was returned to the ward. Death occurred on the seventh day.

HÆMORRHAGE FOLLOWING VAGINAL HYSTERECTOMY

On account of the small space in which to operate, the surgeon is always at a disadvantage, and cannot check bleeding with the same facility as in abdominal hysterectomy. The ligatures controlling the broad ligament have to be applied partly by touch, and occasionally slip off shortly after being placed; again, when the disease has advanced far laterally, the ligature may include carcinomatous

* Bürckle, J. *Ueber das Verhalten der Operirten nach vaginaler Totalexirpation des carcinomatösen Uterus. Inaug.-Dissert.*, Berlin, 1893.

† Sängner, M. *Zur vaginalen Totalexirpation des carcinomatösen Uterus nebst Bericht über zwei von der Operation genesene Fälle. Arch. f. Gynäk.*, 1883, Bd. xxi, S. 99.

‡ Binswanger, O. *Anatomische Beiträge zur Indicationsfrage der Freund'schen Operation. Centralbl. f. Gynäk.*, 1879, Bd. iii, S. 4.

tissue, which is excessively friable and cuts through. One is then in an awkward predicament, and can only control bleeding by applying artery forceps to the ligament and leaving them there for several days.

In Case 4,038 (p. 108) the disease was farther advanced than had been anticipated, and in trying to place ligatures in the right broad ligament, four out of every five would cut through the tissue. The right uterine artery bled profusely, and was with difficulty controlled by artery forceps. A similar experience was met with on the opposite side. Six pairs of forceps were left in the vagina. Free hæmorrhage occurred in Cases 2,415 (p. 125), 2,624 (p. 76), 2,990 (p. 286), and 2,452 (p. 111). In each of these instances artery forceps had to be left on the broad ligament and projected through the vagina. They were removed at intervals between thirty-six hours and six days after operation; in no instance did hæmorrhage follow.

All of these cases were operated upon before the radical method had been adopted; in the future, therefore, trouble from this source will be much less frequent. In all vaginal hysterectomies the operator should be prepared for abdominal section, so that if uncontrollable hæmorrhage occur he can instantly open the abdomen and catch the vessel from above.

CAUSES OF DEATH AFTER VAGINAL HYSTERECTOMY

1. Infection.
2. Ligation of a ureter.
3. Prolapse of the intestines.

Infection may occur here as after abdominal hysterectomy, the precautions as to cleansing being the same. But after the vaginal operation the facility for drainage is infinitely better, there being a direct communication between the pelvis and vagina. In a certain number of cases, however, death follows with symptoms indicative of sepsis.

In Case 2,631 (p. 291) the vaginal pack was removed on the second day, with the escape of a small amount of dark clotted blood. The pulse was 160. On the third day the temperature rose to 101.2°, and there was a greenish vomit. On the fifth day there was abdominal distention, and the patient complained of a feeling of constriction. The urine was loaded with albumin. The patient died on the seventh day.

Ligation of a ureter sometimes causes death, but there is always a chance that a uretero-vaginal fistula may form, as in the case reported by Sängcr.

Prolapse of the Intestine.—This very alarming condition may develop in those cases in which the opening in the vaginal vault is large, and especially when the patient strains a great deal. I have seen a prolapse of several intestinal loops occur a few days after vaginal hysterectomy for double pyosalpinx. The patient died two or three days later. In Case 2,928 (p. 272) there was slight prolapse of the intestine, and the patient died on the ninth day. Reichel,* in

* Reichel, P. *Ileus nach vaginaler Totalexstirpation des Uterus.* *Zeitschr. f. Geburtsh. u. Gynäk.*, 1888, Bd. xv, S. 37.

1888, reported two intestinal cases. In the first the hyperæmic fimbriated end of the right tube was found projecting into the vaginal vault, but no intestines had come down. Fæcal vomiting developed on the seventh day, and on making an exploratory section, the abdominal peritoneum was found injected, but smooth. The lower portion of the ileum lay deep in the pelvis, and with the omentum was adherent to the vaginal wound. After liberating the adhesions, this part of the gut was found to be very narrow, being almost a solid cord. No explanation for this constriction of the lumen could be found. The patient died before the completion of the operation.

In Reichel's second case, during the separation of the cervix from the bladder the posterior cervical lip was torn, and from it a teaspoonful of bloody, foul-smelling pus escaped. Vomiting soon came on, and on the sixth day abdominal distention manifested itself. By the eighth day the vomiting was fæcal in character. On opening the abdomen, Reichel found a deeply seated loop of the ileum kinked and adherent to the vaginal wound. The distended intestinal loops presenting at the abdominal incision stood out in sharp contrast to the contracted portion of the gut below the point of constriction. Death resulted in twenty hours. Reichel also reviewed similar cases which Bokelmann, Leopold, and Landau had reported.

Where such a condition is met with, the prolapsed intestines should be immediately sponged off with sterile salt solution and returned to the pelvis. On the first conclusive sign of peritonitis, the abdomen should be opened and the peritoneal cavity carefully examined. The pelvis, as far as possible, should be walled off, and the prolapsed intestinal loops thoroughly scrubbed with a sponge, following Finney's* method. A drain may then be loosely placed in the pelvis and brought down into the vagina. If general peritonitis be present, the intestinal loops are to be systematically taken out and cleansed.

Prolapse of Intestines after Vaginal Hysterectomy, with Fatal Results

Gyn. No. 2,928

Squamous-cell carcinoma of the cervix; combined vaginal and abdominal hysterectomy; friable uterine arteries controlled by artery forceps left *in situ*, the handles lying in the vagina; descent of intestines to the vaginal vault on removal of the pack on the fourth day. Death with signs of peritonitis on the ninth day.

M. L., aged fifty-seven; white. Admitted July 19, 1894. No history was obtained from the patient previous to operation. On vaginal examination, the outlet is found to be greatly relaxed, the cervix is flush with the vaginal vault, and around the external os are several hard nodules, which seem to extend upward into the uterus. The vagina does not appear to be involved.

The uterus is slightly enlarged, but is moderately movable. The examination was followed by some hæmorrhage.

* Finney, J. M. T. *Five Successful Cases of General Suppurative Peritonitis treated by a New Method.* Johns Hopkins Hosp. Bull., 1897, vol. viii, p. 141.

Operation, July 21st. Combined vaginal and abdominal hysterectomy. The cervix was curetted until nothing but a shell remained. The peritoneal cavity was opened posteriorly through the vagina. As there was some thickening on the left side, a bougie was introduced into the left ureter, the abdomen opened, and the operation completed from above. Great difficulty was experienced in controlling the uterine arteries, as they were very friable. The pelvic cavity was carefully washed out, and a gauze drain was introduced into the pelvis through the abdominal incision and drawn into the vagina. It was necessary to leave four artery forceps on the uterine vessels, the handles lying in the vagina. The abdominal incision was then closed. Thirty-six hours after operation the artery forceps were removed; the patient's condition was good.

On July 24th the vaginal pack was removed and found to be perfectly dry. The intestines had dropped down, and were flush with the vaginal vault; two pieces of iodoform gauze were introduced into the vagina; the patient complained of no pain, and slept a great deal; her pulse, however, was rather rapid. On the fourth day she had several small liquid movements, complained of nausea, was very restless, with a pulse of 120. On the 28th her tongue was dry, the skin was hot, and muscular twitchings were observed. At times the patient slept heavily; now and then she would wander. On July 29th, the involuntary passage of urine occurred; the patient was covered with cold perspiration; the breathing was short and quick. She died at 9 P. M.

Gyn.-Path. No. 388. The specimen consists of a remnant of the uterus, the intact tubes and ovaries, and uterine scrapings.

The uterus measures $6.5 \times 5 \times 2$ centimetres, the cervical portion being represented merely by a cavity. The uterus, both anteriorly and posteriorly, is smooth and glistening. On looking for the cervix, nothing is found but a cup-shaped depression, the walls of which are ragged, but very firm to the touch. The line of demarcation between the growth and the upper part of the body is sharply defined. A more extended description of the macroscopic appearance would be misleading, the curette having been used just previous to operation.

The right tube presents the usual appearance. The ovary contains a small transparent cyst 2.5×2 centimetres. The left tube is normal; the left ovary also contains a small cyst.

Histological Examination.—The scrapings are found to consist of a tissue that is everywhere invaded by alveoli, which are round, oval, finger-like, or branching. They are filled with cells containing large, oval, somewhat deeply staining nuclei. Here and there a few nuclear figures are seen. In some places the centres of the alveoli are filled with polymorphonuclear leucocytes; or the leucocytes may be scattered between the individual cells. The stroma is composed of spindle-shaped cells, which are of connective-tissue origin. Scattered throughout it are many polymorphonuclear leucocytes, and here and there clusters of lymphoid cells. The raw, worm-eaten surface of the cervix is covered by canalized fibrin, in the meshes of which are red blood-corpuscles and polymorphonuclear leucocytes. The tissue itself is everywhere infiltrated by alveoli, which may assume any shape. These alveoli, or nests, as they may be termed, are completely filled with cells containing large, oval, vesicular nuclei. Here and there, especially in the newer portions of the growth, some of the tumour cells

contain deeply staining nuclei, fully four times the size of those in the vicinity. The cells of the new growth extend outward almost to the peritoneal surface, and along the advancing margin occur in single or double rows. The stroma of the tissue shows a varying amount of small-round-cell infiltration. The uterine glands, as far as can be made out after curetting, are normal. The growth in this case is a squamous-cell carcinoma, and it is more than probable that the entire diseased tissue has not been removed. The tubes and ovaries are practically normal.

Diagnosis: Squamous-cell carcinoma of the cervix.

REMOTE SEQUELÆ OF VAGINAL HYSTERECTOMY

Where no untoward symptoms develop within a few days after operation, little further trouble may be anticipated from the operation itself, but as the following case, reported by A. P. Dudley,* will show, the intestines after becoming adherent (as has been noted by Reichel) † may rupture, with formation of a fistulous opening into the vagina. Dudley's patient had undergone a vaginal hysterectomy for squamous-cell carcinoma of the cervix, and at the time of operation the intestines could be seen lying high up in the pelvis. The patient, while making her bed one morning about six months after the operation, felt something suddenly give way in the lower abdomen, and had considerable pain. Six weeks later stercoraceous vomiting developed, and she gave signs of complete intestinal obstruction. Vaginal examination revealed a hard mass in the pelvis situated where the uterus should have been, and subsequently a fistula developed between the gut at this point and the vagina. Sãnger's ‡ case also developed a fœcal fistula in the vault, but in this instance there was a return of the growth in the scar, and it is quite probable that the adherent intestine had been invaded by continuity, and that the fistula was due mainly to a breaking down of the carcinomatous tissue.

ATTEMPT TO CHECK THE CARCINOMA BY LIGATION OF THE INTERNAL ILIAC ARTERIES

Dr. Kelly was first forced to ligate the internal iliac arteries in Case 2,248 (p. 275). After commencing the abdominal hysterectomy, it was found that the broad ligaments were greatly infiltrated; the ligatures cut through, and free hæmorrhage followed. This could not be checked until both internal iliac arteries had been controlled. The operation was then continued, but not completed on account of the patient's weakness. She made a satisfactory recovery. In March, 1894, in Case 2,568½ (p. 236), after the patient had been curetted and placed in the Trendelenburg posture, the abdomen was opened and both internal iliac arteries were ligated. From the accompanying history, it will be seen that a large vein, most probably the common iliac, was tied, and gangrene of the leg followed. On April 16, 1894, both internal iliac arteries were tied in Case 2,725 (p. 277). For several days following the operation there was œdema of the extremities, but no pain was felt. Examination of the patient from time to time

* Dudley, A. P. *New York Med. Jour.*, 1887, vol. xlvi, p. 35.

† Reichel. *Loc. cit.*

‡ Sãnger, M. *Op. cit.*

showed no alteration in the growth. In Case 2,568½, however, subsequent examination gave the impression that the entire pelvic contents were sloughing away. This was probably due to the same cause as the gangrene, namely, accidental injury of the large vein, necessitating ligation.

Fig. 125 (p. 238) shows the various points at which the uterine artery or the vessels from which it arises may be controlled. In Fig. 146 are seen the various tissues supplied by these vessels. We are in doubt, however, just how far the tying off of the uterine arteries will check the blood supply to the uterus in any given case, since the anastomosis between the uterine and ovarian vessels is quite free.

Although only a few examples are on record in which the internal iliac arteries have been ligated for the purpose of checking the growth of the carcinoma, I think they are sufficient to show that almost nothing is to be expected from this mode of treatment.

Cases of Squamous-cell Carcinoma in which the Internal Iliac Arteries were Tied

Gyn. No. 2,248

Squamous-cell carcinoma of the cervix with extension to both broad ligaments; abdominal hysterectomy; severe hæmorrhage controlled by ligating both internal iliac arteries; dissection of the left ureter out of carcinomatous tissue. The growth was not entirely removed. Vesico-vaginal fistula followed and was repaired four months later. Death ten months after operation.

L., aged thirty-seven; white. Admitted October 7, 1893. Complaint: constant uterine hæmorrhages; sharp pains in the back and lower abdomen.

The patient has been married nineteen years, and has had two children. Both labours were protracted and terminated by forceps. Her menses were regular until September, 1892, when the flow became constant, and for a year previous to admission she has had a continual offensive vaginal discharge. At present the patient is anæmic; her appetite is poor; she suffers from nausea and vomiting and from sharp, shooting pains in

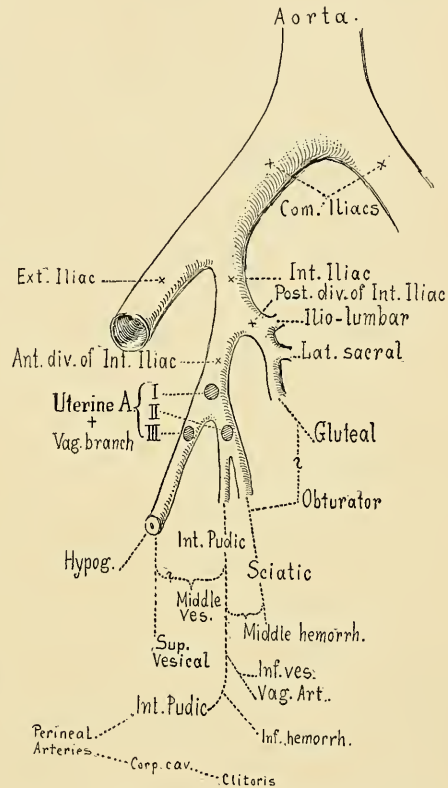


FIG. 146.—BRANCHES OF THE INTERNAL ILIAC ARTERY.

The common iliac divides into the external and internal iliac arteries, the latter of which soon gives off the anterior and posterior branches. Springing from the anterior branch of the internal iliac is the uterine artery, which arises at one of the three circles indicated. As seen from the sketch, the greater part of the pelvic blood supply comes from this source, and ligation of both internal iliacs is likely to be followed by some sloughing.

the back and lower abdomen. The vaginal outlet is greatly relaxed; the cervix is hard and infiltrated, filling the vaginal vault. The anterior vaginal wall is involved for a distance of 3 centimetres. The uterus is somewhat fixed, and there is infiltration of both broad ligaments, more especially the right.

On account of the involvement of the broad ligaments, it was thought advisable to perform abdominal hysterectomy. The abdominal cavity was opened, the ovarian vessels were ligated, and an attempt was made to tie off the broad ligaments. The tissues, however, were so infiltrated that the ligatures would not hold; and as there was severe hæmorrhage, Dr. Kelly deemed it advisable to cut off the entire pelvic circulation. Accordingly, both internal iliac arteries were ligated. All the hæmorrhage having been checked, the operation was proceeded with, but it was soon found that the left ureter was involved in the carcinomatous mass. By careful dissection, the ureter was freed and placed to one side. The patient's pulse had now reached 160, and her respirations were becoming shallow. While the operation was being proceeded with, Dr. Clark transfused 500 cubic centimetres of normal salt solution into the radial artery. The pulse dropped to 120 and improved in volume. The entire carcinomatous tissue was not removed.

The patient made a satisfactory recovery, and left the hospital November 23d.

She returned in March, 1894, for the repair of a vesico-vaginal fistula, which had been accidentally made during the first operation. On vaginal examination, not the slightest trace of carcinoma could be detected. The patient, however, died at her home, August 15, 1894.

Gyn. Path. No. 62. The specimen consists of the uterus and appendages intact. The uterus is 11 centimetres in length, and averages 5 centimetres in breadth. The cervix is enlarged and indurated; its lips are everted. The anterior lip is roughened and irregular, and presents an area of ulceration 1 centimetre in diameter. On section, the cervix is worm-eaten, shaggy, and in places is almost eaten through. The growth extends to the internal os, and along its advancing margin is exceedingly firm. The mucous membrane of the body of the uterus appears to be normal. The right tube presents the usual appearance. The ovary is covered by a few delicate adhesions, and on section is found to be slightly edematous. The left tube presents nothing abnormal, but the ovary is covered by delicate adhesions.

Histological Examination.—The growth occupying the cervix is composed chiefly of masses of epithelial cells. These occur as round or oval nests, but may show divers arrangements, and in many places are branching. The cells composing these nests resemble squamous epithelial cells, and have oval, vesicular nuclei. In several parts of the specimen the cells are arranged in single or double rows, and might at first sight be taken for glands. The growth has extended laterally out into the broad ligament and upward within the internal os. The tissue between the nests of cells shows marked small-round-cell infiltration. The growth is a typical squamous-cell carcinoma.

The cervical mucosa is for the most part intact, showing little invasion by the new growth. The appendages are practically normal.

Diagnosis.—Squamous-cell carcinoma of the cervix with extension to the broad ligaments.

Gyn. No. 2,725

Squamous-cell carcinoma of the cervix with cauliflower outgrowth. Extension to the right broad ligament; marked dilatation of the left ureter; ligation of both internal iliac arteries, followed by slight oedema of the legs for several days. General condition improved; the hæmorrhage ceased for a time, but the growth advanced.

M., aged forty-five; white. Admitted April 16, 1894. Complaint: uterine hæmorrhages; frequent sharp pains in the uterus and lower extremities.

The patient has had four normal labours. Her father died of tuberculosis, but, with the exception of an occasional attack of rheumatism, she has always been healthy. Three months ago she began to have a great deal of pain in the region of the uterus, and had several hæmorrhages. This condition has continued until within a few days previous to admission. She is somewhat emaciated; her mucous membranes are of a good colour; the appetite is normal; the bowels are constipated. At times she has a good deal of burning on micturition, and locomotion is painful.

The vaginal vault is relaxed. Springing from the cervix and extending to the left vaginal vault is a hard, irregular fungating mass, which breaks down readily and bleeds freely. The greater part of the cervix is involved, only a small portion of the anterior lip remaining intact. The disease has extended upward to the internal os. The uterus is slightly enlarged, and is freely movable; there is no apparent thickening in the broad ligaments.

On April 21st the uterus was curetted and a considerable amount of tissue removed; the vagina was then packed with iodoform gauze.

Operation, May 2d. Ligation of both internal iliac arteries. The patient was placed in the Trendelenburg posture, and an incision, 12.5 centimetres long, was made through the abdominal walls. The uterus was a third larger than normal, and was erect in the pelvis. After releasing the tubes and ovaries from general villamentous adhesions, the uterus was drawn forward. On the left side the dilated ovarian vessels crossed the external iliac artery, as it skirts the brim of the pelvis, at an angle of about 30°.

Parallel to, and above these, was the ureter, which was four times its normal size; above, and to the left side of the ureter, appeared the sigmoid flexure. The sigmoid flexure was drawn upward and toward the median line, and the ureter and ovarian vessels were carried over the brim of the pelvis. On opening the peritoneum, the bifurcation of the common iliac artery could easily be felt. The internal iliac was liberated from its surrounding vessels and ligated about 2 centimetres below the bifurcation. The vessel beneath the point of ligation immediately became blanched; this whitened condition could be traced for 1 centimetre, and no pulsation could be felt in the artery. The pulsation in the uterine artery also ceased. In the angle between the external and internal iliac arteries, just below the pelvic brim, a large gland could be felt. The lower part of the right broad ligament was choked with the carcinomatous growth. The right internal iliac was controlled in the same manner, but with much less difficulty. The right ureter was not enlarged,

but in the broad ligament, just below the brim of the pelvis, a small gland was found. The operation lasted thirty-three minutes. When seen a few hours afterward the patient was feeling comparatively comfortable, but the legs were slightly edematous from the ankles to the knees. The oedema continued for several days, but there was no pain in the extremities.

Vaginal examination, on May 8th, showed no change in the local condition; no hæmorrhage, however, followed examination. On May 25th the nodules in the left fornix appeared to be somewhat larger, but the patient's general condition had improved. She left the hospital May 30, 1894.

Gyn.-Path No. 267. The specimen consists of a number of small scrapings, light red in colour and rather hard in consistence. The largest piece measures 3×1 centimetre; on cross section it presents a waxy appearance, and immediately suggests carcinoma. On histological examination these pieces are found to consist of tissue, everywhere traversed by oval or finger-shaped alveoli, which are filled with large epithelial cells having oval, pale-staining nuclei. Most of the nuclei contain very little chromatin, but their nucleoli stand out prominently. Many of the cells contain nuclear figures. The stroma is moderate in amount, and shows much small-round-cell infiltration; this is especially marked around the blood-vessels, which in most places are dilated.

Diagnosis.—Squamous-cell carcinoma of the cervix.

PALLIATIVE TREATMENT

It is appalling to note the large number of cases even in our group in which the disease had advanced too far to warrant a radical operation, and in which only temporary relief was possible.*

The best results are obtained by curetting away as much of the necrotic and sloughing material as possible, thus getting rid, for the time being, of the offensive odour, and minimizing the absorption of septic material that is continually going on. After placing the patient in the dorsal position and cleansing the parts thoroughly, the vaginal vault is carefully surveyed to ascertain if the bladder has been encroached upon, and, if so, how far. Careful palpation is made anteriorly, after a sound has been introduced into the bladder. If there be any reason to suspect vesical involvement, a cystoscopic examination is made. The recto-vaginal septum is now palpated to determine whether or not the rectum is involved. The friable carcinomatous tissue is curetted away, partly with the finger, the firmer portions being removed by means of a large sharp curette. Anteriorly, care must be exercised not to go through into the bladder (see Case 3,712, p. 303), and posteriorly, to avoid producing a recto-vaginal fistula or opening Douglas's cul-de-sac. As soon as a hard, firm base has been reached the

* It has frequently been urged that hysterectomy should be performed even though the growth cannot be entirely removed, in order that the patient may be saved the distressing and excruciating pain so frequently experienced in the late stages of the disease, particularly in those cases in which the uterus has not been removed. Experience, however, teaches that the surgeon is not justified in promising such relief, since in many instances, after removal of the uterus, the patient has nevertheless suffered agonizing pain toward the end of her life.

curetting is stopped; the vagina is then washed out and afterward thoroughly packed with iodoform gauze. When the curetting is first commenced, the bleeding is often profuse, but usually diminishes as soon as firm tissue is reached. This free hæmorrhage is due to capillary oozing from the many finger-like processes of the growth. Occasionally it is necessary to take scissors and forceps and cut pieces of the cervix away. Any large vessel opened in this way must be controlled by a ligature or by a pair of artery forceps, which may be left on for forty-eight hours.

If the peritoneal cavity is accidentally opened, an iodoform gauze tampon should at once be closely packed within the rent and the operation continued, until all septic and sloughing masses have been removed down to a clean surface. The vagina is now cleansed, the gauze removed, and a fresh pack inserted, projecting a short distance into the pelvic cavity. This is allowed to remain in place for three or four days, after which it is removed, a fresh pack being inserted not quite so far up. The patient usually experiences much relief from such an operation, and it is astonishing how the colour clears up, the body weight increases, and the mental condition is improved. Such a curetting may be indicated four or five times during the course of the illness.

Attention should be paid to the hygienic surroundings of such patients, all the fresh air attainable being allowed. They are, if possible, to be kept ignorant of their true condition, as many lose hope the minute they are told that they have cancer. The relatives should, however, have the situation fully explained to them. The diet may consist of anything that suits the patient's taste, and will, of course, vary greatly with the individual. Hæmorrhages will occur from time to time, and are best controlled by thorough douchings with hot water and then packing tightly with gauze. Vinegar and ice-water have been recommended by some as excellent styptics under these circumstances.

In the later stages the patients are frequently great sufferers and require some sedative. Morphine should be withheld as long as possible, but, when absolutely necessary, is to be administered as freely as occasion demands. When the patient's strength is fast failing and when she cannot last more than a few hours or a day or two at most, she should not be disturbed by useless manipulations, but her pain should be rendered bearable by an occasional dose of morphine. The too common practice of keeping up the tonics and giving stimulating enemata to the end is to be condemned. Such measures at best can only serve to prolong the agony, when death is certainly a relief, and when both relatives and physician know that there is not a ray of hope of saving the patient.

LOCAL MEDICINAL TREATMENT

For many years it has been the practice of charlatans, and at times of reputable physicians, to advocate zinc paste in the treatment of cancer, especially of the breast. Occasionally this substance has been employed in carcinoma of the cervix. As might be anticipated, no permanent benefit has resulted therefrom. Recently the injection of alcohol into the carcinomatous area has been recommended and some astonishing results have been reported; this treatment has not as yet proved to be of any especial value.

CHAPTER IX

ADENO-CARCINOMA OF THE CERVIX

1. Gross appearances.
2. Microscopical appearances in adeno-carcinoma of the cervix.
3. Cases illustrating the various stages of adeno-carcinoma of the cervix.
4. A rare form of adeno-carcinoma of the cervix (adenoma malignum).
5. Pyometra associated with adeno-carcinoma of the cervix.
6. Cases of pyometra occurring in adeno-carcinoma of the cervix.
7. Extension of adeno-carcinoma into a vein.
8. Extension of adeno-carcinoma to the lymph channels.
9. Condition of the uterine mucosa in adeno-carcinoma of the cervix.
10. Adeno-carcinoma of the cervix, with an apparently independent and early adeno-carcinoma in the body of the uterus.
11. Adeno-carcinoma of the cervix, secondary to that of the ovary.

WE have learned that the high cylindrical cervical epithelium usually extends from the external to the internal os, the cervical glands being found over the same area. Adeno-carcinoma of the cervix can arise from any portion of this surface epithelium or from any cervical gland. Thus it is evident that the general appearances will be materially influenced by the point of commencement of the growth. For example, if the carcinoma originates in the neighbourhood of the internal os, it may grow for a long time before a digital examination leads to its discovery, whereas if it starts near the external os, early recognition is more probable. For the sake of convenience we will first describe those cases in which the growth commences in the upper part of the cervix.

GROSS APPEARANCES

The new growth sometimes occurs as a round nodule, which may involve almost the entire cervix before any breaking down takes place. Thus in Case 2,782 (Fig. 147, p. 285) the cervix was intact and the uterus was of normal size. On opening the uterus, however, the cervix was found to be occupied by a dense white, waxy growth, which had extended upward nearly to the internal os and outward to within 5 millimetres of the broad ligament attachment. There was practically no breaking down of tissue, and, even with the uterus in one's hand, it was impossible to detect anything wrong with it before it was opened. It may be noted that the condition, which had been totally unsuspected, was diagnosed from an examination of scrapings.

The carcinomatous nodule gradually breaks down, leaving a sloughing cavity, which forms part of the cervical canal. With the progress of the disease upward and outward there is a coincident downward march, until the "worm-eaten" carcinomatous tissue can be seen peeping through the external os (*cf.* Case 3,923,

Fig. 162, p. 315). When the disease begins in the canal near the external os, the cervical lips are soon involved and appear thickened, infiltrated, and glazed; they show, however, little or no loss of substance, and rarely bleed. These points are well illustrated by Cases 3,616 (p. 297) and 3,923 (p. 314). Again, in Case 2,631 (p. 291) the lips are also greatly enlarged, infiltrated, and nodular, but intact (Fig. 152, p. 292). At other times, as in Case 2,625 (Fig. 156, p. 306), the cervix may be only slightly enlarged, but on palpation is felt to contain hard nodular masses, which do not, however, project from the surface. Thus far the conditions are very different from those found in squamous-cell carcinoma, but in not a few instances a cauliflower or fungus-like mass projects from the cervix. Thus, in Case 3,036 (p. 302), springing from one lip was a cauliflower-like mass, measuring 6 × 6 centimetres; it resembled placental tissue, and bled freely on the slightest manipulation. In Case 3,356 (p. 295), springing from the anterior lip and filling the upper part of the vagina, was a fungating mass; while in Case 3,712 (p. 303), the vagina was distended with an offensive necrotic mass, the size of a foetal head, which had sprung from the posterior cervical lip, and had extended over to the vaginal walls.

On careful examination of the growth, whether it be near the external os or far up in the canal, the ragged and worm-eaten appearance is found to be invariably due to many small finger-like or branching papillæ springing from the surface (Fig. 150, p. 289; Fig. 152, p. 292). These average 1 millimetre in diameter, but may be much larger. The carcinomatous tissue, on section, is often as dense as cartilage, yellowish white in colour, frequently traversed by glistening bands of stroma, has an irregularly advancing margin, and stands out in sharp contrast with the uterine muscle. Occasionally, as in Case 2,625 (p. 305), small masses of the growth are found at a distance from the main tumour.

It is remarkable how far laterally the disease may extend before the external os is implicated, or before there is much breaking down. In Case 2,990 (p. 286), for example, the cervix was infiltrated and the growth had extended to the vagina, but there was loss of continuity in the tissue.

John Williams thinks that the posterior lip is more frequently involved than the anterior. From our cases no satisfactory data on this point can be gathered; in some examples the process attacked the anterior lip, in others, the posterior, while in others, again, both lips were involved, as in Case 3,452 (p. 319). In a few instances the disease had advanced too far to enable one to determine the point of origin.

MICROSCOPICAL APPEARANCES IN ADENO-CARCINOMA OF THE CERVIX

After a brief reference to the normal histological picture, especially with regard to the cylindrical epithelium of the cervix and the racemose cervical glands (*cf.* p. 19), one will be better able to appreciate a description of the alterations found in adeno-carcinoma of the cervix. The name indicates a glandular growth, which runs rampant, invading the tissue in all directions. Throughout this book the term adenoma will never be used to designate any benign tumour, being reserved entirely for a malignant growth. At an earlier period the diagnosis of adeno-carcinoma was

made only when the disease was far advanced, so that little opportunity was afforded of studying the process in its initial stages. Fortunately, some of our cases were diagnosed early, and their study has shed much light on some hitherto obscure points. As might be expected, the growth may start from the epithelium at any point, from that covering the surface or from that lining the glands. In the majority of our cases the growth apparently originated in the glands, but a decision upon this point is difficult, inasmuch as the surface epithelium has usually long since disappeared.

Adeno-carcinoma commencing in a Gland.—The epithelial cells begin to multiply and form teat-like or club-shaped growths, projecting into the lumen (Fig. 154, p. 296). These excrescences gradually unite with one another to form small glands. Thus within one third, two thirds of a gland, or in an entire gland, from the multiplication of the epithelial cells may be formed twenty or thirty small glands. Between these there is little or no stroma (Fig. 153, p. 293). The epithelial cells forming these new glands have oval, vesicular nuclei that do not usually stain very intensely. Good examples of such a gland proliferation are found in Cases 2,631 (p. 291), 3,712 (p. 303), 2,990 (p. 286), 3,452 (p. 319), 1,964 (p. 312), and 3,923 (p. 314). Waldeyer,* in his well-known article on *The Development of Carcinoma*, in speaking of adeno-carcinoma of the cervix, says: "At the margin of the carcinomatous growth one sees enlarged uterine glands with many side-pockets, which deviate more or less from the typical form of the glands of the cervical canal, and appear in some places as larger roundish nodules. When one thinks that in the neck of the uterus, where the carcinomata are almost exclusively found, the mucous membrane has deep depressions and folds from which the glands originate, it is little wonder that transverse or longitudinal sections offer scant opportunity for discovering the direct connection of the carcinomatous growth with the orifice of the gland." Waldeyer, however, after considerable search along the margin of the growth, succeeded in obtaining several sections demonstrating the direct connection between the cervical glands and the carcinoma. He reports a case in which the outer gland-opening was still preserved, while the lower end, with several side branches, had been transformed into large epithelial nests. Ruge and Veit† were able to demonstrate the origin of the carcinoma from the cervical glands, and showed that the gland epithelium, which usually consists of one layer, becomes several layers thick, and that the original arrangement of the epithelium is lost. The cells are flat and contain large nuclei. The proliferation of epithelium begins as a small outgrowth that stretches toward the opposite side of the gland, while a similar prolongation juts out from the opposite side; finally, the two unite to form a bridge. By the multiplication of such growths the gland is converted into several smaller glands.

The specimens usually received show an advanced stage, so that the cervical tissue has everywhere been invaded by glands. Owing to the fact that these are cut in various directions, some look oval, while others are irregular in contour.

* Waldeyer, H. *Die Entwicklung der Carcinome*. Virchow's Archiv, 1872, Bd. lv.

† Ruge, C., u. J. Veit. *Der Krebs der Gebärmutter*. Zeitschr. f. Geburtsh. u. Gynäk., 1881, Bd. vi, S. 261.

The typical picture is, however, occasionally found where the gland continuity can be traced. Here it at once becomes apparent that branching in every conceivable direction has occurred, and that the majority of what appeared to be small round glands are merely cross sections of branches of the large glands (Fig. 154, p. 296). The glands are usually lined by one or more layers of epithelium, and projecting into their lumina are teat-like masses composed of epithelial cells. These cells rapidly proliferate, and eventually fill the gland cavity completely (Fig. 163, p. 316). Cross sections of these occluded glands look very much like the nests in squamous-cell carcinoma (Fig. 151, p. 290). In the majority, however, where the cells are closely packed together, a faint gland-like arrangement of the cells can still be made out with the low power, and instantly gives one a clew (see Cases 2,631, p. 291, and 2,990, p. 286). The younger portions—the advancing edges of the growth—are sought out, and the gland arrangement is recognised. An interesting example of such a picture is afforded by Fig. 163 (p. 316). Here one end of a gland is lined by four or five layers of cells. As the margin is approached, the cells diminish in number, until the lumen is lined merely by one layer of cuboidal cells, while at the point of penetration the gland is represented by a single cell. Occasionally the lumina of the glands are empty and dilated, their epithelium being much flattened; in other instances (Case 3,036, p. 302) they appear as mere slits.

The large cauliflower masses found springing from the cervix are composed of branching papillæ, which have an abundant stroma, consisting of spindle-shaped cells, the outer surface being covered by one or several layers of cells continuous with those lining the glands in the depth. These papillæ have a much more abundant framework of stroma and a less abundant blood supply than those of a squamous-cell carcinoma. Owing to this fact they are broken off with much more difficulty and bleed less freely.

The epithelium lining the glands and covering the papillary folds is multi-form. It may consist of a single layer of cylindrical cells, having oval, vesicular nuclei; or, when several layers are present, the cells become more polygonal. The cells, as might be expected, contain nuclear figures in various stages. Not a few have two or three nuclei, as in Cases 2,631 (p. 291), 3,036 (p. 302), and 3,923 (p. 314). In the degenerating cells karyorrhexis is not infrequently noted. Case 3,616 (p. 297) exhibits such a diversity in the forms of the cells that in some portions of the gland it is hardly possible to find two cells alike (Fig. 155, p. 300). At one point the gland is lined by cells approximately cylindrical, but the individual nuclei are unequal in size; in the adjoining cells the nuclei are relatively twice as large, while, a little farther on, the cells are represented by extensive plaques of protoplasm, each containing a large laminated mass of chromatin. Some of the epithelial cells on the opposite side of the gland are spindle-shaped. In brief, it may be said that the epithelial cells in adeno-carcinoma of the cervix differ greatly from those of the normal cervical epithelium, and cannot, morphologically, be recognised as derivatives from it. The cells and nuclei may be of almost any shape or form; sometimes the nuclei stain faintly, at other times most intensely. Along the advancing margin of the growth the nuclei almost invariably stain very deeply.

The stroma of the growth is composed of the cervical tissue, which is usually infiltrated by small round cells. This infiltration may be localized or general, but is most marked along the advancing margin of the growth.

Throughout the study of these cases it was noted that the amount of small-round-cell infiltration was in inverse proportion to the rapidity of the growth.

There may be rarefied areas scattered throughout the stroma. In Case 1,964 (p. 312) such areas were seen to be traversed by delicate fibrillæ, the intervening spaces being filled with a homogeneous material which had taken the eosin stain, and resembled mucoid tissue.

With the onward march of the disease there is a moderate tendency for the older portions of the growth to break down. As a result, the surface is frequently covered by fibrin, red blood-cells, polymorphonuclear leucocytes, and *débris*, while the underlying tissue to a considerable depth is necrotic. The glands contain polymorphonuclear leucocytes, necrotic material, and fragmented nuclei; the stroma of the cervix is abundantly infiltrated with polymorphonuclear leucocytes.

Only rarely is one fortunate enough to see the carcinomatous process developing from the surface epithelium. A most beautiful and instructive example of this stage was afforded by Case 2,990 (*cf.* Fig. 151, p. 290). Just within the external os the cylindrical epithelium, although intact at numerous points, showed proliferation, and had reached several layers in thickness. The epithelium had grown into the cervical canal in such a manner as to form glands having no stroma between them, but lying one against the other. This method of proliferation is precisely similar to that noted in the glandular tissues. In this case the carcinomatous process had also started from the glands. It is most interesting to note that, while the epithelium at numerous points on the surface showed proliferation of cells, the intervening epithelium was perfectly normal.

Cases illustrating the Various Stages of Adeno-carcinoma of the Cervix

Gyn. No. 2,782

Adeno-carcinoma of the cervix, clinically unrecognisable (Fig. 147); endometritis; double pyosalpinx; general pelvic peritonitis; abdominal hysterectomy. No recurrence; the patient appears perfectly well five years and seven months after operation.

K. G., aged forty-six; white. Admitted May, 1894. Complaint: constant pain in the left ovarian region, with a sense of fulness in the uterus.

The patient has had two difficult but non-instrumental labours. Her menses, which began at sixteen, were normal. The last period occurred in December, 1892. Her family history is good, and her previous history unimportant with the exception of a possible gonorrhœa, contracted seventeen years ago.

About two and a half years ago the patient first noticed a slight pain in the left ovarian region, which was more severe after exposure to cold or dampness. In February, 1894, she began to have a feeling of fulness in the uterus, accompanied by a constant, though not profuse, discharge of blood from the vagina.

This bleeding was checked by treatment, but the pain continued. She has lost some flesh during the past year, but is still well nourished; her skin is clear, and mucous membranes are of a good colour. She has a very poor appetite; her tongue is coated; the bowels are constipated. Urination is accompanied by pain and burning, and locomotion is also at times painful.

On examination, the outlet is found to be relaxed, and running from the posterior cervical lip down the vaginal wall is a ridge of scar tissue. The cervix is low down, very irregular, nodular, and indurated; the os cannot be made out. The uterus is irregular in outline and fixed in the posterior portion of the pelvis.

Examination of the scrapings showed that there was an adeno-carcinoma of the uterus, and hysterectomy was advised.

Operation, May 24th. Abdominal hysterectomy. The tubes are distended with pus, and together with the uterus are bound down by dense adhesions to the

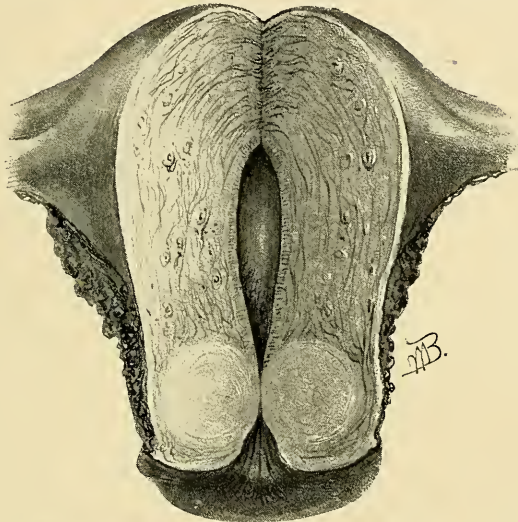


FIG. 147.—VERY EARLY ADENO-CARCINOMA OF THE CERVIX. (Natural size.)

Gyn.-Path. No. 308. The uterus is normal in size, considering the patient's age. The tubes contained pus. The vaginal portion is normal, but occupying the greater part of the cervix is a new growth, circular in outline, and extending laterally almost to the broad ligament attachments. There has been no breaking down, nor is the contour of the uterus in any way altered. A diagnosis of carcinoma could not have been made except with the aid of the microscope. (After H. A. KELLY.)

broad ligaments, pelvic floor, and rectum. The uterus was removed, considerable difficulty being experienced in the enucleation; 4 cubic centimetres of pus escaped from the right tube. After removal of the pelvic organs, the peritoneum from the posterior pelvic wall was united with that from the anterior wall, so that the pelvis was completely shut off from the vagina. The patient made a good recovery, and was discharged on June 14, 1894.

Gyn.-Path. No. 308. The uterus measures $6.5 \times 5.5 \times 4$ centimetres. The cervix is 2.5 centimetres in diameter, and its lips are intact. On being compared with the normal cervix, it shows no difference in size, but is exceedingly dense. On section, it is found to be occupied by a dense, white, waxy growth, which extends upward toward the internal os, and outward to within 5 millimetres of

the broad ligament attachments (Fig. 147). The uterine mucosa is very thin, and of a dirty grayish colour.

The appendages are covered by adhesions; the tubes are enlarged, and filled with pus. Sections from the uterine mucosa justified a diagnosis of endometritis. The tissue was not further examined, being required for museum purposes.

Diagnosis.—Adeno-carcinoma of the cervix. Endometritis. Double pyosalpinx.

December 22, 1899. Dr. Hurdon has just visited this patient and found her perfectly well, giving no signs whatever of a return of the growth. Length of time since operation, five years and seven months.

Gyn. No. 2,990

Adeno-carcinoma of the cervix (Fig. 150). Extension to the vaginal vault. Vaginal hysterectomy; troublesome hæmorrhage in the right broad ligament controlled by two pairs of artery forceps left on for twenty-four hours. Small uretero-vaginal fistula detected on the eighth day. Six weeks later, removal of the right tube, the ovary, and a small septic focus, 2 centimetres in diameter, in the pelvic floor. Right ureter cut off low down and anastomosed into the bladder with perfect result (Figs. 148 and 149). Histological picture showing proliferation of the cylindrical cervical epithelium forming new glands (Fig. 151).

The patient is perfectly well, five years and three months after operation.

B. Z., aged thirty-four; white. Admitted August 20, 1894. Complaint: a leucorrhœal discharge; some pain on micturition. She has been married fifteen years, has had 3 children, and 1 miscarriage six years ago. The menses commenced at twelve, have always been regular, and have been free but painful. The family history is negative.

For some time the patient has had a leucorrhœal discharge. This was controlled by douches, but returned about three months ago; at present it is quite offensive. She is well nourished, her appetite is excellent, and her bowels are fairly regular. She complains of nothing except the leucorrhœal discharge, and of a slight backache. The right side of the cervix is invaded by a new growth, which also involves the vaginal wall for a distance of 2 centimetres. There is no evidence of any breaking-down of tissue.

Operation, August 22d. Vaginal hysterectomy was performed. As the disease had extended far out on the right side, it was not easy to incise beyond it. The right uterine artery was controlled with difficulty, after having bled freely for several minutes; to stop the bleeding entirely, it was necessary to leave two artery forceps attached to the right broad ligament. The vagina was then packed with iodoform gauze. August 23d: The two clamps were removed; a slight oozing of blood followed. Since the operation the patient has had frequent inclination to urinate; she

experiences some abdominal pain; the face is flushed, and the skin is hot and dry. On August 24th the vaginal pack was removed, and two fresh pieces were inserted. On removal of the gauze, on August 28th, there was an escape of serous-like fluid, which was odourless. On August 29th urine was detected on the pack, but careful examination failed to reveal any vesical fistula.

Operation, October 6th. Repair of ureteral fistula, by Dr. Kelly. An incision, 16 centimetres in length, was made through the abdominal walls, which were 5 centimetres in thickness. The intestines, mesentery, and sigmoid flexure contained large masses of fat, and were with difficulty elevated over the brim of the pelvis; it required the constant effort of an assistant to keep them out of the field of operation. The pelvic walls and surface of the bladder were also loaded with adipose tissue. The right tube and ovary were dug out of a bed

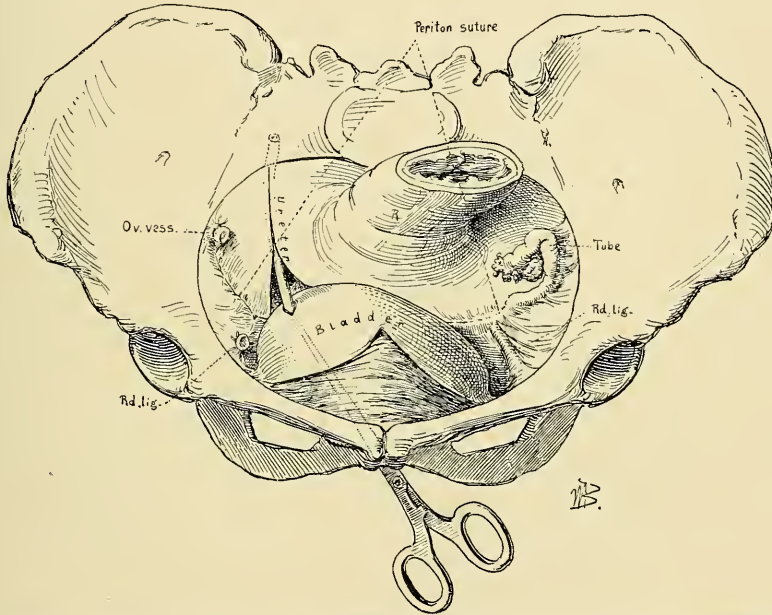


FIG. 148.—RIGHT URETERO-CYSTOSTOMY FOR URETERO-VAGINAL FISTULA FOLLOWING HYSTERECTOMY FOR CANCER OF THE CERVIX.

The ureter has been dissected out of its bed and cut off close to the base of the right broad ligament. As it was too short to reach the bladder, the latter was loosened from its attachments to the anterior pelvic wall and dropped back 3 centimetres, until it met the ureter. (After H. A. KELLY.)

of dense adhesions and removed. After their removal a septic focus, 1 × 2 centimetres, was found on the pelvic floor; in it numerous ligatures could be made out. The purulent area was dissected out, care being taken not to infect the adjacent tissues. After slitting the peritoneum over the brim of the pelvis and removing the underlying adipose tissue, the ureter was found; it was twice its normal size, and was recognised by its dark-red colour, and by its vermicular movement when traction was exerted. A slit, 5 millimetres in length, was made in the under surface of the ureter just below the brim of

the pelvis; the sound was introduced and passed down to the lower end of the scar, but did not enter the bladder. By raising the sound the ureter was made prominent on the pelvic floor, and was then dissected out from the brim downward. The presence of a good deal of cicatricial tissue rendered the dissection particularly difficult. The ureter was ligated at the point of the scar, where it passes over the vaginal vault; it was cut just above the point of ligation. The

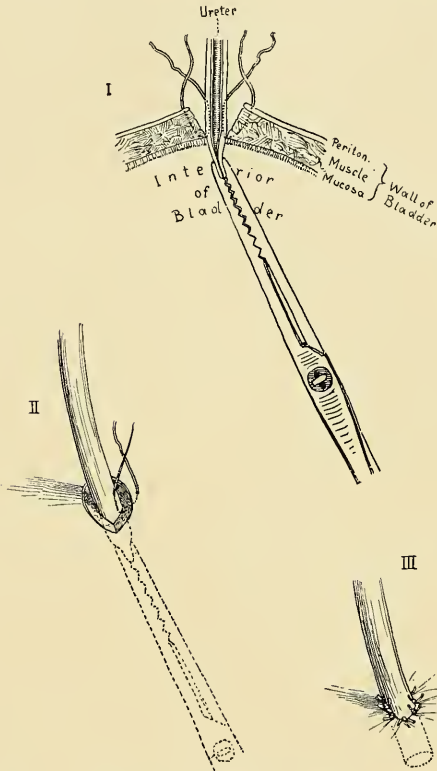


FIG. 149.—URETERO-CYSTOSTOMY.

I. Shows the end of the ureter drawn through the opening in the bladder by a pair of artery forceps passed through the urethra.

II. Shows the ureter held in place by one of the sutures.

III. The ureter has been sutured to the bladder wall on all sides. (After H. A. KELLY.)

lower cicatricial end was dropped, and the upper end slit on its under surface for a distance of 1 centimetre. A sound was then introduced into the bladder, and the point, having been pressed firmly toward the right side of the pelvis, was cut down upon, the incision being 1 centimetre in length. The bladder walls were 1.5 centimetres in thickness, and contained a large quantity of fat just beneath the peritoneal covering.

The ureter, which was now 4 centimetres shorter than normal, could be held in contact with the bladder only by the exertion of strong traction. To obviate this difficulty, the bladder was freed from its attachments to the symphysis pubis; it then dropped backward, exposing above the cellular tissue (Fig. 148). Four fine silk sutures were passed through the peritoneum and muscularis of the bladder, and then through the ureter down to its mucosa. The first suture in the ureter was introduced at a point 1.5 centimetres from the cut extremity. The end of the ureter was drawn through the slit in the bladder by a long, slender pair of forceps (Fig. 149), introduced through the urethra; the sutures uniting the ureter to the bladder were then tied. Two additional sutures, drawing

the peritoneum of the bladder around the ureter and passing through the outer ureteral coats, were introduced. The ureter now lay close to the pelvic brim, and the bladder dropped down upon it. A gauze pack was introduced over the top of the bladder, and was brought out of the lower angle of the abdominal wound. This pack tended to push the bladder down upon the ureter, and to relieve any tension that might occur. The upper part of the abdominal wound was closed with silkworm gut. The operation lasted ninety minutes. A catheter was introduced into the bladder immediately after the operation and left in

place for twenty-four hours, after which time the patient voided urine spontaneously. On October 10th the abdominal drain was half removed and found to be perfectly sweet. On October 11th it was wholly removed and a fresh one inserted. When the dressing was removed, on October 16th, it contained a considerable quantity of greenish material, which was thin and watery, had a distinctly faecal odour, and looked as if it might have come from the small intestines. The discharge, which at first appeared to be faecal, was evidently purulent in character; it ceased after a few days. The patient made a good recovery, and was discharged November 8, 1894.

Gyn.-Path. No. 427. The specimen consists of the uterus, which is 11 centimetres long, 6 centimetres broad, and 5 centimetres in its antero-posterior diameter. Anteriorly and posteriorly it is smooth and glistening. The cervix is 4.5 centimetres in diameter. Occupying the posterior lip, more especially on its left side, is a rough, worm-eaten area, averaging 3 centimetres in diameter (Fig. 150). Springing from its surface are delicate papillary-like elevations. The growth extends upward to a point 8 millimetres within the external os, its advancing margin being sharply defined. It invades the vaginal portion of the cervix nearly to the cut surface, and where it joins with the normal mucosa is slightly raised. The growth does not appear to have penetrated very far, but on longitudinal section of the uterus is found to have invaded the tissues to a depth of 1 centimetre, and

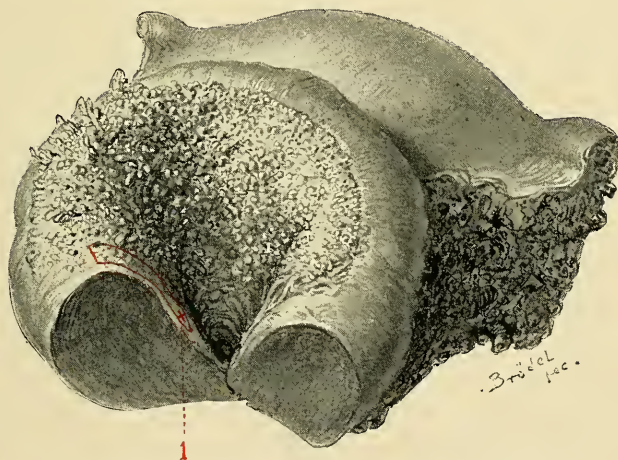


FIG. 150.—ADENO-CARCINOMA OF THE CERVIX. (Natural size.)

Gyn.-Path. No. 427. The uterus is seen from below. Springing from the vicinity of the external os, extending outward to the vagina and upward into the cervical canal, is a new growth, consisting mainly of delicate finger-like processes. The advancing margin of the growth is sharply defined and slightly raised. The arborescent appearance of the cervical mucosa is barely visible. Although the carcinoma might not appear to have penetrated deeply, histological examination shows that the cervical stroma is invaded to a depth of 1 centimetre. The remaining portion of the uterus is normal. Projecting laterally from the fundus are the stumps of the Fallopian tubes.

to extend to within 1 millimetre of the cut surface. It is highly probable that at this point the growth has passed over into the vaginal vault. The cervical mucosa above the point of invasion presents the usual appearance; the uterine mucosa, which reaches 4 millimetres in thickness, is apparently unaltered.

Histological Examination.—Penetrating the posterior lip of the cervix are small finger-like or branching alveoli, completely filled with cells. The cells have oval, or elongate-oval, deeply staining nuclei, while between the individual elements are numerous small round cells. The stroma of the tissue shows considerable small-round-cell infiltration. Thus far one would classify the case as a squamous-cell carcinoma, but the alveoli are very small, and do not stand out so sharply as might have been expected. Further sections give a ready explanation of these appearances, and the true character of the growth is determined with ease. Just within the external or the high cylindrical epithelium is in places found to be intact, but at numerous points has proliferated, reaching

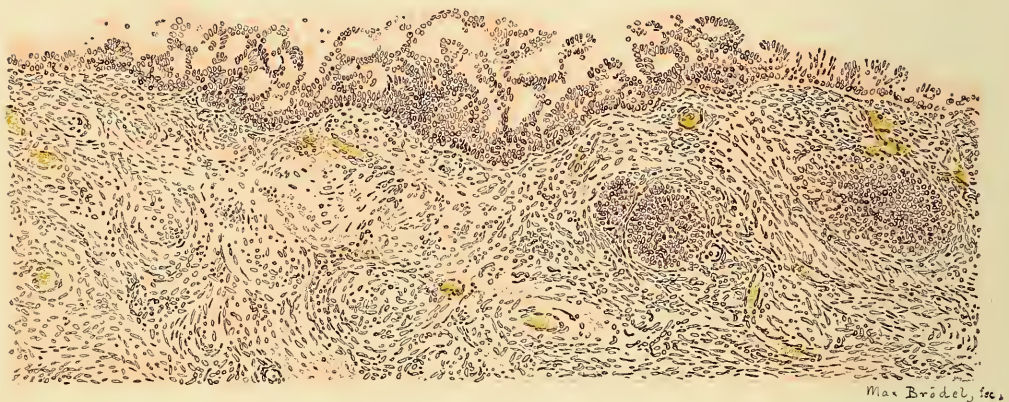


FIG. 151.—EARLY CHANGES IN THE CYLINDRICAL SURFACE EPITHELIUM IN ADENO-CARCINOMA OF THE CERVIX. (70 diameters.)

Gyn.-Path. No. 427. The section is taken from Fig. 150 at *L*. To the right and left appear some areas of normal cylindrical epithelium, one layer in thickness. For the most part, however, the mucosa is greatly thickened, consisting of from five to twenty layers of cells. The epithelium has proliferated in such a manner that many young glands have been formed. They lie one against the other, there being no intervening stroma. As a rule, the cells have small vesicular nuclei, but a few on the surface near the left border of the section show large, deeply staining nuclei. A short distance beneath the surface are three oval or circular areas composed of epithelial cells, closely packed together and forming cell-nests. The stroma of the cervix presents the usual appearance, and has a fairly abundant capillary blood supply.

A new gland formation, as here seen, rarely occurs except in a malignant growth. The large, deeply staining nuclei on the surface, and the cell-nests in the depth, are also suggestive of carcinoma. From this section alone, however, it would not be wise to make a positive diagnosis. The gross specimen itself afforded conclusive evidence, and the typical picture of adeno-carcinoma was found in numerous sections. This drawing is of particular interest as showing the earliest changes, there being, as yet, no loss of substance.

several layers in thickness. The epithelium has grown in such a way as to form new glands, which as yet have no stroma between them, but lie one against the other (Fig. 151). The cervical glands in the immediate vicinity of this altered surface epithelium have also undergone a somewhat similar change. The epithelium has proliferated and reduplicated itself in such a manner that, instead of a single large gland, we now have an irregular area made up of a group of smaller glands. In one instance the process is seen to be less advanced. Two thirds of one of the large glands still presents the normal appearance; the other third, however, is filled up by smaller glands, which have been produced by

the proliferated epithelium. On returning to the areas that suggest squamous-cell carcinoma, one is able to make out a faint, gland-like arrangement.

Diagnosis.—Adeno-carcinoma of the cervix.

November, 1899. Dr. Hurdon has just examined the patient, and finds she is perfectly well. Length of time since operation, five years and three months.

Gyn. No. 2,631

Adeno-carcinoma of the cervix (Fig. 152). Vaginal hysterectomy; death on the seventh day. Histological picture showing newly formed glands (Fig. 153).

M. H., aged forty-three; white. Admitted March 6, 1894. The only complaint, on admission, was of general weakness. She has had seven children; the labours were difficult, but non-instrumental. There is also a history of two miscarriages; the more recent one occurred six years ago, and was followed by hæmorrhages, which continued for about five weeks. Her menses have always been regular, and until three years ago were scanty; since then they have been rather profuse. She gives no history whatever of uterine hæmorrhages. The last menstrual period began about three weeks before admission. Her family history is negative. When a child, she had tubercular glands in the neck and in the groin, but apart from these she has always been healthy.

About eighteen months ago the patient noticed a watery vaginal discharge, which gradually became more profuse and very offensive. About the same time she experienced a heavy, bearing-down feeling in the uterus. In March, 1893, she was curetted; the discharge ceased, and she improved a great deal. In September, 1893, the flow reappeared, and a few weeks before admission she was again curetted; since then she has experienced no pain, and has been free from the discharge.

The patient is emaciated; is very pale and cachectic. Her bowels are constipated; there is no urinary difficulty.

On vaginal examination, the outlet is found to be relaxed; the cervix is low down; its lips are greatly enlarged, infiltrated, and nodular, but the surface is smooth, and does not break down on examination. The os is patulous. The uterus lies forward, is small, and appears to be somewhat fixed. The broad ligaments are apparently thickened. Slight hæmorrhage followed the examination.

Operation, March 7th. Vaginal hysterectomy was performed in the usual manner, and the vagina packed with iodoform gauze. On the second day the gauze packing was removed and a small amount of dark, clotted blood escaped. The vagina was repacked. The pulse on the second day was 160, and very weak. There was no elevation of temperature. On the third day the temperature rose to 101.2 F.; the pulse was very weak and rapid; the patient vomited a grayish substance, and passed very little urine. On March 11th distention was noticed, and the patient complained of a sense of abdominal pressure. She perspired freely, and her face and hands were cold. The highest temperature was 100.6° F. The patient was greatly annoyed by eructations of gas. Only 40 cubic centimetres of urine were passed. On March 12th the pulse was very weak; the urine was very scanty in amount and loaded with albumin; there were many

involuntary movements. On account of the weak pulse the patient was transfused with 300 cubic centimetres of normal salt solution. She died March 13th, at 4.30 P. M.

Gyn.-Path. No. 199. The specimen consists of the uterus with parts of the right tube and ovary. The uterus measures $9 \times 4 \times 3$ centimetres. Both anteriorly and posteriorly it is free from adhesions. The cervix from without is apparently normal, but when the specimen is opened, a portion of the posterior lip, and also the anterior lip to a more limited extent, are found to be involved by a new growth (Fig. 152). On the left side the cervix is slightly excavated, and

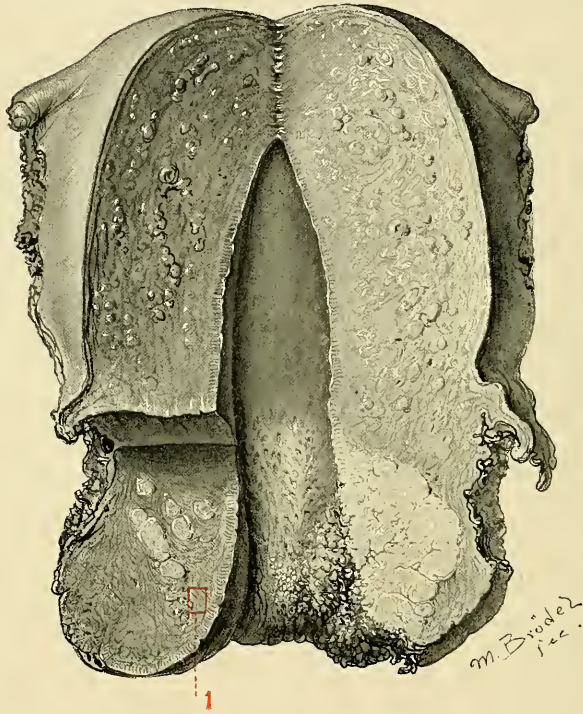


FIG. 152.—ADENO-CARCINOMA OF THE CERVIX. (Natural size.)

Gyn.-Path. No. 199. The uterus is opened anteriorly. The cervix is considerably enlarged, but its contour is well preserved. To the right, in the picture, there is slight loss of substance in the tissue at the external os. At this point short finger-like processes are seen springing from the surface. Occupying the anterior wall just within the external os, continuous with the finger-like processes, and extending laterally to within a short distance of the broad-ligament attachment, is a new growth contrasting sharply with the normal tissue. The advancing margin of the growth, both along the cervical mucosa and in the substance of the cervix, is irregular. On the left side a section of the cervix has been removed, and the mode of extension is well shown, the processes of the growth penetrating into the healthy tissues, as the roots of a tree into the soil. For the histological picture of the growth at 1, see Fig. 153. The body of the uterus is slightly enlarged, its walls are of the usual thickness, but there is an increase of the blood-vessels throughout the muscle, great numbers being seen on cross section projecting slightly from the surface. The arborescent appearance in the upper part of the cervix is well preserved. The endometrium is normal. Vaginal examination would have failed to give any adequate idea of the extent of the growth.

forming the floor of the cavity are small papillary-like masses. On this side the growth has invaded almost the entire thickness of the cervix, and practically

extends to the cut surface. It also involves the uterus above the internal os. The new growth has a somewhat homogeneous appearance, but is divided up into small areas by distinct bands of tissue, which are darker in colour. It stands

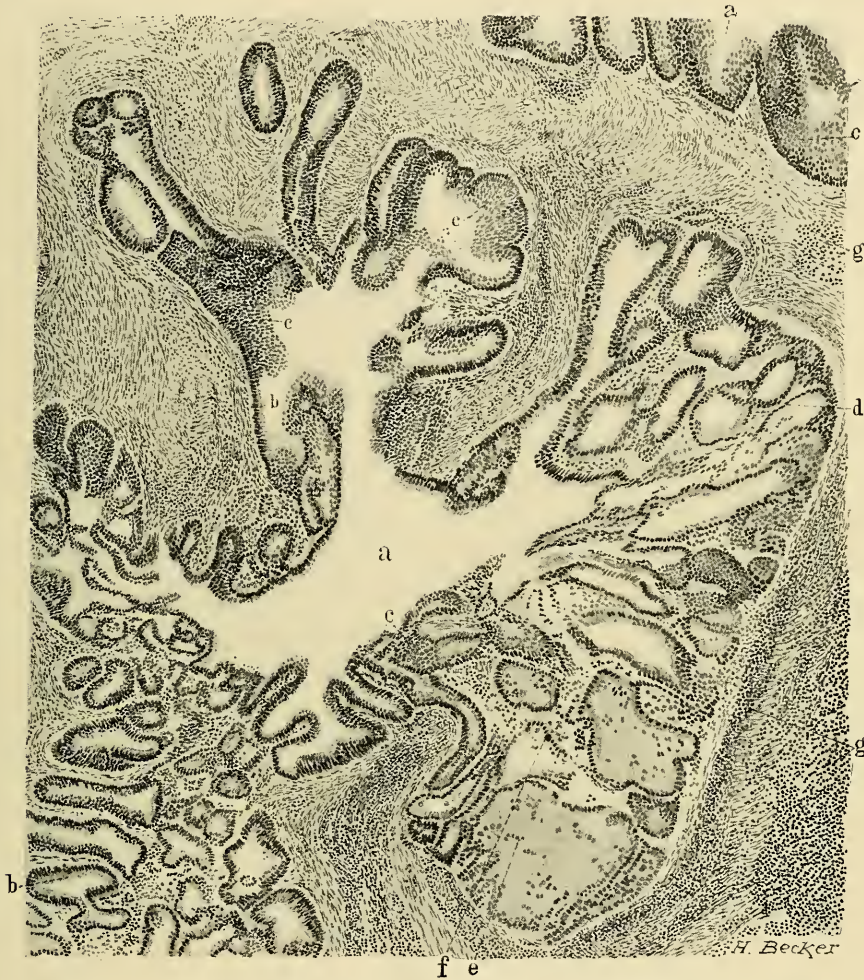

FIG. 153.—EARLY GLAND CHANGES IN ADENO-CARCINOMA OF THE CERVIX. (90 diameters.)

Gyn.-Path. No. 199. The section is taken from Fig. 152 at *L*. *a* is a greatly enlarged and convoluted gland with many small glands opening into it. These vary considerably in size and shape. Some, cut lengthwise, show the manner in which they empty into the central lumen. At *b* the characteristic high cylindrical cervical epithelium is still preserved; but at *c* there is much thickening, due in part to obliquity of the section, but in many places to undoubted cell proliferation. In numerous places, even where the gland is small, the epithelium is cuboidal or almost flat, as is well seen at *d*. At only one point (*f*) an enlarged and deeply staining nucleus is seen. Some of the glands are dilated and filled with mucus. Scattered throughout them are desquamated and swollen epithelial cells, as well as some small round cells, as seen at *e*. It will be noted that the stroma between the young glands is very scanty, and in some parts hardly appears at all. The cervical tissue in the upper part of the field shows only slight small-round-cell infiltration. At *g, g* large numbers of small round cells are present. For comparison, see the normal gland (Fig. 12). For the characteristic high cylindrical cervical epithelium, see Fig. 13.

From this section alone a diagnosis of adeno-carcinoma would not be justifiable, but a reference to the text will show that in the older portions of the growth the typical picture was present.

out in sharp contrast to the uterine muscle, being much lighter. The cervical mucosa just along the margin of the growth is slightly granular, but in other portions presents the usual appearance. The uterine walls are about 2 centimetres in thickness; the mucosa looks normal.

Histological Examination.—To get a clear picture of the condition present it is necessary to study the growth along its advancing margin and follow it toward the surface—the exact reverse of the usual procedure. On examining the deeper portions of the anterior lip, over which the squamous epithelium is still intact, the tissue is seen to contain markedly convoluted glands, which are lined by one or more layers of epithelium, having oval, deeply staining nuclei. Others of these glands have become so convoluted that secondary glands have been formed (Fig. 153). Where such is the case, the epithelium becomes much paler, and is usually only one layer in thickness; between the glands little or no stroma is present. Where the process is further advanced, the individual glands have become so closely packed together that they are distorted, and only on careful examination can the glandular arrangement be made out. On tracing the growth toward the surface, large or small irregular areas composed entirely of cells of the tumour are noted. The epithelial cells of which these are formed are profoundly altered from the normal; some contain small, round, vesicular nuclei, while in others they are large, irregular, and stain very deeply. At times two or more nuclei are seen in one cell. Not infrequently one sees a large, deeply staining mass of protoplasm containing an exceedingly dark nucleus. There is considerable karyorrhesis, and between the individual cells quite a number of small round cells are visible. Many of these large collections of tumour cells are subdivided, by trabeculæ composed of spindle-shaped cells, into smaller areas, which in turn may be still further subdivided.

The tumour cells along the margin of these trabeculæ show a peculiar tendency to assume irregular forms, and may appear as large or irregular plaques of protoplasm, containing three, four, or even five very deeply staining nuclei. Many nuclear figures are present. In nearly every section, on careful examination of these large areas, it will still be possible to find traces of a glandular arrangement. On the surface of the growth is a tree-like arrangement, there being a central stem from which many secondary branches spring. Lying next to the stem are many of the irregular and deeply staining cells, while enveloping it and its branches are large numbers of epithelial cells.

The growth is an adeno-carcinoma of the cervix. Macroscopically, it is interesting, inasmuch as from examination of the external os one would not for an instant suspect such a marked invasion of the cervical tissue. Histologically, were only one of these large homogeneous areas of cells examined, a diagnosis of squamous-cell carcinoma might be almost justifiable. The uterine mucosa is normal. Sections from the tube and ovary present nothing of interest. It is hardly possible that the entire growth has been removed.

D i a g n o s i s.—Adeno-carcinoma of the cervix.

Gyn. No. 3,356

Adeno-carcinoma of the cervix with a cauliflower growth filling the upper part of the vagina. General pelvic peritonitis; small cyst of the right ovary; on the left side a small tubo-ovarian cyst. Histological picture showing a large branching carcinomatous gland (Fig. 154). Combined vaginal and abdominal hysterectomy. Death from recurrence, four years and one month after operation.

M. H., aged thirty-two; white. Admitted March 2, 1895. Complaint: profuse uterine hæmorrhages.

The patient has been married twelve years, and has had four miscarriages. Her family and previous history are unimportant, and her menses up to the time of the present illness were normal.

Ten months ago, without previous warning, she had a profuse hæmorrhage, and at frequent intervals since then there has been a bloody discharge; in fact, at the present time she has two or three hæmorrhages a week. These are most severe after she has been on her feet for a long time. The patient is rather anæmic; the appetite is poor; the bowels are regular.

The vaginal outlet is relaxed. Springing from the anterior lip of the cervix is a fungating mass, which fills the upper part of the vagina. The posterior cervical lip is involved to a limited extent. The uterus is retroflexed, but is movable.

Operation, March 9, 1895. Combined vaginal and abdominal hysterectomy. Before commencing the operation a bougie was laid in each ureter, and the cauliflower-like mass curetted away with the finger. The cervix was then ringed, with great difficulty on account of the friability of the tissue. The abdomen was opened, the adherent omentum freed and turned back, and the appendages on either side were liberated from dense adhesions. The uterus was then removed in the usual manner, and the pelvis was washed out with normal salt solution. A gauze drain was inserted into the pelvic cavity, its lower end being brought out into the vagina. The abdominal incision was then closed. The patient was discharged May 3d, and at the time of her departure was in good condition, complained of no pain, and had no vaginal discharge.

Gyn.-Path. No. 619. The specimen consists of the uterus with its appendages. Both anteriorly and posteriorly the uterus is covered by numerous dense adhesions; attached to the fundus are tags of omental tissue. The cervix is 4 centimetres in diameter, and has surrounding it a rim of vaginal mucosa 5 millimetres in breadth. Almost the entire cervix is occupied by a bright-red growth consisting of large and small papillæ, some of which reach 11 millimetres in length. They are smooth and glistening. On cutting open the uterus, the new growth is seen to have extended upward to a point 1.5 centimetres within the external os. It is yellowish white in colour, presents a sharply defined advancing margin, and has scattered throughout it a few small, light-yellow dots. The uterine walls average 2 centimetres in thickness; the cavity measures 3.5 centimetres in length. The mucosa, as a whole, is pale in colour, but presents numerous bright-red areas,

evidently due to superficial hæmorrhage. It varies from 2 to 3.5 millimetres in thickness.

On the right side the tube is covered by numerous adhesions. In the parovarium is a cyst 3.5 centimetres in diameter. The ovary is mutilated. On the left side the tube and ovary have joined to form a tubo-ovarian cyst, which measures 5×5.5 centimetres. Attached to the outer surface of the tube are numerous omental adhesions.

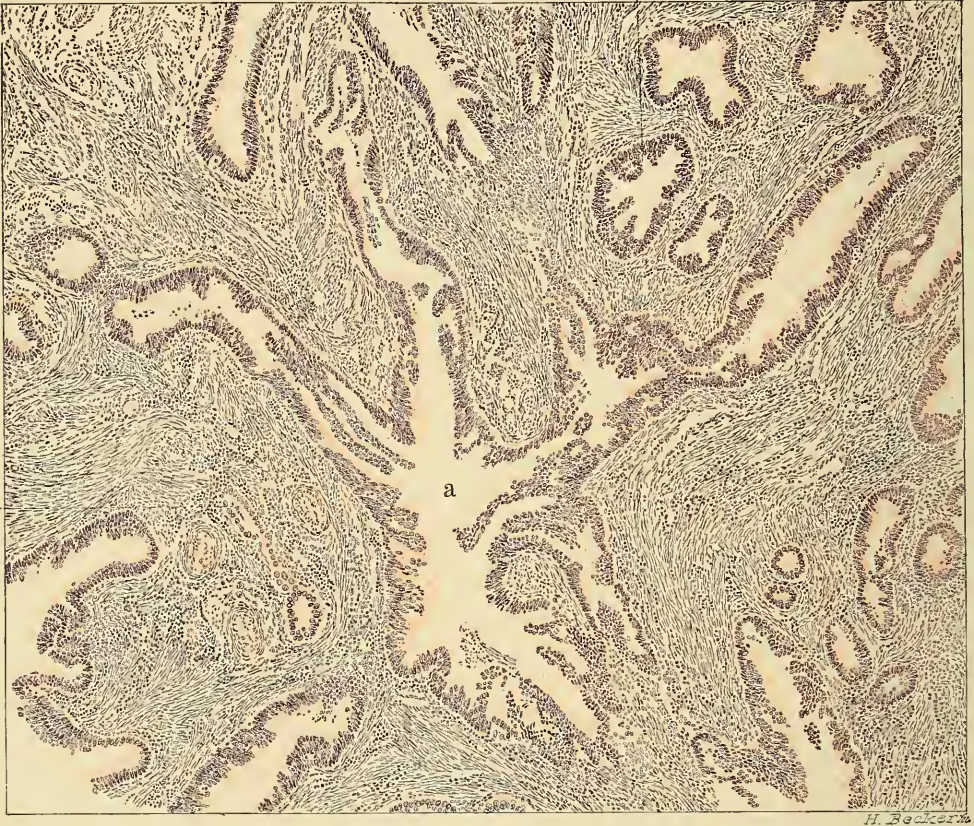


FIG. 154.—A GLAND SHOWING MARKED BRANCHING IN ADENO-CARCINOMA OF THE CERVIX. (75 diameters.)

Gyn-Path. No. 619. *a* is a large gland with long branching bays or outgrowths that can be traced upward, to the right, to the left, and downward. Here and there the epithelial lining is only one layer in thickness, but in most places it is gathered up into long and short, finger-like masses forming festoons. Surrounding these large glands are cross and oblique sections of many other glands. A cross section of one of the terminal branches in *a* would correspond very well with *b*. The nuclei in the epithelial cells of the growth are remarkable for their uniformity in size and staining affinities. The stroma of the cervix shows slight small-round-cell infiltration.

The gland arrangement and the teat-like epithelial outgrowths are sufficient to warrant a diagnosis of carcinoma, although the individual cells offer nothing suspicious.

Histological Examination.—The cervix along its free surface consists of necrotic tissue. The cervical stroma is everywhere infiltrated by glands, which are cut transversely, lengthwise, or obliquely. These glands show

marked branching, and in places are convoluted, having secondary glands opening into them; sometimes finger-like outgrowths are seen springing from their walls (Fig. 154). The glands are lined by one layer of cylindrical epithelium, the nuclei being situated directly at the bases of the cells. Where the glands are large, the epithelium becomes two or three layers, or even more, in thickness. Here and there the proliferation has been so extensive that the gland is completely obliterated. Many of the lumina contain polymorphonuclear leucocytes, while in some places the glands are considerably dilated and the epithelium has become cuboidal or almost flat. The growth extends upward to the uterine mucosa, from which, however, it is sharply defined. The stroma of the cervix shows considerable small-round-cell infiltration, especially around newly formed glands. It is highly probable that the growth has extended laterally into the broad ligament or into the vaginal vault, and that it has not been entirely removed. As can be gathered from the above description, the case is one of adeno-carcinoma.

The uterine mucosa shows considerable hæmorrhage in its superficial portions, and its vessels are dilated. On the whole, however, it must be considered normal.

The cyst occupying the right parovarium appears to be a dilated Graafian follicle. The tubo-ovarian cyst on the left side consists partly of tubal and partly of ovarian elements.

Diagnosis.—Adeno-carcinoma of the cervix. Right side: perisalpingitis and peri-öophoritis. Cyst, probably a dilated Graafian follicle. Left side: tubo-ovarian cyst.

This patient died in June, 1899, from a recurrence of the growth, four years and one month after operation.

Gyn. No. 3,616

Adeno-carcinoma of the cervix with extension to the vagina. General pelvic peritonitis. Tubo-ovarian abscess on the right side; encysted peritoneal fluid on the left side. Abdominal hysterectomy; transfusion of salt solution into the radial artery followed by sloughs in the arm and forearm. Histological picture (Fig. 155) showing markedly altered gland epithelium. Patient died from local recurrence in the vaginal vault four years and one month after operation.

S. E., aged thirty-nine; white. Admitted June 30, 1895. Complaint: abdominal tumour; profuse, yellowish, offensive discharge.

The patient has been married fourteen years; has had one instrumental labour, but no miscarriages. Her menses have always been regular and profuse; the last period began three weeks before admission.

Her family history is negative, and her previous history is unimportant.

In January, 1894, the patient had a profuse hæmorrhage, and was treated for "ulceration of the womb." For more than a year there has been an offensive, yellowish, vaginal discharge. She is well nourished; her mucous membranes are

of a good colour; her appetite is good. She has an occasional soreness in the lower part of the abdomen.

Operation, July 1st. Abdominal hysterectomy. On opening the abdomen the right side of the pelvis was found to be occupied by a pus sac, the left by a large cyst. After freeing the cyst from intestinal adhesions, the uterus was grasped and pulled upward toward the left, and on the right side was enucleated from dense adhesions. The pus sac ruptured, and there was a discharge of 180 cubic centimetres of fetid, yellow pus. The vessels in the right broad ligament were immediately controlled, but there was a great deal of bleeding from those in the cicatricial tissue. The cyst, which occupied the left side of the pelvis, was freed from many adhesions; the vagina was opened and the uterus freed on all sides. From the right side of the pelvis there was a very copious hæmorrhage, the blood filling the pelvis more rapidly than it could be sponged out. The right uterine artery and vein were controlled by three permanent clamps, and the abdomen was drained by large strips of gauze, which were brought out through the abdominal incision above, and from the pelvis into the vagina below. After operation it was impossible to make out the radial pulse, and 750 cubic centimetres of normal salt solution were introduced into the radial artery. The effect was immediate, the pulse being reduced from 160 to 130, and being readily demonstrable at the wrist.

On July 6th the clamps in the vagina were gently rocked from side to side and loosened with the utmost care. There was not the slightest trace of hæmorrhage. The patient was doing well, but complained of pain in the arm and forearm. On July 10th the arm was black along the line of the radial artery, and four days later there were two oval sloughs on the flexor surfaces of both the arm and forearm, the former being midway between the shoulder and elbow, the latter midway between the elbow and wrist.

On July 23d there was still a large amount of necrotic material in the sloughing areas.

The patient was discharged August 14th. On September 12th, when she returned from the sea-shore, the arm was much better, and the excavations were rapidly filling up with granulation tissue, but there was still some œdema of the fingers.

Gyn.-Path. No. 787. The specimen consists of the uterus, both tubes and ovaries, and a cyst from the left side. The uterus is slightly larger than normal, and both anteriorly and posteriorly is covered by dense adhesions. The cervical lips in their outer portion present a glazed appearance, and in the posterior lip there has been loss of tissue, with subsequent involvement of the vaginal wall. On section, the cervical canal is 3.5 centimetres in length. It is the seat of a new growth; the central portion is excavated, and presents a worm-eaten appearance. Those portions of the growth which are still solid appear to consist of small translucent granules, varying from a pin-point to 2.5 millimetres in diameter. The growth extends upward to the internal os, and is sharply defined from the uterine muscle. The uterine cavity is 4.5 centimetres in length, and the mucosa, which averages 3 millimetres in thickness, is roughened, granular, and of a reddish

colour. The right tube, after passing out a short distance, joins with the ovary, forming a tubo-ovarian mass $6 \times 4 \times 3.5$ centimetres. This mass is covered by many adhesions, is soft and yielding, while oozing from it in numerous places is dirty, greenish-yellow pus. The left tube and ovary are enveloped in adhesions, and posterior to the uterus is a cyst, 7 centimetres in diameter. This presents an area of omental adhesions 5 centimetres in diameter, and its walls average 1 millimetre in thickness.

Histological Examination.—A small amount of the squamous epithelium covering the vaginal portion of the cervix is still intact. The rough, worm-eaten surface is covered by necrotic material, in which many polymorphonuclear leucocytes and fragmented nuclei are seen. The stroma of the cervix is everywhere invaded by long, delicate glands, which in places show branching, and in other parts have been cut transversely. The cells of these glands are of the cuboidal or of the low cylindrical type; their nuclei are oval, and somewhat deeply staining. In many places the gland epithelium has proliferated, and the lumina are either partially or completely filled with cells of the new growth. At a few points, where the cylindrical epithelium of the cervix is still intact, a transition from the normal cells can be seen. Thus, while in one area they are normal, in another, not far distant, they are so altered as to be morphologically the same as cells of the new growths. In other places the cylindrical cervical epithelium can be seen projecting into the cervical canal, forming little teat-like masses. At some points the growth extends to the cut surface, and portions of it have certainly been left behind at operation. The stroma of the cervix everywhere shows small-round-cell infiltration. The growth is an adeno-carcinoma. The unevenness of the uterine mucosa appears to have been the result of mechanical injury. The mucosa itself is normal. The right tube is the seat of a typical subacute salpingitis, and the ovary contains miliary abscesses. Neither in the tube nor in the ovary can organisms be detected. There is some salpingitis of the left tube, and the cyst posterior to the uterus probably represents an encysted pelvic peritonitis.

Diagnosis.—Adeno-carcinoma of the cervix. Subacute salpingitis on the right side; miliary abscesses of the right ovary; general pelvic peritonitis.

The patient was admitted to Dr. Kelly's sanatorium, December 26, 1895, and on the following day a small recurrent nodule was removed from the vaginal vault. During the operation the peritoneal cavity was opened. She was discharged January 3, 1896.

Gyn.-Path. No. 1,042. The specimen consists of a considerable amount of uterine scrapings, which are suggestive of carcinomatous tissue.

Histological Examination.—Scattered throughout the stroma of the cervix are glands, which are long and narrow, or, as seen on cross section, are round. Many of them, however, are of an irregularly triangular or ovoid shape, and show considerable branching. The smaller glands are lined by one layer of epithelium, the nuclei being oval, or irregularly oval, and somewhat deeply staining. In most places it is hardly possible to distinguish the protoplasm of one cell from that of another, the one apparently fusing with the other. Some of the cells are swollen, and have very large laminated and deeply-staining nuclei (Fig. 155). Similar deeply-staining nuclei

are seen, especially along the advancing margin; in this situation, such glands as are present, under the low power, look almost like small dots. Where the glands have reached any considerable size, their epithelium has proliferated and

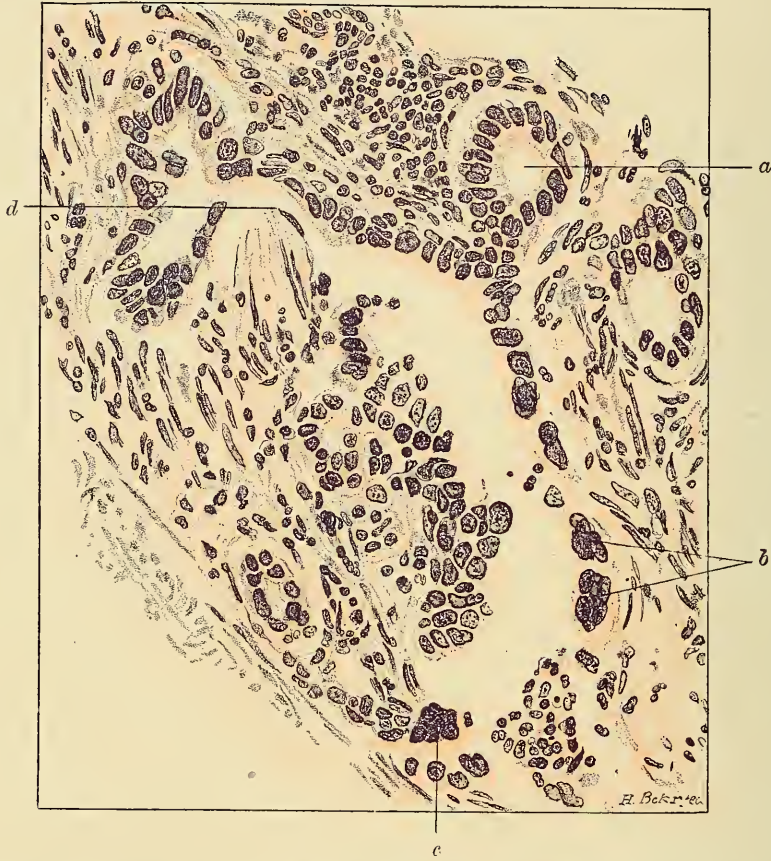

FIG. 155.—A CARCINOMATOUS GLAND IN ADENO-CARCINOMA OF THE CERVIX. (420 diameters.)

Gyn.-Path. No. 1,042. At *a* the epithelium of the small gland is comparatively uniform in size, and the nuclei vary only slightly. On tracing the epithelium downward, the nuclei are seen to be much larger, and irregular in contour, until at *b* we find one large mass of protoplasm containing two very large, lamellated, deeply staining nuclei. A similar nucleus is seen at *c*, while at *d* the cell is flattened and the nucleus is spindle-shaped. Between *c* and *d* the gland epithelium is several layers in thickness. The surrounding stroma consists of cells having spindle-shaped nuclei, and scattered through it are a moderate number of small round cells. At a few points it contains small carcinomatous glands.

Given such a gland as the one occupying the greater part of the field, the increase in size of the cells, together with the large, irregular, deeply staining nuclei, are sufficient to justify the diagnosis of carcinoma.

partially or completely fills the lumina. These nests bear considerable resemblance to those seen in squamous-cell carcinoma, but the cells are much swollen, and the nuclei are more homogeneous in their staining, not showing such a marked vesicular appearance. The stroma of the cervix shows, particularly along the advancing margin of the growth, small-round-cell infiltration. The case is clearly one of adeno-carcinoma of the cervix.

The patient died August, 1899, from a recurrence of the growth, four years and one month after operation.

Gyn. No. 4,232

Adeno-carcinoma, probably of the cervix; curettage six times; combined vaginal and abdominal hysterectomy. Death on the table apparently due to the anaesthetic.

N., aged sixty-four; white. Admitted March 18, 1896. Complaint: uterine hæmorrhages. The patient has had two children; her menses ceased at forty-five. One uncle died of carcinoma of the face. Her previous history is unimportant.

Shortly after the cessation of menstruation, nineteen years ago, she began to have uterine hæmorrhages, which occurred at irregular intervals after that time, sometimes every six weeks, with an occasional remission of a year. Three years ago the flow became very profuse, and lasted from October until January. For the last three months the hæmorrhage has been almost continuous. Between August, 1894, and October, 1895, the patient was curetted five times. Each operation was followed by relief, which was, however, of short duration. For several months she has complained of a sharp pain in the hips and lower part of the abdomen.

On admission she is very stout; the mucous membranes are of a good colour; the appetite is good, the bowels are regular. The outlet is much relaxed, the cervix is intact. The fundus is apparently not enlarged. It is, however, difficult to outline it on account of the thick abdominal walls.

The uterus was curetted for microscopical examination.

Operation, March 28th. On account of the marked obesity, the patient weighing two hundred and thirty-five pounds, it was thought best to remove the uterus through the vagina, which was very lax. After liberating the uterus to some extent on the left side, this route was abandoned, as the organ appeared to be firmly fixed in the pelvis. The patient did not take the ether well, and preparations for abdominal section were made as quickly as possible. The uterus was removed with little difficulty, but there was considerable oozing on the floor of the pelvis along the line of the vaginal incision. This necessitated raising the foot of the table as high as possible, but, as the patient breathed with difficulty in this position, the end was dropped to its former level. By this time the pulse, which before operation had been 96, had reached about 130. Strychnine and atropine were given hypodermically. All oozing having been controlled, the vagina was packed with gauze from above, and the incision was being closed, when the anæsthetizer noticed that the pulse had reached 140, and that it was very weak. The respirations were laboured, the patient was gasping, and her face was of a livid hue. Immediate attempts were made to induce artificial respiration, but the patient's weight proved to be a great disadvantage. The Sylvester method was tried, with only slight effect. After two minutes the pulse failed; the respirations gradually grew shallower and soon ceased.

Gyn.-Path. No. 1,117. The specimen consists of an exceedingly small quantity of uterine scrapings. On histological examination, it is found

that almost the entire specimen is made up of blood clot, there being only one or two minute pieces of tissue, which consist of stroma with glandular elements scattered throughout it. The glands are abundant, show an atypical convoluted appearance, and in places are gathered up into little clumps. They are lined by one layer of high cylindrical epithelial cells, which here and there have proliferated, completely filling the lumina. The stroma consists of cells having spindle-shaped nuclei; scattered throughout it are a good many small round cells. The tissue, on the whole, looks as if it came from the cervix; the diagnosis of adenocarcinoma can readily be made, notwithstanding the very small pieces sent for examination.

Diagnosis.—Adeno-carcinoma of the uterus, probably cervical in origin.

Gyn. No. 3,036

Adeno-carcinoma of the cervix, with a very friable cauliflower outgrowth.

A. S., aged forty-five; coloured. Admitted September 12, 1894. Complaint: frequent pain in the lower part of the abdomen.

The patient has been married twenty-eight years, and has had three children and no miscarriages. Her family history and her previous record are unimportant. Menstruation has always been regular.

About two months ago the patient noticed an abundant leucorrhœal discharge, and at the same time experienced some pain in the lower part of the abdomen; since then, between menstrual periods there has been a moderate amount of bloody discharge. On admission, the patient is debilitated, and she says that she has lost in weight and strength. Her appetite is variable; her tongue is coated and deeply fissured; the bowels are regular.

The vaginal outlet is markedly relaxed. Springing from the cervix is a cauliflower-shaped mass, 6 × 6 centimetres, which resembles placental tissue, and bleeds on the slightest manipulation. The uterus is about the size of that of a two months' pregnancy; on its posterior surface, at its junction with the left broad ligament, a nodule, about 1.5 centimetres in diameter, can be felt. Two similar nodules can be made out on the anterior surface. The left broad ligament is markedly indurated; the right shows less involvement.

Operation, September 13th. Curettement. The cauliflower-shaped mass was removed by means of the finger and a large sharp curette. After the operation the cervix presented a crater-like appearance. On the third day following the operation the temperature rose to 102.3° F., and fluctuated between 100° and 102.5° F. for about three weeks. The patient was discharged November 13th, somewhat improved.

Gyn.-Path. No. 445. The specimen consists of curettings from the cervix.

Histological Examination.—The tissue is everywhere invaded by glands cut both longitudinally and transversely. In places they are very small, looking like mere slits, and are lined by one layer of epithelium having large, oval nuclei. Many of the glands contain a moderate number of polymorphonuclear leucocytes, but frequently the epithelium has proliferated so extensively that the lumen is completely obliterated. In some portions of the specimen

the glands are exceedingly abundant, are closely packed together, and contain masses of protoplasm, in which four or five nuclei are present. In such areas there is practically no stroma separating the individual glands from each other. The stroma of the tissue shows considerable small-round-cell infiltration.

Diagnosis.—Adeno-carcinoma of the cervix.

Gyn. No. 3,712

Adeno-carcinoma of the cervix. Vagina filled with a necrotic mass the size of a foetal head, springing from the posterior cervical lip and vaginal vault. Douglas's cul-de-sac opened into during curettage.

M. L., aged thirty-seven; single, white. Admitted August 8, 1895. Complaint: frequent uterine hæmorrhages, and pain in the lower part of the back.

Her menses commenced at fifteen; they have been regular until recently, lasting from five to six days. For the last few months the flow has been profuse. Her mother and several of her aunts died of tuberculosis; the patient herself has always been healthy.

In March, 1895, she first noticed a sensation of heaviness in the rectum, and some pain on defecation. Within a short time the menstrual flow (?) became profuse. Since June she has had an offensive, irritating, thick, yellowish discharge, which is usually tinged with blood. The patient is debilitated and anæmic; the appetite is fair; the bowels are constipated. Defecation and micturition are painful, and there is constant aching in the hypogastric region. The vagina is distended with an offensive necrotic mass about the size of a foetal head. This springs from the posterior cervical lip and from the vaginal vault.

On August 9th the carcinomatous mass was curetted away with the finger. Douglas's cul-de-sac was opened during the operation. The growth had penetrated the recto-vaginal septum as far as the rectal mucosa. There was severe hæmorrhage, and at the close of the operation the patient was almost pulseless. She was discharged August 22, 1895, slightly improved.

Gyn.-Path. No. 838. The specimen comprises a large amount of tissue removed with the finger. The pieces vary considerably in size, the largest measuring $8 \times 5 \times 4$ centimetres. This tissue is very friable, has a yellowish-white or greenish colour, and for the most part consists of small, translucent areas, varying from a pin-point to 3 millimetres in diameter. Between these alveoli are numerous yellow foci.

Histological Examination.—The tissue has a definite stroma, scattered throughout which are many glands. These are arranged in groups, but may occur as single glands with secondary ones opening into them. They are lined by one layer of cylindrical epithelium, the protoplasm of which stains faintly with eosin, the nuclei of the cells being oval and staining somewhat deeply. The majority of the glands lie directly one against the other, there being no intervening stroma. In many of them the cells have proliferated, and partially or completely filled the gland lumen. In many places this proliferation of

cells is so great, that instead of a bunch of glands we find a large area completely filled with epithelial cells. The central portions of numerous glands contain necrotic material, fragments of nuclei, and an occasional polymorphonuclear leucocyte. Some of the smaller glands are filled with a granular material that stains faintly with eosin. Others contain a homogeneous material that takes the hæmatoxylin stain with avidity. The stroma is composed of spindle-shaped cells having elongate-oval nuclei. It has an abundant blood supply, and is slightly infiltrated with small round cells. Portions of the specimen have undergone complete necrosis.

Diagnosis.—Adeno-carcinoma of the cervix.

A RARE FORM OF ADENO-CARCINOMA OF THE CERVIX (ADENOMA MALIGNUM)

A rather unusual form of adeno-carcinoma of the cervix has been reported by Ruge and Veit.* “In the cervix as in the uterus there occurs, although rarely, a form of carcinoma which preserves to a considerable extent the simple glandular form; the glands are more or less closely packed together, penetrate deeply into the tissue, and are lined by one layer of delicate cylindrical epithelium. After operation, if the growth returns, it shows the same simple glandular form, and metastases in the vagina are similar to the mother tumour. These cases in their pure form are rare.”

C. Gebhard,† in 1895, reviewed this subject under the title *Malignant Adenoma of the Cervical Glands*. He collected all the cases reported up to that time, and after weeding out the doubtful instances, found that only four were typical—those of Williams (two cases), Ruge and Veit, and Bröse. Gebhard then reported two cases of his own.

CASE I.—Gebhard's first patient was fifty-four years of age. The uterus was enlarged, owing to the presence of a myoma; the lower part of the cervix had been converted into an ulcer. At the junction between the normal and diseased tissue was a zone composed of wart-like elevations, which were whitish in colour and projected into the canal. When the cervix was opened, it was seen that the diseased tissue was whiter and more opaque, and with the naked eye numerous lumina could be made out. The epithelium of the cervical glands did not everywhere present the typical characteristics. In the majority it was relatively low, and the cell protoplasm and the position of the nuclei suggested the normal epithelium of the body of the uterus. Some glands, however, showed high cylindrical cells with transparent protoplasm, with the nuclei situated at the bases. The blood-vessels were abundant. In Fig. 2 very long glands are seen, and the lumina are found to persist in nearly every portion of the specimen.

CASE II.—F. H., aged fifty-two. The posterior cervical lip was converted into a tumour the size of a plum. The surface was ulcerated, and bled freely on manipulation. On section, macroscopic changes in the cervix at first appeared to be absent, but on careful observation a zone several millimetres broad, and

* Ruge u. Veit. *Zeitschr. f. Geburtsh. u. Gynäk.*, 1882. Bd. vii, S. 170.

† Gebhard, C. *Ueber das maligne Adenom der Cervixdrüsen*. *Zeitschr. f. Geburtsh. u. Gynäk.*, 1895, Bd. xxxiii, S. 443.

possessing a thread-like structure, could be noted. Microscopically, where the eversion of the cervix had taken place, and also in the cervical canal, cylindrical epithelium was here and there present. The original fibro-muscular tissue of the cervix remained only as isolated narrow prolongations of spindle cells. Between these were numerous gland spaces of variable size. Some of the lumina were smaller than normal, while others were dilated and filled with coagulated secretion. Anastomoses and branchings of the glands occurred, but were not so frequent as in Gebhard's Case I. The epithelium was everywhere one layer in thickness. In the dilated glands the cells were cuboidal; in those of about the usual size they were of the high cylindrical type, with a clear protoplasm, and the nucleus situated at the base. At various points the epithelium was several layers in thickness, but nowhere had solid epithelial nests penetrated into the depth.

Gebhard's Cases I and II were alike, and in Case II a return of the growth occurred. The growth presents a characteristic appearance, and is well shown in Fig. 2, which accompanies Gebhard's article. The condition is seen still more clearly in Winter and Ruge's *Gynäkologische Diagnostik*, where the same photo-micrograph has been reproduced more distinctly.

R. Krukenberg* has recently reported two similar cases; one patient was forty-six, the other, thirty-two years of age.

In March, 1894, I received a uterus removed by Dr. Kelly in which a precisely similar condition was found.

Gyn. No. 2,625

Adeno-carcinoma of the cervix (malignant adenoma) (Figs. 156, 157, 158). Slight involvement of the vagina; extension to a uterine polyp (Fig. 159); involvement of the uterine cornua (Fig. 160). Vaginal hysterectomy. Sudden death, five months after operation.

S. H., aged forty-nine; white. Admitted March 2, 1894. Complaint: constant uterine hæmorrhage.

The patient has been married twenty-five years, and has had three normal labours. One cousin died of tuberculosis. The patient herself has always been healthy. Her menses commenced at thirteen; they were always regular until November, 1893, since which time there has been a continual flow until two weeks before admission. She has had no pain, but for the last six months has not been as robust as usual.

The patient is well nourished, her complexion is good, and the mucous membranes are of a normal colour; she eats well, and her bowels are regular. The vaginal outlet is moderately relaxed. The cervix, which is well back in the vault, is filled with nodular masses, which do not, however, project much from the surface. On the left side the vagina is somewhat incroached upon; the body of the uterus is small, and there is no evidence of any lateral infiltration.

* Krukenberg, R. *Zwei neue Fälle von Adenoma malignum der Cervixdrüsen*. *Monatschr. f. Geburtsh. u. Gynäk.*, 1897, Bd. v, S. 138.

Operation, March 5, 1894. Vaginal hysterectomy. On account of the marked involvement on the left side, a bougie was introduced into the ureter. The vaginal vault was ringed, care being taken to give the disease on the left side as wide a berth as possible. The uterus was then removed in the usual manner, but

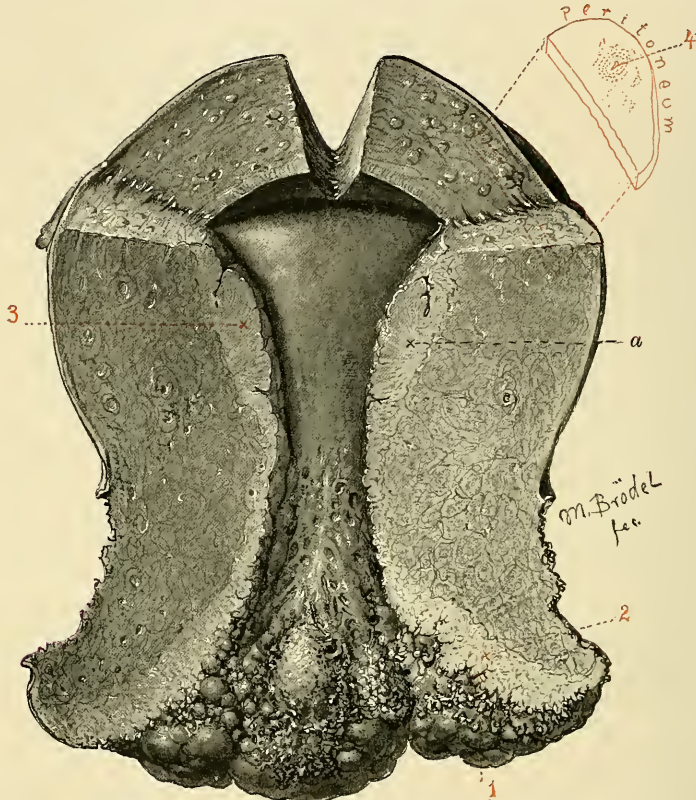


FIG. 156.—ADENO-CARCINOMA OF THE CERVIX WITH EXTENSION TO THE POLYP (*a*) AND TO BOTH UTERINE HORNS. (Natural size.)

Gyn.-Path. No. 195. The cervix is considerably enlarged, and presents a rough, uneven surface, due to dome-like elevations varying in size from a pin's head to 5 or more millimetres in diameter, between which are a few finger-like projections. The growth has apparently penetrated the cervix for a distance of from 2 to 10 millimetres, and on one side has advanced almost to the cut surface. The cervical mucosa, near the internal os, presents the usual arborescent appearance. The uterine walls are slightly thickened. The mucosa of the posterior wall is apparently normal. Projecting slightly from the anterior wall is a polyp (*a*).

This seems to be a most favourable case for operation, but Fig. 159 shows that carcinomatous masses are present at 3, while Fig. 160 shows their presence at 4. Such a demonstration as this should thoroughly convert those few surgeons who still advocate amputation of the cervix in "favourable cases."

the operation was very difficult on account of the extensive involvement. The bougie was withdrawn without difficulty, but the ligatures had been placed very close to the ureter. For several days after the operation the patient had severe abdominal pain, which was paroxysmal in character, and necessitated the frequent administration of morphine. The pack was removed with difficulty on March 7th, and was free from odour. The patient left the hospital April 14, 1894, and died suddenly five months after the operation.

Gyn.-Path. No. 195. The specimen consists of the uterus, which measures $10 \times 6 \times 5$ centimetres. Both the anterior and posterior surfaces are smooth. When the uterus is opened, the lower half of the cervix is found to be converted into a raw, worm-eaten-like tissue (Fig. 156). This condition is especially noticeable along the posterior lip. On examining one of these worm-eaten areas, it is found to consist of delicate knob-like or papillary masses, which are directly continuous with the underlying growth. The cervix, both anteriorly and posteriorly, is invaded to a depth of from 2 to 10 millimetres; laterally the growth

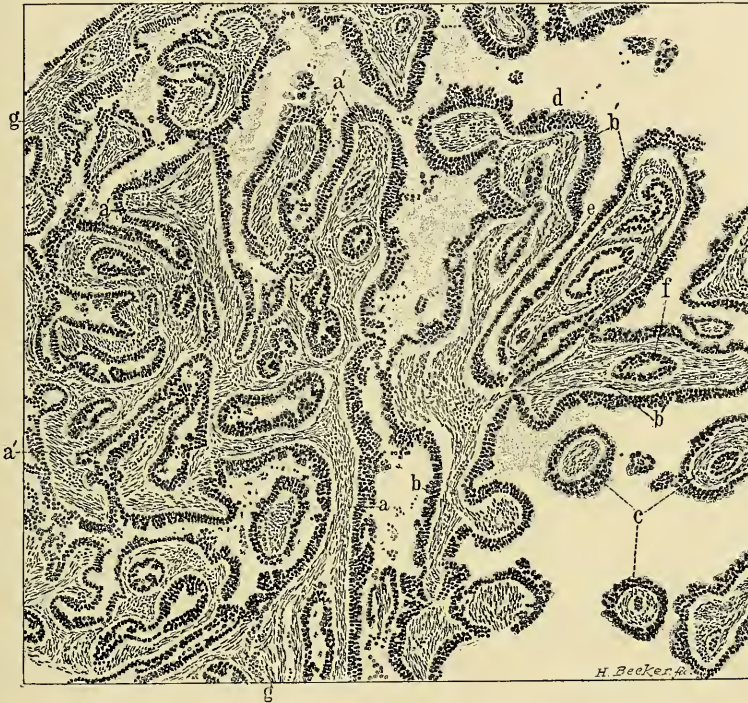


FIG. 157.—ADENO-CARCINOMA OF THE CERVIX. (80 diameters.)

Gyn.-Path. No. 195. The section is taken from the surface of the growth in Fig. 156 at 1. Almost the entire field is made up of the main trunks *a* and *b*, which send off the many terminal branches *a'* and *b'*. *c* indicates cross sections of terminal outgrowths. The stroma (*g*) of the stems consists of elongate cells with spindle-shaped nuclei. Covering the outer surfaces of the main trunks and terminals, in many places, are several layers of epithelium, as seen at *d*; but in the narrow chinks often only one layer is present, as at *e*. The epithelial cells have fairly uniform small, round or oval, deeply staining nuclei, and it is impossible to differentiate the protoplasm of one cell from that of its neighbour. Scattered through the stroma of the terminal folds are irregular gland-like spaces lined by one or more layers of this characteristic epithelium. These are undoubtedly indentations from the surface at another level. The abundance of the stroma accounts for the firmness of the cervix. It will be noted that there is no breaking down of tissue or infiltration with small round cells. The glands in Fig. 158 are in reality a continuation of the spaces between the stems passing into the depths, and the epithelium covering the outgrowths is directly continuous with that lining the deep glands.

Benign processes presenting this picture never occur in the cervix, and the presence of the growth in the body of the uterus and in the uterine horn, as seen in Figs. 159 and 160, clinch the diagnosis.

extends to within at least 1 millimetre of the line of incision. The neoplasm along its advancing margin presents an irregular outline, and has almost the

consistence of cartilage. The uterine walls average 2.5 centimetres in thickness. Scattered everywhere throughout the mucosa, which is pale in colour, are small cyst-like elevations, averaging 3 millimetres in diameter and containing a translucent material. In the body of the uterus is a sessile polyp, 1 centimetre in diameter.

Histological Examination.—The squamous epithelium along the margin of the growth is partially preserved. The surface of the growth is composed of long papillary-like folds which have innumerable branches (Fig. 157). The stroma of these is composed of spindle-shaped cells cut longitudinally and transversely. The fold with its secondary branches is covered by epithelium.

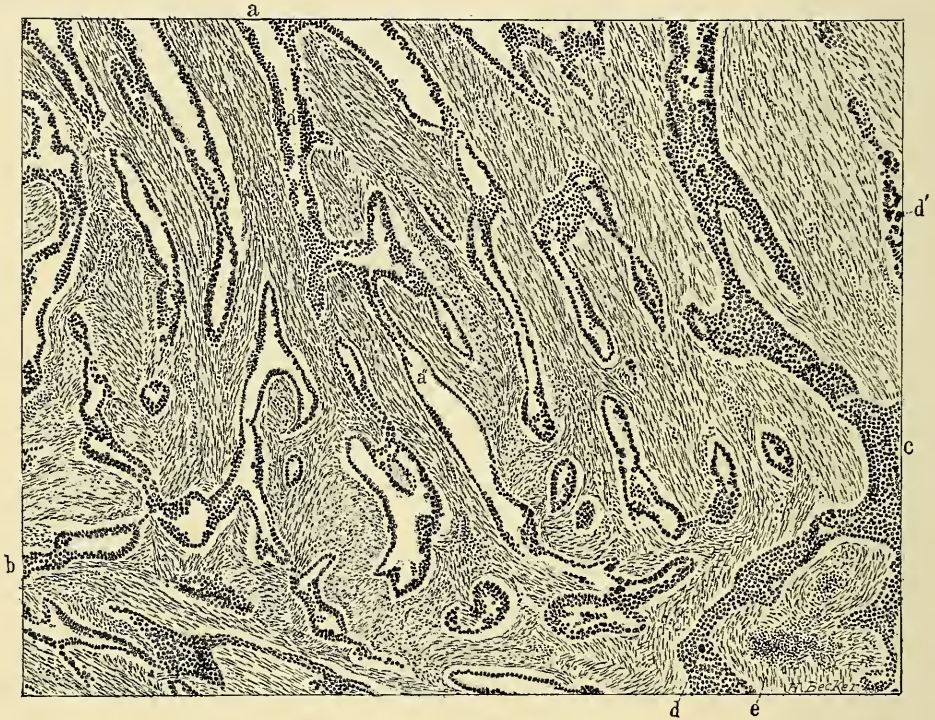


FIG. 158.—ADENO-CARCINOMA OF THE CERVIX. (80 diameters.)

Gyn.-Path. No. 195. The section is taken from Fig. 156 at 2. One is immediately impressed with the sharp and clear-cut details, the section consisting of stroma everywhere penetrated by glands. The glands, fortunately, have been cut lengthwise, and it was possible to trace the continuity of the epithelium covering the branching-out growths, seen in Fig. 157, with that lining the glands. The glands branch in all directions, as seen at *a* and *b*, where the numerous ramifications are depicted. The glands are lined by one or more layers of cells having small, round, deeply staining nuclei. Here, as also in Fig. 157, it is impossible to differentiate the protoplasm of one cell from that of its neighbour. At *a* the gland is lined by three layers of cells; at *a'* by five or more layers. A little farther on, the section is through the gland wall. At *a''* there is a lining of only one layer. The gland indicated by *c* has been cut along its margin throughout almost its entire length, and it therefore appears as a solid cylinder of cells. At *d* and *d'* the nuclei are increased in size and are particularly rich in chromatin. The stroma consists of cells with spindle-shaped nuclei. Practically the only evidence of small-round-cell infiltration is at *e*. Figs. 157 and 158, taken together, enable one to give a positive diagnosis of carcinoma.

The nuclei of the epithelial cells are oval, elongate-oval, or irregular, and stain very deeply. In most places this epithelium is two or three layers in thickness,

and is frequently gathered up into little tufts. On the surface of the specimen many of the papillary-like folds have been cut transversely, and appear as small

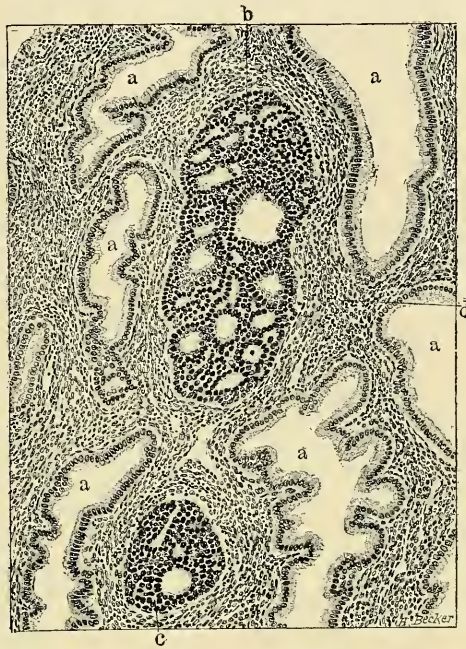


FIG. 159.—ADENO-CARCINOMA IN A UTERINE POLYP SECONDARY TO ADENO-CARCINOMA OF THE CERVIX. (105 diameters.)

Gyn.-Path. No. 195. The section is taken from the polyp in the body of the uterus at 3. The normal glands are indicated by *a*; the lower ones are slightly convoluted, and all are lined by one layer of moderately high cylindrical epithelium containing oval nuclei. The stroma presents the usual appearance except at *d*, where there is a slight infiltration with polymorphonuclear leucocytes. *b* and *c* are areas composed of epithelial cells, containing nuclei that are very uniform in size and stain deeply. In *b* the gland arrangement is very evident, but it will be noted that there is no stroma between the glands, one lying against the other, or being separated by only a few layers of epithelial cells. In *c* only one gland space is visible. Both *b* and *c* are areas of adeno-carcinoma, which are extensions from the original growth in the cervix. (See Figs. 157 and 158.) The cells in this secondary growth closely resemble those of the primary tumour, and their capacity for forming glands is still well preserved.

or round oval masses of stroma containing from one to six or seven blood-vessels. Externally they are covered by one or more layers of epithelium. The epithelium covering the surface of the papillary masses penetrates the underlying cervical stroma in all directions. The down-growth is in the form of glands, which are cut lengthwise or transversely (Fig. 158). These glands assume almost any form, on longitudinal section being cylindrical or showing many branchings. The smaller glands are lined by one layer of cells which stain deeply. The nuclei, as a rule, are large and deeply staining, and it is rarely possible to find two nuclei just alike. It is impossible to differentiate the protoplasm of one cell from that of another. Here and there two or three nuclei are apparently bunched together in one mass of protoplasm. Along the advancing margin the glands are exceedingly minute, and in some places the cells penetrate as a single

row. In many glands the epithelium has spread into the lumen, being two or three layers in thickness, and not infrequently the lumen is partly or completely filled with solid masses of epithelial cells. The growth has extended out into the broad ligament, and is among the most virulent in our experience. The stroma of the cervix shows very little small-round-cell infiltration. The surface of the uterine mucosa is slightly undulating, but the epithelium is still intact. The glands are abundant, and are somewhat convoluted. The polyp consists of uterine mucosa. On examining both the mucosa and the polyp, one instantly notices dark-staining masses of cells, that contrast sharply with the uterine glands (Fig. 159). Some of these masses are situated in close proximity to the blood-vessels, others being scattered irregularly through the stroma. Certain

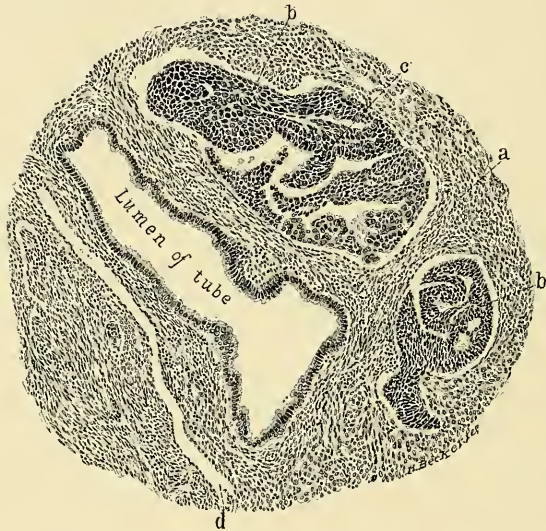

FIG. 160.—ADENO-CARCINOMA IN THE UTERINE HORN SECONDARY TO ADENO-CARCINOMA OF THE CERVIX. (85 diameters.)

Gyn.-Path. No. 195. This section is taken from Fig. 156 at 4. Near the centre is the lumen of the tube, which is, as usual, irregularly circular or slit-like at this point and lined by one layer of cylindrical epithelium. *a* is the normal uterine muscle. Just to the right of the tube are two darkly staining areas (*b, b'*), composed of masses of epithelial cells. The nuclei of these cells vary considerably in size, some being spindle-shaped and rather compressed, while others are round or oval and rather plump. All stain deeply. There is no distinct glandular arrangement, but at *c* a tendency toward a finger-like outgrowth is shown. Both masses of cells are from the carcinomatous growth in the cervix, and are contained in spaces apparently lined by one layer of flattened cells, probably lymph spaces.

From this section alone a malignant growth might very justly be diagnosed, but whether it is a sarcoma or a carcinoma it would be impossible to decide without referring to the primary tumour.

areas consist of glands that are lined by one layer of epithelium; in others the epithelium has so proliferated that the gland lumen is partially or completely filled. In either uterine cornu, just external to the lumen of the tube, are small masses of the new growth (Fig. 160). All of these dark-staining areas present appearances typical of adeno-carcinoma.

Diagnosis.—Adeno-carcinoma of the cervix; secondary involvement of the uterine wall, mucosa, and both uterine cornua.

This is an exceedingly rare form of adeno-carcinoma of the cervix. From the appearance of the surface of the growth we should have hesitated to call it an adeno-carcinoma, but the presence of the myriads of glands in the depth, and the distinctly glandular type of the secondary growths in the mucosa and in the uterine cornua, leave absolutely no doubt as to its proper classification.

The main features, then, were as follows: Although the growth was far advanced, little breaking down had occurred. Springing from the superficial portions of the growth were branching papillæ, covered by one layer of epithelium. The cervical tissue was everywhere invaded by branching glands, in most places lined by one layer of epithelium that was directly continuous with that covering the papillæ—in other words, the glands in the depth could be traced directly to the surface of the growth. That the tumour was very malignant is proved by the metastases found in a uterine polyp and in both uterine horns, these conforming closely to the mother type.

Although this is undoubtedly an unusual form of carcinoma, it does not seem expedient to look upon it as a distinct variety, but rather to include it under the general class—adeno-carcinoma. All the foregoing cases of carcinomata arising from the cylindrical epithelium of the cervix have been glandular in type and have been malignant; hence the designation adeno-carcinoma. In the variety described by Ruge and Veit and by Gebhard, there was also an abnormal proliferation of epithelium, an invasion of the underlying tissue, and in addition the formation of metastases. The fact that the glands are arranged in a slightly different manner, and that they usually, although not always, tend to have but one layer of epithelium, would hardly warrant us in classifying these growths under an entirely separate heading, and it would seem advisable to consider them as merely a variety of adeno-carcinoma of the cervix. From a clinical standpoint this was the most malignant case of carcinoma of our series.

PYOMETRA ASSOCIATED WITH ADENO-CARCINOMA OF THE CERVIX

In Chapter IV (p. 40) we considered the occurrence of pyometra in squamous-cell carcinoma of the cervix, and found that it was due to an occlusion of the cervical canal by the carcinomatous tissue. The uterine cavity becomes dilated as a result of the dammed-up secretion, and the contents become purulent. This is precisely what may also occur in adeno-carcinoma of the cervix. A good illustration is offered by Case 1,964 (Fig. 161, p. 313), in which the uterine cavity contained about 500 cubic centimetres of a fetid, thick, yellow pus, having an odour resembling that of garlic.

Cases of Pyometra occurring in Adeno-carcinoma of the Cervix

Gyn. No. 2,954

Adeno-carcinoma of the uterus, probably cervical in origin. Slight pyometra; curettage.

L. B., aged sixty-eight; coloured. Admitted July 30, 1894. Complaint: frequent uterine hæmorrhages; offensive leucorrhœal discharge; constant pain in the lower abdomen.

The patient has had six children and two miscarriages. The menses ceased sixteen years ago.

In 1891 she noticed a frequent, almost constant, bloody uterine discharge. This has been most pronounced during the last six months, and associated with the blood there has been a purulent fluid.

On admission the patient was very much emaciated; the mucous membranes were pale; the bowels were constipated; micturition was painful. She complained of constant pain in the lower abdomen and pelvis, which also radiated to the lower extremities. The uterus was curetted on August 1st, and a good deal of tissue removed. There was also a discharge of pus from the uterine cavity.

Gyn.-Path. No. 407. The specimen consists of uterine scrapings, which macroscopically present nothing distinctive. The stroma of the specimen is composed of cells, which for the most part have spindle-shaped nuclei. Scattered throughout the tissue are small alveoli filled with large cells having oval nuclei. Examination of other sections shows that the tissue contains numerous glands, which occur singly or in bunches. They are lined by low, cylindrical epithelium.

Diagnosis.—Adeno-carcinoma of the uterus, most probably originating in the cervix.

Gyn. No. 1,964

Adeno-carcinoma of the cervix. A friable cauliflower growth springing from the cervix; extension to the vaginal vault and broad ligaments; pyometra (Fig. 161). The uterine cavity contained 500 cubic centimetres of fetid, yellow pus. Curettage, with evacuation of the uterine contents. Accidental puncture of the vesico-uterine septum, the finger entering the abdominal cavity anterior to the uterus. The patient left the hospital three weeks later.

S. R., aged sixty-three; white. Admitted May 4, 1893. Complaint: bearing-down pain in the lower part of the abdomen, with profuse uterine discharge.

The patient has been married forty-three years; she has had four normal labours and two miscarriages. The family history is negative, and the patient has always been healthy.

In March, 1893, she noticed a slight hæmorrhagic discharge, which was shortly afterward followed by a copious flow; at present the discharge is yellow and non-offensive. On vaginal examination the outlet is found to be relaxed. Occupying the upper part of the vagina is a large, fungating, very friable mass, which springs from the cervix. The disease has extended to the vaginal vault, and the broad ligaments are apparently involved.

Operation, May 8, 1893. The growth involves the entire cervix. In curetting away the carcinomatous tissue the uterine cavity was broken into, and there was a discharge of about 500 cubic centimetres of fetid, thick, yellow pus (Fig. 161), the odour of which resembled that of garlic. Scattered throughout the pus were small clumps and streaks of mucus. The uterine cavity was thoroughly washed out through the opening made in its wall, and packed with iodoform gauze.

On May 24th the cervix was again curetted, and, on account of the friable condition of the tissues, the curetting finger punctured the vesico-uterine septum, and entered the abdominal cavity. The opening was carefully packed with iodoform gauze. On May 26th the abdo-

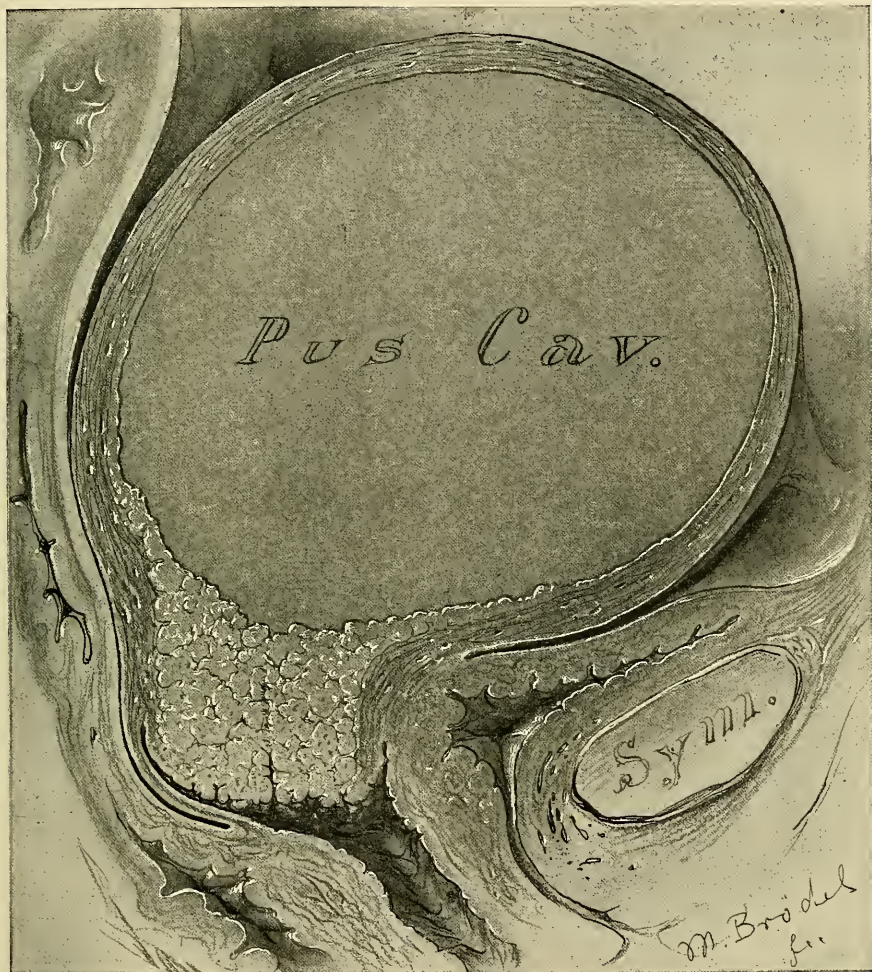


FIG. 161.—PYOMETRA ASSOCIATED WITH ADENO-CARCINOMA OF THE CERVIX.

Schematic clinical picture. Almost the entire cervix and a small portion of the body of the uterus are occupied by a new growth. The cervical canal is totally obliterated. The body of the uterus is globular, and about the size of that of a four-months' pregnancy. Its walls are thinned, owing to distention, and the uterine cavity is filled with pus. Both the bladder and rectum are free from the growth.

When such a condition is present, by pushing the dilator gently through the cervix, free evacuation can readily be secured. Unfortunately, it is only rarely that we find so ideal a case, since, as a rule, either the bladder or rectum is implicated before pyometra develops, and then in endeavouring to empty the uterine cavity the instrument may penetrate into the other organ involved.

men was swollen, and the patient was perspiring profusely. On May 31st, when the vaginal pack was changed, there was a moderate amount of very offensive discharge. The patient was removed from the hospital June 13th. She was

unable to walk, presented a cachectic appearance, was still troubled with the discharge, but was suffering little or no pain.

Gyn.-Path. No. 6. The specimen consists of tissue curetted away from the cervix.

Histological Examination.—The surface of the specimen shows marked small-round-cell and polymorphonuclear infiltration. Scattered throughout the stroma of the cervix are glands, which sometimes occur singly, but are usually found in clusters of four or more. Where the glands are cut lengthwise, they appear to be convoluted, and have numerous branchings. Most of them are lined by one layer of high cylindrical epithelium. The protoplasm of the cells takes the eosin stain; the nuclei are oval, stain somewhat deeply, and many of them show nuclear division. In some places the epithelium is proliferating, and has almost completely filled the gland lumen. Scattered throughout the stroma of the cervix are numerous areas of rarefaction; traversing these are delicate fibrillæ, the intervening spaces being filled with a homogeneous material that takes the hæmatoxylin stain. These areas resemble mucoid tissue. The picture is one of adeno-carcinoma. From the specimen it is impossible to tell how far the disease has advanced, but the glands extend throughout the section, and can be traced to the very edge.

Diagnosis.—Adeno-carcinoma of the cervix.

EXTENSION OF ADENO-CARCINOMA INTO A VEIN

The involvement of the lymph channels is not rare, but a direct growth into a blood-vessel is seldom met with. In all our examinations of carcinomata, whether from the cervix or body of the uterus, this condition was only once seen. In Case 3,923 a clump of carcinoma cells projected into and partially obliterated a vein (Fig. 164). Where the growth projected into the vessel no endothelial lining was visible, but on the opposite side it was still preserved. The entire picture bore a striking resemblance to a glomerulus, the rounded mass of carcinoma cells corresponding to the glomerular body, and the vessel wall to the capsule. The carcinoma cells had large, oval, vesicular nuclei, and stood out in sharp contrast to the neighbouring tissue. Surrounding the vessel was a dense zone of small-round-cell infiltration.

Gyn. No. 3,923

Adeno-carcinoma of the cervix (Fig. 162). Slight extension to the vaginal vault; general pelvic peritonitis; abdominal hysterectomy with removal of pelvic lymph glands; histological picture showing carcinomatous uterine glands (Fig. 163); extension of the carcinoma into a blood-vessel in the broad ligament (Fig. 164). The patient died three months after leaving the hospital.

E. J. C., aged fifty-three; white. Admitted October 30, 1895. Complaint: a bloody vaginal discharge.

The patient has been married thirty years; she has had one child and one miscarriage. Her menses, which had always been regular, ceased one year ago. One sister died of phthisis, and her grandfather of carcinoma.

For five months she has had a thick, yellow, offensive, irritating discharge; two months ago it began to be tinged with blood. The blood is usually more noticeable after exertion. The patient complains of some pain, and has lost flesh; the appetite is fair and the bowels are regular.

The vaginal outlet is intact, but the cervix is occupied by a carcinomatous growth, which slightly involves the vaginal walls. The ligaments appear to be somewhat thickened.

As a preliminary treatment, the cervix was curetted October 31st. Little or no bleeding followed.

Operation, November 2d. Abdominal hysterectomy. On November 11th there was some breaking down along the line of the abdominal incision, followed by the discharge of a considerable quantity of green, foul-smelling pus.

The patient made a good recovery, and was discharged December 3, 1895.

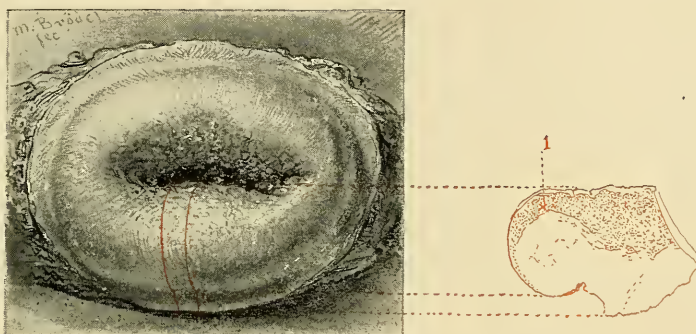


FIG. 162.—ADENO-CARCINOMA OF THE CERVIX. ONLY SLIGHT INVOLVEMENT OF THE VAGINAL PORTION.
(Natural size.)

Gyn.-Path. No. 951. The general outlines of the cervix are perfectly preserved. The mucosa of the vaginal portion is intact. The external os is moderately dilated, and through it part of the ragged cervical growth is just visible. The sketch on the right indicates the depth to which the cervical tissue is invaded by the growth. Although the vaginal portion is still intact, it is involved to a depth of at least 2 or 3 millimetres. The speculum would give little information in this case, and for a positive diagnosis a microscopical examination of curettings would be necessary.

Gyn.-Path. No. 951. The specimen consists of the uterus with intact appendages, together with the pelvic glands. The uterus is slightly larger than usual, and is covered by dense adhesions. The cervix is 4.5 centimetres in breadth. Its vaginal portion is intact, but presents a glazed appearance. The external os is dilated, and through it the dark-red and worm-eaten cervical canal can be seen (Fig. 162). On section, the cervix is found to be everywhere infiltrated by a new growth, which on the left side has broken down, leaving a deep excavation, while projecting from the anterior wall of the right side is an irregular mass, measuring $3 \times 2 \times 1$ centimetres. Almost the entire surface of the cervical canal is covered by a greenish, homogeneous, apparently necrotic material. On the right side only is there a small portion of the mucosa remaining; this contains numerous dilated glands. The uterine cavity is 3 centimetres in length; its mucosa presents a slightly granular appearance, but is smooth and glistening. Projecting into the cavity near the left cornu is a polyp, 4×1 centimetres. The

appendages on both sides are covered by adhesions. The two lymph glands accompanying the specimen are about 3×1.5 centimetres; both are rather firm on pressure.

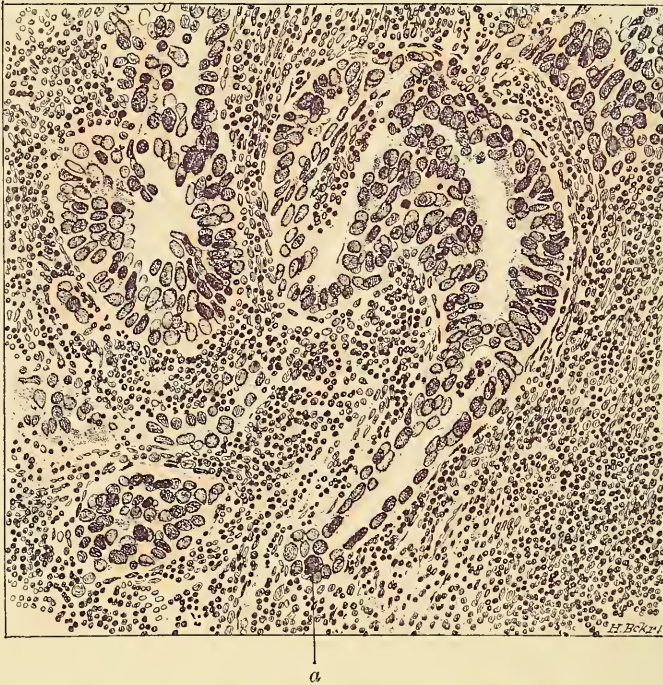


FIG. 163.—CARCINOMATOUS GLANDS IN ADENO-CARCINOMA OF THE CERVIX. (160 diameters.)

Gyn.-Path. No. 951. The section is from Fig. 162 at *l*. Occupying the centre is a large gland, in its upper portion lined by many layers of cells, containing large, vesicular, or deeply staining nuclei. In the lower portion only one layer of cells is present. At the tip, of what is probably the advancing wedge, is a large nucleus containing much chromatin. To the right and left of this gland are other glands lined by several layers of these large cells. In the lower left-hand corner are solid nests of epithelial cells. The stroma shows an abundant small-round-cell infiltration. Knowing, as we do, that this section comes from the cervix, the many layers of cells lining the glands, the solid nests, and the large, deeply staining nuclei, are sufficient to warrant a diagnosis of adeno-carcinoma.

Histological Examination.—A section through the left side of the anterior lip shows that the squamous epithelium covering the vaginal portion is intact; but as one approaches the external os, it is wanting, and the surface is covered by canalized fibrin, containing polymorphonuclear leucocytes in its meshes. Just within the external os the cervical glands are seen to be much altered; they show marked convolution, and have increased in number. On examining a longitudinal section of one of these glands, it appears as an oval body composed of many smaller glands, cut both longitudinally and transversely. These tend to open into a central canal. Many of the glands give off secondary branches. All are lined by one layer of high cylindrical epithelium resembling that of the normal cervical glands. Where the growth is well advanced, the gland epithelium is gathered up into folds and almost completely fills the cavity. The nuclei of the cells are oval, stain somewhat deeply, and are fully three times

as large as in other portions of the growth; in some of the cells two nuclei are present. The glands do not all present the usual outline, but may assume various forms. Thus in its superficial portions the lumen may be convoluted, and have a lining of three or more layers of cells. As it passes into the depth, the gland may push its way down as a finger-like growth, somewhat resembling a wedge. The epithelial lining gradually becomes thinner and thinner, until the walls are lined by but one layer of cells, and the tip of the wedge, or advancing point, consists of a large mass of protoplasm containing a deeply staining nucleus (Fig. 163, *a*). Other portions of the growth, especially in the anterior lip, show that almost the entire tissue is composed of small glands. In these portions it is rather difficult to get the typical glandular outline. Along the advancing margin are masses of protoplasm lying free in the stroma. These contain one or more large, deeply staining nuclei. Throughout the cervix there is considerable small-round-cell infiltration. As one passes toward the broad ligament, numerous oval or round masses of cells of the new growth are seen, usually lying in the vicinity of blood-vessels. One clump of these cells is perfectly free in an irregular cavity, lined by

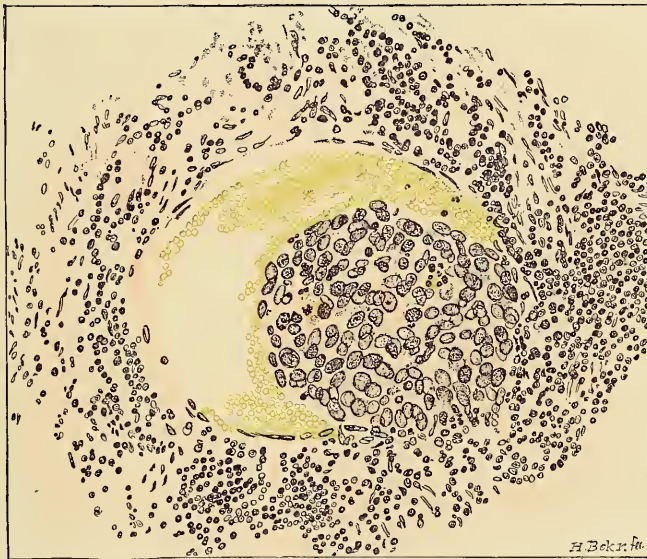

FIG. 164.—A MASS OF CANCER CELLS PROJECTING INTO A BLOOD-VESSEL OF THE BROAD LIGAMENT, IN A CASE OF ADENO-CARCINOMA OF THE CERVIX. (240 diameters.)

Gyn.-Path. No. 951. This cancerous mass is made up of cells containing oval, vesicular nuclei, with here and there one that stains deeply. Compare these cells with those of the primary growth (Fig. 163). Between the epithelial cells are a few polymorphonuclear leucocytes, small round cells, and red blood-corpuscles. This mass is firmly adherent to the underlying stroma, and has evidently projected in from the outside, notwithstanding the fact that its protruding surface is not covered by the endothelium of the blood-vessel. The vessel is evidently a vein, as its wall is composed of a single layer of endothelium. The entire picture reminds one of a glomerulus, with an accumulation between the glomerular body and its capsule. The surrounding connective tissue is abundantly infiltrated with small round cells.

one layer of endothelium, probably a lymph space; another projects into and partially obliterates a vein (Fig. 164). Where the mass projects into the vessel no endothelial lining of the wall is visible, but on the opposite side

this is preserved. The vessel is still partly filled with blood. The entire picture bears a striking resemblance to a glomerulus. The growth extends upward to the internal os, but laterally appears to have been entirely removed. There is, however, some doubt on this point. It is a typical adeno-carcinoma of the cervix. The uterine mucosa is normal. The right tube, beyond being covered by adhesions, presents the usual appearance, and the ovary is unaltered. The left tube is the seat of an old salpingitis. The left ovary is normal. The cells of the lymph gland are somewhat swollen, but there is no evidence whatever of carcinomatous involvement.

Diagnosis.—Adeno-carcinoma of the cervix. General pelvic adhesions. [The daughter writes me that the patient died just three months after leaving the hospital.]

EXTENSION OF ADENO-CARCINOMA TO THE LYMPH CHANNELS

As is generally known, the disease reaches the lymph glands by way of the lymphatics, and hence must pass through the lymph channels. These usually lie in close relation to the blood-vessels, and small masses of carcinoma cells may be seen lying free in a cavity situated near one of the vessels and lined by one layer of endothelium. Such a mass was seen in a lymph channel in Case 3,923 (p. 317).

CONDITION OF THE UTERINE MUCOSA IN ADENO-CARCINOMA OF THE CERVIX

Out of eight of our cases in which the uterus could be thoroughly studied, in four the mucosa was perfectly normal. In Case 3,356 (p. 295) there was slight ecchymosis, but this might very readily have been caused in handling the uterus during its removal. The surface epithelium was intact, and the glands were normal. In Case 1,964 (p. 312) the uterine cavity contained a large pyometra, and had an opportunity of examining the mucosa been afforded, inflammatory changes would certainly have been found. In Case 3,452 (p. 319) a very suspicious picture was noted (Fig. 166, p. 322). The surface epithelium had here and there proliferated, being four or five layers in thickness. At such points the nuclei were half as large again as those in the cells of the surrounding areas, and the epithelial cells were increased in number. Farther up in the uterine cavity the surface epithelium formed solid teat-like outgrowths. These contained no stroma, but in the centres of some were gland-like cavities. The appearance was strongly suggestive of commencing adeno-carcinoma of the body. A few of the glands showed hypertrophy, but the majority were normal. In Case 2,625 (p. 305) the uterine mucosa had numerous cyst-like spaces scattered throughout it; these averaged 3 millimetres in diameter, and contained a translucent material. Situated near the fundus was a small polyp. On histological examination, as already mentioned elsewhere, this polyp was found to contain metastases from the cervical growth; otherwise, apart from the glandular dilatation, as shown by the small cysts, the mucosa was normal.

K. Abel* also reports a case of carcinoma of the cervix in which a small nodule

* Abel, K. *Ein Fall von circumscriptem Cervixcarcinom und gleichzeitigem isolirten Krebsknoten im Fundus uteri.* Berlin. klin. Wochenschr., 1889, Bd. xxvi, S. 675.

was found in the uterine mucosa. The patient, aged sixty-two, was curetted and adeno-carcinoma of the cervix demonstrated. On later examination, a nodule the size of a pea was found in the posterior uterine wall near the fundus. This protruded from the surface 2.5 millimetres, and the surrounding mucosa showed chronic inflammation. Histologically, it was identical with the cervical tumour.

From the above it will be seen that, where there are no metastases into the uterine mucosa, and if there is no damming up of discharges, as in pyometra, the mucosa of the body will probably be unaltered, unless there has been some previous tubal disease.

ADENO-CARCINOMA OF THE CERVIX, WITH AN APPARENTLY INDEPENDENT
AND EARLY ADENO-CARCINOMA IN THE BODY

Gyn. No. 3,452

Adeno-carcinoma of the cervix, with a cauliflower out-growth; extension to the vaginal vault and rectum. Probably commencing adeno-carcinoma of the body independent of that in the cervix (Fig. 166); abdominal hysterectomy; growth not entirely removed.

J. P., aged forty-eight; coloured. Admitted April 24, 1895. Complaint: hæmorrhage from the vagina, accompanied by an offensive discharge. Duration of symptoms, about four months.

The patient has been married twenty-five years; she has had twelve normal labours, the last child being born November, 1894. Her menstrual history is unimportant, and with the exception of an occasional attack of malaria (?) she has always been healthy.

In August, 1894, when six months pregnant, she had a vaginal discharge which was irritating and offensive; she grew weak, was pale, and commenced to lose flesh. One month after the birth of the child she had copious bleeding, and since then hæmorrhages have been of frequent occurrence. At no time has she complained of pain.

The patient is debilitated, has lost weight, and has a very poor appetite; micturition is normal; the bowels are constipated.

The vaginal outlet is relaxed. Springing from the cervix is a fungoid mass, which has extended laterally to the vaginal vault, invading it for a distance of 2 centimetres; the broad ligaments are slightly indurated.

Operation, April 25, 1895. Abdominal hysterectomy. Before the administration of the anæsthetic, a bougie was introduced into the left ureter, but the right ureter was not found. On opening the abdomen the bougie in the left ureter could be pushed out of the carcinomatous area. The left broad ligament was tied close to the pelvic wall, the ureter was dissected out, and the uterine vessels were controlled as near as possible to their point of origin. The uterus was freed anteriorly without difficulty; posteriorly, it was intimately adherent to the rectum. After liberating the uterus and dissecting out the involved portions of the vaginal vault, the right uterine vessels were controlled and the uterus was removed.

On carefully examining the rectum where it was adherent to the uterus, an area was found which appeared to be carcinomatous; on account of its position, however, it could not be removed. The vaginal vault was partially closed by sutures, a gauze drain introduced into the vagina, and the abdominal incision closed.

The patient made a good recovery. Inspection several weeks after operation revealed a suspicious nodule on the posterior vaginal wall, in close proximity to the rectum. The nodule was cauterized. The patient was discharged May 29th. She returned for examination July 14, 1895, when the nodule was found to have considerably increased in size.

Gyn.-Path. No. 678. The specimen consists of uterine scrapings.

Histological Examination.—The tissue is for the most part composed of epithelial elements, which in the more typical portions present a convoluted, gland-like arrangement. These glands are lined by one layer of very high cylindrical epithelium, the nuclei of which are oval and vesicular, and are situated directly on the basement membrane. Quite a number of the cells contain nuclear figures. In many places the gland epithelium is two or three layers in thickness, and not infrequently a gland lumen is completely filled with cells. The epithelium of such cell-nests varies considerably. The outer layer consists of cylindrical epithelium corresponding to that of the gland, but the central portion is filled with cells which somewhat resemble squamous epithelium (Fig. 165). Here and there such cells are much above the normal in size, and contain large, irregular, deeply staining masses of chromatin. In a few places a partially obliterated gland is seen, in the lumen of which there still remain a few polymorphonuclear leucocytes. Polymorphonuclear leucocytes and small round cells are occasionally found between the epithelial elements. The stroma of the tissue is very scant, and is composed of spindle-shaped cells. It shows some small-round-cell infiltration.

The diagnosis of adeno-carcinoma of the uterus was certain, but whether it had originated in the cervix or body we would have been at a loss to say had we not soon after been given the uterus itself to examine.

Diagnosis.—Adeno-carcinoma of the cervix.

Gyn. Path. No. 685. The specimen consists of the uterus with its appendages intact. The uterus measures $9 \times 6 \times 7.5$ centimetres, and both anteriorly and posteriorly is smooth and glistening. The cervix is 4.5 centimetres in diameter, and is considerably altered. The anterior lip, which is pinkish red in colour, presents an eaten-out appearance; the posterior lip is considerably thickened. On section, the cervix is found to be invaded by a new growth, which presents a waxy-white appearance, is firm and non-yielding, is sharply defined, extends upward as far as the internal os, and laterally appears to invade the tissue as far as the line of incision. The cervical mucosa is waxy white in colour, smooth, but slightly corrugated; near the internal os it shows moderate glandular dilatation, some of the glands reaching 2 millimetres in diameter. The uterine muscle averages 1.5 centimetres in thickness. The uterine cavity is 4.5 centimetres in length, and its mucosa, which varies from 2 to 3.5 millimetres in thickness, shows slight ecchymosis. The appendages on both sides are apparently normal.

Histological Examination.—The surface of the anterior cervical lip is composed of necrotic tissue throughout which many polymorphonuclear leucocytes are scattered. The underlying tissue is everywhere infiltrated by gland-like spaces, lined by one or several layers of epithelium. The nuclei of the cells are sharply defined and are oval and vesicular, but the individual cells cannot easily be differentiated from one another. Some of the cells contain

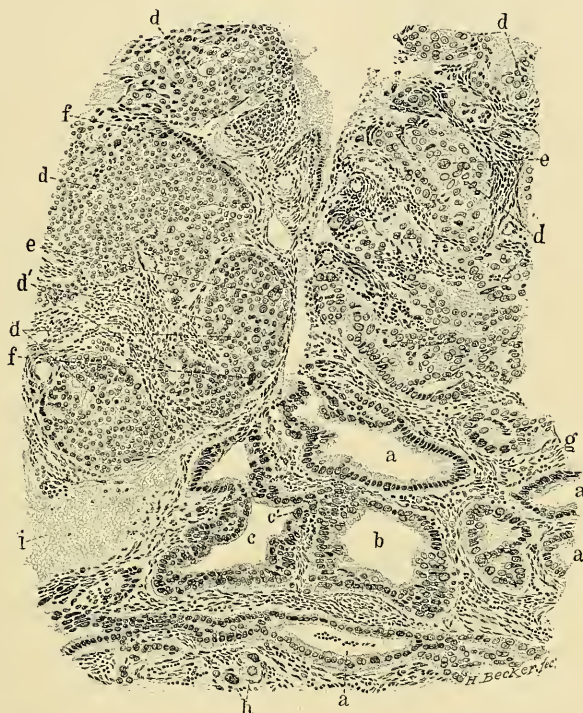


FIG. 165.—PROLIFERATION OF THE GLAND EPITHELIUM IN ADENO-CARCINOMA OF THE CERVIX WITH FORMATION OF SOLID NESTS RESEMBLING THOSE OF SQUAMOUS-CELL CARCINOMA. (115 diameters.)

Gyn.-Path. No. 678. At *a* the glands deviate but little from the normal; but at *b* the epithelial cells form several layers, and some of the nuclei are swollen. In *c* the cell proliferation is also clear, and in addition one of the nuclei (*c'*) is enlarged and stains deeply. As indicated by *d, d'*, the gland epithelium has in numerous places so proliferated that nests are formed, the cells bearing a striking resemblance to those of squamous epithelium. At *d'* a distinct glandular arrangement is still visible. In some places (*e*) the nuclei are swollen and vesicular; at others (*f*) they are irregular and stain deeply. *g* is the stroma of the growth, fairly abundant, and consisting of cells containing spindle-shaped nuclei. *h, h* indicate isolated cancer cells in the stroma. The areas *d, d'* are certainly strongly suggestive of squamous-cell carcinoma, but their direct origin from the gland epithelium is clear, while at *d'*, as we have seen, the glandular arrangement is still demonstrable.

nuclear figures, while in others are seen very large irregular nuclei. In many places the epithelium has so proliferated that the gland is completely filled. Here and there single rows of cells may be seen invading the stroma, their nuclei tending to stain more deeply, and being irregular in contour. The stroma between the glands is, as a rule, very scant, but where it is at all abundant it shows a marked degree of small-round-cell infiltration.

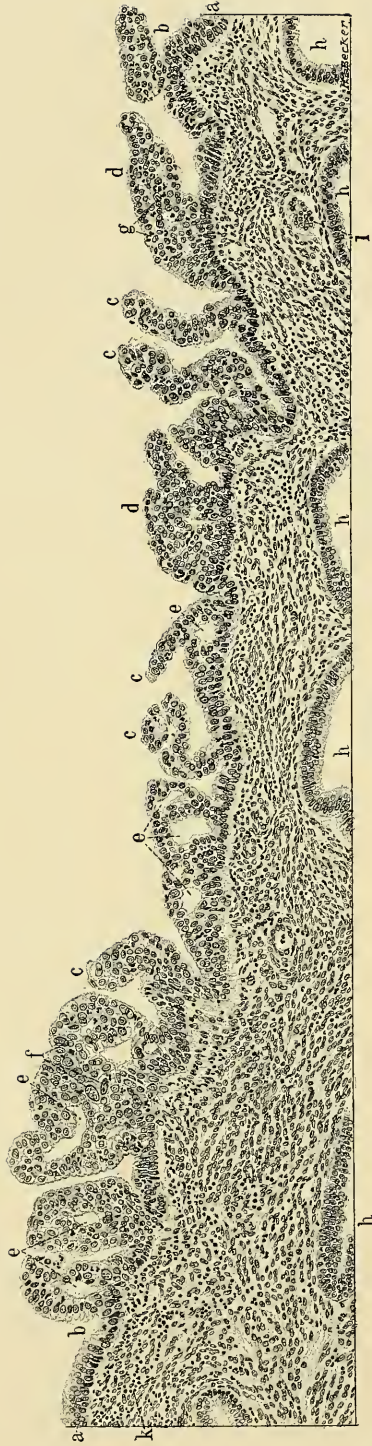

FIG. 166.—PROBABLY COMMENCING ADENO-CARCINOMA OF THE BODY OF THE UTERUS INDEPENDENT OF THE ADENO-CARCINOMA OF THE CERVIX. (115 diameters.)
 Gyn.-Path. No. 685. The section is taken from high up in the uterine cavity. At *a, a* the surface epithelium is practically normal, but at *b, b* it suddenly becomes thickened. Projecting from the surface at many points are long fingers or tongue-like outgrowths, consisting of epithelial cells closely packed together, and containing oval, or round, vesicular nuclei. At *d, d* are large and compact outgrowths. At numerous places, indicated by *e*, the epithelium has proliferated in such a way that new glands have been formed. It is a striking fact that none of the outgrowths contain the faintest trace of stroma, but consist entirely of epithelial cells. Although the nuclei are, as a rule, uniform in size, yet at *f* are two, fully twice or three times the size of their neighbours; one of them stains deeply. Between the epithelial cells are a few polymorphonuclear leucocytes, as indicated by *g*. At *h* are seen normal uterine glands. *i* is the edge of a normal gland. The stroma of the mucosa is unaltered, save just beneath the surface epithelium, where, as indicated by *k*, it shows some small-round-cell infiltration.

Somewhat analogous pictures are seen in Fig. 197 (p. 386) and Fig. 209 (p. 396), from cases in which undoubted adeno-carcinoma of the body of the uterus existed. Fig. 274 (p. 524), from a case in which only an endometritis was present, also bears some similarity to this section. From the proliferation of the epithelium with the formation of new glands, together with the few enlarged, somewhat deeply staining nuclei, one must strongly suspect commencing adeno-carcinoma, but from this section alone would not be justified in making a positive diagnosis.

In the posterior lip, which, macroscopically, although thickened, was still intact, there is considerable change. The vaginal portion of the cervix has lost its epithelium, and the underlying stroma shows marked small-round-cell infiltration. The cervical glands, instead of presenting their convoluted appearance, are made up of bunches of small tubular glands, all of which open into one central gland cavity (compare with Fig. 153, p. 293). They are lined by one or more layers of high cylindrical epithelium, the nuclei of which are oval and vesicular. Between these small glands there is no appreciable amount of stroma. This condition in the posterior lip represents the earliest stage of adeno-carcinoma of the cervix that we have ever met with. The glands have increased considerably, and are just commencing to invade the surrounding tissue. The cervical glands above the new growth appear perfectly normal, except that an occasional one is dilated.

The uterine mucosa is of moderate thickness, and its surface epithelium is in many places intact. Here and there it is only one layer in thickness, but in other places it has proliferated and consists of four or five layers. The nuclei of the proliferated cells are half as large again as those of the surrounding epithelium, and their protoplasm is more abundant. Such areas bear a marked resemblance to squamous epithelium. Farther up in the cavity, solid, teat-like projections of epithelial cells spring from the surface. These contain no trace of stroma, but in the centres of some are spaces which remind one of gland cavities (Fig. 166). From the above picture commencing adeno-carcinoma of the body of the uterus is strongly to be suspected. There is here and there hypertrophy of the uterine glands, but the majority of them are normal.

The appendages show nothing unusual.

Diagnosis.—Adeno-carcinoma of the anterior cervical lip. Commencing adeno-carcinoma of the posterior lip, apparently independent of the former. Papillary outgrowths of the uterine mucosa, with suspicion of commencing adeno-carcinoma of the body of the uterus.

ADENO-CARCINOMA OF THE CERVIX SECONDARY TO THAT OF THE OVARY

This is a rare condition. C. Gebhard* incidentally mentions a case in which the primary growth was thought to be in the uterus, but in which, on microscopical examination of a piece removed from the cervix, the growth proved to be ovarian in type. The tumour was primary in the ovary, and had involved the uterus only secondarily. In the following case the patient entered complaining of an abdominal tumour. In Douglas's sac was a mass about the size of a normal uterus; this was connected with the cervix, and the entire pelvis was choked by a hard, irregular mass, continuous with the abdominal tumour. A piece of the cervix was removed for diagnostic purposes, and on histological examination I found it riddled by large bunches of glands. The growth was an adeno-carcinoma, but totally different from that seen in primary adeno-carcinoma of the cervix. The patient soon died, and the primary growth was found to be in the right ovary.

* Gebhard, C. *Op. cit.*

Gyn. No. 2,492

Removal of a piece of cervix for diagnosis. A type of adeno-carcinoma totally foreign to that occurring in the cervix (Fig. 167). The autopsy showed that the growth was primarily in the ovary, and had extended to the cervix by continuity.

S. B., aged forty-eight; white. Admitted January 6, 1893. Complaint: abdominal tumour.

The patient has had seven children, but no miscarriages. Her menses have

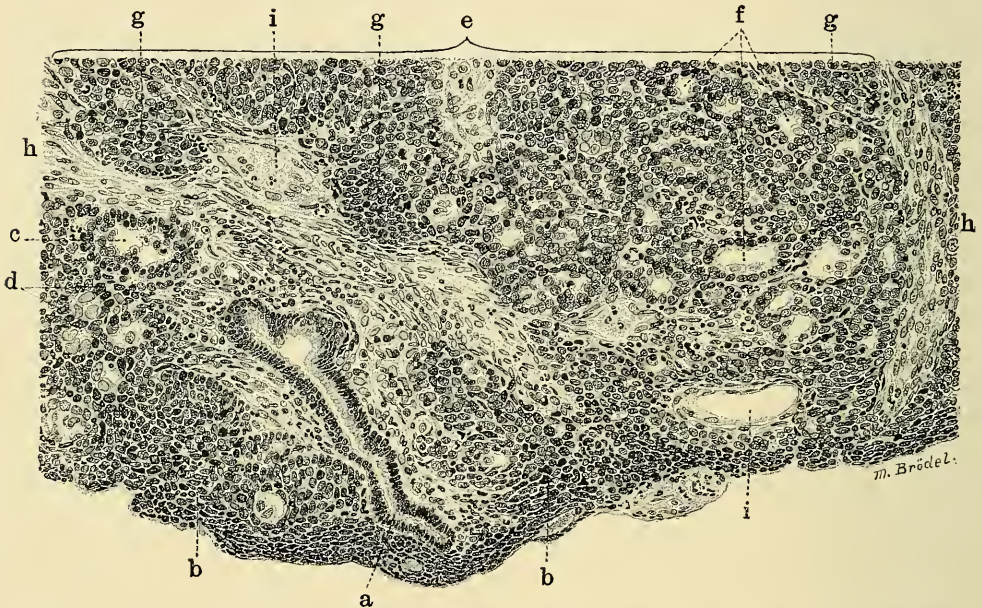


FIG. 167.—ADENO-CARCINOMA OF THE CERVIX SECONDARY TO CARCINOMA OF THE OVARY. (150 diameters.)

Gyn.-Path. Nos. 126 and 148. Autopsy 486. The section is from the cervix, and was removed for diagnosis. *a* is a normal cervical gland surrounded by a scant amount of stroma, which separates it from the carcinomatous areas, *b*. The cells of this growth are closely packed together, and have oval or slightly irregular nuclei that stain uniformly. Altogether the cells in most parts seem to form homogeneous areas. At *c* a faint gland-like arrangement can be detected. At *d* are three small glands filled with pale staining cells. The large area, situated in the upper part of the section and embraced by *e*, is also carcinomatous tissue. On holding the picture a little distance off, a glandular arrangement is noted, and at *f* the glands are fairly well formed, being lined by low cylindrical or cuboidal epithelium. At *g g* the cells have proliferated to such an extent that all trace of the glands has disappeared. *h* is the stroma, very scanty in amount, and consisting of cells having pale-staining, elongate-oval, vesicular nuclei. *i i* are blood-vessels. A reference to Fig. 154 (p. 296), Fig. 153 (p. 293), Fig. 163 (p. 316), Fig. 157 (p. 307), and Fig. 158 (p. 308), will show that this carcinoma differs greatly from those developing primarily in the cervix.

always been regular, but recently have diminished in amount. Her family history is negative, and she has always been well.

Four or five months ago she began to complain of severe abdominal pain, which commenced in the epigastric region and radiated throughout the entire abdomen. The patient gives very vague statements as to her condition. She is

somewhat emaciated, and her skin is of a waxy hue. Her appetite is poor; the bowels are regular.

The abdomen is greatly distended; the distance from the pubes to the umbilicus is 18 centimetres; from the umbilicus to the ensiform cartilage, 14 centimetres. The greatest circumference, which is at a point 6 centimetres below the umbilicus, is 92 centimetres. The abdominal cavity seems to be filled with a hard, irregular mass, which extends about 3 centimetres above the umbilicus, and which also projects into the right flank. On the left side is a distinct sulcus, but the mass extends up under the ribs. The vaginal outlet is greatly relaxed, and the cervix is high up under the pubic arch. The os is dilated, admitting the tip of the index finger. In Douglas's cul-de-sac is a mass about the size of a normal uterus; this is continuous with the cervix. The whole pelvis is choked with a hard, irregular mass, intimately connected with that lying in the abdominal cavity. The examination occasions considerable pain.

On January 8th the patient was etherized and a small piece of the posterior cervical lip removed for microscopic examination. She died four days later.

Gyn.-Path. No. 126. The small piece of the cervix which was removed has a mucous membrane which is smooth, and, apart from being slightly injected, appears perfectly normal. On microscopic examination, the cervical glands, where present, are found to be normal, but the tissue is riddled by large bunches of glands (Fig. 167). Some of these are cut lengthwise, others transversely. The gland epithelium is, here and there, one layer in thickness, but has in many places so proliferated that the cavity is almost or completely filled. The growth is an adeno-carcinoma, but totally different from the variety usually seen in the cervix.

Gyn.-Path. No. 148. Autopsy 486. On opening the abdominal cavity the right ovary was found to be the seat of a new growth, and reached 20 centimetres in diameter. The left ovary was also enlarged. The uterus was firmly wedged in between the enlarged ovaries. Small whitish-yellow nodules were found on the surfaces of the intestines, stomach, diaphragm, omentum, and general peritoneum.

Histological Examination.—The growth involving the right ovary presented the typical appearance of adeno-carcinoma, and the small nodules seen covering the surface of the different organs were composed of the same morphological elements. The uterus was everywhere invaded by the growth. The glands of the new growth were found lying in between the normal uterine glands. In the cervix the invasion was more extensive.

Diagnosis.—Adeno-carcinoma of both ovaries. Invasion, by continuity, of the uterus. Secondary growths on the peritoneal coats of the intestines, stomach, liver, abdominal walls, diaphragm, omentum, and mesentery.

CHAPTER X

ADENO-CARCINOMA OF THE CERVIX. ORGANS SECONDARILY INVOLVED. AUTOPSY FINDINGS

1. Extension to the vagina.
2. Involvement of the broad ligaments.
3. Extension to the bladder.
4. Extension to the rectum.
5. Condition of the tubes and ovaries.
6. Involvement of the lymph glands in adeno-carcinoma of the cervix.
7. Carcinoma of the liver secondary to adeno-carcinoma of the cervix.

It is with the clinical phenomena at this stage of the disease that the general practitioner is most familiar, since he is rarely called in during the early months.

Extension to the Vagina.—It is astonishing to note how early, in some instances, the vaginal vault is involved. Thus, in Cases 3,923 (p. 314), 2,625 (p. 305), 1,964 (p. 312), 2,990 (p. 286), 3,452 (p. 319), and 3,712 (p. 303), it was found that the process had already implicated parts of the vagina, although little or no breaking-down of the cervical tissue had occurred. In Case 2,990, for example, the growth, starting in the right half of the still intact cervix, had involved the vaginal wall for a distance of 2 centimetres. Again, in Case 3,712 (p. 303), the vagina was filled with an offensive, necrotic mass, about the size of a foetal head, which sprang from the posterior cervical lip and vaginal vault.

This early extension to the vault is another point indicative of the rapidity of the growth of adeno-carcinoma of the cervix.

Involvement of the Broad Ligaments.—Adeno-carcinoma of the cervix grows with great rapidity, and shows little tendency to break down. Thus it often happens that the disease is far advanced before the patient seeks medical aid. The relatively late occurrence of disintegration is to be explained by the fact that the epithelial cells are often only one layer in thickness, and are not so crumbly as squamous cells; while the papillary folds forming the surface of the growth contain more stroma, and as a consequence are more stable. The growth is often high up in the cervix, and is partially or wholly hidden from view, so that a determination of its dimensions is impossible. In Cases 1,964 (p. 312), 2,990 (p. 286), 3,616 (p. 297), 3,452 (p. 319), 2,782 (p. 284), and 2,631 (p. 291), on macroscopic examination, the neoplasm had extended almost, if not quite, to the cut surface, and the histological examination was naturally even more conclusive. In Cases 3,923 (p. 314), 2,625 (p. 305), and 3,356 (p. 295), although examinations of the gross specimens were negative, involvement of the broad ligaments was easily demonstrable in microscopic sections. Thus in nearly every case the

disease had extended to the broad ligament, in the majority being recognisable with the naked eye, but occasionally requiring further study.

Winter,* in a series of thirty-two local recurrences of carcinoma of the cervix, found twenty-four cases of adeno-carcinoma and eight of squamous-cell carcinoma. The preponderance of the former he attributes to the difficulty in determining the amount of extension in adeno-carcinoma previous to operation. Reference to Winter's article shows that the majority of these uteri were removed through the vagina. It will be well to remember that in all cases of adeno-carcinoma of the cervix a very guarded prognosis should be given, inasmuch as the disease may have extended far laterally, even though the ligaments may be only slightly, if at all, thickened.

Extension to the Bladder.—In statistics dealing with this point, instances of squamous-cell carcinoma are usually included with those of adeno-carcinoma. Hence it is almost impossible to conclude in what percentage of cases of the latter variety of malignant growths the bladder is involved. In our series of adeno-carcinomata, even in those cases which were considered inoperable, no invasion of the bladder was made out. Furthermore, after the bladder becomes implicated, it is probable that a vesico-vaginal fistula will occur only at a very late stage, since the tissues, as has been pointed out before, are very slow in breaking down.

Extension to the Rectum.—What has been said concerning involvement of the bladder applies also to the rectum. In only two cases of our series was the rectum proved to have been invaded. In Case 3,712 (p. 303), which was curetted, the growth had penetrated the recto-vaginal septum as far as the mucosa, but no recto-vaginal fistula had occurred. One case (Autopsy 813) showed a very advanced stage of the disease and widespread metastases, so that it was not to be wondered at that the process had extended to the rectum and had caused perforation.

Condition of the Tubes and Ovaries.—Our material has not been abundant enough to warrant any wide-sweeping conclusions.

As will be seen from the accompanying table of six cases, only two of the patients had normal adnexa. In Case 3,923 (p. 314) the appendages were covered by adhesions, and one tube was the seat of an old salpingitis. Case 3,356 (p. 295) had a general pelvic peritonitis, a small parovarian cyst on the right side, and a tubo-ovarian cyst on the left side. Case 3,616 (p. 297) showed a tubo-ovarian abscess on the right side and an encysted peritonitis on the left, while Case 2,782 (p. 284) had a double pyosalpinx. Thus out of six cases four had pelvic peritonitis, while in three there was a salpingitis. There is little reason to suppose that the carcinoma bore any causal relation to the development of the salpingitis; nor would it be at all a matter of surprise if subsequent investigators find that the appendages are normal in quite a large proportion of cases.

* Winter, G. *Ueber die Recidive des Uteruskrebses, insbesondere über Imprecidive.* *Zeitschr. f. Geburtsh. u. Gynäk.*, 1893, Bd. xxvii, S. 101.

Condition of the Tubes and Ovaries

CASE No.	TUBE.		OVARY.		Remarks.
	Right.	Left.	Right.	Left.	
C., 3,923	Covered by adhesions.	Covered by adhesions; seat of a chronic salpingitis.	Enveloped in adhesions, otherwise normal.	Enveloped in adhesions, otherwise normal.	
R., 3,856	Covered by adhesions.	Covered by adhesions.	Ovary mutilated.	Tubo-ovarian cyst 5 x 5.5 centimetres.	Parovarian cyst, 3.5 centimetres in diameter, on right side.
E., 3,616	Pus sac formed by tubo-ovarian mass, 6 x 4 x 3.5 centimetres. Soft and yielding; on histological examination, found to be a subacute salpingitis.	Slight salpingitis.	Miliary abscesses in ovary.	Cyst 7 centimetres in diameter: probably an encysted peritonitis.
P., 3,452	Normal.	Normal.	Normal.	Normal.	
G., 2,782	Pyosalpinx.	Pyosalpinx.			
W., Autopsy 813	Normal.	Normal.	Normal.	Normal.	

INVOLVEMENT OF THE LYMPH GLANDS IN ADENO-CARCINOMA OF THE CERVIX

On page 15 the lymphatics of the uterus, and the glands with which these communicate, were considered. It will be remembered that the lymphatic channels of the cervix originate in the mucous membrane and muscular coats and pass to the side of the cervix, where they become convoluted; hence they follow a transverse direction, the various branches anastomosing to form two or three large trunks, which usually pass outward along the course of the arteries, and may be as large as the uterine artery.

Their valves are so arranged that their concave surfaces are away from the uterus. After reaching the pelvis they skirt its sides to reach the iliac glands situated at the bifurcation of the common iliac artery. The iliac glands are usually three in number. The upper one, which is also the largest, occupies the summit of the angle formed by the external iliac with the hypogastric artery, and partly covers the external iliac vein. The other two glands are situated along the course of the hypogastric artery, and are consequently in the pelvis. As before mentioned, Henle described a lymph gland that is frequently found on either side of the cervix

As might be expected, the carcinomatous process follows these lymph channels and involves the iliac glands. John Williams,* in his Case XVI (adeno-carcinoma of the cervix), found at autopsy a chain of carcinomatous glands along the course of the left iliac vessels, while on the right side there were a few enlarged glands at the sacro-iliac synchondrosis and along each side of the spine. The presence

* Williams, John. *On Cancer of the Uterus, being the Harveian Lectures for 1886.* 119 pp., 18 pl., 8 vo. London, 1888.

of the carcinomatous glands along the course of the aorta is readily explained, when one remembers that lymphatics pass directly from the iliac to the lumbar glands, which are consequently the next to be invaded.

In Case 3,923 (p. 314) two of the iliac glands were removed. They averaged 3×1.5 centimetres in diameter, and were both rather firm on pressure. On histological examination the cells were found to be somewhat swollen, but there was not a trace of carcinomatous involvement. In Autopsy 813 it was found that the disease had extended to the surrounding structures, and that both the iliac and lumbar glands were involved. One of the iliac glands reached 1.5×1 centimetre in size, but, as a rule, the glands were only slightly enlarged. On histological examination, they were found to be penetrated in all directions by masses of epithelial cells, in parts still preserving the glandular arrangement, but in other parts appearing as cell-nests (Fig. 168). Many irregular nuclear figures

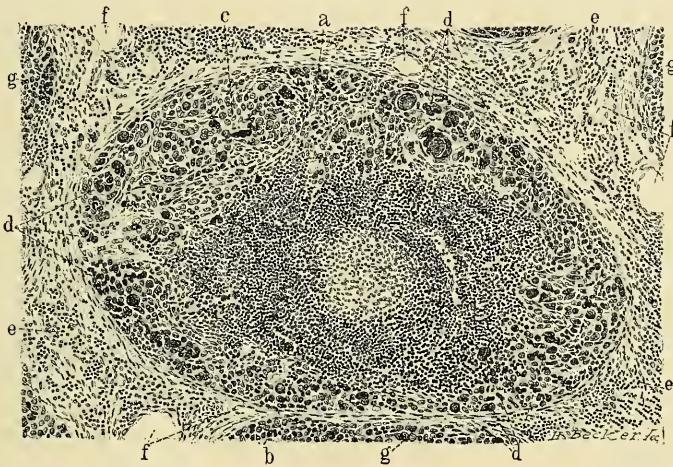


FIG. 168.—METASTASES IN A PELVIC LYMPH GLAND IN A CASE OF ADENO-CARCINOMA OF THE CERVIX. (120 diameters.)

Gyn.-Path. No. 1,229. Autopsy 813. In the lymph gland, from which this picture was taken, there was a marked increase in connective tissue, the lymphoid cells being divided off into large islands. The figure shows one of these islands. It consists of two definite portions: an outer zone composed of carcinoma cells (*a*), and a central portion (*b*) made up of typical lymphoid cells. In the centre the nuclei are not so closely packed together, and are rather vesicular, giving to the tissue a pale appearance. The carcinoma cells have no definite arrangement, and one would not for a moment suspect that the original growth was glandular in character. The nuclei at *c* are uniform in size and vesicular, but many of the epithelial cells contain large, round or irregular, very deeply staining nuclei (*d*). *e* is the stroma which contains several blood-vessels (*f*), and shows considerable small-round-cell infiltration. Along the edge of the field are portions of other islands of lymphoid cells, showing carcinomatous involvement (*g*). From the section it is readily seen that the carcinoma cells are much larger than those of the ordinary lymphoid type. The diagnosis of a malignant growth is readily made from the presence of the large, deeply staining nuclei alone.

were found in the epithelial cells. It is interesting to note that some of the glands, although little enlarged, showed carcinomatous involvement.

With the more systematic resort to the radical operation an opportunity of examining the glands will be offered, and it will then be possible to determine in what percentage of apparently operable cases the disease has extended to the lymphatics.

CARCINOMA OF THE LIVER SECONDARY TO ADENO-CARCINOMA OF THE CERVIX

Metastases in the various organs, in any variety of carcinoma of the uterus, are of rare occurrence, but in Autopsy 813, in a case in which the disease was wide-spread, a nodule the size of a walnut was found on the surface of the liver

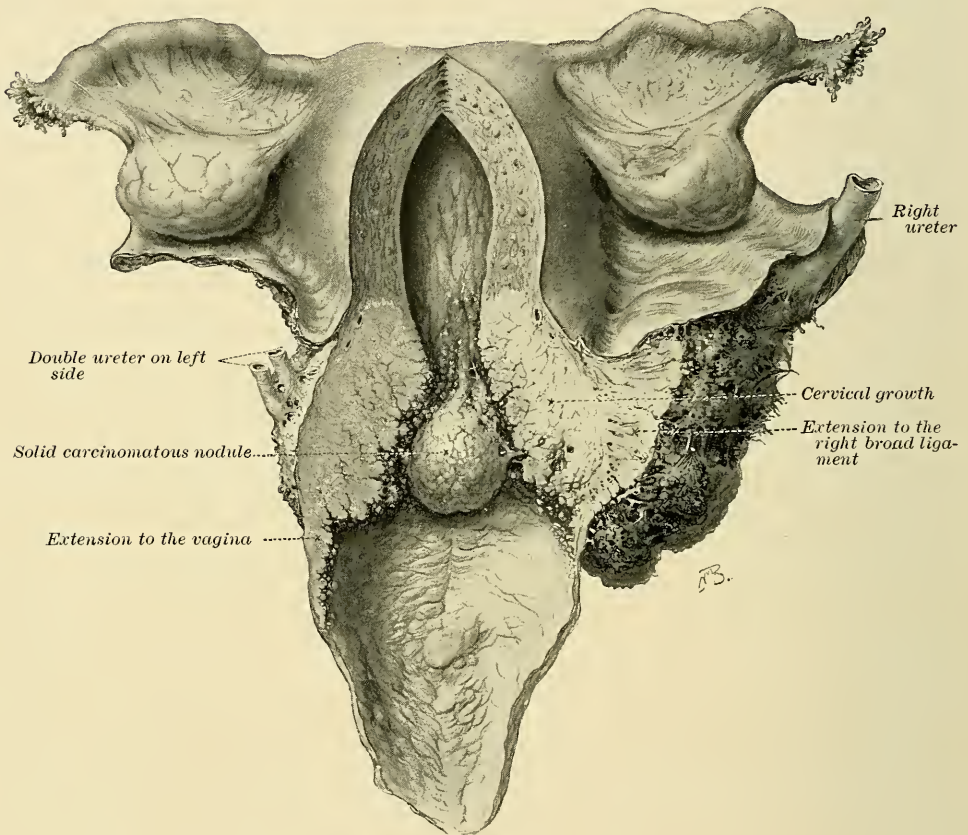


FIG. 169.—ADENO-CARCINOMA OF THE BODY OF THE UTERUS. ($\frac{3}{5}$ natural size.)

Gyn.-Path. No. 1,229. Autopsy 813. The uterus has been opened posteriorly. The entire cervix and the lower part of the body are occupied by a neoplasm, which is friable, shows little outgrowths projecting from its surface, and in the anterior wall forms a solid, slightly nodular exerescence. The carcinomatous process has extended into the broad ligaments on both sides. On the right side it has constricted the ureter, producing a hydronephrosis. On the left side is a double ureter. The growth has encroached on the vaginal vault. The body of the uterus is of the normal size. Its walls are thinner than usual, and its mucosa, where not invaded by the new growth, is normal. The tubes and ovaries present the usual appearance. (After W. W. RUSSELL.)

and growing into its substance. It had evidently started on the peritoneal covering. A histological examination showed that this secondary growth contained numerous glands and resembled the parent tumour (Fig. 171).

Autopsy No. 813

Case first seen at autopsy. Adeno-carcinoma of the cervix (Fig. 169). Extension to the surrounding tissues; perforation of the rectum; involvement of the pelvic and lumbar lymph

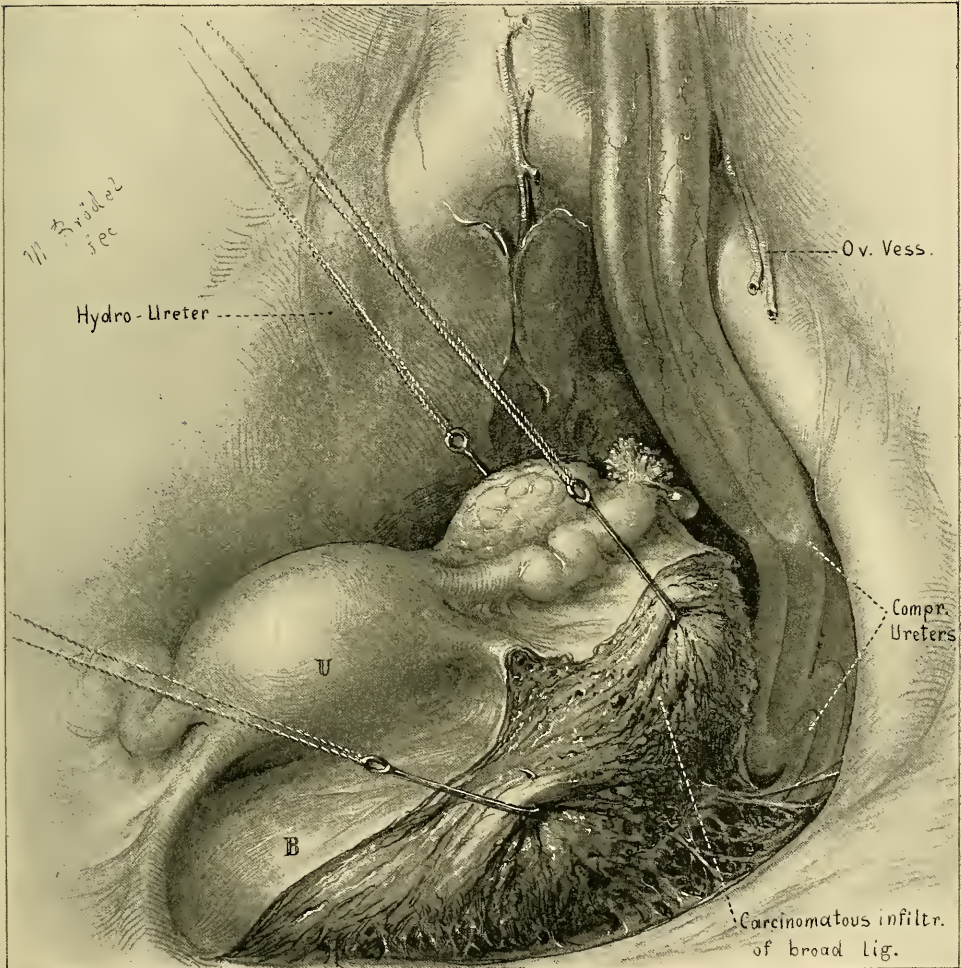


FIG. 170.—COMPRESSION OF A DOUBLE LEFT URETER IN ADVANCED ADENO-CARCINOMA OF THE CERVIX. (Natural size.)

Gyn.-Path. No. 1,229. Autopsy 813. The ureter and bladder have been dissected free on the left side and drawn over to the right. The left broad ligament is markedly infiltrated with carcinomatous tissue, as seen in Fig. 169. The compressed double ureter is displaced outward against the pelvic wall, and immediately above the point of compression is markedly dilated. To the right the hazy outline of the dilated right ureter is seen. (After H. A. KELLY.)

glands; secondary nodule in the liver; double hydroureter and slight hydronephrosis; double ureter on the left side

(Fig. 170), with separate renal pelves and two distinct openings into the bladder; chronic nephritis; subacute pericarditis; pleurisy; peritoneal cyst attached to the vermiform appendix; superficial bed sore over sacrum; histological picture showing carcinoma cells in a pelvic lymph gland (Fig. 168); carcinomatous glands in the liver (Fig. 171).

A. W. Autopsy 813. June 22, 1896.

The body is greatly emaciated, and the abdomen is scaphoid. Over the sacrum is a superficial bed sore. The cervix and part of the body have been destroyed, a disintegrating necrotic mass filling the space formerly occupied

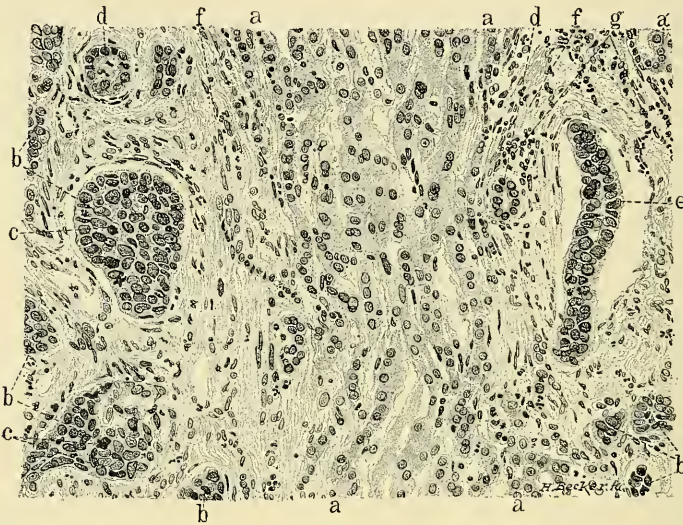

FIG. 171.—ADENO-CARCINOMA OF THE LIVER SECONDARY TO THAT OF THE CERVIX. (210 diameters.)

Gyn.-Path. No. 1,229. Autopsy 813. The central third of the field, inclosed by *a, a*, consists of liver substance. The cell outlines are not well preserved, but the nuclei of the liver cells still present the usual appearances. Scattered throughout the section are numerous solid areas (*b*) composed of epithelial cells, containing oval, vesicular nuclei, fairly uniform in size. A few of them, however, are irregular and contain an increased amount of chromatin, as shown by *c*. At *d, d* are two well-formed glands, lined by one layer of cuboidal epithelium. *e* shows a gland in a longitudinal section; it has retracted from the surrounding stroma. The stroma consists chiefly of cells having oval, or elongate-oval, nuclei, and at *g* shows slight small-round-cell and polymorphonuclear leucocyte infiltration. *a'* indicates a small group of liver cells. From this picture one would have no hesitation in making a diagnosis of carcinoma; moreover, the presence of the typical glands, which in their number and grouping differ from bile-ducts, enables one to classify the neoplasm as an adeno-carcinoma.

by these structures (Fig. 169). The growth has extended for a considerable distance into the vaginal tissue, but adhesions between the uterus and the posterior wall of Douglas's cul-de-sac have prevented the escape of the necrotic material into the peritoneal cavity. The uterus is not enlarged, but is bound down to the surrounding structures, especially on the right side, where the tumour extends through all the soft parts, including the iliac muscle, and has eroded the iliac bone. The tumour here is firm, white, and opaque. The iliac glands are only slightly enlarged, save one, which measures about 1.5×1 centimetre. Between the right kidney and the lower border of the right lobe of the liver is a nodule the

size of a walnut, which is growing into the liver substance. The glands along the descending colon are swollen, indurated, and apparently contain tumour metastases. Both kidneys are similar in general appearance, but the left is somewhat larger than the right. The right ureter is about the size of the index finger, and the corresponding pelvis is dilated. On the left side the ureter is double (Fig. 170). Commencing at the hilum of the kidney these two ureters run side by side to the bladder, where they have distinct orifices, 1.5 centimetres apart; they also have separate pelves; they are dilated from their origin in the kidney to the point at which they are involved in adhesions in the vicinity of the cervix. The average calibre is about 1 centimetre. The contents are clear. The ureters are much constricted at the cervix, but a probe can be readily passed through the narrowed portions. The mucous membrane of the bladder at the trigonum is dotted with a few hæmorrhages. The right ureteral orifice is situated on the summit of a teat-like projection from the vesical wall.

Gyn.-Path. No. 1,229. On histological examination, the growth proved to be an adeno-carcinoma of the cervix.

Examination of the enlarged lymph glands shows them to be invaded by the carcinomatous process, only a slight amount of the lymphoid tissue being left. The invasion has apparently commenced around the periphery of the glands, and has evidently followed the course of the vessels (Fig. 168). In some sections a glandular arrangement of the cells can be made out, but in many places no characteristic grouping is demonstrable, the carcinoma cells occurring as solid masses or being scattered throughout the tissue. Many irregular nuclear figures are found. Some of the cells contain large masses of chromatin, others have several nuclei bunched together.

The nodule in the liver shows an ill-defined glandular arrangement of the cells. The degenerative changes are not marked (Fig. 171).

CHAPTER XI

THE CLINICAL HISTORY IN CASES OF ADENO-CARCINOMA OF THE CERVIX

1. Age.
2. Initial symptoms.
3. Menstrual history.
4. Number of pregnancies.
5. Condition of the patient on admission to the hospital.
6. Pain.
7. Adeno-carcinoma of the cervix in the coloured race.
8. Treatment of adeno-carcinoma of the cervix.

As the majority of the cases of cancer of the cervix found in the literature have not been differentiated into adeno-carcinoma and squamous-cell carcinoma, I have thought it advisable to limit myself to the symptoms found in our series. While it is clear that no very definite conclusions can be arrived at from studies upon so small a number of cases, it is hoped that a comparison of the prominent symptoms, occurring in instances of undoubted adeno-carcinoma, with those of squamous-cell carcinoma, may be of some use to future investigators in their endeavours to differentiate clinically these two forms of carcinoma of the cervix. Unfortunately for our purpose, my group does not include the histories of any cases coming to autopsy, so that the late clinical symptoms cannot be given. Already one or two minor points of differentiation have been shown to exist between the two varieties. In squamous-cell carcinoma the growth, as a rule, bleeds more readily, owing to the friable character of the squamous epithelium; secondly, the tissue in adeno-carcinoma is much firmer, so that the disease is farther advanced before breaking-down of tissue occurs, whence it happens that an adeno-carcinoma may be inoperable before there has been any distinctive sign of the presence of a new growth.

Age.—In thirteen of our cases it was possible to ascertain the patient's age. The youngest was thirty-two, the eldest was sixty-eight years old. From the accompanying table it will also be seen that the most common period was between forty-five and fifty.

Between 30 and 35 years.....	2 cases.
" 35 " 40 " 	2 "
" 40 " 45 " 	1 case.
" 45 " 50 " 	4 cases.
" 50 " 55 " 	1 case.
" 55 " 60 " 	0 "
" 60 " 65 " 	2 cases.
" 65 " 70 " 	1 case.

When considering the ages, one must remember that the patient has probably had the disease for several months, or even longer.

Although we never expect to find adeno-carcinoma in very young individuals, Ganghofner* has reported a case of a child not yet in her teens who presented a characteristic growth. The additional fact that the histological examination of the tumour was made by Professor Chiari, of Prague, leaves no doubt concerning its authenticity. The child was eight years old, and for two or three years had had uterine hæmorrhages, which were thought to be due to early menstruation. The patient, having been etherized, on vaginal examination a lobulated tumour, slightly larger than a hazelnut, was found springing from the cervix; it was nodular, pale red in colour, and bled slightly on examination. The mass was nipped off with a pair of scissors, and the base of the growth destroyed with the cautery. The child developed small-pox, and soon died. At autopsy it was found that the entire growth had been removed. Chiari found numerous nuclear figures in the epithelial cells.

Initial Symptoms.—These are at times absent, or they may be very indefinite. Thus, for example, in Case 2,990 (p. 286) the patient complained merely of an offensive leucorrhœal discharge and of slight backache, although the growth had not only involved the cervix but had extended over into the vaginal walls. Case 2,631 (p. 291) complained of weakness and of an offensive watery discharge. Both cases demonstrate clearly the absolute necessity of an immediate examination before any treatment is instituted, since had it not been for the vaginal examination, carcinoma might not have been suspected.

In the majority of instances there is first a yellowish, offensive, irritating leucorrhœal discharge, as in Cases 3,923 (p. 314), 2,954 (p. 311), 3,036 (p. 302), 3,452 (p. 319), 3,616 (p. 297), and 1,964 (p. 312). This soon becomes blood-tinged, and later hæmorrhages occur from time to time. In Case 3,356 (p. 295) a profuse hæmorrhage was the first indication of any trouble, while in Case 2,625 (p. 305) there was continuous bleeding. In Case 2,782 (p. 284) a feeling of fulness in the region of the uterus was experienced, and there was also a constant, though not profuse, hæmorrhagic discharge. In Case 3,712 (p. 303) a sensation of fulness in the rectum was the first sign noticed; it was followed by profuse menstruation, and later by an offensive, irritating, leucorrhœal discharge.

Hæmorrhages may take place at any time, but are most prone to occur after exertion.

Menstrual History.—In eleven cases the menstrual history is given, and in each instance the flow had been normal up to the time of the menopause or until symptoms of carcinoma developed. Menstruation apparently plays no rôle whatsoever in adeno-carcinoma of the cervix.

Number of Pregnancies.—In thirteen cases of adeno-carcinoma of the cervix we were able to obtain full data as to gestation. Twelve of the patients were married, and from the accompanying table it will be seen that all of these had been pregnant. Case 3,452 (p. 319) had had the largest number of children,

* Ganghofner, F. *Ein Fall von Carcinoma Uteri bei einem achtjährigen Mädchen.* *Zeitschr. f. Heilk.*, 1888, Bd. ix, S. 337.

namely, twelve. The thirteenth patient, 3,712 (p. 303), was single, and had never been pregnant.*

NAME.	Case No.	No. of children.	No. of miscarriages.
Z.....	2,990	3	1
C.....	3,923	1	1
H.....	2,625	3	0
G.....	2,782	2	0
B.....	2,954	6	2
S.....	3,036	3	0
P.....	3,452	12	0
N.....	4,232	2	0
E.....	3,616	1	0
H.....	3,356	0	4
R.....	1,964	4	2
L (single).	3,712	0	0
H.....	2,631	7	2

The Condition of the Patient on Admission to the Hospital.—The greater number of the patients on admission were well nourished and had good appetites. In a few there was a history of loss of flesh, and the women were anæmic. On close comparison of the various conditions present in the cervix, it will be found that in nearly all the patients who had lost much flesh, and in whom the appetite was poor, the disease was already far advanced. In only two instances was there any cachexia (Cases 2,631, p. 291, and 1,964, p. 312). Thus it will be seen that in adeno-carcinoma, when the case is still operable, as well as in many inoperable cases, there may be no cachexia, this symptom coming on, as a rule, only in the far advanced stages of the disease.

The bowels are usually regular, but as the disease progresses and as the patient loses flesh and appetite, their power of contractility is partially lost, and the patient becomes costive, as is well exemplified in Cases 2,782, 2,954, 3,712, and 2,613.

Pain is a varying symptom. In some instances—for example, in Cases 3,452 and 2,631—there was at no time any pain, while other patients complained only of a slight backache or of an occasional soreness in the lower abdomen. In the advanced cases, however, frequent or constant pain in the lower abdomen was experienced (Cases 2,954, 3,036, and 1,964). Case 4,232 for several months had continual pains in the hips and lower abdomen, while Case 3,712 complained of a sensation of heaviness in the rectum.

None of our cases showed very extensive carcinomatous involvement, but with the encroachment on the pelvic walls one would naturally expect a good deal of pain due to pressure upon the nerve trunks. Locomotion may be painful, as was noted in Case 2,782.

ADENO-CARCINOMA OF THE CERVIX IN THE COLOURED RACE

When considering squamous-cell carcinoma of the cervix, the comparative frequency with which it was met with in the coloured race was noted. Out of

* Since this table was arranged a second case of adeno-carcinoma in a single woman has been noted (Gyn.-Path. No. 3,627).

thirteen cases of adeno-carcinoma of the cervix, three were in coloured patients. This is a large percentage, since the ratio of whites to blacks admitted to the hospital is about six to one. Thus one may, for the present, assume that adeno-carcinoma is equally prevalent in the negro, and it is highly probable that further statistics will substantiate this view.

TREATMENT OF ADENO-CARCINOMA OF THE CERVIX

This has been included under that of squamous-cell carcinoma of the cervix, which was considered in Chapter VIII. Here also the object to be aimed at is the same: the entire removal of the diseased tissue. Thus the radical operation, as recommended by Werder, is to be employed in all suitable cases. One special point is, however, to be remembered in the treatment of adeno-carcinoma of the cervix: the disease may have extended far laterally and yet on palpation no thickening be detected. This lateral involvement is often demonstrable only with the aid of the microscope.

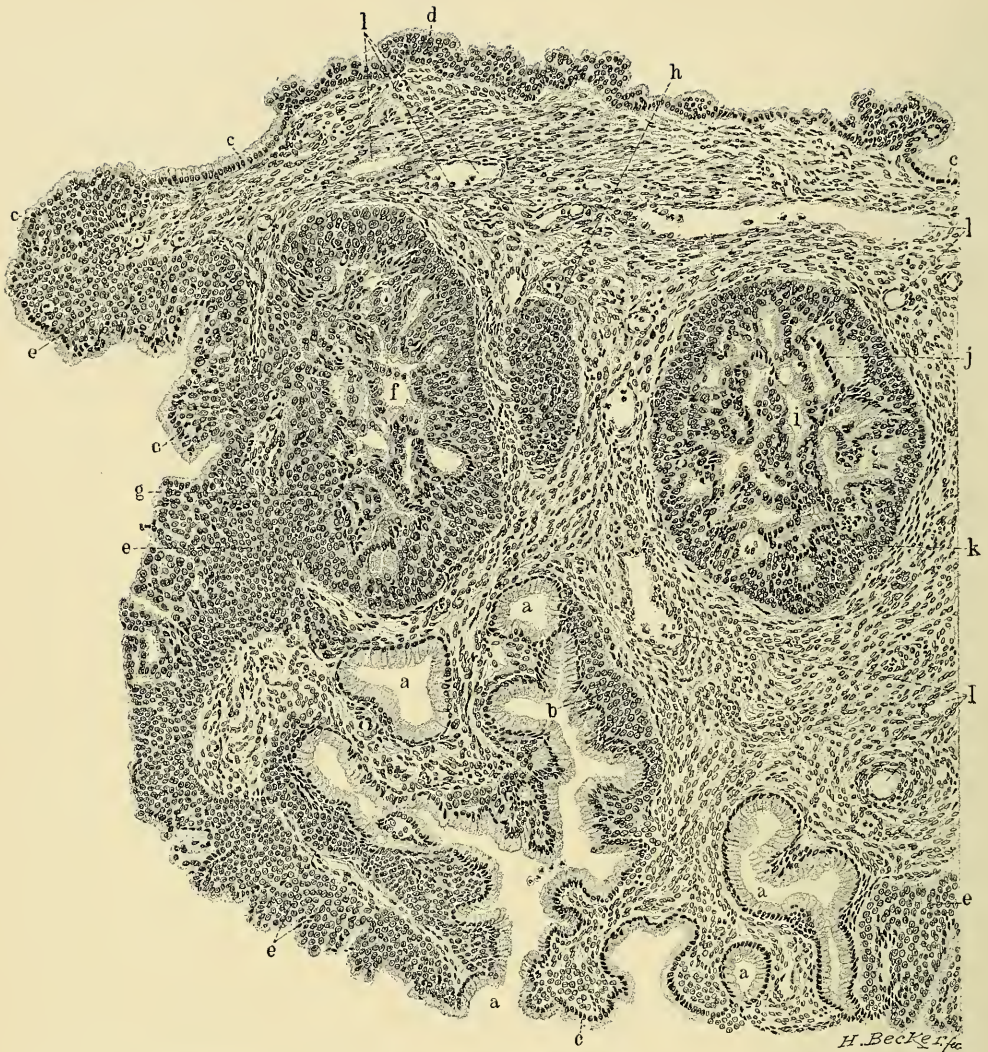

FIG. 172.—THICKENING OF THE CYLINDRICAL CERVICAL EPITHELIUM ON THE SURFACE AND AROUND THE GLANDS. (135 diameters.)

Gyn.-Path. No. 2,602. At the points indicated by *a* are normal cervical glands, lined by one layer of typical high cylindrical, cervical epithelium, but at *b* there is a zone of epithelial cells fully five layers in thickness, containing oval, vesicular nuclei, uniform in size. At certain points (*c*) the surface is covered by normal cylindrical epithelium, but at *d* this is seen to be several layers in thickness. In other places (*e*) we also have marked thickenings of the epithelium. *f* is a convoluted gland, lined by fairly well-defined cylindrical epithelium, and surrounded by many layers of epithelial cells, which at *g* are continuous with those just beneath the surface. *i* is a similar gland. Its ramifications are likewise lined by one layer of cylindrical epithelium, particularly characteristic at *j*, and are surrounded by many layers of epithelium (*k*). *h* is a solid nest of cells, probably continuous with those surrounding *f* at a lower level. *l l l* are blood-vessels.

The pictures presented in *f* and *i* are occasionally found in normal glands at their bases, and little out-growths, as seen at *d*, are frequently met with, but the thickenings, as indicated by *e*, *e*, are most unusual. It will be noted that the general contour of the specimen is perfectly preserved. There are no marked out-growths from the surface, nor is there any distinct tendency on the part of the cells to invade the stroma. Above all, the nuclei throughout the specimen are uniform in size and perfectly regular. I am entirely at a loss to explain just how this condition is produced, but have not the slightest hesitancy in saying that it is benign.

CHAPTER XII

DIFFERENTIAL DIAGNOSIS IN ADENO-CARCINOMA OF THE CERVIX

1. Unusual thickenings of the cylindrical cervical epithelium on the surface and in the glands.
2. Erosions.
3. Slight changes in the gland epithelium.
4. Cervical polypi.
5. Submucous cervical myomata.
6. Interstitial cervical myomata.
7. Adeno-myomata projecting into the cervical canal.
8. Tuberculosis of the cervix.
9. Differential diagnosis between squamous-cell carcinoma and adeno-carcinoma of the cervix.
10. Endothelioma of the cervix.

UNUSUAL THICKENINGS OF THE CYLINDRICAL CERVICAL EPITHELIUM ON THE SURFACE AND IN THE GLANDS

Occasionally we meet with a localized or general thickening of the surface or gland epithelium, which presents a picture that is somewhat suggestive of a neoplasm. In many of such cases, however, careful study of the section, and a close examination of every portion in detail, will enable us with certainty to exclude a malignant growth. Fig. 172 affords a good illustration of this point; on first sight the appearances presented are certainly very suspicious.

EROSIONS

The gross and histological pictures in eversions of the cervical mucosa and in erosions, both of the vaginal and cervical portions of the cervix, have been described in detail in Chapter VII, p. 179.

SLIGHT CHANGES IN THE GLAND EPITHELIUM

By a systematic study of each gland in the section one will occasionally meet with some slightly suspicious picture, which might easily escape notice. In the accompanying drawing (Fig. 173) a few of the gland cells have enlarged nuclei, and one cell contains several nuclei. Nevertheless, it must be said that there is no evidence of malignancy.

CERVICAL POLYPI

Cervical polypi vary considerably in size, averaging from .5 to 1.5 centimetres in length and from 3 to 5 millimetres in breadth (Figs. 175, 176). At times they are pear-shaped, their cervical attachment corresponding to the stem, while,

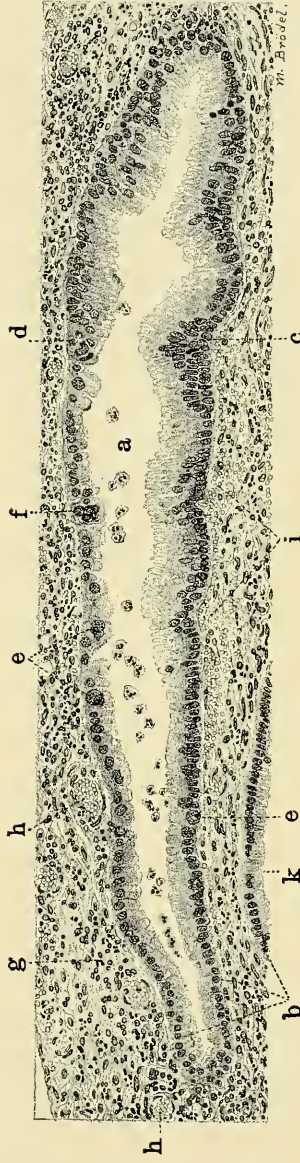


FIG. 173.—A GIANT CELL IN THE WALL OF THE CERVICAL GLAND. (180 diameters.)

Gyn.-Path. No. 1,252. *a* is a cervical gland containing a few polymorphonuclear leucocytes. At *b* the typical cylindrical cervical epithelium is seen. The thickening, noticeable at *c*, is probably due to obliquity of the section. At *d* a few polymorphonuclear leucocytes have wandered in between the epithelial cells. At several points (*e*) the nuclei are fully two or three times their normal size, but do not stain deeply. At *f* is a giant cell containing five deeply staining nuclei. The stroma contains numerous polymorphonuclear leucocytes, indicated by *g*. *h, h'* are small blood-vessels. *i* indicates free blood in the stroma. *k* is the edge of an adjoining cervical gland. All other portions of the section contain normal glands.

The presence of the large nuclei is probably due to some swelling, as there is a slight inflammatory condition, evidenced by the abundance of the polymorphonuclear leucocytes in the surrounding stroma. The giant cell may be due to a coalescence of several epithelial cells. The picture does not seem to show the slightest sign of malignancy.

again, they may form little elevations projecting from the surface of the mucosa. These polypi may be considered simply as masses of cervical mucosa, which have been pushed into the cervical canal and partially nipped off from the parent mucosa. Once in the cervical canal, they act as foreign bodies, are gradually expelled, and reach the external os, where they may be mistaken for portions of an early adeno-

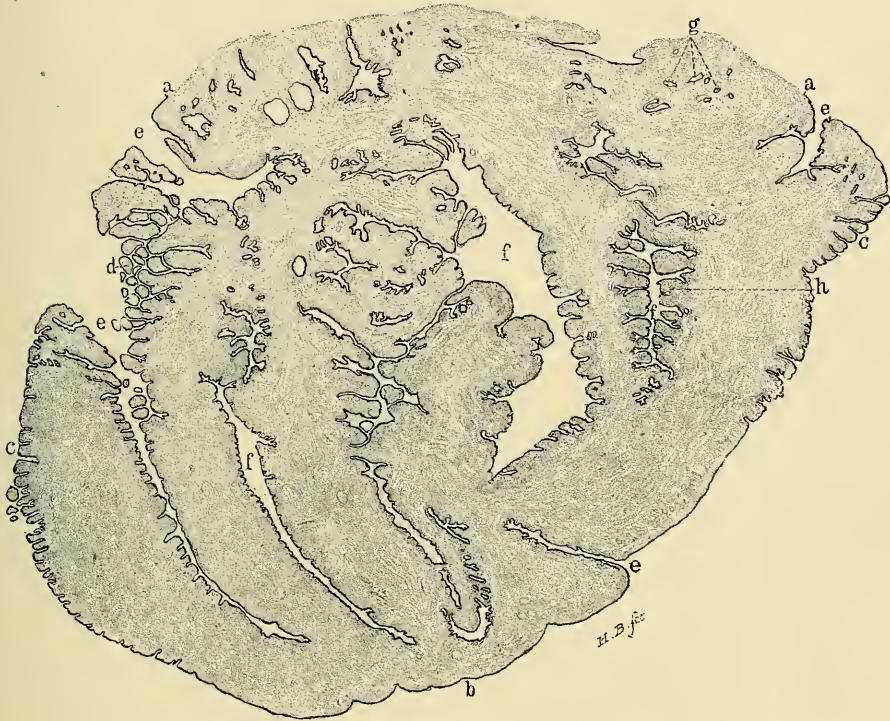

FIG. 174.—A CERVICAL POLYP. (7 diameters.)

Gyn.-Path. No. 941. Between *a* and *a'* is the cut surface corresponding to the basal attachment. At *b* the surface of the polyp is smooth, but at *c* it is uneven, owing to the presence of many small indentations. *d* indicates cross sections of the little elevations projecting from the mucosa. At numerous points (*e*) cervical glands are seen opening on the surface. At *f* are cervical glands in the depth, and at *g* are cross sections of small terminal branches of the glands. The surface of the polyp and all of the glands are covered by one layer of epithelium. The stroma of the polyp is uniform throughout, but that surrounding the gland *h* is denser. This polyp consists essentially of cervical mucosa.

carcinoma. Consisting as they do of normal mucosa, their outer surfaces are covered by one layer of the characteristic high cylindrical epithelium, which is directly continuous with that lining the cervical canal (Figs. 174, 177). The glands of the polypi are cervical glands, which differ only from the wholly normal variety in being somewhat smaller. The stroma of the polypi is similar to and directly continuous with that of the cervical mucosa. Hence it will be seen that on histological examination no confusion can arise between cervical polypi and adeno-carcinoma of the cervix. Not infrequently cross sections of these polypi are seen in the scrapings, and are easily recognised from the fact that they are

completely surrounded by one layer of high cylindrical epithelium and contain typical cervical glands.

To the examining finger such polypi appear smooth; they slip away from the touch and do not tend to bleed.

Gyn. No. 6,447

Cervical polyp springing from the posterior lip (Figs. 175 and 176). Histological appearances (Fig. 177).

V., aged twenty-nine; white. Admitted October 18, 1898.

The patient commenced to menstruate at sixteen, and was usually regular. Her last period ended five days ago. For two or three years she has had consid-

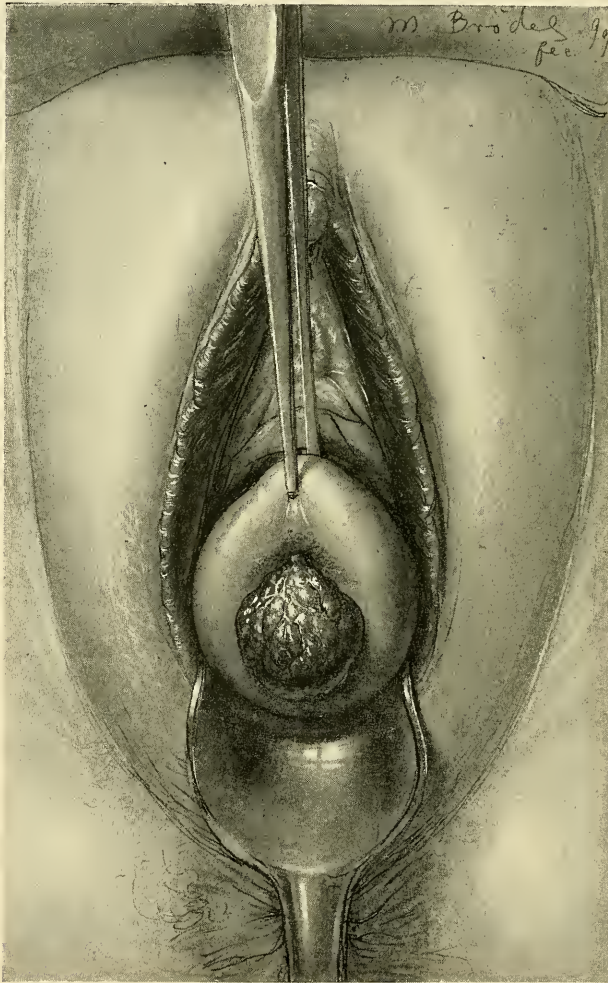


FIG. 175.—A CERVICAL POLYP. (Natural size.)

Gyn.-Path. No. 6,447. The cervix presents the usual appearance, but projecting from the external os is seen a growth, about 1.5 centimetres in diameter, which has a finely lobulated surface. A reference to Fig. 176 shows that it originates from the posterior lip.

erable backache, which is increased by exertion. Her general health is good. She is fairly well nourished, and has a good colour.

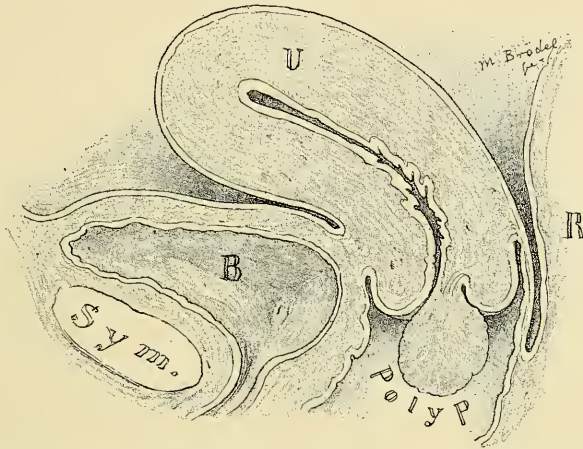


FIG. 176.—POLYP SPRINGING FROM THE POSTERIOR LIP OF THE CERVIX. ($\frac{3}{4}$ natural size.)

Gyn. No. 6,447. This sketch represents Fig. 175 on sagittal section. The bladder, uterus, and rectum retain their normal anatomical relations. Attached by a constricted pedicle to the inner portion of the posterior lip of the cervix is a pear-shaped polyp, which projects from the external os.

Vaginal examination. The outlet is intact. About 3 centimetres from the external os, on the left side, is a reddish-brown, soft, cone-shaped mass, which is freely movable (Figs. 175 and 176). The diagnosis of cervical polyp is readily made.

October 19th. The pedicle of the polyp, which was 5 millimetres in length, was controlled by a pair of artery forceps and the growth cut away. The forceps were removed on October 24th, and the patient was discharged October 27th.

Gyn.-Path. No. 2,663. The specimen consists of a rounded piece of tissue 1.5 centimetres in diameter. The surface is glistening, but is slightly uneven, and in places shows hæmorrhagic areas. A raw surface, about 7 millimetres in diameter, evidently represents the site of its attachment to the cervix. On section, the tissue is found to be rather firm; the central portion is occupied by a cyst fully 5 millimetres in diameter.

Histological Examination (Fig. 177).—The outer surface of the growth is very uneven, and shows here and there slight indentations, while at other points glands are seen opening on the surface. The epithelium covering the surface and lining the glands is uniform in size, and corresponds with the high cylindrical cells of the cervix. The cell protoplasm takes the hæmatoxylin stain; the nucleus is situated near the base of the cell. Several of the little out-growths from the surface present a distinctly papillary arrangement. Their surfaces are covered by one layer of epithelium, and their stroma contains small gland-like spaces, evidently due to cross sections of little indentations. The epithelium is uniform in size, and there is no increase in the amount of chromatin. The stroma of the growth consists of spindle-shaped cells, rather densely packed. Scattered throughout it are a few typical cervical glands. The cyst occupying

the centre of the growth is a dilated gland. Its epithelium is considerably flattened. The growth is evidently a cervical polyp.

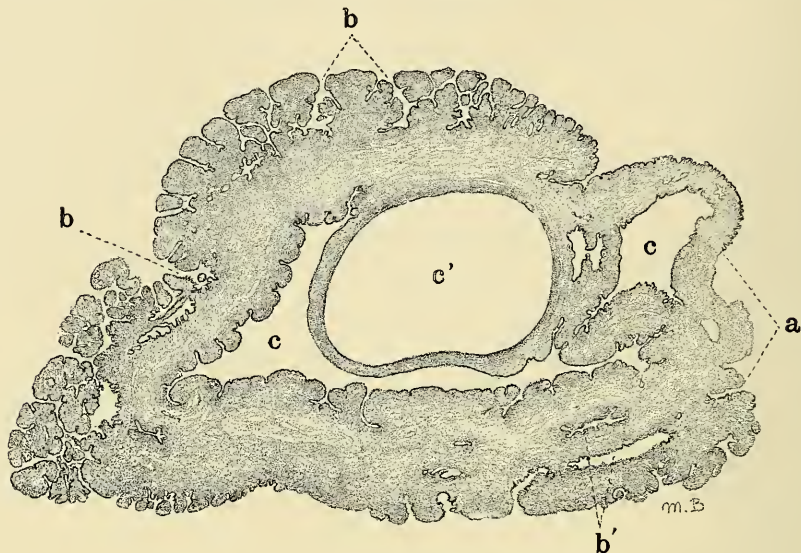


FIG. 177.—A CERVICAL POLYP. (8 diameters.)

Gyn.-Path. No. 2,663. This is a longitudinal section of the polyp seen in Fig. 175. The point of attachment is indicated by *a*. The outline of the growth is very uneven, owing to the fact that many glands open upon the surface. Some fairly characteristic glands are seen at *b* and *b*. *b'* shows glands on cross section. *c c'* are uterine glands, the latter being greatly dilated. The surface of the polyp, the glands seen opening on the surface as well as those in the depth, are covered by one layer of epithelium. The polyp is made up entirely of cervical mucosa.

Macroscopically, the comparative smoothness of the growth, its uniform firmness, and homogeneous colour are all against a malignant tumour. On histological examination, the picture, as a whole, would not for a moment be mistaken for one of carcinoma, although by themselves the complicated papillary branchings, seen on the surface at a few points, might readily lead to an erroneous conclusion. The facts, however, that the epithelium is uniform in size, does not contain any increase in chromatin, and shows no tendency to invade the stroma, indicate clearly the benign character of the growth.

SUBMUCOUS CERVICAL MYOMATA

Submucous myomata of the cervix are usually very small. When one or more are present, the cervix, on palpation, feels hard and nodular. A similar condition is sometimes noticed in adeno-carcinoma, when the growth is localized, but in the latter case a history of a watery discharge, and probably of some hæmorrhage, can usually be obtained. As a rule, when a submucous myoma is present in the cervix, other myomata are scattered throughout the uterine walls. Hence the organ may be larger than normal, and hæmorrhages are not unlikely to occur. On introducing the finger into the cervical canal, which in these cases is often patulous, a rounded nodule can be felt in the cervical wall, projecting somewhat into the canal. The elevated area is covered by smooth

mucosa, which, unlike carcinomatous tissue, does not break down under the finger. If there still be doubt, the curettings obtained from a case of sub-mucous myoma will show slight atrophy, and probably small-round-cell infiltration of the cervical mucosa, while in adeno-carcinoma the characteristic epithelial proliferation will be demonstrable.

INTERSTITIAL CERVICAL MYOMATA

These are small, and on palpation are found to be deeply seated in the cervical wall. On introducing a probe into the canal and carefully palpating on all sides, the mucosa is found to be intact, showing no areas of friability. There is little danger of confusing a myoma with an adeno-carcinoma.

ADENO-MYOMATA PROJECTING INTO THE CERVICAL CANAL

From time to time adeno-myomata have been reported, but the recent exhaustive work of von Recklinghausen* has given great impetus to research in this direction. Most of the monographs have dealt with interstitial or subperitoneal adeno-myomata, but a few mention adeno-myomatous tumours projecting into the uterine cavity. Diesterweg† reported the case of a woman who for three years had had profuse and painful menstruation; on vaginal examination, a nodule, the size of a hen's egg, presented at the external os. Its surface was somewhat eroded, and the pedicle, which was one inch in thickness, sprang from the uterine cavity. The nodule was composed of concentric layers, and in its centre was a large cavity, which presented numerous small depressions, and resembled somewhat a ventricle. There was also a similar cavity about the size of a cherry. Both cavities were lined by cylindrical ciliated epithelium, and contained blood. Two years later the patient again entered the hospital on account of profuse menstruation, and the enlarged uterus admitted a sound for a distance of 13 centimetres. After the administration of ergotin a tumour, the size of a man's fist, presented at the external os. It was removed, and found to contain a cyst the size of a walnut, lined by cylindrical ciliated epithelium and filled with blood.

In 1896, while describing two cases of adeno-myoma uteri diffusum benignum, I incidentally mentioned the presence in the first case of a cervical polyp. This was 2.5 centimetres in diameter, apparently covered by somewhat hæmorrhagic mucosa, and sprang from the right side of the cervix (Fig. 282, p. 537). On histological examination, this nodule was found to be composed of non-striped muscle fibres; its outer surface was covered in places by cylindrical epithelium, but for the most part by several layers of spindle-shaped connective-tissue cells. Scattered everywhere throughout the muscle were gland-like spaces varying from a pin-point to 3 millimetres in diameter. The majority of these were small,

* Von Recklinghausen. *Die Adenomyome und Cystadenome der Uterus und Tubenwandung*. Berlin, 1896.

† Diesterweg, A. *Ein Fall von Cystofibroma uteri verum*. *Zeitschr. f. Geburtsh. u. Gynäk.*, 1883, Bd. ix, S. 191.

round, tubular, or branching, and showed little tendency to become convoluted. They were lined by one layer of epithelium, which in the smaller glands was of the high cylindrical variety; in the dilated ones, cuboidal or flat. The protoplasm of the cells took the hæmatoxylin stain; the nuclei were oval and vesicular, and in many places it was possible to make out cilia. The glands were empty, or contained a granular material that took the hæmatoxylin stain.

These two cases suffice to demonstrate the benign character of the growths from a histological stand-point, as the glands showed no tendency whatever to become malignant. From the clinical side von Recklinghausen's* investigations, as well as those of others and of myself, have shown that adeno-myomata may exist for years, and that they are not malignant.

TUBERCULOSIS OF THE CERVIX

In tuberculosis of the cervix, when the changes are most pronounced between the external and internal os, indications suggestive of adeno-carcinoma may be found. Recently a case of this nature came to autopsy in the hospital, and Dr. Flexner kindly placed the generative organs at my disposal. The case is described in detail on p. 193 (see Plate VI). Histological examination showed advanced tuberculosis of the cervix and body. All trace of cervical epithelium had disappeared. Thus the possibility of the existence of an adeno-carcinoma was definitely excluded.

E. Kaufmann † reports a most interesting case of an autopsy on a seventy-nine year old woman, in which he discovered tuberculosis of the cervix. The vaginal portion was atrophied. The external os was open and slightly eroded; the cervix was thick and appeared to be dilated. The inner surface was grayish white or yellowish in colour, partly nodular, owing to the tumour-like prominences projecting into the cavity, partly traversed by longitudinal folds, and in other portions irregular. In places it looked as if it had been scraped out. It was everywhere hard. On section, the cervical walls were found to be infiltrated by a yellowish-white, rather dry tissue. This infiltration ended at the internal os. Kaufmann immediately suspected carcinoma of the cervix, and from the picture accompanying his article one would undoubtedly favour this diagnosis. Histological examination, however, proved it to be a typical case of tuberculosis.

From these two cases it is clear that tuberculosis may at times give a picture closely resembling that found in carcinoma. In our case the patient had general tuberculosis, and hence some suspicion as to genital tuberculosis was naturally aroused. On examination of the gross specimen, the presence of the small tubercles in the floor of the vaginal ulcer, the soft character of the cervical growth, the marked thickening of the Fallopian tubes while their fimbriated extremities remained patent, and the history of general tuberculosis, would make the probability of tuberculosis of the cervix very great. In Kaufmann's case the cervical

* Von Recklinghausen. *Ueber die Adenocysten der Uterustumoren und Ueberreste des Wolff'schen Organs.* *Deutsche med. Wochenschr.*, 1893, Bd. xix, S. 825.

† Kaufmann, E. *Beitrag zur Tuberculose der Cervix uteri.* *Zeitschr. f. Geburtsh. u. Gynäk.*, 1897, Bd. xxxvii, S. 119.

growth was hard, and the patient had no general tuberculosis; hence the differentiation was much more difficult.

On histological examination, there is not the slightest possibility of confounding adeno-carcinoma with tuberculosis. In the latter the squamous epithelium has not proliferated; it is sometimes present, but at other times it may have disappeared (Fig. 292, p. 566). The cervical epithelium and the glands may be in part preserved, and, if so, present the usual appearance. The cervical tissue is infiltrated by tubercles, many of which present the typical appearance. Where the process is far advanced much of the tissue has become caseous, and tubercle bacilli are found. Above all, as has been said, in no case of tuberculosis does the epithelium show proliferation—the fundamental feature in the development of carcinoma.

DIFFERENTIAL DIAGNOSIS BETWEEN SQUAMOUS-CELL CARCINOMA AND ADENO-CARCINOMA OF THE CERVIX

Gross Differences.—The most instructive way by which the points of resemblance and difference between these two groups of carcinomata can be appreciated is to be found in a comparison of the gross drawings of squamous-cell carcinoma with those of adeno-carcinoma. In Case 2,625 (p. 305), which proved to be one of adeno-carcinoma, the growth occupies the cervical lips, which are nodular but do not break down (Fig. 156, p. 306); it might very readily be taken for a commencing squamous-cell carcinoma. In Case 3,923 (p. 314) the cervix is intact, and the finger-like folds are peeping through the external os (Fig. 162). The growth could hardly be mistaken for squamous-cell carcinoma, but, as we know, the latter may at times commence above the external os; hence the diagnosis could not be made with certainty. In Case 2,990 (p. 286) the vaginal portion of the cervix presents a worm-eaten, papillary appearance, which extends a short distance into the cervical canal (Fig. 150, p. 289). Under no circumstance could this growth, macroscopically, be differentiated from squamous-cell carcinoma, and from its position the latter diagnosis would undoubtedly be given.

Case 2,590 (Fig. 39, p. 55) differs only from Case 2,990 (p. 286) in that the growth does not extend so far up into the cervical canal; and yet, on histological examination, the former proves to be a typical squamous-cell carcinoma. In Case 2,415 (Fig. 71, p. 127), in which the growth is far advanced and has extended upward beyond the internal os and downward into the vaginal vault, macroscopically it is impossible to tell whether we have to deal with an adeno-carcinoma or a squamous-cell carcinoma. On microscopic examination, however, the squamous type is distinct.

Case 3,698 (Fig. 106, p. 208) is another example in which a squamous-cell carcinoma could very readily be mistaken for an adeno-carcinoma. We know that in adeno-carcinoma, when the disease commences high up in the cervix, the cervical lips may be intact, and such is the case here. Moreover, in adeno-carcinoma the tendency for the tissue to break down is not great, and solid nodular masses may form; this appearance is also met with here. Looking at this specimen one would be tempted to make a diagnosis of adeno-carcinoma

without awaiting the microscopic diagnosis. Case 2,591 (Fig. 143, p. 266, and Fig. 144, p. 267) is even more instructive from a diagnostic stand-point. The cervical lips are intact, but thickened; but on opening the uterus, one is astonished to find that the growth has extended upward almost to the fundus, and laterally to the broad ligament, while the disintegration is most marked near the internal os.

In those cases of squamous-cell carcinoma in which the growth commences far out on the vaginal portion of the cervix, and in the cases of adeno-carcinoma beginning in the cervical canal near the internal os, a fairly certain differential diagnosis can be arrived at from the gross appearances. Nevertheless, even the few examples just cited are amply sufficient to demonstrate the utter impossibility of making a positive diagnosis, when the growth commences near the external os. Under all circumstances it is advisable to await the results of the histological examination.

Histological Differences.—In squamous-cell carcinoma it is usually possible to trace the direct connection between the cell-nests in the depth and the surface epithelium along the margin of the growth. This connection being once established, little hesitancy need be felt in making a diagnosis, since we know that an adeno-carcinoma never arises from the squamous epithelium. On the other hand, in the early stages of adeno-carcinoma, the proliferation of the cervical epithelium from the surface or from the glands is usually found, thus giving a solid basis for a positive decision. The chief difficulty arises in those cases of adeno-carcinoma in which the gland epithelium has proliferated to such an extent that the gland as such has become obliterated. These areas might readily be taken for squamous-cell carcinoma, but on careful examination, even with the low power, an ill-defined gland-like arrangement is still to be made out, while a study of further sections embracing the margins of the growth will show the typical glandular arrangement. In Case 2,990 (p. 286), penetrating the posterior cervical lip were small finger-like or branching alveoli, completely filled with cells. The cells had oval or elongate-oval, deeply staining nuclei; between the individual elements were numerous small round cells, and the stroma of the tissue showed considerable small-round-cell infiltration. Thus far one would have been led to classify the growth as belonging to the squamous-cell variety, had it not been for the fact that the alveoli were very small and did not stand out as sharply as might have been expected. On examining additional sections the reason for this appearance was readily explained, and the true character of the growth determined with ease. Just within the external os the high cylindrical epithelium had in places proliferated in such a way as to form new glands, between which there was as yet no intervening stroma. The glands in the vicinity had undergone a somewhat similar change, the epithelium having proliferated in such a manner that instead of a single large gland there was a group of smaller glands. On careful re-examination of the areas that looked like squamous-cell carcinoma, a faint gland-like arrangement could readily be made out. A similar picture was met with in

Case 2,631 (p. 291). These cases indicate the necessity of always examining sections from various portions of the growth, since the study of only one or two slides might give a very erroneous idea of the actual condition. The advancing margin of the growth affords the truest picture.

Another possibility of confusing squamous-cell carcinoma with adenocarcinoma is well illustrated by Case 2,964 (p. 102). Here the scrapings had not been well hardened, and the central portions of many alveoli had partially or completely dropped out, only one or possibly two rows of cells being left around the margin. Such areas might at first sight have been taken for adeno-carcinoma. Sections from other portions of the scrapings, and later from the uterus, however, proved that the growth was a typical squamous-cell carcinoma. In Case 2,885 the central portions of many cell-nests had also dropped out.

In the accompanying table will be found the chief histological points of difference between squamous-cell carcinoma and adeno-carcinoma of the cervix:

SQUAMOUS-CELL CARCINOMA	ADENO-CARCINOMA
Starts from the squamous epithelium.	Commences in the cylindrical cervical epithelium.
Forms solid finger-like or branching ingrowths.	As a rule, grows as hollow cylinders or gland prolongations, which are also branched.
May form epithelial pearls.	Pearls are never found.
Cell-nests or alveoli are seen which are solid, unless the central portions have dropped out.	If the gland epithelium has proliferated to such an extent that the cavity is filled, a faint gland-like arrangement can still be made out even with the low power of the microscope.
Breaks down rapidly.	Disintegration is much slower.

ENDOTHELIOMA OF THE CERVIX

This condition in the cervix is very rare, not more than two or three cases having been reported. The chief features may be conveniently given by detailing a case that was worked up in our laboratory, and which was reported by my colleague, Dr. E. Hurdon.

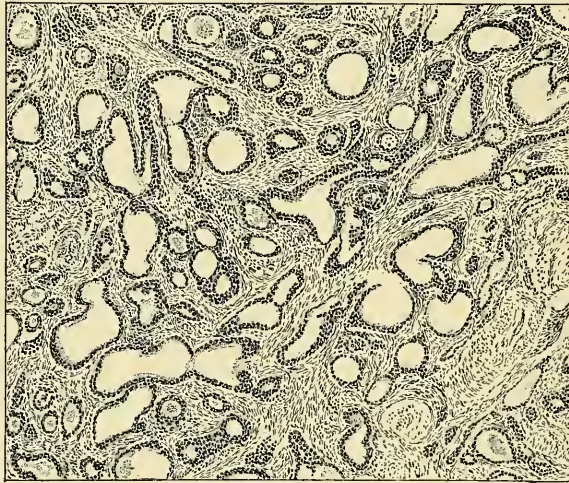
Gyn.-Path. No. 1,405. Endothelioma of the cervix with much thickening of the posterior lip; extension to the broad ligaments; small polyp in the uterine cavity; histological pictures of the malignant growth (Figs. 178, 179, and 180).

Gyn.-Path. No. 1,405; also 1,442. December 14, 1896.

Operation, pan-hysterectomy (Dr. Kelly).

The specimen consists of the uterus with the appendages intact. The uterus measures $8 \times 5 \times 3$ centimetres; its external surface is smooth and glistening. The cervical portion is enlarged, measuring 4.5×3.5 centimetres, and is markedly indurated. The external os is represented by a crater-like excavation covering an area measuring 2.5×2 centimetres, and being 2 centimetres in depth. The anterior lip has been eaten away; the posterior lip is thickened laterally, being 2 to 3 centimetres in thickness. The floor of the excavation is corrugated and roughened, but there is no evidence of softening or friability until the upper

part of the cavity is reached. The mucous membrane of the upper part of the cervical canal is apparently unaltered, but the walls of the entire cervix, and also of the lower segment of the body, more especially posteriorly and on the left side, are thickened, mark-



H. Beckwith

FIG. 178.—ENDOTHELIOMA OF THE CERVIX. (45 diameters.)

Gyn.-Path. No. 1,405. Scattered everywhere throughout the stroma are round, oval, oblong, or branching spaces, lined by one or more layers of cells, which are uniform in size. Note the intimate relationship between these cells and the stroma, there being no tendency whatever for the cells to drop off, as is so often the case in adeno-carcinoma. (After ELIZABETH HURDON.)

edly indurated, and on section present a dense fibrillated structure. The uterine cavity has a smooth mucous membrane, but on the posterior wall is a small polypoid thickening, while springing from the centre of the anterior wall is a pedunculated, flattened, mushroom-like polyp, 2 centimetres in diameter. The appendages present nothing of interest.

Histological Examination.—The lower portion of the cervix is covered by stratified squamous epithelium, but on advancing inward toward the apex of the excavation, which macroscopically presented an eroded appearance, the surface becomes necrotic. Above the necrotic area the cervical canal is lined by normal cylindrical epithelium. The cervical glands are in a few places dilated, but for the most part are practically normal. Ramifying in the tissue at the floor of the excavated area, penetrating all portions of the cervix even to the mucous membrane internally, reaching the broad ligament laterally and extending upward to the body of the uterus, are myriads of tubules. These sometimes form long sinuses and show some branching, but as a rule they appear as round or oval spaces (Fig. 178), which in many places are so abundant that the tissue looks not unlike portions of a lung in which there has been considerable increase of connective tissue. Many of the small spaces, and more particularly some of the larger ones, are lined by one layer of spindle-shaped cells, which are sometimes so flat as to be scarcely recognisable. Others are lined by one uniform layer of cells having oval, deeply staining nuclei (Fig. 179). It is practically im-

possible to differentiate the protoplasm of one cell from that of another. Many of the cells contain nuclear figures which may be in any stage of development. Not infrequently the cells have proliferated to such an extent that the cavity is lined by two, three, or even more layers of cells. These layers are irregular, and there may be two or three on one side and as many as six or eight on the opposite side. At numerous points the cells have proliferated to such an extent that the cavity is completely obliterated. Such areas look very much like the cell-nests found in squamous-cell carcinoma, but show the following differences: The nuclei throughout such an area stain uniformly, not presenting the usual vesicular appearance. In the outer layer the cells show little or no tendency to become cuboidal, as is so often the case in squamous-cell carcinoma. The majority of the spaces are empty; some, however, contain desquamated cells, fragmented nuclei, and shadows of cells. Surrounding many of the tubules are narrow zones of hyaline. The stroma of the tissue is abundant, exceedingly dense, and consists to a great extent of normal cervical tissue. In the deeper portions there is a considerable amount of non-stripped muscle fibres and a moderate infiltration with small round cells. Blood-

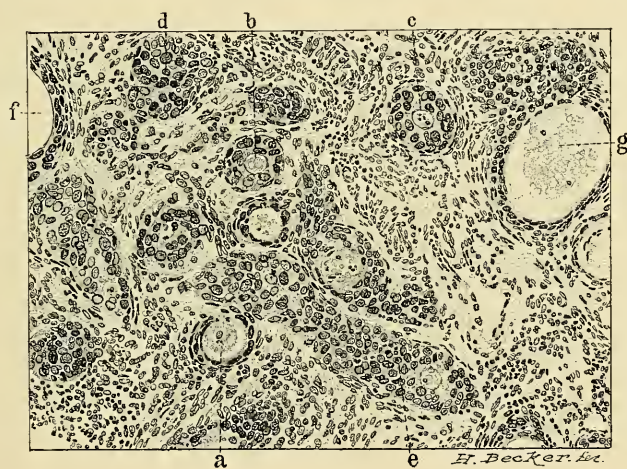


FIG. 179.—ENDOTHELIOMA OF THE CERVIX. (120 diameters.)

Gyn.-Path. No. 1,405. *a* represents a space lined by a single layer of cells, spindle-shaped on one side and very low cuboidal on the other. In the centre is detritus and a desquamated cell. At *b* a space is lined by two layers of cells, at *c* by three layers, while at *d* a cell-nest has been formed. *e* is a cell-nest seen on longitudinal section. *f* is the margin of a dilated space in which there are from two to three layers of partially flattened cells. *g* shows a similar space containing a considerable amount of granular detritus. The areas *a*, *b*, and *c* more particularly do not resemble the glands found in adeno-carcinoma. (After ELIZABETH HURDON.)

vessels are fairly numerous, and show marked obliterative endarteritis and arteriosclerosis. The uterine mucosa is practically unaltered. The tubes and ovaries present the usual senile appearance.

Diagnosis.—Endothelioma of the cervix uteri, extending laterally into the parametrium and upward into the body of the uterus. Normal appendages.

As may be gathered from the foregoing description, the growth was exceedingly firm, in contrast to what is found in most cases of adeno-carcinoma. On histological examination, although there are numerous points of similarity, the following differences are marked: 1. The cervical glands, even in the older portions of the growth, appear normal, while in adeno-carcinoma they almost invariably show cell multiplication. 2. The spaces appear as isolated tubules or round areas, exhibiting little tendency toward branching, while in adeno-carcinoma the glands usually occur in bunches, and branching is frequent. 3. There are no teat-like ingrowths of the cells, as in carcinoma. 4. The protoplasm of one cell cannot, in the majority of places, be differentiated from that of the adjoining cells, and there is little or no tendency to desquamation. 5. Many of the spaces, both large and small, are lined by one layer of spindle cells.

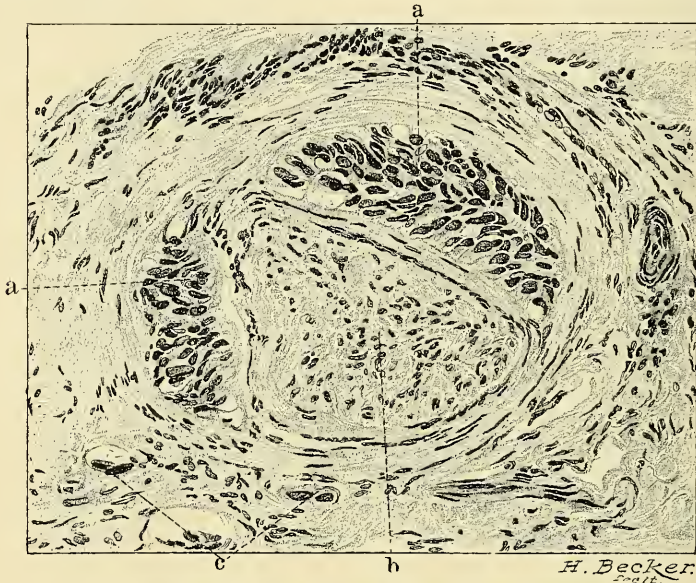


FIG. 180.—ENDOTHELIOMA OF THE CERVIX. (250 diameters.)

Gyn.-Path. Nos. 1,405 and 1,442. The section has been taken from the broad ligament. *a* and *a* are masses of cells from the growth, and partially surround *b*, which is probably an obliterated vessel. The cells are readily recognised by their large size and deeply staining nuclei. At *c* are a few isolated tumour cells, which have retracted considerably from the surrounding stroma, leaving empty spaces. (After ELIZABETH HURDON.)

In adeno-carcinoma it is exceptional to find the epithelium spindle-shaped; this form occurs only when the gland is distended and the epithelium has been flattened by pressure. The tubules in this case offer no evidence of pressure. In adeno-carcinoma it is often possible to trace the glandular origin, but in our case of endothelioma no clew could be elicited as to the starting-point. Quite a number of the alveoli were surrounded by zones of hyaline—a condition that I have not noted in adeno-carcinoma of the cervix. Thus, in endothelioma there are many points of difference, and the diagnosis, as a rule, should not be very difficult, although in the rare form of adeno-carcinoma, described by Ruge and Veit as well as by Gebhard, and exemplified by Case 2,625 (Fig. 156, p. 306, Fig. 157, p. 307, and Fig. 158, p. 308), there is considerable resemblance.

CHAPTER XIII

ADENO-CARCINOMA OF THE BODY OF THE UTERUS

1. Gross appearances of adeno-carcinoma of the body of the uterus.
2. Histological appearances.
3. Cases illustrating the various stages of adeno-carcinoma of the body of the uterus.

WHILE squamous-cell carcinoma and adeno-carcinoma of the cervix, in some cases almost from the beginning, and in others at some later time during their course, are recognisable *in situ* with the naked eye, adeno-carcinoma of the body rarely extends to the external os, and we have, therefore, to rely mainly upon the microscope for the diagnosis. An important stimulus for careful work on these lines is supplied by the fact that the prognosis in adeno-carcinoma of the body is generally favourable, provided that the process be detected in the early or comparatively early stages.

It will be remembered that the uterine cavity commences at the internal os and extends upward to the fundus, a distance of from 3 to 5 centimetres; at the internal os the cavity is not more than from 5 to 8 millimetres wide, but broadens out until at the uterine horns it is fully 3 to 3.5 centimetres in its transverse diameter. The mucosa varies from 2 to 4 millimetres in thickness; it is pinkish in colour, and usually smooth and glistening. A slightly undulating surface is not uncommon, and the presence of a small polyp has little significance.

GROSS APPEARANCES OF ADENO-CARCINOMA OF THE BODY

Adeno-carcinoma of the body may commence at any point within the cavity. It is recognised as a circumscribed growth springing from the surface of the mucosa, and consisting of many delicate, finger-like processes, which give it a somewhat shaggy appearance. Such a picture is supplied by Fig. 184 (p. 363). Occupying the anterior wall, near the fundus, is a new growth not more than 4 millimetres in thickness, and consisting almost entirely of delicate, finger-like outgrowths. In this case the uterus has preserved its normal contour, and is smaller than usual. In Fig. 185 (p. 365), we also have a very early growth, which springs from the fundus and presents a finely lobulated surface.

The carcinoma gradually becomes thicker, and may appear as a branched or tree-like outgrowth, consisting of several main stems and numerous offshoots, with the delicate fingers as terminal branches. Such a growth is soft to the touch, and feels like brain tissue (Fig. 190, p. 373, Fig. 191, p. 374). Occasionally a case is

met with in which nearly all stages of the process are demonstrable. Thus, in Fig. 193 (p. 377) it is possible to trace its development with the utmost ease, from the tiny finger-like projections to the relatively immense growth. Near the internal os, isolated, minute prickles are seen springing from the surface of the mucosa. As one advances upward a short distance these are found to be more abundant, and consequently closer together. They soon become longer, and gradually form a single base, so that we now have a solid mass with delicate fingers springing from the surface. In the oldest or central portion these fingers have merged into one another throughout their entire extent, making up a smooth or slightly lobulated, solid mass. Somewhat similar growths are seen in Fig. 201 (p. 384), Fig. 236 (p. 451), and Fig. 231 (p. 442).

Although, as a rule, the carcinoma commences at one particular point, it sometimes happens that in the very earliest stages the whole mucosa is found to be involved, development apparently taking place simultaneously in all parts of the cavity (see Fig. 207, p. 394; Fig. 208, p. 395). In a few instances the growth in the cavity may take the form of polypi, which vary considerably in size. These are usually very soft and friable, as was the case in Fig. 237 (p. 454); but in Fig. 212, in which is represented a remarkable polypoid formation, many of the polypi were exceedingly dense, and slipped away easily from the finger. These features, as was subsequently shown by histological examination, were the result of the presence of an excess of connective tissue.

In rare instances the proliferation of the epithelium is so abundant that the uterus is much enlarged, and the cavity is filled with large and small, fairly smooth, dome-shaped masses, showing but little trace of the delicate fingers. Fig. 210 (p. 399) illustrates the most pronounced case of this character that I have ever met with. With the ingrowth into the cavity, there is a corresponding, though usually more tardy, penetration of the uterine walls, the growth being whitish yellow, fairly homogeneous, but soft, and standing out in sharp contrast with the surrounding muscle. The extension is usually irregular, as is seen in Fig. 222 (p. 422) and Fig. 210 (p. 399). Eventually the growth reaches the outer surface, as shown in Fig. 207, in which, just beneath the peritoneal surface, are seen several rows of small, smooth elevations. These were whitish yellow and soft, and could not for a moment be mistaken for myomata.

With the gradual advancement of the growth there naturally come about necrosis and disintegration of the older portions (Fig. 205, p. 391). The finger-like processes disappear, and we have a sloughing and foul-smelling crater-like area representing the uterine cavity. It is this disintegrating material that goes to form the offensive vaginal discharge.

HISTOLOGICAL APPEARANCES OF ADENO-CARCINOMA OF THE BODY OF THE UTERUS

In considering the histological changes in adeno-carcinoma of the body of the uterus in detail, it must be remembered that no one case will give a complete picture, and that it is only from the study of many instances that any exact idea of the progress of the disease can be obtained, although from nearly every one some new feature may be gleaned. The two chief elements taking part

in the development of the carcinoma are of course the surface and the gland epithelium.*

Changes in the Surface Epithelium.—At some distance from the growth little mounds of epithelium will be found springing from the surface. These consist of two, three, or more layers of epithelial cells (Fig. 196, *b* and *b'*, p. 379), and are totally devoid of any supporting stroma (Fig. 195, p. 378). The epithelial cells, apart from occasional swelling of their nuclei, show nothing abnormal. In a short time these little outgrowths become longer, the stem of stroma from the underlying tissue accompanying them and carrying with it the vessels which furnish the necessary blood supply (Fig. 196, *b''*, p. 379). In some of these tufts the stroma is present in considerable amount (Fig. 197, p. 380), and the epithelial covering proliferates, forming new glands. The surface epithelium between the outgrowths remains normal. In the neighbourhood of the characteristic carcinomatous areas the projections become more numerous, until suddenly all trace of the normal mucosa disappears, and we have nothing but long and short, finger-like outgrowths covering the surface everywhere (Plate VIII). The isolated, very long fingers have an exceedingly scanty framework of stroma, and are covered by one or more layers of epithelium. The epithelial cells may be uniform in size, but as a rule show a good deal of disparity, some being fully three or four times as large as their neighbours, and staining deeply (Fig. 198, p. 381). Occasionally, instead of showing these delicate fingers, the outgrowth is rounded (Fig. 233, *a*, p. 445), having crenated margins, and being covered by many layers of epithelial cells fairly uniform in size. At other times, again, they are branched, and send off numerous terminal offshoots, consisting entirely of long, slender epithelial threads (Fig. 189, p. 372). Not infrequently the margins of these papillæ are crenated, showing depressions or bays along their sides and often at their tips (Fig. 183, p. 362). Both the main outgrowths and the various branches are covered by one or more layers of epithelium. When a single layer only is present, the cells are cylindrical, whereas when more than one are found, the secondary layers are more polymorphous in character. In this connection probably the most instructive illustration of our entire series is to be found in Fig. 181 (p. 357). This represents a section from a scraping, and shows a main stem with numerous primary and secondary branches. Both the stem and its branches are covered by many layers of epithelial cells, which are remarkably uniform in size. Proliferation has taken place, and as a result many new glands have been formed. Such a finger-like projection is frequently noted macroscopically, and in its contour bears a striking resemblance to a tree. The

* Adeno-carcinoma of the Body developing from Uterine Polypi.—Lubarsch, speaking of carcinomatous changes in benign tumours, says: "Quite a number of authorities are convinced that a benign tumour may become malignant, more particularly in the case of simple polypi and papillomata. Both Klebs and Ribbert accept this view. For our own part we are unable to answer this question in the affirmative or in the negative." Case 4,262 (p. 440), which I have recently had the opportunity of studying, shows beyond a doubt that such a possibility exists. We know that adeno-carcinoma is a derivative of the uterine epithelium: we also know that uterine polypi are nothing more than portions of the mucosa that have been partially nipped off; accordingly, it is just as natural that carcinoma should develop from the polyp as from the uterine mucosa.

marked uniformity in size of the epithelial cells, observed in this case, is not by any means characteristic. Fig. 235 (p. 447), taken from another case, represents the tips of two terminal folds. Here the nuclei, indicated by *c*, are greatly increased in size, are very irregular, and stain intensely. These cells alone are sufficient to stamp the growth as malignant. As seen in Fig. 181 (p. 357), the epithelial cells at the tips of the terminal folds often form glands. Fig. 234 (p. 446), taken from a different case, represents a new gland formed at the tip of a fold by a few very large cells, irregularly dovetailed into one another, and containing nuclei of varying sizes. Those indicated by *c* are very rich in chromatin.

From what has been said, it is evident that there is a distinct and progressively increasing proliferation of the surface epithelium, beginning with small outgrowths consisting of a few cells; we next have a larger growth containing stroma, which shows marked branching, and finally, an excessive proliferation of the epithelium with the formation of many new glands. Coexistent with the outgrowths from the surface epithelium we may have other changes, as shown in Fig. 214 (p. 404). Here at *c* the surface epithelium stains faintly and has become cuboidal, but on tracing it to the left, it is found to be two layers in thickness; at *d* several layers are observed, and finally, at *e* the proliferated cells are arranged in such a manner that the new glands (*e*) are formed. A somewhat analogous appearance is presented in Fig. 194 (p. 378); the epithelium is several layers in thickness, and new glands (*e*) have been formed. In the more advanced portions of the growth the epithelium covering the individual fingers has proliferated to such an extent that all trace of them is lost, and the surface is covered by a solid mass of epithelial cells closely resembling squamous epithelium. Such a picture is presented in Fig. 199 (p. 381).

Early Changes in the Gland.—In a few instances we have been able to trace the early gland changes. In Fig. 187 (p. 369) two normal glands are seen to the left in the lower part of the field, while occupying the upper part is a

FIG. 181.—ONE OF THE DELICATE BRANCHING OUTGROWTHS SO OFTEN SEEN MACROSCOPICALLY IN ADENO-CARCINOMA OF THE BODY OF THE UTERUS. (75 diameters.)

Gyn.-Path. No. 1,574. This is one of the fragments from a scraping from the body of the uterus, and was found lying free. It presents a delicate tree-like arrangement. The growth consists of a main stem or trunk (*a*), which sends off the branches *b*, *b'*, *b''*, *b'''*, and *b''''*. The stem and its branches consist of spindle-shaped connective-tissue cells, and are barely stout enough to carry the blood supply. Covering the main trunk and all its branches are many layers of epithelium, the layer of cells next to the stroma being arranged at right angles to it. From the branches the epithelium projects as delicate tufts (*c*), or may form more stable masses, as indicated at *d*. Occasionally, as shown at *e*, the surface of the outgrowth is perfectly smooth, and is covered by one layer of low cylindrical epithelium. Throughout the entire field the epithelial cells tend to form definite glands, as is particularly well shown at *f*, where the glands are lined by one layer of cuboidal epithelium. In the older portions, notably along the main trunk, the epithelium forms solid masses, as indicated by *g*. The nuclei of the epithelial cells are remarkably uniform in size and staining properties. At only one point (*h*) is there an enlarged and deeply staining nucleus. Since the framework is so scanty it is only natural that, with the continued progress of the growth, the older portions should gradually break down. Knowing that the tissue is from the uterine cavity, the general contour of the growth alone is sufficient to warrant a diagnosis of malignancy. The many newly formed glands supply ample confirmation of this view, and show that the neoplasm is an adeno-carcinoma.

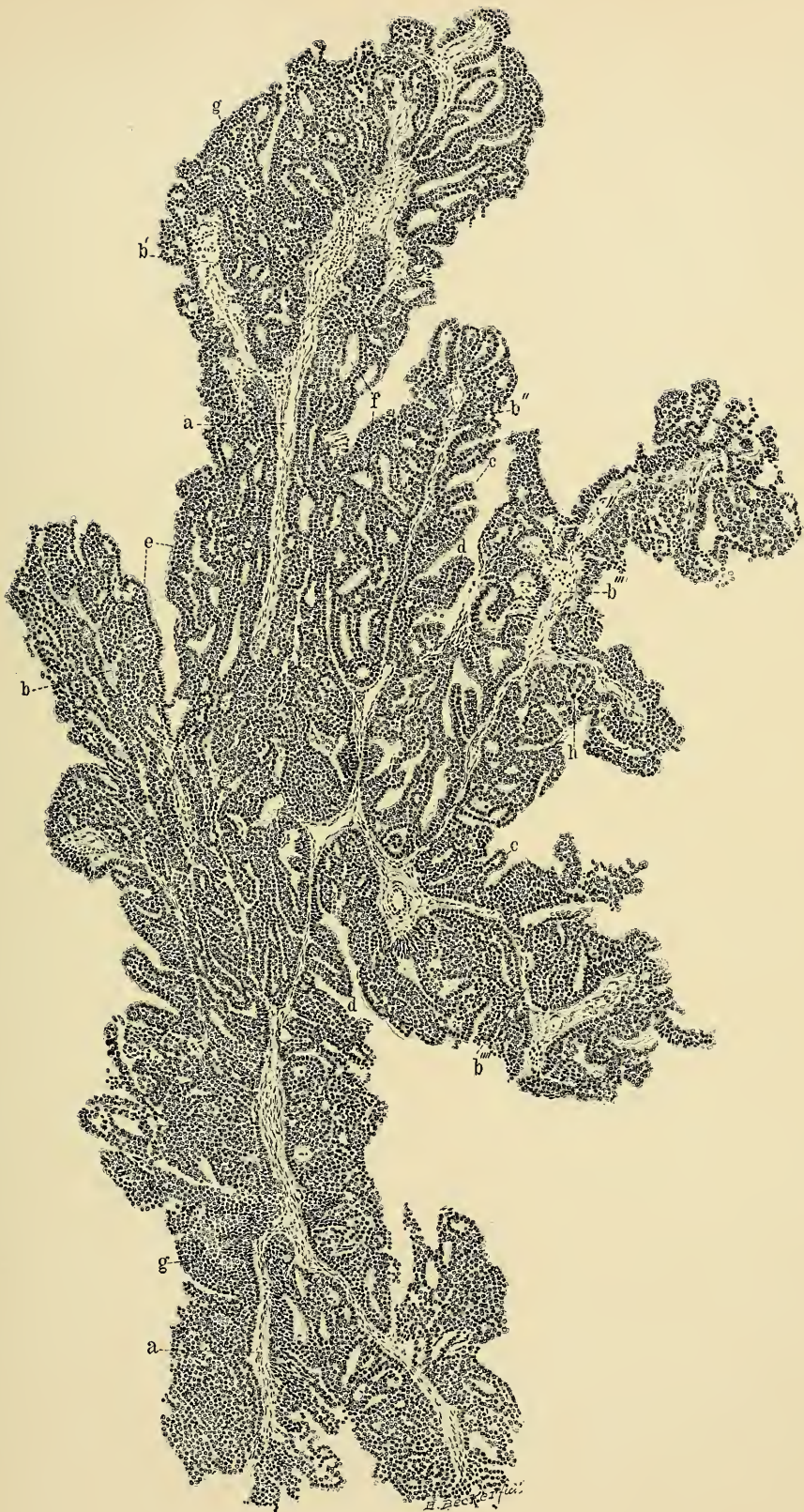

FIG. 181.

portion of a gland which stains only faintly. The cells are five or six layers deep, and the nuclei, although vesicular and staining faintly, are enlarged and irregular

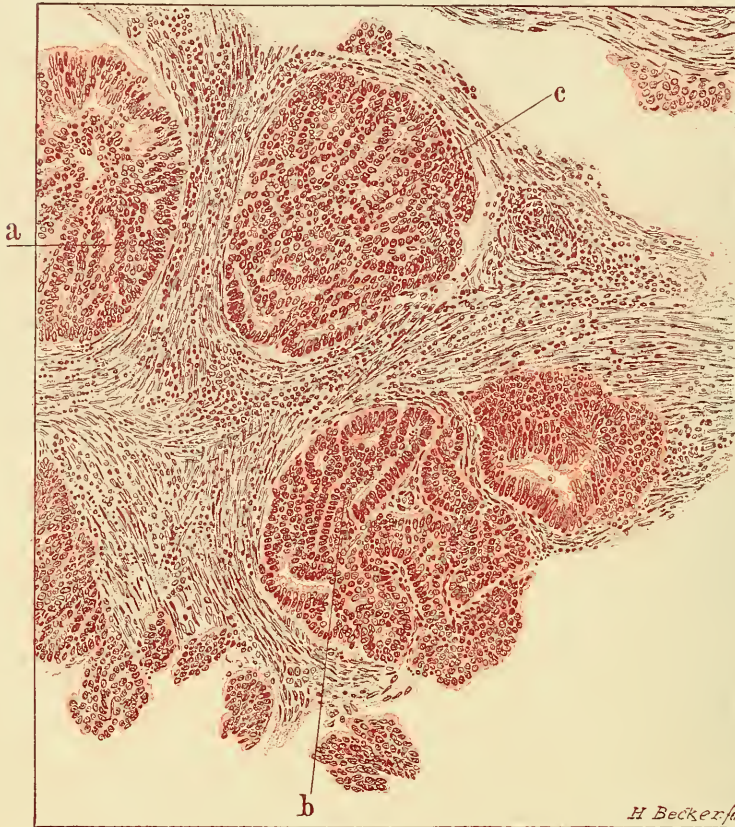


FIG. 182.—ADENO-CARCINOMA OF THE BODY OF THE UTERUS DIAGNOSED FROM A SMALL SCRAPING.
(160 diameters.)

Gyn.-Path. No. 1,117. Although the specimen consists of a very small piece of scraping, there is not the slightest doubt as to the diagnosis. At *a* we have a very convoluted gland with the epithelium several layers in thickness. At *b* is a group of glands lined by one layer of epithelium. This, in places, is regular, but at several points the nuclei are considerably enlarged and stain deeply. The area *c* is composed of many gland loops. The glands have increased so rapidly that they are pressed one against the other, and are consequently much distorted. In the left lower corner is a mass of epithelial cells, from which all evidence of the gland type has disappeared. The scraping is evidently from the uterine wall, as the stroma consists of muscle. It shows considerable small-round-cell infiltration. The areas *a* and *b* are suspicious, but the skein-like grouping in the glands at *c* leaves no doubt that the growth is an adenocarcinoma.

in outline. The increase in the size of the gland, its tendency to stain faintly, and the formation of many layers of cells, are particularly striking in Fig. 214 (p. 404); these points should instantly make one suspect carcinoma, although this picture by itself is not conclusive. On passing toward the more active portion of the growth, it will occasionally be possible to detect the gland epithelium proliferating and forming new glands. Such a condition is met with in Fig. 188 (p. 370). Here is seen a large gland, in the upper half of which

the epithelial lining is perfectly normal, whereas in the lower half it has proliferated to such an extent that nearly twenty young glands have developed. The newly formed glands lie side by side, or are separated from one another by epithelial cells. Little or no stroma is present between them. In Fig. 220 the gland epithelium at a few points is comparatively normal, but in the upper part it shows marked proliferation, and numerous young glands (*e*) appear. In these glands it will be noted that the epithelial cells vary much in size, and some of them contain very large, deeply staining nuclei, indicated by *d*.

The gland grouping in carcinoma of the body of the uterus, as might be expected from the lawless growth of the epithelium, varies greatly. Not only is it rare to obtain two cases just alike, but even in the same case sections from different portions of the growth show marked divergences. In Plate VIII we see the glands extending down between the finger-like outgrowths, the epithelium of the outgrowths being continuous with that lining the glands. At the points indicated by *b*, deep in the muscle, we have large bunches of glands cut longitudinally, obliquely, transversely, and, in fact, in every conceivable direction. The glandular type is here well preserved, but in other parts of the same specimen the gland cavities are completely filled with cells. In Fig. 242 (p. 462), Fig. 192 (p. 376), Fig. 215 (p. 406), and Fig. 189 (p. 372), the gland arrangement is also well preserved, but in other sections from these cases the epithelium formed solid masses. In Fig. 206 the arrangement is very complicated, especially at *d*, where the gland presents a markedly festooned appearance. In Fig. 221 (p. 419) the gland grouping is particularly well preserved at *a*, *a'* and *d*. In the central portion of the field the epithelium has proliferated to such an extent that only a few gland spaces, *g*, *g'*, *g''*, remain. In Fig. 211 the epithelium has increased until the growth resembles a papilloma of the ovary, and only at *c* is there any clew as to its glandular origin. A review of these few cases is sufficient to show that a clear idea of the varied glandular arrangement in adeno-carcinoma of the body of the uterus can only be obtained by a careful study of many instances; and that while all can be classed under one main group, each case has its individual characteristics.

In a few cases in which we have parallel rows of gland epithelium, the picture may be somewhat suggestive of the syncytial bands seen in deciduoma malignum (Fig. 240, p. 458). Where the gland epithelium has proliferated so that it fills the entire cavity, it bears a striking resemblance to squamous epithelium (Fig. 165, p. 321). In fact, so great is the similarity, that some authorities have thought that squamous-cell carcinoma and adeno-carcinoma existed in the same case. Fig. 200 (p. 382) also affords a good example of the thickened and swollen gland epithelium. The section was taken from the muscle, nearly 1.5 centimetres from the uterine cavity.

The nuclei of the gland epithelium may be very uniform in size, as in Fig. 221 (p. 419), Fig. 242 (p. 462), Fig. 192 (p. 376), Fig. 211 (p. 400), Fig. 215 (p. 406), Fig. 189 (p. 372), Fig. 214 (p. 404); or they may be enlarged, irregular, and deeply staining, as in Fig. 230 (p. 441), Fig. 220 (p. 418), and Fig. 206 (p. 392). Nu-

clear figures in all stages are frequently present, and giant cells are occasionally found in the gland walls (Fig. 227, p. 432). These changes, together with the retrograde metamorphoses that take place in the cells, will be treated of in detail in the chapter on Etiology. The gland cavities are frequently empty, but may contain desquamated epithelial cells, polymorphonuclear leucocytes, and detritus.

Gebhard* and Winter and Ruge † lay stress on the fact that the growth sometimes shows a great tendency to form papillary outgrowths, there being a central stem, generally covered by one layer of cells. This group of cases they would class under the "everting form," in contradistinction to those in which the glands are very large, have many convoluted ingrowths, and always retain a central lumen—"the inverting form." They are inclined to make two separate groups of these varieties, but since both are frequently associated in the same case, such a classification would not seem to be advisable. I am strongly of the opinion that where the papillary arrangement is most marked, the growth has started in the surface epithelium; whereas it seems probable that when the gland-like arrangement is more pronounced, the process has started first in the glands. The simpler plan will be to consider all these conditions merely as variations occurring in one disease.

The stroma of the papillary folds is usually composed of spindle-shaped cells, which rapidly diminish in number as the tip of the papilla is reached. It is derived from that of the mucosa, and shows considerable small-round-cell infiltration. It frequently has a very abundant blood supply. The deeper portions of the growth invade the muscle, and the latter shows a varying amount of small-round-cell infiltration, particularly abundant along the advancing margin of the growth. Orth has occasionally noticed a distinct zone of hyperæmia along the outer portions of the tumour.

With the advance of the disease there is a breaking-down of the older portions of the growth. The surface becomes necrotic (Fig. 202, p. 385), and shows considerable small-round-cell and polymorphonuclear leucocytic infiltration, while the glands, sometimes even in the deeper portions, show coagulation necrosis. Scattered throughout the deeper portions of the tissue, especially in the centre or margin of a necrosed gland, but occasionally in the stroma, are irregular, laminated, calcareous plates, which with hæmatoxylin and eosin take the former stain with avidity. Lubarsch ‡ has pointed out the presence of these calcareous particles, which were also seen in Fig. 203 (p. 387). As the process of degeneration advances still farther, the necrosis extends to the uterine muscle, and both the muscle and glands are overwhelmed with polymorphonuclear leucocytes.

* Gebhard, C. *Ueber das maligne Adenom der Cervixdrüsen. Zeitschr. f. Geburtsh. u. Gynäk.*, 1895, Bd. xxxiii, S. 443.

† Winter u. Ruge. *Lehrbuch der gynäkologischen Diagnostik*. Leipzig, 1896.

‡ Lubarsch, O. *Ergebnisse der allgemeinen pathologischen Morphologie und Physiologie des Menschen und der Tiere*. Lubarsch und Ostertag, Wiesbaden, 1895.

Cases illustrating the Various Stages of Adeno-carcinoma of the Body of the Uterus

Gyn. No. 2,436

Adeno-carcinoma of the body of the uterus (Fig. 184), diagnosed from scrapings (Fig. 183). Vaginal hysterectomy. Perinaeum on right side incised nearly to the rectum to secure the requisite working space. Patient in good health, six years after operation.

M. E. G., aged fifty-three; white. Admitted November 30, 1893. The patient has had four children. Her menses ceased eight years ago. In October, 1892, she noticed a slight bloody discharge. This reappeared at frequent intervals, being sometimes replaced by a watery or purulent flow. Of late she has had excruciating pain in the lower part of the abdomen, more especially in the left groin. On admission, the patient appears to be in great pain, looks dull and listless, and is continually moaning. The mucous membranes are of a good colour; the appetite is poor; the bowels are regular. She has almost constant pain in the lower part of the abdomen and back. The patient was anaesthetized, and the uterus was found to be retroflexed but non-adherent. On curetting the uterus a large amount of tissue was brought away; and to control the free haemorrhage which followed, it was necessary to close the cervix with silkworm-gut ligatures.

Gyn.-Path. No. 100. The specimen consists of a small amount of scrapings from the uterine cavity.

Histological Examination.—Some portions of the specimen present a markedly convoluted glandular appearance. The gland cavities are lined occasionally by one, but much more often by several layers of epithelium. The nuclei of the epithelial cells are oval and vesicular. Projecting into the gland cavity are knob-like folds, each consisting of a delicate stem of connective tissue with a covering of several layers of epithelium. When the gland cavity is nearly filled with cells, those occupying the central portion appear to be somewhat swollen; their protoplasm stains palely, and their nuclei are somewhat enlarged. They look not unlike squamous epithelial cells (Fig. 183). Many portions of the specimen consist of irregular stems of connective tissue, traversing which are delicate blood-vessels. The stems send off twigs. The stem and its branches are covered by one, or more frequently by several layers of epithelium. Sometimes the small branch has been cut across in such a way that in the centre a blood-vessel is seen, with a small amount of connective tissue surrounding it, the whole being enveloped by several layers of cells. Taking in consideration such points alone, angiosarcoma would immediately be suspected.

Diagnosis.—Adeno-carcinoma of the body of the uterus. Hysterectomy is advised.

Operation, December 4th. Vaginal hysterectomy. The outlet being very narrow, it was incised on the right side nearly back to the rectum. The operation was then proceeded with in the usual way. The perineal incision was sutured and the vagina packed with gauze. On the eighth

day there was slight breaking down of the perinæum, and about half a dram of pus was discharged. The patient left the hospital December 23d.

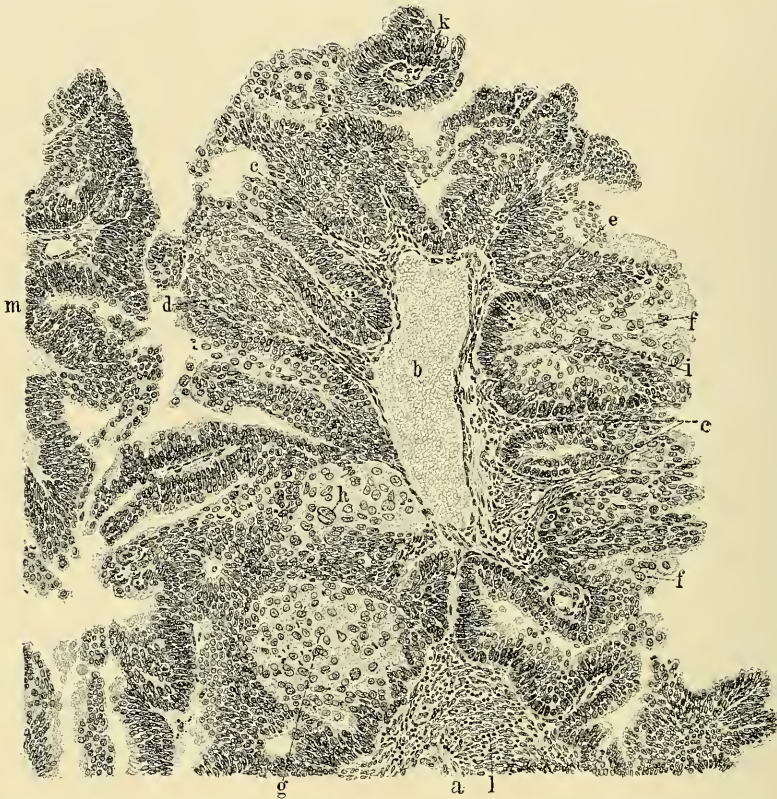

FIG. 183.—ADENO-CARCINOMA OF THE BODY OF THE UTERUS. SCRAPINGS FROM WHICH THE CONDITION SHOWN IN FIG. 184 WAS DIAGNOSED. (125 DIAMETERS.)

Gyn.-Path. No. 100. The picture represents one of the little finger-like projections seen springing from the surface of the mucosa in Fig. 184. *a* is a stem with a broad base, and containing near its tip the large blood-vessel *b*. Passing off laterally are many secondary stems of stroma, some of which are indicated by *c* and *e*. Covering these secondary stems, and filling in the spaces between them, are many layers of epithelial cells. They may form a homogeneous mass, as at *d*, where the cell nuclei are all uniform and vesicular. In other places the cells next the stroma are cylindrical, and are arranged at right angles to the stroma (*e*). Those between the secondary stems are swollen, surrounded by much protoplasm, and resemble squamous epithelium, as at *f*. *g* is a similar area, and in *h* one cell contains two large, somewhat deeply staining nuclei. At *i*, polymorphonuclear leucocytes have wandered out between the epithelial cells. *k* is a terminal stem, seen on cross section, and is covered by several layers of epithelium. The stroma at *l* shows small-round-cell infiltration. *m* is the margin of an adjoining finger. The tree-like arrangement is sufficient to render the diagnosis of carcinoma certain; the large nuclei at *h* are suggestive. Other portions of the scrapings showed a characteristic gland-like grouping of the cells.

Gyn.-Path. No. 100. The specimen consists of the greater part of the uterus. It is 9 centimetres long, 5 centimetres broad, and 3 centimetres in its antero-posterior diameter. Just anterior to the right tube is a firm subperitoneal nodule, 1 centimetre in diameter (Fig. 184). The uterine walls average 2 centimetres in thickness, and the cavity presents a roughened, worm-eaten, and hæmorrhagic appearance. This is only what might have been expected, the uterus having been

curetted two days previously. In the vicinity of the right cornu, however, where the curette has not disturbed the tissue, the mucous membrane presents a somewhat shaggy appearance. This shaggy material is made up of minute papillary-like folds. On microscopic examination, the cervical glands, where present, are normal. The uterine cavity almost everywhere is covered by canalized fibrin, containing many polymorphonuclear leucocytes in its meshes, and here and there a few carcinomatous glands. The underlying tissue shows marked polymorphonuclear leucocytic infiltration, and all the stroma cells are swollen. The blood-vessels are exceedingly abundant, and their endothelial lining is also swollen. Only in the vicinity of the right cornu, where the shaggy appearance was noted, are there any remains of the carcinomatous growth. These present the same appearances as those described in the examination of the scrapings. There has as yet been only slight invasion of the uterine muscle. The small subperitoneal nodule is a typical myoma. The diagnosis of adeno-carcinoma of the body of the uterus is confirmed.

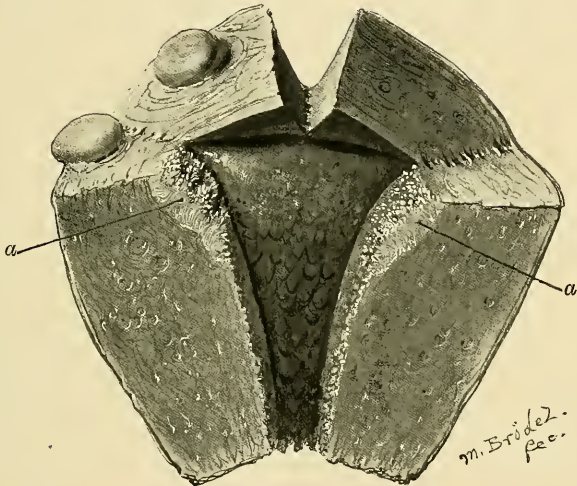


FIG. 184.—EARLY ADENO-CARCINOMA OF THE BODY OF THE UTERUS DIAGNOSED FROM SCRAPINGS SHOWN IN FIG. 183. (Natural size.)

Gyn.-Path. No. 100. The uterus is rather small, and its walls are of normal thickness. Situated in the fundus is a myoma, about 1 centimetre in diameter, and divided into two equal halves. The uterine cavity in its lower three fourths presents a ragged surface, due to the recent curettage; but at *a* and *a'* the mucosa, though considerably thickened and showing myriads of delicate finger-like outgrowths springing from its surface, is still intact. This is the only portion of the growth remaining. It contrasts sharply with the normal mucosa at a corresponding point on the posterior wall. It would be practically impossible to make a positive diagnosis in such a case without the aid of the microscope.

January 1, 1900. Dr. J. H. Whitehead, of Rocky Mount, N. C., informs me that there is no evidence of a return of the growth, and that the patient has been free from hæmorrhages. Her general condition is "first class; weight, one hundred and fifty pounds." Length of time since operation, a little over six years.

Gyn. No. 5,340

Suspension of the uterus, June, 1897. Adeno-carcinoma of the body of the uterus. Diagnosis from scrapings made in April, 1898. Patient refused operation at that time, but the uterus was removed in November, 1898 (Fig. 185). No signs of recurrence, thirteen months after operation.

S. C., aged thirty; white; married. Admitted June 19, 1897. Complaint: pain in the left lower abdomen, extending down into the leg. This pain was so severe that vomiting frequently accompanied it.

July 12, 1897. The left ovary was bound down to the posterior surface of the broad ligament by web-like adhesions. It was removed, and the uterus was suspended. The left tube and the right appendages were normal. The patient left the hospital on August 13th, feeling much improved.

She was readmitted on April 13, 1898, complaining of uterine hæmorrhages. It was then learned that she had been married thirteen years, and had had one child and one miscarriage. Her menses were regular until her pregnancy, about six years ago, but since that time they have been very irregular, coming on too frequently, and apparently following the slightest exertion. For the last three or four months there has been quite a profuse, yellowish, irritating, but not offensive discharge. So far as can be learned, the hæmorrhages first made their appearance two weeks after her first operation. The uterus was dilated on the day of her admission and the cavity curetted.

Histological examination of the scrapings revealed the presence of an adeno-carcinoma of the body. The patient refused operation, and left the hospital on April 20th.

Gyn.-Path. No. 2,291. The specimen consists of a considerable amount of scrapings.

Histological Examination.—Several of the pieces of tissue are composed of uterine mucosa presenting a fairly even surface. The superficial epithelium is intact, although in some places it is swollen, while between the epithelial cells are many polymorphonuclear leucocytes. The uterine glands are small, round on cross section, and present a normal appearance. The stroma of the mucosa is very dense, and shows marked small-round-cell and polymorphonuclear leucocytic infiltration. From such sections an acute endometritis is easily diagnosed. Other pieces of tissue present an entirely different picture. No glands are visible, and the stroma, which consists of spindle-shaped cells, is infiltrated by numerous irregular nests of epithelium. These epithelial cells are fairly uniform in size, have oval, evenly staining nuclei, and contain numerous nuclear figures. From such fields one would naturally diagnose squamous-cell carcinoma, but other areas present a widely different picture. The cell-nests are not solid, and on careful examination are found to consist of groups of small glands. In the older portions these are seen coalescing to form the solid nests. The growth is an adeno-carcinoma, which might very readily be mistaken for one of squamous-cell origin. From the sections it would be impossible to determine whether it had sprung from the body or cervix.

She was again admitted November 22, 1898.

Since leaving the hospital, in April, she has had profuse hæmorrhages. Her doctor curetted, and there has been no further loss of blood, but a constant burning sensation in the uterus. The menstrual periods have been regular, but have been accompanied by excessive pain. She has not lost any weight, and thinks she is a little stouter than when in the hospital in April.

November 23, 1898. Hysterectomy was performed.

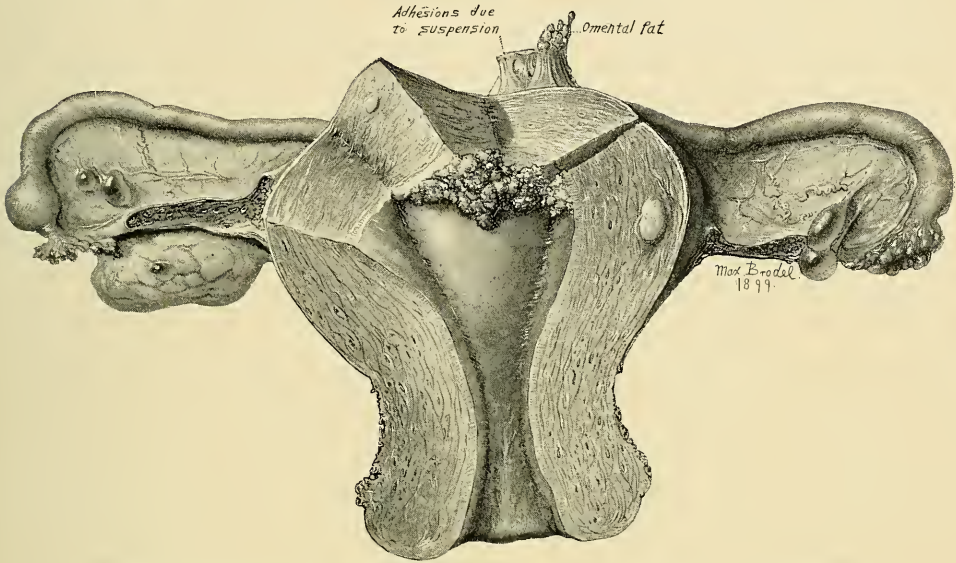


FIG. 185.—EARLY ADENO-CARCINOMA OF THE BODY OF THE UTERUS. ($\frac{2}{3}$ natural size.)

Gyn.-Path. Nos. 2,291 and 2,750. The uterus is of the normal size and shape. Attached to the fundus are broad adhesions due to the suspension performed about one and a half years before. Connected with the adhesions are small masses of omental fat. The uterine walls are of the usual thickness, and contain two small myomatous nodules. The mucosa of the cervix, and of the greater portion of the cavity of the uterus, is normal. Springing, however, from the fundus and posterior wall is a finely lobulated growth, which reaches nearly 1 centimetre in thickness, but does not appear to penetrate the uterine walls.

This case is of great clinical interest, as the uterus had been examined from above, during the operation for removal of an ovary, seventeen months previous to the hysterectomy. Again, we know positively from microscopic examination that the carcinoma had existed more than seven months before the uterus was removed—a fact which demonstrated the slowness of the growth.

Gyn.-Path. No. 2,750. The specimen consists of the uterus and its appendages.

The uterus is 10 centimetres in length and 6.5 centimetres in breadth; its posterior surface is covered by dense adhesions (Fig. 185). The cervix is 4 centimetres in diameter and 3 centimetres in length. The cervical portion presents a comparatively normal mucosa. The external os is 1 centimetre in width, and the mucosa between the external and internal os is normal. The uterine cavity is 4.5 centimetres in length and 3 centimetres in breadth at the fundus. In most portions of the cavity the endometrium averages 3 millimetres in thickness, is smooth and glistening, but springing from the fundus is an irregular mass about 3 centimetres in breadth and 1.5 centimetres in thickness. This consists of branching finger-like processes, which are pale and glistening. The growth apparently only involves the muscle for a distance of 2 to 3 millimetres.

The appendages on the right side seem to be normal.

The fimbriated extremity of the left tube is adherent. The left ovary is missing.

Histological Examination.—The squamous epithelium covering the vaginal portion of the cervix is unaltered. The cylindrical epithelium of the cervical portion is everywhere intact, and the glands are also normal. The uterine mucosa shows here and there some gland hypertrophy; it is, however, practically normal. The growth springing from the fundus consists to a great extent of finger-like processes, containing in their centres large capillaries, and being surrounded by many layers of epithelial cells having oval, uniformly staining nuclei. In these masses of epithelial cells a faint gland-like arrangement is occasionally perceptible, but such portions of the growth might very readily be mistaken for the finger-like processes of a squamous-cell growth. At other points, especially just in the vicinity of the muscle, the gland-like arrangement of the growth is fairly well marked.

The neoplasm is undoubtedly an adeno-carcinoma. The underlying muscle has been involved to only a slight extent. Along the advancing margin of the growth there is considerable small-round-cell infiltration, and along its free surface some coagulation necrosis can be noted.

The right tube, on section, presents the usual appearance. The ovary is unaltered. The left tube at the uterine cornu is normal. Sections through the outer portion also show no pathological changes.

This case demonstrates very clearly the slowness with which adeno-carcinoma of the body may develop, and the extent to which the growth may advance before there is any appreciable involvement of the underlying muscle.

January 1, 1900. Dr. T. S. West, of Keyser, W. Va., writes as follows: "Her condition is improving all the time, with the exception of an intense cystitis, from which she suffers a great deal. There have been no hæmorrhages; there is no evidence of a return of the growth." Length of time since operation, thirteen months.

Gyn.-Path No. 994

Adeno-carcinoma of the body of the uterus (Fig. 186); marked dilatation of the cervical glands; vaginal hysterectomy. No evidence of a recurrence, four years after operation.

S. A., aged forty-three; white. Admitted to Dr. Kelly's sanatorium November 29, 1895.

She has been married seven years, but has never been pregnant. Her menses were always regular until June, 1895. Some time last winter she noticed a free uterine discharge; this was accompanied by considerable pain in the lower part of the abdomen. Ever since that time the menstrual flow has been very profuse. Since July she has had frequent uterine hæmorrhages. In September, 1895, the uterus was curetted and the hæmorrhages ceased for two weeks.

On vaginal examination no change in the cervix can be made out; a small nodule about 1 centimetre in diameter can, however, be detected on the anterior

surface of the uterus. The uterus was dilated and curetted, and a few small pieces of tissue were removed. These appeared to be normal. Examination of the scrapings, however, by Dr. Russell showed them to consist of carcinomatous tissue.

Gyn.-Path. No. 994. The specimen consists of a small amount of uterine scrapings which on histological examination are seen to be made up almost entirely of glands. The majority of these are convoluted, but in some places are small and round. They are lined by one layer of high cylindrical epithelium, the nuclei of which are oval and somewhat deeply staining. In many of the cells nuclear figures are visible. The epithelium of some of the glands has pro-

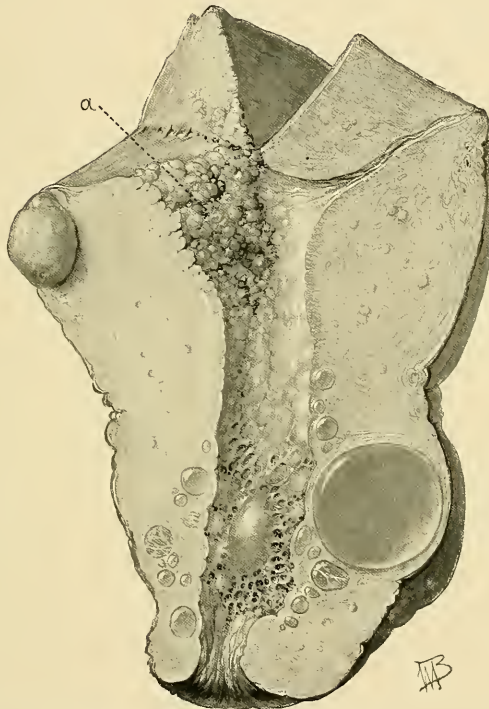


FIG. 186.—EARLY ADENO-CARCINOMA OF THE BODY OF THE UTERUS; DILATED CERVICAL GLANDS.
(Natural size.)

Gyn.-Path. No. 994. The lower part of the cervix is normal, but occupying the cervical canal are several cysts, one of which reaches nearly 1 centimetre in length. Numerous cysts are also scattered throughout the cervical stroma, one of these being at least 1.5 centimetres in diameter. All of them are in reality dilated cervical glands. The uterine cavity has been curetted, which gives the ragged appearance seen everywhere except in the neighbourhood of the fundus, where, over an area indicated by α , the growth has not been disturbed by the curette. Here the mucosa is slightly thickened and gathered up into little dome-like elevations, but no delicate finger-like outgrowths are to be seen. The uterine walls are slightly thickened. Just beneath the peritoneal covering is a small myoma, which stands out prominently, since the surrounding muscle has retracted. The carcinomatous growth is in a very early stage. (After H. A. KELLY.)

liferated, forming teat-like ingrowths; not infrequently it has partially or completely obliterated the gland cavity. The stroma is very scanty, and is composed of cells having elongate-oval nuclei. It shows some small-round-cell

infiltration. The growth is an adeno-carcinoma. It bears some resemblance to the type found originating in the cervix, but on the whole is more like that occurring in the body of the uterus.

Diagnosis.—Adeno-carcinoma of the uterus probably originating in the body.

Operation, December 12th. Vaginal hysterectomy was performed in the usual manner, and a drain laid in the pelvis. The pack was removed on the second day; the patient was in good condition. She left the hospital January 20, 1896.

Dr. Russell has kindly furnished us with the following description: The uterus measures $8.4 \times 5.5 \times 3.5$ centimetres. On its anterior surface is a subperitoneal myoma, 1 centimetre in diameter (Fig. 186). The cervical canal is intact, but its mucous membrane shows numerous cystic glands. The uterine cavity has been curetted, and the greater part of the mucosa has been removed. At either cornu, however, are little patches of a papillary-like growth. These, on histological examination, present appearances similar to those found in the scrapings. The growth has as yet involved the muscle to a very limited extent, and has been entirely removed.

Diagnosis.—Adeno-carcinoma of the body of the uterus.

December 1, 1899. Dr. Kelly has just heard from this patient. She says she is perfectly well. Length of time since operation, four years.

Mrs. R., a Patient of Dr. F. R. Eccles, of London, Canada

Very suspicious-looking scrapings. Hysterectomy advised. Subsequent removal of the uterus proved the existence of early adeno-carcinoma of the body. Histological picture showing the earliest changes in the gland epithelium (Fig. 187). Proliferation of the gland epithelium with the formation of new glands (Fig. 188). No recurrence. Patient well, three years and eight months after operation.

Mrs. R., aged sixty-three; white; was first seen by Dr. Eccles in March, 1895. He dilated the uterus and removed a growth about 3 centimetres in diameter. Following the operation there was severe hæmorrhage, and the patient complained of labour-like pains. From the time of the operation until April of the same year there was no hæmorrhage. On April 15th Dr. Eccles again curetted the uterus, and sent me the scrapings for examination.

On May 11th hysterectomy was performed, and an uninterrupted recovery followed.

Gyn.-Path. No. 1,154. The specimen consists of a very small amount of uterine scrapings. On microscopic examination, the surface epithelium is intact. In some portions the glands, apart from being dilated, are normal; in other places the epithelium has proliferated and partially fills their lumina. The newly formed epithelial cells are larger than those lining the wall, and between them are a moderate number of polymorphonuclear leucocytes. On examining further sections, numerous glands are found to be markedly convoluted, while projecting from the surface of the mucosa are branching papillary-like masses. These papillary outgrowths have exceedingly delicate stems of connective tissue,

and are covered by cylindrical epithelium, which is swollen and in many places two or three layers in thickness. The stroma of the mucosa shows some small-round-cell infiltration. In this case an absolute diagnosis of adeno-carcinoma was not made, but as the case was very suspicious I advised hysterectomy.

Gyn.-Path. No. 1,192. The uterus was slightly larger than usual, and showed some tendency toward bifurcation. We had permission to take sections from various portions.

Histological Examination.—The epithelium covering the vaginal portion of the cervix is intact. One or two of the cervical glands present a more convoluted appearance than usual, but are otherwise normal. Sections

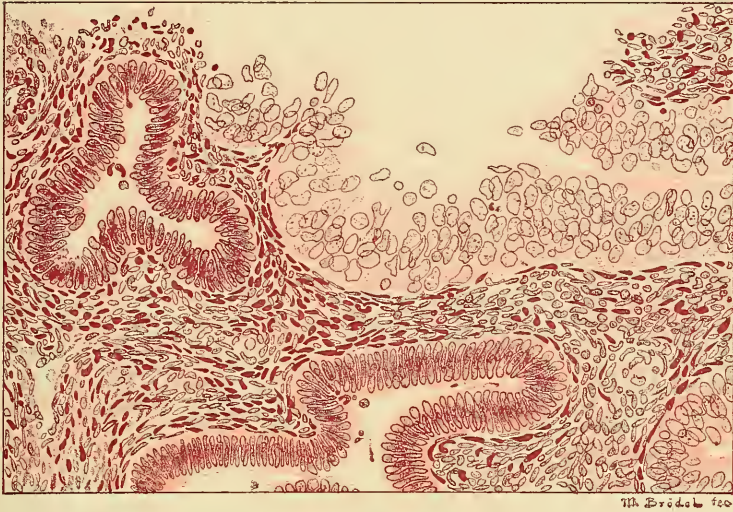
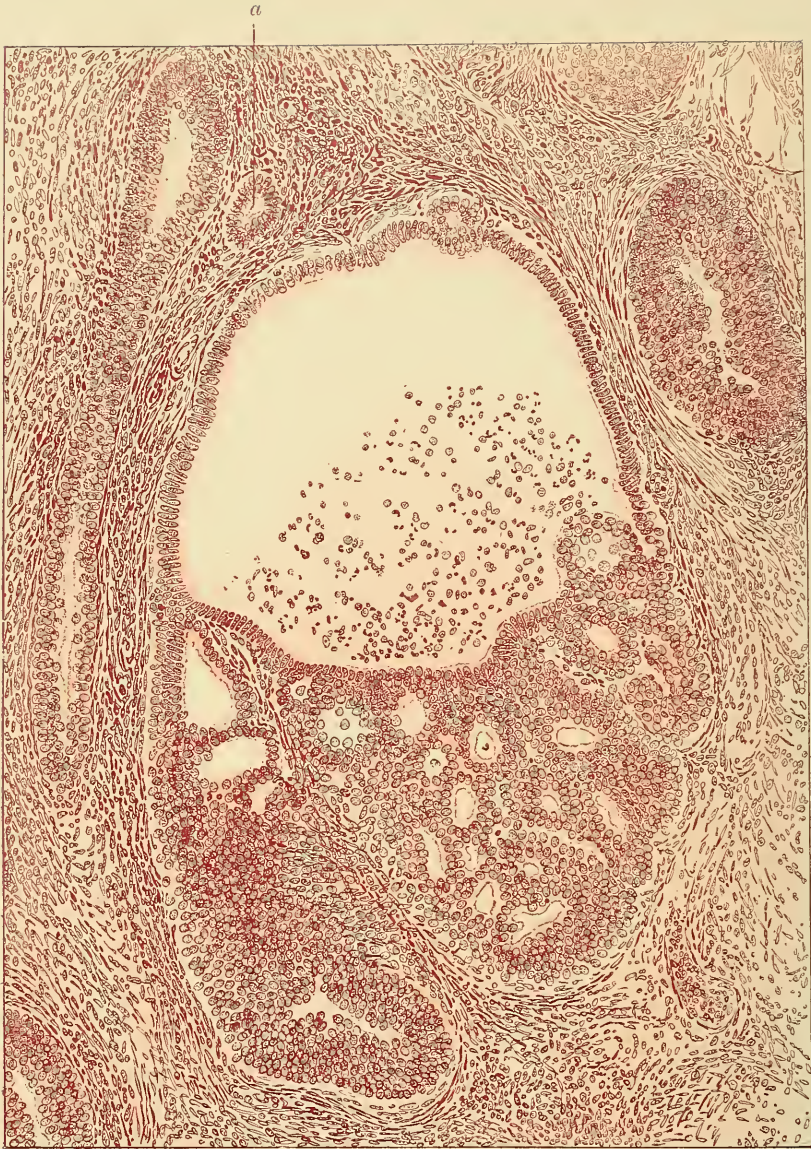

FIG. 187.—EARLIEST CHANGE IN THE GLAND EPITHELIUM IN ADENO-CARCINOMA OF THE BODY.
(200 diameters.)

Gyn.-Path. No. 1,192. To the left and in the lower part of the section are two slightly convoluted and normal uterine glands. As the section is rather thick, they appear to be lined by two layers of epithelium. In the upper part of the field is a portion of a gland. Here one is immediately impressed with the faint staining. The cells are five or six layers in thickness and contain swollen and irregular nuclei, but there is no increase in chromatin. In the lower right-hand corner is the edge of a similar gland. The stroma between the glands is normal. This is probably the earliest change that can be recognised in carcinoma of the body. From such a field the pathologist, while not justified in making a diagnosis of malignancy, instantly receives a clew, starting with which he will go on to find the typical picture of an adeno-carcinoma not far distant. The counterpart of this section is seen in Fig. 214.

from some portions of the uterus show that the glands of the mucosa, apart from being here and there dilated, are normal. In other parts it is noticed that a few of the glands stain more faintly than others; on examination, it is found that their epithelial lining has become thicker, and now consists of two or three layers (Fig. 187). In others of these faintly staining glands the epithelium tends to form little knob-like ingrowths. At only one point in this slide is there a still more suspicious picture; a gland is dilated to fifteen or twenty times its normal size; the epithelium lining the one half is normal, but over the other half is lighter in colour, and has proliferated to such an extent that this



Max Brödel.

FIG. 188.—PROLIFERATION OF THE GLAND EPITHELIUM WITH THE FORMATION OF NEW GLANDS IN ADENO-CARCINOMA OF THE BODY OF THE UTERUS. (140 diameters.)

Gyn.-Path. No. 1,192. Occupying the greater portion of the drawing is a uterine gland fully fifteen or twenty times its natural size. The epithelium in the upper half is perfectly normal; the corresponding part of the cavity, however, contains desquamated epithelium and polymorphonuclear leucocytes. The epithelium in the lower half has greatly proliferated, completely filling this portion of the gland cavity, and growing in such a manner that many new glands are formed. At a few points it has produced solid masses. In two places only have the stroma cells grown in between the epithelial elements, the glands, as a rule, lying one against the other. The remaining glands are lined by many layers of cells. The stroma of the growth is normal. In this case the peculiar proliferation of the epithelium, as seen in the large gland, is practically sufficient ground for the diagnosis of adeno-carcinoma, although the nuclei are everywhere uniform. Such a picture is never found in the uterus, except in the case of a malignant growth. Fig. 153 (p. 293) shows a somewhat analogous change in a cervical gland in adeno-carcinoma of the cervix.

half of the gland consists of a large mass of epithelium arranged in such a manner as to form definite glands (Fig. 188). These glands lie one against the other, there being no intervening stroma, and on their epithelium the cilia are visible. A section near the fundus shows that at one point the mucosa dips into the muscle, forming a regular bay. Here every stage of transition from the normal to the abnormal gland can be seen. First, there is the small normal gland; next, one in which the epithelium is two or three layers in thickness on one side or on both; then a gland presenting the markedly convoluted appearance, and having finger-like or knob-like projections springing into the cavity; and finally, the enlarged gland with its proliferated epithelium so arranged as to form smaller glands. Between these carcinomatous glands there is an exceedingly small amount of stroma, and in many places none. The growth is a very early one, and has doubtless been entirely removed.

Diagnosis.—Adeno-carcinoma of the body of the uterus.

December 25, 1899. Dr. Eccles tells me that the patient has shown no signs of a return of the growth. Length of time since operation, three years and eight months.

Gyn. No. 2,832

Adeno-carcinoma of the body of the uterus (Figs. 190 and 191) diagnosed from scrapings (Fig. 189). Pelvic peritonitis; abdominal hysterectomy; uterus amputated at a point midway between the external and internal os. No recurrence; patient well, five years and seven months after operation.

K. A., aged fifty-seven; white. Admitted June 11, 1894. Complaint: backache; general weakness; loss of flesh; a blood-stained vaginal discharge.

She has been married thirty-two years, but has had no children and no miscarriages. The menses ceased twelve years ago. Her family history is unimportant.

About one year ago the patient began to suffer with backache, was tired, languid, and had a profuse watery discharge which was streaked with blood. This discharge continued of the same character until one month ago, when it became thick, yellowish, and was more blood-stained than usual. The patient, on admission, is well nourished, the mucous membranes are of a normal colour, the appetite is poor, the bowels are constipated. She has slight œdema of the legs.

Gyn.-Path. No. 324. The specimen consists of uterine scrapings for diagnosis.

Histological Examination.—The scrapings are made up almost entirely of gland-like depressions, which have secondary gland-like cavities running off from them (Fig. 189). All of these cavities are lined by high cylindrical epithelium, which is usually only one layer thick. In several places, however, it has proliferated, reaching four or five layers in thickness. The stroma, which is

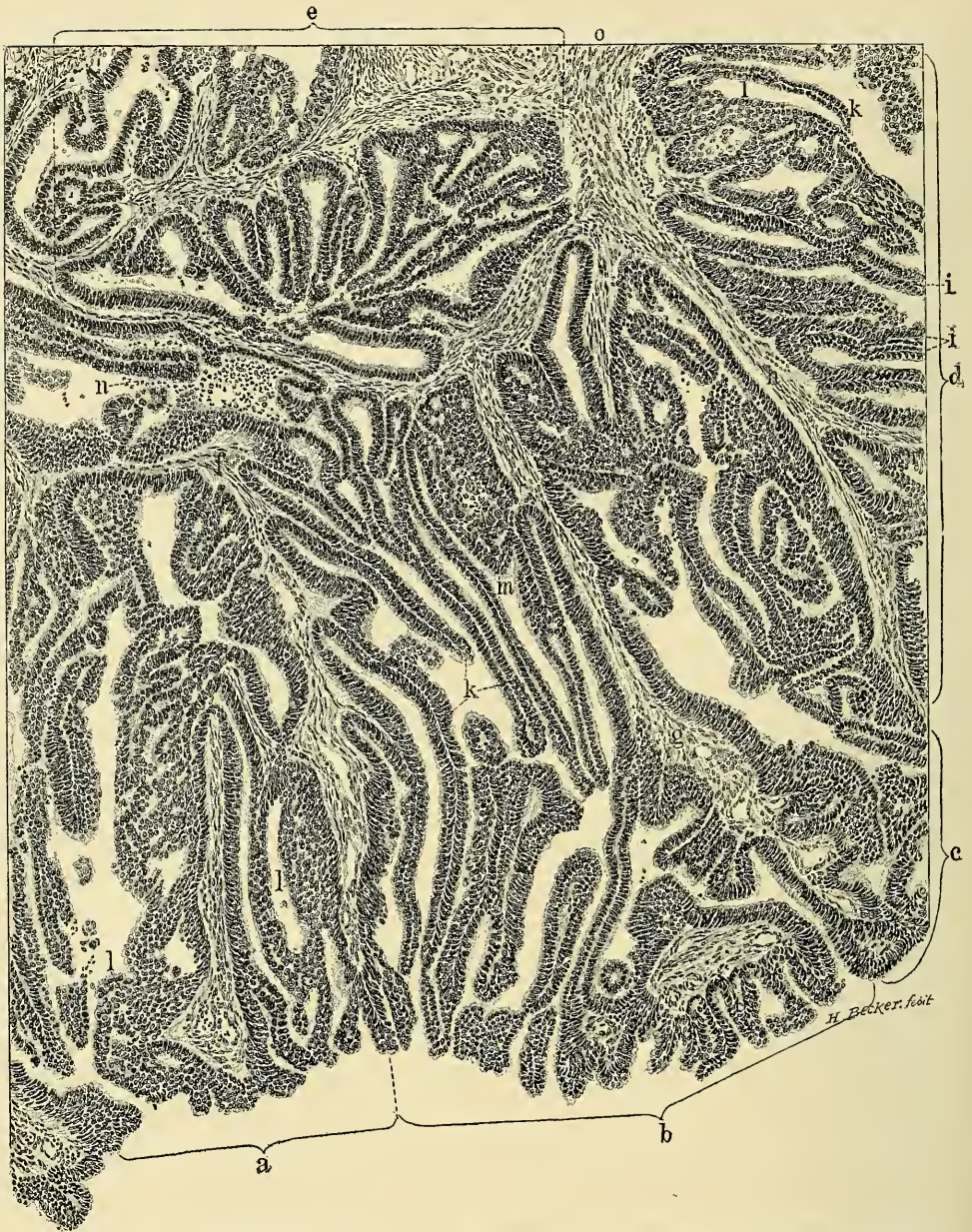


FIG. 189.—ADENO-CARCINOMA OF THE BODY OF THE UTERUS; SCRAPINGS FROM WHICH THE CONDITION REPRESENTED IN FIG. 190 WAS DIAGNOSED. (130 DIAMETERS.)

Gyn.-Path. No. 324. *o* may be likened to a main stem, from which arise numerous secondary stems, which in turn give off delicate terminals consisting entirely of epithelial cells. In order that the tree-like arrangement may be appreciated, the drawing should be turned upside down. The glands may be arbitrarily divided into groups, *a*, *b*, *c*, *d*, and *e*, by the stems of stroma, *f*, *g*, and *h*. The stems are covered by several layers of cylindrical epithelium, while projecting into the gland cavities are long, slender ingrowths of epithelium devoid of stroma, as seen in *i*. Very delicate ingrowths, consisting merely of two layers of epithelium, are seen at *k* and *k*. At points indicated by *l* the epithelium is several layers in thickness. At *m* there is also considerable epithelial thickening, and polymorphonuclear leucocytes have wandered out between the epithelial cells. At *n* numerous polymorphonuclear leucocytes are seen in the gland cavities. The epithelial cells throughout are uniform in size. From the tree-like arrangement and the peculiar gland-like grouping adeno-carcinoma may be readily diagnosed.

very scanty, is composed of cells having spindle-shaped or oval nuclei. Numerous polymorphonuclear leucocytes are scattered throughout the stroma. The growth seems to be of recent origin, as there is no evidence of a retrograde process. It is an adeno-carcinoma. Hysterectomy is advised.

Diagnosis.—Adeno-carcinoma of the body of the uterus.

Operation, June 20, 1894. Abdominal hysterectomy. The uterus was amputated at a point midway between the internal and external os. The patient made an uninterrupted recovery, and was discharged July 18th.

Gyn-Path. No. 345. The specimen consists of a portion of the uterus to which both tubes and ovaries are attached. The portion of the uterus present measures $6 \times 4 \times 3$ centimetres. Both anteriorly and posteriorly it is covered by normal peritoneum. The uterine walls average 1.2 centimetres in thickness. Situated in the posterior wall just above the cervix is a myomatous nodule, 1 centimetre in diameter (Fig. 190). The uterine cavity is 3 centimetres in length; its

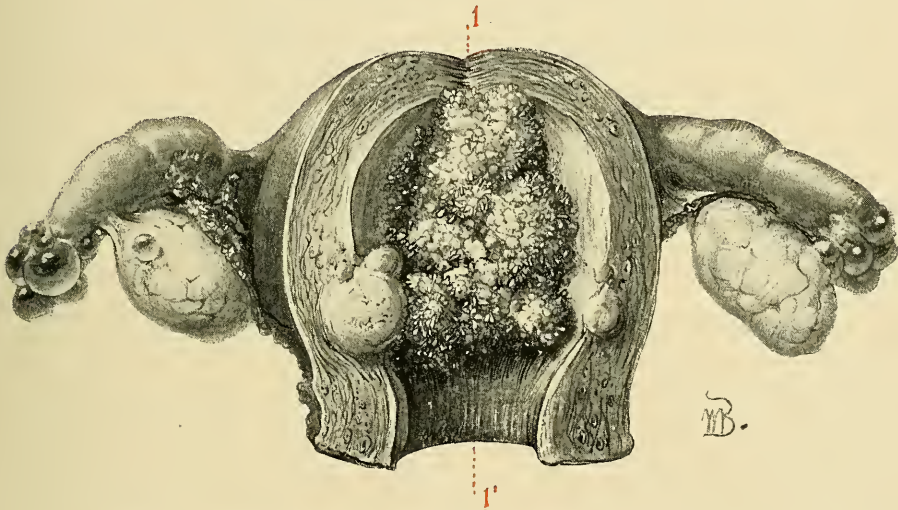


FIG. 190.—EARLY ADENO-CARCINOMA OF THE BODY OF THE UTERUS DIAGNOSED FROM SCRAPINGS REPRESENTED IN FIG. 189. (Natural size.)

Gyn-Path. No. 345. The uterus has been cut open from behind. It is smaller than normal. Situated in the posterior wall near the internal os is a small submucous myoma. Springing from the anterior wall, and occupying almost the entire uterine cavity, is a growth composed of myriads of little dome-like elevations. The tubes are slightly enlarged, and the occluded fimbriated extremities are obscured by a few small subperitoneal cysts. The ovaries are normal. (After H. A. KELLY.)

mucosa averages 1 millimetre in thickness. Springing from the anterior surface of the cavity is a papillary-like mass, 3.5 centimetres in length, 2.5 in breadth, and 1.5 in thickness. On close examination it is found to consist of two or three main trunks, from which come off secondary branches (Fig. 191). These again branch, and end in delicate knob-like terminals. The growth is waxy-like, contrasting sharply with the surrounding tissue. The mucosa at the fundus, laterally and also posteriorly, is pinkish in colour, but in several places is slightly hæmorrhagic. About the middle of the posterior wall is a small rough surface

measuring $1 \times .5$ centimetres. This is uneven, and apparently represents an early stage of the growth springing from the anterior wall. The upper half of the cervix is present; its mucosa is pinkish in colour, smooth, and glistening. Both tubes are covered by adhesions, and have occluded fimbriated extremities.

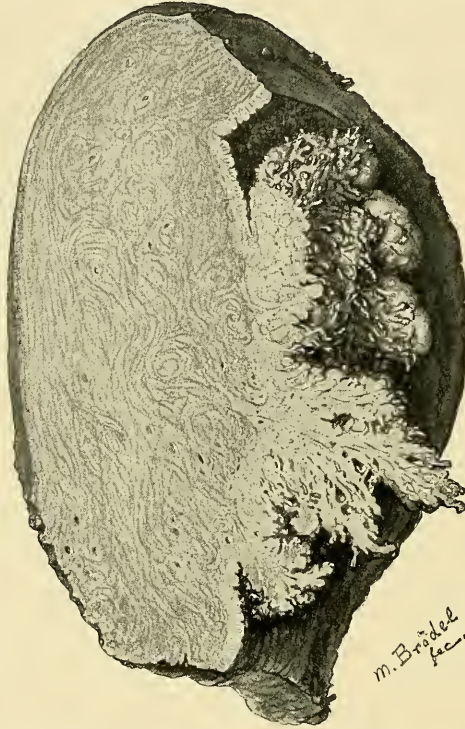


FIG. 191.—EARLY ADENO-CARCINOMA OF THE BODY OF THE UTERUS. (2 diameters.)

Gyn.-Path. No. 345. This is a longitudinal section through Fig. 190 at point *I*, and is twice the natural size. Springing from the wall is a new growth, divided into three or four main stems, and presenting a shaggy appearance. Projecting from the surface of these tufts are delicate finger-like outgrowths. The carcinoma has barely commenced to invade the underlying muscle. Fig. 190 was drawn from the fresh specimen; hence the delicate outgrowths were stuck together by mucus and blood, and, accordingly, are not clearly defined.

Histological Examination.—The cervical glands present their usual appearance; one or two, however, are slightly dilated. The uterine mucosa at the internal os is unaltered; the glands are normal in size, their epithelium is intact, and their cavities are empty. On passing upward, the surface epithelium is seen to be intact, and in a few places to have proliferated, being four or five layers thick. The epithelial cells, where the thickening occurs, are swollen, and bear a striking resemblance to squamous epithelium. Above this point the one layer of cylindrical epithelium is again found. The mass springing from the anterior wall is composed of myriads of gland-like cavities lined by high cylindrical epithelium. In many places large areas are occupied by masses of epithelial cells, many of which resemble the squamous variety. The stroma between the gland-like spaces, and also where

there are large masses of cells, is exceedingly scanty, in some places being actually wanting. This glandular growth extends a short distance into the muscle, where it presents exactly the same appearance. Portions of the protoplasm are necrotic, but fail to show any polymorphonuclear infiltration. The mucosa above the growth is very atrophic, but has an intact surface epithelium which, as below, also shows some proliferation. So striking is the resemblance between these proliferated cells and squamous epithelium, that were it not for their situation, one would not be able to make any differentiation. The uterine muscle, just beneath the growth, is markedly infiltrated with small round cells; the veins in the vicinity are considerably dilated. The growth represents a very early stage of adeno-carcinoma, and has undoubtedly been entirely removed.

Diagnosis.—Adeno-carcinoma of the body of the uterus.

February 6, 1900. Dr. A. S. Mason, of Hagerstown, Md., writes me to-day: "Mrs. A. called to see me, and I made a careful examination. I find the vaginal incision is in a perfectly healthy condition; the resultant cicatrix soft and smooth. Mrs. A.'s condition to-day is one of absolute health." Length of time since operation, five years and seven months.

Gyn. No. 3,258

Adeno-carcinoma of the body of the uterus (Fig. 193). Diagnosis from scrapings (Fig. 192). General pelvic peritonitis; double hydrosalpinx; abdominal operation with amputation of the uterus at the cervix; mental disturbance for several weeks following operation. Histological pictures showing various steps in the growth (Figs. 194, 195, 196, 197, 198, and Plate VIII). Proliferation of the surface epithelium, resembling squamous epithelium (Fig. 199); proliferated gland epithelium, closely simulating squamous epithelium (Fig. 200). Local recurrence. Death one year and nine months after operation.

H. A., aged fifty-two, white. Admitted January 3, 1895. Complaint: profuse vaginal discharge, pain in the lower abdomen.

She has been married thirty-three years, has had two children and five miscarriages. Her menses ceased two years ago. Her family history is unimportant.

For nearly two years she has had a somewhat offensive vaginal discharge, and five months ago there was some uterine hæmorrhage. This at first seemed to be a return of the menstrual flow, and was accompanied by considerable pain. The hæmorrhages have increased in frequency, and are at present almost constant; the blood is at times bright red in colour, but is often dark and clotted. On admission the patient's general condition is fair, the mucous membranes are of a good colour, the bowels are constipated, defecation is painful. At times she has a sharp, shooting pain in the lower part of the abdomen; this extends to the back, and radiates to the lower extremities. The vaginal outlet is relaxed; the cervix is normal; the uterus is the size of that of a ten weeks' pregnancy; it is normal in shape and nowhere gives any sensation of unevenness. On January 5th the uterine cavity was curetted,

and a large quantity of soft, friable, whitish tissue was removed. There was free hæmorrhage, and the operation was stopped, as there was danger of perforating the uterus. The vagina was packed with iodoform gauze.

Gyn.-Path. No. 556. The specimen consists of large quantities of uterine scrapings, the pieces varying in size from that of a pin's head to 1 or 2 centimetres in diameter. Some are soft, others are firm.

Histological Examination.—The tissue consists almost entirely of glands, which are small and round on cross section, or are large and present a

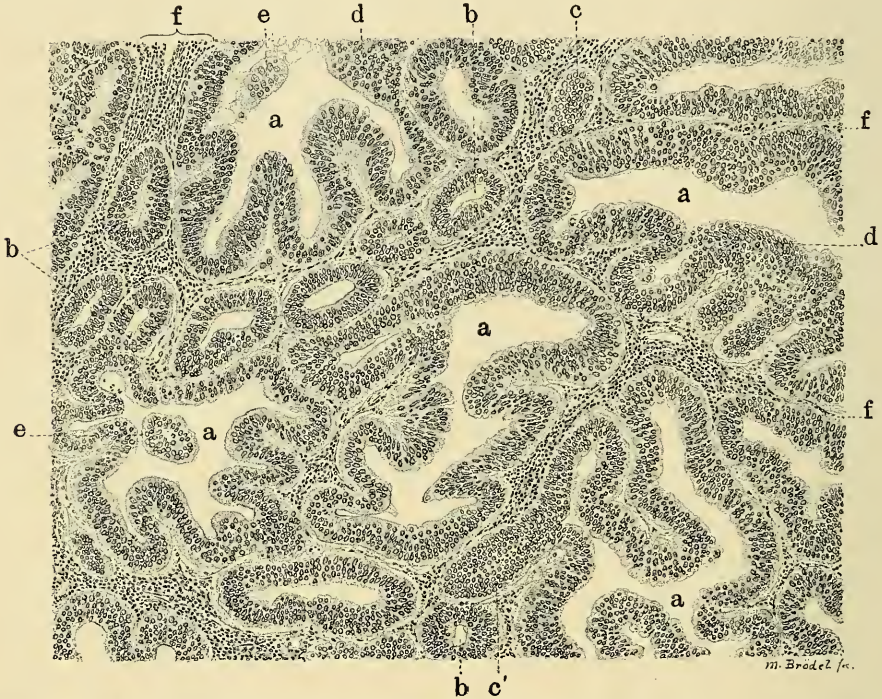

FIG. 192.—ADENO-CARCINOMA OF THE BODY OF THE UTERUS; SCRAPINGS FROM WHICH THE CONDITION REPRESENTED IN FIG. 193 WAS DIAGNOSED. (100 DIAMETERS.)

Gyn.-Path. No. 556. Here it is important to study carefully the gland arrangement. *a, a, a* indicate the markedly convoluted glands. *b, b, b* are cross sections of the terminal branches of the glands. *c* is a cross section of a terminal branch at its base. Its longitudinal counterpart is seen in *c'*, where the terminal branch has been cut along the margin. The gland epithelium in this section is everywhere several layers in thickness, and at *d, d* consists of numerous layers. The nuclei are, however, everywhere uniform in size. *e* shows a cross section of the tip of one of the folds, which appears as a homogeneous mass of protoplasm with several nuclei scattered through it. *f* is the stroma, scanty in amount and showing marked small-round-cell infiltration. The increase in their number and the convoluted condition of the glands, the many layers of epithelium, and the scanty amount of stroma, taken together are sufficient to warrant a diagnosis of adeno-carcinoma. For a picture of the uterus, see Fig. 193. For other histological changes in this uterus, see Figs. 194, 195, 196, Plate VIII., Figs. 197, 198, 199, and 200.

Somewhat similar pictures occurring in adeno-carcinoma are to be found in Fig. 233 (p. 445), Fig. 214 (p. 404), Fig. 215 (p. 406), Fig. 242 (p. 462). In order to appreciate the differences between this growth and gland hypertrophy, compare Fig. 254 (p. 489), Fig. 255 (p. 490), Fig. 257 (p. 493), Fig. 256 (p. 491), Fig. 258 (p. 494). For gland hypertrophy occurring in pregnancy, see Fig. 263 (p. 502).

convoluted appearance (Fig. 192). The smaller ones are lined by one layer of high, cylindrical, ciliated epithelium, the nuclei of which are oval and vesicular.

The epithelium lining the larger glands is similar in character, but is frequently three or four layers in thickness, and has in some parts proliferated to such an extent that the gland cavity is completely filled. Numerous karyokinetic figures can be seen in the gland epithelium. The stroma between the glands is exceedingly

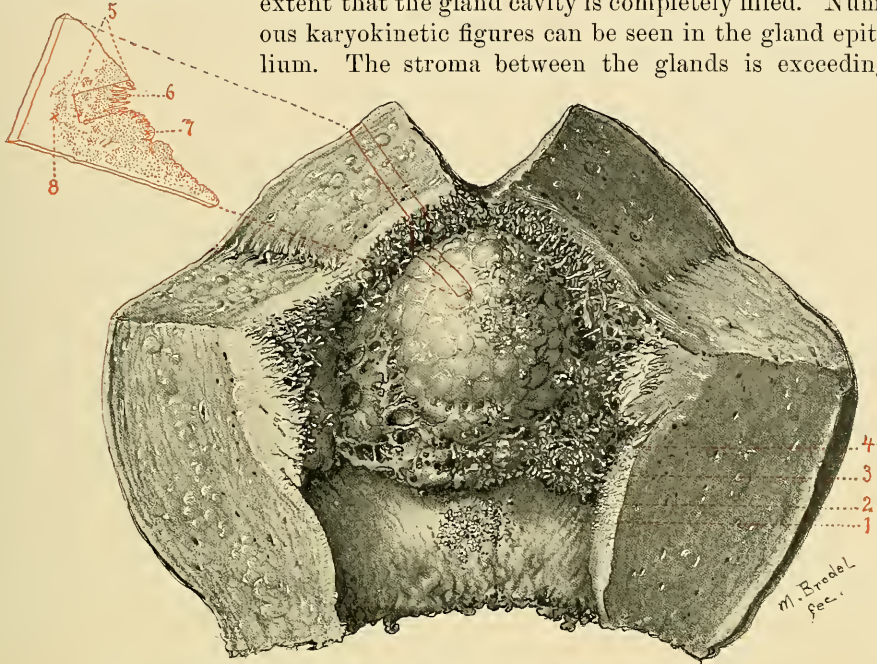


FIG. 193.—ADENO-CARCINOMA OF THE BODY OF THE UTERUS. (Natural size.)

Gyn.-Path. No. 559. The specimen consists of the body of the uterus, and has been opened anteriorly. The mucosa in the vicinity of the internal os is normal, but a short distance above delicate isolated prickles are seen springing from the surface. The entire upper portion of the cavity is filled by a new growth, consisting in most places of long, slender fingers. In the posterior wall these have coalesced to form a conglomerate dome-shaped mass. The growth, as seen from the projected sketch, has invaded the posterior uterine wall to a considerable depth. Note the sharp line of demarcation between the normal mucosa and the new growth.

From point 1, Fig. 194 is taken.

From point 2, Fig. 195 is taken.

From point 3, Fig. 196 is taken.

From point 4, Fig. 197 is taken.

From point 5, Plate VIII is taken.

From point 6, Fig. 198 is taken.

From point 7, Fig. 199 is taken.

From point 8, Fig. 200 is taken.

This specimen, both macroscopically and microscopically, is a most beautiful example of the various stages in the development of adeno-carcinoma of the body of the uterus. With our present knowledge we would not for a moment think of amputating at the cervix, but would remove the uterus in its entirety.

scanty, there being little or no tissue between one gland and its fellow. It has a poor blood supply. The picture is a typical one of adeno-carcinoma of the body of the uterus. Hysterectomy is advised.

Diagnosis.—Adeno-carcinoma of the body of the uterus.

Operation, January 9th. Abdominal hysterectomy. The operation proved to be very difficult on account of the thick abdominal walls and of the enormous amount of omental fat. The uterus was freed from adhesions, and the vessels were controlled; the organ was then amputated at the cervix, and the abdomen closed. For several weeks following the operation the patient was mentally unbalanced; she would frequently wake up screaming or singing songs, and was also subject to hallucina-

tions. A few days after the operation the abdominal incision broke down to some extent, and there was a moderate amount of suppuration; this, however, had ceased before the patient left the hospital on February 27th.

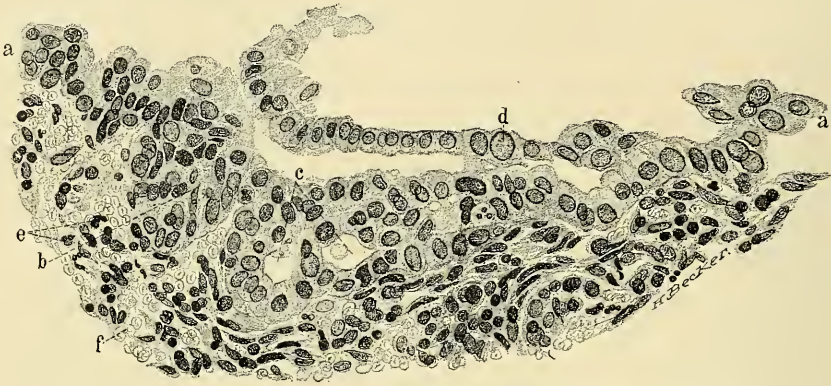

FIG. 194.—PROLIFERATION OF THE SURFACE EPITHELIUM ALONG THE EDGE OF AN ADENO-CARCINOMA OF THE BODY OF THE UTERUS. (380 diameters.)

Gyn.-Path. No. 559. The section is taken from Fig. 193 at point 1. At *a, a'* the surface epithelium is two or three layers in thickness. At *b* it forms a solid wedge, consisting of at least eight layers of cells. Here the nuclei already vary considerably in size, and several stain deeply. At *c* the cells have proliferated in such a way that new glands are formed. *d* is a nucleus of considerable size. The underlying stroma shows polymorphonuclear leucocytic infiltration, as seen at *e*. A moderate amount of hæmorrhage is indicated by *f*. The surface epithelium, immediately above and below the point at which this section was taken, was only one layer in thickness.

Gyn.-Path. No. 559. The specimen consists of a portion of the uterus and of both tubes and ovaries intact. The portion of the uterus present is 5 centimetres long, 6 centimetres broad, and 4 centimetres in its antero-posterior diameter. The anterior surface is smooth and glistening, but the posterior aspect is covered by numerous adhesions. Springing from the left cornu, just posterior to the tube, is a myomatous nodule, 1.3 centimetres in diameter. The uterine walls average 2.5 centimetres in thickness. Little, if any, of the cervix is present.

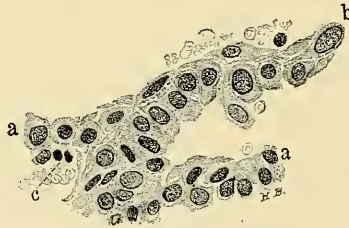

FIG. 195.—EARLY CHANGES IN THE SURFACE EPITHELIUM ALONG THE MARGIN OF AN ADENO-CARCINOMA OF THE BODY OF THE UTERUS. (380 diameters.)

Gyn.-Path. No. 559. This picture is taken from Fig. 193 at point 2. The surface epithelium is one layer in thickness at *a, a'*, but springing from the surface between these points is the delicate outgrowth *b*. This consists entirely of epithelial cells, which have nuclei fairly uniform in size. At the tip, however, is seen a considerably enlarged nucleus. *c* indicates a small round cell and a polymorphonuclear leucocyte in the underlying stroma. It is interesting to note that there is no stroma in this outgrowth.

The uterine mucosa over the lower part of the anterior wall, and also over a portion of the posterior wall, at first

sight appears normal, but on close examination is found to be covered by minute prickles, which are just visible to the naked eye (Fig. 193).

Occupying the upper half of the uterine cavity anteriorly and also posteriorly, is a new growth, which shows distinct finger-like masses, consisting of delicate threads of tissue which project everywhere from the walls into the uterine cavity. It is possible to trace some of these for a distance of 5 millimetres or more as single threads, coming from a common base in the underlying tissue. The junction between the growth and the mucosa, in the lower part of the cavity, is very sharply defined, there being an elevated margin of from 2 to 5 millimetres. In the upper and central portion of the posterior walls the growth is more advanced

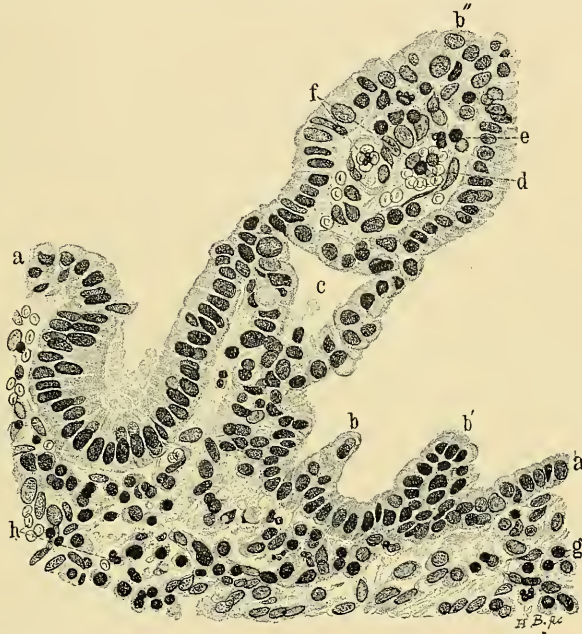


FIG. 196.—CHANGES IN THE MUCOSA ALONG THE MARGIN OF AN ADENO-CARCINOMA OF THE BODY OF THE UTERUS. (380 diameters.)

Gyn.-Path. No. 559. The section is from Fig. 193 at point 3. At *a*, *a'* we have normal surface epithelium, but at *b*, *b'*, the cells are already gathered up into little projections. *b''* is a distinct outgrowth covered by one layer of epithelium, and so formed that it produces the gland-like space *c*. Some of the epithelial cells contain large oval nuclei. *d* is a swollen endothelial cell of a blood capillary. The stroma of the outgrowth is similar to that of the mucosa proper, and contains small round cells, as shown at *e*. *f* indicates dilated blood capillaries. The stroma of the endometrium contains numerous small round cells, as seen at *g*; also polymorphonuclear leucocytes, indicated by *h*.

and appears as a globular, but slightly lobulated mass, measuring 2.5×2 centimetres, and giving rise on all sides to the little finger-like folds. On section it is seen to have reached nearly 2.5 centimetres in thickness, and in some places the uterine muscle is penetrated to within 8 millimetres of the peritoneal surface. The appendages are very small and are covered by numerous adhesions.

Histological Examination.—The uterine mucosa in the vicinity of the internal os presents little change; its surface epithelium is intact, but is

somewhat swollen and shows some tendency to proliferate (Fig. 194). On passing a short distance farther upward, the surface is found to be gathered up into small folds, which at first are seen as little finger-like prolongations of the surface epithelium (Fig. 195). Soon, however, they contain a stem of stroma continuous with that of the mucosa (Fig. 196). A little farther up the small finger-like projections send off secondary branches (Fig. 197). The uterine glands in this region are not very numerous, and present nothing unusual, apart from the fact that a few are dilated, have a lining of cuboidal epithelium, and contain some polymorphonuclear leucocytes and the shells of old cells. The stroma of the mucosa has

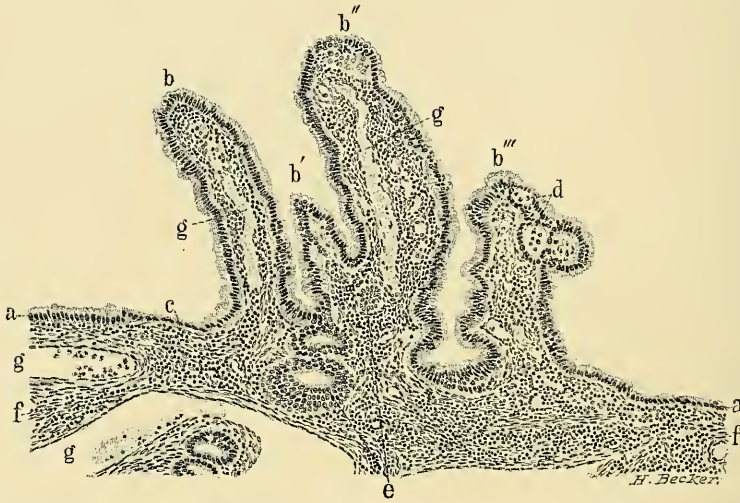


FIG. 197.—OUTGROWTHS FROM THE SURFACE OF THE MUCOSA ALONG THE MARGIN OF AN ADENO-CARCINOMA OF THE BODY OF THE UTERUS. (90 diameters.)

Gyn.-Path. No. 559. The section is taken from Fig. 193 at point 4. At *a, a*, the surface epithelium is intact and normal, but at *e* it is considerably flattened. Springing from the surface are the finger-like outgrowths *b*, *b'*, and *b''*, all of them consisting of stroma similar to, and continuous with, that of the endometrium. *d* are new glands lined by only one layer of epithelium, and containing polymorphonuclear leucocytes. *e* is the epithelium cut obliquely, and hence appears to be several layers in thickness. *f* is the stroma of the mucosa. It contains many small round cells, which are also abundant in the stroma of the outgrowth. *g* are blood-vessels. While outgrowths of this character are not in themselves in the least suggestive of a malignant growth, they are rarely, if ever, found in the endometrium, except along the edge of an adeno-carcinoma.

a very rich blood supply, as has also the muscle immediately beneath it. On passing still farther upward, the mucosa becomes exceedingly thin and ends almost abruptly, being replaced by masses of epithelial cells. These cells are closely packed together, have large and small, oval, vesicular nuclei, and bear a remarkable resemblance to masses of squamous epithelium (Fig. 199). Immediately beneath these masses of cells are rows of tubular glands lined by one or two layers of cylindrical epithelium, and having cavities partially filled with polymorphonuclear leucocytes and blood. The stroma at this point is infiltrated by alveoli, which

PLATE VIII.—EARLY ADENO-CARCINOMA OF THE BODY OF THE UTERUS.

Gyn.-Path. No. 550. The section is taken from Fig. 193 at point A. The upper surface of the
fore, corresponds to the uterine cavity. Projecting from the surface are many delicate strands,
or slightly branching, finger-like outgrowths, as indicated by a. Covering this is one layer of
epithelium, as can be well seen in Fig. 192, p. 381, which shows one of the fingers under the high
power. The epithelium covering the surface of the fingers is directly continuous with the lining
the glands, which are exceptionally long and slender. Thus it will be seen that the mucous
thickened mucosa is due to an outgrowth of the stroma and surface epithelium, as well as to
simultaneous penetration of the glands into the depth. b indicates large clumps of glands lying
deep in the muscle. Longitudinal, transverse and oblique sections of glands are seen. Note
that the epithelium in this section is only one layer in thickness and that it shows no tendency
to fill the gland cavity. Other sections, however (see Figs. 199 and 200) show marked prolifera-
tion of the epithelium, both on the surface and in the depth. The characteristic grouping of the
glands in the depth is in itself sufficient to warrant the diagnosis of adeno-carcinoma, even if we
had not had further sections to support this view. (After H. A. HARRIS.)

THESE AND OTHERS ARE THE MAIN FEATURES OF THE EARLY ADENO-CARCINOMA OF THE BODY OF THE UTERUS. THE Glands are arranged in small groups, and the epithelium is thickened. The glands are long and slender, and the epithelium is directly continuous with that lining the glands. The glands are exceptionally long and slender. Thus it will be seen that the markedly thickened mucosa is due to an outgrowth of the stroma and surface epithelium, as well as to simultaneous penetration of the glands into the depth. *b* indicates large clumps of glands lying deep in the muscle. Longitudinal, transverse, and oblique sections of glands are seen. Note that the epithelium in this section is only one layer in thickness, and that it shows no tendency to fill the gland cavity. Other sections, however (see Figs. 199 and 200), show marked proliferation of the epithelium, both on the surface and in the depth. The characteristic grouping of the glands in the depth is in itself sufficient to warrant the diagnosis of adeno-carcinoma, even if we had not had further sections to support this view. (After H. A. KELLY.)

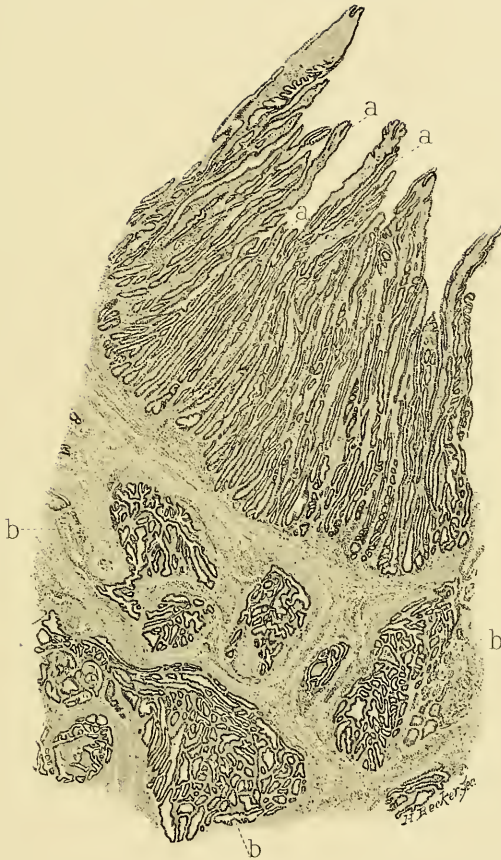PLATE VIII.—EARLY ADENO-CARCINOMA OF THE BODY OF THE UTERUS.

Gyn.-Path. No. 559. The section is taken from Fig. 193 at point 5. The upper surface, therefore, corresponds to the uterine cavity. Projecting from the surface are many delicate, straight, or slightly branching, finger-like outgrowths, as indicated by *a*. Covering this is one layer of epithelium, as can be well seen in Fig. 198 (p. 381), which shows one of the fingers under the high power. The epithelium covering the surface of the fingers is directly continuous with that lining the glands, which are exceptionally long and slender. Thus it will be seen that the markedly thickened mucosa is due to an outgrowth of the stroma and surface epithelium, as well as to simultaneous penetration of the glands into the depth. *b* indicates large clumps of glands lying deep in the muscle. Longitudinal, transverse, and oblique sections of glands are seen. Note that the epithelium in this section is only one layer in thickness, and that it shows no tendency to fill the gland cavity. Other sections, however (see Figs. 199 and 200), show marked proliferation of the epithelium, both on the surface and in the depth. The characteristic grouping of the glands in the depth is in itself sufficient to warrant the diagnosis of adeno-carcinoma, even if we had not had further sections to support this view. (After H. A. KELLY.)

THESE AND OTHERS ARE THE MAIN FEATURES OF THE EARLY ADENO-CARCINOMA OF THE BODY OF THE UTERUS. THE Glands are arranged in small groups, and the epithelium is thickened. The glands are long and slender, and the epithelium is directly continuous with that lining the glands. The glands are exceptionally long and slender. Thus it will be seen that the markedly thickened mucosa is due to an outgrowth of the stroma and surface epithelium, as well as to simultaneous penetration of the glands into the depth. *b* indicates large clumps of glands lying deep in the muscle. Longitudinal, transverse, and oblique sections of glands are seen. Note that the epithelium in this section is only one layer in thickness, and that it shows no tendency to fill the gland cavity. Other sections, however (see Figs. 199 and 200), show marked proliferation of the epithelium, both on the surface and in the depth. The characteristic grouping of the glands in the depth is in itself sufficient to warrant the diagnosis of adeno-carcinoma, even if we had not had further sections to support this view. (After H. A. KELLY.)

THESE AND OTHERS ARE THE MAIN FEATURES OF THE EARLY ADENO-CARCINOMA OF THE BODY OF THE UTERUS. THE Glands are arranged in small groups, and the epithelium is thickened. The glands are long and slender, and the epithelium is directly continuous with that lining the glands. The glands are exceptionally long and slender. Thus it will be seen that the markedly thickened mucosa is due to an outgrowth of the stroma and surface epithelium, as well as to simultaneous penetration of the glands into the depth. *b* indicates large clumps of glands lying deep in the muscle. Longitudinal, transverse, and oblique sections of glands are seen. Note that the epithelium in this section is only one layer in thickness, and that it shows no tendency to fill the gland cavity. Other sections, however (see Figs. 199 and 200), show marked proliferation of the epithelium, both on the surface and in the depth. The characteristic grouping of the glands in the depth is in itself sufficient to warrant the diagnosis of adeno-carcinoma, even if we had not had further sections to support this view. (After H. A. KELLY.)

PLATE VIII.



Early adeno-carcinoma of the body of the uterus.

are completely filled with cells having large, oval, vesicular nuclei. Between these cells are many polymorphonuclear leucocytes. The stroma shows marked

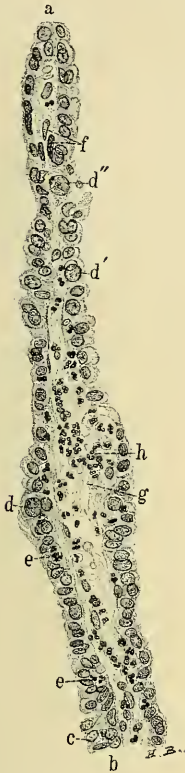

FIG. 198.

FIG. 198.—AN ISOLATED FINGER-LIKE OUTGROWTH IN ADENO-CARCINOMA OF THE BODY OF THE UTERUS. (215 diameters.)

Gyn.-Path. No. 559. The picture represents one of the delicate outgrowths in Plate VIII, and is taken from Fig. 193 at point *c*. *a* corresponds to the tip. *b* represents the base. At the base there is an outer covering of two layers of cells. *c* represents the average size of the nucleus. *d*, *d'*, and *d''* are nuclei fully three times the average size. At *e*, polymorphonuclear leucocytes have wandered out between the individual cells. The stroma of the outgrowth is very scant, but two of its spindle-shaped cells are recognised at *f*. Scattered throughout the stroma is much blood, as seen at *g*, and many polymorphonuclear leucocytes, especially abundant at *h*. Such an outgrowth as this in the scrapings would surely indicate a malignant growth, as they are never found in the uterus except in cases of carcinoma. Of course, other confirmatory pictures would also be found.

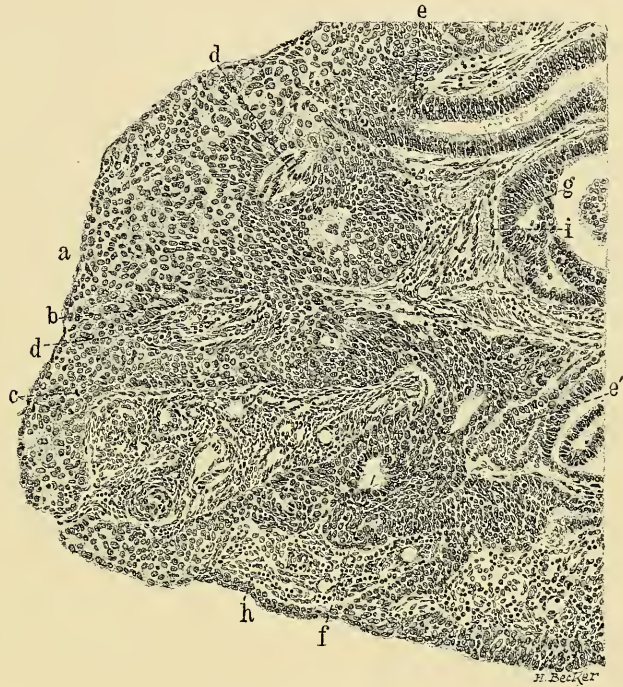

FIG. 199.

FIG. 199.—PROLIFERATION OF THE SURFACE EPITHELIUM RESEMBLING SQUAMOUS EPITHELIUM, BUT BELONGING TO ADENO-CARCINOMA OF THE BODY OF THE UTERUS. (100 diameters.)

Gyn.-Path. No. 559. This section is taken from Fig. 193 at point 7. *a* is the surface of the growth. Here the epithelium is many layers in thickness, and resembles proliferated squamous epithelium. *d*, *d* are clumps of stroma which correspond well with papillae. At *b* the epithelial cells are cuboidal, and arranged at right angles to the stroma. At *e* a few polymorphonuclear leucocytes have wandered out between the epithelial cells. At *e* and *e'* the direct continuity of the gland epithelium with that of the proliferated portion can be traced. *f* is a gland surrounded by many layers of epithelium. *g* is one of the carcinomatous glands. *h* is the stroma of the growth infiltrated with many small round cells. *i* is a small blood-vessel. Such pictures as this have led to considerable confusion, and more than one authority has, not without some excuse, concluded that two varieties of cancer were present: an adeno-carcinoma, and, in addition, a squamous-cell carcinoma. In this connection Fig. 200 (p. 382), Fig. 183 (p. 362), and Fig. 165 (p. 321) should be referred to.

small-round-cell infiltration, and has a rich blood supply. Almost the entire mucosa of the uterine cavity is altered, being represented by finger-like papillæ, which project irregularly into the cavity. These papillæ form the walls of tubular

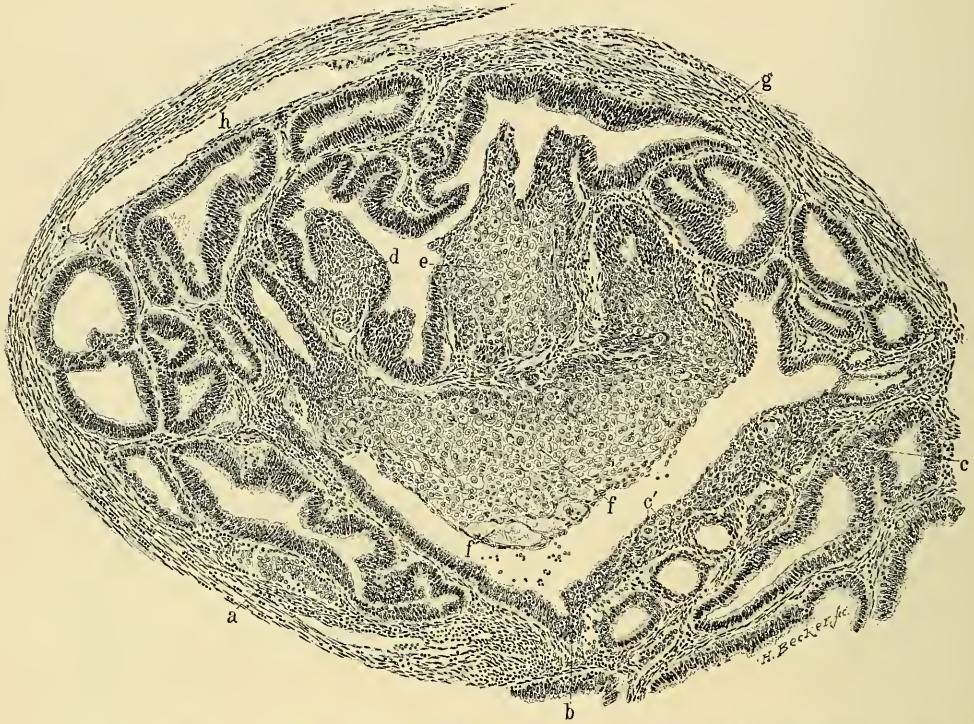

FIG. 200.—A GROUP OF CARCINOMA GLANDS DEEP DOWN IN THE UTERINE MUSCLE, AND SHOWING MARKED PROLIFERATION OF CELLS, RESEMBLING SQUAMOUS EPITHELIUM. (75 diameters.)

Gyn.-Path. No. 559. This section is taken from Fig. 193 at point 8, fully 1.5 centimetres beneath the surface of the growth. The picture comprises a clump of glands, which, on the whole, have preserved their original type remarkably well. (See Plate VIII.) Some are cut transversely, others obliquely; a few show considerable branching. At *a* is represented a gland cut at its base or along the side, so that we only see a bunch of cells. The gland epithelium is at some points only one layer in thickness, but in most places several layers are present. At *b* many small round cells have wandered in between the individual cells. At *c* there is considerable thickening of the epithelium, and at *c'* several of the cells stain faintly, owing to the presence of an abundant zone of protoplasm. At *d* there is also much thickening. The epithelium at *e* is greatly thickened, and the cells in the central portion look exactly like squamous cells. Precisely the same picture is present at *f*, and yet in both these places there is no question but that the cells have originated from the cylindrical epithelium. At *f'* there is slight necrosis of the cells. *g* is the uterine muscle showing some small-round-cell infiltration. *h* is a blood-vessel.

glands, which extend down into the muscle (Plate VIII). The papillæ are covered by cylindrical epithelium, which on the surface is usually one layer in thickness (Fig. 198). As it extends down into the glands, it may still be one layer thick, but usually consists of two or three layers. In the papillæ themselves are small gland-like spaces, lined by one layer of cuboidal or cylindrical epithelium. The stroma of the papillæ, which is very lax, is composed of cells, whose nuclei are elongate-oval. Scattered throughout this tissue are many small round cells and a moderate number of polymorphonuclear leucocytes.

Penetrating the muscle for at least a distance of 1.2 centimetres are large or small groups of glands (Plate VIII). These are lined by one or two layers of cylindrical epithelium, are sharply outlined, and have a faint amount of stroma between them. In some places the gland epithelium has grown into and has almost obliterated the cavity. The cells have large, oval, vesicular nuclei, surrounded by a large quantity of protoplasm. So profound is the transformation, that were it not for their position, it would be almost impossible to distinguish them from squamous epithelium (Fig. 200). The new growth has in places undergone coagulation necrosis, and shows moderate polymorphonuclear leucocytic infiltration. The uterine muscle along the advancing margin of the growth shows moderate small-round-cell infiltration, but apart from this is normal. The nodule situated in the posterior wall, just beneath the left cornu, is composed of non-striped muscle fibre. Both tubes are the seat of a hydrosalpinx simplex.

This case is of especial interest from the fact that in some places the epithelium closely resembles the squamous variety, the more so since transformation from cylindrical into so-called squamous epithelium can readily be traced. It is also noteworthy on account of the great clearness with which the various stages of development of adeno-carcinoma can be distinguished—from the delicate finger-like outgrowths of the surface epithelium to the final typical adeno-carcinomatous structure.

Diagnosis.—Adeno-carcinoma of the body. Subperitoneal uterine myoma. Double hydrosalpinx simplex.

The patient's daughter informs me that for a short time after returning home Mrs. A. was a little better, but had some intestinal trouble all summer. "Her stomach was as hard as could be and shone like glass." She never had any hæmorrhages, but a recto-vaginal fistula developed. Her suffering was severe and she became "flighty." Death took place one year and nine months after operation.

Gyn.-Path. No. 780

Adeno-carcinoma of the body of the uterus (Fig. 201). Small parovarian cyst on the left side; abdominal operation, the uterus being amputated just above the vaginal vault. Histological picture showing necrotic surface of the growth (Fig. 202). Death from a local recurrence, two years and seven months after operation.

R. M., aged fifty-two, white. Admitted to Dr. Kelly's sanatorium June 22, 1895.

The patient has been married twenty-four years, and has had two children. Her menstrual history was normal.

For about eight months she has suffered with colicky-like pain in the lower abdomen and left flank. This usually commenced during the morning, and would last for a number of hours. She has had several uterine hæmorrhages, most of which occurred after exertion. At present she complains of pain in the lower abdomen, and of a slightly blood-stained leucorrhœal discharge. The

patient looks fairly healthy, but is rather sallow. The vaginal outlet is relaxed; the cervix is small and intact. The uterus is enlarged, movable, and rather soft. The appendages are apparently free.

Operation June 27th. Abdominal hysterectomy.

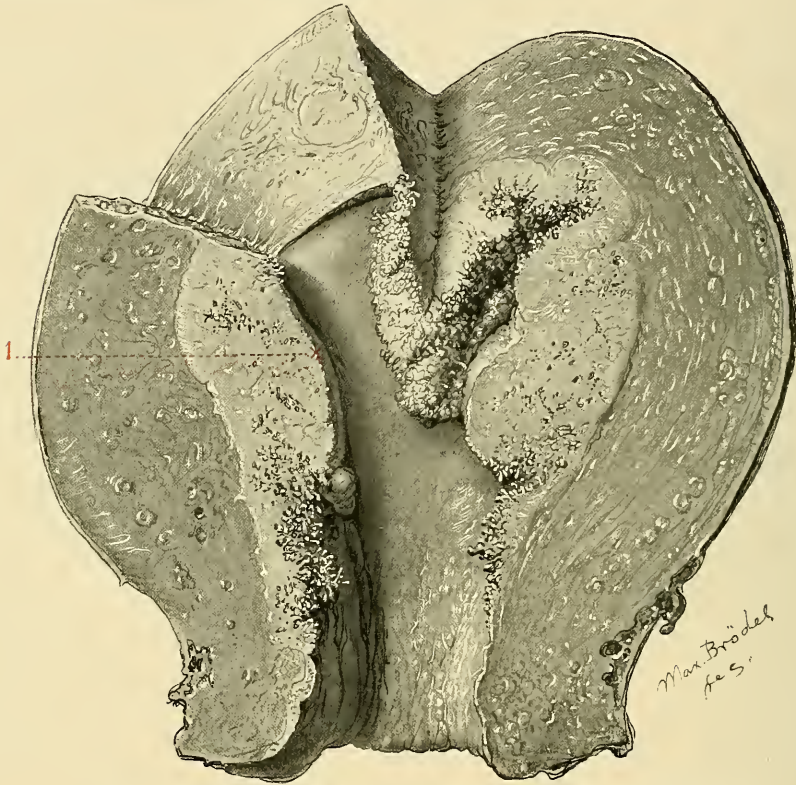


FIG. 201.—ADENO-CARCINOMA OF THE BODY OF THE UTERUS. (Natural size.)

Gyn.-Path. No. 780. The uterus is twice its normal size, and has been opened anteriorly. The upper part of the cervix is present; its mucosa appears to be normal. The mucosa of the body of the uterus over a limited area is smooth, of the normal thickness, and shows no change. Occupying the anterior wall, however, on the left side, is a new growth, which near the internal os is recognised as delicate or knob-like processes springing from the mucosa. On passing upward the growth becomes thicker and more compact, but we still have these little outgrowths covering the surface. In the upper part of the cavity the growth reaches nearly 2 centimetres in thickness, and in some places is very smooth, as at 1. Here the surface is entirely necrotic, as seen in Fig. 202. The carcinoma has invaded the uterine wall to some extent, and its light appearance stands out in marked contrast to the darker uterine muscle. In such a case we now remove the entire uterus, and would not for a moment consider the question of amputation, even at the vaginal vault.

The uterus was amputated just above the vaginal vault, and the parts were closed in the usual manner. The patient made a good recovery, and was discharged August 5th.

Gyn.-Path. No. 780. The specimen consists of the greater part of the uterus, to which both tubes and ovaries are attached. The portion of the uterus measures $9 \times 7 \times 5.5$ centimetres. Both anteriorly and posteriorly the surface is smooth and glistening; 1.5 centimetres of the cervical canal are included in the speci-

men (Fig. 201). Its mucosa is longitudinally corrugated, and some of its glands reach 3 millimetres in diameter. The uterine walls vary from 1.5 to 3 centimetres in thickness. The uterine cavity is 4 centimetres in length, and in its upper portion is of equal breadth. The mucosa is bluish-white, smooth, and glistening. Springing from the left side of the wall is a nodule, 4.5 centimetres in length and 3 centimetres in breadth. This occupies almost the entire left side of the uterine cavity, which it narrows considerably. On section it is yellowish-white in colour, presents a homogeneous, almost smooth, surface, and is of the consistence of brain tissue. Scattered here and there throughout it, however, are pinkish-red or

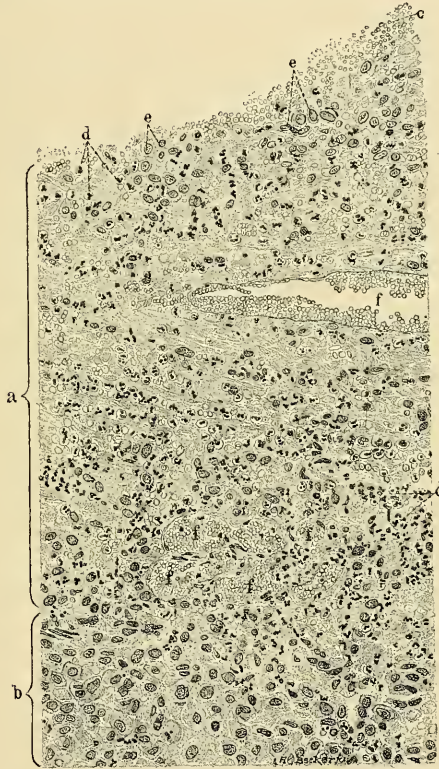


FIG. 202.—NECROSIS OF THE SURFACE OF AN ADENO-CARCINOMA OF THE BODY OF THE UTERUS.
(120 diameters.)

Gyn-Path. No. 780. This section is taken from Fig. 201 at point *l*. *a* is the necrotic surface. *b* shows the underlying carcinoma, with the epithelial cells still intact. The greater part of the area *a* is composed of necrotic epithelial cells. Covering the surface are numerous blood-corpuscles, as indicated by *c*. Scattered freely throughout the necrosed area are polymorphonuclear leucocytes, particularly abundant in the vicinity of *d*. Quite a number of epithelial cells are still to be found, as indicated by *e*. *f* shows dilated capillaries. Although the growth is an adeno-carcinoma, the cells in the area *b* form a homogeneous mass, the gland arrangement having been lost, as is so frequently the case in the older portions of the neoplasm.

yellow areas. The growth has sharply-defined margins, and invades the uterine muscle to a depth of fully 1 centimetre. Continuous with the nodule, and evi-

dently forming a part of it, is a papillary-like growth, which involves the anterior wall of the uterus from the lower margin of the nodule almost to the internal os. This consists of minute elevations or finger-like folds, which have clearly arisen in the mucosa. They project from the surface for about 5 millimetres.

Both tubes and ovaries are apparently normal, but in the left parovarium is a cyst, 2×1.5 centimetres.

Histological Examination.—The cervical glands, apart from being here and there dilated, are normal. Sections through the nodules, situated in the left uterine wall and projecting into the cavity, show that the more superficial portions are composed of necrotic material (Fig. 202). Here and there throughout this material are cells having oval, or irregularly oval, somewhat deeply staining nuclei, and scattered between them are many polymorphonuclear leucocytes. The underlying tissue has no very definite arrangement, consisting merely of cells, which lie loosely together. They are irregular in contour, have a pale-staining protoplasm, and contain irregularly oval nuclei. It is only in the deeper portions, along the advancing margin of the growth, that one is able to get at the true nature of the process. Here the cells present a gland-like arrangement. These glands are small and round on cross section, or are branching and somewhat irregular; they are lined by a single layer of cells, which are similar in character to those described above. Between the glands is a small amount of stroma, consisting of spindle-shaped cells. Along the advancing margin the muscle is seen to be invaded by delicate glands or irregular bunches of epithelial cells. Even here polymorphonuclear leucocytes are present, and the muscle shows considerable small-round-cell infiltration. The growth has apparently not reached the broad ligaments, and appears to have been entirely removed. The appendages are normal.

Diagnosis.—Adeno-carcinoma of the body of the uterus.

There was a return of the growth in the vaginal vault, the patient dying January 24, 1898, about two years and seven months after operation.

Mrs. M., a Patient of Dr. Eccles, of London, Canada

Adeno-carcinoma of the body of the uterus, diagnosed from scrapings; vaginal hysterectomy; calcareous particles both in the carcinomatous glands and in the surrounding muscle (Fig. 203). Recurrence, the patient dying eight months after operation.

M., aged sixty-two; white. Was first seen in December, 1895, when she complained of pain in the hypogastric region and also throughout the pelvis. The symptoms being somewhat suggestive of carcinoma, the uterus was curetted. Dr. A. McCallum and I both saw the scrapings, diagnosed adeno-carcinoma of the body of the uterus, and advised hysterectomy.

On January 20, 1896, Dr. Eccles removed the uterus *per vaginam*, but before doing so had to make an incision in the perinaeum to obtain the necessary room. The patient made a good recovery, but in June was

suffering from pelvic pain, and experienced great pain on defecation. From the symptoms Dr. Eccles was inclined to think that there had been a return of the growth.

Gyn.-Path. No. 1,124, March 25, 1896. The specimen consists of mutilated portions of the uterus. On making a section through the entire thickness of the uterine wall, the muscle is found to be everywhere invaded by glands, some of which occur singly, and are small and round on cross section, or are moderately dilated. In many places longitudinal sections of the glands can be seen. Here they present a markedly convoluted appearance. Both the large and small glands are lined by one layer of cylindrical epithelium, with oval, vesicular nuclei. In many places there is proliferation of the gland epithelium, the cells being gathered up into little knob-like growths or completely filling the cavity. Here and

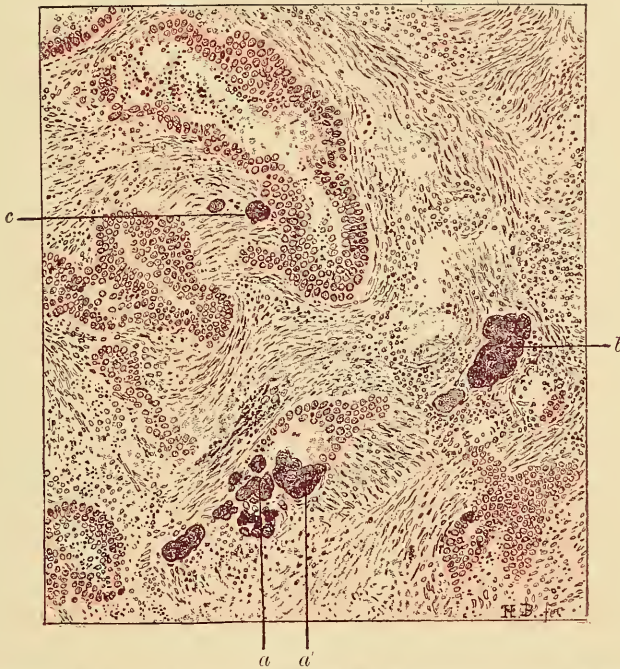

FIG. 203.—ADENO-CARCINOMA OF THE BODY OF THE UTERUS, SHOWING CALCAREOUS PLATES BOTH IN THE GLANDS AND IN THE SURROUNDING MUSCLE. (110 diameters.)

Gyn.-Path. No. 1,124. Scattered through the muscle are irregularly-shaped glands lined by several layers of cells containing oval, vesicular nuclei, or completely filled with cells. At *a* and *a'* a gland is seen partially filled by large irregular, lamellated, deeply staining bodies, which were found to be calcareous particles. At *b* the large plate completely fills the gland. Scattered throughout the muscle are a few of these particles, as seen at *c*. While such pictures are frequently noted in ovarian tumours, it is rare to find them in the uterus. There has undoubtedly first been a necrosis of the epithelial cells, followed by a deposition of calcareous salts.

there the epithelium on one side of the gland consists of a single row of cells, while on the opposite side it is several layers in thickness. At many points in the muscle are large masses of epithelial cells, which, were it not for the surrounding glands, might readily be taken for masses of squamous epithelium.

Scattered throughout the uterine wall, both in the glands and also in the muscle, are small, oval, laminated, calcareous bodies, which stain either faintly or deeply with haematoxylin (Fig. 203). These show a tendency to occur in bunches, but are also found singly. The muscle is everywhere infiltrated by small round cells, and is invaded by the new growth as far as its peritoneal surface. Scattered throughout the wall are many areas of necrosis. In the cervix the growth has extended to within 1 centimetre of the external os. Whether it has been entirely removed or not it is impossible to say.

Diagnosis.—Adeno-carcinoma of the body of the uterus.

December 25, 1899. Dr. F. R. Eccles writes me that the growth returned in the vaginal vault, and that the patient only lived about eight months after operation.

Gyn. No. 3,967

Adeno-carcinoma of the body of the uterus (Fig. 204). Abdominal hysterectomy. Patient well, four years and two months after operation.

S. G., aged thirty-six; white. Admitted November 17, 1895. Complaint: a bloody vaginal discharge.

The patient, who is single, has always been regular until the present illness. Her family history is negative. She first noticed a pale bloody discharge about four years ago; this was of short duration and not accompanied by any pain. It became yellowish-white, and was at times offensive. In June of this year she had a free discharge, lasting two weeks; shortly afterward the uterus was curetted. For a time the discharge ceased but reappeared, being thin, watery, and somewhat offensive. Recently it has become purulent in character, and is frequently tinged with blood.

On admission the patient is pale and anæmic, and has evidently lost flesh. Her appetite is good, her bowels are regular. The vaginal outlet is slightly relaxed; the cervix is deeply lacerated, is soft and friable, and breaks down under the finger; the broad ligaments do not appear to be involved.

Operation. Abdominal hysterectomy. A few days after the operation there was some suppuration in the upper angle of the abdominal incision. The patient steadily recovered, and was discharged January 3, 1896.

Gyn.-Path. No. 979. The specimen consists of the uterus with its appendages intact. The uterus measures $10 \times 5 \times 4$ centimetres; its surface is smooth (Fig. 204). On the right side, 8 centimetres of the uterine vessels with the accompanying broad ligament have been removed, while on the left side they can be traced for a distance of 4 centimetres. The cervix averages 4 to 5 centimetres in diameter, and its lip is about 1 centimetre in thickness. The mucosa covering the vaginal portion of the cervix is smooth, but on pressure the tissue feels unusually firm; at various points, however, there is a sensation of softening. The external os is 2.5 centimetres in diameter; filling it is a fungating mass. On section the cervix and almost the entire uterine cavity are found to be occupied by a new growth, the surface of which is gathered up into large and small undulations, covered by mucus,

whereby their granular appearance is somewhat obscured. Laterally, the growth extends to within a very short distance of the broad-ligament attachment. The uterine mucosa, in the upper part of the cavity, is gathered up into small papillary folds which project from 2 to 9 millimetres from the surface. The appendages are normal with the exception of a few adhesions.

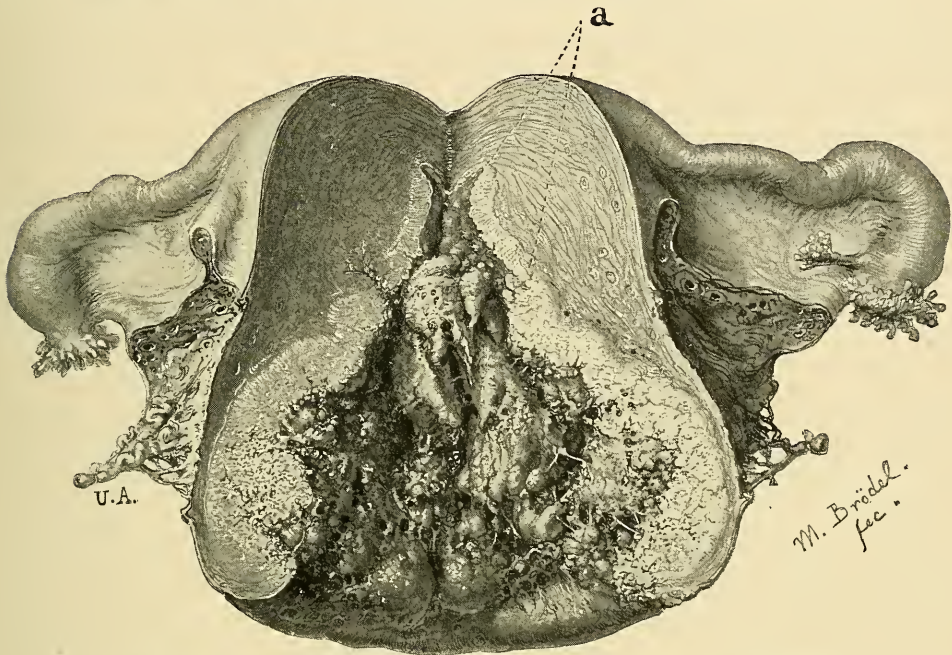


FIG. 204.—ADENO-CARCINOMA OF THE BODY OF THE UTERUS. ($\frac{1}{5}$ natural size.)

Gyn.-Path. No. 979. The cervix is greatly enlarged, but its vaginal portion is intact. Occupying almost the entire cervix and the greater part of the uterine cavity is a new growth, presenting a coarsely lobulated appearance with numerous clefts between the elevations. Springing from the surface at a few points are delicate finger-like outgrowths. Laterally, the growth has extended almost to the broad ligament attachments, and its advancing margin is sharply defined. The uterine mucosa over the area indicated by *a* is apparently still intact, but the surface is somewhat uneven. The uterine walls in the upper part of the body present the usual appearance. Laterally, the uterine arteries are seen. The body of the uterus is free from adhesions, and the tubes are apparently normal. The marked involvement of the cervix naturally suggests a cervical origin for the growth, but histological examination proved that the majority of the cervical glands were normal, and that the type of the growth corresponded to that usually found in the body.

Histological Examination.—The squamous epithelium of the vaginal portion of the cervix is intact, and the glands in the vicinity of the external os are normal. Where the growth commences, large and small bunches of glands are seen. These are lined by one or more layers of cylindrical epithelial cells, on many of which it is possible to detect cilia. Scattered throughout these islands of glands are numerous pale-staining areas, that on close inspection are found to be bunches of proliferated epithelial cells, which have evidently become fatty. On casual examination they do not look unlike epithelial pearls. The cervical glands, as a whole, do not appear to take an active part in the process, but here and there they branch more than usual, and look as if they were giving rise to new glands. In the uterine cavity the typical picture of adeno-carcinoma is

seen, there being in places finger-like projections from the surface, and everywhere in the depth large and small bunches of glands. The uterine muscle has been penetrated to a considerable depth. The mucosa in the upper part of the uterine cavity is normal, and the line of junction between the unaltered mucosa and the carcinoma is sharply defined. There is a possibility that the entire growth has been removed; it will, however, be wise to follow very closely the subsequent clinical history before rendering a favourable prognosis. The growth is an adeno-carcinoma, which has originated in the uterine glands. There is at the same time a possibility of an independent development in the cervix. The appendages are normal.

Diagnosis.—Adeno-carcinoma of the body of the uterus.

January 24, 1900. Dr. E. S. Ash, of Wadesboro, N. C., writes me "The patient's general condition is very good. There is no evidence of a return of the growth." Length of time since operation, four years and two months.

Gyn. No. 2,817

Adeno-carcinoma of the uterus apparently originating in the body (Fig. 205). Lateral incisions made in the perineum on account of the small outlet. Combined vaginal and abdominal hysterectomy. Histological picture of scrapings showing adeno-carcinoma (Fig. 206). Patient in good health, five years and six months after operation.

S. A., aged fifty; white. Admitted June 2, 1894. Complaint: a thin, bloody, vaginal discharge, with aching in the back and hips.

The patient has been married twenty-one years, and has had one normal labour but no miscarriages. Her menses ceased four years ago. One uncle died of carcinoma; the family history is otherwise negative.

In November, 1893, she noticed a constant vaginal discharge; when this was copious there was no pain, but when the amount was scanty she experienced a good deal of uneasiness in the region of the uterus. She has lost a good deal in weight. On admission, the patient is fairly well-nourished; her colour is good, the appetite is poor, the bowels are constipated; locomotion is painful.

On vaginal examination, carcinoma was diagnosed.

Operation, June 6th. On account of the small outlet it was necessary to make a lateral incision in the perineum. The cervix was ringed, and freed on all sides as far as the peritoneum; at this juncture the cervix tore away from the body of the uterus, the tissue being very friable on account of the carcinomatous involvement. The abdomen was then opened and the fundus dissected out; the vaginal vault was closed, the abdominal wall sutured, and a gauze pack introduced into the vagina.

The patient made a good recovery, and was discharged June 30th.

Gyn.-Path. No. 321. The specimen consists of the uterus, both tubes and ovaries, together with a moderate amount of uterine scrapings. The uterus measures $8 \times 5 \times 3.5$ centimetres. Both anteriorly and posteriorly its surface is smooth and glistening. The cervix is small and intact; its lips average 5 millimetres in thickness. On opening the uterus it is found that the cervix is almost

separated from the body by a new growth which extends far up into the uterine cavity, and also downward into the cervix (Fig. 205). The cervical mucosa, just within the external os, is normal in appearance, but on tracing it upward for a distance varying from 3 to 5 millimetres, a change is noticed, and springing from its surface are large and small papillary-like folds, some of which have knob-like extremities. At a point corresponding to the position of the internal os the growth has invaded almost the entire uterine wall, anteriorly, posteriorly

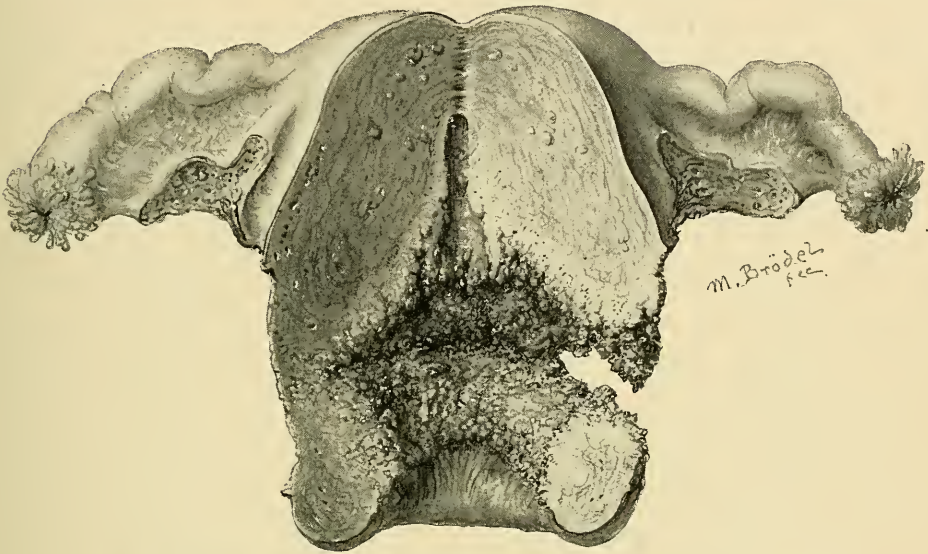


FIG. 205.—ADENO-CARCINOMA PRESUMABLY OF THE BODY OF THE UTERUS. (Natural size.)

Gyn.-Path. No. 321. The uterus is rather under size. Its general contour is well preserved, and the vaginal portion of the cervix is normal. (The conditions in the uterine cavity are naturally materially altered, as a result of the curettage.) Occupying the position of the internal os is an excavated cavity, presenting a worm-eaten appearance. The growth has extended downward to within 5 millimetres of the external os. Its advancing margin is slightly raised, and consists of small elevations. Upward, the carcinoma has invaded the mucosa almost to the fundus. On the left side the growth has advanced practically to the broad ligament, while on the right side it extends close to the cut margin. It is very doubtful whether the neoplasm has been entirely removed. The tubes are normal.

and laterally, and apparently has extended into the broad ligament. The advancing margin of the growth in the body is sharply defined, and is somewhat irregular. Where the mucosa has not been removed by the curette, it is found to consist of branching papillary folds, such as were noted in the cervix. In the small portions of the uterine mucosa which still remain, isolated mounds of papillæ spring from the surface.

Both tubes and ovaries are senile; they are free from adhesions.

Histological Examination.—The scrapings from the uterine cavity show many branching papillary-like masses having a stroma composed of spindle-shaped cells and covered externally, sometimes by one, but usually by two or several layers of cells. Where one layer only of epithelium is present it is possible to make out the cylindrical character of the cells. The nuclei are large,

elongate-oval, and vesicular; many of the cells contain nuclear figures. The growth of epithelium is out of all proportion to the amount of stroma, there being, as a rule, only two or three delicate strands of spindle-shaped cells form-

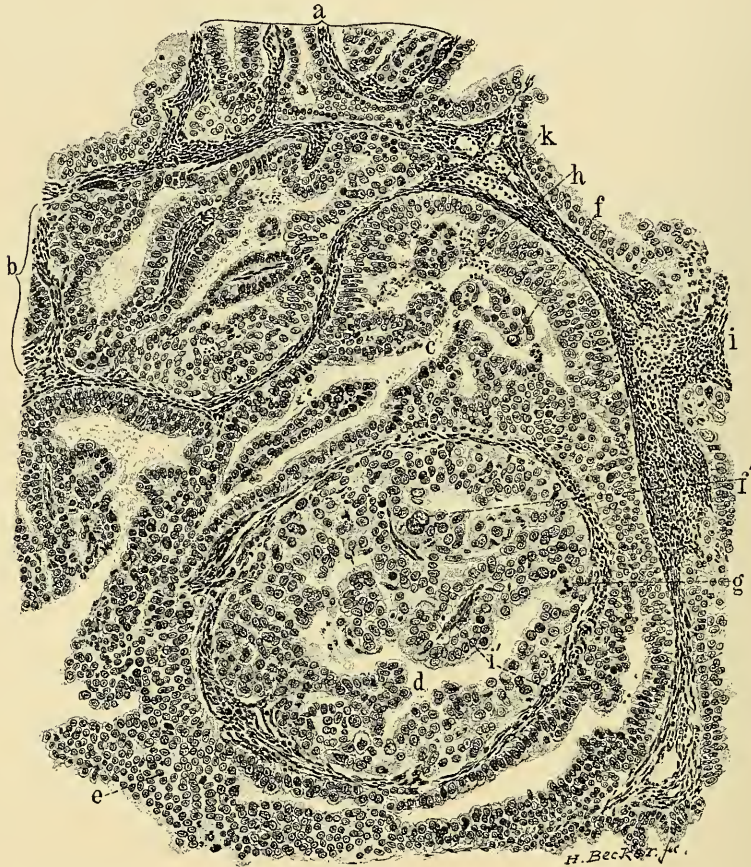

FIG. 206.—ADENO-CARCINOMA PROBABLY ORIGINATING IN THE BODY OF THE UTERUS.
A SCRAPING FROM THE UTERUS REPRESENTED IN FIG. 205. (120 diameters.)

Gyn.-Path. No. 321. Before studying the details, it is advisable to note the character of the gland grouping, which instantly suggests carcinoma. Four distinct groups of glands are indicated by *a*, *b*, *c*, and *d*. In group *b* we have two long stems of stroma stretching across one large gland. The epithelium in one or two places is only one layer deep, but, as a rule, many layers are present. In *c* the gland is irregularly convoluted, and some of the ingrowths have been so cut that they lie absolutely free in the gland cavity. In this gland also the epithelium forms many layers. The gland *d* is markedly convoluted and contains numerous ingrowths. There is some resemblance to the gland hypertrophy seen in Fig. 258 (p. 494), but the epithelial cells form many layers, and some of the nuclei are much enlarged. *e* is a solid area of epithelial cells, which can be traced far to the right and to the left. On the whole, the nuclei in this section are uniform in size and vesicular, but at *f* is a slightly enlarged and deeply staining nucleus, and at *f'* two others which are much larger and stain somewhat deeply. In group *b*, above and to the left, lying against the stroma is a very long and deeply staining nucleus. *g* is a large cell with a nucleus that has divided irregularly. At a few points the glands contain polymorphonuclear leucocytes (*h*). *i* is the stroma of the growth, which, taken as a whole, is rather scanty and dense. *k* indicates blood capillaries in the stroma.

The gland arrangement alone in this case is sufficient to justify the diagnosis of adeno-carcinoma, this view being further supported by the marked proliferation of the epithelium and the occasional enlarged and deeply staining nuclei.

ing the framework of the papillary masses. In the young papillæ one not infrequently finds in the centre only a single row of spindle-shaped cells; sometimes they are entirely wanting. At various points throughout the section markedly convoluted glands are seen; these may be lined by a single layer of epithelial cells, but in most places delicate papillary folds are seen projecting into the gland cavity, and the epithelium reaches several layers in thickness (Fig. 206). From the above scrapings, which, it may be mentioned, were obtained only at the time of the operation, a diagnosis of adeno-carcinoma could immediately be made. Moreover, from the morphological characteristics of the growth one was justified in inferring that it had originated from the mucosa of the body of the uterus. Sections were also made from various portions of the uterus. The squamous epithelium covering the vaginal portion of the cervix is still intact, but the relations in the cervical canal and also in the uterine cavity cannot be very satisfactorily made out, the tissues having been distorted by the curette. The surface of the cervical canal is covered by canalized fibrin; the underlying glands are normal. The worm-eaten and excavated area, involving both the cervix and a portion of the body, is covered by necrotic material, while extending into the tissue in all directions are branching glands similar to those described in the scrapings. The tissue everywhere shows abundant small-round-cell and polymorphonuclear leucocytic infiltration. It is hardly possible to say whether the entire growth has been removed or not. The appendages on both sides are normal.

In this case we are at a loss to tell whether the growth originally started in the cervix or in the body. As is seen, it involves the lower portion of the body and the upper portion of the cervix, whereas, as a rule, adeno-carcinoma of the body usually commences far up in the cavity. From the character of the scrapings we are inclined to believe that it first began in the body, since we have never observed this type limited entirely to the cervix.

January 6, 1900. Dr. Rufus W. Dashiell, of Princess Anne, Md., writes me: "There is no evidence of a return of the growth. The patient's general condition is good; she attends to her household duties." Length of time since operation, five years and six months.

Gyn.-Path. No. 392

Adeno-carcinoma of the body of the uterus, with extension to the peritoneal surface (Figs. 207 and 208). Abdominal hysterectomy; development of carcinomatous glands from the surface epithelium (Fig. 209). No return of growth. The patient is well, five years and five months after operation.

M. P., aged fifty-seven, white. Admitted to Dr. Kelly's sanatorium July 23, 1894. Complaint: continuous uterine hæmorrhage, pain in the lower part of the back.

Several members of the family died of tuberculosis. The patient has been married thirty-one years, but has never been pregnant; her menses ceased seven years ago. About three years ago she noticed a slight bloody uterine discharge. This has continued until the present time; now and then it has been dark in colour and clotted, but never has had any odour. Until six weeks ago she was

entirely free from pain, but lately has had a burning sensation in the lower part of the sacrum, and a feeling of discomfort in the lower extremities. When the pain is most severe, the uterine discharge becomes thicker and darker in colour. The patient's general condition is good, her bowels are regular. The vaginal outlet is intact, and the cervix is flush with the vault. The uterus is somewhat enlarged, soft, and gives a sensation of fluctuation.

Operation, July 25, 1894. Abdominal hysterectomy. The cervix was dilated, and the uterus partially curetted. The cervical lips were brought together by two silk sutures; the vagina was then cleansed and packed with iodoform gauze. The uterus was removed *per abdomen*, and the vaginal vault closed. The patient made a good recovery, and was discharged August 22d.

Gyn.-Path. No. 392. The specimen consists of the uterus with its intact appendages. The uterus measures $9 \times 7 \times 5$ centimetres, and both anteriorly and posteriorly shows no adhesions. Just beneath the left uterine cornu, posteriorly, is a whitish, slightly elevated, lobulated nodule, 2.5 centimetres in diam-

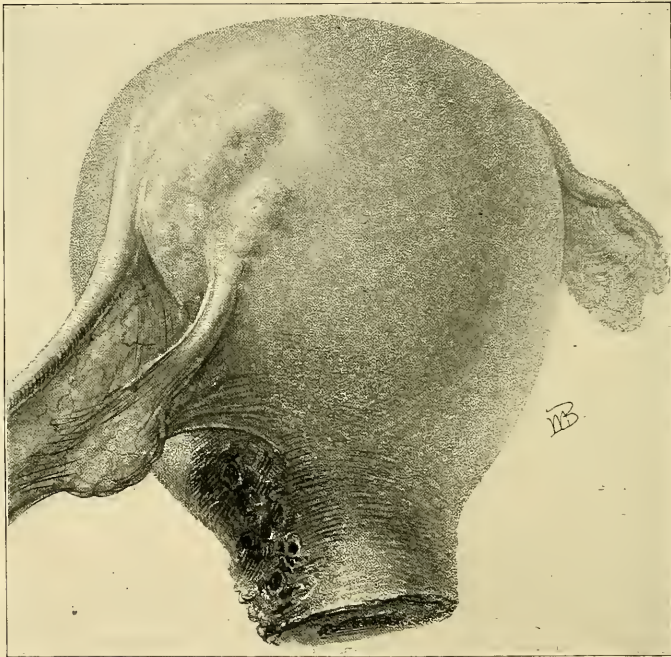


FIG. 207.—ADENO-CARCINOMA OF THE BODY OF THE UTERUS WITH EXTENSION TO THE PERITONEAL SURFACE. (Natural size.)

Gyn.-Path. No. 392. Seen from behind. The body of the uterus is globular in outline and is normal. Just posterior to the origin of the left tube is an elongated and lobulated area consisting of small, slightly raised nodules. Continuous with the inner end of the utero-ovarian ligament are four similar nodules. As will be seen from the text, these are carcinomatous masses, the growth having penetrated the entire thickness of the uterine wall and lying just beneath the peritoneum. The appendages, so far as can be determined, are normal. For the appearance of the uterine cavity, see Fig. 208. (After H. A. KELLY.)

eter (Fig. 207). This has a smooth, peritoneal covering. About 1.5 centimetres below this nodule are two or three smaller ones, similar in character. On sec-

tion of the uterus the cervix is found to be 2 centimetres in length. Its mucosa is pinkish in colour, and gathered up into transverse folds. The uterine muscle averages 8 millimetres in thickness. The cavity is 6.5 centimetres long, and when the uterus is laid open, 8 centimetres in circumference. The mucous

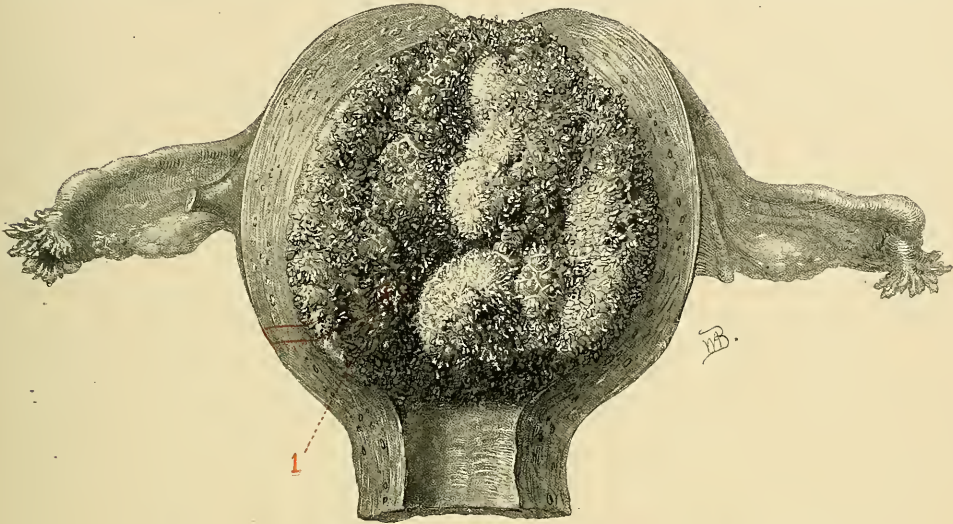


FIG. 208.—ADENO-CARCINOMA OF THE BODY OF THE UTERUS. ($\frac{4}{5}$ natural size.)

Gyn.-Path. No. 392. The uterus has been opened posteriorly. The cervical mucosa is normal, but occupying the entire uterine cavity, and extending as far as the internal os, is a new growth consisting of myriads of delicate finger-like outgrowths. The uterine walls would not appear to have been invaded to any appreciable extent, but a reference to Fig. 207 shows that at several points the carcinoma has involved the entire thickness of the muscular walls, and is seen forming small nodules just beneath the peritoneal covering. This case is particularly noteworthy on account of the uniform involvement of the mucosa, practically no uterine cavity remaining. The appendages are normal. (After H. A. KELLY.)

membrane as such is not present, but is represented by a yellowish-white friable material, that springs from every part of the uterine cavity, and completely fills it (Fig. 208). This growth is composed of large and small, ill-defined papillary masses, the largest of which is about 2 centimetres long, 1.5 centimetres broad, and 5 to 10 millimetres in thickness. The large masses are partially divided into smaller ones, being slightly lobulated. In many places, and especially between these large masses, are myriads of small, delicate, finger-like folds, which in diameter would be about half that of the smallest pin. This growth in most places projects 1 centimetre or more into the uterine cavity. It also extends outward, penetrating the uterine muscle almost to its peritoneal coat; on the left side, just beneath the uterine cornu, where the white, slightly lobulated nodule was seen, it has penetrated through the entire thickness of the wall. Sometimes the new growth invades the muscle in one solid mass, but in other places, especially near the left cornu, it is recognised as irregular yellowish-white foci, varying from a pin-point to 1.3 centimetres in diameter. Both tubes and ovaries are senile, and appear to be normal.

Histological Examination.—The cervical mucosa is normal. Its glands present no change, until within a short distance of the internal os, where a few are dilated, some reaching 1.5 millimetres in diameter. The dilated glands are lined by cuboidal epithelium. Just beyond the internal os, two or three

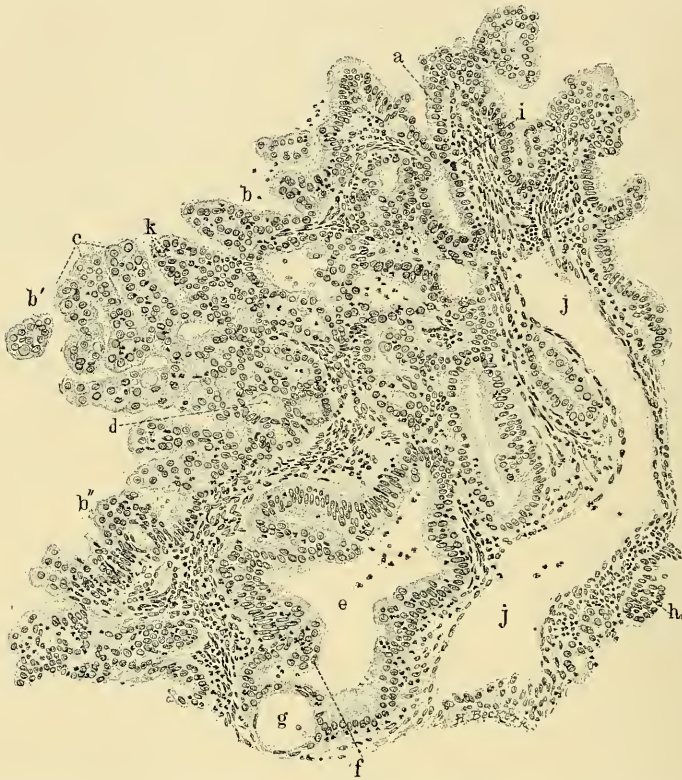

FIG. 209.—ADENO-CARCINOMA OF THE BODY OF THE UTERUS ORIGINATING FROM PROLIFERATION OF THE SURFACE EPITHELIUM. (108 diameters.)

Gyn.-Path. No. 392. The section is taken from Fig. 208 at point *I*. *a* is a gland lined by one layer of cylindrical epithelium, and is seen opening on the surface. Springing from the mucosa are many finger-like or irregular outgrowths composed entirely of epithelial cells. One of the most characteristic is indicated by *b*. A similar one is shown in cross section by *b'*. At *b''* the epithelium has developed in such a way that a new gland is formed. *c* embraces three parallel outgrowths, entirely devoid of stroma. In the subjacent epithelium are numerous newly formed glands, as shown at *d*. *e* is a convoluted gland in the underlying stroma. It is lined by several layers of cells, and at *f* shows a distinct ingrowth. *g* is a small gland space formed in the wall of this convoluted gland. Its epithelium is considerably flattened. *h* is a small mass of cancer cells. The epithelium throughout the specimen is very uniform, but at *i* commencing changes in the nuclei are visible, two staining very deeply. *j* is a large vein with very delicate walls. At numerous points polymorphonuclear leucocytes have wandered out between the epithelial cells, as indicated at *k*. The stroma is very abundant in the deeper portions, and consists of cells having elongate-oval or spindle-shaped nuclei. It shows considerable infiltration with polymorphonuclear leucocytes and small round cells. From a picture of this character a diagnosis of adeno-carcinoma is justifiable.

normal uterine glands are noticed, but a little farther on a marked change is seen both in the glands and in the stroma. The former are slightly increased in number, are long and narrow, and project somewhat in the form of papillary masses into the cavity of the uterus. Their epithelium is identical with that of

the ordinary uterine glands. As one approaches the fundus, the proliferation is more extensive, the glands being typical or completely filled with epithelial cells. At a few points a most instructive picture is seen (Fig. 209). Here the epithelium of the surface has greatly multiplied in such a manner that many new glands have been formed. These lie side by side, or are separated from each other by epithelium. In such areas no stroma cells are as yet to be found. The tissue is becoming necrotic, but there is but little breaking-down. Scattered between the glands are a few half-moon-shaped bodies, which stain very deeply. These are surrounded by a large rim of protoplasm, which has taken up numerous red blood-corpuscles.

The stroma between the newly formed glands is very scanty, the glands in many places lying practically one against the other. Scattered throughout the uterine muscle, especially in the posterior wall and left uterine cornu, are clusters of these glands. The nodule on the posterior surface of the uterus consists of the same elements. In the deeper parts of the muscle the epithelial cells tend more to the formation of solid alveoli, the gland cavities being completely filled with the cells. At the first glance over such an area, the diagnosis of squamous-cell carcinoma might very readily be made. In the left uterine cornu the central portions of many of the alveoli contain large quantities of blood. The muscle surrounding the areas of the new growth shows marked small-round-cell infiltration. The entire picture is one of adeno-carcinoma. The appendages are normal.

The chief interest in this case lies in the fact that the entire uterine cavity shows such a uniform involvement by the new growth. Whether the disease has extended into the broad ligament or not, we are unable to say.

Diagnosis.—Adeno-carcinoma of the body of the uterus.

January 1, 1900. Dr. Kelly informs me that the patient is perfectly well, and that there is no evidence of a return of the growth. Length of time since operation, five years and five months.

Gyn. No. 4,922

An unusual form of adeno-carcinoma of the body of the uterus (Fig. 210). Small uterine myomata. Abdominal hysterectomy. An area resembling somewhat, on histological examination, a solid ovarian tumour (Fig. 211).

No evidence of return, one year and eleven months after operation.

S. J. S., white; aged fifty-eight. Admitted January 6, 1897. Complaint: bloody vaginal discharge of sixteen months' duration. The menses commenced at sixteen, were always regular, lasted six to seven days, but at times were painful; they ceased in her fifty-first year, and for seven years she had no discharge. Since September, 1895, however, there has been a very constant offensive bloody and watery vaginal flow, but never any flooding.

The previous history is unimportant. The patient has been married thirty-six years, and has had two children. Her cousin died of cancer of the rectum; otherwise the family history is good.

Present illness. Accompanying the bloody discharge in 1895, there was much pain in the lower abdomen radiating to the back and down the legs to the knee. The patient has lost much flesh and strength, is pale and markedly cachectic.

The vagina is bathed in a foul secretion. The cervix is high up and very small, not being over 5 millimetres in diameter. The uterus is elongated, large, and irregular, the size of that of a two-and-a-half months' pregnancy.

January 16th. Abdominal hysterectomy.

The patient was first put in the perineal position and the cervical canal closed by a continuous silk ligature, which was then cut off short. The vagina was carefully cleansed and packed with iodoform gauze. The uterus was then removed through the abdomen and the peritoneal cavity closed. The patient rapidly gained in strength, and was discharged February 12th.

Gyn.-Path. No. 1,473. The specimen consists of the uterus with its appendages intact.

The uterus is 13 centimetres long, 10 centimetres broad, and 9 centimetres in its antero-posterior diameter. Its surface is smooth and glistening. Situated low down on the posterior surface is a myomatous nodule, 2 centimetres in diameter. The cervix is 3.5 centimetres broad, and its vaginal portion appears to be normal. The cervical canal is 2 centimetres in length; its mucosa is apparently unaltered. With the uterus lying open, its cavity is 10 centimetres in length and 9 centimetres in breadth at the fundus (Fig. 210). The mucosa in the lower part of the cavity is smooth and apparently not more than 1 millimetre in thickness. Nearly the entire uterine cavity has been invaded by a new growth which consists of large and small, irregular, but smooth masses, varying from 1.5 to 5 centimetres or more in size. In the deep sulci between these ingrowths, and here and there on their surfaces, tufts of minute finger-like processes are visible. The growth in some places reaches 4 centimetres in thickness, the average being about 2 centimetres. On section it appears to be made up of large and small alveoli separated by translucent bands of tissue. These alveoli vary from a pinpoint to 3 millimetres in diameter. At several points, especially in the vicinity of the left uterine horn, the growth has penetrated to within 5 millimetres of the peritoneal surface. Situated in the middle of the anterior wall and partially surrounded by the new growth is a myomatous nodule 1.5 centimetres in diameter.

The right tube is 9 centimetres in length, averages 6 centimetres in diameter, and has a patent fimbriated extremity. The ovary is $3.5 \times 2 \times 1$ centimetres and covered by a few delicate adhesions.

The left tube corresponds in size to its fellow on the right side and is free from adhesions. The ovary is $4 \times 2.5 \times .8$ centimetres; it has a few delicate adhesions clinging to its surface.

Histological Examination.—The squamous epithelium covering the vaginal portion of the cervix is intact, but the cylindrical epithelium of the cervical portion is wanting. The surface is here covered by blood and polymorphonuclear leucocytes. The underlying stroma shows considerable small-round-cell infiltration. The glands in their superficial portions are somewhat compressed, and their epithelial cells are slightly swollen. In the deeper portion the glands are normal. On passing within the internal os, the surface epithelium is found

to be intact, but much flattened. At some points the mucosa is gathered up into club-shaped projections, in the neighbourhood of which the epithelium is five or more layers in thickness.

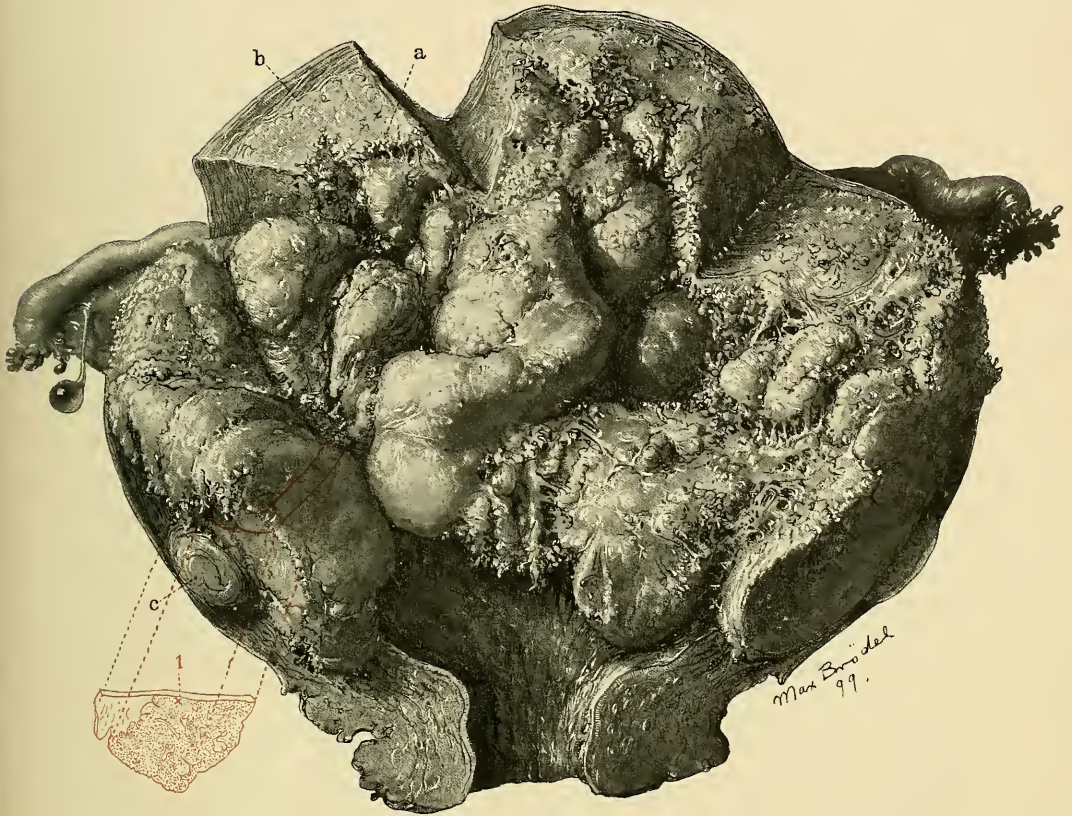


FIG. 210.—ADENO-CARCINOMA OF THE BODY OF THE UTERUS. ($\frac{4}{5}$ natural size.)

Gyn.-Path. No. 1,473. The uterus is much enlarged. The mucosa of the cervical portion presents the usual appearance, and that of the lower part of the cavity over a limited area is unaltered, but over almost the entire uterine cavity it is replaced by a new growth. The surface of the neoplasm is gathered up into large and small dome-like or polypoid outgrowths, which are comparatively smooth, or have delicate finger-like tufts springing from them (*a*). These are also found in the depressions between the large outgrowths. The growth, as seen from the depression, reaches a thickness of several centimetres, and has penetrated the muscle almost to the peritoneal surface, as is indicated by *b*. *c* is a small myoma. The tubes, as far as they can be followed, are normal. It is exceptional to find an adeno-carcinoma of the body of the uterus attaining such proportions, and even here we are able to detect the delicate outgrowths.

The uterine glands, where present, are for the most part small and round on cross section; they have a normal epithelial lining, but in a few places the nuclei of the cells are two or three times their usual size. Sections from the new growth show that the surface has undergone complete coagulation necrosis, bounded along the lower border by a zone of fragmented nuclei and polymorphonuclear

leucocytes. The growth is exceedingly rich in epithelial elements. Scattered here and there throughout the field are longitudinal, branched, and transverse sections of stems of stroma—the stroma looks like little islands of tissue in a sea of epithelial cells (Fig. 211). The epithelial cells are for the most part uniform in size, and contain

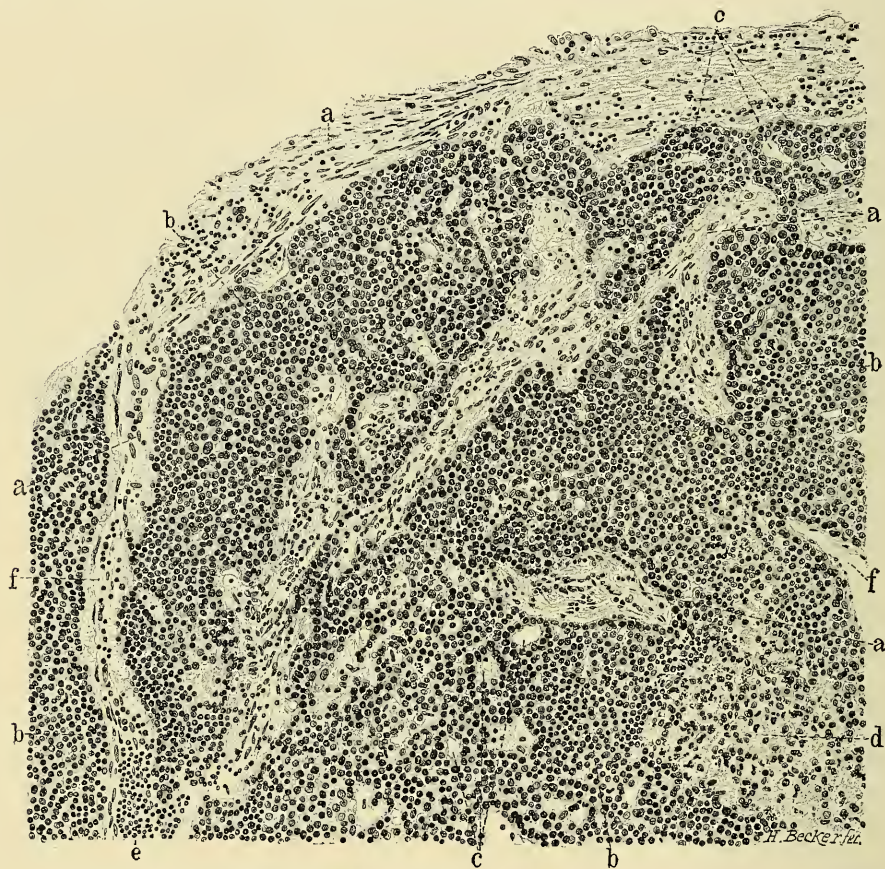


FIG. 211.—ADENO-CARCINOMA OF THE BODY OF THE UTERUS WITH ONLY A FAINT GLAND-LIKE ARRANGEMENT. (120 diameters.)

Gyn.-Path. No. 1,473. The section is from Fig. 210 at point *l*. This field may be looked upon as a large sea of epithelial cells, partially divided into smaller areas by the stems of stroma, indicated by *a, a, a*. At *b* the cells form homogeneous masses, and their source of origin could not be determined were it not for the fact that at *c* a distinct glandular arrangement of the cells is demonstrable. The nuclei of the epithelial cells are, on the whole, fairly uniform and stain deeply; a few are slightly enlarged. *d* is an area of necrosis. Many of the epithelial cells have broken up, and there is considerable polymorphonuclear leucocytic infiltration. The stroma at *e* is markedly infiltrated by small round cells. *f* is a small blood capillary in the stroma.

The entire picture bears quite a resemblance to some of the solid ovarian tumours. Knowing that this specimen came from the body of the uterus, a diagnosis of carcinoma would be justifiable, as there is no benign uterine growth that would give this picture.

oval or round, somewhat deeply staining nuclei. Even with the low power it is seen that the epithelial cells lie loosely one against the other, and, further, that in numerous places they show a fairly well marked glandular arrangement. In the

older portions of the growth some of the epithelial cells are swollen. Their nuclei are two or three times the size of those of their neighbours, and are surrounded by a large zone of protoplasm. Such cells occur singly or in small groups. Near the surface, masses of epithelial cells in many places have undergone complete coagulation necrosis. Such areas are usually some distance from the stems of stroma, and are found at the points farthest away from the blood supply. The majority of the necrotic areas show no fragmentation of nuclei, but at a few points there is both fragmentation and polymorphonuclear leucocytic infiltration. The stems of stroma consist of spindle-shaped connective-tissue cells. The larger trunks show much small-round-cell infiltration. Many of the stems, even the smallest ones, contain fairly large capillaries. Along the advancing margin of the growth the spaces in the muscle are much dilated; the tissue shows considerable small-round-cell infiltration, and at some points the presence of numerous polymorphonuclear leucocytes. The growth is an adeno-carcinoma of a very unusual type, and one that might on casual examination be mistaken for a squamous-cell neoplasm. The presence of the connective-tissue stems and the gland-like arrangement, however, render the diagnosis certain.

The myomatous nodules scattered throughout the uterus show considerable hyaline degeneration.

Sections through the right tube at the uterine cornu show that it is normal. The ovary presents a normal stroma, but scattered throughout the superficial portion are many gland-like spaces somewhat irregular in shape. They are lined by one layer of high cylindrical epithelium. A few are dilated, and their epithelium is flattened. The outer surface of the ovary at a few points is also covered by one layer of cylindrical ciliated epithelium.

The folds of the left tube show localized small-round-cell infiltration of their stroma, but are practically normal. The ovary contains several gland-like spaces similar to those on the right side.

Diagnosis.—Slight cervical endometritis. Adeno-carcinoma of the body of the uterus far advanced and of such a character as to simulate a squamous-cell carcinoma. Interstitial and subperitoneal uterine myomata.

Right Side. Normal tube; slight peri-oöphoritis; gland-like spaces in the ovary.

Left Side. Normal tube; gland-like spaces in the ovary; slight peri-oöphoritis.

December 28, 1899. Dr. Howard S. Reeser, of Reading, Pa., informs me that the patient has had no hæmorrhages, and that she is in "excellent condition." Length of time since operation, one year and eleven months.

Gyn. No. 6,659

Adeno-carcinoma of the body of the uterus, showing a very unusual polypoid condition (Figs. 212 and 213). Vaginal hysterectomy; phlebitis in the left leg; slight pleurisy; early changes in the surface and gland epithelium along the margin of the growth (Fig. 214). Typical carcinoma glands (Fig. 215). Giant cells in carcinomatous glands (Fig. 216). This

patient is reported living and well eleven months after operation.

F. P. L., aged thirty; white. Admitted January 24, 1899. Complaint: uterine hæmorrhages.

The menses commenced at thirteen; they have always been profuse and irregular. They usually occurred every three or four months, but sometimes there

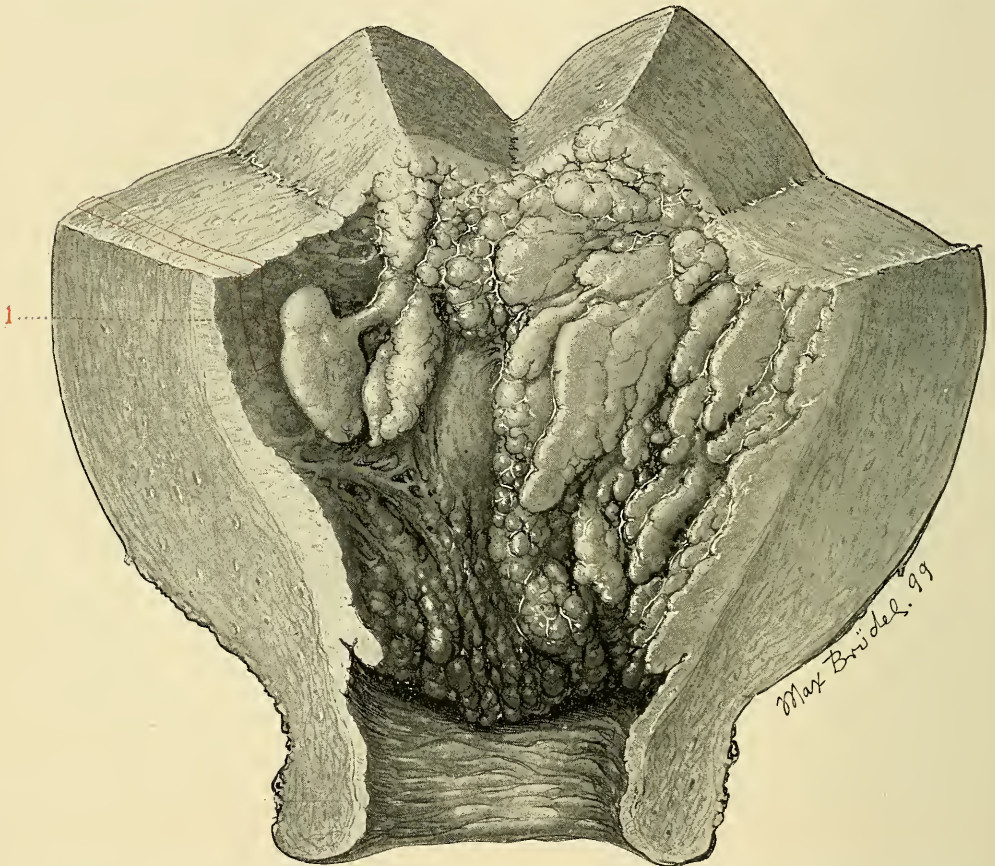


FIG. 212.—ADENO-CARCINOMA OF THE BODY OF THE UTERUS SHOWING AN UNUSUAL POLYPOID FORMATION. (Natural size.)

Gyn.-Path. No. 2,897. The uterus is more than twice its natural size, and its walls are slightly thickened. The mucosa lining the cervical canal is normal. Occupying the greater part of the uterine cavity are parallel rows of polypi of varying sizes and showing transverse depressions, which partially subdivide them into smaller excreescences. The surfaces of these polypi are somewhat smooth, and one misses the characteristic finger-like outgrowths. The lower part of the cavity also was evidently lined by similar polypi, but these have been brought away by the curette. Only over the area surrounding the point indicated by 1 is there any semblance of the normal mucosa, and even here a reference to Fig. 214 will show commencing carcinomatous changes. For the histological appearances, see Figs. 214, 215, and 216.

would be only an interval of a week between the periods, while at other times the slightest exertion was sufficient to bring them on. During the past five years the flow has lasted from one to two weeks, being very profuse and consisting of clotted blood. In the latter part of December the loss of blood was profuse

and the physician found two polypi in the cervical canal. These were removed, and the hamorrhage ceased for two weeks, but then reappeared. Menstruation has never been accompanied by much pain.

The family record and the previous history are unimportant. The patient has been married about two years but has never been pregnant.

For the last five years she has had a moderate, thin, unirritating, odourless, vaginal discharge. The patient is a rather large, well-nourished woman. There is a faint soft systolic murmur at the cardiac apex. The lung sounds are normal.

The outlet is intact; the cervix is large, but in the normal position; the external os is patulous. The body of the uterus is the size of that of a four months' pregnancy; it is freely movable and remarkably soft. The lateral structures are easily palpable and are normal.

Operation, January 25th. Vaginal hysterectomy. The uterus was curetted and a large quantity of tissue, presenting a polypoid surface, was removed. It was then decided to perform hysterectomy at once. The cervix was encircled, the bladder readily pushed back, and the peritoneum opened anteriorly. The enlarged fundus was grasped with Jacobs's forceps and drawn forward. The delivery of the organ was accomplished with difficulty on account of its large size. The broad ligaments were then tied and the uterus was cut away. The peritoneum from the anterior pelvic wall was then loosely united with that from the posterior wall, and a gauze drain introduced into the vagina.

On February 3d the last pelvic drain was removed.

On February 16th she complained of aching in the left leg, and on the following day a cord-like body could be felt along the middle of the calf of the leg. The leg was elevated and the thermocautery applied. On February 22d she had severe pain in the lower part of the chest on the right side, and complained of pain in the right shoulder and in the muscles of the neck. A few crepitant rales and a pleuritic friction sound were to be made out in the subaxillary region.

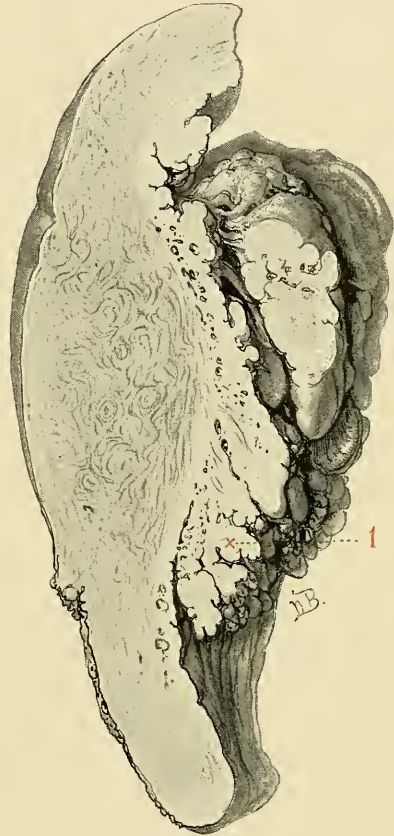

FIG. 213.—ADENO-CARCINOMA OF THE BODY OF THE UTERUS WITH EXCESSIVE FORMATION OF POLYPI. (Natural size.)

Gyn.-Path. No. 2,897. This is a longitudinal section through Fig. 212. Note the smooth surfaces of the polypi and the manner in which they spring from the mucosa. Some are nearly 2 centimetres in thickness. The uterine muscle shows little or no involvement by the growth. The histological picture at point 1 is shown in Fig. 215.

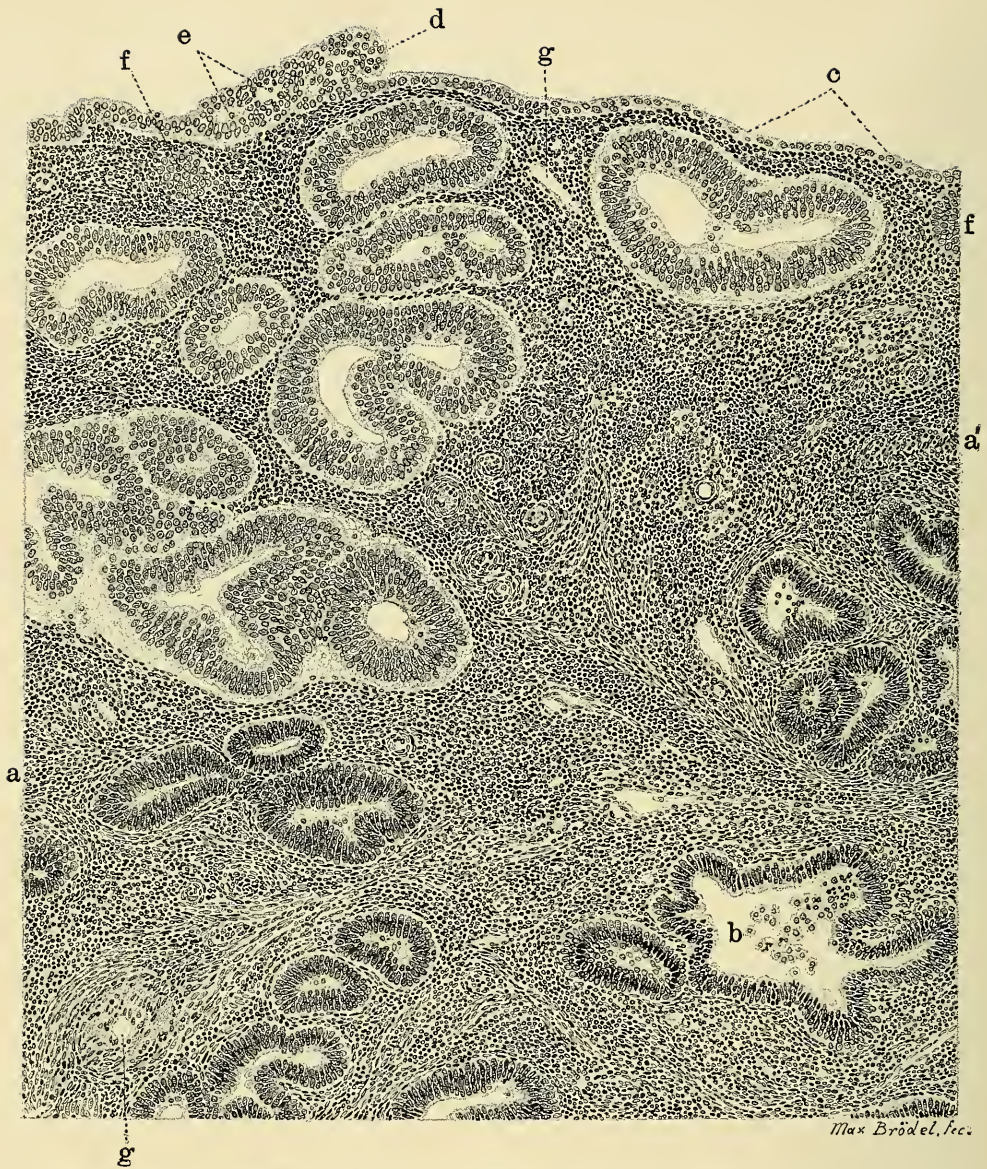


FIG. 214.—EARLY CHANGES IN THE SURFACE AND GLAND EPITHELIUM IN ADENO-CARCINOMA OF THE BODY OF THE UTERUS. (120 diameters.)

Gyn.-Path. No. 2,897. The section is from Fig. 212 at point *I*, and is divisible into two distinct portions by a line drawn from *a* to *a'*. In the lower half we have normal uterine glands, apparently lined by two or three layers of cells, as the section is not particularly thin. The nuclei of these cells are oval, and stain somewhat deeply. *b* is a dilated gland that contains desquamated epithelial cells and a few polymorphonuclear leucocytes. The stroma in the lower half is practically normal. The surface epithelium at *c* is somewhat flattened, and stains palely. On tracing it to the left, it gradually becomes two layers thick, and at *d* forms a distinct outgrowth. This proliferated epithelium at *e* has formed two young glands. The glands in the upper half of the specimen are much larger; their epithelium is many layers in thickness, and the nuclei are oval and vesicular. The stroma near the surface shows much small-round-cell infiltration. *f* indicates the edges of the glands cut in such a way as to appear as solid nests of cells. Given glands similar to those in the upper half of the picture, one is sure to find adeno-carcinoma in the neighbourhood. For a similar condition, see Fig. 187 (p. 369).

The patient left the hospital on February 27th. The vagina was free from induration, the pelvis perfectly clear, and the general condition excellent. The phlebitis had disappeared and the respiratory symptoms were no longer present.

Gyn.-Path. No. 2,897. The specimen consists of the uterus. This is pear-shaped, 12 centimetres long, 8 centimetres broad, and 5 centimetres in its antero-posterior diameter. The surface is smooth and the organ on pressure is found to have a uniform consistence. The external os presents the usual appearance, but is considerably dilated. The cervical canal is 2.5 centimetres in length; its mucosa is apparently unaltered. The uterine cavity is 8 centimetres in length, and 6.5 centimetres in breadth at the fundus. The mucosa, as a whole, presents a most unusual picture, consisting of large polyp-like masses springing from all parts and completely filling the enlarged cavity (Fig. 212). Some of the polypi are pedunculated, others have broad basal attachments (Fig. 213). They vary in size, the largest being 4 centimetres in length and fully 2 centimetres in thickness. They are yellowish pink in colour, with here and there slight mottling. The surfaces are comparatively smooth, but many of the polypi are traversed by numerous depressions, which divide them into several lobules. In a few cases the surfaces are covered by minute finger-like processes, more especially near the internal os. The deeper portions present a comparatively smooth cut surface, while here and there between the polypi are delicate tufts of finger-like processes. The uterine walls average 2.5 centimetres in thickness. They have not been penetrated by the growth.

Histological Examination.—The epithelium covering the vaginal portion of the cervix is intact. The cervical glands in the vicinity of the external os present the usual appearance, but near the internal os are several convoluted glands, lined by one or more layers of cells, having very deeply staining nuclei. On passing upward to the internal os, little of the normal endometrium is to be made out, almost the entire mucosa being replaced by a new growth. The large and small polypoid outgrowths consist almost entirely of broad trunks of stroma, springing from the sides of which are myriads of well-formed glands. In many places these glands have been cut longitudinally, and can be seen opening directly upon the sides of the outgrowth. The glands, where cut longitudinally, are irregularly tubular in form. In many places they are separated from one another by considerable stroma; at other points they are so closely packed together that little stroma is visible (Fig. 215). One of the chief features is the preservation of the lumina of the glands. The epithelial cells vary from one to several layers in thickness. The cell nuclei are elongate oval, somewhat deeply staining, and remarkably uniform in size. Few, if any, nuclear figures are to be made out; numerous cilia can be demonstrated. At some points, more particularly in the superficial portions of the growth, the epithelium has proliferated to such an extent that the gland cavities have become obliterated, and the nests thus formed bear quite a resemblance to squamous-cell carcinoma. The uterine muscle has not been penetrated by the growth—in fact, at some points there still remains a small amount of normal mucosa separating the growth from muscle.

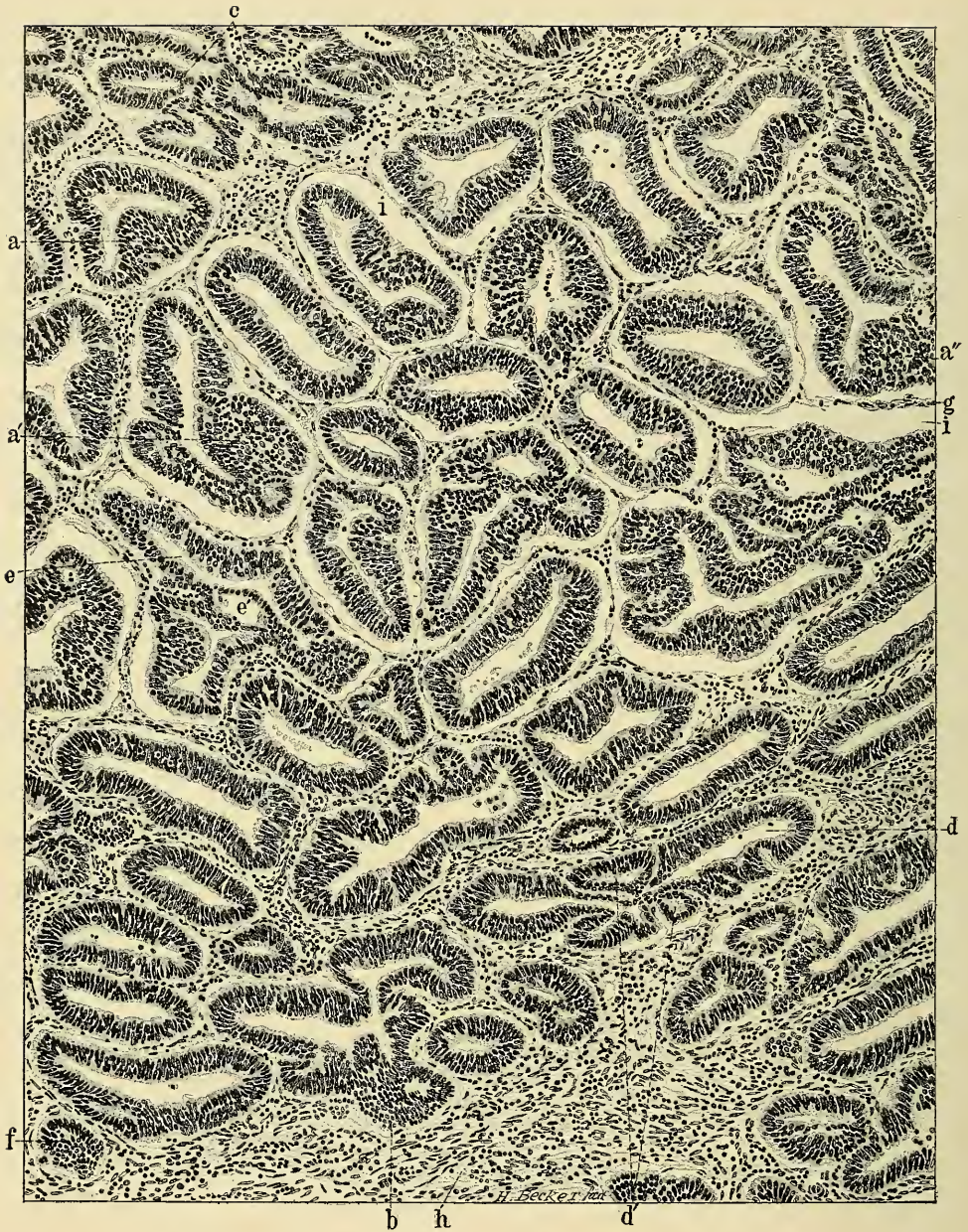

FIG. 215.—ADENO-CARCINOMA OF THE BODY OF THE UTERUS. (130 diameters.)

Gyn.-Path. No. 2,897. The section is from Fig. 213 at point *l*. The gland arrangement is well preserved. The glands are lined by several layers of cylindrical epithelium, and in some places, as at *a*, *a'*, and *a''*, there are localized areas of thickening. The increase in thickness at *b* is apparently due to obliquity of the section. At *e* a gland has become considerably convoluted; while at *d* the convoluation has become more pronounced, and secondary glands (*d'*) have been formed. *e* is a gland somewhat convoluted and containing the secondary gland *e'*. *f* is the edge of a gland. In the upper two thirds of the section the glands are very closely packed, there being just a faint network of stroma (*g*) from which the glands have retracted, leaving clear spaces, as indicated by *i*. The stroma at *h* is rather abundant, and shows considerable small-round-cell infiltration. The great numbers of glands with little stroma are in themselves sufficient to indicate adeno-carcinoma, apart from the supplementary evidence furnished by the great increase in the epithelium and the tendency to the formation of new glands.

Macroscopically, it was noted that some of the polypi were very firm. The consistence, as might have been expected, is due to a marked preponderance of stroma, but even here the growth is well marked. The stroma forming the framework of the polypi consists of spindle-shaped cells having elongate, irregular, and deeply staining nuclei. Many of these on transverse section appear perfectly round, and besides these cells considerable small-round-cell infiltration can be noted. At a few points near the fundus the mucosa is of normal thickness, but here the new growth is also present. It is sharply outlined from the surrounding normal mucosa by staining more faintly and showing a more complicated glandular arrangement (Fig. 214). Some of the glands are considerably dilated. The growth is an adeno-carcinoma.

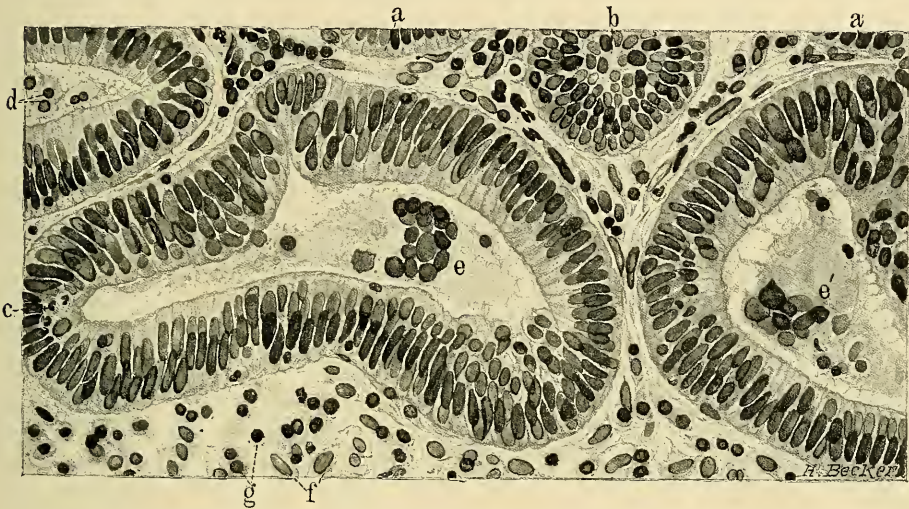


FIG. 216.—GIANT CELLS LYING IN THE GLANDS OF AN ADENO-CARCINOMA OF THE BODY OF THE UTERUS. (420 diameters.)

Gyn.-Path. No. 2,897. Occupying a large portion of the field is a gland lined by two or three layers of epithelial cells, containing oval or elongate-oval, somewhat deeply staining nuclei. Between the cells, at a few points, are polymorphonuclear leucocytes, as seen at *c*, while occupying the gland cavity is a granular material, probably coagulated serum, and an irregular giant cell (*e*), containing about seventeen nuclei, similar in character to those of the gland epithelium. This apparent giant cell may be a cross section of a tuft springing from the under surface of the gland, or may possibly have originated through a coalescence of several desquamated epithelial cells. *e'* is a somewhat similar but partially degenerated giant cell. *d* indicates several small round cells in the gland. *a* and *a* are the edges of glands. *b* is a section through a gland near its base. *f* indicates stroma cells. *g* shows small round cells infiltrating the stroma. From this section alone one would not for a moment suspect carcinoma. The diagnosis in this area was made entirely from the characteristic grouping of the glands.

Macroscopically, the picture is particularly interesting on account of the polypoid condition, and from the fact that so few finger-like processes are visible.

Histologically, the wonderful preservation of the gland type is of interest. The comparative smoothness of the surfaces of many of the polypi is due to the proliferation on the surface of the gland epithelium, which thus forms an almost continuous covering. The growth has been entirely removed.

December 22, 1899. Dr. T. B. Amiss writes me: "The patient looks well, and goes around as much as she ever did before operation." Length of time since operation, about eleven months.

Gyn. No. 2,813

Adeno-carcinoma, probably of the body of the uterus. Extensive involvement of the right broad ligament; attempted abdominal hysterectomy; removal of the appendages on both sides.

D., aged fifty-five; white. Admitted June 1, 1894. Complaint: almost constant pain in the region of the uterus, and occasional hæmorrhages. The patient has been married twelve years, has had no children and no miscarriages. Her menses ceased three years ago. The family history is negative.

Her present illness dates from July, 1893, when she had her first hæmorrhage. Since this time there have been frequent slight hæmorrhages, the last occurring one month ago. Since December she has experienced intense abdominal pain, and has lost considerably in weight. The patient is well-nourished, the mucous membranes are of a good colour, the appetite is good, the bowels are constipated. At times, defecation has been painful. Micturition is painful and burning.

Operation, June 6th. A large amount of friable tissue was curetted away from the uterine cavity; the uterus was then packed with iodoform gauze, and abdominal hysterectomy was attempted. This was, however, abandoned, as the broad ligament on the right side was involved as far as the pelvic walls. The patient was discharged June 30th. Her pain had perceptibly diminished, but the infiltration of the broad ligament had increased.

Gyn.-Path. No. 322. The specimen consists of the appendages from both sides, and of uterine scrapings. Some of the scrapings reach 1 millimetre in diameter, and are grayish in colour. The appendages are covered with many adhesions.

Histological Examination.—The tubes and ovaries on both sides, apart from numerous adhesions, are normal. Along the margin of the scraping the surface epithelium of the uterine mucosa is still preserved, and in the underlying stroma a few glands are seen. Their epithelium is intact. Occupying the stroma of the mucosa, and forming the greater part of the section, are large and small alveoli, almost if not completely filled with cells, having oval, vesicular nuclei, and in frequent instances containing nuclear figures. This newly formed tissue in places shows nuclear fragmentation. On examining the whole specimen carefully with the low power, a distinct glandular arrangement can, here and there, be made out in the alveoli. With the high power this arrangement is not so clear, but in several places it is well marked. Whether this is a squamous-cell carcinoma or an adeno-carcinoma cannot be decided. The exceedingly small amount of stroma and the faint gland-like arrangement certainly arouse a suspicion that it belongs to the latter variety.

Diagnosis.—Probable adeno-carcinoma.

CHAPTER XIV

ADENO-CARCINOMA OF THE BODY OF THE UTERUS (*continued*)

1. Pyometra occurring in adeno-carcinoma of the body of the uterus.
2. Primary adeno-carcinoma of the body of the uterus with hæmatometra and hæmatocolpos, associated with atresia vaginæ senilis.
3. Extension of adeno-carcinoma of the body of the uterus to a myoma.
4. Uterine calculi associated with adeno-carcinoma of the body of the uterus.
5. Carcinoma in one horn of a uterus bicornis.
6. Perforation of the uterus following adeno-carcinoma of the body.
7. Adeno-carcinoma of the vagina secondary to adeno-carcinoma of the body of the uterus.
8. Extension of adeno-carcinoma of the body of the uterus to the larger lymph channels and lymph glands.
9. Cases of adeno-carcinoma of the body of the uterus with extension to the lymph glands.
10. Metastases following adeno-carcinoma of the body of the uterus.
11. Condition of the tubes and ovaries in adeno-carcinoma of the body.
12. Secondary carcinoma of the body of the uterus.

PYOMETRA OCCURRING IN ADENO-CARCINOMA OF THE BODY OF THE UTERUS

FROM the position of the carcinoma it is readily seen that there is not the same tendency to occlusion of the cervical canal as would occur when the neoplasm is situated in the cervix. Hence pyometra is very rarely associated with adeno-carcinoma of the body of the uterus. Should the growth commence near the internal os and spread upward, it is readily seen that the secretions might possibly be dammed back, but the primary site of invasion is rarely so low down. Furthermore, the papillary growth is at times so abundant that the uterine cavity is completely filled, no space being left for the accumulation of fluid.

In Case 2,136 (p. 413) there was a slight amount of pus in the uterus, but the condition resembled that found in connection with a fistulous tract, and could not, strictly speaking, be classed as a pyometra. This is the only example in our series in which pus was found in the uterine cavity.

PRIMARY ADENO-CARCINOMA OF THE BODY OF THE UTERUS WITH HÆMATOMETRA AND HÆMATOCOLPOS, ASSOCIATED WITH ATRESIA VAGINÆ SENILIS

An instance of this very rare condition was reported by Sondheimer* in 1895. A woman, sixty-seven years of age, who had had one child thirty years previously, complained of a hardening in the lower part of the abdomen. This was of six weeks' duration, and was associated with pain on both sides. Vaginal examina-

* Sondheimer, J. *Primäres Corpuscarcinom mit Haematometra und Haematokolpos bei Atresia vaginæ senilis.* *Monatsschr. f. Geburtsh. u. Gynäk.*, 1895, Bd. i, S. 348.

tion was impossible, as the outlet was completely closed; but with the finger in the rectum it was possible to make out that the lower half of the small pelvis was filled by a tense tumour, the under surface of which was convex. Under narcosis the vaginal walls could be separated from one another for a distance of 3 centimetres; on puncture, a dirty, brownish-red, thin fluid escaped, which contained degenerated red blood-corpuscles, fatty detritus, and many large, round, or cylindrical cells, with large glistening nuclei.

On opening the abdomen, the uterus was found to be the size of that of a five-months' pregnancy; the right appendages were enveloped in adhesions. Following puncture of the uterus there was an escape of fluid similar to that obtained from the vagina.

The uterus was opened, and about 3 litres of fluid were removed. The inner surface of the uterus was covered with tumour masses, the largest being the size of a hen's egg. The cervix was also dilated, and the vaginal walls were found studded with similar new growths.

The uterus was amputated, but the patient died. The growth on microscopical examination proved to be an adeno-carcinoma. There were metastases in the right tube near the uterus. No reason could be given for the atresia.

This case is one of interest from a clinical standpoint, for the reason that, prior to operation, a positive diagnosis could not be made.

EXTENSION OF ADENO-CARCINOMA OF THE BODY OF THE UTERUS TO A MYOMA

To say that a myoma may undergo carcinomatous degeneration involves a contradiction of terms, since a myoma consists essentially of non-striped muscle fibre, while, for the development of a carcinoma, epithelial elements are requisite. In very rare instances, however, a myoma may have scattered through it glands many of which conform to the type of those found in the normal uterine tissue. Only under this one condition is it possible for a myoma to become primarily carcinomatous. Nevertheless, in spite of a rigid search, I have failed to find among our own cases a single instance in which an adeno-myoma has become carcinomatous.

Myomata are very common, and it is hardly surprising that these tumours and carcinoma should often be found in the same uterus. But, although the two growths are frequently associated, it is only in very rare instances that the myoma is found to be invaded by the epithelial growth. The probable explanation for this lies in the extreme density of the myoma in comparison with the softness and succulence of the uterine muscle. In our entire series of cases, including new growths both of the cervix and of the body, only twice was a myoma found to have been invaded by the carcinoma. In Case 2,634 (p. 431) the carcinomatous process was far advanced, and there were metastases in distant organs. Lying in the uterine cavity was a pedunculated myoma the size of a hen's egg. The mucosa covering it offered a suspicious appearance, and on histological examination (Fig. 228, p. 433) the myoma, the greater part of which had undergone hyaline degeneration, showed abundant carcinomatous involvement. The growth was

precisely similar to that occupying the uterine muscle, and the involvement had been by continuity.

A somewhat similar case has been reported by John Williams* (Case XXXI). A patient, aged forty-eight, was curetted, and a vaginal hysterectomy was then performed. The entire uterine cavity was filled with a carcinomatous growth, and a myoma, situated in the posterior wall, had been invaded by the carcinoma.

UTERINE CALCULI ASSOCIATED WITH ADENO-CARCINOMA OF THE BODY OF THE UTERUS

Our attention was first directed to this subject by a study of Gyn.-Path. No. 161. In this case, during removal of carcinomatous tissue from the uterine cavity a calculus was brought away. On referring to Fig. 217 (p. 412) this is seen in the form of a hollow hemisphere presenting externally a rough irregular surface. Chemically, the calculus was composed of calcium carbonate and calcium phosphate. I advanced the hypothesis that there had existed a partially calcified myoma, which during the breaking down of the carcinoma had also shared in the degenerative process, so that merely the shell of the calcareous material had been left. A subsequent reference to the literature brought to light a similar case reported by Thorn,† who has made a statistical study of uterine calculi from the time of Hippocrates down. Thorn's patient was fifty-five years of age. Six years after the menopause she began to complain of uterine hæmorrhages. Six months later she experienced labour-like pains, which were soon followed by a profuse yellowish, bloody discharge. The uterus was the size of that of a three months' pregnancy. After dilatation of the cervix, a calculus nearly the size of a man's fist was removed. It was characterized by a coral-like formation, and contained in the clefts a network of fibres. The discharge ceased, but the hæmorrhages returned in two months, and, from the examination of scrapings, carcinoma was diagnosed. On histological examination the stone was found to resemble a calcified myoma; indeed, Thorn was of the opinion that it was nothing more than a myoma that had become calcified.

Gyn.-Path. No. 161

Advanced adeno-carcinoma of the body of the uterus. Curettage with removal of a calculus from the uterine cavity (Fig. 217).

The specimen consists of uterine scrapings, together with a concretion removed from the uterine cavity. The concretion is about 1.5 centimetres in breadth. It somewhat resembles the half of a hollow sphere. Its outer surface is rough and irregular, and at several points presents a mulberry-like appearance. The inner and concave surface is covered by a soft, friable tissue. A small chip of the concretion was examined by Dr. Welch, who failed to find any trace of

* Williams, J. *On Cancer of the Uterus; being the Harveian Lectures for 1886*, 119 pp., 18 pl., 8vo, London, 1888.

† Thorn, J. *Zur Kasuistik der Uterussteine. Zeitschr. f. Geburtsh. u. Gynäk.*, 1894, Bd. xxviii, S. 75.

bone corpuscles. Chemically, Dr. Abel showed that it was composed of Ca_2CO_3 and $\text{Ca}_3(\text{PO}_4)_2$.

Histological Examination.—The uterine scrapings consist of many glands, some of which are exceedingly small, while others are quite large. They are lined by one layer of cylindrical epithelium, but in many places the epithe-

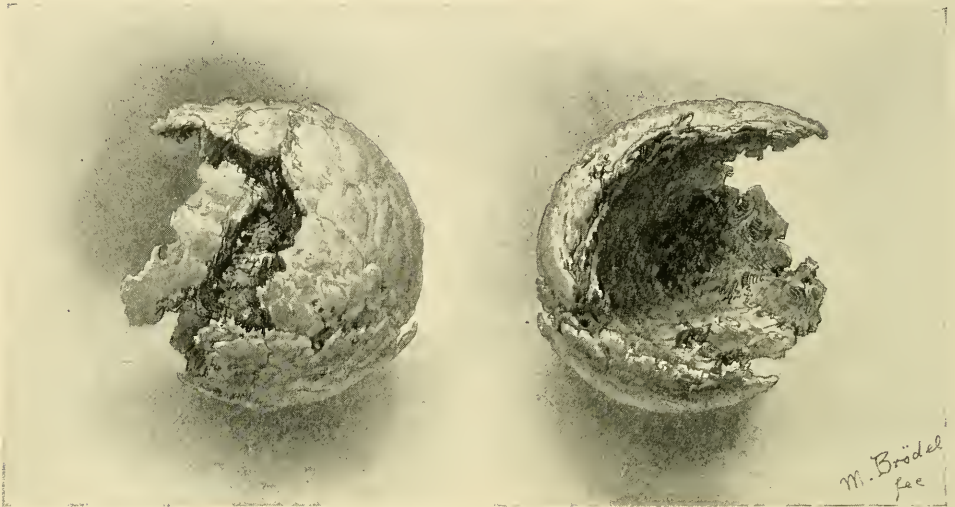


FIG. 217.—CALCULUS REMOVED FROM THE UTERINE CAVITY DURING CURETTAGE. (2 diameters.)

Gyn.-Path. No. 161. To the left is seen the convex, slightly lamellated surface of the calculus, which shows a broad, shallow depression near its left margin, and ragged edges. To the right is the concave inner surface, to which necrotic tissue was intimately adherent.

lium has proliferated, and is forming new glands. Some of the newly formed epithelial cells are paler, and considerably larger than the others. In the specimen are several masses of large cells. The picture is one of adeno-carcinoma. It is rather difficult to explain the origin of the calcareous concretion. The most plausible theory is that it is the remains of a partially calcified myoma. Of this, however, no proof could be adduced, as the uterus was not removed, nor did the patient come to autopsy.

CARCINOMA IN ONE HORN OF A UTERUS BICORNIS

This condition is naturally rare, since a bicornate uterus is not very frequently met with. Vineberg* recently reported such a case. The patient was fifty-five years old; she had had five children, and had ceased to menstruate at forty-nine. She had been complaining of profuse hæmorrhages, was very anæmic, and had lost considerable flesh. The uterus seemed half as large again as normal, and to the left side of it there appeared to be a small sensitive mass. On opening the abdomen, two uteri with a common cervix were found. The right horn measured

* Vineberg, H. N. *Carcinoma in one Horn of a Uterus Bicornis*. *Amer. Gyn. and Obstet. Journal*, 1897, vol. x, p. 465.

9.5 by 12 centimetres; the greater part of its cavity was occupied by a ragged, irregular growth, which had involved chiefly the posterior and lateral walls, and which on microscopical examination proved to be an adeno-carcinoma. To each horn was attached the normal tube and ovary which properly belonged to that side of the uterus.

PERFORATION OF THE UTERUS FOLLOWING ADENO-CARCINOMA OF THE BODY

This is an infrequent occurrence, since extension usually takes place in a lateral direction. In those cases, however, in which the uterus has, prior to the development of the carcinoma, become densely adherent to the rectum or to a loop of small intestine, it is easily seen how the gut might be involved by direct continuity. In Case No. XXVIII, reported by John Williams, there was a fistulous opening between the intestine and uterus. At autopsy, several nodules were seen on the posterior surface of the uterus, while on the anterior aspect appeared a single large tumour, to which the intestines were attached. A direct communication existed between the uterus and the gut at this point. The opening was the size of a man's thumb.

Our Case 2,136, which came to autopsy, revealed a very instructive picture. As will be noted, the disease was far advanced, the uterus being represented by a sloughing necrotic mass. At one point there was a direct communication between the uterine cavity and a large collection of pus occupying the left side of the abdomen.

Gyn. No. 2,136

Autopsy No. 446. August 18, 1893. Adeno-carcinoma of the body of the uterus. Pyometra. Perforation through the uterine wall. Abdominal and supraphrenic abscess. Fibrinopurulent peritonitis. Metastases in the pelvic lymph glands and liver. General arteriosclerosis. Brown atrophy of the heart. White infarctions in the spleen. Chronic diffuse nephritis. Metastatic abscesses in the kidney.

An abstract from the autopsy report is as follows: The body is 170 centimetres long, and is much emaciated. The surface is pale; the superficial veins are dilated. The muscles are atrophied and red. On opening the peritoneal cavity, between 3 and 4 litres of a greenish-yellow, stinking pus escaped. This for the most part has occupied the left side of the abdomen, the right side being walled off. The omentum is everywhere adherent, especially over the enlarged uterus. At one point there is an ulceration in the omentum, through which there is direct communication with the uterine cavity. The diaphragm is pushed upward, and the liver downward to the right; its left lobe is covered with a pyogenic membrane. The intestines are everywhere loosely bound to one another by a fibrinous exudate; in numerous places the exudate is purulent. Portions of the right side of the abdomen are free from the inflammatory process, and the right lobe of the liver is smooth and glistening. The vulva and vagina show nothing abnormal; the cervix admits the index finger. The uterus

is 9 centimetres in length, and measures 11 centimetres from side to side. Projecting into its cavity everywhere are large, sloughing tumour masses; the whole inner surface of the cavity is covered with pus and necrotic tissue. The tumour growth extends deep into the muscle in several places near the fundus, having penetrated completely through the walls and appearing on the peritoneal surface. A little to the left of the median line the necrotic and ulcerative process has extended through the neoplastic growth to the peritoneal surface, forming a channel large enough to admit an ordinary lead pencil. This communicates with the opening in the omentum, and has been the starting point of the abscess before described. The ovaries and tubes on both sides are embedded in masses of adhesions. The lymph glands are filled with tumour metastases, some of which have attained the size of a walnut.

In the right lobe of the liver are two metastatic nodules, one as large as a cherry, the other being of the size of a pea. Both are sharply circumscribed, grayish white in colour; the larger shows opaque, yellowish-white, necrotic patches in its centre.

On histological examination the growth in the body of the uterus is found to be an adeno-carcinoma, and the metastases in the liver present exactly the same appearance. Coverslips from the pus in the large abscess show many streptococci, and a few examples of a rather short, thick bacillus. The latter on cultivation prove to be *Bacillus pyocyaneus*.

ADENO-CARCINOMA OF THE VAGINA SECONDARY TO ADENO-CARCINOMA OF THE BODY OF THE UTERUS

Under this head will be included here only cases in which this condition had occurred previous to any operation. Those instances in which the appearance of the secondary growth followed a vaginal hysterectomy will be considered separately in Chapter XXVII. Such metastases have rarely been reported. Fischer,* however, cites a case of this nature, in which the body of the uterus was the seat of an adeno-carcinoma, while scattered throughout the vagina were numerous carcinomatous metastases. Only one similar case has come under our notice. As will be seen from the history, the patient came to the hospital to have a nodule removed from the vagina. This on subsequent histological examination proved to be an adeno-carcinoma. The patient was lost sight of, but returned a year later with an inoperable carcinoma of the body of the uterus. The disease had evidently been primary in the uterus, but, owing to the lack of symptoms, had been entirely overlooked during her first stay in the hospital.

The extension of the growth to the vagina is an unexpected complication, inasmuch as the lymphatics from the uterus do not pass toward the vagina. There are two ways in which this secondary involvement may occur: the first, by implantation, the carcinoma cells from the body finding their way down

* Fischer, E. *Zur Entstehungsweise secundärer Scheidenkrebsse bei primärem Gebärmutterkrebs.* *Zeitschr. f. Geburtsh. u. Gynäk.*, 1891, Bd. xxi, S. 185.

through the cervix, clinging to the vagina and there developing; the second, through a backward flow of the lymph (*rückläufige Metastase*). Fischer inclined to the implantation view, but I think it much more probable that in both the cases cited the extension had taken place along the lymphatics, as in neither was there evidence of any injury to the vagina, which would have given the cancer cells a satisfactory location for development; furthermore, it is usually the degenerate and necrotic cells that are cast off, and not the living, active ones. It is not in my province to speak more fully on this backward flow of lymph. A clear insight into the subject can be obtained from the articles by von Recklinghausen* and K. Vierth.†

Gyn. No. 3,955

Adeno-carcinoma of the posterior vaginal wall (Figs. 218 and 219). Admission ten months later with advanced adeno-carcinoma of the body of the uterus, and extension of the growth in the right broad ligament as far as the pelvic wall. The iliac glands on the left side were about 2 centimetres in diameter, and the lumbar glands as large as almonds. No histological examination of these was made, as the glands were not removed. Hysterectomy impossible. Histological picture showing new glands developing in the wall of a gland (Fig. 220). Drawing under the high power, representing a typical carcinomatous area (Fig. 221). In this case the adeno-carcinoma of the uterus was evidently present when the patient was first admitted, and the neoplasm in the vagina was in all probability secondary to that of the body.

J. S., aged forty-six. Admitted November 13, 1895. Complaint: pain in lower right abdomen; vaginal discharge.

The patient has been married twenty-four years; has had four children, but no miscarriages. Her menses began at sixteen, were always regular, and unaccompanied by pain. The last two periods were five weeks apart. For the past three or four years the flow has been abundant and clotted. For about the same period there has been an abundant leucorrhœal discharge, which at times has been offensive, irritating, and blood-stained; occasionally small clots of blood have been passed.

Family History.—Tuberculosis is marked on the paternal side. One brother died of a tumour of the bowels.

Present Condition.—One year after the birth of her second child, sixteen years ago, she first noticed a peculiar sensation in the lower part of the abdomen, as if the contents were falling out; soon after, the uterus appeared externally. After the prolapsus had existed for four years, the patient commenced

* Von Recklinghausen. *Ueber die venöse Embolie und den retrograden Transport in den Venen und in den Lymphgefäßen.* *Virchow's Archiv*, 1885, Bd. c. S. 503.

† Vierth, K. *Ueber rückläufige Metastase in den Lymphbahnen.* *Beiträge z. path. Anat. u. allgem. Path.*, Jena, 1895, Bd. xviii, S. 515-533.

to wear a support, which has kept the uterus in place until the present time. Micturition is accompanied by bearing-down pains.

General Condition.—The patient is thin and has lost flesh, but her lips and mucous membranes are of a good colour. The appetite is fair, the bowels are constipated.

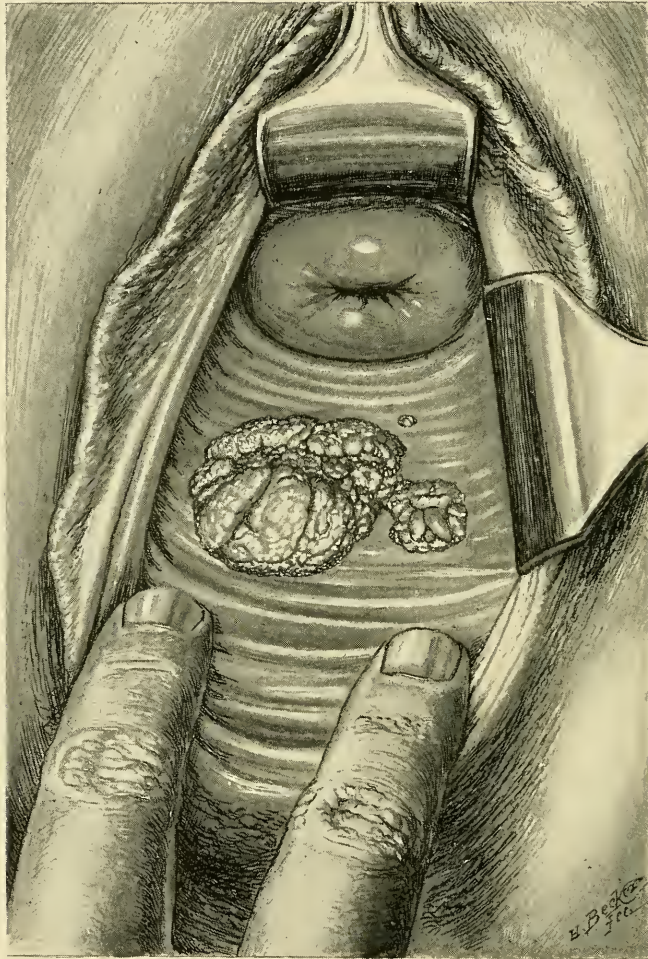


FIG. 218.—ADENO-CARCINOMA OF THE POSTERIOR VAGINAL WALL SECONDARY TO ADENO-CARCINOMA OF THE BODY OF THE UTERUS. (Natural size.)

Gyn.-Path. Nos. 969 and 1,311. Situated on the posterior vaginal wall, just below the cervix, is a sharply circumscribed, irregular, and finely lobulated outgrowth. To the right of this, and attached to it, is seen a similar but smaller excrescence, while above these two masses is a minute tumour of a like character. For the thickness of the larger mass, see Fig. 219. (After W. W. RUSSELL.)

Vaginal Examination.—The outlet is much relaxed. On the posterior vaginal wall, 2 centimetres from the cervix, is a fungating mass which seems to be perfectly circumscribed (Figs. 218 and 219). The cervix is normal, and the uterus, which is in ante-

position, is of the usual size and freely movable. The appendages are apparently normal. On rectal examination, no induration of the bowel can be detected.

Operation, November 14, 1895. The growth in the posterior wall was excised along with a good margin of normal vaginal mucosa. The wound was closed with catgut sutures. The patient was discharged on December 15th, the wound in the vagina having completely healed.

Gyn.-Path. No. 969. The specimen consists of a portion of the posterior vaginal wall, measuring 5×4 centimetres. The outer margin is smooth, and resembles normal vaginal mucosa; the greater part of the surface, however, is uneven, and is the seat of a new growth. In some places this presents a papillary arrangement, extending from 2 to 5 millimetres above the ordinary level of the mucosa. At other points are roundish, smooth, conglomerate masses, which coalesce to form a nodule about 1 centimetre long, 8 millimetres broad, and about 3 millimetres in thickness. The most prominent part of the growth consists of a slightly lobulated nodule, measuring 2.5×2 centimetres, which projects 2 centimetres from the surface of the mucosa. The line of junction between the vaginal mucosa and the growth is irregular, but sharply defined. On section the growth appears to be very superficial.

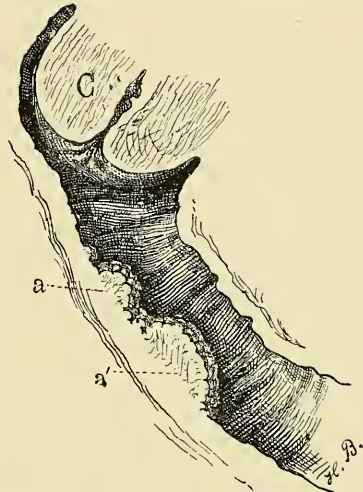


FIG. 219.—ADENO-CARCINOMA OF THE VAGINA SECONDARY TO ADENO-CARCINOMA OF THE BODY OF THE UTERUS.

Gyn.-Path. Nos. 969 and 1,311. This drawing represents Fig. 218 on longitudinal section. *C* is the normal cervix. *a* and *a'* represent a section through the largest tumour mass. The deep depression between *a* and *a'* corresponds to that seen in Fig. 218. The growth in its thickest portion projects fully 6 or 7 millimetres from the surface, and is intimately attached to the vaginal mucosa. This secondary growth appears to have been an implantation on the surface of the mucosa, as there is little or no infiltration of the underlying tissue. (After W. W. RUSSELL.)

The stroma, where present, consists of spindle-shaped cells, and shows much small-round-cell infiltration. The epithelium has in many places proliferated so as to form nests. The underlying tissue shows only slight alteration, but along the advancing margin there is marked small-round-cell infiltration. The growth is an adeno-carcinoma.

The patient was readmitted August 31, 1896, complaining of pain in the lower abdomen radiating to the right thigh and back. Her general condition was much improved after the first operation, although since that time she has

had very severe and almost constant pain, commencing in the median line in the lower abdomen, extending to the right side of the pelvis, and thence to the thigh

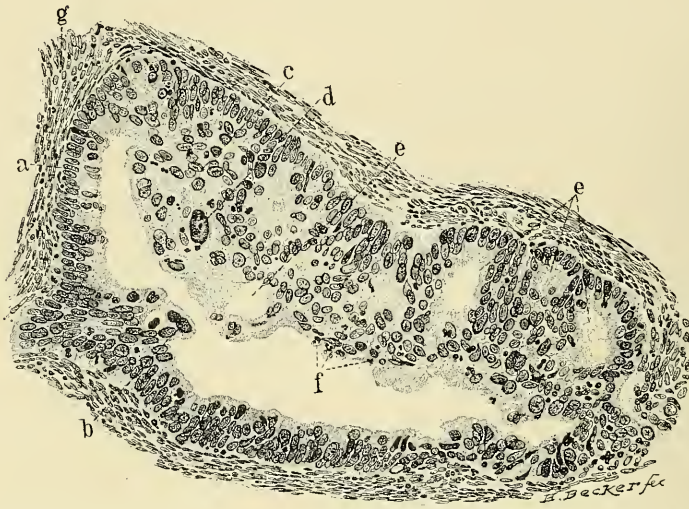

FIG. 220.—ATYPICAL PROLIFERATION OF THE GLAND EPITHELIUM WITH FORMATION OF NEW GLANDS IN ADENO-CARCINOMA OF THE BODY OF THE UTERUS. (185 diameters.)

Gyn.-Path. No. 1,311. At *a* the gland epithelium is practically normal, but at *b* there is marked cell proliferation, and one of the cells contains two large, deeply staining nuclei. The increase of cells at *e* is marked. The nuclei are larger in size, notably at *d*, where there is a very large, irregular, and deeply staining nucleus. The cell proliferation has been accompanied by a new gland formation, as seen at points indicated by *e*. In numerous places polymorphonuclear leucocytes have wandered out between the epithelial cells, as indicated by *f*. *g* is the stroma, showing no alteration.

The marked proliferation of the epithelium with the new gland formation and the deeply staining nuclei (*b*, *d*) leave no doubt as to the malignant character of the growth. Even if this were the only suspicious area in the scraping, one would not for a moment hesitate in diagnosing it as an adeno-carcinoma.

and hip, later involving the back. These pains are so severe that the patient has to lie down. She has a constant but not excessive vaginal discharge. This is not offensive in odour, is at times blood-tinged, but never resembles a hæmorrhage. The menstrual periods, however, last two weeks, are very free, and the blood is clotted. The bowels are constipated, and defecation is usually painful. The patient has lost flesh, is very thin, weak, anæmic, and has a poor appetite.

Vaginal Examination.—The outlet is markedly relaxed; the cervix lies directly in the axis; the os is patulous, easily admitting the index finger. Its

FIG. 221.—THE MANNER IN WHICH NEW GLANDS ARE FREQUENTLY FORMED IN ADENO-CARCINOMA OF THE BODY OF THE UTERUS. (140 diameters.)

Gyn.-Path. No. 1,311. The drawing is from a scraping. The entire picture consists of carcinomatous tissue. The glands *a*, *a'*, and *a''* have well preserved their forms, and are lined by about two layers of epithelium. *b* shows the edge of a gland similar to *a*. At points indicated by *c*, the gland epithelium is only one layer in thickness, but stains faintly. At *c'* the epithelium is already several layers in thickness, and the cells and their nuclei are swollen, instantly suggesting the earliest gland changes, as seen in Fig. 187 (p. 369) and Fig. 214 (p. 404). The gland *d*, *d* is somewhat irregular, but is lined by two orderly arranged layers of cylindrical epithelium; projecting into it is the stem *e*. The small amount of stroma, the regularly arranged epithelium, and the ingrowth remind one strongly of pictures frequently met with in papillo-cystoma of the ovary. The gland *f*, in its upper portion, closely resembles the gland *a*, but in its lower half the epithelial

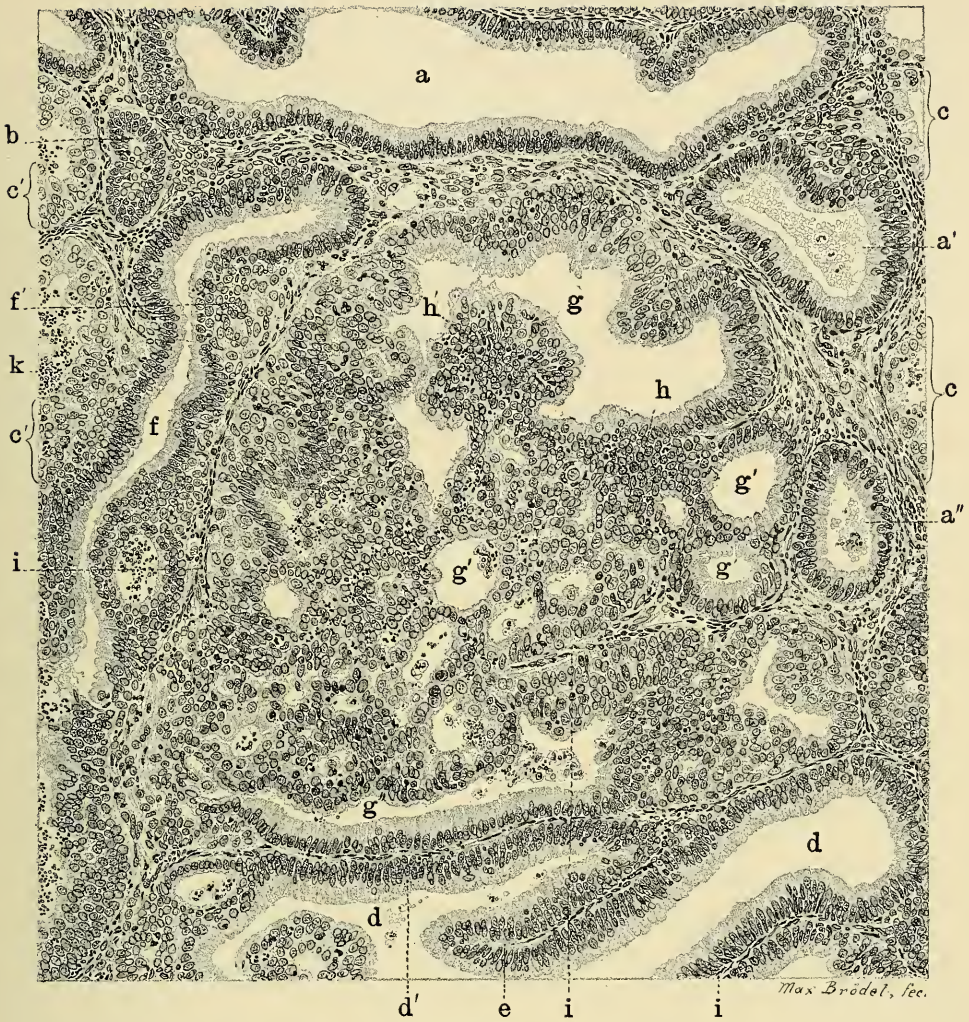

FIG. 221.

lining becomes many layers in thickness, and even at *f'* the cells are fully nine layers thick. The gland *g*, with its many ramifications, occupies the central portion of the field. Above, it is lined by from two to five layers of epithelium, and on the left side by many layers. At *h* there is also much thickening, while projecting into the small cavity remaining is a knob-like ingrowth (*h'*). Scattered throughout the proliferated epithelium, which forms almost a homogeneous mass in the lower two thirds of the gland *g*, are the secondary glands *g'* and *g''*, as well as numerous other smaller and less distinct gland spaces. In time the epithelium would undoubtedly fill all these gland spaces, and we should then have a homogeneous mass of cells. The stroma in the upper part of the field is fairly abundant, and consists of cells containing spindle-shaped nuclei, but at the points indicated by *i* there is barely enough stroma to support the growth. The nuclei of the epithelial cells throughout the growth are very uniform, but in the central portion are a few that are slightly enlarged and stain deeply. Scattered between the epithelial cells and partially filling some of the gland spaces are polymorphonuclear leucocytes. These are especially abundant at *k*.

From the glands *a*, *a'*, and *a''* we could gain little information. The glands indicated by *c'* show early carcinomatous changes, and would naturally suggest examination of more tissue. The gland *d* is also indicative of an abnormal process, which bears a slight resemblance to gland hypertrophy on account of the faint amount of stroma. But on referring to Fig. 257 (p. 493) and Fig. 263 (p. 502), we find that in gland hypertrophy the epithelium is only one layer in thickness.

The central portion, consisting of the gland (*g*) with its marked cell proliferation, new gland formation, and a few enlarged and deeply staining nuclei, leaves no doubt that the growth is an adeno-carcinoma.

edges are slightly indurated and everted. The body of the uterus is enlarged, soft, and rests on the rectum. The examination occasions no hæmorrhage.

Operation, September 5th. Exploratory cœliotomy; dilatation and curettage. On opening the abdomen the uterus is found to be the size of that of a three months' pregnancy. It is hard, and has a somewhat irregular outline. The left tube is normal; in the left ovary are seen the walls of a cyst, which was ruptured by vaginal examination just prior to the operation. The whole broad ligament on the right side, from the uterus to the pelvic wall, is infiltrated with the new growth; the right tube at the uterine extremity is greatly thickened. It can be traced for 3 centimetres, and then is lost in the mass. On the left side two of the iliac glands are about 2 centimetres in diameter, and the lumbar glands are as large as almonds. The right ovary is not involved in the growth, but the small intestines are adherent to the indurated mass on the right side. There was no evidence of a return of the vaginal growth.

As it was impossible to remove the uterus, the abdomen was closed. The cervix was then dilated, and a considerable amount of friable tissue was removed. The patient was discharged on October 9th.

Gyn.-Path. No. 1,311. The specimen consists of uterine scrapings.

Histological Examination.—The tissues vary greatly in type. In some places the surface is comparatively smooth, the epithelium being intact, and the glands immediately beneath unaltered. At other points an irregular papillary mass is encountered, cut transversely, and lying free. In other sections the glands show a markedly convoluted arrangement; here the epithelium is only one layer in thickness and is normal. The stroma between the glands is, however, very scant in amount and consists of spindle-shaped cells. Still other sections show that the epithelium on the surface of some of the papillary masses has proliferated, forming new glands, while the epithelium of the glands in the depth has so increased in amount that the lumen has become partially filled with cells (Fig. 220). At such points the cells are swollen and contain nuclei three or four times as large as those of the cylindrical epithelium. These also stain more intensely. Such an area is best described as a large mass of cells somewhat closely packed together and divided off into smaller groups by a branching network of connective tissue, in which are supported delicate capillaries.

In some places most instructive pictures are seen. Thus in Fig. 221 the epithelium forms a large sea of cells with practically no stroma; but even here a definite gland-like arrangement is at many points demonstrable. The case is one of undoubted adeno-carcinoma of the body of the uterus.

EXTENSION OF ADENO-CARCINOMA OF THE BODY OF THE UTERUS TO THE LARGER LYMPH CHANNELS AND LYMPHATIC GLANDS

From the careful and exhaustive work of Poirier* we have gained an insight into the distribution of the various lymph channels, their collecting ducts, and the glands to which they pass (Fig. 9, p. 15). The lymphatics of the body and of the fundus approach the surface of the organ, converge, and gradually unite to form two, and occasionally three, large channels on either side. These vary from 1 to 2 millimetres in diameter, pass outward along the upper surface of the broad ligament by the side of the utero-ovarian artery, and thence upward to the lumbar glands. It will thus be seen that after leaving the uterus they run between the tube and ovary. The lumbar glands, which receive these lymphatics, are situated on a level with the lower extremity of the kidney, and lie in front of and to the sides of the vena cava and aorta. The lymphatics from the uterine horns pass down along the round ligaments to the inguinal glands, while on either side of the uterus is a large lymph channel providing free anastomosis between the body and cervix.

Poirier based these data on a study of several hundred cases. The line of extension of the carcinoma will be seen to be along the paths indicated.

In only one of our cases, in which an operation was feasible, was there any evidence of glandular involvement.

In many autopsy records a note is made that the glands are involved by the carcinomatous process, but in the majority of these there is no mention of the microscopical examination. All such cases, therefore, are of little value, since Wagner† has pointed out that the lymph glands in carcinoma frequently show marked enlargement, and are hard and firm, but nevertheless, on microscopical examination, no evidence of carcinoma can be demonstrated, the enlargement and induration being due to a recent and abundant increase in the connective-tissue elements of the gland. We have not infrequently noticed such changes, the stroma cells being increased and the endothelium of the blood capillaries thickened. Drs. Bloodgood and Cone, of the surgical staff of the Johns Hopkins Hospital, have made a systematic study of the axillary glands in breast cases, and have shown that many of the glands previously thought to be carcinomatous contain no epithelial elements, but that their increase in size and density is due to the connective-tissue increase.

Fig. 222, published by Russell,‡ demonstrates most beautifully the extension of the carcinoma along the lymphatics between the tube and ovary on their way to the lumbar glands. Three distinct nodules, averaging 5 millimetres in diameter, can be seen. On looking at the primary tumour, it will be noted that the

* Poirier, P. *Lymphatiques des organes génitaux de la femme*. Paris, 1890.

† Wagner, Ernst. *Der Gebärmutterkrebs. Eine pathologisch-anatomische Monographie*, vi, 169 pp., 2 Tafeln, 8vo, Leipzig, 1858.

‡ Russell, William W. *The Operative Significance of Metastases and Post-operative Recurrences in Carcinoma of the Uterus*. *Am. J. Obst.*, 1896, vol. xxxiv, p. 851.

growth has extended to the uterine horns, and that the left round ligament contains a carcinomatous nodule. No note was made as to whether the lumbar or inguinal glands were enlarged.

It may be safely said that in nearly all the operable cases of adeno-carcinoma of the body no glandular involvement has taken place. Winter's* cases fully support this view. In forty-four autopsies on patients dying of carcinoma, in whom the disease was still confined to the uterus, only two showed glandular involvement. In Case I—cancer of the cervix—the iliac glands on both sides were carcinomatous; in Case II—a carcinoma of the body—the glands along the aorta were implicated.

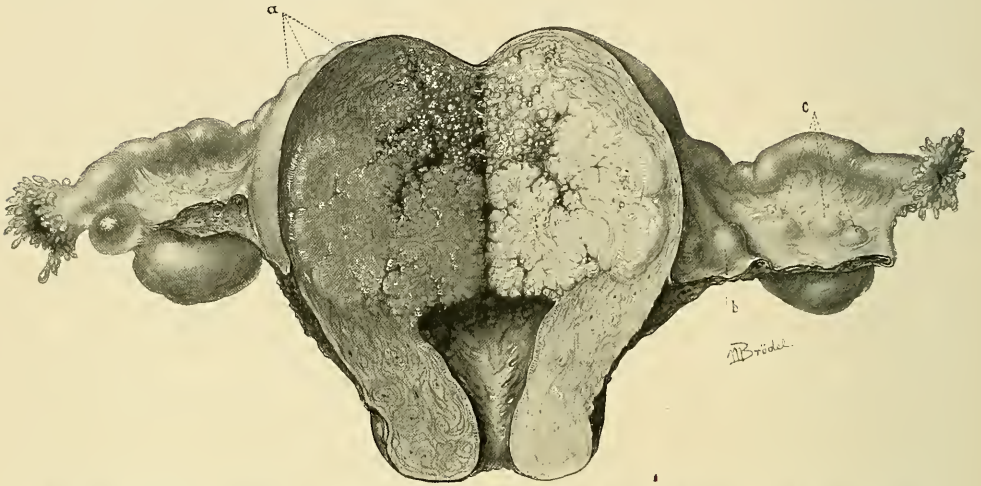


FIG. 222.—ADENO-CARCINOMA OF THE BODY OF THE UTERUS WITH EXTENSION TO THE LEFT ROUND LIGAMENT. ($\frac{5}{8}$ natural size.)

The uterus was nearly twice its normal size. The cervix and lower part of the body present the usual appearance, but the upper half of the body is occupied by a friable-looking growth which has involved the entire thickness of the uterine walls (*a*). In the left round ligament is a definite nodule (*b*), while between the left tube and ovary, and following the course of the lymph channels from the body of the uterus, are three small, oval, carcinomatous nodules (*c*). The appendages on both sides appear to be normal. (After W. W. RUSSELL.)

Although Winter does not say in how many of these cases the primary growth was in the cervix and in how many it was in the body, the results so obtained, even though not thoroughly explicit, are sufficient to show that glandular involvement is a very late complication.

It is rather astonishing that this glandular involvement occurs so late, and the fact certainly calls for an explanation. In all varieties of cancer of the uterus the epithelial cells are usually large, and it is quite probable that they cannot enter the lymph radicles. Accordingly, the lymphatics will not be involved until the growth has extended far laterally, and eaten into a large lymph channel. This view is held by Lubarsch,† and would seem to be satisfactory.

* Winter, G. *Ueber die Recidive des Uteruskrebses, insbesondere über Imprecidive.* *Zeitschr. f. Geburtsh. u. Gynäk.*, 1893, Bd. xxvii, S. 101.

† Lubarsch, O. *Ergebnisse der allg. Path. u. s. w.* Lubarsch u. Ostertag, Wiesbaden, 1895.

In only one of our operable cases of adeno-carcinoma of the body were the glands, so far as we know, involved. In case Gyn-Path. No. 1,412 (p. 424) the growth had evidently commenced near the internal os, and extended both upward and downward; hence it was only natural that the iliac glands should be involved, while the lumbar glands were apparently not implicated. At operation the iliac glands on both sides were slightly enlarged, averaging 1 by 0.5 centimetre. Histological examination showed that they contained abundant secondary growths. The epithelial elements had a typical glandular arrangement (Fig. 224, p. 427), but in some places the cells had so proliferated that the gland lumen was obliterated. Five months later, when it was found necessary to open the abdomen for another purpose, not the slightest trace of any enlarged glands could be made out.

In Case 3,955 (p. 415), in which an exploratory section was performed, the growth was too far advanced to admit of any radical operation. On the left side two iliac glands had reached 2 centimetres in diameter, and the lumbar glands were as large as almonds. No histological examination of these was made, as it was not deemed advisable to remove them, since the complete operation could not be performed.

At autopsy on Case 2,136 (p. 413) the carcinomatous process was widespread, and the iliac glands were implicated, one being about 4 centimetres in diameter.

Case 2,634 (p. 431) at autopsy showed a remarkable lymphatic involvement. Not only were the inguinal, pericardial, and bronchial glands invaded, but also those of the neck and those around the liver. No mention of the iliac glands is made, but they also were without doubt involved. On histological examination, even in the glands of the neck (see Fig. 229, p. 434), the type of the primary growth is perfectly preserved.

In Case 6,439 (p. 463) various organs contained secondary growths, and, as might have been expected, metastases appeared in the lymph glands.

From the foregoing we see that in only one operable case was there any evidence of glandular involvement, and that in this case, five months after removal of the uterus and glands, a digital and ocular examination of the abdominal cavity revealed no evidence of a return of the growth. It is to be hoped that from a careful routine examination of the glands we may soon learn in what percentage of operable cases they are involved.

Involvement of the Inguinal Glands.—These are rarely invaded by the new growth, and then only when the process has extended to the uterine horn. They become enlarged, and are at first firm and hard, but may soften and eventually break down. On cutting into one of the firm glands, the gland substance proper is usually easily distinguished from the yellowish white, glistening growth. On histological examination the carcinoma is seen to preserve the mother type, the glandular arrangement still being visible.

Carcinoma of the Bronchial Glands.—This is very rare, and is only to be expected if there be general glandular involvement. The gross and microscopical changes are precisely the same as those noted in the inguinal glands, and illustrated in Case 2,634 (p. 431).

Adeno-carcinoma of the Glands of the Neck.—This is a most unlooked-for extension of the growth, and is only likely to occur in cases of general lymphatic involvement. The macroscopical picture is similar to that found in the lumbar or other glands. Microscopically, as seen in Fig. 229 (p. 434), the mother type is preserved, and in nearly every portion it is still possible to make out the gland arrangement. On examining the section closely, the carcinomatous growth is found principally in the stroma of the gland, and in close proximity to the blood-vessels.

Cases of Adeno-carcinoma of the Body of the Uterus, with Extension to the Lymph Glands

Gyn.-Path. Nos. 1,412–1,414. Adeno-carcinoma of the body of the uterus commencing near the internal os (Fig. 223). Extension to the iliac lymph glands (Fig. 224). Abdominal hysterectomy; subsequent uretero-vaginal fistula on the right side; anastomosis of the left ureter into the bladder on the supposition that the fistula was on this side; lack of union, with escape of urine into the pelvis. Critical condition of the patient. Puncture of the vaginal vault to allow escape of urine from Douglas's cul-de-sac. As a result of the second operation both ureters now formed fistulous openings into the vagina. Plastic operation, the portion of the vaginal vault containing the fistulous openings being turned into the bladder, with a perfect result (Figs. 225 and 226). Patient well, two years and nine months after the operation.

P., aged fifty-three. Admitted to Dr. Kelly's sanatorium November 24, 1896.

The patient has been married twenty-one years, and has had two children. With the second child she had placenta prævia, and it was nearly a year before she regained her strength after the severe hæmorrhage. Her menses commenced at thirteen, were free, without pain, and lasted four or five days. They were regular until her forty-ninth year, when the menopause came on. In 1894 a bloody discharge was noticed; this has gradually increased in amount until the present time.

Examination of a piece of the cervix showed it to be carcinomatous.

Gyn.-Path. No. 1,412. November 25, 1896.

Operation: Excision of vaginal portion of the cervix, dilatation, and curettage. The portion of the cervix measures 3.2 centimetres in breadth and 2.5 centimetres in its antero-posterior diameter (Fig. 223). The external os is 2.2 centimetres in width. The vaginal portion of the cervix has a smooth, glistening mucosa; that lining the cervical canal, however, is redundant, deep red in colour, and on careful examination is seen to present a granular or fibrillated appearance. Projecting into the canal is a small nodule, about 6 millimetres in diameter; this presents a finely papillomatous appearance. The cervical tissue is indurated, and on examination of the cut surface is found to be invaded by the new growth.

On histological examination the growth is seen to consist of large, irregularly branching alveoli, formed by a conglomeration of rapidly proliferating

glands. The alveoli are lined by one or more layers of cylindrical epithelium, which not infrequently fill the spaces completely. Nuclear figures are abundant, and are often perfectly symmetrical; they may, however, be irregular, many of the

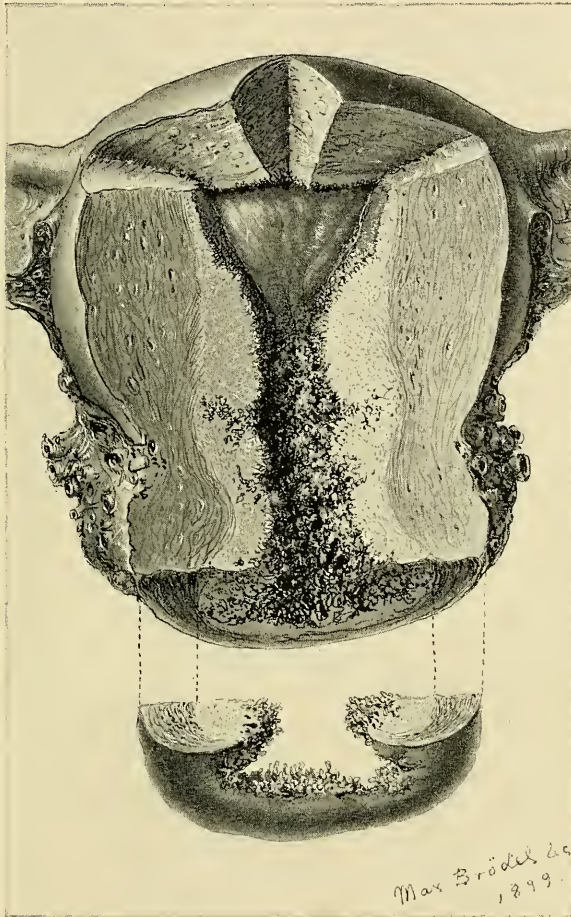


FIG. 223.—ADENO-CARCINOMA OF THE BODY OF THE UTERUS COMMENCING NEAR THE INTERNAL OS.
(Natural size.)

Gyn.-Path. Nos. 1,412 and 1,414. The lower portion of the cervix had been removed a few days before hysterectomy was performed. The uterus is slightly enlarged. The vaginal portion of the cervix is intact and presents the usual appearance. The external os is dilated, and many finger-like outgrowths project through the orifice. Occupying the cervix and the greater part of the body of the uterus is a new growth. This has attained nearly 1 centimetre in thickness. Its inner surface presents a shaggy appearance due to the many finger-like outgrowths, similar to those near the external os. The growth has invaded the cervical tissue to a considerable depth, and to a lesser extent the uterine muscle. The advancing margin is sharply defined, and in the upper part of the uterine cavity the carcinoma gradually tapers off into the normal mucosa. Laterally, the blood-vessels in the broad ligaments are well seen; at the fundus appear the proximal ends of the Fallopian tubes.

nuclei showing karyorrhesis. The stroma of the tissue is rather scant, and consists of spindle-shaped connective-tissue cells. Scattered throughout the stroma and lying between the epithelial cells are numerous polymorphonuclear leuco-

cytes. The vaginal portion of the cervix looks natural, and contains a few normal cervical glands.

The growth is an adeno-carcinoma; the glands suggest those of an adeno-carcinoma of the body. Without a later examination of the uterus, however, it would have been impossible to decide definitely whether the neoplasm had originated in the cervix or in the body.

Operation, November 30th. The uterus was removed through an abdominal incision. The patient made a good recovery, and was discharged January 8, 1897.

Gyn.-Path. No. 1,414. The specimen consists of a part of the uterus with its appendages and the iliac glands (Fig. 223). The lower portion of the uterus has been removed at a previous operation, but the remainder, included in the specimen, is 7 centimetres long, 5 centimetres broad, and 3.2 centimetres in its antero-posterior diameter. It is covered by a few delicate adhesions. To either side is attached a length of 5 centimetres or more of the broad ligament, together with the uterine vessels. The portion of the cervix is 3 centimetres in length; the mucosa is roughened, markedly hæmorrhagic, and presents an eaten-out appearance, which is, of course, partly due to the previous curettage. The part of the cervical mucosa which was left uninjured during the previous operation is gathered up into small polypoid or papillary masses. The uterine cavity is 3.2 centimetres in length, and at the fundus 3 centimetres in breadth. The mucosa on the anterior wall is in places much thickened, and gathered up into myriads of delicate, thread-like outgrowths. At such points it may reach 8 millimetres in thickness. In the upper part of the cavity the mucous membrane is not more than 1 or 2 millimetres in thickness, but in the right horn is a little wart-like mass, 8 millimetres in diameter, which projects for a distance of 3 millimetres from the surface and consists of the same delicate, finger-like growths.

As the appendages were required for other purposes, we had not the opportunity of examining them. The iliac lymph glands average $1 \times .5$ centimetre, being enlarged on both sides.

Histological Examination.—The growth in the cervix, as well as that from the body of the uterus, presents a picture identical with that previously described as occurring in the piece excised for diagnostic purposes. The papillary masses filling the cervical canal and portions of the uterine cavity consist of delicate papillæ; in the centre of each is a slender blood-vessel, and covering the surface are one or more layers of epithelial cells.

Lymph Glands.—Scattered through the lymph glands on both sides are metastases from the primary growth. The epithelial cells, in most cases, show a typical glandular arrangement (Fig. 224). Numerous glands, as in the primary growth, are completely filled with cells. The metastases are not limited to any special portion of the gland, but may be found in the centre, at the periphery, or just without the capsule.

The growth, which is a typical adeno-carcinoma, originated most probably in the body of the uterus, near the internal os, and has grown both upward into the cavity and downward into the cervix.

The patient was admitted to the Johns Hopkins Hospital March 30, 1897, complaining of continual leakage of urine from the vagina.

The patient says that as soon as she regained consciousness after the previous operation she noticed a leakage of urine from the vagina. This has continued up to the present time. She was advised to return home after the operation, and wait a few months before having the fistulous opening closed.

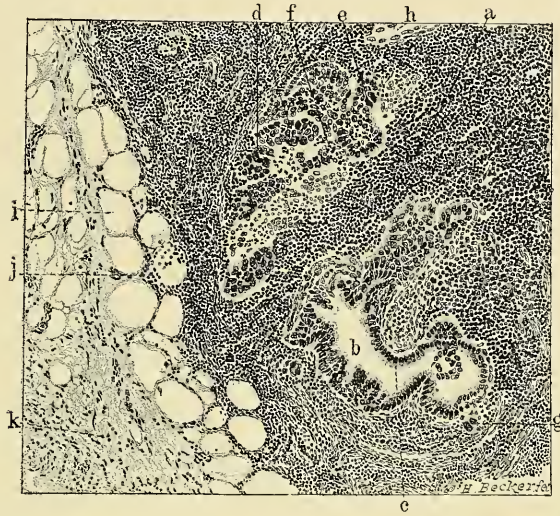


FIG. 224.—ADENO-CARCINOMA OF A PELVIC LYMPH GLAND IN ADENO-CARCINOMA OF THE BODY OF THE UTERUS. (90 diameters.)

Gyn.-Path. No. 1,414. *a* represents the normal lymphoid tissue, consisting of cells having small, round, deeply staining nuclei. *b* is a carcinomatous gland lined by one layer of cylindrical cells at *c*. In most places, however, there are several layers of epithelium, while in the upper portion the cells have so proliferated that the gland lumen is obliterated. At *d* a fairly characteristic gland-like arrangement can be made out, but above and below this point the cells form solid nests. The nuclei of the epithelial cells are for the most part uniform in size, but at *e* are two which are enlarged and stain deeply. *f* indicates polymorphonuclear leucocytes that have wandered in between the epithelial elements. Lying free in the stroma are two isolated epithelial cells (*g*) containing large and deeply staining nuclei. *h* is a blood capillary showing a swollen endothelium. *i* indicates one of the many fat droplets surrounding the gland. Between these droplets the connective tissue has increased, as seen at *j*. *k* is a solid area of connective tissue that has entirely replaced the adipose tissue. The presence of the glands *b* and *d* are at once sufficient proof that we are dealing with metastases, since no epithelial elements are normally found in the lymph glands. Where the endothelium of the blood capillaries is swollen, as at *h*, and the capillary is considerably contracted, the cells may bear some resemblance to carcinoma cells.

The patient is well nourished; the tongue is clean; the appetite is good; the bowels are regular.

Operation, March 31, 1897. Anastomosis of the left ureter into the bladder.

An incision, 12 centimetres in length, was made through the dense abdominal walls at the site of the old scar; after pulling up the peritoneum from the pelvic floor on the left side, the ureter was found skirting the pelvic brim, whence it was followed to the point at which it apparently entered the vagina; here it was markedly constricted. After being cut off at this point it was freed as far as the pelvic brim, and lay as a cord in the pelvis. A sound was then introduced into the bladder, and the end, being projected toward the left side, was cut down upon. A fine curved intestinal needle was then intro-

duced into the bladder wall 1 centimetre from the point of the sound, and was brought out through the incision. The lower end having been slit for a short distance, the ureter was gently caught up by the same ligature, which was made to

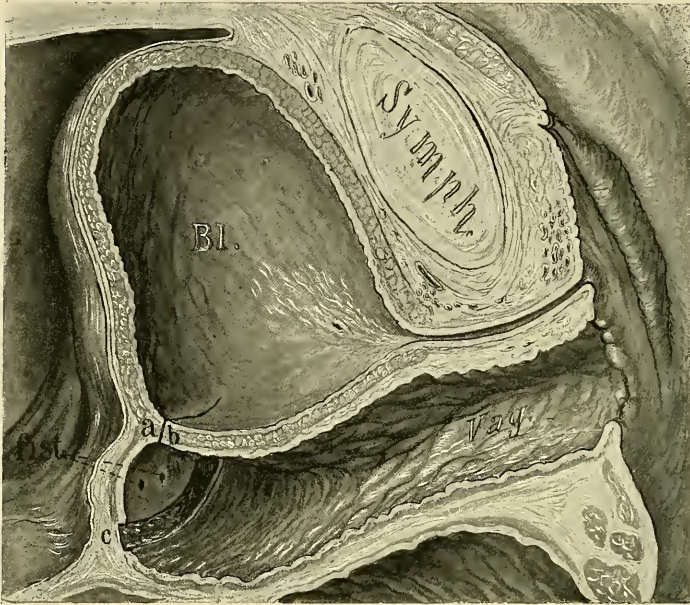


FIG. 225.—TWO URETERO-VAGINAL FISTULAE TURNED INTO THE BLADDER BY A PLASTIC OPERATION.

In the vaginal vault are two small round orifices lying near one another. The one to the right is a fistulous opening from the right ureter; the other represents a similar outlet from the left ureter. The posterior bladder wall has been divided transversely between *a* and *b*, and the vaginal field has been denuded over an area indicated by *c*. As will be seen from Fig. 226, the cut surface (*b*) is brought down and sutured to the raw area (*c*) after the latter has been turned in on itself, so that its vesical and vaginal surfaces are approximated by catgut sutures. (After H. A. KELLY.)

re-enter through the opening in the bladder, and to emerge at a point about 1.2 centimetres from it, thus making a mattress suture. By pulling this tight the ureter was drawn into the bladder and held firmly. Additional sutures were then applied to the ureteral coats, uniting them with the bladder wall, and insuring good approximation. The mattress suture was then removed. At this stage the ureter was seen as a small cord, crossing the left side of the pelvis instead of skirting along its margin. The bladder was then drawn outward and backward, and united with the raw surface at the pelvic wall. At the completion of the operation the ureter was completely covered in. The abdomen was washed out with 2 litres of salt solution, and closed without drainage. A rubber catheter was left in the bladder to prevent any accumulation of urine.

April 2d. Since the operation, only a little urine has come away through the catheter. This is blood-stained. The catheter has been frequently expelled, it sometimes having been necessary to reinsert it from four to six times daily. There is continual tenesmus of the bladder. The patient's general condition is

not very satisfactory; she has an anxious expression and is restless. At 6 P. M. she was taken to the operating room. The posterior vaginal vault was punctured, and several cubic centimetres of extravasated urine escaped.

April 6th. The catheter has been removed. The vesical tenesmus is severe; the patient is still restless, and complains of considerable pain. The catheter is passed every two hours.

April 7th. The patient is fairly comfortable, and has passed 300 cubic centimetres of urine during the twenty-four hours. A fair amount has also escaped through the vagina. Practically the same condition was noted on the following day, but on April 9th no urine was found in the bladder, and a great deal was passed through the vagina. On April 17th her general condition was good, and

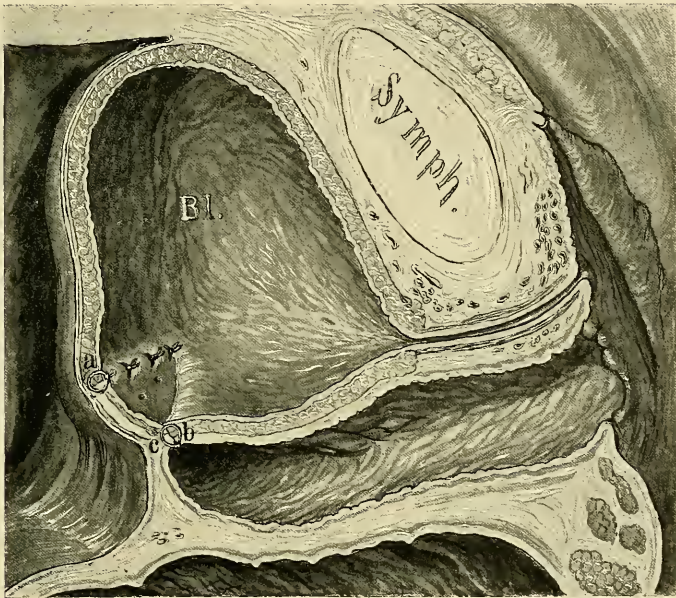


FIG. 226.—COMPLETION OF A PLASTIC OPERATION BY WHICH TWO URETERO-VAGINAL FISTULAE SITUATED IN THE UPPER PART OF THE VAGINAL VAULT HAVE BEEN SUCCESSFULLY TURNED INTO THE BLADDER.

For the various incisions and denudations, see Fig. 225. The portion of the vaginal vault between *a* and *c*, which includes two fistulous openings, now forms a part of the bladder wall. The raw surface (*a*) has been obliterated by approximating the vesical and vaginal mucosae, and the raw surface (*b*), which normally was attached to *a*, has been drawn down and snugly fitted into the denuded area *c*. The urine now passes down the ureters, out through the fistulous openings in them, and into the newly formed bladder. The old ureteral orifices are of no further importance. One of the sutures at *a* became encrusted with salts, and was removed through a vesical speculum on the eighth day. (After H. A. KELLY.)

she was secreting 200 to 300 cubic centimetres of urine each day, besides the quantity escaping from the vagina.

It is probable that in this case the fistula was on the right side and not on the left. The error is easily explicable from the fact that the fistulous opening could not be determined from below, and the scar tissue was most marked on the left side. As a result of the operation, however,

instead of one uretero-vaginal fistula, there were now two fistulae.

The patient was admitted to Dr. Kelly's private hospital April 17, 1897.

The vaginal outlet was 3 centimetres in diameter; the mucosa was smooth. The cavity terminated in a cul-de-sac drawn up on either side into a pocket, the one on the right receiving all the flow from that ureter. Between the two pockets was a fine, but indistinct, white line marking the site of the enucleation of the uterus. During the twenty-four hours preceding operation, 350 cubic centimetres of urine were obtained from the bladder, having entered it through the anastomosed left ureter.

Operation, April 27, 1897. Dr. Kelly's intention was to make a free communication between the bladder and vaginal vault, and to there unite the anterior portion of the bladder wall to the posterior vaginal wall, thus directing the urinary flow into the newly formed bladder, and thence through the urethra. To accomplish this object, a most accurate approximation of tissues was imperative. Two points having been taken, one on each side of the vagina just where the anterior vaginal wall joins the lateral walls, the posterior wall between these points was denuded over an area measuring 1 centimetre in breadth (Fig. 225). Constant and free oozing followed. Sutures of fine silk were then passed in an antero-posterior direction through this raw area, at intervals of 3 millimetres from each other, and dropped. A transverse incision, 3 centimetres in length, was then made into the bladder, 2 centimetres below the vaginal vault, a sound in the bladder serving as a guide. The entire anterior vaginal wall lay in close relation with the bladder; the vesico-vaginal septum at the point of the incision was 1.2 centimetres in thickness. The bladder walls bled freely, and to check the flow the vesical mucosa on the posterior side of the incision was drawn out and united with the vaginal mucosa by seven catgut sutures (Fig. 226, *a*). The incision and denudation were now continued laterally toward the demarcating lines on either side, so as to make a raw surface forming a complete circle, above which was an area, about 2 centimetres in diameter, of the vaginal vault into which the ureteral orifices opened. The operation was now completed by carrying the sutures, which had been passed from before backward, in the posterior vaginal wall through the denuded area on the anterior half of the incised bladder (Fig. 226, *b*). In this way the vagina was closed transversely, a cul-de-sac, about 5 centimetres in depth, being formed. As a result, the urine now escaped into the pocket in the vaginal vault through the fistulous opening into the bladder, and thence to the urethra. Thus the upper vagina was closed by uniting the anterior with the posterior vaginal walls at the sides, but in the middle by approximating the vesico-vaginal septum to the posterior vaginal wall.

The entire operation occupied seventy-five minutes.

The sutures were removed on the eighth day; the union was perfect. One catgut suture, removed on the fourteenth day from the inner surface of the bladder, was found to be encrusted. When discharged, on May 14th, the patient had complete control over the bladder, and the urine contained little pus.

The amount of urine for the first few days was as follows :

April 28th.....	398	cubic	centimetres.
“ 29th.....	418	“	“
“ 30th.....	not	estimated.	
May 1st.....	555	cubic	centimetres.
“ 2d.....	565	“	“
“ 3d.....	820	“	“
“ 4th.....	800	“	“
“ 5th.....	705	“	“
“ 6th.....	723	“	“
“ 7th.....	692	“	“

September 1, 1899. Dr. Kelly has just heard from this patient, and she is in good health. There is no evidence of a return of the growth. Length of time since operation, two years and nine months.

Gyn. No. 2,634

Exploratory laparotomy. The peritoneal cavity contained 2 litres of turbid fluid. Occupying the pelvis was a tumour mass, and studding the peritoneum many secondary nodules. Incision closed. Autopsy. Adeno-carcinoma of the body of the uterus with extension of the growth to uterine myomata (Fig. 228). Secondary involvement of the peritoneum, the inguinal, pericardial, bronchial, and cervical (Fig. 229) lymph glands; carcinoma of the omentum; chronic endocarditis of the mitral, aortic, and tricuspid valves and acute endocarditis of the mitral valves. Giant cells in a carcinomatous gland (Fig. 227).

E. S., aged fifty; coloured. Admitted March 6, 1894. Complaint: abdominal enlargement, with soreness in the region of the umbilicus.

The patient had one miscarriage ten years ago, but gives no history of having had any children.

Her family history is unimportant, and with the exception of an attack of rheumatism a year ago she has always been well.

Her menstrual history is normal; her last period commenced February 22d.

In the latter part of December, 1893, she began to complain of some abdominal pain, and on putting her hand on the abdomen discovered a lump about the size of the end of the finger, just above the umbilicus. This nodule, which was at first hard and non-sensitive, has gradually become larger, and is now quite tender. The patient, on admission, is fairly well-nourished, and, apart from the abdominal enlargement, feels well.

Operation, March 10th. Exploratory cœliotomy. On opening the abdomen, the peritoneum was found to be covered with numerous small nodules; similar tumours were also attached to the intestines, tubes, ovaries, and to the posterior surface of the uterus. The omentum was rolled up, forming a firm, nodular mass just beneath the costal margin. The peritoneal cavity contained about 2 litres of turbid fluid.

For several days after the operation the patient did well, but died March 23d.

Gyn.-Path. No. 204. A large amount of dark-yellow, muddy-looking fluid from the abdominal cavity, and two small papillary-like masses from the omentum, each measuring 1×1 centimetre, were sent for examination. A note was made that similar masses were attached to the abdominal walls, intestines, pelvic organs, mesentery, and, in fact, to the peritoneum everywhere. On microscopic examination, these small nodules are found embedded in adipose tissue. They consist of glands lined by one layer of low cylindrical epithelium. In many of the cells nuclear figures are visible. The gland epithelium has in numerous places proliferated so as to completely fill the cavity. The stroma between the glands is moderate in amount, and is poor in cellular elements. The picture is that of an adeno-carcinoma.

Autopsy No. 505. Gyn.-Path. No. 222. Anatomical diagnosis: adeno-carcinoma of the body of the uterus, with invasion of uterine myomata. Secondary involvement of the peritoneum, of the inguinal, pericardial, bronchial, and cervical lymph glands. Carcinoma of the omentum. Chronic endocarditis of the mitral, aortic, and tricuspid valves; acute endocarditis of the mitral valve.

An abstract from the protocol is as follows: The abdomen is somewhat distended, and in the peritoneal cavity is a considerable accumulation of yellow-

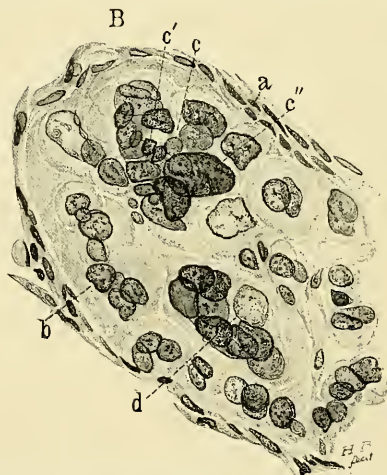


FIG. 227.—A CARCINOMATOUS GLAND CONTAINING GIANT CELLS, FROM A CASE OF ADENO-CARCINOMA OF THE BODY OF THE UTERUS. (420 diameters.)

Gyn.-Path. No. 222. Autopsy 505. *B* is the upper half of a carcinomatous gland. *a* is a delicate zone of the surrounding stroma, consisting of cells with elongate-oval nuclei. *b* is a large, irregular cell containing four vesicular nuclei, two of which are slightly uneven in contour. *c* is a cell showing two larger nuclei. *c'* indicates a small, deeply staining nucleus. *c''* is a very large and slightly lamellated nucleus, exceedingly rich in chromatin. *d* is a very large, oval cell, containing at least nine fairly large nuclei. From the surrounding glands it was easily seen that these giant cells were derivatives from the gland epithelium.

ish serum. Extending completely across the abdominal cavity, in the region of the umbilicus, is a large tumour mass, which covers the anterior surface of the transverse colon. This tumour is lobulated, light in colour, and opaque. It corresponds to the greater part of the omentum. The right edge of the omentum is thicker than the left; the gastro-colic portion is relatively free from tumour

involvement. In the peritoneum at the hilum of the spleen are several small white nodules; the lymphatics around the portal vein also contain small nodules. All of these appear to be metastatic. Covering the peritoneum and the large intestine are numerous metastases, varying from a millet-seed to a pea in size.

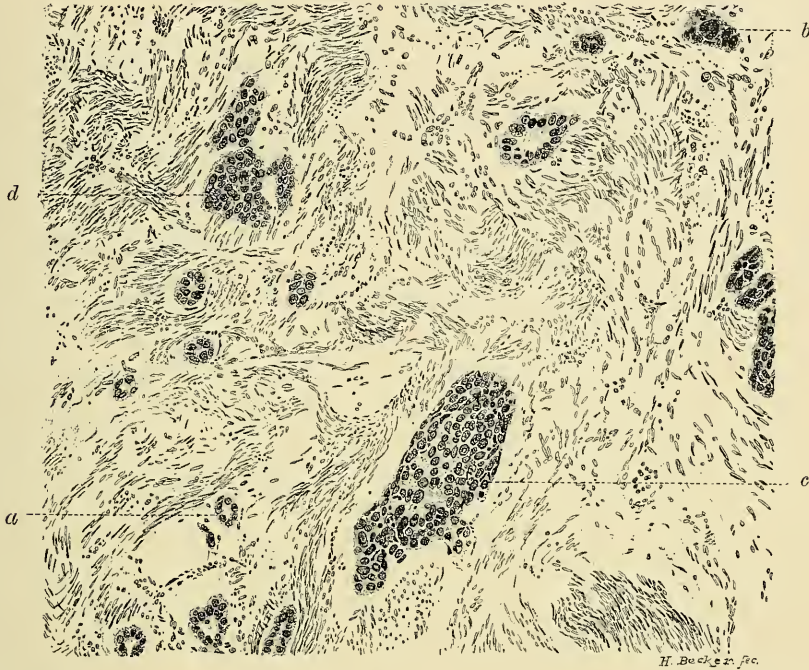


FIG. 228.—ADENO-CARCINOMA IN A MYOMA SECONDARY TO ADENO-CARCINOMA OF THE BODY OF THE UTERUS. (130 diameters.)

Gyn.-Path. No. 222. Autopsy 505. The section consists of typical myomatous tissue. The majority of the muscle fibres have been cut longitudinally and wind in and out in all directions, not showing the regular arrangement so characteristic of normal uterine muscle. Moreover, there is an excess of connective tissue. Scattered abundantly throughout the myoma are groups of carcinoma cells. In the majority of places they appear as glands lined by one layer of cuboidal epithelium (*a*), but in a few places the glands have become filled, as at *b*, or the cells form large solid masses, as seen at *c*. *d* is an irregular mass of cells showing a tendency to branch. On the whole, the nuclei of the epithelial cells are fairly uniform in size, but at *c* are a few large nuclei, and at *b* one that is very large and stains deeply. The growth has extended by continuity.

They cover the peritoneum everywhere, and are especially abundant in the pelvis. The lymph glands beneath the pericardium are enlarged, and contain tumour metastases. The vagina is apparently normal, as is also the cervix. The uterus contains several myomata, the largest of which is pedunculated, and reaches the size of a hen's egg.

The mucosa covering one half of the surface of this nodule is congested and hæmorrhagic; it presents a mottled appearance, and resembles carcinoma. The second myoma is subperitoneal, and also appears to have been invaded by the tumour occupying the uterus. The inner surface of the uterus is grayish in the upper portion, and in places presents a yellowish mottling. The mucosa appears

to extend for some depth into the muscle. The ovaries do not show any involvement.

Histological Examination.—Sections from the uterus show that the muscular coat is invaded by bunches of glands, which are small, circular, and have a lining of cylindrical epithelium. In some of the cells two or more nuclei appear. A few of the glands contain giant cells (Fig. 227). At numerous points

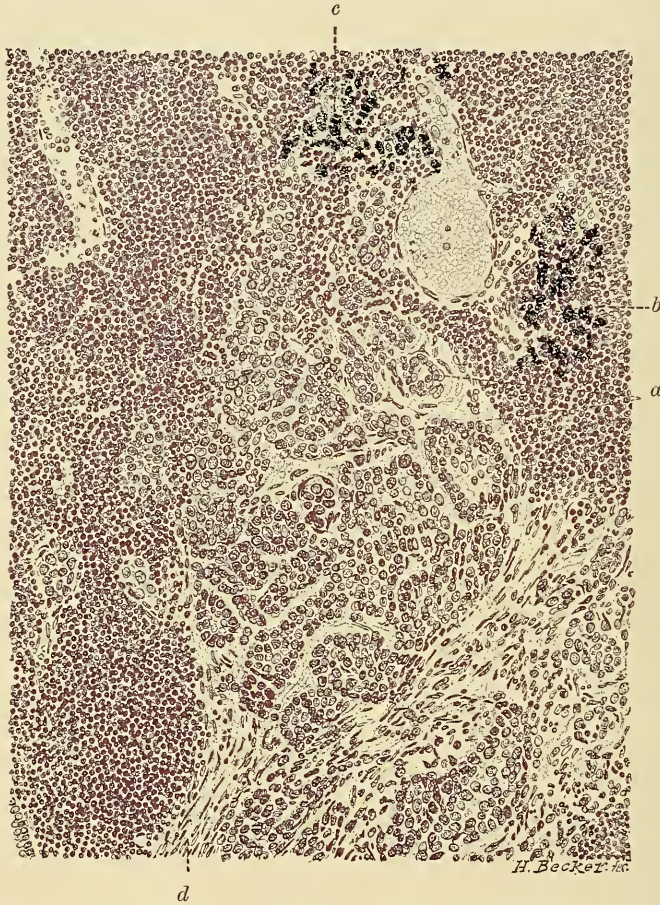

FIG. 229.—ADENO-CARCINOMA OF THE LYMPH GLANDS OF THE NECK SECONDARY TO ADENO-CARCINOMA OF THE BODY OF THE UTERUS. (160 diameters.)

Gyn.-Path. No. 222. Autopsy 505. Occupying the left side and upper portion of the field are the characteristic lymphoid cells. Filling the centre is a large group of cells with a faint glandular arrangement, best seen at *a*. The nuclei of the epithelial cells are round, or oval, and vesicular. In one or two places the nucleus is large and stains very deeply. These glands are surrounded by a small amount of stroma. In the lower right corner there is much connective tissue, and scattered throughout it are groups of epithelial cells forming solid masses. *b* and *c* are pigmentary deposits. *d* is the stroma.

From this section we should be able to say definitely that the primary growth was glandular in character, but secondary growths frequently bear a closer resemblance to the parent tumour.

the gland epithelium has so proliferated, that instead of a bunch of glands there is merely a large mass of cells having no definite arrangement. The centres of such masses often show nuclear fragmentation, but no inflammatory reaction.

The myoma, which appeared to be involved by the new growth, has to a great extent undergone hyaline change. The principal part of it consists of hyaline tissue, with here and there tufts of non-striated muscle fibre. Other portions of the myoma contain glands arranged singly or in bunches; some show a central lumen, while others are completely filled with cells (Fig. 228). This growth is but a continuation of that in the uterine muscle. Portions of the myoma have undergone coagulation necrosis. Just beneath the capsule of the liver, and attached to the surface of the kidneys, are small tumour masses. The glands of the neck show marked carcinomatous involvement, the typical glandular type being here well preserved (Fig. 229).

METASTASES FOLLOWING ADENO-CARCINOMA OF THE BODY OF THE UTERUS

Our knowledge of metastases following carcinoma of the uterus is rather meagre. R. Williams,* in 1896, in seventy-nine autopsies found metastases sixteen times, or in 20.2 per cent; and although he speaks in detail of secondary growths in the skin, pleura, peritoneum, lungs, heart, liver, kidney, tibiae, and innominate bones, he fails to state whether the growths had started in the cervix or in the body, and whether they were squamous-cell carcinomata or adenocarcinomata. Accordingly, we can make no further use of these cases in speaking of metastases. Unfortunately, the majority of the cases in the literature are also lacking in the necessary details.

Adeno-carcinoma of the Peritoneum.—Where the carcinoma penetrates the entire thickness of the uterine wall and reaches the peritoneum, it is possible for carcinoma cells to become free, drop into the peritoneal cavity, become adherent to the pelvic floor, the intestines, omentum, or any peritoneal surface, and further develop. In Case 2,634 (p. 431), scattered over the large intestine, and at the hilum of the spleen, were secondary growths varying from 1.5 to 5 millimetres in diameter. These, on histological examination, consisted of glandular elements identical with those of the primary tumour, while the stroma was made up of spindle-shaped connective-tissue cells.

In Case 6,439 (p. 463) the parietal peritoneum had lost its glistening appearance, and over a large area was covered by rough, irregular, translucent deposits. These were especially abundant on the right side and over the diaphragm. Studying the mesentery (Fig. 243, p. 465) and small intestines were many small, white tumour growths. The mesentery varied from 5 to 6 millimetres in thickness.

Adeno-carcinoma of the Omentum.—With general peritoneal carcinoma the omentum is naturally studded with small, round nodules, or conglomerate tumour masses are present in it. Sometimes it shows profound involvement, as was noted in Case 2,634 (p. 431), in which the omentum formed a large tumour mass completely covering the anterior surface of the transverse colon. This tumour was lobulated, and of a light colour.

* Williams, R. *On the Morphology of Uterine Cancer*. *Brit. Gyn. Journal*, 1895-'96, vol. xi, p. 529.

In Case 6,439 (p. 463), in which there was general peritoneal carcinosis, the omentum was drawn up and contracted into a firm mass between the stomach and the transverse colon.

I have seen a much more marked omental involvement following adeno-carcinoma of both ovaries.

The structure of these omental tumours secondary to adeno-carcinoma of the body is identical with that of the mother growth, the glands still preserving their typical picture, while the surrounding fat shows connective-tissue-cell proliferation and small-round-cell infiltration.

Metastases in the Liver.—These are rare, unless the extension of the process has been very marked. John Williams reports a case of adeno-carcinoma of the body, in which, at autopsy, metastases were found on the surface of the liver. This case, however, hardly comes under the present category, since the growths had probably resulted from a peritoneal implantation.

In Case 2,136 (p. 413) the disease was very far advanced, and two metastases were found in the right lobe of the liver, one about 1 centimetre, the other .5 centimetre in diameter. Both were sharply circumscribed, and were grayish-white in colour; the larger showed opaque, yellowish-white, necrotic patches in its centre. The metastases, on histological examination, resembled the original tumour in all particulars.

In Case 6,439 (p. 463) the liver was rather small. Studding its surface were several irregularly circular nodules, whitish in colour, translucent, and somewhat umbilicated (Fig. 243, p. 465). Numerous nodules were also found scattered throughout the substance of the organ. On section, some of the metastases contained cyst-like spaces, from which a clear, reddish fluid escaped. The liver showed extensive fatty degeneration; the metastases consisted of a network of spindle-shaped cells, containing well-formed glands in its meshes. The glands resembled those of the adeno-carcinoma present in the body of the uterus.

Metastases in the Pleuræ.—John Williams reports a case of adeno-carcinoma of the body with metastases in the pleuræ; in this case there was also a secondary nodule on the surface of the liver.

In Case 6,439 (p. 463) the pleuræ were free from adhesions. Each pleural cavity contained 400 cubic centimetres of a clear yellow fluid, and small translucent tumour nodules were present in the costal pleuræ. Numerous carcinomatous foci were scattered throughout both lungs.

Metastases in the Lungs.—These are found occasionally in cases in which the disease is far advanced and other organs are implicated. The case reported by Hesse* is of interest. A woman, fifty-four years of age, had her uterus removed on account of adeno-carcinoma of the body, and died not long afterward. At autopsy, secondary growths were found in the retroperitoneal glands (probably the lumbar), in the lungs, and pleuræ. The nodules in the lungs were small, grayish white, and firm; on histological examination they proved to be adeno-carcinomata.

* Hesse. B. *Ein Fall von primärem Carcinoma corporis uteri mit nachfolgenden Carcinomen des Scheideneingangs.* Inaug.-Dissert., Jena, 1886.

As seen from the autopsy report, in Case 6,439 (p. 463) of our series, yellowish-white tumour metastases were found scattered throughout both lungs, some of them reaching 1 centimetre in diameter. These, on histological examination, were found to be sharply circumscribed, and consisted almost entirely of convoluted branching glands; they were evidently derivatives from the uterine tumour.

CONDITION OF THE TUBES AND OVARIES IN ADENO-CARCINOMA OF THE BODY

In eight of our cases it was possible to study the appendages both macroscopically and microscopically. From the accompanying table it will be seen that in five cases the tubes and ovaries were normal; in two cases the appendages were adherent, while in the remaining one there was bilateral hydrosalpinx.

GYN.-PATH. NUMBER.	Right tube.	Right ovary.	Left tube.	Left ovary.
P., 392.....	Normal.	Normal.	Normal.	Normal.
A., 2,817.....	"	"	"	"
G., 3,967.....	"	"	"	"
M., 780.....	"	"	"	"
A., 3,258.....	Hydrosalpinx simplex. Adherent.	Adherent.	Hydrosalpinx simplex. Adherent.	Adherent
A., 2,832.....	Adherent.	"	Adherent.	"
W., 2136 (autopsy, far advanced carcinoma)....	Densely adherent.	Densely adherent.	Densely adherent.	Densely adherent.
K., 5,782.....	Normal.	Normal.	Normal.	Normal.

It is to be regretted that a thorough study of all the cases was impossible, but in some instances vaginal hysterectomy was performed, and the appendages were left behind, while in others the disease was so far advanced that it was only possible to curette away the excessive growth. In none of these cases included in the table were the tubes or ovaries invaded by the carcinomatous process. Thus, if we exclude Case 3,693 (p. 588), we have not a single case of adeno-carcinoma of the body in which involvement of the appendages had taken place.

That the tubes may be secondarily involved is shown in a case reported by Ries.* This extension is, however, late, and not likely to be found in operable cases.

Secondary growths in the ovary may also occur, as is proved by the cases of Löhlein,† Wehmer,‡ and Reichel.§ Löhlein's patient was fifty-six years of age, and had, beside the carcinoma in the body of the uterus, secondary growths in both ovaries, that in the left side being as large as a child's head. Löhlein points out the rapid growth of the metastases as contrasted with that of the

* Ries, E. *Eine neue Operationsmethode des Uteruscarcinoms. Zeitschr. f. Geburtsh. u. Gynäk.*, 1895, Bd. xxxii, S. 267.

† Löhlein. *Demonstration eines Carcinoma corporis uteri bei gleichzeitigem Carcinom beider Ovarien. Deutsche med. Wochenschr.*, 1889, Bd. xv, S. 502.

‡ Wehmer, F. *Ueber gleichzeitiges Vorkommen bösartiger Geschwülste des Uterus und des Ovarium. Würzburg*, 1894.

§ Reichel, P. *Ueber das gleichzeitiges Vorkommen von Carcinom des Uteruskörpers und des Eierstockes. Zeitschr. f. Geburtsh. u. Gynäk.*, 1888, Bd. xv, S. 354.

original tumour. Wehmer's patient was thirty-six years old. At operation for the adeno-carcinoma of the body a secondary growth was found in the ovary.

Reichel, who has paid considerable attention to this subject, reported four cases of adeno-carcinoma of the body associated with ovarian tumours. Two of the four tumours proved to be adeno-carcinomata.

SECONDARY CARCINOMA OF THE BODY OF THE UTERUS

This is an exceptional condition, and, according to Wagner, is most common as a sequela to carcinoma of the ovary or mamma. Wagner reported a very interesting case (LII), in which there was a primary carcinoma of the caecum and lower ileum. The bowel having become adherent to the uterus, the growth extended by continuity, so that eventually the uterine wall was perforated, there being a direct communication at this point between the intestine and the uterine cavity.

In one case in the Johns Hopkins Hospital, from a carcinomatous right ovary the process had invaded the body of the uterus by continuity. In all probability this frequently occurs in inoperable cases.

CHAPTER XV

OTHER PATHOLOGICAL PROCESSES IN THE BODY OF THE UTERUS SOMETIMES ASSOCIATED WITH ADENO-CARCINOMA

1. Uterine myomata associated with adeno-carcinoma of the body of the uterus. Illustrative cases.
2. Adeno-carcinoma of the body, an interstitial myoma, and a subperitoneal adeno-myoma in the same uterus.
3. Multiple uterine myomata, adeno-carcinoma of the body of the uterus, and papillo-cystomata of both ovaries.
4. Squamous-cell carcinoma associated with adeno-carcinoma of the body of the uterus.
5. Adeno-carcinoma and sarcoma of the body of the uterus.
6. Sarcoma, adeno-carcinoma, myoma, and uterine polypi in the same uterus.

MUCH might be said on this subject, but I shall only speak of conditions that are entirely independent of the carcinoma, not touching on secondary changes, such as endometritis, that may owe their origin to the malignant growths.

UTERINE MYOMATA ASSOCIATED WITH ADENO-CARCINOMA OF THE BODY OF THE UTERUS

Uterine myomata are so common that one is not surprised to find them co-existing with carcinoma. In our small group of cases a relatively large percentage of uteri contained myomata. These cases may be divided into two groups:

1. Cases in which the myomata are small and play a minor rôle.
2. Cases in which the myomata are very large, and give rise to clinical symptoms overshadowing those due to the carcinoma.

GROUP 1. Small myomata. Several examples of this group are to be found in our series. In No. 2,436 (Fig. 184, p. 363) a myoma, about 1 centimetre in diameter, was found situated in the fundus. In Fig. 186 (p. 367) a myoma of about the same size, and occupying a similar position, is shown. In Case 2,832 (Fig. 190, p. 373) a small, partially submucous myoma occurred, and in Case 5,782 (Fig. 241, p. 460) a small interstitial myoma was found. None of these, however, was sufficiently large to give rise to symptoms, and certainly none was so situated that it could be palpated. Gyn.-Path. No. 161 should in all probability be also included in this group, inasmuch as during curettage of the uterus there was brought away a calcareous mass (Fig. 217, p. 412), which presumably represented the remains of a degenerated calcified myoma. The cases just cited have merely a pathological interest, and are without clinical significance.

GROUP 2. Large myomata obscuring the presence of the carcinoma. In a series of over five hundred myomata we have had at least four well-marked cases of this character. The uterus in Case 5,858 (Fig. 237,

p. 454) was pear-shaped, firm, and more than twice as large as normal. Situated in the anterior wall was a myoma of moderate size.

Fig. 236 (p. 451) represents the enlarged and globular uterus in Case 5,957. The organ projected 4 centimetres above the pelvic rim, and from the surface sprang one pedunculated and several sessile myomata, while the walls contained numerous interstitial myomata, one of which reached 5 centimetres in diameter. This uterus was removed on account of the myomata, carcinoma not being suspected.

In Case 4,262 (Fig. 231, p. 442, and Fig. 232, p. 443) there was also an enlarged and globular uterus, containing several subperitoneal and interstitial myomata and a large submucous myoma. In this case also carcinoma was not suspected by the operator, and the uterus was removed solely on account of the myomatous condition.

In Case 2,634 (p. 431) the uterus was removed at autopsy. Several myomata were present, the largest reaching the size of a hen's egg, in addition to a cancerous growth.

I saw Case No. 6,439 in consultation (Fig. 243, p. 465, and Fig. 244), and from the clinical symptoms and bimanual examination made a provisional diagnosis of multiple myomata. At that time no nodules were visible in the inguinal regions. At autopsy we found a much enlarged myomatous uterus, an adeno-carcinoma of the body, which had given rise to metastases, and small papillo-cystomata of both ovaries. This case is described in detail on page 463.

It is evident that the recognition of the true condition in cases belonging to this group is of the utmost importance from the stand-point of treatment. In none of these instances could a diagnosis of the existing carcinoma have been made without curetting the uterine cavity. Where the uterus is of moderate size and pressure symptoms are absent, in the case of patients who are near the menopause, it is frequently thought advisable to refrain from operating for myomatous tumours. But the cases just cited prove that it is always well to bear in mind the possible existence of a carcinoma of the body of the uterus, so that, if there be any reasonable doubt, the uterus should at least be curetted. In all of the foregoing instances curettage would have been easy to perform, but I have seen many myomatous uteri in which the cavity was so distorted by submucous tumours that the introduction of a curette—not to mention a thorough exploration of the cavity with the instrument—was entirely out of the question. In such cases, if there be a suspicion of cancer, it will be well to remove the uterus at once.

Cases of Adeno-carcinoma of the Body of the Uterus in which the Growth was Obscured by the Presence of Large Myomata

Gyn. No. 4,262

Scrapings indicating a malignant growth (Fig. 230); subperitoneal, interstitial, and submucous uterine myomata (Fig. 231); adeno-carcinoma of the body of the uterus (Fig. 232), developing from the tips of polypi. Early changes in

the epithelium (Figs. 233, 234, and 235). Abdominal hysterectomy.

The patient is living and well, three years and eight months after the operation.

P., aged thirty. Admitted March 30, 1896. Complaint: pain in the back and lower abdomen, with a profuse, yellowish vaginal discharge.

The patient has been married twelve years; she has had one child, but no miscarriages. Her menses commenced when she was fourteen, and have been regular until one year ago, since which time the flow has been very profuse. The last period began two weeks before admission. Her family history is decidedly tuberculous.

About a year ago she began to complain of pain in the back and in the lower part of the abdomen, together with some dysmenorrhœa. Before admission into

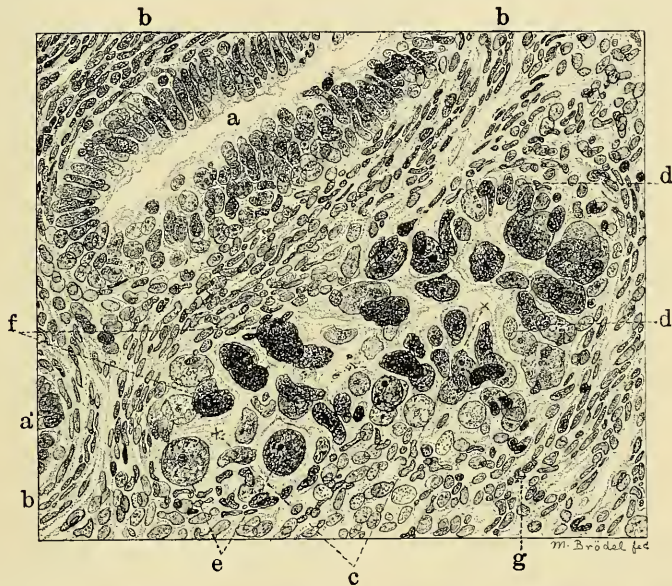


FIG. 230.—A SCRAPING SHOWING INDICATIONS OF THE PRESENCE OF A MALIGNANT GROWTH IN THE UTERUS, REPRESENTED IN FIG. 231. (350 diameters.)

Gyn.-Path. No. 1,133. This was the only area in the scraping that pointed to a malignant process. *a* shows a uterine gland with a well-preserved lumen and a lining of several layers of epithelium. The apparent increase in the number of epithelial layers is probably due to the thickness of the section. *a'* is the edge of another gland. The stroma (*b*) consists of cells containing oval or elongate-oval nuclei. It is comparatively normal save for a stray polymorphonuclear leucocyte (*g*). At *c* is a greatly altered gland. A few of the cells (*d*) contain nuclei of the usual size, but at *e* the latter are fully six or seven times larger than normal, while at *f* the large nuclei are irregular and contain large quantities of chromatin.

From such cell changes as are present in the gland indicated by *c*, the pathologist is warranted in making a diagnosis of a malignant growth. At the time, we said that the picture was very suspicious and advised a second curettage. Further experience has shown that such cell changes are never found in the endometrium except in malignant growths.

the hospital she was examined under ether by Dr. Russell, and a large myomatous uterus was found. The cervix was dilated and curettage was performed.

Gyn.-Path. No. 1,133. A considerable amount of mucosa was removed. On histological examination, the superficial epithelium is intact, but in a

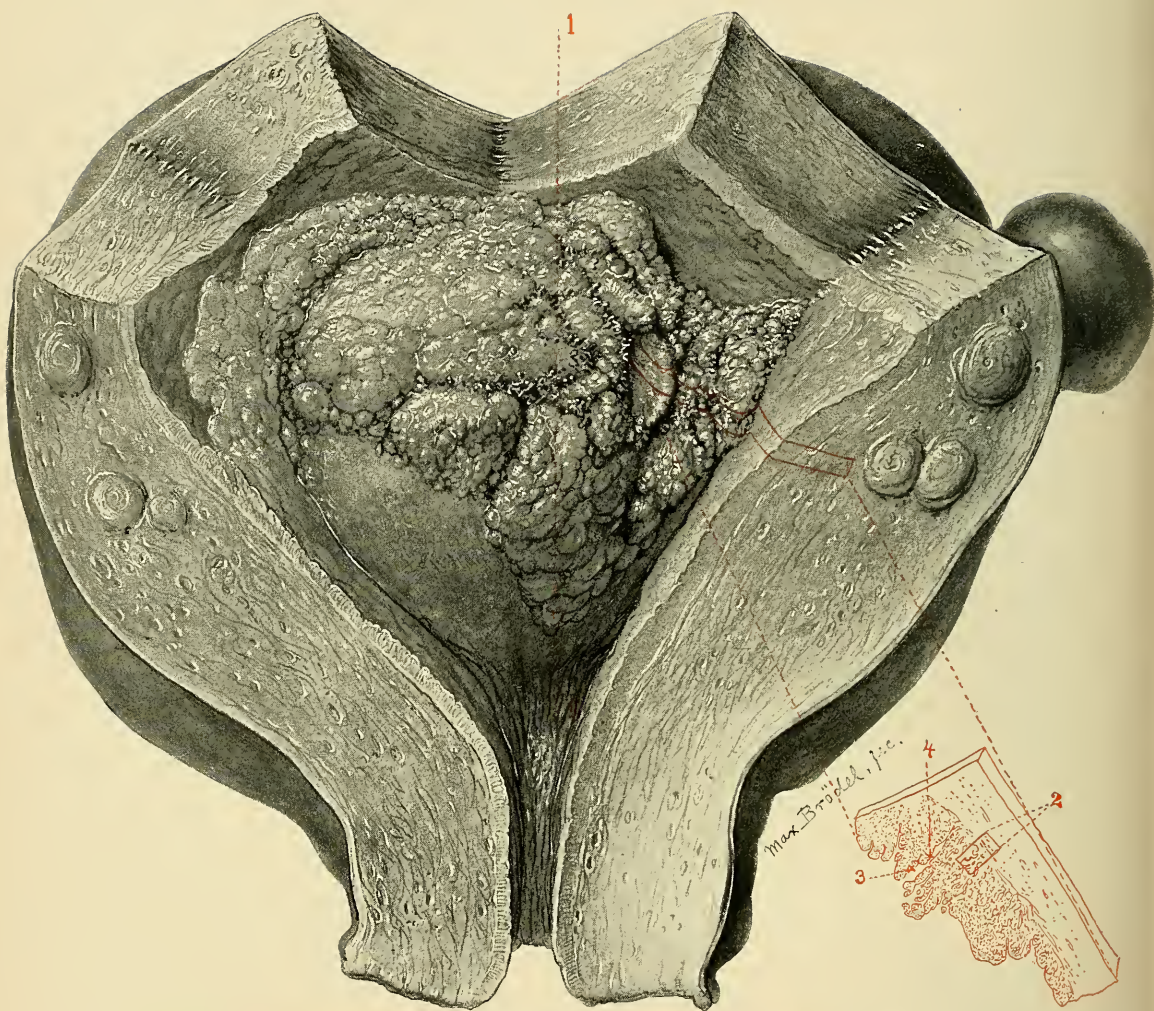


FIG. 231.—ADENO-CARCINOMA OF THE BODY OF THE UTERUS ASSOCIATED WITH LARGE MYOMATA.
($\frac{6}{7}$ natural size.)

Gyn.-Path. No. 1,137. The much enlarged uterus has been opened posteriorly. Projecting from the posterior surface is a small subperitoneal myoma. Scattered through the walls, which are increased in thickness, are a few interstitial myomata. The cervical mucosa is unaltered. The uterine cavity is much enlarged; projecting into it from the anterior wall is a large submucous myoma. (See Fig. 232.) Occupying the anterior wall and extending over the posterior wall is a new growth, in some parts forming a homogeneous and slightly lobulated mass, but in most places consisting of polypi of varying sizes, and with fairly sharp edges. In a few places delicate finger-like outgrowths spring from the surface of the polypi and from the depressions between them. The new growth stands out sharply from the normal mucosa covering the posterior wall. To determine the thickness of the growth, see Fig. 232. For the histological points of interest, see Figs. 233, 234, and 235.

Fig. 232 is taken from the portion of Fig. 231 indicated by 1.
 " 233 " " " " " " 2.
 " 234 " " " " " " 3.
 " 235 " " " " " " 4.

Fig. 230 shows the scraping from which the diagnosis of carcinoma was made.

good many places the surface is gathered up into teat-like folds. The glands are very abundant; some are small and round on cross section, while others are irregular and have teat-like projections extending into their cavities. All of the glands are lined by one layer of cylindrical epithelium, which in a few places tends to fill the lumina. The stroma of the mucosa is of moderate density. At

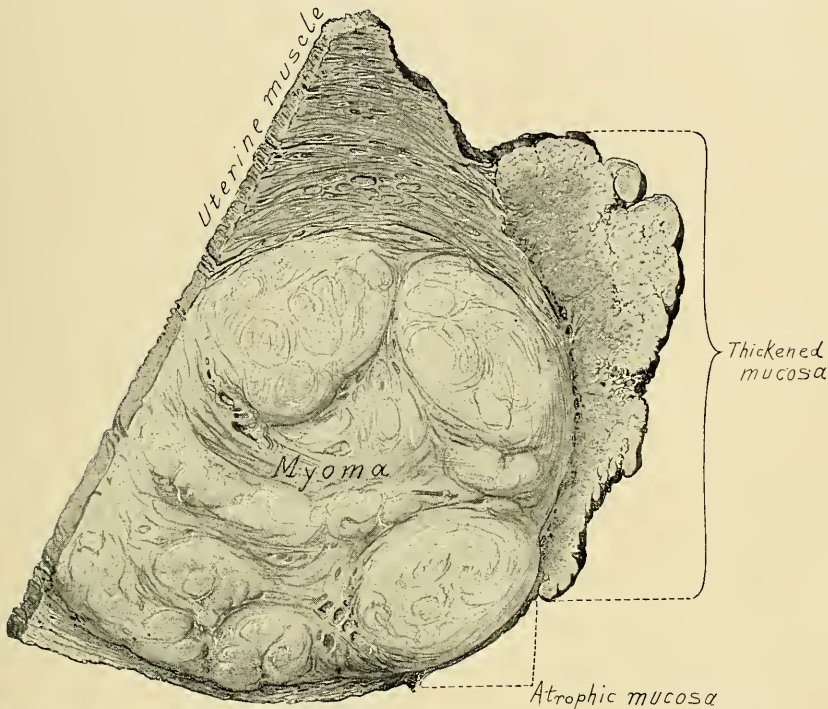


FIG. 232.—ADENO-CARCINOMA OF THE BODY OF THE UTERUS OVER A SUBMUCOUS MYOMA.
($\frac{6}{7}$ natural size.)

Gyn.-Path. No. 1,137. This is a longitudinal section through the part of Fig. 231 indicated by 1. Occupying the anterior wall is a submucous myoma containing several small, cyst-like areas of degeneration. The mucosa covering this and the uterine muscle in some places reaches more than 2 centimetres in thickness. Its surface presents a wavy outline, and at several points distinct polypi are formed. In the deep depression near the middle of the area a few finger-like projections are visible. The mucosa below the growth is somewhat atrophic, as a result of pressure.

one point a short distance from the surface is an elongate-oval area filled with cells, whose nuclei are very large, being five or six times the usual size. Some of these nuclei are round and vesicular, showing a distinct nucleolus; other cells have irregular nuclei which contain large quantities of chromatin (Fig. 230). The picture immediately suggests a gland, whose cell elements are rapidly dividing. This area excites strong suspicions of carcinoma.

Diagnosis.—Hypertrophy of the uterine mucosa; probable malignancy.

No immediate operation is advised, but it will be well to curette again in two or three weeks.

At the time of rendering this report we had not seen the history, and were entirely unaware that the operator contemplated removing the uterus on account of a large myoma.

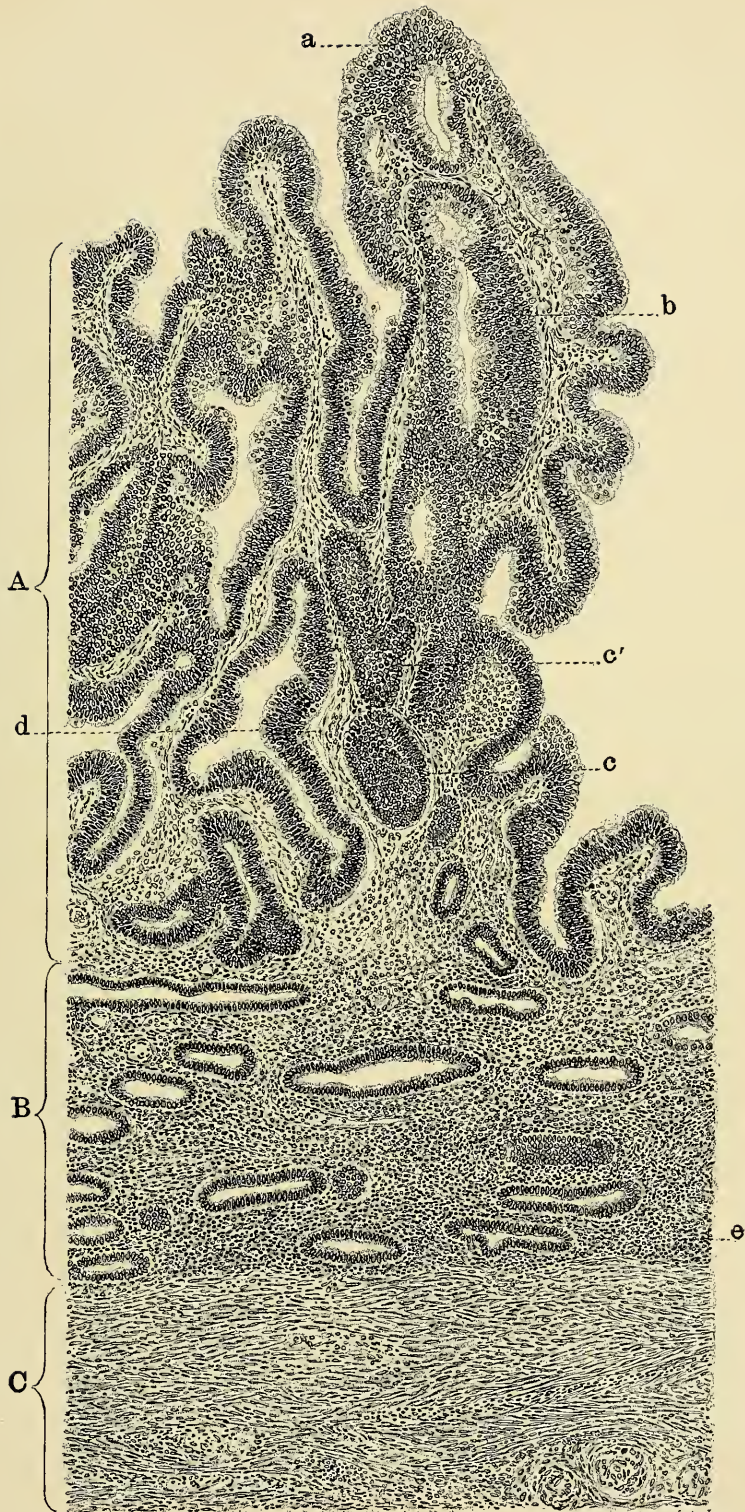
Operation, April 6th. Abdominal hystero-myomectomy. The patient made an uninterrupted recovery, and was discharged April 30th.

Gyn.-Path. No. 1,137. The specimen consists of the uterus with its appendages. The uterus is approximately globular, measuring $15 \times 13 \times 13$ centimetres. Both anteriorly and posteriorly it is smooth and glistening. The cervix is 4 centimetres in diameter; its canal is about 3.5 centimetres in length. The posterior uterine wall varies from 2.5 to 3 centimetres in thickness. Scattered throughout it are several myomata, some of which are interstitial, while others are sessile (Fig. 231). The anterior wall varies from 2 to 9 centimetres in thickness, and, in addition to several small myomata, contains a submucous myoma, 8 centimetres in diameter. The uterine cavity measures 8 centimetres in length, and at the fundus is 7.5 centimetres in breadth. The mucosa at the fundus varies from 2 to 3 millimetres in thickness, but over the greater part of the anterior wall and over the posterior wall it presents a marked alteration, being gathered up into large and small dome-like folds, varying from 0.3 to 1.5 centimetres in breadth. Some of them reach 0.7 centimetre in thickness, but where they have been subjected to pressure they are flattened. The small dome-like masses are smooth and glistening, and cannot be subdivided into smaller eminences, as is usually the case in adeno-carcinoma of the body. After hardening the specimen in Müller's fluid, however, it is possible, in a few places, to make out a delicate, branching or tree-like arrangement. The larger excrescences are traversed by shallow depressions, which tend somewhat to subdivide them. Ramifying through them in all directions are delicate capillaries. Near the fundus the mucosa reaches 2 centimetres in thickness; here only the superficial portions are tending to become polypoid. The mucosa in its deeper portion is sharply defined, being easily distinguished from the muscle, which it

FIG. 233.—ADENO-CARCINOMA OF THE BODY OF THE UTERUS STILL LIMITED TO THE SUPERFICIAL PORTION OF THE MUCOSA. (100 diameters.)

Gyn.-Path. No. 1,137. The section is taken from the part of Fig. 231 indicated by 2, and is divisible into three distinct portions. *A* represents carcinomatous tissue; *B*, normal uterine mucosa; *C*, normal muscle. On examining the carcinomatous area, we find that on the right the surface epithelium is intact and about three layers in thickness. On following the surface toward the left there appears a short outgrowth, after which is seen a long outgrowth (*a*) with convoluted margins and covered by at least four or five layers of epithelium. In this outgrowth are several gland-like spaces due to invaginations from the surface. These also are lined by several layers of cells, especially at *b*, where we have at least ten rows. *c* and *c'* are gland spaces cut along their margins. To the left of the outgrowth (*a*) we have similar excrescences and corresponding gland spaces. The stroma in the carcinomatous area is rather scant, and consists of cells containing spindle-shaped nuclei. It is directly continuous with that of the normal mucosa. The area *B* consists of typical normal mucosa. The glands are equidistant from one another, and are lined by one layer of epithelium. The stroma shows no alteration except a slight small-round-cell infiltration (*e*) near the muscle. The muscle presents the usual appearance.

With the outgrowths from the surface, the atypical gland arrangement, the scanty amount of stroma, and the normal mucosa for comparison, there is no doubt as to the malignant character of the growth; but where only small pieces of tissue have been removed by the curette, some confusion may arise.



Max Brödel, f.c.

FIG. 233.

apparently has not penetrated (Fig. 232). The posterior wall, over a limited area, has been entirely denuded of mucosa by the curette.

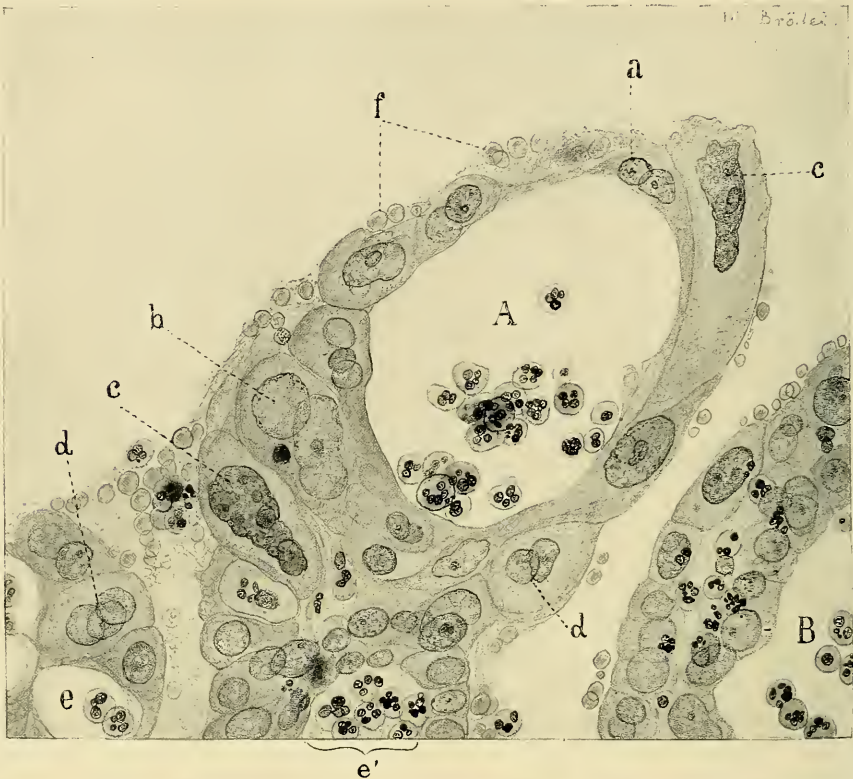

FIG. 234.—NEW GLANDS DEVELOPED IN THE TIPS OF FINGER-LIKE PROJECTIONS IN ADENO-CARCINOMA OF THE BODY OF THE UTERUS. (400 diameters.)

Gyn.-Path. No. 1,137. The section is taken from the portion of Fig. 231 indicated by 3. *A* and *B* are two young glands. At *a* is seen the average size of the nuclei of the carcinoma cells. At *b* is a nucleus much larger and somewhat irregular in contour. The nuclei indicated by *c* are very large, irregular in contour, and somewhat lamellated; they contain an excess of chromatin. Certain cells (*d*) contain two and three nuclei each. Thus we see that the new glands are sometimes composed of a few cells of variable size and shape, dovetailed into one another. *e* is a small vacuole in an epithelial cell, and contains polymorphonuclear leucocytes. The gland *e'* contains many polymorphonuclear leucocytes. At *f* are red blood-corpuscles clinging to the surface of the gland.

The left tube is 7 centimetres in length. At the uterus it is 4 millimetres in diameter, but gradually dilates, terminating in an occluded fimbriated extremity, 1 centimetre in breadth. It is bound down to the side of the uterus by loose adhesions. The parovarium is intact. The left ovary measures $3.5 \times 3 \times 1.5$ centimetres, and is covered by a few adhesions.

The right tube is 13 centimetres long. After passing outward for a distance of 5.5 centimetres, it curves downward and terminates in an occluded fimbriated extremity. It is bound down to the side of the uterus by fan-like adhesions. On pressure it is soft and yielding, being filled with fluid. The ovary is covered by a few adhesions.

Histological Examination.—The epithelium covering the vaginal portion of the cervix is normal. The cervical glands are abundant, and present the usual appearance. The uterine mucosa, over those portions of the cavity which show no elevations, has an intact surface epithelium; the epithelial cells are, however, slightly flattened. The glands are abundant and somewhat convoluted, but present the usual picture. The stroma of the mucosa, especially in the superficial portions, is slightly rarefied. The individual cells are somewhat

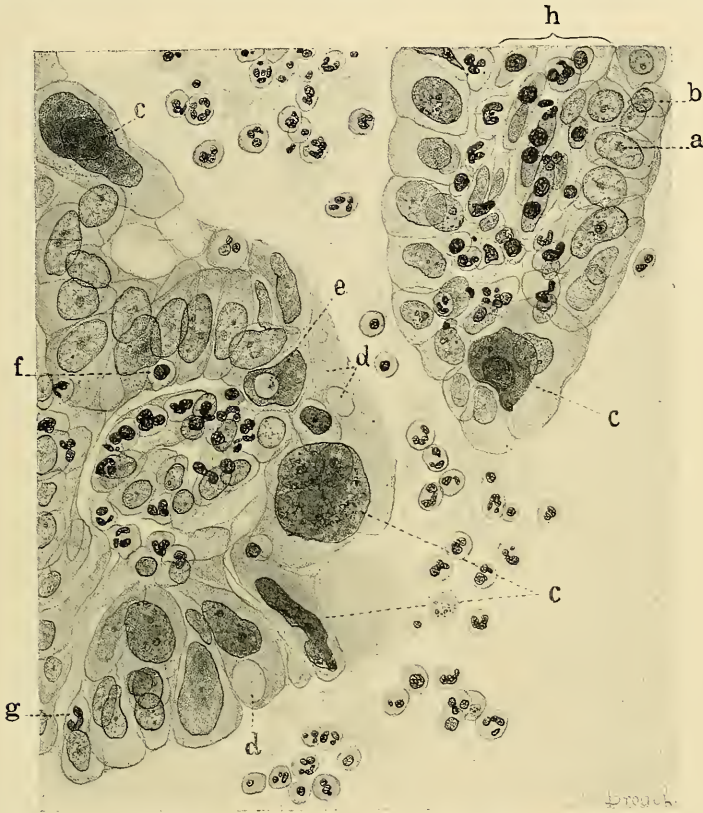


FIG. 235.—THE TIPS OF TWO FINGER-LIKE PROJECTIONS IN ADENO-CARCINOMA OF THE BODY OF THE UTERUS. (400 diameters.)

Gyn.-Path. No. 1,137. The section is from the portion of Fig. 231 indicated by 4. Note the differences in size of the epithelial cells covering these projections. *a* represents an average-sized nucleus; *b* is a very small one; while at *c* are very large nuclei, irregular in outline and staining deeply, owing to an excess of chromatin. At *d* are hyaline droplets in the protoplasm of the cell. At *e* is a nucleus containing a hyaline droplet. *f* is a small round cell between epithelial cells; *g*, a polymorphonuclear leucocyte between the cells. *h* represents the stroma of one of the folds; it consists of elongate-oval cells, containing elongate, vesicular nuclei. Scattered throughout the stroma are numerous small round cells and polymorphonuclear leucocytes. They are also abundant in the space around the folds.

Given such a picture as we have here, and being told that it came from the body of the uterus, we could diagnose the growth as malignant from the presence of the large and deeply staining nuclei (*c*). Of course, we could not tell that it came from an adenocarcinoma, inasmuch as no gland arrangement is present.

swollen, and occasionally a nuclear figure can be seen. The veins of the stroma are greatly dilated, and appear as veritable sinuses. Where the polypi are

found, the glands near the muscle are normal, but as one approaches the surface they become more convoluted, have teat-like projections extending into their lumina, and show considerable branching, the stroma in the meantime diminishing in amount. Toward the surface of these polypi the glands are not so abundant, but their deficiency is made up by an increase in the stroma, the cells of which are fully twice the normal size. Externally the polypi are covered by cylindrical epithelium continuous with that of the general uterine cavity.

Where the tree-like appearance was noted, and especially over the areas covered by the greatly thickened mucosa, a most exceptional picture is seen. The tips of the polypi have undergone a radical change, being the seat of a typical and unmistakable adeno-carcinoma. At the bases of these polypi, where the mucosa joins the muscle, the glands are frequently normal, and the stroma shows no alteration (Fig. 233). After passing a short distance toward the surface the gland lumina become much larger, the walls are more convoluted, and there are teat-like projections extending into the cavities. Not infrequently the epithelium becomes two, three, or perhaps four layers in thickness. Still nearer to the surface it shows a marked tendency to proliferate, the gland lumina being in some places obliterated. In other portions the cells have increased to such an extent that they form large masses, showing an ill-defined gland-like arrangement; or the picture may be well defined, one gland lying against the other, with no intervening stroma separating them. On the surface, at such points, the epithelium shows marked proliferation, is much convoluted, and has formed many small secondary glands (Fig. 234), so that there may be as many as four or five layers of them covering the surface of the polypi. Many of the glands are filled with polymorphonuclear leucocytes; a few contain necrotic material. The nuclei of the carcinoma cells differ materially from those of the other epithelial cells (Fig. 235). They are often two or three times as large, show very sharply defined contours, are poor in chromatin, and have very distinct nucleoli. As they lie side by side they differ greatly in size, some being fully three or four times as large as those surrounding them, the size of the nucleus increasing in direct proportion with the diminution in the amount of chromatin. At no point can the carcinomatous process be seen invading the uterine muscle. The large submucous myoma presents the typical appearance.

The right tube is the seat of a follicular hydrosalpinx. The ovary apart from its adhesions is normal.

The left tube also shows follicular hydrosalpinx. The ovary is unaltered.

Diagnosis.—Uterine polypi, showing normal mucous membrane in their bases, glandular hypertrophy in their middle portions, and, at certain points, adeno-carcinoma in their superficial portions. Subperitoneal, interstitial, and submucous myomata. Slight pelvic peritonitis. Double follicular hydrosalpinx.

December 22, 1899. Dr. Hurdon has visited this patient. She is living and well, three years and eight months after operation.

From this case many very instructive lessons may be learned. In the scrapings, in a few places, was noted a moderate glandular hypertrophy, and at one point an elongate-oval area filled with cells having very large nuclei, some of

which were especially rich in chromatin (Fig. 230). Such a picture is practically never found in any other condition of the mucosa, the cells and their nuclei, as a rule, being very uniform in size and also in their behaviour to the various stains.

The thickness of the mucosa in the upper part of the uterine cavity is very unusual, and the finely granular appearance of some of the polypi, in contradistinction to the smooth surface of the majority of them, is also significant of carcinoma.

The clinical significance of this case is that the uterine cavity should be thoroughly curetted, since it might readily happen that only portions of the smooth or benign polypi might be removed, those of the papillary or carcinomatous variety being left behind. From a pathological stand-point it will also be seen that it is necessary to examine several pieces of the scrapings, inasmuch as, if only one or two were taken, the malignant portions might not be detected. In this case the diagnosis of "a suspicion of malignancy" was based entirely upon the presence of the five or six large cells in one of the scrapings.

Winter and Ruge have stated that the malignant process is to be recognised not so much by the penetration of the muscle by the carcinomatous mucosa as by the characteristic formation of the growth. The truth of this view is indisputable, and one might even go a step farther and maintain that the disease, almost without exception, can be diagnosed from the gland arrangement, even though no muscle be present.

Gyn. No. 5,957

A large myomatous uterus with adeno-carcinoma of the body (Fig. 236). General pelvic peritonitis; abdominal hysterectomy with amputation at the cervix. Histologically the adeno-carcinoma in many places closely resembled a squamous-cell carcinoma. The patient is well, one year and nine months after operation.

S. B., coloured, aged forty-seven. Admitted March 16, 1898, complaining of an abdominal tumour.

Her menses commenced at thirteen, and were always regular until six years ago. At seventeen she was married, and when she was twenty-three years of age she had a miscarriage. Her family history is unimportant.

Six years ago she had a fairly constant bloody uterine discharge, alternating with a leucorrhœal flow. About three years later she first felt a small lump in the lower abdomen, and says that it has slowly increased in size. It was not at all painful until August, 1897, but since that time there has been a dull, aching sensation in the lower part of the abdomen and back.

The patient is a well-nourished woman; the mucous membranes are slightly pale; the heart and lungs are negative.

Projecting from the pelvis is a rounded mass, reaching 4 centimetres above the pelvic brim. The vagina is relaxed, the cervix is small and conical, but merges into an irregularly rounded tumour, apparently composed of several myomata.

Operation. Abdominal hysterectomy, March 21, 1898.

The uterus was removed in the usual way from left to right, but the left appendages were not disturbed, and the uterus was amputated at the cervix, carcinoma not having been suspected until after the operation had been completed.

The patient made a perfect recovery, and was discharged April 22d.

Gyn.-Path. No. 2,238. The specimen consists of the uterus, which is converted into a globular tumour, 11 centimetres in diameter, covered by numerous vascular adhesions. Springing from it are several myomata, some of which are sessile, while one is pedunculated. The portion of the cervix is 2 centimetres long; its mucosa presents the usual appearance. The uterine walls vary from 4 to 8 centimetres in thickness, and contain several myomatous nodules, the largest being 6 centimetres in diameter (Fig. 236).

The uterine cavity is 6 centimetres long, and 4.5 centimetres broad at the fundus. The mucosa covering the posterior wall is smooth, glistening, and slightly injected; it varies from 1 to 2 millimetres in thickness. The portion covering the anterior wall is profoundly altered, and now consists of a new growth, averaging 1 centimetre in thickness. The surface is for the most part smooth, but occasionally projecting from it is a minute finger-like process, while at several points the surface presents a shaggy appearance, due to aggregations of myriads of these finger-like projections. At one point these delicate outgrowths form a bunch, projecting fully 1 centimetre from the surface. The growth, on section, presents a waxy appearance, and stands out in sharp contrast to the muscle, which it has invaded for a short distance.

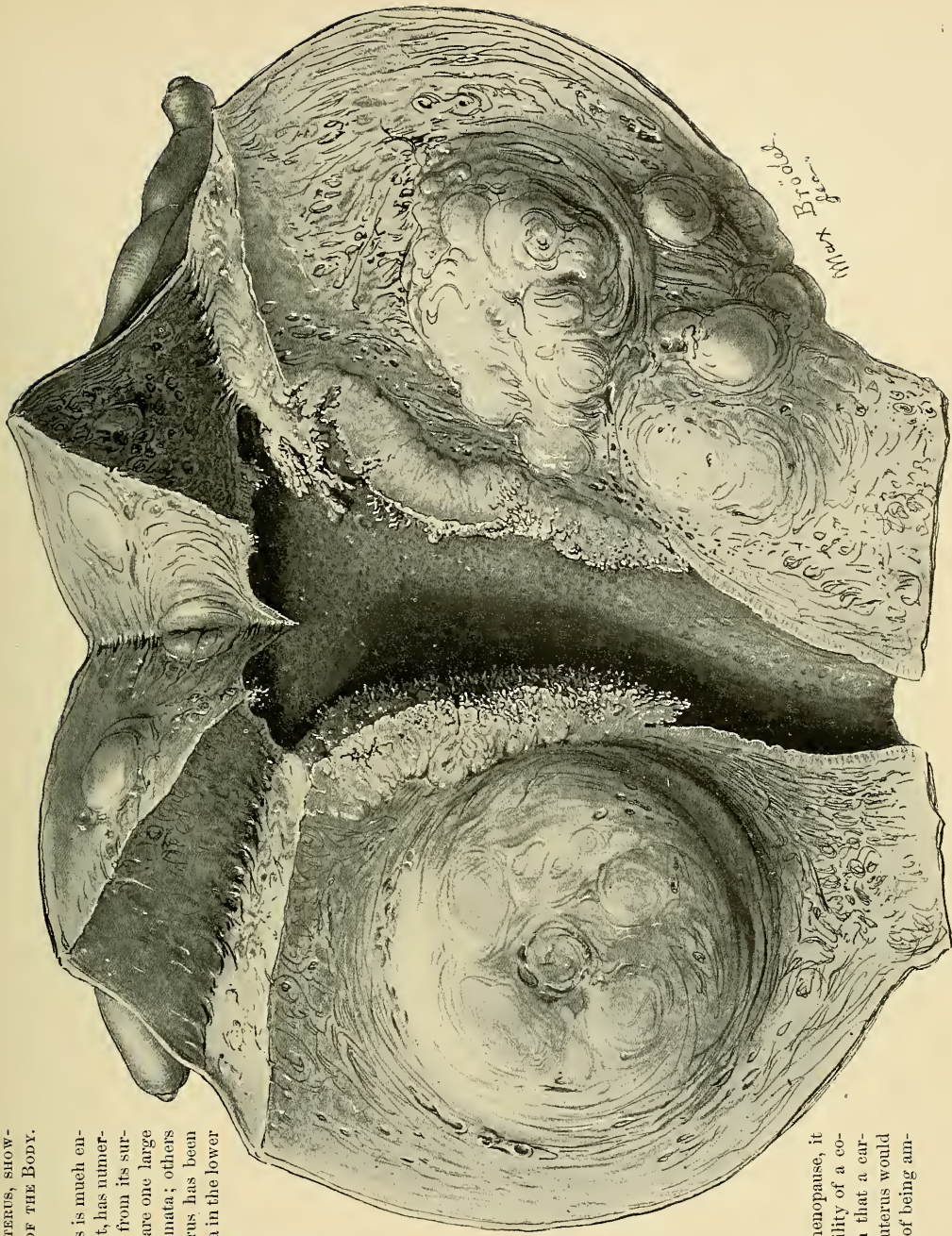
Histological Examination.—The superficial epithelium of the mucosa in the lower part of the uterus and on the posterior wall is intact. The cells are somewhat flattened, and stain rather faintly. Projecting from the surface at several points are knob-like or slightly irregular outgrowths. Their epithelium is intact. The uterine glands are few in number, are small and round on cross section, and for the most part have an intact epithelium; in a few, the epithelial cells are swollen and contain vacuoles. The stroma of the mucosa is very dense, and in its superficial portions shows much small-round-cell infiltration. The blood supply is rather scant, but at a few points several veins are markedly distended, so much so that they project slightly above the surface of the mucosa.

Sections from the superficial portions of the growth show that it is composed of masses of epithelial cells, closely packed together, and having an indefinite gland-like arrangement. There is very little stroma at such points. The glands in other parts are very distinct, and occur singly or in bunches. On cross section they are usually small and round. The gland epithelium, where it is well preserved, is cylindrical in form, and contains oval, somewhat deeply staining nuclei. Where the epithelial cells have multiplied to such an extent that the gland spaces are entirely obliterated, the nuclei are frequently much larger, have irregular contours, and stain more deeply. Nuclear figures are scattered abundantly throughout the various fields. At many points no glands are visible, and the epithelial cells form solid nests; given such a field, the diagnosis of squamous-cell carcinoma would certainly be justified. Scattered between the epithelial cells in all parts of the growth are many small round cells.

FIG. 236.—A LARGE MYOMATOUS UTERUS, SHOWING ALSO AN ADENO-CARCINOMA OF THE BODY. (Natural size.)

Gyn.-Path. No. 2,238. The uterus is much enlarged, and, as is mentioned in the text, has numerous subperitoneal nodules projecting from its surface. Situated in the anterior wall are one large and several smaller interstitial myomata; others are found in the fundus. The uterus has been amputated at the cervix. The mucosa in the lower part of the uterine cavity is normal, but after tracing it upward several centimetres on the anterior wall it has been replaced by a new growth. In places it is smooth, but at most points it is covered by delicate finger-like outgrowths. The growth reaches 1 centimetre in thickness, is light in colour, and stands out in sharp contrast to the uterine muscle, which it has invaded to a slight extent. Upward it reaches to the fundus, its advancing margin being irregular. The mucosa covering the posterior wall is slightly mottled, but otherwise is apparently normal. The stumps of both Fallopian tubes are visible in the upper part of the picture.

All of the symptoms in this case might readily have been accounted for by the presence of the myomata, and without curettage it would have been impossible to diagnose the carcinoma. When considering the advisability of refraining from removing a myomatous uterus after the menopause, it will be well to remember the possibility of a co-existent carcinoma. Had we known that a carcinoma was present in this case the uterus would have been entirely removed, instead of being amputated at the cervix.



The stroma of the growth is scant in amount, and consists of spindle-shaped connective-tissue cells. It shows very profuse small-round-cell infiltration; in fact, the stroma at several points consists of practically nothing else than young capillaries and small round cells.

The finger-like processes which project from the surface of the growth have been cut both longitudinally and transversely; they consist of large capillaries, having very delicate walls and a scant amount of surrounding connective tissue. Their outer surfaces are covered by from five to ten or more layers of epithelial cells, having oval, vesicular nuclei. The nuclei are fairly uniform in size, but occasionally one is fully six or eight times as large as those in the vicinity. Between the epithelial cells are numerous polymorphonuclear leucocytes and some small round cells. These finger-like projections fail to show the gland-like arrangement of their epithelial cells, so frequently seen in adeno-carcinoma of the body. They seem to be practically identical with the finger-like projections found in squamous-cell carcinoma of the cervix.

The growth shows very little breaking-down, but there is, of course, here and there slight necrosis, or a hyaline change in the cell protoplasm, as well as some polymorphonuclear infiltration. The muscle along the advancing margin of the growth shows extensive small-round-cell infiltration, which also appears at some distance from the growth. The muscle at a few points shows polymorphonuclear infiltration.

The myomata scattered throughout the uterus have undergone marked hyaline degeneration.

Diagnosis.—Slight endometritis; adeno-carcinoma of the body of the uterus, in many places closely simulating squamous-cell carcinoma. Subperitoneal, interstitial, and submucous uterine myomata. General pelvic adhesions.

December 27, 1899. The patient writes: "I gained my strength about eleven weeks after operation. I have not had one hæmorrhage since the operation. I feel as strong and can do as much work as I ever did." Length of time since operation, one year and nine months.

Gyn. No. 5,858

Adeno-carcinoma of the body of the uterus associated with interstitial myomata (Fig. 237). Slight pelvic peritonitis; endometritis both in the cervix and in the body of the uterus (Figs. 238 and 239). Rows of carcinomatous glands bearing some resemblance to the syncytial bands found in deciduoma malignum (Fig. 240); acute salpingitis on the right side; abdominal hysterectomy; death on the second day with signs of peritonitis; cultures from the abdominal cavity yielded streptococci.

K. H., aged forty-seven; single. Admitted February 8, 1898, complaining of pain in the left lower abdomen and of uterine hæmorrhages.

Her menses commenced at fifteen, were always regular, and lasted three days. For about four years the flow on the first day has been more profuse than before. For two years she has had severe hæmorrhages and a somewhat profuse vaginal discharge, watery in character, frequently blood-tinged, and very offensive. Her family history is unimportant.

The patient is pale; her mucous membranes are anæmic; the pulse is rather rapid; the heart and lungs appear to be normal.

Abdominal examination is unsatisfactory on account of the extreme tenderness; there is severe pain in the left iliac region.

Blood examination: Red blood-corpuscles, 5,556,000; white blood-corpuscles, 6,000; hæmoglobin, 65 per cent.

Examination under ether revealed a small, soft cervix. The uterus was large, and from its anterior surface, a little to the left of the median line, was a protruding nodule. On the posterior wall was another nodule.

The examination of scrapings from the body of the uterus shows the presence of adeno-carcinoma.

Operation, May 12, 1898. Pan-hysterectomy.

After making a long incision, the adherent omentum was released. The uterus was removed in the usual way, and before the abdomen was closed the cavity was irrigated with 2,000 cubic centimetres of normal salt solution. The patient passed a fairly comfortable night, but suffered a good deal of pain. The pulse varied from 116 to 128. At 7.45 A. M. the patient seemed to be in a state of collapse. The pulse rose to 160, and was very weak; the respirations were rapid, the patient gasping for breath. She vomited 540 cubic centimetres of a dark-brown fluid, the colour being to a great extent due to the presence of blood. At 9.45 the pulse was still weak and irregular, but better in quality. At noon her temperature rose to 102.5° F., and the pulse to 152; 1,000 cubic centimetres of salt solution were introduced under the mamma. The patient died at 1 P. M. No autopsy was made, but the abdominal cavity was opened. It contained a large amount of sero-hæmorrhagic fluid, and the intestines were slightly bound together by a fresh fibrinous deposit.

Cultures give a growth of streptococcus pyogenes.

Gyn.-Path. No. 2,146. The specimen consists of the uterus, tubes, and ovaries.

The uterus is 11 centimetres in length, 7 centimetres broad, and 8 centimetres in its antero-posterior diameter; it is free from adhesions. Projecting from the anterior surface is a round boss, 5 centimetres in diameter; this is firm in consistence, and on section presents the usual myomatous appearance (Fig. 237). The vaginal portion of the cervix appears to be normal. The cervical canal is 3.5 centimetres long, and averages 9 millimetres in diameter. Its mucosa is smooth, but somewhat injected; it is covered with a hæmorrhagic discharge, which has trickled down from the cavity of the uterus. The uterine cavity is 5 centimetres long, and at the fundus reaches 5 centimetres in breadth. Occupying nearly the entire uterine cavity is a new growth, grayish in colour. It is for the most part divided up into several longitudinal ridges, separated by deep furrows. The tissue composing the ridges has a smooth surface, but at several points along the advancing

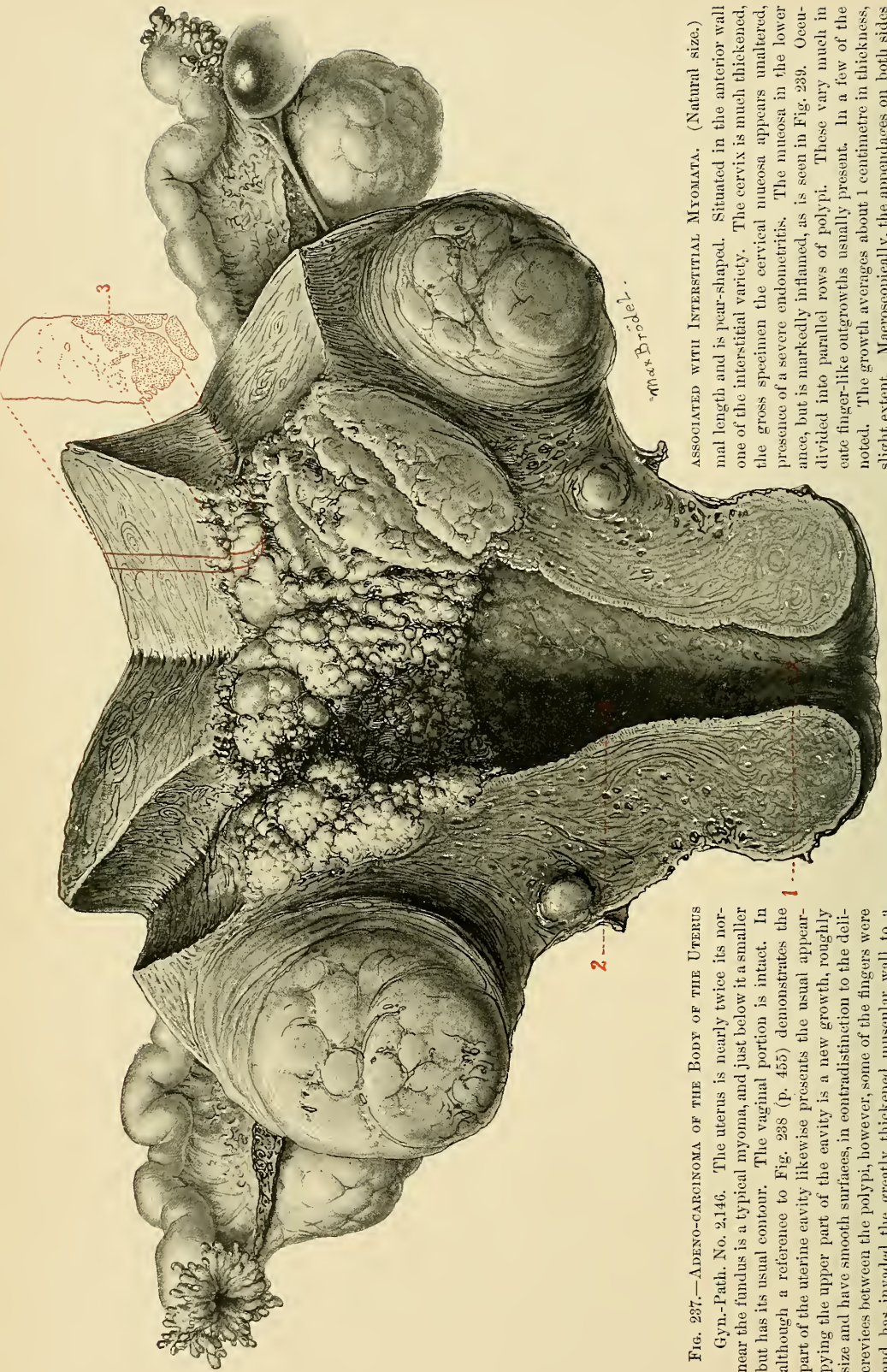


FIG. 237.—ADENO-CARCINOMA OF THE BODY OF THE UTERUS

Gyn.-Path. No. 2,146. The uterus is nearly twice its normal length and is pear-shaped. Situated in the anterior wall near the fundus is a typical myoma, and just below it a smaller but has its usual contour. The vaginal portion is intact. In although a reference to Fig. 238 (p. 455) demonstrates the part of the uterine cavity likewise presents the usual appearance, but is markedly inflamed, as is seen in Fig. 239. Occupying the upper part of the cavity is a new growth, roughly size and have smooth surfaces, in contradistinction to the delimitations between the polyphi, however, some of the fingers were and has invaded the greatly thickened muscular wall to a degree which appeared to be normal, but the right tube was found to be the seat of an acute salpingitis, although the fibrinated extremity was patent. From point 1, Fig. 238 is taken. From point 2, Fig. 239 is taken. From point 3, Fig. 240 is taken. It is quite possible that the streptococcus peritonitis developed from the acute salpingitis or from the pronounced endometritis,

ASSOCIATED WITH INTERSTITIAL MYOMATA. (Natural size.)

mal length and is pear-shaped. Situated in the anterior wall one of the interstitial variety. The cervix is much thickened, the gross specimen the cervical mucosa appears unaltered, presence of a severe endometritis. The mucosa in the lower uterine cavity is markedly inflamed, as is seen in Fig. 239. Occasional finger-like outgrowths usually present. These vary much in size, but averages about 1 centimetre in thickness, slight extent. Macroscopically, the appendages on both sides were patent. From point 1, Fig. 238 is taken. From point 2, Fig. 239 is taken. From point 3, Fig. 240 is taken. It is quite possible that the streptococcus peritonitis developed from the acute salpingitis or from the pronounced endometritis,

Max Brodel.

margin of the growth many delicate finger-like processes are visible. The downward extension of the tumour is sharply defined, the growth overlapping the mucous membrane. On an average it is 1 centimetre in thickness, and has

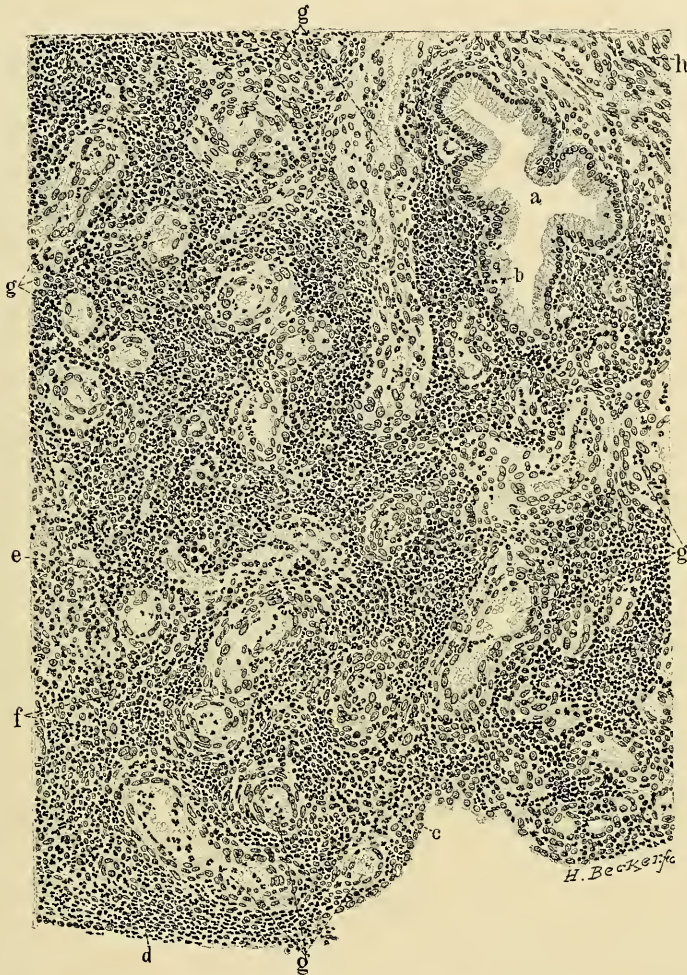


FIG. 238.—CERVICAL ENOMETRITIS OCCURRING IN A CASE OF ADENO-CARCINOMA OF THE BODY OF THE UTERUS. (125 diameters.)

Gyn.-Path. No. 2,146. The section is taken from Fig. 237 at point *l*. The convoluted cervical gland, *a*, is lined by one layer of characteristic high cylindrical epithelium, which gives us a clue as to its origin. Between the epithelial cells (*b*) are a few polymorphonuclear leucocytes. *c* is the flattened surface epithelium, but at *d* this has entirely disappeared, and the surface is covered by many polymorphonuclear leucocytes. Scattered everywhere through the tissue are myriads of polymorphonuclear leucocytes, to be recognised by the horseshoe-shaped nuclei. They are especially abundant at *e*. *f* indicates two stroma cells characterized by oval, vesicular nuclei, and a pale protoplasmic zone surrounding them. Scattered everywhere throughout the field, and occupying fully one third of the section, are longitudinal and cross sections of blood-vessels (*g*). The endothelial linings, as well as the cells forming the walls, have swollen nuclei. *h* is the normal stroma of the cervix.

Were it not for the gland (*a*), the normal stroma (*h*), and the partially preserved surface epithelium (*c*), this section might readily be taken as representing the wall of an abscess, consisting as it does of practically nothing more than granulation tissue.

extended for about 3 to 4 millimetres into the uterine wall. On section, the tissue of the new growth is seen to be somewhat friable. The uterine mucosa in the lower part of the cavity is smooth, but slightly undulating.

The right tube is apparently normal. The ovary is of the usual size, and is covered over by many delicate adhesions.

The left tube presents the usual appearance, but just beneath the fimbriated extremity is a transparent cyst, 1.5 centimetres in diameter. The ovary is normal in size, and is covered by many delicate adhesions.

Histological Examination.—The squamous epithelium covering the outer part of the vaginal portion of the cervix is intact, but here and there, just beneath the surface, the capillaries are considerably increased in number, and the tissue shows much small-round-cell infiltration. Nearer the external os the surface epithelium shows polymorphonuclear infiltration and then suddenly disappears, the underlying tissue containing dilated arteries and many small round cells. At the external os all trace of epithelium has disappeared, and the appearances immediately suggest granulation tissue (Fig. 238), the surface being covered by polymorphonuclear leucocytes, and the underlying tissue consisting of numerous capillaries, many small round cells, and an abundance of polymorphonuclear leucocytes. On passing up the cervical canal the same evidences of inflammation are present. The glands are greatly diminished in number, but, where present, show little alteration. Their epithelium is somewhat swollen; pus cells have wandered in between the epithelial elements, and some of the gland cavities are full of them. Near the internal os the glands are normal in their deeper portions, but the superficial part of the mucosa here also is recognisable as granulation tissue.

The mucosa in the lower part of the uterine cavity is profoundly altered. The glands have in most places disappeared, but, where present, show little change. The mucosa is represented by granulation tissue (Fig. 239). Its capillaries are very abundant, show a swollen endothelium, and are surrounded by one or more layers of cells, having oval, vesicular nuclei and an abundant protoplasm. The tissue between the capillaries is composed wholly of small round cells. The surface is covered by a few polymorphonuclear leucocytes. The muscle immediately beneath shows a slight small-round-cell infiltration and a marked dilatation of the veins. Where the new growth commences, the surface is covered by many layers of polymorphonuclear leucocytes, while the growth itself consists of glands taking on almost every conceivable form, isolated and round examples being sometimes visible, while in other places they are longitudinal. At many points, however, there are areas composed of numerous glands lying side by side, and not separated from one another by any stroma. Other portions of the growth present a distinctly papillomatous appearance; from a central stem come off delicate secondary terminals, both the main trunk and the branches being covered by one or more layers of epithelium. In some places longitudinal sections of glands lie side by side, not being separated from one another by any stroma (Fig. 240). Under the low power such areas bear a striking resemblance to bands of syncytium, but the nuclei do not stain deeply, nor does the pro-

toplasm take on a brownish tinge. With the higher powers it is frequently possible to differentiate the cells from one another. In the older portions of the growth the epithelial cells have proliferated and form solid masses, looking not unlike squamous epithelium. The epithelial cells, which for the most part are uniform in size, are cylindrical in form, and have oval, vesicular nuclei, some of

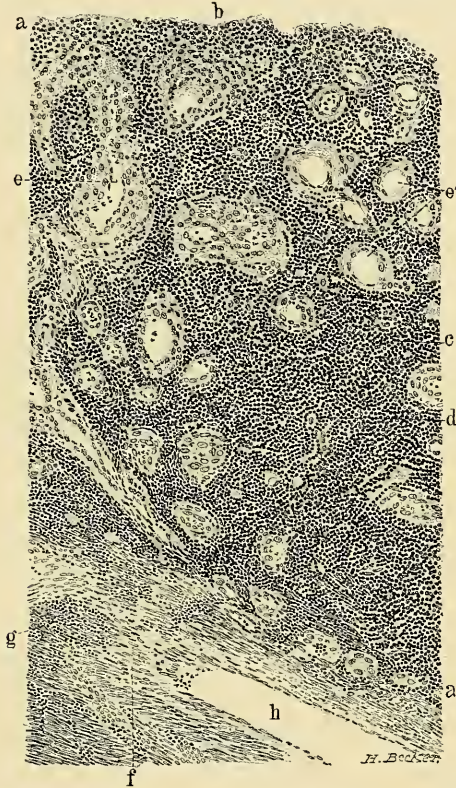


FIG. 239.—CHRONIC ENDOMETRITIS IN A CASE OF ADENO-CARCINOMA OF THE BODY OF THE UTERUS.
(100 diameters.)

Gyn.-Path. No. 2,146. The section is from Fig. 237 at point 2. The area from *a* to *a* represents the mucosa. *b* is the surface, but no trace of the surface epithelium remains. The stroma from the surface to the muscle consists almost entirely of small round cells, particularly abundant at *c*. *d* is one of the few normal stroma cells still remaining, and is recognisable by its wide zone of protoplasm and its vesicular nucleus. *e* is one of the numerous blood capillaries cut obliquely. Both its endothelial lining and the cells composing its wall are swollen. *e'* indicates similar vessels on cross section. *f* is the normal uterine muscle. At *g* the muscle shows considerable small-round-cell infiltration. *h* is a vein.

From this section we see that all the component parts of the normal mucosa, the surface epithelium, glands, and stroma have disappeared, being replaced by granulation tissue. The condition is one of chronic endometritis.

which contain nuclear figures. In the older portions of the growth the surface is covered by polymorphonuclear leucocytes, which also partially fill the gland lumina and have wandered in between the individual cells. Where the papillary arrangement is present, the delicate stems supporting the epithelium frequently consist of nothing more than the endothelial walls of the delicate capillaries supplying them. In the deeper portions of the growth the stroma to a great extent

consists of non-stripped muscle fibres, showing much small-round-cell and some polymorphonuclear infiltration. The uterine muscle along the advancing margin of the growth shows much small-round-cell infiltration, which is also present in localized areas in the deeper portions of the connective tissue between the muscle bundles. The growth is a typical adeno-carcinoma.

The myoma situated in the body of the uterus consists of non-stripped muscle fibres cut in various directions. It shows much hyaline degeneration, but does not appear to have been invaded by the carcinoma.

The right tube at the uterine cornu shows slight changes. Its epithelial cells are somewhat swollen; between them are polymorphonuclear leucocytes and small round cells, while the underlying stroma shows some small-round-cell infil-

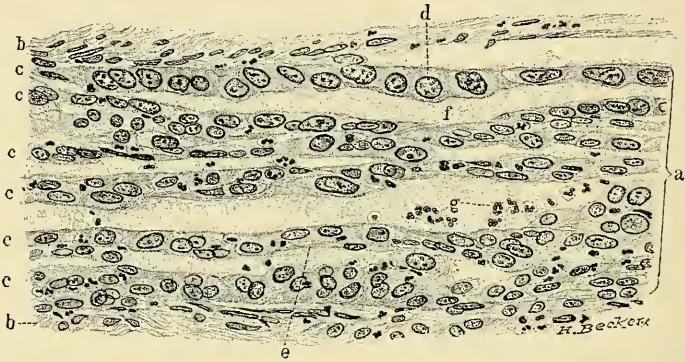


FIG. 240.—PARALLEL GLANDS IN ADENO-CARCINOMA OF THE BODY OF THE UTERUS BEARING SOME RESEMBLANCE TO SYNCYTIAL RIBBONS IN DECIDUOMA MALIGNUM. (210 diameters.)

Gyn.-Path. No. 2,146. The picture is from Fig. 237 at point 3. *a* represents the epithelial elements divided into six more or less parallel rows of cells (*c*). At *d* a faint line of division between the individual cells can be made out, but at *e* it looks as though we had a homogeneous mass of protoplasm with nuclei scattered throughout it, as in syncytium. On tracing the epithelium to the right and left of *e*, however, the division into individual cells can be made out. The nuclei of the epithelial cells vary much in size and are vesicular. In syncytium they usually stain deeply. In the gland spaces, indicated by *f*, is a somewhat granular material, probably coagulated serum. At *g* one of the glands contains polymorphonuclear leucocytes. *b* is the stroma of the growth. Scattered throughout it also are polymorphonuclear leucocytes. Other portions of the same section from which this drawing was taken presented the typical picture of an adeno-carcinoma.

tration. In its middle portions it shows an intact epithelium, which is somewhat irregular, and contains a few pus cells and small round cells between its elements. There is marked small-round-cell infiltration of some of its folds, and the lumen is completely filled with polymorphonuclear leucocytes. The outer surface of the tube is partially enveloped in dense vascular adhesions. The ovary is covered by delicate vascular adhesions, but is otherwise normal.

The left tube is normal. The ovary itself shows no changes, although it is covered by numerous fine adhesions.

Diagnosis.—Chronic endometritis both of the body and cervix. Adeno-carcinoma of the body of the uterus; interstitial myomata. On the right side, acute salpingitis and slight peri-oöphoritis. On the left side the tube is normal, but there is slight peri-oöphoritis.

ADENO-CARCINOMA OF THE BODY, INTERSTITIAL MYOMA, AND SUBPERITONEAL
ADENO-MYOMA IN THE SAME UTERUS

The following case is of interest on account of the occurrence of the three pathological conditions in the same organ. Myomata associated with adeno-carcinoma of the body of the uterus are common, and our literature on adeno-myoma of the uterus is constantly increasing. The simultaneous presence of the three growths must be looked upon as a mere coincidence.

Gyn. No. 5,782

Adeno-carcinoma of the body of the uterus (Fig. 241). Small myoma in the anterior wall; small adeno-myoma in the posterior wall. Hysterectomy. Histological picture showing a well-preserved glandular arrangement of the growth (Fig. 242).

Rapid enlargement of the inguinal, axillary, and cervical lymph glands; death twenty months after operation.

M. K., aged fifty-six. Admitted January 12, 1898, complaining of pain in the lower abdomen.

The menses were irregular, occurring at intervals of from two to six weeks; they were painful, and lasted from three to seven days. They ceased four years ago. About a year and a half ago a bloody discharge was noticed, which at times was clotted. During the last six months it has been frequent, but at no time has it been offensive. The patient has been married twenty-one years; she has had one child, and no miscarriages. She has never been very strong, and during the past year has had severe pain in the lower abdomen, extending down the legs. At present the bowels are constipated.

On January 12th the cervix was dilated, and a small amount of tissue was removed for examination. On January 14th an examination under ether showed that the uterus was slightly enlarged, but freely movable. Two nodules could be felt on the posterior surface.

Gyn.-Path. No. 2,075. The specimen consists of a considerable amount of curettings. The tissue is composed of small pieces, which do not present the smooth, glistening surface of normal mucosa, but are finely granular, or show minute papillary-like outgrowths.

Histological Examination.—All trace of normal uterine mucosa is lacking. Along one margin of the scraping delicate stems of stroma are seen with glands developing along their sides. These glands are irregular, cut lengthwise or transversely, and are lined by several layers of cylindrical epithelium. The epithelial cells are fairly uniform in size; they stain relatively deeply, and contain nuclear figures. At these points the glandular arrangement is sharply defined, but in other parts the cells tend to form a homogeneous mass, take the dye only faintly, and thus stand out in sharp contrast to the deeply staining glands. Even when the cells form large masses, evidences of the gland-like

arrangement are still visible. The epithelial cells are remarkably uniform in size. The case is one of adeno-carcinoma of the body of the uterus.

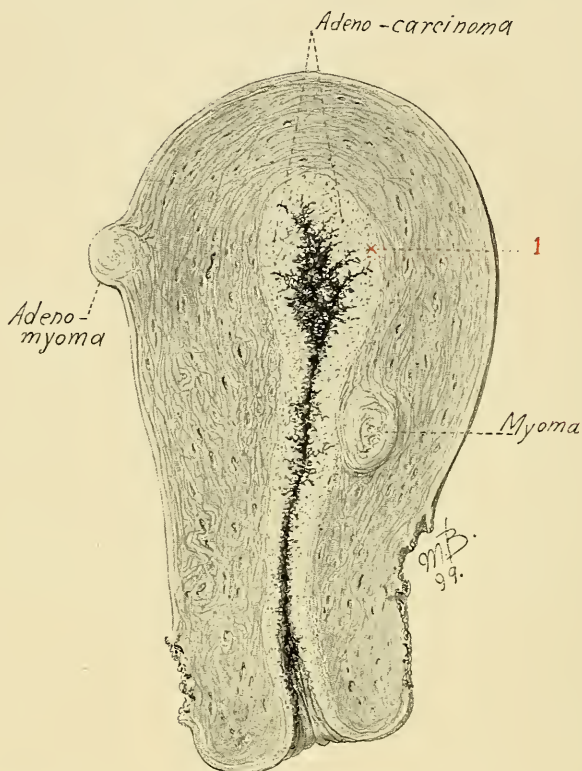


FIG. 241.—ADENO-CARCINOMA OF THE BODY OF THE UTERUS ASSOCIATED WITH A SMALL SUBPERITONEAL ADENO-MYOMA. (Natural size.)

Gyn.-Path. No. 2,084. The uterus is of normal size. The left half appears in the figure. Attached to the posterior surface near the fundus is a small subperitoneal myoma, which, on histological examination, is found to contain mucosa resembling that of the uterus. In the middle of the anterior wall is a small interstitial myoma. The cervix is intact. The mucosa in the lower part of the cervical canal is normal, but that of the body is replaced by a new growth. The inner surface presents an eaten-out appearance, due to the finger-like growths; the growth itself is light in colour and appears to be friable. It does not seem to penetrate the uterine walls very far, but, as the subsequent history shows, the case was one of the most malignant in our series. It is rather interesting to find a myoma, an adeno-myoma, and an adeno-carcinoma of the body of the uterus in the same patient.

The specimen contains no muscle. The epithelial cells are fairly uniform in size, but the diagnosis is easily established on account of the presence of the finger-like outgrowths, with glands developing on their sides, and from the fact that the gland epithelium in many places has proliferated, forming solid, or partially solid, cell-nests. Hysterectomy is advised.

Operation. Pan-hysterectomy.

The uterus was removed in the usual way. The patient made a good recovery, and was discharged February 15, 1898.

Gyn.-Path. No. 2,084. The specimen consists of the uterus with the appendages. The uterus is 8 centimetres in length, 5.5 centimetres in breadth, and 5 centimetres in its antero-posterior diameter. Its surface is deep red in colour and free from adhesions, but projecting from the posterior portion is a small firm nodule, 1.2 centimetres in diameter (Fig. 241). The outer surface of this nodule is covered by a calcareous plate, 2 millimetres in thickness. On section, the growth is found to be continuous with the uterine muscle, with which it is intimately associated, the sharp line of demarcation so characteristic of myomata being wanting. The calcareous deposit has extended into the nodule at one point. The cervical canal is 3 centimetres in length; its mucosa is finely granular and slightly injected. The uterine cavity is 5 centimetres long and 4 centimetres in breadth at the fundus. The mucosa in the lower portion of the cavity is roughened and granular. On passing farther upward it is found to be thicker and more furrowed; the upper half of the cavity is occupied by a new growth, consisting of papillary masses, varying from 1 to 6 millimetres in size. These tree-like growths consist of delicate papillæ, which often show secondary branching. Some of the papillæ are glistening and semi-translucent, others are yellowish and opaque, while not a few are deeply injected. The growth has extended for 8 or 10 millimetres into the uterine muscle. The deeper portions consist of a fibrillated waxy material, which is sharply differentiated from the surrounding muscle. The growth has invaded the muscle more deeply on the left side. Downward it reaches to within 1 centimetre of the internal os.

The appendages are senile, and offer nothing of importance.

Histological Examination.—The vaginal portion of the cervix is practically normal. The folds of the mucosa lining the cervical canal present the usual appearance. The surface epithelium is to a great extent intact, and the underlying glands are normal.

Sections from the body of the uterus show that the greater part of its cavity is occupied by a neoplasm. Along the advancing margin this appears in the form of irregularly branching outgrowths, consisting of delicate stems of stroma, covered by one or more layers of cylindrical epithelium. On passing toward the older portions of the growth this papillary-like arrangement becomes much more complex. In the deeper portions the glandular arrangement is much more in evidence, and along the advancing margin, where the growth has penetrated the muscle, large bunches of glands are seen. As noted in the description of the scrapings, the gland-like arrangement in many places is perfectly preserved, and the epithelial cells are remarkably uniform in size (Fig. 242). In some places the stroma is fairly abundant, but at other points is only just sufficient to support the delicate blood-vessels. The preservation of the glands, which show practically no coagulation necrosis, is rather remarkable, and is more probably due to their slight deviation from the normal rather than to any increase in the blood supply, since the latter is by no means abundant. Along the advancing margin of the growth the muscle shows small-round-cell infiltration.

The small nodule situated on the posterior uterine wall consists of non-stripped muscle fibres cut in various directions. Its blood-vessels are few in number, and frequently show obliteration. At a few points, 2 or 3 millimetres beneath the peri-

toneal covering, are deeply staining areas, at first sight suggesting small-round-cell infiltration, were it not for the fact that they are too sharply circumscribed and that with the higher powers it is impossible to distinguish them from the stroma cells of the uterine mucosa. Some of these areas contain glands, irregular or elongate in form, and lined by one layer of low cylindrical epithelium on which cilia can sometimes be demonstrated. Some of the gland cavities contain desquamated epithelium; others inclose a varying amount of blood. The nodule

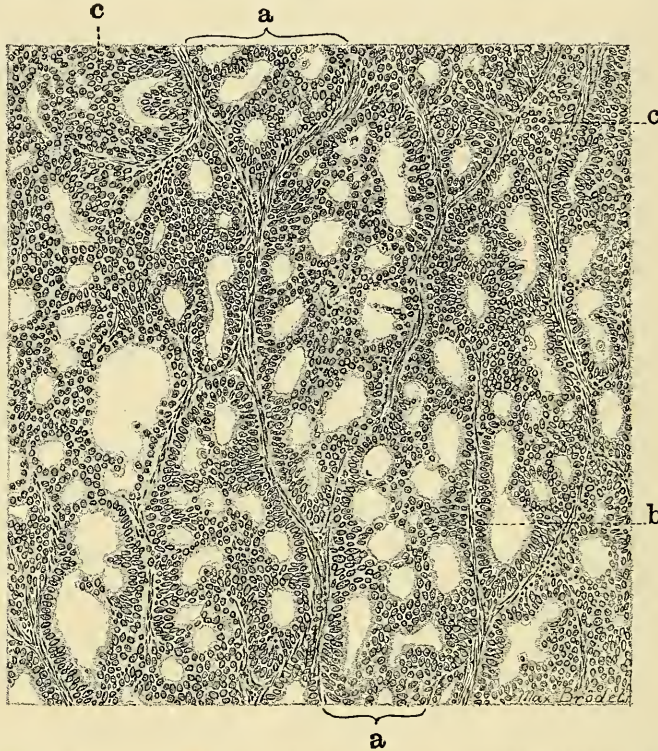


FIG. 242.—ADENO-CARCINOMA OF THE BODY OF THE UTERUS SHOWING REMARKABLY WELL-PRESERVED GLANDS. (100 diameters.)

Gyn.-Path. No. 2,084. The section is taken from Fig. 241 at point *I*. We may look upon this field as representing a sea of glands divided into groups (*a* and *a*) by delicate strands of stroma (*b*). The stroma often consists of but two layers of spindle-shaped cells, which are in reality the endothelial lining of delicate blood capillaries. The glands are very uniform in size, and are lined by cuboidal epithelium. A gland is frequently separated from its neighbour of the same group by several layers of epithelium without any stroma. In some places the epithelium forms solid nests, as at *c*. The nuclei of the epithelial cells in this particular section are vesicular, and very uniform in size. It is unusual to find no necrosis when the stroma is so scant.

In this case the grouping of the glands is sufficient to justify the diagnosis of adeno-carcinoma, although the cells are very uniform in size. As a matter of fact, this growth appears to have been one of the most malignant in our series.

is a myoma. The glands and their surrounding stroma resemble more or less the uterine mucosa. We are dealing with a small subperitoneal adeno-myoma.

Sections from the tubes show nothing abnormal.

Both ovaries contain a few small gland-like spaces, but are otherwise normal.

Diagnosis.—Adeno-carcinoma of the body of the uterus associated with subperitoneal adeno-myoma.

Dr. J. W. Hobach, of Baltimore, writes me that about May, 1899, the patient complained of pain and slight hæmorrhage. In August she had an attack of violent pain, with constipation, followed later by diarrhœa. She died unexpectedly, September 20th. There was no loss of weight, no cachexia, but toward the last a very rapid enlargement of the inguinal, axillary and cervical glands was observed. Death took place about twenty months after the operation.

MULTIPLE UTERINE MYOMATA, ADENO-CARCINOMA OF THE BODY OF THE UTERUS, AND PAPILLO-CYSTOMA OF BOTH OVARIES IN THE SAME INDIVIDUAL

This is certainly a rich pathological finding, and one that will rarely be met with. In the present case the clinical signs and bimanual examination pointed entirely to myomata, although the coexistent adeno-carcinoma of the body of the uterus was far advanced, and had given rise to widespread metastases. Of course, the small cystomata of both ovaries were completely obscured by the overlying, partly calcified myomata, so that they could not be palpated either from above or below. From the ovarian growths extension had taken place to the inguinal glands. Thus, in this uterus there were many benign tumours and two distinct malignant processes, each with its characteristic secondary growths.

Gyn. No. 6,439

Subperitoneal and interstitial uterine myomata (Figs. 243 and 244). Adeno-carcinoma of the body of the uterus with secondary growths on the peritoneum and in the omentum, mesentery, liver, pancreas, left adrenal body, pleurae, and lungs. Papillo-cystomata of both ovaries, with extension by continuity to the corresponding inguinal glands. Hydrosalpinx in the inner part of the left tube due to a kink, the fimbriated extremity being patent.

M. H., aged sixty; coloured. Admitted October 14, 1898, complaining of an abdominal tumour, accompanied by general weakness.

The patient has been married twenty-seven years, has had no children, and no miscarriages. Menstruation commenced at twelve, was usually regular, lasting from three to seven days, and was always excessive. At forty-one the flow ceased. One year ago a hæmorrhagic discharge commenced, and has been practically continuous. For many years there has been an irritating leucorrhœal discharge. The family history and her previous record are unimportant.

About ten years ago the patient noticed a lump, about the size of an egg, in the left lower abdomen. This was not painful and caused no inconvenience. In August, 1897, the same nodule, although not enlarged, became quite tender, and the patient noticed that the abdomen at times was somewhat distended. As noted above, uterine hæmorrhages commenced at this time. The abdominal pain has been more or less constant of late, sometimes dull and aching in character,

at other times sharp and cramp-like. There has been considerable swelling of the lower extremities and shortness of breath. At present she is an apparently strong, well-nourished woman; her temperature is 100.3° F.; the pulse is 116. The bowels are constipated, and both defecation and micturition are painful. The lungs and heart are apparently normal.

October 16th. The abdomen is much enlarged, and just above the umbilicus measures 115 centimetres in circumference. The most prominent point lies midway between the umbilicus and the ensiform cartilage. The abdominal wall just above the pubes is much thickened and pendulous. The distance from the umbilicus to the pubes is 18 centimetres; from the umbilicus to the ensiform cartilage, 27 centimetres; from the right anterior superior spine to the umbilicus, 32 centimetres; from the left anterior superior spine to the umbilicus, 32 centimetres.

Vaginal examination. The labia are large and flabby. The vaginal outlet admits two fingers, and it is just possible to touch the tip of the cervix, which lies far back, and is apparently continuous with the tumour filling the abdomen. Occupying the left groin is an immovable mass, 6 × 3 centimetres. This has a somewhat elastic feel, and reminds one of metastases.

Operation, October 17, 1898. Partial excision of the glands in the left inguinal region. Prior to opening the abdomen, Dr. Stokes thought it advisable to explore the mass in the left inguinal region. As soon as an incision had been made through the skin over the most prominent portion of the tumour, a thin, watery fluid escaped. Still deeper, small cysts, lined by a pale, glistening membrane, were found, and in the deepest portions many of these cysts contained papillomatous masses. On finding this condition associated with the large abdominal tumour, it was deemed advisable to abandon any further operation. A small drain having been placed in the lower angle of the wound, the latter was closed. The patient recovered satisfactorily from the effects of the slight operation, so that on October 29th she sat up in a wheel-chair. The lower extremities gradually became edematous,

FIG. 243.—A LARGE MYOMATOUS UTERUS CHOKING THE PELVIS. SMALL OVARIAN CYSTS ON BOTH SIDES. THICKENING AND RETRACTION OF THE OMENTUM. METASTASES IN THE LIVER, SECONDARY TO AN ADENOCARCINOMA IN THE BODY OF THE UTERUS. (1/2 natural size.)

Gyn.-Path. No. 2,808. Autopsy 1,220. The figure shows the appearance of the abdominal cavity as seen at autopsy. Filling the pelvis, and projecting into the general cavity, is a large, irregular myomatous uterus. (See Fig. 244.) Springing from the surface of the organ are large and small subperitoneal myomata. The right tube is seen passing upward in a depression between several of the largest myomata. On the right side the edge of a small ovarian cyst is seen. On the left are two cysts springing from the left ovary. The lower one has very thin walls and is translucent. On the left, a loop of the small intestine has dropped down and become firmly adherent to the growth in the left inguinal region. Studding the mesentery of the small intestines are minute whitish nodules, which are secondary growths from the adeno-carcinoma in the body of the uterus. (See Fig. 244.) The tip of the vermiform appendix is also embedded in carcinomatous nodules. As a result of cancerous infiltration, the omentum is drawn up and forms a dense mass between the stomach and transverse colon, and just below the gall-bladder the adipose tissue is also greatly involved. Studding the right lobe of the liver are five carcinomatous nodules, one of which, even in the reduced drawing, is more than a centimetre in diameter. All are sharply defined, whitish in colour, and are slightly umbilicated. There were also minute nodules both in the substance and on the surface of the organ. The hepatic nodules were secondary to the carcinoma of the uterus.

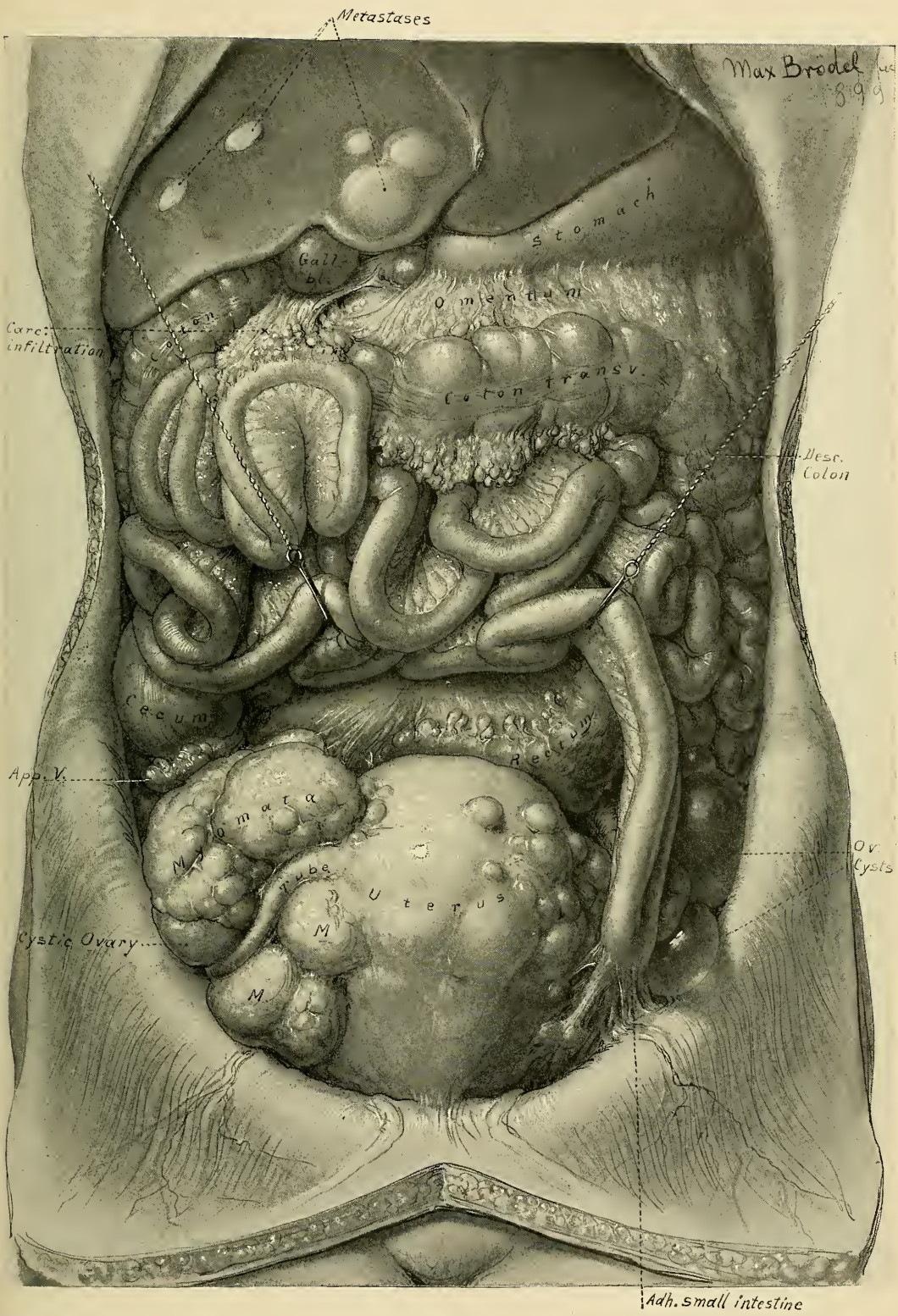


FIG. 243.

and there were numerous eructations of gas. She grew weaker, and died on December 17th. The urine, on admission, was normal.

Autopsy No. 1,220. December 17, 1898. The body is 163 centimetres long; rigor mortis is not marked. There is an extreme degree of œdema of the lower extremities and of the trunk as far as the shoulders. The abdomen is markedly distended, and fluctuation can be elicited. Filling the lower part of the abdomen is a large tumour mass, while an oval, deeply-seated tumour is found in the left inguinal region (Fig. 243). The body presents an anæmic appearance; the muscles are very pale, but an abundance of adipose tissue is present. The peritoneal cavity contains about 3,000 cubic centimetres of fairly transparent, yellow fluid. The parietal peritoneum has lost its glistening appearance, and over a large area is covered by rough, irregular, translucent deposits; this condition is especially marked over the diaphragm and on the right side. The bowels are very much contracted throughout their entire extent, and the small intestines average from 1.5 to 2 centimetres in diameter. Studding the mesentery of the small intestines are many small white tumour metastases; the mesentery itself varies from 5 to 6 millimetres in thickness. On the left side a loop of the ileum is adherent to the large tumour filling the lower part of the abdomen. The omentum is drawn up and contracted into a firm mass between the stomach and transverse colon. It everywhere contains tumour deposits. Attached to the rolled-up omentum is a loop of the ileum, which makes it appear as if the transverse colon passes through a canal. The ascending and descending colon are firmly adherent to the posterior abdominal wall, being bound down by tumour metastases. Studding the intestine at various points are small tumour nodules.

The pericardial cavity contains a slight excess of clear yellow fluid, but there are no adhesions. The heart muscle is rather pale and soft; its vessels are tortuous. The coronary arteries contain yellow patches of atheroma. The pleural cavities, each of which contains 400 cubic centimetres of clear yellow fluid, are free from adhesions; small translucent nodules are found on the costal pleuræ.

Both lungs are emphysematous, and at their bases show marked œdema. Scattered throughout both lungs are yellowish-white tumour masses, some reaching 1 centimetre in diameter. The arteries of the right lung contain several definite, organizing thrombi.

The spleen weighs 70 grammes; attached to its surface are a few translucent tumour masses; its substance shows nothing of interest.

The liver is rather small, measuring approximately $25 \times 16 \times 9$ centimetres. It is pale, the surface is fairly smooth, but studding the organ are several irregularly circular nodules, whitish in colour, translucent, and somewhat umbilicated (Fig. 243). Several of the nodules are cystic, and the cyst spaces contain a clear reddish fluid. Numerous nodules and cyst-like spaces, having corrugated walls, are scattered throughout the substance of the organ. There are numerous minute nodules both on the surface and in the substance of the liver. On the under aspect of the liver the nodules are surrounded by areas of congestion.

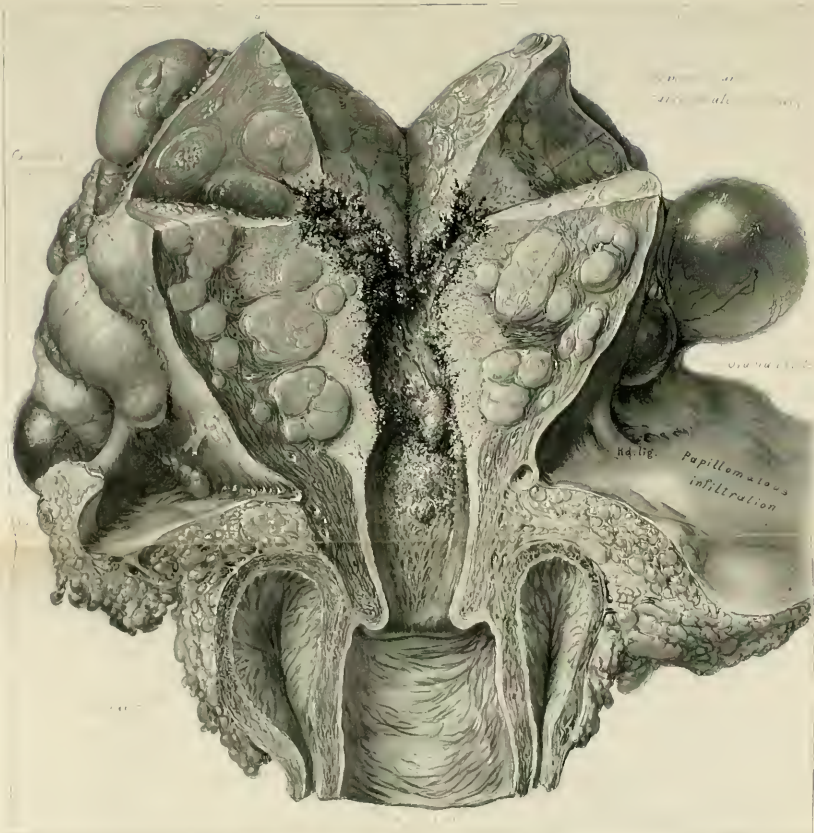

FIG. 244.—AN ENLARGED MYOMETRIUM LIKE K. ABDON. (FROM THE COLLECTION OF THE LIVER.) PAPILOMATA OF BOTH OVARIES WITH EXTENSION BY CONTINUITY TO THE INGUINAL GLANDS. (74, natural size.)

FIG. 244. No. 2200. Antopsy, 1890. The bladder is contracted, but normal. The uterus is much enlarged, irregularly pear-shaped, and lies springing from its surface a mass of papillomatous nodules which are calcified. The uterine walls are greatly thickened. They contain many small interstitial myomata. The vaginal mucosa is normal, and the vaginal portion of the cervix presents the usual appearance. The cervical mucosa in the lower part is unaltered, but near the internal os the mucosa covering the posterior wall is uneven and roughened, owing to the many minute finger-like processes springing from the surface. In the body of the uterus the normal mucosa is no longer recognizable, being replaced by a ragged-looking growth, from the surface of which spring myriads of delicate finger-like processes. The growth is whitish in colour, friable in appearance, and has invaded the uterine muscle to a marked degree; in places it completely encircles the myomata nodules. At another level it was found penetrating some of the myomata, and had extended almost to the peritoneal surface a distance of fully 5 centimetres. On the right side a small portion of an ovarian cyst can be seen. Springing from the outer and inner surfaces of these myomata are papillary masses, the papillary growth extending by continuity to the inguinal glands. On the left side is a small multilocular ovarian cyst, from the inner surface of which arise papillary growths. The marked thickening and infiltration of the left inguinal region is due to papillary growths from the left ovary. A section through this thickened area would show large and small cyst-like spaces containing tree-like ingrowths.

The periportal lymph glands apparently contain metastases. The gall-bladder is distended, evidently owing to pressure at its neck, resulting from involvement of the adjacent lymph glands.

Both kidneys present the usual appearance, but on the surface of the right kidney is a small tumour nodule, 2 millimetres in diameter. The ureters are normal in size. The right adrenal is apparently normal, but the left, about its middle portion, contains a translucent tumour nodule, 1 centimetre in diameter. The pancreas is enveloped in adhesions, and at its tail contains a small tumour nodule. The stomach at the pyloric orifice is surrounded and compressed by a mass of enlarged glands; the greater curvature is intimately adherent to the tumour mass lying between it and the transverse colon. The vermiform appendix, in its last 2 centimetres, is entirely occluded by secondary growths. The external iliac vein on the left side shows a partial thrombosis; many of the veins below Poupart's ligament are also thrombosed. The right femoral vein is completely occluded by a firm thrombus, pale brown in colour.

In the inguinal regions the larger tumour masses are intimately connected with the veins; the mass on the left side is the larger, and is composed of many cysts of considerable size, from which a slightly turbid fluid escapes. The mass on the right side is much firmer. The thyroid gland on both sides of the median line is much enlarged. A lymph gland in the anterior axillary line, 10 centimetres below the axilla, contains a cystic tumour. The bone-marrow of the femur is dark red in colour, but fairly firm. The brain and cord are apparently normal.

Gyn.-Path. No. 2,808. The specimen consists of the pelvic contents and of tissues from the inguinal regions. The vagina presents the usual appearance, and the vaginal portion of the cervix is unaltered. The uterus measures $18 \times 16 \times 13$ centimetres (Fig. 244). The anterior surface, fundus, and posterior wall are studded with myomatous nodules, varying in size from that of a pea to 7 centimetres in diameter. Nearly all of the nodules are sessile. Attached to the posterior surface of the uterus are several broad fan-like adhesions. The uterine walls vary from 5 to 6 centimetres in thickness, owing to the presence of myomatous nodules, which are sharply circumscribed, and can be readily shelled out. One of them encroaches to a slight extent on the uterine cavity. The cervical canal is rather short, but the mucosa presents the usual appearance. The uterine cavity is 12 centimetres in length, and the mucosa in the lower part has a slightly granular appearance, due to short finger-like outgrowths. In its upper portion the cavity shows no normal mucosa. The walls are somewhat ragged and are involved in a new growth, which in places infiltrates the tissue to a depth of at least 5 centimetres, penetrating the entire thickness of the uterine wall. The growth consists of delicate trabeculae, in the meshes of which is a fine crumbly material.

The right tube is 9 centimetres in length, considerably curved, and throughout the greater part of its course lies in a depression between myomatous nodules. It averages 1 centimetre in diameter, and has a patent fimbriated extremity. The ovary is converted into a semi-cystic tumour, 6 centimetres in diameter. Its outer surface is in places covered by adhesions, but springing from it at several points are delicate papillary projections or warty outgrowths. On section, the tumour to a great extent is seen to be made up of large and small thin-walled cysts.

The semi-solid portion consists in a great measure of a somewhat friable papillary growth, which projects into the cyst cavities. The contents of the smaller cysts are gelatinous.

The left tube is 8 centimetres in length, averages 8 millimetres in diameter, and terminates in an occluded fimbriated extremity. Its outer surface is covered by dense adhesions binding it to the posterior surface of the uterus. On more careful examination it is found that the point of occlusion is situated a short distance from the fimbriated extremity of the tube, and that the fimbriae are free; thus we have a hydrosalpinx, and at the same time a patent outer extremity. The occlusion is due to dense adhesions.

Springing from the outer pole of the ovary is a smooth-walled cyst, 5 centimetres in diameter; its walls vary from 1 to 2 millimetres in thickness; its inner surface is for the most part smooth, but over an area 2.5×2 centimetres, and corresponding to the ovarian attachment, are clusters of papillary masses projecting into the cavity, while springing from the small portion of the ovary that remains there are also similar outgrowths.

The bladder mucosa presents the usual appearance, and no changes can be noted in the rectum. Both broad ligaments are markedly thickened; the areas of induration can be traced down to, and are directly continuous with, the growths in the inguinal regions. On pressure they are somewhat elastic. The inguinal growth on the left side, on section, is found to consist of cyst-like spaces, some fully 5 centimetres in diameter, which contain a gelatinous material. Springing from the partitions between the cysts are complicated papillary outgrowths. Such sections remind one very much of a papillo-cystoma of the ovary.

Histological Examination.—The high cylindrical epithelium in the lower part of the cervical canal presents the usual appearance, and the cervical glands are normal. In the upper part of the cervix there is some flattening of the epithelium, and in the vicinity of the internal os the stroma of the mucosa contains some irregular glands having atypical epithelium. The nuclei of some of these cells are considerably enlarged and stain deeply. Just within the internal os all trace of the normal mucosa is lost. The surface epithelium is missing; the stroma as such is scarcely visible, and the mucosa in the vicinity of the cavity is infiltrated by branching glands, some of which can be seen opening out upon the surface, while others on cross section appear as little tubules. A short distance farther up the cavity little tree-like outgrowths are seen springing from the surface; these are covered for the most part by one layer of epithelium, the individual cells varying greatly in size. Some are cylindrical, and have oval, somewhat deeply staining nuclei; others have elongate oval, or very large round nuclei, while still others contain very large irregular masses of chromatin, which stain intensely. The stems of these papillary projections consist of spindle-shaped cells having elongate nuclei. Many of the projections near the surface have been cut across, and appear as little islands of connective tissue, surrounded by one layer of epithelium. On passing toward the centre of the cavity the process is seen to be limited entirely to the endometrium. The papillary arrangement is not so evident, but tubular and branching glands are everywhere seen opening on the surface, and the glands show a marked tendency to preserve their lumina. The superficial portions of the glands are necrotic, but their contours

are still perfectly preserved. In the upper part of the cavity the epithelial elements have run riot, penetrating the uterine muscle as far as the peritoneal covering. The portions lining the uterine cavity have to a great extent become necrotic, but this dead tissue contains many very large venous sinuses. Penetrating the muscle in all directions are glands which are frequently branched, appear as tubules, and, on cross section, are round. The gland epithelium in this part of the uterus is fairly uniform in size, but the nuclei stain intensely. In many places the epithelium has proliferated or become desquamated, forming loosely packed cell-nests, many of which are necrotic. It is interesting to note the invasion of the uterine muscle in the vicinity of the myomata. The carcinoma has invaded the muscle as far as the myoma, but the latter, in the majority of instances, has formed an effectual barrier to the further progress of the disease. At several points, however, the growth has penetrated the myomata, and in one place at least, carcinomatous glands are seen lying a short distance beneath the peritoneal covering of a pedunculated myoma. The growth is undoubtedly an adenocarcinoma of the body of the uterus.

The right tube is markedly atrophic, and in the parovarium accompanying it are small deposits from the primary growth. Sections from the ovary show that the cyst cavities are lined by one layer of cuboidal and somewhat degenerated epithelium, and that their cavities contain a slightly granular material that takes the eosin stain. Projecting into the cavities of some of these cysts are papillary masses, covered over by one layer of high cylindrical epithelium, on which the cilia are in some places visible. The framework of the cysts and of the papillary masses is composed of spindle-shaped cells, while scattered throughout thickened portions of the connective tissue are numerous gland-like spaces. The epithelial elements in this cystic ovary are, in the main, uniform in size, but here and there is a cell containing a very large, irregular, deeply staining nucleus. Occasionally a giant cell is met with which has a mulberry-shaped nucleus. In one portion of the ovary, apparently the hilum, is a small amount of typical ovarian stroma, containing remnants of the Wolffian body. The tumour is a papillo-cystoma of the ovary.

Sections from the left tube, near its centre, show marked senile changes in its mucosa. The walls of the cyst occupying the outer pole of the ovary are composed of spindle-shaped connective-tissue cells. There is much hyaline degeneration. The inner surface of the cyst has been lined by one layer of low cylindrical or cuboidal epithelium, but in most places this has dropped off. The projections into the cyst cavity are likewise covered by one layer of epithelium, their stroma being continuous with that of the cyst wall. The growth is a papillo-cystoma of the ovary.

The large mass in the left inguinal region presents an exquisite example of a papillary growth. The large cyst-like spaces, seen macroscopically, are lined by one layer of epithelium, in some places cylindrical, at other points cuboidal. Projecting into the cyst cavities are papillary growths, which are also lined by one layer of epithelium. This epithelium is not very regular, and often forms giant cells containing mulberry-shaped nuclei.

The growth evidently represents an extension from that found in the ovaries. The tumour in the right inguinal region is of the same character.

Sections from the liver show profound fatty degeneration. The metastases consist of a delicate network of spindle-shaped cells, containing well-formed glands in its meshes. They resemble those forming the uterine tumour. The growths in the lung are sharply circumscribed, and consist almost entirely of convoluted branching glands. They also are evidently secondary to the uterine growth. The lung alveoli, in the immediate vicinity of the nodules, contain a small amount of desquamated epithelium, or are empty.

This case is of importance on account of the intimate relationship between the myomata and the adeno-carcinoma. From a clinical examination alone, the case would have been considered as one of myomata. Still more interesting is the coexistence of the carcinoma of the body of the uterus and the papillo-cystomata of both ovaries. When an incision was made over the prominence in the left inguinal region, the papillary nature of that growth was clearly perceptible to the naked eye; and even if one had previously thought of the possibility of an adeno-carcinoma of the uterus, the mind would have been entirely set at rest on that point, inasmuch as uterine carcinomata, whether originating in the cervix or body, never give rise to such metastases. The combination of the uterine myomata, the adeno-carcinoma of the body of the uterus, and the papillo-cystomata of both ovaries, is of course merely a coincidence. It may be well, however, to remember, when considering the advisability of removing an ill-defined pelvic tumour, that independent malignant growths may exist in the uterus and ovaries at the same time.

SQUAMOUS-CELL CARCINOMA AND ADENO-CARCINOMA OF THE BODY OF THE UTERUS IN THE SAME INDIVIDUAL

Kaufmann * reports the case of a woman, sixty-four years of age, who for over six years had been troubled with uterine hæmorrhages. Later he obtained the uterus, and found that there were two distinct pathological processes in the body—an adeno-carcinoma and a squamous-cell carcinoma. With alum picrocarmine he was able to bring out the epithelial pearls, which in some places were found pushing their way into the glands of the adeno-carcinoma, forming tongue-like projections into the lumina.

Several cases have been reported in which squamous-cell carcinoma as well as adeno-carcinoma were supposed to have been found in the body of the uterus; but from the descriptions, and the illustrations accompanying them, it seems clear that there was no squamous-cell growth, but that adeno-carcinoma alone was present. It is readily seen how the confusion can arise in such cases, unless sections are taken from various portions of the growth, inasmuch as in adeno-carcinoma the cells often form large masses looking not unlike squamous epithelium (see Fig. 183, *g*, p. 362; Fig. 199, *a*, p. 381; and Fig. 200, *e* and *f*, p. 382), and numerous glands, when filled with swollen epithelial cells, bear a striking

* Kaufmann. *Eine eigenartige Form carcinomatöser Entartung des Endometrium corporis. Jahresbericht der schlesischen Gesellsch. f. vaterländische Cultur, Jahr lxxii, 1894, S. 52.*

resemblance to epithelial nests. We know from the reports of von Rosthorn,* Zeller, † and others, that squamous epithelium may be found in the body of the uterus; accordingly, there is no reason why squamous-cell carcinoma and adeno-carcinoma should not occur there at the same time. In Kaufmann's case the finding of the typical pearls proves beyond a doubt the existence of the two carcinomatous processes.

ADENO-CARCINOMA AND SARCOMA OF THE BODY OF THE UTERUS

As mentioned elsewhere, Emanuel ‡ reports a case in which these two conditions were demonstrated. The patient was forty-seven years of age. Projecting into the uterine cavity was a soft, smooth, sharply defined tumour, the size of a pigeon's egg. The mucosa surrounding it was everywhere gathered up into little papillary folds, presenting the typical appearances of adeno-carcinoma. Histological examination showed that the tumour was a round-cell sarcoma, and that over a portion of it the atrophic mucosa was still intact. The surrounding mucosa was the seat of an adeno-carcinoma. Conclusive illustrations accompany the text.

SARCOMA, ADENO-CARCINOMA, MYOMA, AND UTERINE POLYPI IN THE SAME UTERUS

Niebergall # describes the case of a woman, sixty-two years of age, in which a diagnosis of carcinoma was made from an examination of curettings. Two days after the curettage a tumour, the size of a goose's egg, was expelled. This was lobulated, dark brownish-red, and resembled liver substance. The cut surface was smooth. On histological examination the growth was found to be a "fibro-cell sarcoma." Vaginal hysterectomy was performed, and the growth proved to be an adeno-carcinoma. Niebergall, after a review of the literature, concluded that his case was probably the first authentic one.

I must confess that I am not thoroughly convinced that the extruded nodule was a sarcoma, more especially since it was described as being of the "fibro-cell" variety. In the case of a type of sarcoma, which is always intimately dovetailed into the uterine muscle, the tumour would hardly be expelled with such readiness, even after the uterus had been dilated and curetted; furthermore, many submucous myomata at the time of their expulsion are somewhat edematous, and have before now been mistaken for sarcomata. We are, however, not justified in denying that it was a sarcoma.

As a result of further investigation and careful tabulation of the cases of carcinoma, it will not be at all surprising to learn that almost any variety of pathological process may be associated with adeno-carcinoma of the body of the uterus.

* von Rosthorn, A. *Ueber Schleimhautverhornung der Gebärmutter. Zeitschr. zur Feier des fünfzigjährigen Jubiläums der Gesellsch. f. Gynäk.*, 1894, Wien, S. 319.

† Zeller, A. *Plattenepithel im Uterus (Psoriasis uterina). Zeitschr. f. Geburtsh. u. Gynäk.*, 1884-'85, Bd. xi, S. 56.

‡ Emanuel, R. *Ueber gleichzeitiges Vorkommen von Carcinom u. Sarkom im Uteruskörper. Zeitschr. f. Geburtsh. u. Gynäk.*, 1896, Bd. xxxiv, S. 1.

Niebergall, E. *Sarkom, Carcinom, Myom u. Schleimpolypen an ein- und demselben Uterus. Archiv f. Gynäk.*, 1895-'96, Bd. l. S. 129.

CHAPTER XVI

THE SYMPTOMATOLOGY OF ADENO-CARCINOMA OF THE BODY OF THE UTERUS

1. The uterine discharge.
2. The age.
3. The menstrual history.
4. The number of pregnancies.
5. Pain.
6. Duration of the malignant process before operation.
7. Adeno-carcinoma of the body of the uterus in the coloured race.

UNFORTUNATELY there are no symptoms which are pathognomonic. The patient may come to us looking the picture of health, even though the disease is far advanced. On the other hand, she may be thin, haggard, and sallow when the growth is still in the early stages. Accordingly, the physician must rely almost entirely on the local manifestations.

From a study of the cases it will be seen that adeno-carcinoma of the body is noted most frequently after the menopause. Hence any vaginal discharge occurring in a woman who is past the climacteric should always be regarded with suspicion. A patient may come complaining of a slight watery discharge tinged with blood, or occasionally purulent, and which sometimes causes irritation of the genital tract. At other times the first symptom is a free uterine hæmorrhage. In some instances, for example in Case 2,634 (p. 431), no local manifestations were noted until the patient herself became aware of the presence of a small lump under the abdominal wall. At operation the growth was found to have extended through the uterus and to have involved the peritoneum.

The Uterine Discharge.—The discharge at first is usually watery, and, as in Case 3,258 (p. 375), it may be present many months before hæmorrhages occur. Although thin and colourless, it may be very irritating and have a penetrating odour. It is only necessary to call to mind the gross appearances of the growth and remember the nature of the subsequent degenerative changes, in order to understand the reason for the discharge. Under ordinary conditions a slight leucorrhœa is common. In adeno-carcinoma we have an increase in the number of blood-vessels, which are even more delicate than those of the normal mucosa; hence the probability of the occurrence of an abundant discharge. Again, the normal epithelial cells are supposed to secrete a certain quantity of fluid; in adeno-carcinoma a greatly increased amount of epithelium is present, by which a portion of the fluid is probably secreted. Furthermore, since degenerative changes soon follow, small particles of necrotic tissue are apt to be included in the flow, rendering the odour offensive. Often the discharge is blood-tinged.

Hæmorrhages are less frequent in adeno-carcinoma of the body than in cancer of the cervix. Only exceptionally, as in Cases 2,813 (p. 408) and Gyn.-Path.

No. 994 (p. 366), are they among the first manifestations; as a rule, they do not appear till late in the disease. Here again the explanation can readily be found. In the first place, the blood supply, although abundant, is not so rich as in the cervical growths; and secondly, the diseased tissue is protected from any external injury, being inclosed on all sides by the uterine walls. As is exemplified in case Gyn-Path. No. 780 (p. 383), any over-exertion seems to predispose to hæmorrhage. The blood may be fluid, but is sometimes dark red and clotted.

Age.—In estimating the age of these patients some latitude must be allowed, inasmuch as it is impossible to determine accurately just when the disease commenced, and it is safe to assume that in some patients the process had already existed for one or two years before any operation was undertaken. In twenty-one cases it was possible to obtain the age of the patients, and from the following table it will be seen that, on an average, adeno-carcinoma of the body comes on at a later period than either squamous-cell carcinoma or adeno-carcinoma of the cervix:

30 years	Number of cases, 3
Between 35-40 years	“ “ 1
“ 40-50 “	“ “ 4
“ 50-55 “	“ “ 5
“ 55-60 “	“ “ 5
“ 60-65 “	“ “ 3

According to this table, therefore, the period of maximum morbidity is between fifty and sixty years of age.

Menstrual History.—The majority of the patients had ceased to menstruate, but it will be noted that the monthly flow had been normal until the menopause. In those developing carcinoma before the climacteric there was a profuse menstrual flow for some time prior to the manifestation of other symptoms. Menstruation apparently bears no relation to the development of the disease.

Number of Pregnancies.—In nineteen cases it was possible to get accurate data as to the number of pregnancies. Seventeen of these patients were married, while only two were single.

CASE.	Condition.	Children.	Miscarriages.
A. (Gyn.-Path. No. 994)	Married 7 years.	0	0
D. (Gyn. No. 2,813)	“ 12 “	0	0
A. (Gyn. No. 2,817)	“ 21 “	1	0
G. (Gyn. No. 3,967)	Single.
M. (Gyn.-Path. No. 780)	Married 24 years.	2	0
A. (Gyn. No. 3,258)	“ 33 “	2	5
G. (Gyn. No. 2,436)	“ ?	4	0
A. (Gyn. No. 2,832)	“ 32 “	0	0
P. (Gyn. No. 4,262)	“ 12 “	1	0
S. (Gyn. No. 2,634)	“ . . .	0	1
P. (Gyn.-Path. No. 392)	“ 31 “	0	0
S. (Gyn. No. 3,955)	“ 24 “	4	0
S. (Gyn. No. 4,922)	“ 36 “	2	0
C. (Gyn. No. 5,340)	“ 13 “	1	1
K. (Gyn. No. 5,782)	“ 21 “	1	0
H. (Gyn. No. 5,858)	Single.	0	0
B. (Gyn. No. 5,957)	Married 30 years.	0	1
H. (Gyn. No. 6,439)	“ 27 “	0	0
L. (Gyn. No. 6,659)	“ 2 “	0	0

From the table it will be seen that ten had never been pregnant, and none of the patients had had more than four children.

On comparing with these figures those from the table dealing with pregnancy occurring in patients who later developed squamous-cell carcinoma (p. 174), it will be found that out of fifty of the latter only one had never been pregnant—a marked contrast.

Of the twelve married women who developed adeno-carcinoma of the cervix (p. 336), all had been pregnant.

From such a limited number of cases it is hardly warrantable to draw any deductions, but the figures are nevertheless suggestive.

Appetite.—This varies within wide limits. In many patients it is poor even in the early stages of the disease, while not infrequently in advanced cases the sufferer eats well.

The bowels are in some cases regular, but in the majority constipation exists, and, as was noted in Case 3,258, defecation may be accompanied by considerable pain.

Pain is a variable symptom. In the early stages of the disease the patient may have an ill-defined tired, languid feeling, as was noted in Case 2,832 (p. 371). Others suffer from no pain so long as the vaginal discharge is present, but when this ceases they have an uneasiness in the region of the uterus, evidently due to a damming up of the flow. Some complain of colicky or sharp shooting pains through the abdomen, while others are troubled with backache and radiating pains in the legs, which may be constant or intermittent, and are usually more severe in the late stages, owing to pressure on the sacral plexus. In some instances there is no pain whatever, but shortly before death the patient may be dull, apathetic, and give vent to low moans.

Duration of the Malignant Process before Operation.—It is exceedingly difficult in any given case to say just when the disease has commenced, since it may have been present for some time before any symptoms showed themselves. In the following table, in attempting to determine as nearly as possible the date of commencement, we have used as our starting-point the onset of the discharge, or of the hæmorrhages.

CASE.	Duration.	Condition of growth at operation.
A. (Gyn.-Path. No. 994).....	8 months. (?)	Very early stage.
M. (Gyn.-Path. No. 780).....	8 months.	“ “
G. (Gyn. No. 2,436).....	13 months.	“ “
A. (Gyn. No. 2,832).....	1 year.	“ “
A. (Gyn. No. 3,258).....	2 years. (?)	Fairly early stage.
A. (Gyn. No. 2,817).....	8 months.	Advanced stage.
D. (Gyn. No. 2,813).....	11 months.	“ “
P. (Gyn.-Path. No. 392).....	3 years.	“ “
G. (Gyn. No. 3,967).....	4 years. (?)	“ “

For the reason given above the table does not offer very reliable data. It will nevertheless be seen that in four of the cases coming to operation with the process in the early stage, the duration of the symptoms had not exceeded thirteen months, while in one instance in which the symptoms had been present appar-

ently for two years, the disease had made no great progress. On the other hand, Cases 2,817 (p. 390) and 2,813 (p. 408), in which symptoms had been noted for less than a year, showed marked uterine involvement.

We had an excellent opportunity to follow Case 5,340 (p. 364). As noted in the history, the left ovary was removed July 12, 1897, and the uterus was suspended on account of a retrodisplacement. At this time the organ appeared to be normal, and there were no signs pointing to carcinoma. The patient was readmitted on April 13, 1898, complaining of uterine hæmorrhages. These had come on first about two weeks after her discharge from the hospital, and for three or four months previous to the second admission she had had a profuse, yellowish, irritating, but not offensive, discharge. The uterus was curetted, and the scrapings were found to consist of adeno-carcinoma of the type usually found in the body. The patient refused operation, and left the hospital on April 20th. On November 22, 1898, when she was again admitted to the hospital, she appeared to be stouter than when last seen. The uterus was removed. On referring to Fig. 185 (p. 365), it will be seen that the disease was still confined to a very limited area of the uterus, and had invaded the walls to only a slight extent. The process was evidently a slow one, the growth having made so little progress, although definite symptoms had been present for at least thirteen months. This growth appears to have been entirely removed.

One very important point may be learned from this table. If the patients had been operated upon as soon as the symptoms were manifest, all would probably have been cured.

As to how long the patient may live after the onset of the disease, we are, from our observations, not prepared to say.

ADENO-CARCINOMA OF THE BODY OF THE UTERUS IN THE COLOURED RACE

The statistics on this point are scanty. In twenty-one cases, in which definite data were obtainable, eighteen of the patients were white women, three were coloured. Although the total number is small, yet, when it is remembered that six whites enter the hospital to one negress, adeno-carcinoma of the body would appear to be equally prevalent in the two races.

CHAPTER XVII

THE DIFFERENTIAL DIAGNOSIS IN ADENO-CARCINOMA OF THE BODY OF THE UTERUS

1. Suspicious changes due to imperfect hardening of the mucosa.
2. Extension of normal uterine glands into the muscle.
3. Copious uterine hæmorrhages. The glands are normal, but the surrounding stroma shows considerable cell proliferation.
4. Large venous sinuses in the uterine mucosa, causing free hæmorrhages.
5. Uterine polypi: illustrative cases.
6. Glandular hypertrophy of the uterine mucosa; illustrative cases.
7. Characteristic changes occurring in the endometrium during pregnancy
 1. The normal placenta.
 2. Gland hypertrophy in pregnancy.
 3. The normal decidua.
8. Decidual giant cells in the muscle.
9. The uterine mucosa in cases of extra-uterine pregnancy.
10. Exfoliated menstrual membrane.
11. Conditions in endometritis that might be taken for early adeno-carcinoma of the body of the uterus. Cases of endometritis (*a*) presenting gross appearances somewhat resembling those of adeno-carcinoma of the body; (*b*) showing suspicious histological changes.
12. Uterine myomata.
13. Adeno-myoma uteri diffusum benignum.
14. Sarcoma of the body of the uterus.
15. Secondary sarcoma of the body of the uterus.
16. Tuberculosis of the endometrium.
17. Suspicious scrapings.

IN the preparation of this chapter all the clinical and pathological material of the hospital for the last seven years has been utilized, and every condition that might be confused with adeno-carcinoma has been dealt with. The normal changes in the endometrium during pregnancy are discussed *in extenso*. No apology is offered for the fulness of detail, inasmuch as a glance at the chapter on Prognosis will show that operative interference offers brilliant results in cancer of the body of the uterus, provided only that the diagnosis be made sufficiently early. Furthermore, it is evident that in the first stages of the disease the microscopical examination of specimens obtained from curettings or from excised portions will often render a diagnosis possible in clinically obscure cases. It must be remembered, however, that, in order to render our observations reliable, a good technique is indispensable.

SUSPICIOUS CHANGES CAUSED BY IMPERFECT HARDENING OF THE MUCOSA

Uterine scrapings are usually placed in the hardening fluid at once, and are therefore generally well preserved. But when the uterus is much enlarged, for instance as the result of the presence of myomata, if it be not properly opened, the mucosa of the anterior wall frequently comes in contact with that of the pos-

terior wall, and considerable maceration of the tissues takes place before the fluid has had time to penetrate them thoroughly. In consequence of such degenerative

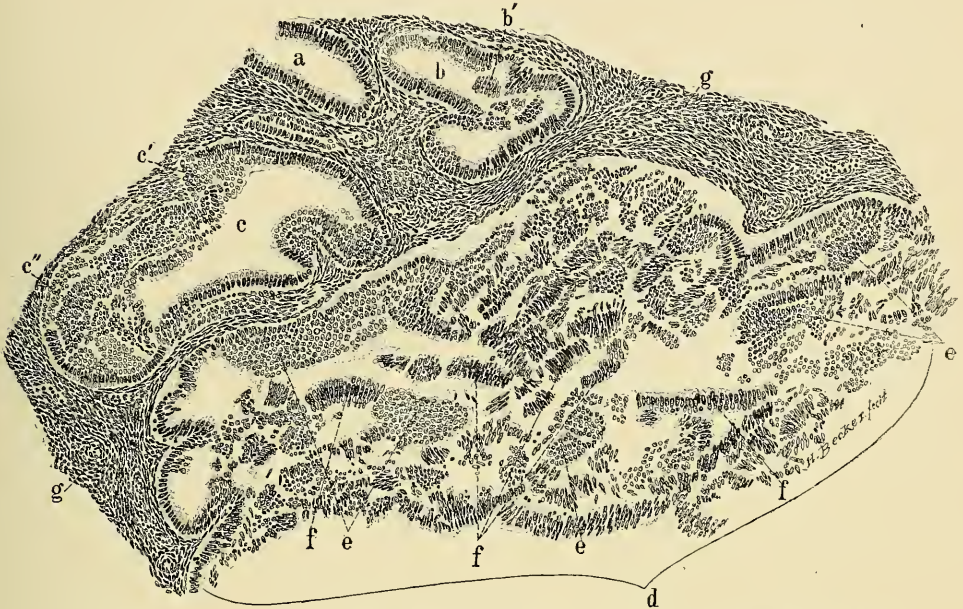

FIG. 245.—SUSPICIOUS CHANGES IN THE UTERINE MUCOSA RESULTING FROM IMPERFECT HARDENING.
(135 diameters.)

Gyn.-Path. No. 332. The section is rather thick. *a* is a normal gland. *b* is a gland lined by one layer of epithelium, and containing a double row of epithelial cells (*b'*) lying free in its lumen. *c* is a moderately enlarged gland, in which the epithelium at *c'* and *c''* has been cut on the bevel. The area *d* represents a very large gland, the epithelium of which is much disorganized. At the points indicated by *e*, the epithelial cells appear to be many layers in thickness, but the cells are regularly arranged, uniform in size, and the section has been cut obliquely. *f* indicates single or double rows of cylindrical epithelium that have dropped off and are lying free in the gland space; they belong to the gland wall at another level. *g* is the normal stroma of the mucosa. The glands surrounding the area shown here were perfectly normal.

processes very suspicious pictures may be found, as exemplified in Fig. 245. The gland epithelium drops off in rows and often becomes much distorted, reminding one somewhat of adeno-carcinoma. It is always well to open the uterus in such a manner that the fluid comes in contact with all parts of the mucosa (see Fig. 30, p. 35).

EXTENSION OF NORMAL UTERINE GLANDS INTO THE MUSCLE

In systematic examinations of the uterine mucosa from all parts of the cavity it has been observed that in the majority of the cases the glands, at one or more points, extend for a short distance into the muscle. These glands are perfectly normal (Fig. 246, p. 478), and are usually surrounded by stroma identical with that of the uterine mucosa; occasionally, however, they lie in direct contact with the muscle fibres. The accompanying case supplies one of the many examples noted.

Gyn.-Path. No. 534

Suppurating interstitial myoma; normal uterine mucosa with some extension of the glands into the muscle (Fig. 246); a slight degree of peri-salpingitis on both sides.

Operation. Hysterectomy, December 3, 1894. The patient was forty-four years of age.

Histological Examination.—The epithelium covering the surface of the uterine mucosa is everywhere intact. The glands appear in moderate num-

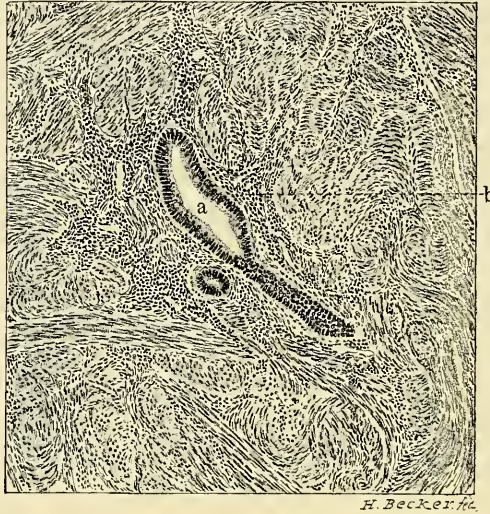

FIG. 246.—NORMAL UTERINE GLANDS DEEP DOWN IN THE MUSCLE. (90 diameters.)

The greater part of the section consists of non-striped muscle fibres, but situated in the centre is an oblique section of a gland (*a*). In the upper portion the gland epithelium is clearly seen; in the lower half just the edge of the gland has been cut off. Partially surrounding the gland, and separating it from the muscle, is the stroma (*b*), identical with that of the uterine mucosa. To the left of the large gland, just described, is a cross section of a smaller one.

bers, the majority being small and round on cross section. Some of those in the depth, however, are slightly dilated. All have an intact epithelium. A few of the glands extend for a short distance into the muscle. They look perfectly normal; some of them are surrounded by stroma similar to that of the mucosa, while others lie in direct contact with the muscle.

COPIOUS UTERINE HÆMORRHAGES. THE GLANDS ARE NORMAL, BUT THE SURROUNDING STROMA SHOWS CONSIDERABLE CELL PROLIFERATION

In a certain group of cases uterine hæmorrhages are very frequent. Curetting the uterus gives relief for several months, after which the loss of blood begins again. In the instance cited here, although the uterine mucosa had an intact surface epithelium, and the glands were perfectly normal, the stroma showed marked changes. It was much

richer in cellular elements than usual, and many of the cells contained nuclear figures. It is interesting to note that an examination of the mucosa sixteen months later revealed exactly the same condition.

A sister of this patient in her early life had been affected in the same way. Recently, Dr. Eccles, of London, Ontario, sent me scrapings from a patient giving a similar history. On microscopical examination the same histological changes were observed as had been noted in Dr. Meek's case.

In all three cases the patients were under twenty-five years, a fact which of itself would tend to negative the presumption of adeno-carcinoma of the body of the uterus, although it must be remembered that the disease occasionally manifests itself early in life.

The histological examination shows nothing at all suggestive of adeno-carcinoma, the epithelial elements being perfectly normal.

Such patients cannot be mistaken for constitutional bleeders, inasmuch as curetting is sufficient to check the hæmorrhages for several months, while in the latter this treatment would be of little value.

In July, 1895, Dr. H. Meek, of London, Canada, sent me scrapings from a woman twenty-five years of age. Up to her nineteenth year the menses were regular, but since that time there has been an almost continuous hæmorrhagic discharge. At the age of twenty-one she came under Dr. Meek's care, and had been curetted by him, on an average, every three or four months. The patient has been married two years, but marriage has in no way altered the condition. There is no pain, and the only thing she complains of is weakness following the hæmorrhages. After being curetted, she gains rapidly and remains well for about three months, after which time the hæmorrhages recur. Her sister, who is three years older, has manifested similar symptoms, but not of so severe a type. Both women have remained sterile, and in both the uterus is sharply anteflexed. The appendages are normal.

Gyn.-Path. No. 799. July 13, 1895. The specimen consists of a moderate amount of uterine scrapings. On histological examination the surface epithelium is seen to be intact. The glands are abundant; many are small and round on cross section, but quite a number are dilated. All have an intact epithelial lining. The lumina of the dilated glands contain some desquamated epithelium and granular material. The stroma of the mucosa is very rich in cellular elements; the nuclei are slightly larger than usual. Numerous nuclear figures may be seen scattered throughout the stroma, and were it not for the fact that the spaces between glands are everywhere approximately equal, one might suspect sarcoma. It must also be remembered that this patient was curetted four months ago.

Diagnosis.—Slight dilatation of the uterine glands; excessive growth of the stroma of the mucosa.

No. 1,415. November 30, 1896 (Meek). On examination of the scrapings, practically the same condition was found as on the previous occasion. Some of the glands were dilated, while others were small. The stroma presented the same

appearance as before, being characterized by the abundance of the stroma cells, which were also nearly twice as large as normal. Many of them contained nuclear figures in various stages of development.

December 18, 1899. Dr. Meek informs me that the patient is now twenty-nine years of age, and that she has been married more than four years, but has never been pregnant. "The last time I curetted was in August, 1899. At that time she was rather thin and pale, but feeling well, except for the weakness from the flow. From the past history I will probably hear from her about January 1, 1900."

LARGE VENOUS SINUSES IN THE UTERINE MUCOSA CAUSING FREE HÆMORRHAGES

As will be seen from the following case, a patient will occasionally come complaining of profuse and frequent hæmorrhages, and on histological examination of the mucosa the gland elements will be found perfectly normal, the loss of

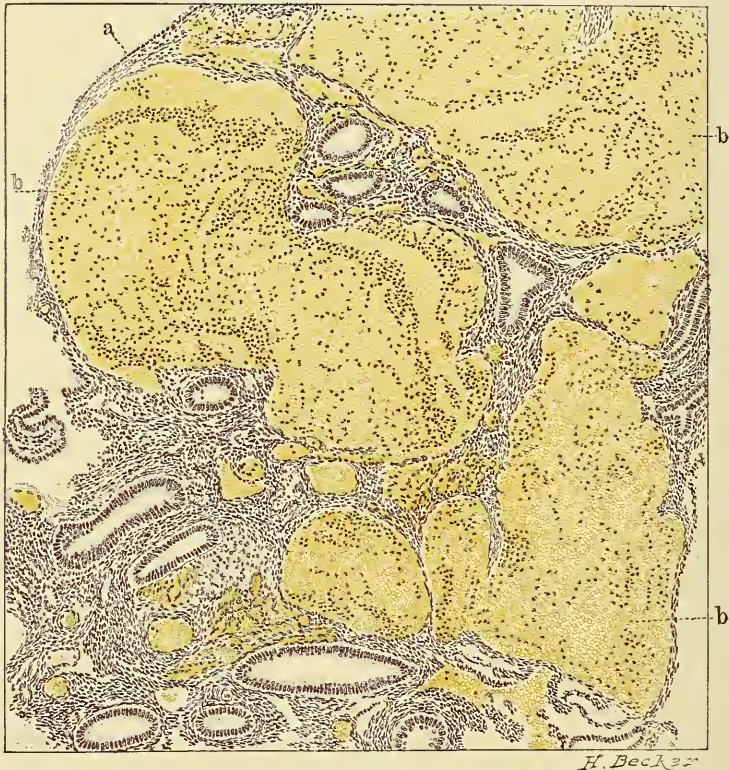


FIG. 247.—LARGE VENOUS SINUSES IN THE UTERINE MUCOSA CAUSING SEVERE HÆMORRHAGES. (80 diameters.)

Gyn.-Path. No. 2,048. *a* is a portion of the surface epithelium, which is greatly flattened. In the lower part, as well as in the upper third of the field, are several uterine glands of the usual size and shape, and lined by one layer of cylindrical epithelium. They are perfectly normal, and are surrounded by the normal stroma of the mucosa. Over one half of the section is made up of three large venous sinuses, showing exceedingly delicate walls.

That there is no malignant process is clear. It is little to be wondered at that free hæmorrhages should have taken place, when such large blood sinuses existed.

blood being due to the presence of very large venous sinuses in the stroma (Fig. 247). In such cases the information to be gained from a histological examination of the mucosa is of the utmost value, inasmuch as without it one might feel justified in removing the uterus.

The plan of treatment in these cases is to thoroughly curette the uterus. Sometimes one such procedure may suffice, but it is occasionally necessary to repeat it several times before the hæmorrhages are entirely overcome.

Gyn.-Path. No. 2,048. Patient of Dr. Glass, of Utica, N. Y. December 14, 1897. For about one year she had had uterine hæmorrhages at frequent intervals. On bimanual examination nothing could be detected, but as malignancy was suspected the uterine cavity was curetted. Only a small amount of mucosa was brought away.

On histological examination the surface epithelium is found to be intact; the glands are moderate in number, and show a normal epithelium; quite a number of them are dilated, and their epithelium is slightly flattened. The stroma of the mucosa is rather dense; the individual cells are normal. The most striking feature consists in the great abundance of large venous sinuses scattered throughout the stroma (Fig. 247). These in some places are wanting, but in others form fully one third of the field; they are apparently lined by one layer of endothelium, which is with difficulty made out. Many of the sinuses contain canalized fibrin, in which are myriads of polymorphonuclear leucocytes. Other sinuses are filled with blood. There is not the slightest trace of malignancy. The hæmorrhages can very readily be accounted for by the presence of the venous sinuses.

This patient was admitted to the Johns Hopkins Hospital in November, 1898. The uterus was again curetted, but no evidence of malignancy was demonstrable. December 16, 1899. She is now in better health than for years past.

UTERINE POLYPI

Reference is made here not to those cases of endometritis associated with a polypoid formation of the mucosa, but to the isolated and flattened polypi so frequently found in the uterus. Not infrequently, when a patient comes complaining of intermittent or persistent hæmorrhages, careful investigation will show that the condition is caused by a uterine polyp. These polypi are usually finger-like or heart-shaped growths, which are flattened, and point toward the internal os; occasionally, as in Case 3,038 (p. 486), the apex is directed upward. While most common in the upper part of the uterine cavity, they may be found at any point. Their surfaces are smooth and glistening, resembling the surrounding mucosa (Fig. 250, p. 484; Fig. 251, p. 484); their tips are often bright red in colour, as a result of hæmorrhage into their substance. Occasionally a polyp is very long, and may project through the internal os.

In rare instances, when the uterine cavity is small and the mucosa thick, it may be gathered up into smooth, undulating, and parallel ridges, as seen in Fig. 248.

On histological examination, the outer surface of the polyp is found to be covered by one layer of cylindrical ciliated epithelium, directly continuous

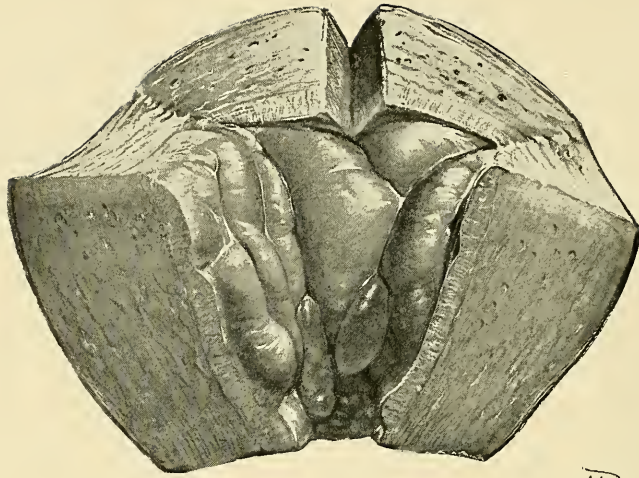


FIG. 248.—SLIGHT POLYPOID FORMATION, DUE ENTIRELY TO EXCESSIVE THICKNESS OF NORMAL MUCOSA. (Natural size.)

Gyn.-Path. No. 585. The uterus has been amputated at the cervix. The body is of the usual size, and its walls are of normal thickness. The mucosa is considerably thickened, and gathered up into fairly parallel and smooth ridges. There is a total absence of any finger-like outgrowths, and at no point does the mucosa show any tendency to encroach upon the muscle. No resemblance to a malignant growth can be detected. Histological examination shows that the mucosa is normal.

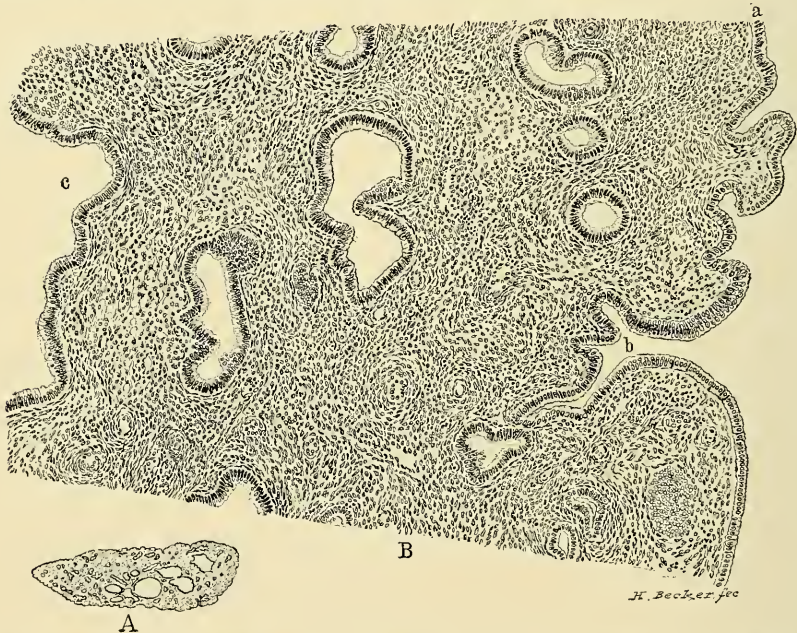


FIG. 249.—HISTOLOGICAL APPEARANCES OF A UTERINE POLYP. (A, 3 diameters; B, 70 diameters.)

Gyn.-Path. No. 652. A is a cross section of a uterine polyp. We know that it is a cross section, since its point of attachment is not visible and the outer surface in the vicinity is everywhere covered by epithelium. Scattered throughout the polyp are uterine glands, a few of which are dilated.

B is a portion of A more highly magnified. *a* is the slightly undulating surface covered by one layer of cylindrical epithelium. *b* is a gland opening directly on the surface. Numerous normal uterine glands are seen scattered throughout the stroma. The stroma is of moderate density, and consists of cells containing oval or spindle-shaped nuclei. *c* is a portion of another gland. Given the section B without any clew as to its origin, one would instantly say that it represented normal uterine mucosa. (After H. A. KELLY.)

with that covering the surface of the mucosa (Fig. 252); of course, where they have been subjected to much pressure the epithelial cells have become somewhat flattened. These polypi are composed of the same elements as the mucosa proper—glands and stroma (Fig. 249). The glands are similar to those found in the surrounding stroma, but they often show moderate or considerable dilatation, the cells being flattened. The presence of a giant cell in the gland cavity, as seen in Fig. 253 (p. 487), is of little significance, inasmuch as such a cell could not be mistaken for one of a new growth. The stroma of the polyp is directly continuous with that of the mucosa, and its elements are similar. In the bases of some polypi, however, bundles of non-stripped muscle fibre are seen.

From the above description it is evident that no confusion should arise between uterine polypi and adeno-carcinoma of the body of the uterus. As can be readily seen from the four accompanying cases, these polypi are very frequently associated with myomata, the uterus being then enlarged and hard. Again, if the polyp be curetted away, it will be found to be of considerable size, perfectly smooth and glistening, and showing no trace of branching. Furthermore, on histological examination, the picture will be practically that of normal mucosa.

An ordinary uterine polyp may be looked upon merely as a localized portion of the mucosa that has been partially extruded from the mucosa proper.

A Few Examples of Uterine Polypi

Gyn. No. 5,946

Subperitoneal and interstitial uterine myomata. Large glandular polypi.

P. P., aged fifty-two. March 19, 1898. Hystero-myomectomy.

Gyn.-Path. No. 2,242. The uterus is converted into a nodular tumour, measuring approximately 40×24 centimetres; it weighs 10,900 grammes. The tumours are for the most part of the subperitoneal variety, and vary in size from that of a pea to 20 centimetres in diameter. In general they are soft, and are evidently edematous. On section they are seen to consist of typical myomatous tissue. The uterine cavity is 11 centimetres in length and 7 centimetres in breadth; the upper two thirds are filled with three remarkably large polypi. The largest of these is $7 \times 4 \times 2.5$ centimetres (Fig. 250). The surfaces of the polypi are injected, traversed by branching blood-vessels, and studded with minute cysts, averaging 1 millimetre in diameter. On making sections of these polypi, it is found that there are cyst-like spaces scattered everywhere throughout their substance, some of them reaching 5 millimetres in diameter (Fig. 251).

The uterine mucosa is smooth, but markedly hæmorrhagic. The uterine cavity is little, if at all, encroached upon, although one myoma, at its most prominent part, extends to within 5 millimetres of the mucosa.

The appendages on the right side are normal.

The left tube is drawn out over the myomatous nodules, and reaches 16 centimetres in length. The ovary is slightly enlarged, and contains a calcareous deposit.

Histological Examination.—All the polypi present the same picture. Their surfaces are comparatively smooth, and in most places are covered by one layer of epithelium. Scattered throughout the stroma of the polypi are many typical uterine glands. The cyst-like spaces are dilated glands; in the majority of them the gland epithelium is still well preserved; in not a few

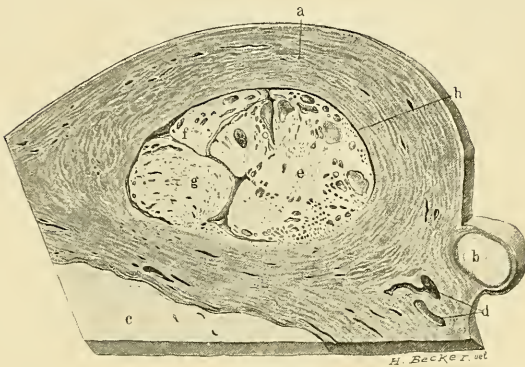


FIG. 250.

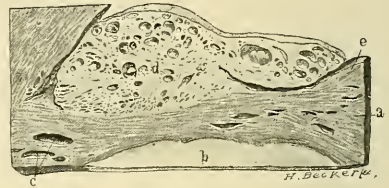


FIG. 251.

FIG. 250.—CROSS SECTION OF A VERY LARGE UTERINE POLYP IN A CASE OF MYOMA. (Natural size.)

Gyn.-Path. No. 2,242. As may be gathered from the text, the uterus was very large, owing to the presence of many myomata. The uterine cavity was 11 centimetres in length. The section is taken from the neighbourhood of the uterine horn, and shows a small part of the uterine cavity filled with polypi. *a* is the normal uterine muscle; *b*, a small sessile subperitoneal myoma; *c*, the edge of a large myoma. *d* indicates blood-vessels, which, judging from their thin walls, are probably veins. *e*, *f*, and *g* are cross sections of polypi. Note the smooth surfaces of each, there being no tendency to form little finger-like outgrowths. Scattered throughout the substance of the polypi are large and small cyst-like spaces—dilated uterine glands. Although the mucosa is greatly thickened, it shows no disposition to invade the muscle, and there is no breaking-down of tissue. *h* is the smooth inner surface of the uterine cavity.

FIG. 251.—CROSS SECTION OF A LARGE UTERINE POLYP IN A CASE OF MULTIPLE MYOMATA. (Natural size.)

Gyn.-Path. No. 2,242. This section is taken from the fundus. *a* is the normal uterine muscle; *b*, the edge of a large myoma; *c*, dilated veins. *d* shows a cross section of a large polyp. Its surface, although undulating, is perfectly smooth, but on section it presents a cystic appearance due to the many dilated glands, one of which reaches at least 5 millimetres in diameter. The polyp has a broad base, and shows no tendency to penetrate the muscle. The perfectly smooth surface, the dilated glands, and the lack of penetration into the underlying tissue almost certainly exclude carcinoma. On histological examination, it is found to consist of practically normal mucosa.

places, however, it has dropped off in ribbons, forming irregular skeins in the gland space, and at first sight offering a suggestion of malignancy.* The picture presented is often noted in specimens in which the hardening agent has imperfectly penetrated the tissue. The gland elements end abruptly where the muscle commences. The stroma of the polypi varies considerably in density, but corresponds to that of the uterine mucosa.

* For a similar picture see Fig. 245 (p. 477).

Gyn. No. 3,408

Diagnosis.—Subperitoneal, interstitial, and submucous uterine myomata. Dilatation of the cervical glands. Atrophy of the uterine mucosa. Uterine polypi. Normal appendages.

L. April 6, 1895.

Operation. Hystero-myomectomy.

Gyn.-Path. No. 659. The uterus is approximately 9 centimetres long, 7 centimetres broad, and 13 centimetres in its antero-posterior diameter. The uterine cavity is 4 centimetres in length. Its mucosa, which is less than 1 millimetre in thickness, is whitish yellow in colour; beneath its surface can be seen delicate, branching blood-vessels. At the fundus is a tongue-shaped polyp, 12 millimetres long and from 1 to 2 millimetres in breadth; this points downward; it is smooth, and its tip is bright red in colour.

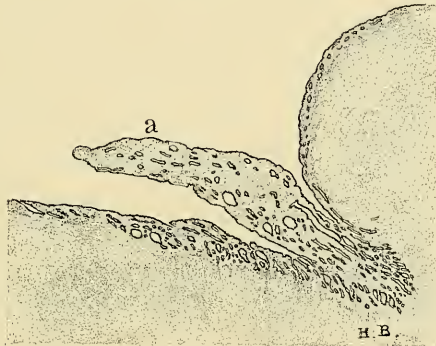


FIG. 252.—A SMALL UTERINE POLYP. (4 diameters.)

Gyn.-Path. No. 659. This section is from the fundus of the uterus. The mucosa lining the uterine cavity is rather thin, and has a smooth surface covered by one layer of epithelium. Scattered throughout the mucosa are a small number of normal uterine glands. Projecting from it is a tongue-shaped polyp (*a*), which points downward. Its surface is covered by one layer of epithelium, continuous with that covering the surface of the mucosa. Its substance contains glands differing from those in the mucosa only in that a few of them are dilated. The stroma of the polyp merges imperceptibly into that of the normal mucosa, and is of the same character. It is evident that this polyp is in reality the result of a partial extrusion of the normal mucosa. It bears no resemblance to an adeno-carcinoma.

Histological Examination.—The uterine mucosa is atrophic. The polyp, projecting from the fundus, is covered by one layer of epithelium, directly continuous with that upon the surface of the mucosa (Fig. 252). This epithelium is in some places almost flat. Scattered through the polyp are typical uterine glands, some of which are seen opening directly upon the surface. Most of the glands are small and round on cross section, but some are considerably dilated; all have an intact epithelium. The stroma of the polyp is continuous with that of the mucosa, but resembles more closely the normal type. It shows considerable hæmorrhage, which accounts for the bright-red appearance noted macroscopically.

Gyn. No. 2,800

Subperitoneal and interstitial uterine myomata. Normal uterine mucosa. Small uterine polypi. Right side: normal appendages. Left side: peri-salpingitis and peri-oöphoritis.

M., May, 1894.

Operation. Hystero-myomectomy.

Gyn.-Path. No. 312. In this case the largest myoma measured 19 × 12 centimetres. The uterine cavity was 3 centimetres in length; the mucous membrane was smooth and glistening, and the seat of some ecchymosis. Springing from the left side of the fundus was a polyp, 1 centimetre long, 8 millimetres broad, and 2 millimetres in thickness. This presented the same colour as the mucosa, but at its tip was bright red.

Histological Examination.—The uterine mucosa was normal. The surface of the polyp was covered by one layer of cylindrical ciliated epithelium. In places, the epithelial cells were perfectly normal, but at other points had become flattened and stained palely, the nuclei being twice their usual size. Between the epithelial cells, here and there, appeared a few small round cells. Scattered throughout the polyp were numerous glands, cut longitudinally or transversely. The epithelium of some of them was perfectly normal, but in others appeared to be disintegrating. The gland cavities contained coagulated serum, and, in places, desquamated epithelium. The stroma of the polyp resembled that of the mucosa in every particular, and had scattered throughout it numerous small capillaries. The red colour of the tip of the polyp was due to free hæmorrhage into the stroma. Traversing the central portion of the base of the polyp were numerous non-stripped muscle fibres.

Gyn. No. 3,038

Interstitial uterine myomata. Dilatation of the cervical glands. Haemorrhage into the uterine mucosa. Uterine polyp. Right side: follicular hydrosalpinx. Left side: hydrosalpinx simplex.

B., September 26, 1894.

Operation. Hystero-myomectomy.

Gyn.-Path. No. 452. The uterus is 17 centimetres in its antero-posterior diameter, 14 centimetres from side to side, and approximately 12 centimetres in length. The cervical glands are dilated; the uterine cavity is 9 centimetres in length and 3 centimetres broad at the fundus; the mucosa is smooth and glistening, dark red in colour, and apparently 2 millimetres in thickness. Situated on the anterior surface, just within the internal os, is a polyp, 1.2 centimetres long, 1 centimetre broad, and 4 millimetres in thickness. It is balloon-shaped, and points upward. Just beneath its surface, which is smooth, glistening, and whitish yellow in colour, are numerous small blood-vessels. Its tip is lightly attached to the anterior wall; the mucosa of the posterior wall, just opposite the polyp, is much paler than the surrounding portion, evidently owing to pressure.

Histological Examination.—The uterine mucosa shows considerable extravasation of blood into its stroma; otherwise it is normal. The polyp springing from the anterior wall is glandular in character, and is covered by one layer of cylindrical ciliated epithelium, which is directly continuous with that covering the surface of the cavity. This epithelium is well preserved, but at several points it has become somewhat flattened. The glands of the polyp are precisely similar in appearance to those found in the surrounding mucosa, and the polyp appears to be nothing more than a localized thickening of the mucous membrane. A few of its glands are dilated, and their epi-

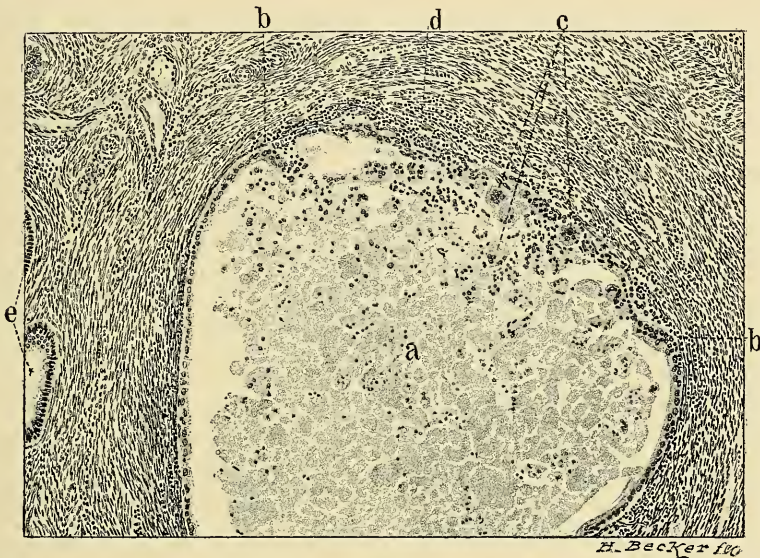

FIG. 253.—GIANT CELLS IN THE WALL OF A DILATED GLAND, FROM A UTERINE POLYP. (90 diameters.)

Gyn.-Path. No. 452. *a* is a much dilated uterine gland. Its epithelium in part stains only faintly and is considerably flattened; between the points *b* and *b* it is wanting. At *e* are several round masses of protoplasm, two of which contain nuclei bunched in their centres. These nuclei are uniform in size, and closely resemble those of the epithelium. The gland cavity is nearly filled with glandular material, shadows of desquamated epithelium cells, small round cells, and detritus. The surrounding stroma shows considerable small-round-cell infiltration at *d*, where there is loss of the epithelium; otherwise it is normal. *e* indicates the edges of normal glands. There is nothing to suggest a malignant process.

thelium is somewhat flattened. One of these dilated glands presents a most unusual picture. Its epithelium is flattened, its nuclei are swollen and irregular in contour, some staining more intensely than usual. Clinging to the wall at two points are rounded masses of protoplasm that take the eosin stain (Fig. 253). Each contains in its centre more than ten oval, deeply staining nuclei, and looks not unlike a placental giant cell, but bears a still closer resemblance to giant cells found in a case of adeno-myoma of the round ligament. Not far from this giant cell is seen a somewhat fragmentary portion of protoplasm containing several nuclei. The giant cells have probably resulted from a degenerative process. The same gland also contains shadows of desquamated cells. The stroma of the polyp is directly continuous with that of the mucosa proper. It has a rich blood supply.

GLANDULAR HYPERTROPHY OF THE UTERINE MUCOSA

Not infrequently glandular hypertrophy is observed entirely independent of pregnancy. It may occur where the uterus is normal in size, or where myomata are present (Fig. 255, p. 490). We have absolutely no clew as to its causation.

From a study of the accompanying cases a fairly accurate idea of the histological picture may be obtained.

The surface of the mucosa may be perfectly smooth, but is usually wavy, as shown in Fig. 254. There may be a tendency to polypoid formation, as in Case 5,041. The chief features are the increase in size of the gland and the markedly convoluted form (Fig. 255, p. 490; Fig. 256, p. 491; Fig. 257, p. 493). This change is usually noticeable throughout the entire course of the gland, but is occasionally limited to its deeper portion. Projecting into the gland from the sides are little finger-like folds. On careful examination it will be seen that those on opposite sides correspond with one another, while in a thick section or in favourable specimens the folds are found to be portions of little bars that extend from one side of the gland to the other; furthermore, these ribs or bars are merely sections through the convoluted gland wall.

With a clear idea of the manner in which the gland is convoluted, there is little trouble in understanding the condition. The glands are lined by one layer of epithelium, which is somewhat swollen. The cell protoplasm is rather granular, and the nuclei are slightly enlarged. These little folds or ribs, being part and parcel of the gland, are also covered by one layer of epithelium. Frequently there is a little ingrowth from the bottom of the gland (Fig. 258, *b*, p. 494). This is in the form of a finger-like or a branched projection, and is, of course, covered by one layer of epithelium. When a gland is cut transversely near its base, such a projection will naturally be included, and a section of it is seen lying free in the gland lumen, consisting of a delicate stem of stroma, with a covering of one layer of epithelium. At times these projections are very complex, so that a transverse section is somewhat confusing (see Fig. 258, *b'*).

The stroma cells in the superficial portions are often slightly swollen, but in the deeper parts are compressed, being spindle-shaped. Where two adjoining glands are much dilated and convoluted the stroma may be almost absent, the picture at first sight causing some perplexity (see Fig. 257, *c*, p. 493).

With the comparatively smooth surface of the mucosa, the intact surface epithelium, the even distribution of the glands, and the intact gland epithelium, consisting of only one layer of cells having oval or vesicular nuclei, little difficulty should arise in differentiating gland hypertrophy from adeno-carcinoma.

*Cases illustrating Various Degrees of Gland Hypertrophy of the Endometrium***Gyn. No. 5,041**

Glandular hypertrophy (Fig. 254).

E., February 27, 1897. Operation. Curettage.

Gyn.-Path No. 1,543. The specimen consists of a moderate amount of scrapings. The surface of the mucosa is gathered up into numerous small, finger-like

or polypoid outgrowths, the larger ones occasionally presenting secondary branchings. The surface epithelium is intact, but here and there a few small round cells have wandered in between the individual epithelial cells. The glands are

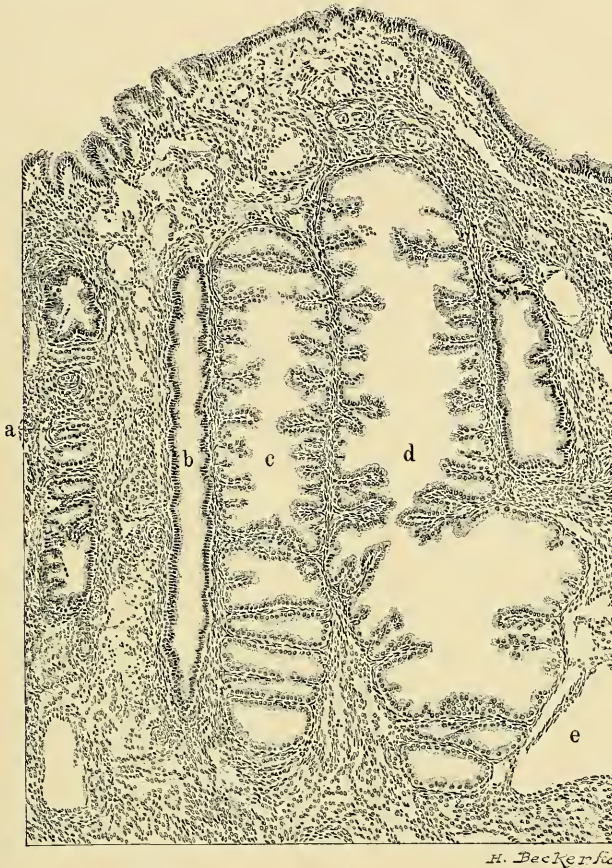


FIG. 254.—HYPERTROPHY OF THE UTERINE GLANDS. (75 diameters.)

Gyn.-Path. No. 1,543. The section is from a scraping. The surface of the mucosa on the right is slightly undulating, but smooth; on the left it is gathered up into delicate projections. The surface epithelium is one layer in thickness and is intact. At *a* are represented various sections of a slightly convoluted gland, normal in size, and lined by slightly flattened epithelium. *b* is a normal gland. The gland *c* is dilated, and has little tufts projecting from its sides. On closer examination, it is seen that each tuft has its equivalent on the opposite wall, and on examining the upper and lower parts of the field, the two portions are seen to form one bar that stretches from side to side. In this way it can be recognised that the appearances found are due to marked convolutions of the glands, the little tufts merely representing sections through the walls. The gland walls and the tufts are covered by one layer of swollen and slightly flattened epithelium. *d* is a gland similar to *c*, but much dilated in its lower half. To the right of *d* is a normal gland. The stroma of the mucosa is slightly œdematous just beneath the surface epithelium, but on the whole is normal. It contains numerous empty spaces, which are veins, one of them (*e*) being quite large. In this section we have fortunately cut the glands longitudinally, and their benign character is easily seen; but in Fig. 256 (p. 491) and Fig. 257 (p. 493), where only cross sections are presented, adeno-carcinoma might be suspected.

markedly hypertrophied, their cavities are dilated, and the gland contour presents a scalloped appearance (Fig. 254). Stretching from one side of the gland to the other are delicate bands or ribs. These run straight across or show some branch-

ing. They are nothing more than sections through gland folds. The epithelial cells lining the glands are cylindrical, and their nuclei, which are situated slightly below the centres of the cells, are oval and vesicular; some, however, stain somewhat deeply. The stroma of the mucosa shows some œdema and a moderate infiltration with small round cells. At one margin of the specimen is a small tag of tissue, which is very suggestive of carcinoma. It consists of folds of what is evidently surface epithelium. The cells apparently form three to five or more layers; they are swollen, of variable size, and contain large oval nuclei.

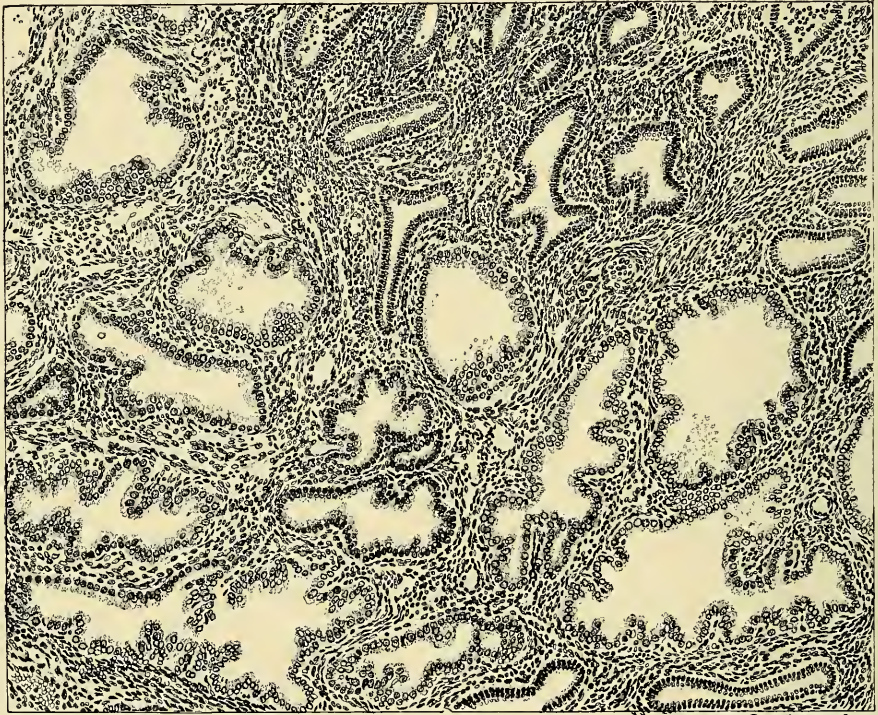


FIG. 255.—MODERATE GLAND HYPERTROPHY OCCURRING IN A MYOMATOUS UTERUS. (110 diameters.)

Gyn.-Path. No. 213. The glands in the upper part of the field, as well as two along the lower margin, are normal in size and shape, and are lined by one layer of epithelium, which, however, appears as two layers on account of the thickness of the specimen. The remaining glands are dilated and considerably convoluted. Their epithelium is one layer in thickness, somewhat œdematous, and stains palely in comparison with that of the normal glands. The stroma of the mucosa is normal. We have here only a mild degree of gland hypertrophy, and all the glands are equidistant from one another. This section could not be mistaken for one representing a carcinomatous process.

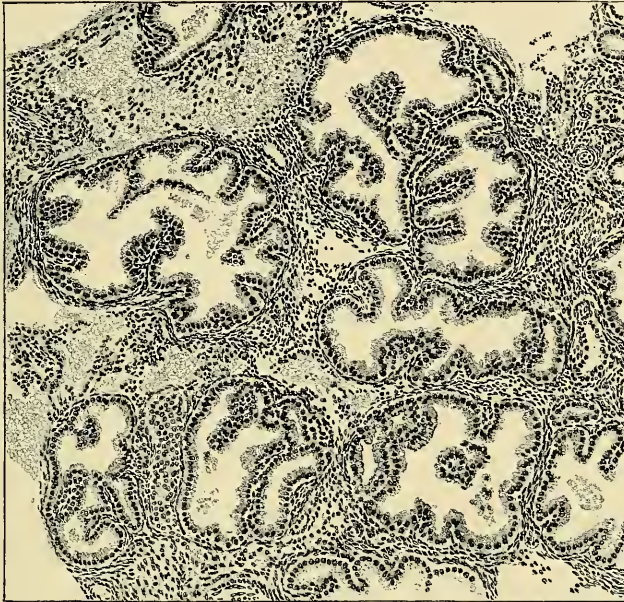
A diagnosis of glandular hypertrophy, with a suspicion of a commencing adeno-carcinoma, was rendered. It was suggested that the uterine cavity be again curetted, but on account of the continued free hæmorrhage, which nearly caused the patient's death, hysterectomy had to be resorted to. Examination of the uterus revealed the presence of a submucous myoma, but there was no carcinoma.

Gyn. No. 2,658

Submucous and interstitial uterine myomata. Hypertrophy of the uterine glands (Fig. 255).

Q., aged forty-five. March 21, 1894.

Gyn.-Path. No. 213. The uterus measures $13 \times 11 \times 11$ centimetres. On section, its walls are found to vary from 2.5 to 4 centimetres in thickness. Scattered



H. Becker, Jr.

FIG. 256.—HYPERTROPHY OF THE UTERINE GLANDS. (90 diameters.)

Gyn.-Path. No. 355. The picture represents a portion of a scraping from the body of the uterus. Six cross sections of uterine glands and portions of others are seen. The row near the bottom appears to be formed by convolutions of a single gland. All of the glands present the same general characteristics. They are convoluted, have little tuft-like ingrowths, which tend to form bars stretching from side to side, and are lined by one layer of rather low cylindrical epithelium, in which it is difficult to separate the protoplasm of one cell from its neighbour. The glands are equidistant from one another, and the stroma is normal. The various breaks in continuity and the presence of the blood are accounted for by the curettage. Compare with Fig. 255 (p. 490) and Fig. 257 (p. 493), cases of gland hypertrophy, bearing in mind the longitudinal sections of similar glands seen in Fig. 254 (p. 489). There is little reason for confusing with adenocarcinoma.

throughout them are myomata, varying in size from that of a pea to 5 centimetres in diameter. The uterine cavity is 5 centimetres in length, and its mucosa varies from 1 to 5 millimetres in thickness. Projecting into the cavity from the fundus are two myomata, the larger one of which is 5 centimetres in diameter. The whole inner surface of the uterus is paved with myomata, varying in size from that of a pea to 3 centimetres in diameter; the intervening spaces are occupied by injected mucosa. The picture instantly reminds one of a mosaic pavement.

HISTOLOGICAL EXAMINATION.—The mucous membrane over the largest submucous myoma is greatly atrophied, and a similar atrophy can be made out

over most of the nodules. The mucous membrane at the fundus reaches 8 millimetres in thickness. The surface epithelium is intact; the glands are dilated and convoluted; their epithelium, although somewhat flattened, is everywhere well preserved (Fig. 255). The gland cavities are empty; the stroma between the glands is scant in amount, but is perfectly normal, save for the presence of hæmorrhage in its superficial portions.

It looks as though the moderate glandular hypertrophy has to a certain extent compensated for the atrophy seen over the submucous myomata.

Gyn. No. 2,870

Glandular hypertrophy (Fig. 256).

C., June 25, 1894. Operation. Dilatation and curettage.

Gyn.-Path. No. 355. The specimen consists of a moderate amount of uterine scrapings.

Histological Examination.—The surface epithelium is intact. The glands in the superficial portion are unaltered, but in their deeper portions are dilated, convoluted, and have little folds projecting into their cavities (Fig. 256). The gland epithelium is intact, and only one layer in thickness. The cell nuclei are uniform in size, and show no evidence of active division. The stroma cells in the superficial portions of the mucosa are swollen, and somewhat resemble decidual cells; in the deeper portions, where the glands are dilated and convoluted, they are spindle-shaped. At the time this examination was made (1894) the diagnosis of glandular hypertrophy was rendered, and it was recommended that the case should be watched. At present we should not for a moment hesitate in saying that there is no evidence of malignancy.

Gyn.-Path. No. 1,429

Glandular hypertrophy of the uterine mucosa (Fig. 257).

N., December 9, 1896.

The specimen consists of a small amount of scrapings. The mucosa presents a slightly wavy outline; its epithelium is intact, and the glands, from the surface down, are enlarged and convoluted. In several places, where two convoluted glands lie side by side, the picture is somewhat confusing. The two glands lie one against the other, the intervening wall being very delicate (Fig. 257). Traversing each gland are little folds consisting of exceedingly delicate stems, covered by one layer of cylindrical epithelium. In some places the little folds are seen to pass directly from one side of the gland to the other. The cells are uniform in size, and their nuclei do not show any evidence of division. The stroma of the mucosa surrounding these glands is rather scant.

Gyn. No. 2,828

Glandular hypertrophy of the uterine mucosa.

J., June 16, 1894. Operation. Dilatation and curettage.

Gyn.-Path. No. 336. The specimen consists of uterine scrapings.

Histological Examination.—The surface epithelium is intact. The glands in the superficial portion, but more particularly in the depth, are dilated

and convoluted. The gland epithelium is everywhere intact, but in those areas in which the greatest amount of dilatation has taken place, the cells are considerably flattened, and the nuclei are somewhat swollen. Many of the glands contain oblong, irregular, or branched stems of connective tissue, which are covered by

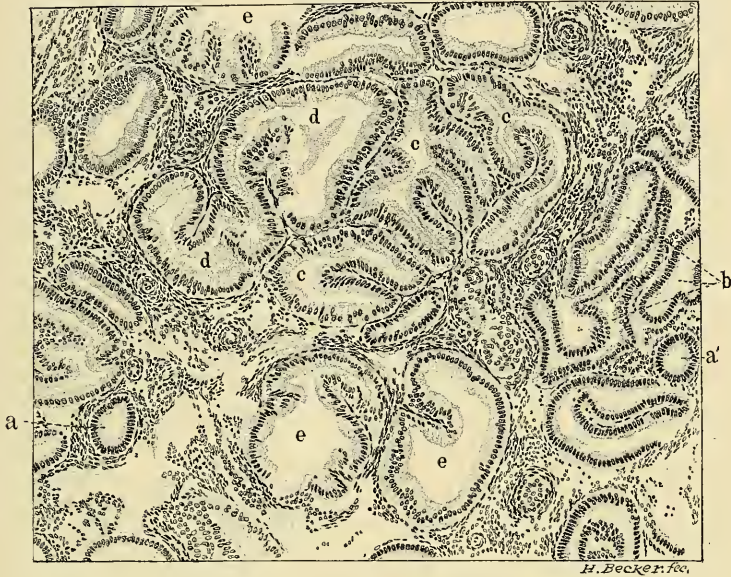

FIG. 257.—HYPERTROPHY OF THE UTERINE GLANDS. (100 diameters.)

Gyn.-Path. No. 1,429. A portion of a scraping from the body of the uterus. *a* and *a'* are cross sections of perfectly normal glands, lined by one layer of cylindrical epithelium. At *b* is a group of normal glands considerably distorted by the curette. *c* and *e* are evidently portions of the same gland. These glands are enlarged, contain little tongue-like ingrowths, and are lined by one layer of very high pale-staining epithelium. At some points the tufts from one wall of the gland practically meet those from the opposite side. At *d* are two formations similar to those indicated by *e*; in this case a direct continuity can be traced between them, showing that they are portions of the same gland. The glands indicated by *e* also show hypertrophy, but in these the convoluted appearance is not so marked. The nuclei of the epithelial cells everywhere are normal. Sections such as this to the beginner, at first glance, are very apt to suggest adenocarcinoma.

one layer of epithelium, and represent cross sections of little projections from the bottom of the gland. Accordingly, they are more abundant in sections of glands near the muscle. The stroma of the mucosa, in the superficial portions, shows considerable swelling of its elements, but in the deeper portions, where the glands are especially dilated, it is compact, and the nuclei, consequently, are spindle-shaped. There is not much danger of confusing this condition with carcinoma.

Gyn. No. 2,844

Glandular hypertrophy (Fig. 258).

O., June 13, 1894. Operation. Dilatation and curettage.

Gyn.-Path. No. 343. The specimen consists of uterine scrapings.

Histological Examination.—The uterine mucosa presents a slightly wavy outline, but the surface is everywhere covered by a single layer of cylin-

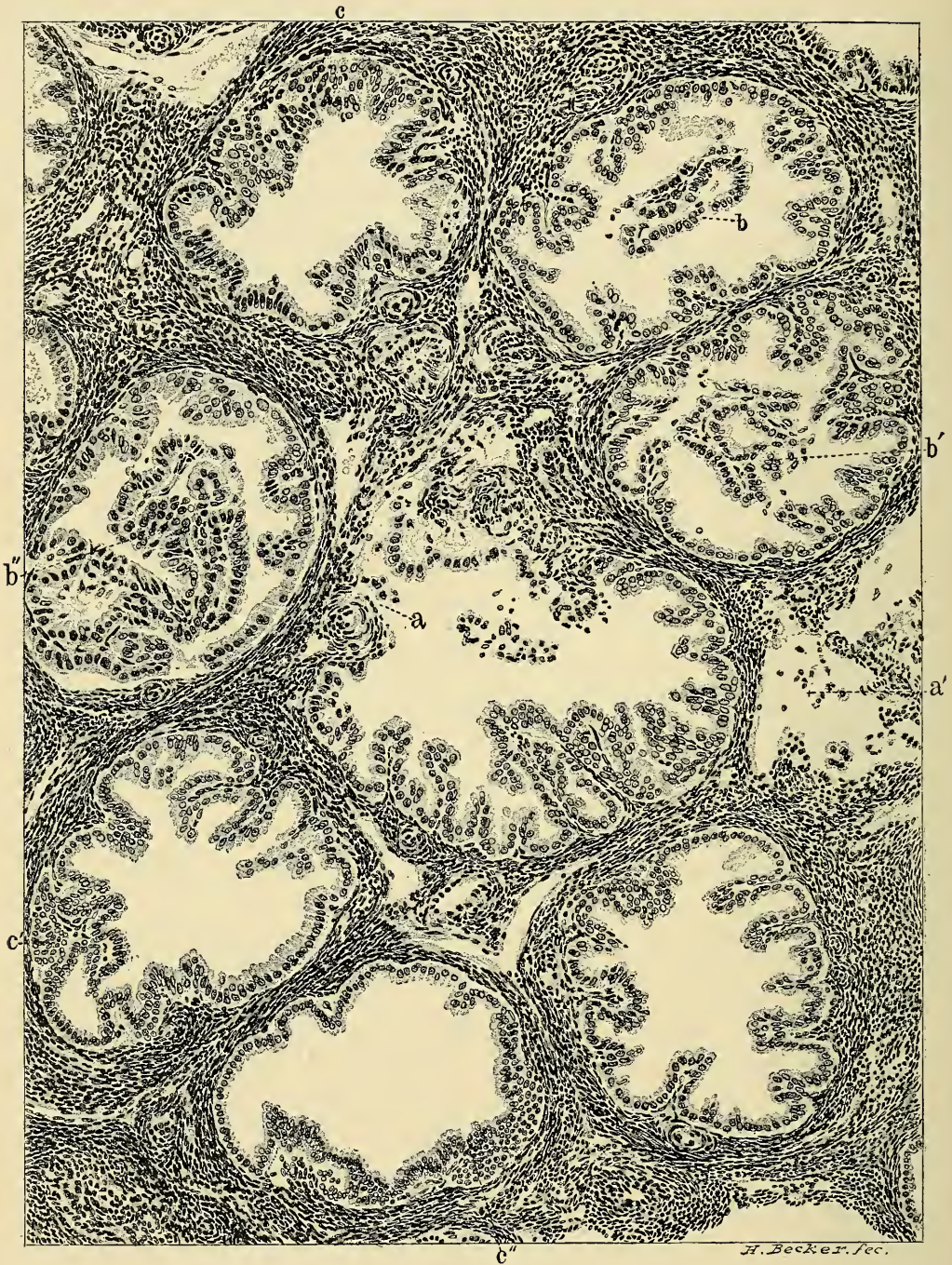

FIG. 258.—HYPERTROPHY OF THE UTERINE GLANDS. (150 diameters.)

Gyn.-Path. No. 343. A fragment from a uterine scraping. In the field we have eight cross sections of enlarged glands. At a glance it will be noticed that they are arranged in an orderly fashion, being equidistant from one another and fairly uniform in size. At *a* there is a loss of continuity in the gland wall; at *a'* there is a break in the stroma. Both have resulted from mechanical injury caused by the curette. All of the glands present a convoluted appearance, due to the delicate tufts springing from their walls. The

dricul, ciliated epithelium. The glands, in their superficial portions, present the usual contour, but as they pass downward toward the muscle they become dilated, convoluted, and show tiny ingrowths (Fig. 258). Where the glands are of the usual size the epithelium is unaltered, but in the deeper portions, where dilatation has taken place, there are projections into the gland cavity, the epithelial cells are swollen, the protoplasm is somewhat granular, and the nuclei are slightly enlarged. The small ingrowths consist of a delicate central stem of spindle-shaped cells, and are covered by one layer of epithelium. Several of the glands contain irregular figures which are branched, consist of a delicate stroma, and are covered by one layer of cells; these represent cross or oblique sections of little growths that project upward from the bottom of the gland lumen. The stroma near the surface of the mucosa is slightly swollen, and shows considerable small-round-cell infiltration; in the deeper portions, where the glands are dilated, it is somewhat compressed, and the cells are spindle-shaped.

A beginner might very readily mistake the dilated and convoluted glands, containing cross sections of branching ingrowths, for parts of a carcinomatous growth.

December 21, 1899. Dr. J. Lincoln Hertz, of Lititz, Pa., writes me that the patient had called at his office about a month before, and that she was in perfect health. Length of time since curettage, five years and six months.

CHARACTERISTIC CHANGES OCCURRING IN THE ENDOMETRIUM DURING PREGNANCY

The Normal Placenta.—Whenever it happens that in curettage of the uterus large quantities of tissue are removed, carcinoma is instantly thought of. In cases of miscarriage pregnancy is often denied, while, on curetting, large quantities of placenta may be removed; thus it will be necessary to differentiate between placental and carcinomatous tissue.

On examination of the placental tissue, it is seen to present a shaggy appearance, as in Cases 662 and 120. This is due to the myriads of slender threads (Fig. 260) of which it is composed. These threads may be fully 1.5 centimetres

gland walls and the ingrowths are covered by one layer of high cylindrical, pale-staining epithelium, and the majority of the tufts contain delicate stems of stroma. At several points the gland epithelium appears to form numerous layers, as at *c*. This appearance may be due to an oblique cut, although it certainly seems as if there were some increase in the epithelial cells. At *c'* and *c''*, however, the several layers are clearly seen to be due to obliquity of the section. At *b* a gland contains a central stem covered by one layer of cylindrical epithelium, a cross section of a projection from the base of the gland. For a clew to the origin of these stems, see Fig. 19 (p. 24), Fig. 20 (p. 24), and Fig. 21 (p. 25). *b'* is a similar but slightly more complicated example. After understanding the simpler forms *b* and *b'*, one can unravel the more complex stem *b''*, and follow its various windings. This has very delicate branches, and is made up of a scanty framework of spindle-shaped connective-tissue cells, covered by one layer of cylindrical epithelium. The epithelial cells throughout the entire field are regularly arranged; their nuclei are remarkably uniform in size. The stroma of the mucosa is composed of cells containing elongate-oval or spindle-shaped nuclei cut lengthwise and transversely; though somewhat dense, it is normal. The hypertrophy, especially in the glands, showing the stems *b* and *b'* and *b''*, might be mistaken for adeno-carcinoma; but when the picture is contrasted with one showing the malignant growth, the points of difference are marked. Compare this figure with Fig. 214 (p. 404), Fig. 192 (p. 376), Fig. 188 (p. 370), Fig. 220 (p. 418), and Fig. 206 (p. 392), all taken from examples of adeno-carcinoma of the body of the uterus.

or more in length, are readily teased apart, show some branching, and will bear considerable traction. Almost the entire placenta consists of these threads, there being little, if any, solid portion.

In adeno-carcinoma the tree-like outgrowths are thick, show more branching, and are not nearly so long; furthermore, they are friable. Again, in some portions of the adeno-carcinoma no thread-like arrangement exists, the tissue being solid and not infrequently showing areas of softening.

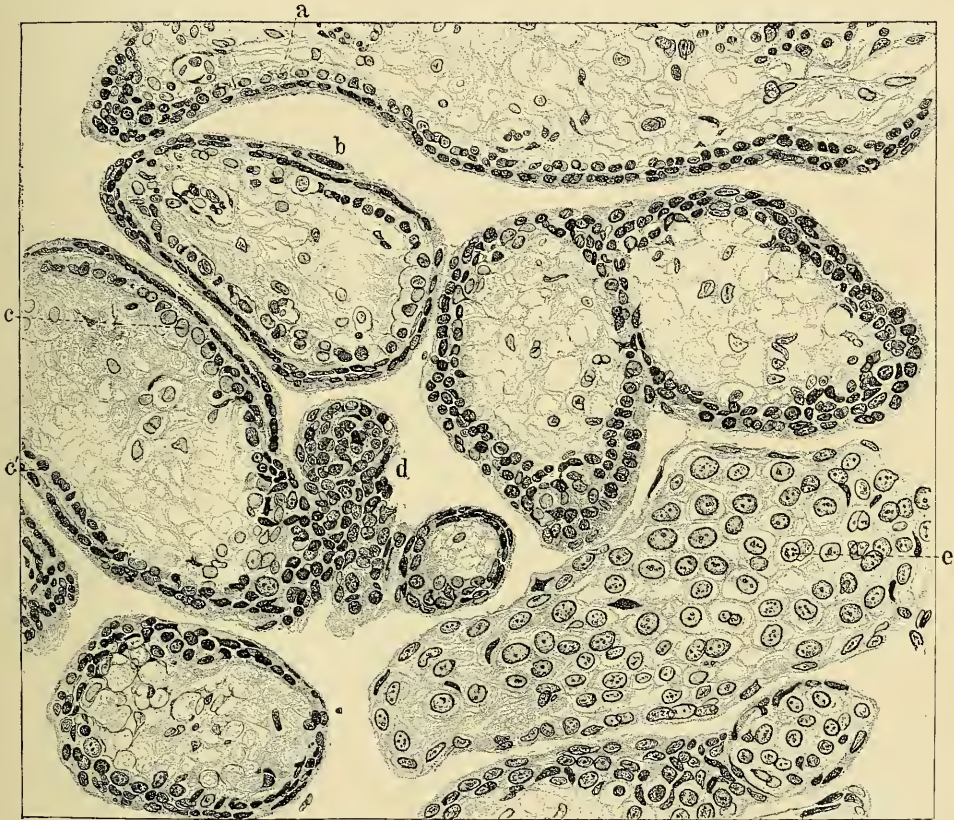On microscopical examination the differences between placental tissue and adeno-carcinoma are still more evident. A specimen from the placenta will show cross and longitudinal sections of the villi lying perfectly free and isolated (Fig. 259, p. 497; Fig. 261, p. 499). These may be round, oval, oblong, or branching; they consist of a delicate stroma composed of spindle-shaped or branching cells, having oval or irregularly-shaped nuclei. On injecting the placenta these villi are found to have a very rich blood supply, many even of the terminal branches containing six or eight vessels. In the early months—the only period during which any confusion in the diagnosis can possibly exist—the outer surfaces of the villi are covered by two layers of cells. The innermost layers of cells have oval or round, pale-staining nuclei, which closely resemble those of the stroma of the villi. I believe that this layer of cells represents nothing more than the outermost stroma cells, that have of necessity assumed a marginal arrangement. The outer or syncytial layer consists of a ribbon of protoplasm, in which it is impossible to differentiate the protoplasm of one cell from that of its fellow. This protoplasm takes the eosin stain, and has scattered throughout it small, round or oval, deeply staining nuclei of variable size.

With a careful macroscopical examination little difficulty should arise in deciding between placental tissue and adeno-carcinoma; furthermore, on microscopic examination there is not the slightest possibility of mistaking placental tissue for a malignant growth of any kind.

So-called Placental Giant Cells.—In some malignant growths giant cells play an important rôle, but in adeno-carcinoma of the body of the uterus they are scanty in number, or may be entirely wanting. In placental tissue the so-called placental giant cells are constantly found. When these are mingled with the villi the diagnosis is clear, but occasionally an isolated example is seen in a section in which no villi are present; hence it will be well to say a few words concerning them.

The outer or syncytial layer of the villi frequently shows considerable thickening, the protoplasm being gathered up into club-shaped or irregular forms (Fig. 261, p. 499). These elevations stain just like the protoplasm from which they spring, and have scattered throughout them, or more usually bunched in the centre, many small, deeply staining nuclei, similar to those found in the parent protoplasm. As might be expected, these outgrowths may be cut at any angle; hence numerous cross or oblique sections are found lying perfectly free in the field, as was noted in Gyn.-Path. Nos. 740, 662, 820, 120. They are then recognised as round, oval, or oblong masses of protoplasm taking the eosin stain, and containing in their centres from eight or ten up to forty or fifty deeply staining nuclei of variable size (see Fig. 261).

These so-called giant cells should not for a moment be mistaken for carcinomatous elements; they lie perfectly isolated, and have a distinct and wide zone of protoplasm that stains rather deeply with eosin; the nuclei are grouped in their centres, are uniform in size, and stain deeply. In adeno-carcinoma, if present, the giant cells are situated in the midst of carcinomatous tissue, are usually irregular in form, and have nuclei which vary much in size.



H. Becker. &c.

FIG. 259.—NORMAL PLACENTA AT ABOUT THE SIXTH WEEK. (300 diameters.)

Gyn.-Path. No. 662. *e* is a group of decidual cells recognisable by the polymorphous character of the cell and the large, oval, vesicular nucleus. The remaining portion of the field is occupied by transverse and longitudinal sections of placental villi, the stroma of which presents a gelatinous appearance and is poor in cell elements. Such cells have oval, vesicular nuclei, and the villus along the upper margin of the section shows some small-round-cell infiltration. Covering the villi are two definite rows of cells: an inner, the layer of Langhans, and an outer layer composed of syncytium. The former, at *a*, consists of cuboidal cells, containing oval, vesicular nuclei. At *e* these are larger and also vesicular, but at *e'* they stain very deeply. *b* represents the outer or syncytial layer composed of a ribbon of protoplasm, which it is impossible to differentiate into cells. Scattered throughout it are elongate-oval, deeply staining nuclei, which are usually round. At *d* a villus has curved on itself; thus a parallel section through the syncytium has been obtained.

Gyn.-Path. No. 662

Normal placenta, 2.5 centimetres in diameter. Foetus, 1.5 centimetres long (Fig. 259), sent by Dr. Douglas, of Nashville, Tenn.

The entire specimen was small, round, and shaggy, and consisted of delicate, slender fibres.

On histological examination, the tissue is found to be made up of typically formed placental villi (Fig. 259). The stroma of these villi is poor in cellular elements. The nuclei are oval or round, and stain somewhat deeply. The blood-vessels of the villi contain delicate cells, having small, round, deeply staining nuclei. These are easily distinguishable from mononuclear leucocytes, which are also seen in the vessel; they appear to be nucleated red blood-corpuscles. The external portions of the villi are covered by two layers of cells; the inner surface is almost flat, and is composed of cells having elongate-oval, deeply staining nuclei. The outer or syncytial layer consists of a mass of protoplasm, varying greatly in thickness; throughout it are scattered small, oval or round, deeply staining nuclei. In some places the syncytium is gathered up into little knob-like projections, which contain many nuclei similar to those found in the syncytium proper. Cross sections of these give rise to the so-called placental giant cells, which are found lying here and there between the villi.

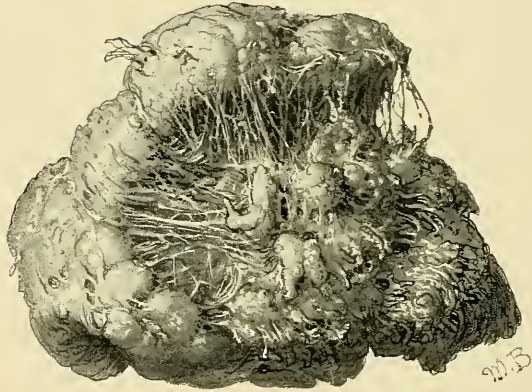


FIG. 260.—A NORMAL PLACENTA AT ABOUT THE TWELFTH WEEK. (Natural size.)

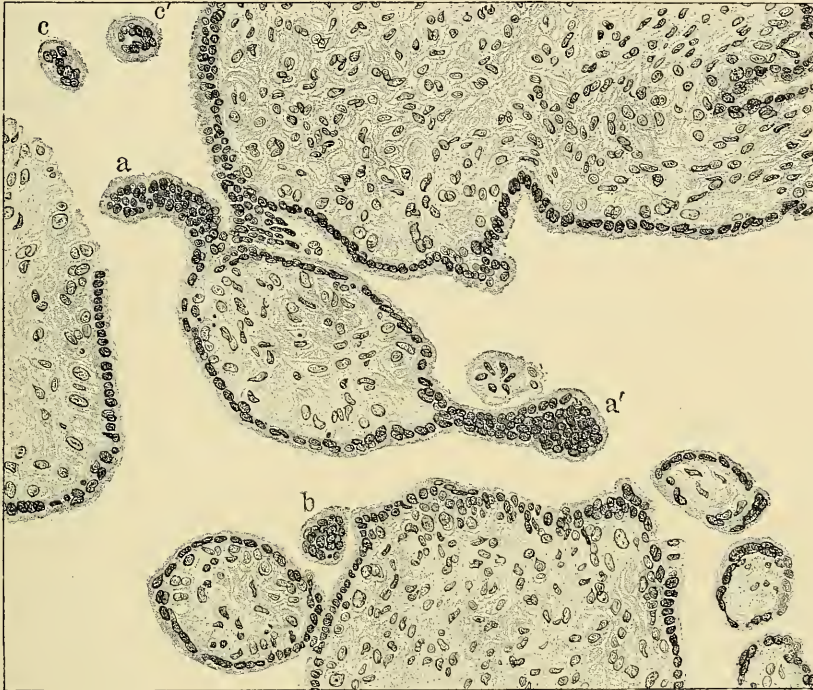
Gyn.-Path. No. 120. The specimen consists of the greater portion of the placenta. The surface corresponds in situation to the uterine attachments. In the outlying portions it presents a homogeneous appearance and is somewhat lobulated; but in the centre, where the tissue has been teased apart, it is seen to consist of delicate threads, some of which are nearly 1.5 centimetres in length. These are narrower, more slender, and less friable than the finger-like outgrowths found in adeno-carcinoma of the body. See Fig. 191 (p. 374), Fig. 201 (p. 384), and Fig. 236 (p. 451). Furthermore, a large piece of carcinomatous tissue, whether well preserved or necrotic, is never expelled from the body of the uterus.

Gyn.-Path. No. 120

Normal placenta at about the twelfth week (Figs. 260, 261).
L., January 2, 1894.

The specimen consists of an oval mass, 8 × 7 centimetres, and 2 centimetres in thickness. The inner surface is smooth and glistening. The outer surface consists of a shaggy material, which, on being teased

out, is seen to be made up of delicate threads, some of which are fully 1.5 centimetres in length (Fig. 260). They are firm, and will bear considerable traction. As one approaches the inner surface, delicate bands of glistening tissue can be seen passing in, and dividing to form these threads, which make up the entire tissue, even to the smooth inner surface. As a whole, we have an entirely different picture to that found in adeno-



H. Becker. sec.

FIG. 261.—NORMAL PLACENTA (AT ABOUT THE TWELFTH WEEK) SHOWING THE SYNCYTIAL BUDS, CROSS SECTIONS OF WHICH PRODUCE THE SO-CALLED PLACENTAL GIANT CELLS. (250 diameters.)

Gyn.-Path. No. 120. The section represents a portion of the placenta seen in Fig. 260. The greater part of the field is occupied by three large villous trunks, surrounding which are cross sections of the secondary branches or small villi. All are made up of a well-developed stroma, consisting of cells containing oval, vesicular nuclei. The outer surface is covered by a layer of syncytium containing the characteristic, round or oval, deeply staining nuclei. Langhans' layer is no longer demonstrable. At points *a* and *a'*, the syncytium forms definite outgrowths or buds, consisting of masses of protoplasm containing round, deeply staining nuclei, similar to those surrounding the villi. Cross sections of these buds present so-called placental giant cells (*b*, *c*, and *c'*).

carcinoma. The threads are much more delicate, do not show the same marked tendency to branch, and are not friable. In adeno-carcinoma one also expects to find solid areas, and where the process is advanced, foci of necrosis or small abscesses. Even with the naked eye one could hardly mistake a piece of such a placenta for carcinoma.

Histological Examination.—Covering the outermost surface of the placenta is decidual tissue, in which a few uterine glands can be seen. These are irregular in shape, and in most places are greatly enlarged; their epithelium may

be much distorted, and sometimes is almost flat. The adjoining nuclei differ greatly in size, some being fully three times as large as those in the vicinity. The gland cavities contain desquamated epithelium and polymorphonuclear leucocytes. The stroma of the mucosa consists almost entirely of decidual cells, between which are numerous small round cells. Here and there are foci of coagulation necrosis, with fragmentation of the nuclei, while along one margin of the specimen not only is there necrosis, but the tissue is riddled with polymorphonuclear leucocytes. Lying on the surface of the decidua are the placental villi, some of which appear to be directly attached to the surface. The villi are cut at all angles; some are round on cross section, others are irregular in form, and show branching, while not a few are oblong. The stroma of the villi is rather scant, and consists of cells having oval or triangular nuclei. The outer surfaces of the villi are covered by two layers of cells, the outer layer of which consists of a ribbon of protoplasm. Scattered throughout this are round or elongate-oval, deeply staining nuclei. The innermost layer is made up of cells having oval or round, faintly staining nuclei.

At numerous points the outermost layer of cells is seen to present localized thickenings; the protoplasm is gathered up into elongate or knob-like projections, and in the centre of such a collection are many deeply staining nuclei, corresponding in every way with those forming the outer layer (Fig. 261). Many cross sections of these knob-like projections are seen lying free between the placental villi. They form the so-called placental giant cells. Occasionally in the depth of the placenta a villus is found surrounded by decidual cells. These lie directly against the villus, or are separated from it by a layer of a homogeneous hyaline substance, probably canalized fibrin.

The blood-vessels in the decidua, wherever found, are dilated, and the decidual cells at such points are especially large.

RETAINED PLACENTA

Occasionally the secundines are retained for several weeks, and the patient has a persistent bloody discharge. On examining the placenta in such a case all trace of the epithelial elements may have disappeared, so that the diagnosis will then be based entirely on the characteristic outlines of the villi, as depicted in Fig. 262.

GLAND HYPERTROPHY OCCURRING IN PREGNANCY

From the following cases it will be seen that in pregnancy the glands in their superficial portions are compressed by the decidual cells, and that they are recognisable only as narrow slits, or may even escape notice altogether. In the deeper portions—namely, in the neighbourhood of the muscle—the condition is reversed. The glands are sometimes dilated and their epithelium is flattened. As a rule, however, besides the dilatation there is a hypertrophy, the glands being markedly convoluted, or having a scalloped appearance, as noted in Case 128 and shown in Fig. 263 (p. 502). The epithelial cells are swollen, and the cell outlines are in-

distinct. The nuclei are, however, uniform in size and do not show any tendency to proliferate. On account of the marked gland dilatation and hypertrophy the stroma is compressed and its cells are spindle-shaped.

Curettings showing such glandular hypertrophy, in the absence of the decidual cells and placental villi, have been mistaken for portions of an adeno-carcinoma by competent observers. When such a section is examined closely, it is found

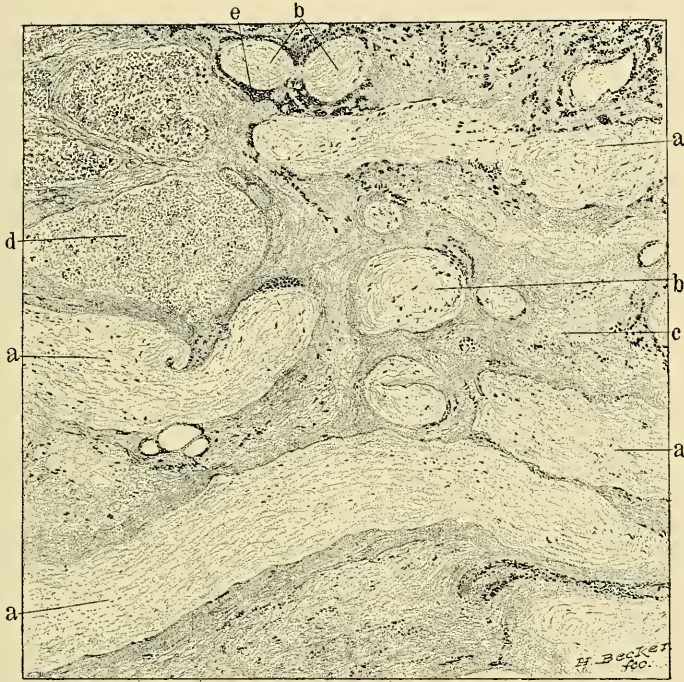


FIG. 262.—APPEARANCES OF THE VILLI IN A PLACENTA WHICH HAS BEEN RETAINED FOR SOME WEEKS IN THE UTERINE CAVITY. (80 diameters.)

Gyn.-Path. No. 2,221. This is the picture at times met with when the fetus has escaped several weeks before the placenta has been expelled or brought away with the curette. At points indicated by *a*, we have mere shadows or outlines of the villi on longitudinal section. *b* shows villi cut transversely. All traces of the stroma and of the outer covering of the cells have disappeared. Surrounding the altered villi is canalized fibrin (*c*), scattered throughout which are venous sinuses, indicated by *d*. Clustered around a few of the villi are polymorphonuclear leucocytes (*e*).

that the glands are equidistant from one another; they are not increased in number, and, although they are markedly convoluted, their epithelium is only one layer in thickness; furthermore, the epithelial cells are uniform in size, have pale-staining nuclei, and show no tendency to fill the gland lumen. These points are sufficient to absolutely exclude adeno-carcinoma.

Normal Decidua.—Small portions of the decidual tissue are often found attached to the placenta, and may form part of the curettings in cases of retained secundines (Fig. 259, p. 497).

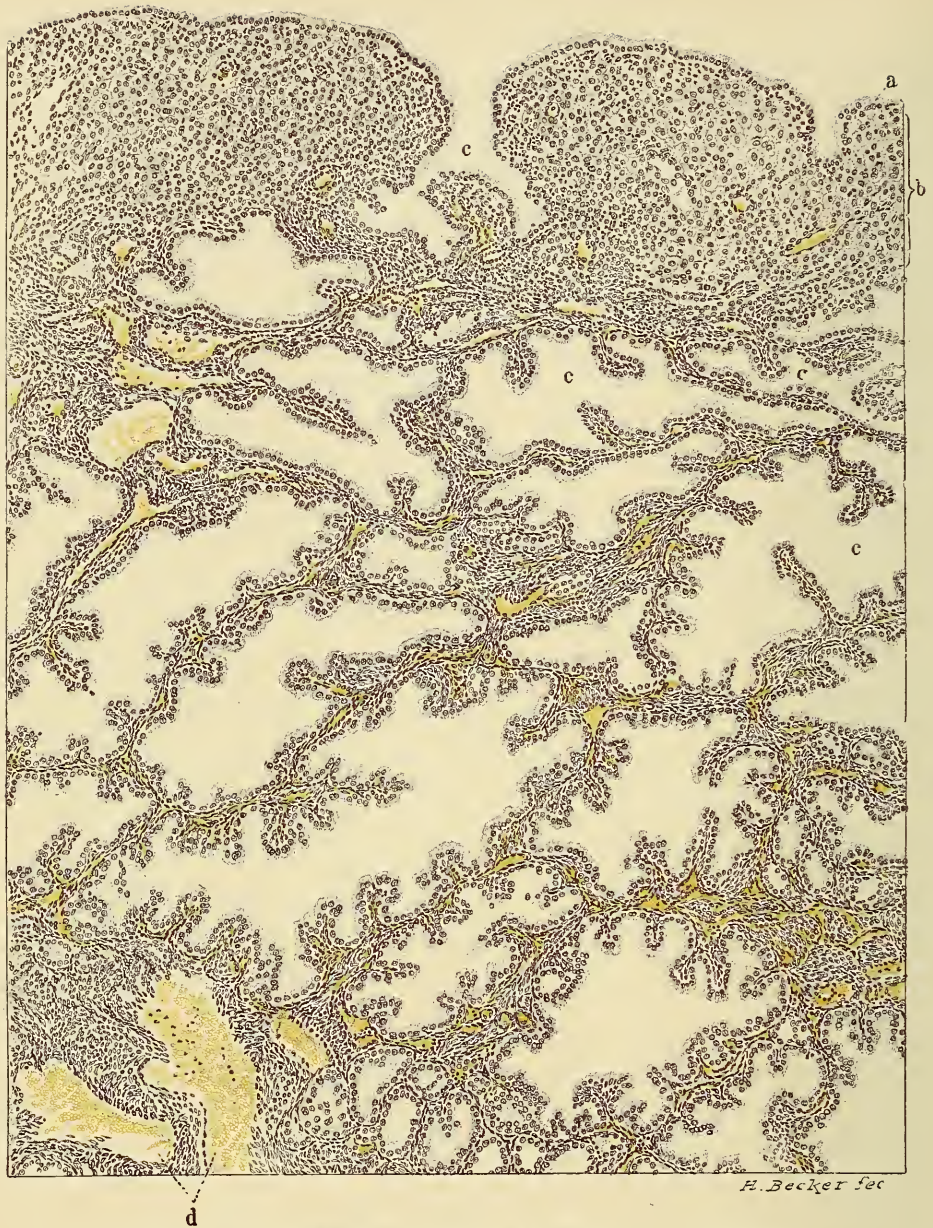


FIG. 263.—GLAND HYPERTROPHY OCCURRING IN PREGNANCY. (90 diameters.)

Gyn.-Path. No. 1,281. This section has evidently been taken from the mucosa near the margin of the placental site, since all trace of the surface epithelium usually disappears from the site of the placental attachment. The surface of the mucosa is smooth. The epithelial covering (*a*) is intact. The area designated by *b* represents the decidua, which at this point is rather thin. It is recognisable by the characteristic polygonal cells, clearly outlined from each other, and containing round, vesicular nuclei. Between these altered and swollen stroma cells, near the surface, are a few small round cells and polymorphonuclear leucocytes. The blood supply of the decidua at this point is rather scanty. Beneath the decidua, the glands, some of which are indicated by the letter *c*, are markedly dilated; they have convoluted margins, and small tufts project into their lumina. The glands are lined by one layer of low cylindrical, or cuboidal, somewhat pale-staining epithelium. The nuclei, which are uniform in size, are vesicular. The stroma between the glands is compressed, consists of spindle-shaped cells, and has a rich capillary blood supply. At *d* are two fairly large veins. The glands, although markedly convoluted, present a striking regularity in size. They are equidistant from one another, and are lined by only one layer of epithelium, which is somewhat flattened.

The decidua is nothing more than altered uterine mucosa. In the vicinity of the placenta it has an intact surface epithelium, but the cells are somewhat flattened and are usually swollen; the glands in the superficial portion are flattened, and are recognisable as narrow slits lined by one layer of cuboidal epithelium. Sometimes they cannot be detected. The glands in the deeper portion are often the seat of a hypertrophy, of which we have had occasion to speak in detail. The stroma in the superficial portion of the mucosa is much altered, as seen in Fig. 263; the individual cells are swollen, being round, oval, or sometimes spindle-shaped, and contain round, vesicular, sharply defined nuclei. These cells are nothing more than the swollen stroma cells; between them are numerous small round cells. Scattered throughout the superficial portions of the decidua are many large venous sinuses (Fig. 264, p. 504), some of which are partially or completely filled with thrombi. Numerous small arteries are also seen. These usually occur in groups of six or eight, the stroma cells around them being swollen, and the endothelium of the vessels thickened (Fig. 265, p. 505).

The portion of the decidua on which the placenta rests, except that it is devoid of surface epithelium and presents an uneven surface, looks much like the remainder. The part of the decidua which has just been described bears no resemblance to carcinomatous tissue, and should not for a moment be mistaken for it.

Gyn.-Path. No. 128

Usual appearance of the scrapings in cases in which a portion of the placenta has been retained.

Operation. Dilatation and curettage.

The specimen consists of a moderate amount of uterine scrapings. The mucosa has an undulating surface, and is covered by one layer of cuboidal or low cylindrical epithelium. In the superficial portions of the mucosa the glands are hardly recognisable, and almost the entire tissue is composed of decidual cells. In the deeper portions of the mucosa, however, the glands are abundant, large, and convoluted; their epithelium is gathered up into delicate, finger-like, branching folds. The individual epithelial cells are swollen, and are outlined with some difficulty; their nuclei are large, practically round, and take a homogeneous stain. In no place does the epithelium tend to proliferate and fill the gland cavity; the nuclei are everywhere uniform in size. In this portion of the mucosa the stroma is scanty, and consists of spindle-shaped cells; there is often nothing more than the walls of a capillary separating one gland from its neighbour. Examinations of other specimens show the presence of placental villi.

Gyn.-Path. No. 578

Normal decidual and placental tissue (Fig. 264).

Judging from the size of the foetus, the patient was about four months pregnant.

Histological Examination.—The specimen contains decidual and placental tissue. Scattered here and there throughout the decidua are elongate,

or irregularly oval, spaces lined by one layer of epithelium. These epithelial cells are swollen, have a somewhat brownish protoplasm, and contain large, oval, vesicular nuclei. In some places this epithelium becomes flat. The spaces above

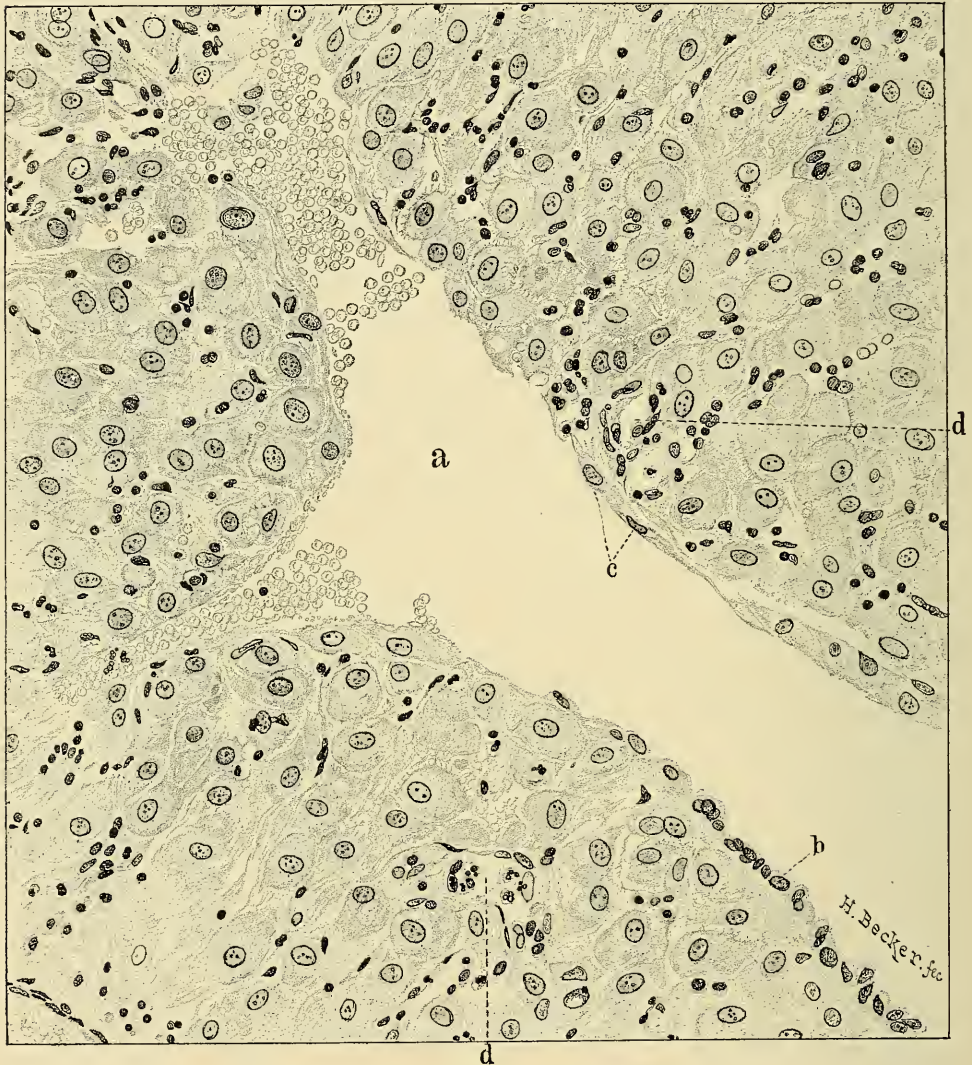

FIG. 264.—NORMAL DECIDUA. (300 diameters.)

Gyn.-Path. No. 578. In the centre is a large vein (*a*) containing some blood in its branches. Its walls are very delicate, consisting only of endothelium, which at *b* is somewhat heaped up and distorted. At *c* the cells are swollen, but are still intact. Surrounding the vessel, and occupying almost the entire field, are decidual cells, polygonal in form, rich in protoplasm, and containing oval, or round, vesicular nuclei. Between the decidual cells are numerous small round cells. Delicate capillaries are indicated by *d*.

described are the altered uterine glands. The decidual cells appear as large, irregular, or oval plaques of protoplasm (Fig. 264), containing oval, vesicular nuclei; in some of them two distinct nuclei are visible. A few of the nuclei

stain very deeply, leading one to suppose that some cell division has been going on. Scattered here and there among the decidual cells are small round cells. In a few places the decidual cells are undergoing coagulation necrosis. The blood supply is abundant; the vessel walls consist of a single layer of endothelium. The decidua is perfectly normal.

Gyn.-Path. No. 754

Placenta *in situ*. Decidual giant cells developing from muscle and connective-tissue cells just beneath the decidua. Typical decidual cells derived from the endothelium of the blood-vessels (Fig. 265).

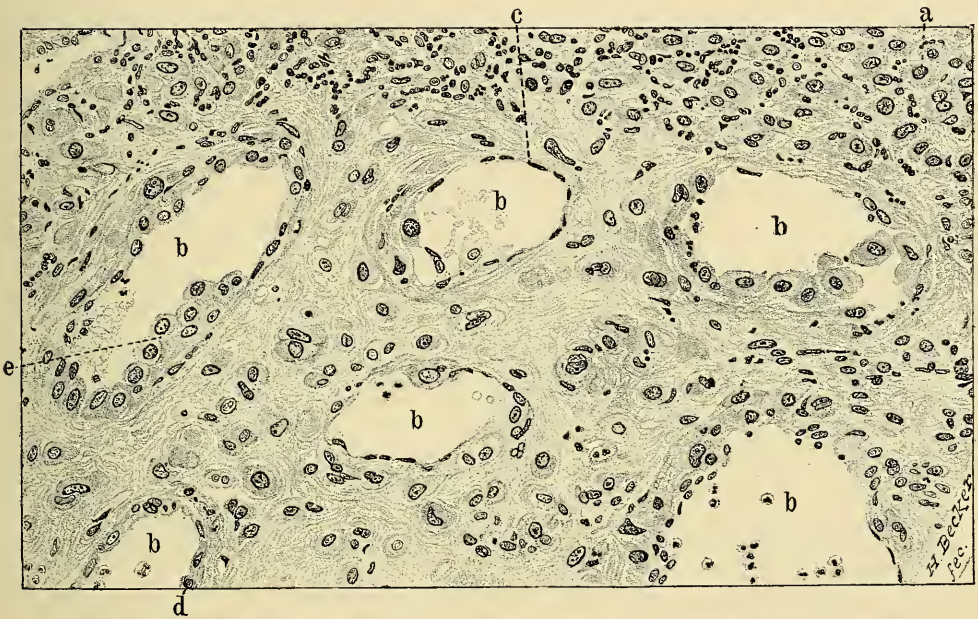


FIG. 265.—DEVELOPMENT OF DECIDUAL CELLS FROM THE ENDOTHELIUM OF THE BLOOD-VESSEL.
(180 diameters.)

Gyn.-Path. No. 754. Lying in a large mass of decidual cells, the edge of which is seen at *a*, is a group of blood-vessels (*b*). Scattered through the connective tissue between these vessels are isolated decidual cells. At *c* the endothelium of a blood-vessel is spindle-shaped and normal; at *d* it is considerably thickened and almost cuboidal, while at *e* the endothelium has proliferated, forming one or two rows of typical decidual cells. In the same vessel the endothelium at one point is still spindle-shaped. In several other places this formation of decidual cells from endothelial cells is visible. Between the outlying decidual cells are small round cells.

Histological Examination.—The villi exhibit much degeneration. The decidua presents the usual appearances, and groups of blood-vessels show the characteristic hyaline change, the tissue between them consisting of hyaline, with decidual cells scattered sparingly throughout it. The vessels are lined by one layer of endothelium, which has here and there proliferated, forming typical decidual cells (Fig. 265). The chief interest in the specimen centres in the muscle just beneath the decidua.

Here there is considerable change. The muscle fibres vary greatly in size, the nuclei of some of them being fully four times as large as those of the surrounding ones. Some of the enlarged nuclei are oval and vesicular, while others are irregular and stain deeply. Not infrequently a muscle fibre will contain two or more nuclei. In the connective tissue between the muscle bundles there is also considerable change; the connective-tissue cells have proliferated and have formed spindle-shaped or irregular giant cells. These may contain three or four nuclei in a row; in some of them there are as many as fifteen or twenty nuclei. While the majority of the large cells are scattered throughout the muscle near the mucosa, a few are found at a considerable depth. Those in the connective tissue appear to some extent to follow capillaries, but whether these small channels are blood-vessels or lymphatics it is impossible to say.

DECIDUAL GIANT CELLS IN THE MUSCLE

Up to the present time but little attention has been paid to these cells. Nevertheless, in all of the five cases in which I have had the opportunity of examining the human placenta *in situ* they were always present. In two of these cases the placenta were fully developed, Cesarean section having been performed at

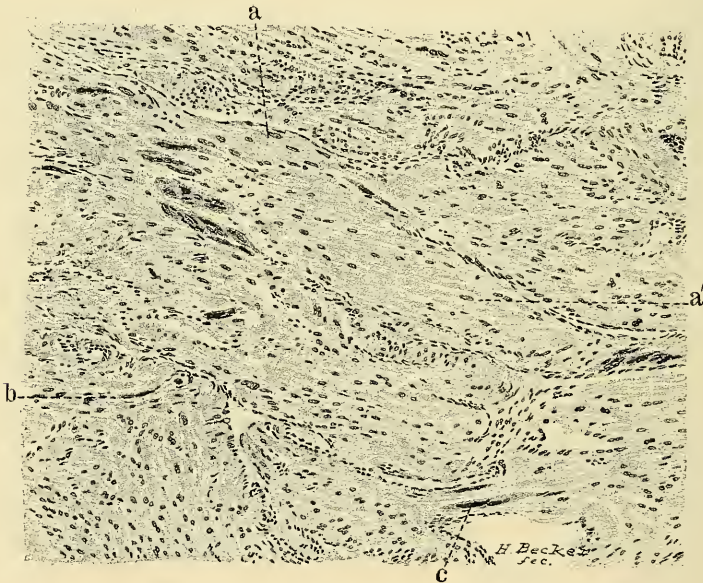


FIG. 266.—DECIDUAL GIANT CELLS IN THE MUSCLE. (85 diameters.)

Gyn.-Path. No. 186. The section is from the muscle just beneath the decidua, from a pregnant uterus at full term. *a* and *a'* are swollen muscle nuclei. At *b* is an elongate, deeply staining nucleus of a muscle fibre. At *c* a spindle-shaped mass of protoplasm, containing two deeply staining nuclei, is seen lying in the outer wall of a vein, while in the upper and left portions of the field are several large, dark areas, composed of elongate-oval masses of protoplasm, containing numbers of small, irregular, deeply staining nuclei. These giant cells are in the connective tissue between muscle bundles.

term. In one case pregnancy had gone on for four and a half or five months, the uterus having been removed on account of multiple myomata. The fourth

patient had died of pneumonia at term. In the fifth case no particulars could be obtained.

Scattered throughout the muscle, just beneath the decidua, were decidual cells appearing singly or in groups. They were for the most part confined to the connective tissue between the muscle bundles, and appeared at times to follow the course of the blood-vessels. Both in the connective tissue and in the muscle bundles themselves giant cells were found (Figs. 266 and 267). These consisted of spindle-shaped or irregular masses of protoplasm, containing from two to twenty or more deeply staining nuclei, which were at times arranged in rows of six or seven, or formed a mulberry-shaped mass in the cell. Although the majority had evidently originated from the connective tissue, not a few had developed from muscle fibres, as was demonstrable in Gyn.-Path. Nos. 740, 870 (p. 508), 754 (p. 505), and 186 (Fig. 266). Some of the muscle nuclei were slightly swollen; others were much enlarged; a few contained two nuclei; in short, all transitions from normal nuclei could be traced.

This change in the muscle appeared to be limited to the area just underlying the decidua.

It is interesting to note that such changes may occur even under normal conditions. From a single microscopic field of this kind one might be led to strongly suspect the existence of a malignant growth; but in a careful study of the whole specimen the detection of typical decidua and placental villi would clear up the diagnosis.

Gyn.-Path. No. 740

Decidual giant cells in the uterine muscle, originating from the connective tissue and the muscle fibres.

The specimen, sent by Dr. Sutton, of Pittsburg, consists of a pregnant uterus, from the posterior surface of which springs a large subperitoneal myoma.

The uterus is ovoid in shape, being 12 centimetres long, 11 centimetres broad, and 9.5 centimetres in its antero-posterior diameter. Both anteriorly and posteriorly it is smooth and glistening. The uterine walls vary from .6 to 1 centimetre in thickness. The uterine mucosa just within the internal os reaches 5 millimetres in depth. The anterior portion of the uterine cavity, as well as the right side, are covered by placental tissue. The uterine muscle is traversed by many slits, which run parallel with the long axis of the organ and give to the tissue a decidedly porous appearance. The placenta is intimately attached to the uterine wall, and in its central portion is 9 millimetres in thickness. The cord is inserted about midway between the fundus and the internal os. The uterine mucosa at the fundus reaches 3 millimetres in thickness; it is smooth and glistening. The sac which contains the fœtus fills almost the entire cavity; it is approximately globular, has a diameter of 7 centimetres, and is smooth and glistening. The fœtus, when doubled up, is 6 centimetres in length.

Histological Examination.—The placental villi present their usual appearance, and are covered by the characteristic two layers of cells. Scattered between the villi are numerous so-called placental giant cells. The villi occasionally lie directly on the decidua, but at most points are separated from it by a

small amount of canalized fibrin. The decidual cells present the normal appearance. Scattered between them are many small round cells, in some of which nuclear division is apparently going on. The uterine glands are still to be made out in the decidua. In the superficial portions they are somewhat flattened, and the epithelial cells are cuboidal or almost flat. In the deeper portions the glands are dilated, the epithelium is much flattened, and there is very little stroma between the glands.

At some points the muscle immediately beneath the decidua is normal, but elsewhere it shows changes which are especially noticeable in the connective tissue around the blood-vessels and between muscle bundles. At such points there are bunches of typical decidual cells in process of development from the connective-tissue cells. There are also masses of protoplasm taking the haematoxylin stain, and containing eighteen to twenty or more nuclei; sometimes six or seven nuclei occur in a row. Not a few of these large cells are derived from another source—the muscle fibres. Some of the nuclei of the muscle fibres are normal; others stain more deeply, and are slightly enlarged. It is possible to trace the transitional forms until they attain the size of the large nuclei.

The uterine mucosa in the vicinity of the placenta is converted into typical decidua, and has a comparatively even surface. It is covered by one layer of epithelium, which shows much variation from the normal cylindrical type. The cells are swollen, and the protoplasm is granular; the nuclei are also swollen and somewhat distorted. The decidual cells present the usual appearance; there is a considerable degree of small-round-cell infiltration. The veins are dilated, forming large sinuses. The glands also are dilated, their epithelium being much flattened. The underlying muscle at such points is perfectly normal.

Gyn.-Path. No. 870

A uterus of an early pregnancy showing decidual giant cells in the muscle (Fig. 267).

The specimen consists of the uterus removed at autopsy. The patient had miscarried in the fifth month, during an acute attack of pneumonia, and had died within a few days. A section was made through the entire thickness of the uterine wall. On the inner surface, which was covered with blood, there appeared cross and longitudinal sections of many placental villi. In the deeper portions the villi were still preserved; the outer or syncytial layer was everywhere recognisable, while scattered between the villi were numerous so-called placental giant cells. Separating the villi from the altered decidua was a layer of homogeneous material that took the eosin stain. This was probably canalized fibrin. The muscle in the vicinity was much altered, being infiltrated by giant cells, which appeared as spindle-shaped, oval, or round, masses of protoplasm, containing nuclei, which were oval or round, and stained deeply. Others of these giant cells contained two or three nuclei of variable size; while in others, again, large mulberry-shaped nuclei were seen. The large cells were found not only in the decidua, but also in the muscle at some depth. Here they appeared principally in the connective tissue between the muscle bundles, occurring in groups of six or

more (Fig. 267). Some of these giant cells contained one or two nuclei, while in an adjoining cell ten or more could be seen. Although it was probable that a good many of these giant cells had originated in the connective tissue, the muscle fibres in the vicinity were occasionally found to be swollen, and were tending to form such giant cells.*

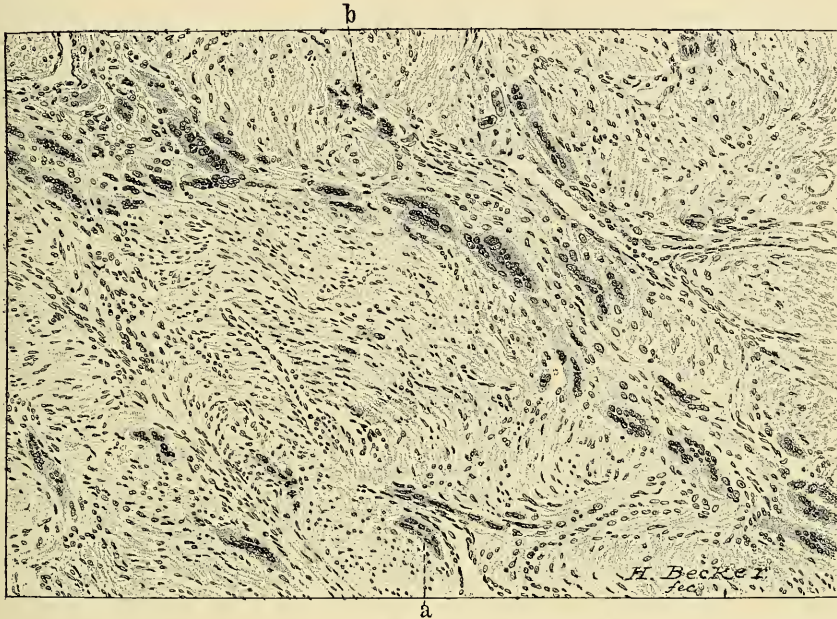

FIG. 267.—DECIDUAL GIANT CELLS IN THE UNDERLYING UTERINE MUSCLE. (170 diameters.)

Gyn.-Path. No. 870. The specimen consists of bundles of muscle fibres from a point a short distance beneath the decidua, in a pregnant uterus at full term. Scattered freely throughout the field are giant cells. These are found chiefly in the connective tissue between muscle bundles, as seen at *b*. At a few points they lie within the muscle bundles (*a*). The giant cells vary much in shape, and consist of large masses of protoplasm containing from two or three to twenty nuclei, which are uniform in size, and vesicular.

The giant cells, on the whole, strongly resembled the so-called placental giant cells; their protoplasm, however, stained more intensely with hæmatoxylin, while those of the syncytium took the eosin; furthermore, the nuclei of the so-called giant cells, as a rule, were more regular than those found in the muscle.

Were one to examine a field showing nothing but muscle and these giant cells, a malignant growth might very readily be suspected. The subsequent finding of the villi would of course negative such a supposition.

THE UTERINE MUCOSA IN CASES OF EXTRA-UTERINE PREGNANCY

In cases of extra-uterine pregnancy in which uterine hæmorrhages occur, and in which the history of impregnation is obscure or the possibility is denied, car-

* A similar transformation was found in a four months' pregnancy in a rudimentary horn (Gyn.-Path. No. 572, p. 510), in which the muscle fibres were undoubtedly taking part in the formation of decidual cells.

cinoma of the uterus may be suspected. On bimanual examination, the organ will be found to be but little enlarged. To find out the true condition, it may be necessary to curette the uterus. If there be an extra-uterine pregnancy, alterations in the mucosa may or may not exist. In Gyn.-Path. No. 501, in which a left tubal pregnancy was present, degenerated placental villi were found, but no fœtus was seen. It is quite probable that in this case, even if a decidua had formed in the uterus, the child had been dead so long that the mucosa had had time to regain its usual appearance. In Gyn.-Path. No. 1,959, also an example of a tubal pregnancy, histological examination of the uterine mucosa showed it to be unaltered.

Had the uterus from Gyn.-Path. No. 572, in which pregnancy in a distant and rudimentary horn existed, been examined, a very different result would have been obtained. The curettings would have been very abundant, but the surface of the mucosa would have presented a comparatively smooth surface, instead of the papillary appearance seen in carcinoma. Further, the histological examination would have revealed the glandular hypertrophy and the typical decidual formation described in detail on page 500—a picture differing widely from that found in adeno-carcinoma.

Gyn.-Path. No. 1,959

Unruptured tubal pregnancy. Normal uterine mucosa.

J., October 20, 1897. The patient gave a history indicative of a three months' pregnancy. The proximal end of the tube averaged 4 millimetres in diameter, but after passing outward 12 centimetres it merged into an irregularly ovoid mass, 6 centimetres long, and measuring from 4.5 to 4 centimetres in diameter. On histological examination, degenerate placental villi were found. The uterine mucosa was normal in every particular.

Gyn.-Path. No. 501

Old tubal pregnancy. Normal uterine mucosa.

G., November 3, 1894. The specimen consisted of the uterus and appendages. On the left side the tube was converted into a mass approximately 14×8 centimetres. This was composed chiefly of blood. On histological examination, Dr. Williams found numerous degenerated placental villi in the blood.

The uterus was slightly enlarged; its mucosa was somewhat roughened. On histological examination, the surface epithelium was everywhere intact, the glands presented the usual appearance, and the stroma was unaltered. In other words, there was not the slightest trace of any decidual formation.

Gyn.-Path. No. 572

Pregnancy in a rudimentary uterine horn. Typical decidua in the unimpregnated uterus.*

In this case there was a well-developed uterus. Attached to its left side was a duct, which, after running for a distance of 7 centimetres, entered a rudimen-

* Cullen, Thomas S., and Wilkins, G. L. *Pregnancy in a Rudimentary Uterine Horn; Rupture; Death.* Johns Hopkins Hospital Reports, 1897, vol. vi, p. 113.

tary uterine horn. The rudimentary uterus was 6 centimetres long, 4.5 centimetres broad, and 4.5 centimetres in its antero-posterior diameter. It was smooth, glistening, and presented typical muscular striation. In its posterior wall was a rent, 4 centimetres in length, through which projected placental tissue. At the time of autopsy 4,000 cubic centimetres of blood were found in the abdominal cavity, and a fœtus, 11 centimetres in length, was lying free among the intestines. On microscopic examination of the well-developed uterus, in which no pregnancy existed, the glands of the cervix were found to be dilated; the epithelium was very pale. The mucosa lining the body of the uterus varied from 6 to 8 millimetres in thickness, and had a smooth surface. The surface epithelium was in most places intact, but consisted of one layer of flat cells. The mucosa was divisible into three layers: a superficial layer, in which practically no glands could be seen; a middle layer, in which the glands appeared as narrow slits lined by one layer of cuboidal or low cylindrical epithelium; and a third layer, composed of glands which were somewhat dilated, and had convoluted, wavy outlines. The epithelium lining the convoluted glands was very abundant; the individual cells were enlarged, and their nuclei appeared to be swollen. The stroma of the mucosa was represented by decidual cells, the nuclei of which were irregularly oval, spindle-shaped, or round. Scattered everywhere throughout the stroma were small round cells. As one approached the muscle the decidual cells lost their characteristic appearance, assuming the usual type of stroma cells. The stroma of the mucosa, in its superficial and middle layers, contained many blood-vessels, which might justly be called sinuses. Their walls were composed merely of one layer of endothelium, which separated them from the stroma cells. These sinuses contained canalized fibrin, which in many places had myriads of polymorphonuclear leucocytes in its meshes. The uterine muscle was normal.

EXFOLIATED MENSTRUAL MEMBRANE

As is exemplified in the accompanying case, although the outer surface may present a shaggy appearance, the threads comprising the membrane are too regular to be confounded with adeno-carcinoma. Again, in no case of carcinoma would there be a smooth inner lining; and, lastly, the microscopic examination demonstrates that this membrane in no manner resembles carcinomatous tissue.

Gyn.-Path. No. 686

S., April, 1895.

The specimen consists of what appears to be a cast of the uterine cavity. The membrane forms a hollow cone, 4.5 centimetres long, 3 centimetres in diameter, the walls averaging 5 millimetres in thickness. From its outer surface, which is uneven, spring many delicate threads. The inner surface is somewhat corrugated, but is smooth and glistening.

On histological examination, this inner surface presents a wavy outline, and here and there appears to be covered by an ill-defined layer of flat epithelium. Through its entire thickness the membrane is composed of round and irregular cells, that have oval, triangular or somewhat irregular, deeply-staining nuclei. Some of the cells are spindle-shaped, but all bear a considerable resemblance to

decidual cells. The cells lie loosely in a homogeneous matrix, while scattered between them are masses of small round cells. Here and there numbers of small blood-vessels and many large irregular venous sinuses are noticed. These are lined by one layer of endothelium, and contain much canalized fibrin. The cells in the deeper portion of the membrane are smaller, and more closely packed. Sections submitted to the Weigert stain show that several blood-vessels contain masses of cocci; the surrounding tissue, however, exhibits absolutely no inflammatory reaction.

From the clinical history the tissue must be taken as representing an exfoliated menstrual membrane.

CONDITIONS IN ENDOMETRITIS THAT MIGHT BE TAKEN FOR EARLY ADENOCARCINOMA OF THE BODY OF THE UTERUS

We limit ourselves here entirely to the pathological aspect of this question, as the clinical phenomena offer no definite clew as to the condition present.

Within the last four years we have had the opportunity of examining specimens from between fifty and sixty cases of endometritis—a very small number, considering the supposed frequency of this affection. About one fourth of the cases have presented pictures offering varying degrees of similarity to carcinoma of the body of the uterus.

For several years it has been the custom to remove the uterus whenever the appendages on both sides were the seat of a marked pyosalpinx. Since in all of these cases we have been able to obtain the specimen perfectly fresh and before it had been handled, the surface epithelium has been preserved intact, enabling us to study the minutest changes occurring in it.

In the usual run of cases there is not the slightest difficulty in differentiating between adeno-carcinoma and endometritis, inasmuch as in the latter, macroscopically, the mucosa is smooth, not presenting the tree-like growth found in cancer; and further, on microscopic examination, the surface epithelium is intact and the glands are comparatively normal. The chief alteration consists in the infiltration of the tissues with polymorphonuclear leucocytes.

The doubtful cases may be conveniently divided into two groups: 1, those presenting gross appearances somewhat resembling those of cancer of the body; 2, those showing suspicious histological changes.

1. Cases of Endometritis presenting Gross Appearances somewhat resembling those of Adeno-carcinoma of the Body

Only two—a very small percentage—of our cases have presented a macroscopic picture that was likely to be mistaken for carcinoma. In Case 4,921 (p. 513) the entire uterine cavity was lined by polypi varying from 1.5 to 2 millimetres in length, and projecting from 5 to 7 millimetres into the cavity (Fig. 268, p. 514). These pointed toward the internal os, and on careful examination were found to be blunt or rounded at their ends. In adeno-carcinoma, as will be remembered, the projections were usually more sharply defined, branched, and ended in pointed extremi-

ties (see Fig. 191, p. 374; Fig. 193, p. 377; Fig. 208, p. 395). Moreover, they were more friable, and the underlying muscle was invaded by a yellowish-white growth. In cases of endometritis, however, the muscle is not involved.

On histological examination, the points of differentiation are still more striking. In Case 4,921, the rounded forms of the polypi, as seen under the microscope, are well defined (Fig. 269, p. 515); they are covered by only one layer of epithelium or are entirely devoid of covering, while the greater part of their stroma is composed of small round cells. In carcinoma, on the contrary, the projections are very pointed, and show marked branchings both on their sides and at the tips (see Plate VIII, and Fig. 181, p. 357). Again, the surface is more frequently covered by several layers of cells, which usually show evidences of active division. But the most important differential point lies in the fact that the epithelium projects into and invades the muscle, while in endometritis the glands in the deeper parts of the mucosa are usually normal and the muscle is unaltered.

In Case 3,476 (p. 516) the polypoid or warty condition of the mucosa was somewhat more marked than in the preceding case, so that at the time of operation the case was regarded by several of the onlookers as one of adeno-carcinoma (Fig. 270, p. 516). On the other hand, the inflammatory process was less marked; the epithelium covering the polypi was intact, in some places looking normal, but at other points being swollen, and occasionally two to three layers in thickness. The cells in the thickened areas, however, were pale, contained no nuclear figures, and showed no tendency to invade the mucosa. The uterine glands, as a rule, were normal.

Thus it will be seen that while in both of these cases the macroscopic picture was somewhat suggestive of adeno-carcinoma, the histological appearances were entirely different.

Detailed Report of Cases of Endometritis presenting Gross Changes Suggestive of Adeno-carcinoma of the Body of the Uterus

Gyn. No. 4,921

Endometritis with polypoid formation (Fig. 268). Histological picture totally different from that of adeno-carcinoma (Fig. 269); localized thickening of the surface epithelium, at one point suggesting squamous epithelium. General pelvic peritonitis; nodular salpingitis in the left tube.

J., aged twenty-three. January 8, 1896.

Gyn.-Path. No. 1,466. The specimen consists of the uterus with its appendages intact. The portion of the uterus present is 8.5 centimetres long, 9 centimetres broad, and 7 centimetres in its antero-posterior diameter. Its surface is everywhere covered by dense vascular adhesions, and all parts of the organ are firm and resistant. The uterine cavity is 6.5 centimetres in length, its breadth at the fundus being 3.7 centimetres. The mucosa varies from 2 to 4 millimetres in thickness, is bright red in colour, and is covered with a thick, creamy, puru-

lent fluid. When this is removed, the mucous membrane is found to be gathered up into polypi of variable size; some of those in the lower part of the cavity are no larger than a pin-point, but on an average they are from 1.5 to 2 millimetres in breadth and 5 to 7 millimetres in length (Fig. 268). They point toward the internal os. In the upper part of the uterine cavity these polypi are very small, few of them projecting 1 millimetre from the surface. At no point in the cavity is the mucosa smooth. The uterine walls vary from 2 to 3.5 centimetres in thickness, and are coarsely striated.

On histological examination, the surfaces of the polypi are in a few places covered by one layer of flattened epithelium, but over the greater

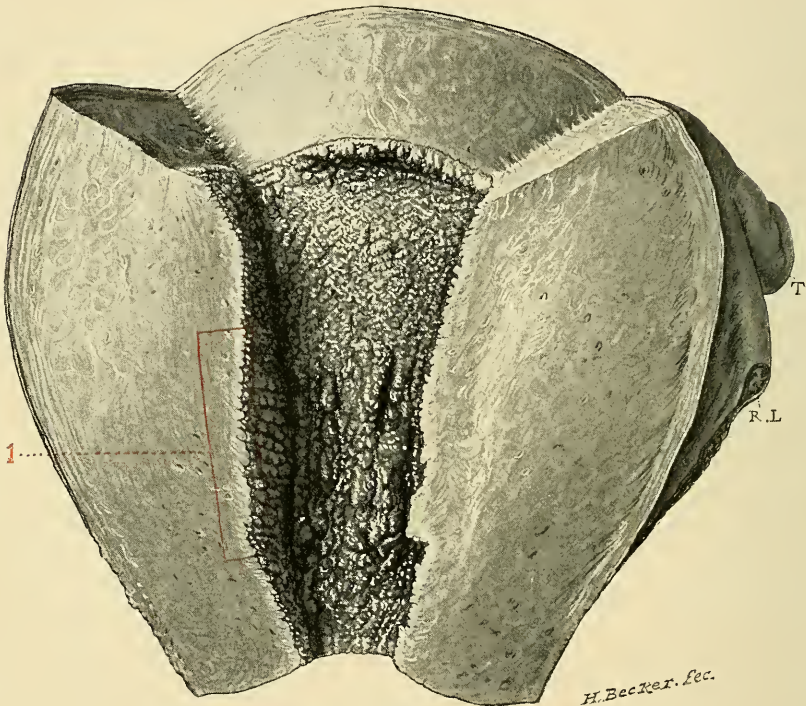


FIG. 268.—POLYPOID ENDOMETRITIS. (Natural size.)

Gyn.-Path. No. 1,466. The uterus and appendages were removed on account of the salpingitis and the general pelvic peritonitis. The uterus is enlarged; its walls are thickened and very dense. The entire uterine cavity is lined by a shaggy growth, consisting of small stubby polypi, which point toward the internal os. These vary considerably in size, but the majority are of the same length and have rounded ends. The junction between these outgrowths and the muscle is not very sharply defined, nor is there any evidence that the muscle has been invaded. In adeno-carcinoma the growth does not usually involve the entire cavity in the early stages. The outgrowths vary greatly in their respective lengths, and are much more slender. For comparison, see Fig. 184 (p. 363), Fig. 193 (p. 377), Fig. 201 (p. 384), Fig. 223 (p. 425), cases of adeno-carcinoma of the body. From point 1, Fig. 269 is taken.

number there is no epithelial covering whatever. These polypi consist almost entirely of small round cells, and are richly supplied with capillaries (Fig. 269), the outer coverings of which have undergone a limited degree of hyaline degeneration. Occasionally a polyp contains one or more large blood-vessels,

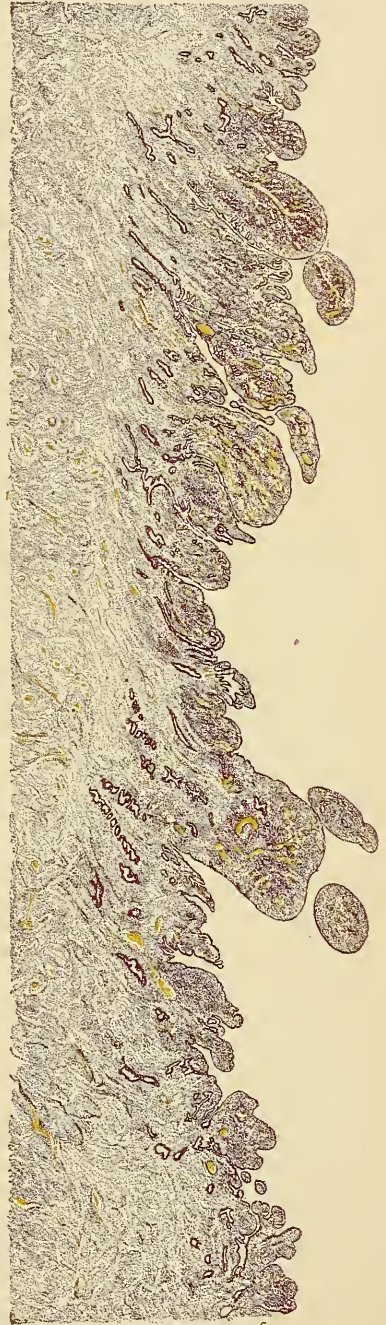
the walls of which likewise show some hyaline degeneration, a few being completely obliterated. The majority of these polypi are totally devoid of gland elements, but occasionally a cross or longitudinal section of a gland is seen in the interior or opening on the surface. Some of the polypi, which are protected by larger ones on either side, are covered by one layer of cylindrical epithelium, or by two or three layers of pale-staining, flattened epithelial cells. The protected portions of nearly all the polypi are also covered by cylindrical epithelium, and from the chinks between adjoining polypi spring secondary finger-like outgrowths. In one of these clefts the surface epithelium gradually increases in thickness until it forms an irregularly wedge-shaped mass of cells fully thirty layers thick. The cells at this point are increased in size, and their nuclei stain very deeply. Between the individual cells are a few small round cells.

The polypoid condition, in most places, involves only the superficial half of the mucosa, the glands in the deeper half presenting their usual contour and being lined by normal epithelium. In parts, however, the deeper portions of the glands run parallel with, instead of at right angles to, the surface, and occasionally the clefts between polypi extend almost to the muscle. The stroma in the deeper portions of the mucosa shows much small-round-cell infiltration.

FIG. 269.—POLYPOID ENDOMETRITIS. (6 diameters.)

Gyn.-Path. No. 1,466. The section is taken from Fig. 268 at point 1. Springing from the surface are polypi of variable size, nearly all of which point downward and have blunt or rounded extremities. The surfaces of the majority of those in this section are covered by one layer of epithelium continuous with that lining the underlying glands. The stroma of the polypi is very abundant and dense. Examination with the high power shows that this condition is due to marked small-round-cell infiltration. The majority of the polypi have a rich capillary blood supply. The uterine glands are diminished in number, are of the usual size and contour, and have a lining of only one layer of epithelium.

In adeno-carcinoma of the body of the uterus the typical fingers are long and slender, as seen in Plate VIII, or may show much branching, as is depicted in Fig. 181 (p. 357). With the high power they are found to have little stroma, and are covered frequently by many layers of cells. Thus, the histological picture of polypoid endometritis is totally different from that of adeno-carcinoma of the body.



H. Becker fsc

FIG. 269.

Gyn.-Path. No. 608

This case shows a less marked but similar condition to that found in No. 4,921. Here the epithelium over the polyp is intact, but considerably swollen.

Gyn. No. 3,476

Chronic polypoid endometritis, macroscopically somewhat suggestive of adeno-carcinoma of the body of the uterus (Fig. 270), but histologically presenting a totally different picture. Slight pelvic peritonitis; small-round-cell infiltration of the tubal mucosa on the right side. Small parovarian cyst; haematosalpinx of the left tube.

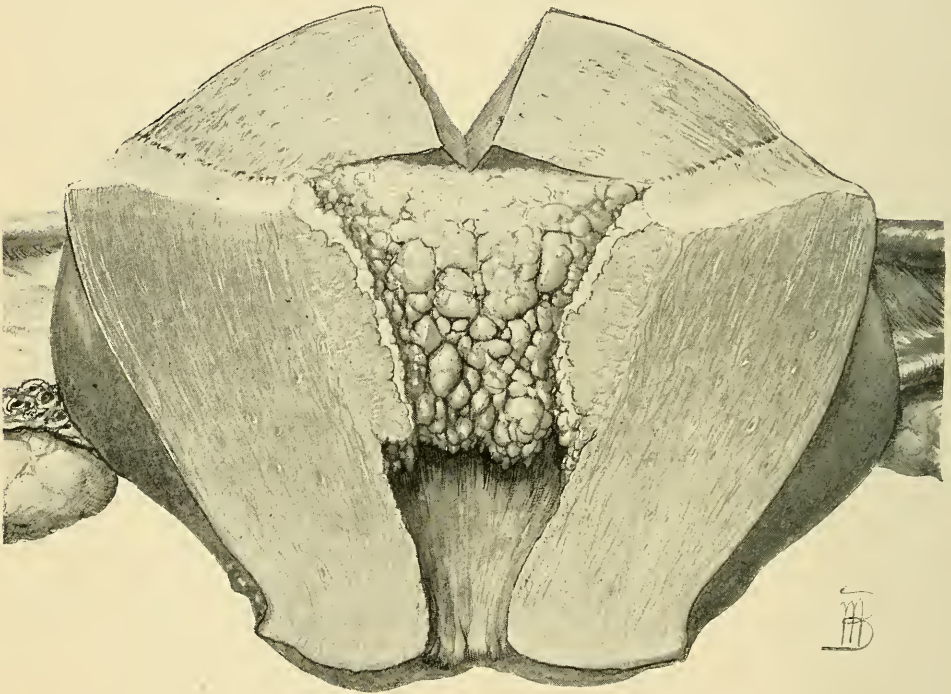


FIG. 270.—POLYPOID ENDOMETRITIS. (Natural size.)

Gyn.-Path. No. 705. The uterus is considerably enlarged. Its walls are increased in thickness, and dense. The mucosa in the lower part of the cavity is smooth and presents the usual appearance, but that of the upper part is much thickened and gathered up into polypi, fairly uniform in size. All of these have smooth, rounded surfaces, and on holding the specimen off at a considerable distance a mosaic effect is obtained. The growth is sharply defined from the normal muscle, and shows no tendency to invade it. Macroscopically, it bears much resemblance to several cases of adeno-carcinoma of the body (see Fig. 212, p. 402, Fig. 213, p. 403, and Fig. 231, p. 442), but in each of these the delicate finger-like outgrowths were in places visible. In all of these cases the typical appearance of adeno-carcinoma was noted histologically, but, as will be gathered from the text, the uterus in Fig. 270, on microscopical examination, did not even suggest carcinoma.

L., May 7, 1895.

Gyn.-Path. No. 705. The uterine cavity is 5 centimetres in length. Near the internal os the mucosa is smooth and glistening, resembling that of the cer-

vix, but over the greater portion of its extent it presents an uneven warty appearance (Fig. 270). It varies from 2 to 8 millimetres in thickness, is yellowish white in colour, and shows little projections, from 1 to 5 millimetres in diameter, some of which resemble delicate polypi and may be 7 millimetres in length. On histological examination, the mucosa near the internal os is found to be of moderate thickness; its glands are small and round on cross section, and have an intact epithelium. Between the individual epithelial cells are a moderate number of small round cells, and the stroma of the mucosa shows a marked small-round-cell infiltration, especially in the superficial layers. As one passes upward toward the point where the mucosa assumes a warty appearance, the surface epithelium becomes flattened or entirely disappears. Over the warty-like growths, the epithelium, though considerably flattened, is swollen, and many of the nuclei are twice the normal size and stain rather faintly. Between the individual epithelial cells are numerous polymorphonuclear leucocytes, while in a few places the epithelium has proliferated, reaching two or three layers in thickness. The uterine glands are, on the whole, small, and have somewhat wavy outlines. The gland epithelium is everywhere intact, but between the epithelial cells are small round cells, occurring singly or in clumps; these also occur in the gland cavities, partially filling them. The stroma of the mucosa is dense; the individual stroma cells are normal, but in the superficial portions they are almost entirely supplanted by the small round cells, of which the warty-like outgrowths are composed almost entirely. The stroma has a rich blood supply. Here and there, in the superficial portions, appear a few polymorphonuclear leucocytes, but taking the section as a whole, they are conspicuous by their absence.

The interesting points in the mucosa are: the warty-like appearance and the marked small-round-cell infiltration both of stroma and gland epithelium; the presence of so many small round cells in the cavities is also significant, and suggests a diapedesis of mononuclear leucocytes from the blood-vessels. While it might be possible to mistake some portions of the uterine mucosa for carcinomatous tissue, histological examination proves that not the slightest similarity exists.

2. Cases of Endometritis showing Suspicious Histological Changes

In many cases of endometritis there is a swelling of the surface epithelium, which, however, should cause no confusion provided there be no proliferation of cells. In Cases 3,246 (p. 520), 3,476 (p. 516), 4,958 (p. 527), 4,921 (p. 513), 4,653 (p. 522), 3,340 (p. 519), 3,526 (p. 525), 3,437 (p. 524), and 2,976 (p. 533), there was a distinct increase in the surface epithelium, the cells forming from three to six or more layers. These epithelial cells were swollen, and contained pale-staining nuclei, which were on an average twice the size of the normal ones. No evidence of nuclear division could be seen, nor was there any tendency for the epithelium to penetrate the underlying tissue. Between the individual cells were polymorphonuclear leucocytes and occasionally small round cells. In some there were small localized thickenings of the mucosa, as seen in Cases 2,976 (Fig. 278) and 4,958 (Figs. 276 and 277). These presented the same picture as the areas in which the thickening was more widely spread. In Case 3,437 the epithelium had proliferated in such a

way that five or six new glands were formed on the surface (Fig. 274). These glands were lined by low cylindrical or cuboidal epithelium, and in many places the cells were very much flattened, the nuclei being far from one another. The epithelium stained very faintly. The gland cavities contained desquamated epithelium and polymorphonuclear leucocytes.

If we compare such a picture with that found in adeno-carcinoma, the difference is marked, inasmuch as in carcinoma the glands are usually smaller, the epithelial cells are cylindrical, closely packed together, and stain deeply; furthermore, the clew is always found by examining the underlying mucosa.

Detailed Report of Cases of Endometritis exhibiting Histological Changes somewhat suggestive of Carcinoma of the Body of the Uterus

Gyn. No. 2,824

Acute endometritis; acute purulent salpingitis and peri-oöphoritis.

L., June 15, 1894.

Gyn.-Path. No. 332. The uterine mucosa averages 2 millimetres in thickness, is smooth, glistening, and grayish pink in colour.

Histological Examination.—The surface of the mucosa is covered by several layers of polymorphonuclear leucocytes. The surface epithelium is intact, but many of its cells are swollen and their nuclei are enlarged, while between the individual cells are polymorphonuclear leucocytes. The glands are abundant, but normal in number, and are slightly dilated. Their epithelium is intact; their cell protoplasm appears more granular than usual. The gland lumina are either empty or contain a small amount of delicate granular material. The stroma of the mucosa is slightly altered; the cell nuclei are larger than usual and stain less intensely. Between the cells, especially just beneath the surface, are many polymorphonuclear leucocytes. There are numerous small round cells scattered throughout the stroma. As one approaches the fundus the mucosa is gathered up into little knob-like outgrowths. In a few portions, especially in the depth of the mucosa, the tissue has not been well hardened; the glands are markedly distorted; the epithelium has dropped off and is lying free. Such a picture might prove confusing to the beginner.

Points of difference. In this case the outgrowths are knob-like instead of being papillary; they are covered by only one layer of epithelium, and contain much stroma. The cells in the masses of epithelium in the depth also differ widely from those of carcinoma; they are shrunken, the nuclei are somewhat atrophied, and there is not the slightest trace of nuclear division.

Gyn.-Path. No. 413

Sub-acute endometritis. Abscess in the right uterine cornu; acute pyosalpinx on the right side; also peri-salpingitis and peri-oöphoritis.

August 11, 1894.

The uterine mucosa is apparently 1 millimetre in thickness, pinkish in colour, smooth, and glistening. On histological examination, the surface epithelium can

be detected only in a few places; it has probably been mechanically removed. In the superficial portions of the mucosa the gland epithelium is swollen, and is with difficulty distinguished from the surrounding stroma. In the deeper portions of the mucosa the glands are normal. The stroma, especially near the surface, contains many small round cells and polymorphonuclear leucocytes. The capillaries here are filled with leucocytes.

It is interesting to note that there are papillary growths on the surface, and that the gland epithelium may be so changed as to closely resemble the altered stroma cells.

Gyn. No. 3,120

Atrophy of the uterine mucosa, with slight evidence of interstitial endometritis. Right side: multilocular ovarian cyst (one of the loculi being a dermoid). Left side: hydrosalpinx simplex; peri-salpingitis and peri-oöphoritis.

B., aged forty-five. October 22, 1894.

Gyn.-Path. No. 484. The uterine mucosa is yellowish white in colour, smooth, glistening, and approximately 1 millimetre in thickness. On histological examination, the mucosa throughout the entire cavity is found to be not more than half the normal thickness. The surface epithelium is everywhere intact, but at numerous points proliferation is noted, there being a flattened or irregular outgrowth from the surface. At these points of thickening the cells may be six or more layers in thickness; the nuclei are of different sizes, but no nuclear figures are visible. In such areas vacuoles may be found containing a few polymorphonuclear leucocytes. The central portions of others of these outgrowths contain little masses of small round cells. While these outgrowths on the surface are by no means infrequent, there is no tendency for the epithelium to project into the depth. The glands are small and round, show some branching, and near the muscle run parallel instead of at right angles to the surface. The gland epithelium is intact. In the superficial portions of the stroma, especially just beneath the epithelial outgrowths, there is considerable localized small-round-cell infiltration.

Gyn. No. 3,340

Uterine myomata (subperitoneal, interstitial and submucous). Atrophy of uterine mucosa with proliferation of its surface epithelium. Right side: normal tube. Left side: chronic salpingitis. The ovaries were not removed.

L., aged forty-six. February 27, 1895.

Gyn.-Path. No. 607. The uterus measures $11 \times 10 \times 12$ centimetres; attached to it are several myomata, one of which is 13.5 centimetres in its largest diameter. The uterine cavity is 6 centimetres in length, and is markedly distended by six submucous nodules. The uterine mucosa is pinkish in colour, and does not appear to be more than 1 millimetre in thickness.

Histological Examination.—The uterine mucosa throughout the entire cavity is atrophic; its surface epithelium is everywhere intact, and in most places normal, but toward the fundus are three finger-like outgrowths from the

surface, in the immediate vicinity of which the surface epithelium has proliferated, being three or four layers in thickness. These newly formed cells stain much more faintly than do normal epithelial cells, and are separated from one another by a moderate number of polymorphonuclear leucocytes. The uterine glands are very scant in number, but appear normal. The stroma of the mucosa is composed of spindle-shaped cells; it shows considerable small-round-cell infiltration.

Gyn. No. 3,246

Subacute endometritis (Figs. 271 and 272). Normal right tube and ovary. Old left salpingitis; adherent left ovary; gland-like spaces in tubal adhesions; thickened and indurated omentum.

Q., aged twenty-two. December 24, 1894.

Gyn.-Path. No. 552. The uterine mucosa is 2 millimetres in thickness.

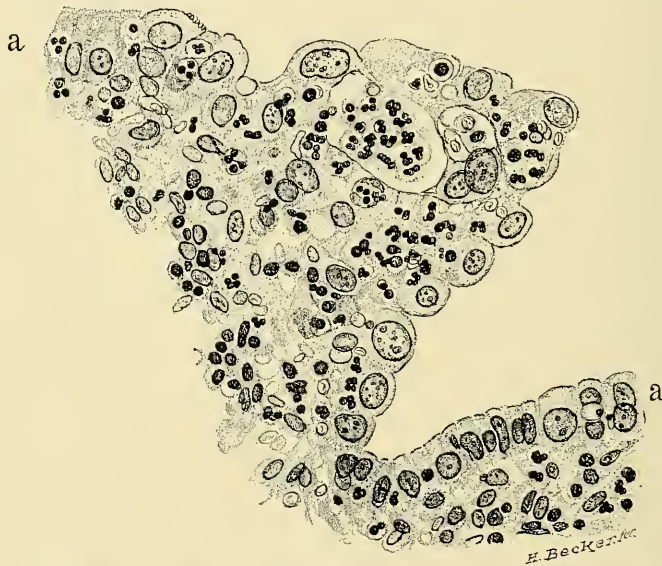


FIG. 271.—SLIGHT PROLIFERATION OF THE SURFACE EPITHELIUM WITH THE FORMATION OF A NEW GLAND, IN A CASE OF ENDOMETRITIS OF THE BODY OF THE UTERUS. (380 diameters.)

Gyn.-Path. No. 552. At *a* and *a* the surface epithelium is considerably swollen. Its nuclei vary somewhat in size, but the arrangement is regular. Between the epithelial cells are a moderate number of polymorphonuclear leucocytes and small round cells. Near the centre of the surface the epithelium has proliferated, forming a wedge-shaped outgrowth. Here some of the nuclei are considerably enlarged, and the epithelium has increased in such a manner that a small gland-like space is formed. This is filled with polymorphonuclear leucocytes, which are also abundant between the epithelial cells of the outgrowth. The underlying stroma contains many small round cells and a few polymorphonuclear leucocytes.

This outgrowth bears a faint resemblance to those pictured in Fig. 235 (p. 447), but we miss the very large and irregular, deeply staining nuclei seen at *c*. The projection hardly suggests any suspicion of carcinoma. Had the growth been malignant, at least a few delicate finger-like outgrowths and some atypical glands would have been found.

Histological Examination.—The surface of the mucosa is somewhat uneven, but the epithelial covering is everywhere intact. The individual cells differ materially from the normal; they are swollen, somewhat flattened, and

their nuclei are two or three times their normal size. Between the cells, polymorphonuclear leucocytes and small round cells are frequently visible. In several places the surface epithelium has proliferated, forming little teat-like or irregular projections (Fig. 271). The epithelial cells at such points are also swollen, but show no nuclear figures. Between the epithelial cells are a number of polymorphonuclear leucocytes, and occasionally a red blood-corpusele. At one point is a small knob-like projection from the surface (Fig. 272). There is no tendency for the epithelium to dip down

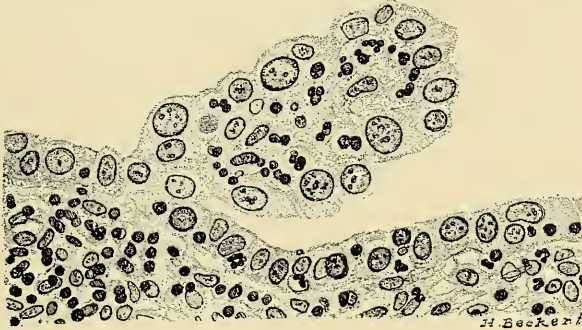


FIG. 272.—A SMALL KNOB-LIKE OUTGROWTH FROM THE MUCOSA OF THE BODY OF THE UTERUS IN A CASE OF ENDOMETRITIS. (380 diameters.)

Gyn.-Path. No. 552. Projecting from the surface and attached by a narrow stem is a blunt outgrowth, with the surface epithelium continued up over it. The nuclei of the surface epithelium and of that covering the projection are swollen, vary considerably in size, but are regular, and show little tendency to stain deeply. Between the individual cells are a few small round cells and polymorphonuclear leucocytes. The stroma of the mucosa of the outgrowth is infiltrated by many small round cells and a few polymorphonuclear leucocytes. This outgrowth bears some resemblance to that in Fig. 196 (p. 379), found along the edge of the carcinoma in Fig. 193 (p. 377); but in the present figure no new glands have been developed, neither is there any tendency to the formation of the pure epithelial outgrowths seen in Fig. 196, at points *b* and *b'*.

into the mucosa, but at one point the gland epithelium, near the mouth of the lumen, has proliferated, being two or three layers in thickness. The glands are abundant, of the usual size, and have an intact epithelial lining. That of the superficial portions of the glands, however, is swollen, the nuclei are much enlarged, while between the individual cells a few polymorphonuclear leucocytes can be seen. The glands near the muscle are perfectly normal. The stroma of the mucosa is much altered, being everywhere infiltrated by small round cells, and occasionally by polymorphonuclear leucocytes. The endothelium of the veins is swollen, and in many places has proliferated.

Gyn. No. 2,960

Interstitial endometritis; double pyosalpinx; general pelvic adhesions.

A. N., August 7, 1894.

Gyn.-Path. No. 410. The uterine mucosa is apparently 5 millimetres in thickness, bluish red in appearance, smooth, and glistening.

On histological examination, the mucosa is found here and there gathered up into irregular, dome-like, papillary or flattened projections. These and likewise

the surface of the mucosa are covered by one layer of low cylindrical or cuboidal epithelium. Where the epithelium is protected—as, for example, at the base of one of these projections—it may be cylindrical. The glands near the surface are very small, and run to some extent parallel with the surface; their epithelium tends to be cuboidal, and looks stunted. The glands in the depth present the usual appearance, except that here and there one is dilated. The lumen may be empty, or partially filled with desquamated epithelium and polymorphonuclear leucocytes. The stroma just beneath the surface consists of spindle-shaped cells, between which are many small round cells, especially abundant in the small outgrowths on the surface. The stroma near the muscle is normal.

Gyn.-Path. No. 982

Slight chronic endometritis.

H., November, 1897.

The specimen consists of a moderate amount of uterine scrapings.

Histological Examination.—The surface of the mucosa presents a wavy outline, and here and there is gathered up into delicate finger-like folds. The surface epithelium is intact, but the individual cells are separated from one another by a few small round cells and polymorphonuclear leucocytes. At one or two points there are club-like outgrowths, covered by one layer of epithelium continuous with that forming the surface of the mucosa. The stroma consists of essentially the same cells as are found in the mucosa, and shows much small-round-cell infiltration. The uterine glands are small and round in cross sections; or they may be convoluted, branching, and slightly dilated. The gland epithelium shows slight infiltration with small round cells, a few of which are also seen in some of the gland lumina. The stroma of the mucosa shows considerable small-round-cell infiltration, while just beneath the surface epithelium in a few places appear areas poor in nuclei and staining very much like hyaline.

Gyn. No. 4,653

Endometritis (Fig. 273); double peri-salpingitis and peri-*oö*phoritis.

K., aged fifty. October 21, 1896.

Gyn.-Path. No. 1,352. The uterine cavity is 5 centimetres long and 3 centimetres broad at the fundus. The cavity contains a large blood clot. Springing from the upper half of the anterior uterine wall is a submucous myoma 3×2.5 centimetres, and projecting 1.5 centimetres from the surface. The mucosa surrounding the nodule is gathered up into small polypoid outgrowths, some of which reach 7 millimetres in length; the remaining portion of the uterine cavity has a smooth mucous membrane 2 millimetres in thickness.

Sections from the body of the uterus show that the surface epithelium is in most places absent, the superficial portion consisting of fibrin, which holds in its meshes polymorphonuclear leucocytes and blood. At some points the epithelium is still preserved; it may be one layer in thickness, or have proliferated, the cells being swollen and interspersed with polymorphonuclear leucocytes. At one point

there is a finger-like projection from the surface (Fig. 273). The surface epithelium on either side of it is intact, but of a low cuboidal type, the nuclei being situated far from one another. The base of this finger-like projection is likewise covered by one layer of epithelium, which on the tip has been replaced by polymorphonuclear leucocytes. Its stroma, which is poor in nuclei, shows considerable hyaline degeneration and slight infiltration, with polymorphonuclear leuco-

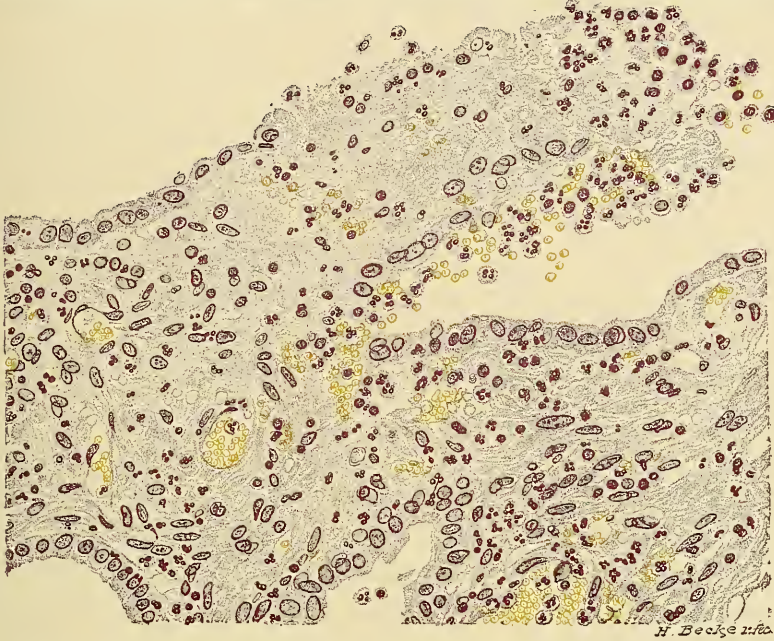


FIG. 273.—A SMALL OUTGROWTH FROM THE SURFACE OF THE MUCOSA IN ENDOMETRITIS OF THE BODY OF THE UTERUS. (270 diameters.)

Gyn.-Path. No. 1,352. Projecting from the surface is a small outgrowth. The surface epithelium on both sides of this is intact, but the cells are somewhat flattened and swollen. It can be traced upward on both sides of the projection, but is soon lost, its place being taken by polymorphonuclear leucocytes and small round cells. The stroma of the outgrowth is poor in cell elements, and contains some blood, small round cells, and polymorphonuclear leucocytes. In the lower part of the section are portions of two glands; their epithelium is also somewhat swollen, but is only one layer in thickness. Between the epithelial cells is seen an occasional small round cell or a polymorphonuclear leucocyte. The stroma of the mucosa shows some hæmorrhage and infiltration with pus cells. The outgrowth does not resemble those occurring in adeno-carcinoma, and there is a loss instead of an increase in the epithelial cells.

cytes and small round cells. The glands in the superficial portions of the mucosa are distended, their epithelium is swollen, and their cavities are partially filled with polymorphonuclear leucocytes. Near the muscle they are normal. The stroma of the mucosa in the superficial portion shows small-round-cell and polymorphonuclear leucocytic infiltration. In the deeper portions it is but little altered, except for the presence of small round cells.

Gyn. No. 3,437

Subperitoneal uterine myoma. Localized dilatation of uterine glands with foci of endometritis. Localized new gland formation on the surface of the mucosa (Fig. 274). Haemorrhage into the mucosa. Right side: peri-salpingitis; tubo-ovarian cyst. Left side: slight peri-salpingitis; a small corpus luteum cyst; remains of Wolffian body.

A., April 13, 1895.

Gyn.-Path. No. 665. The uterine mucosa is smooth and glistening, but presents a mottled appearance on account of hæmorrhage; it averages 3 millimetres in thickness.

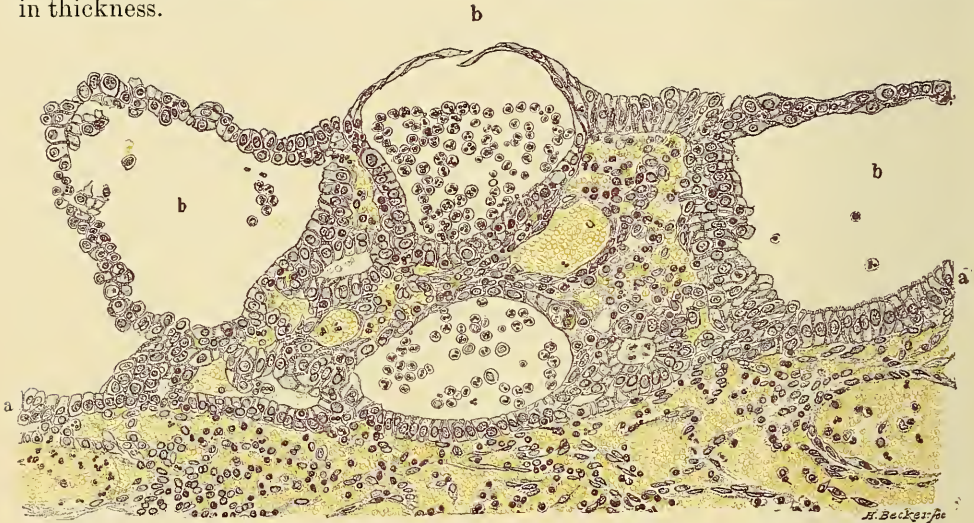

FIG. 274.—NEW GLANDS DEVELOPING FROM THE SURFACE EPITHELIUM IN ENDOMETRITIS OF THE BODY OF THE UTERUS. (205 diameters.)

Gyn.-Path. No. 665. *a* and *a* indicate the surface epithelium, which is one layer in thickness and intact. Between these points, however, it has proliferated, forming numerous small glands and some large ones (*b*). The newly formed epithelial cells show a marked uniformity in size. None of their nuclei contain any increased amount of chromatin. In many places the cells are loosely arranged. Between the epithelial cells are a few small round cells and polymorphonuclear leucocytes, some of the glands being filled with them. The epithelium of the dilated gland on the surface has lost many of its nuclei, and the cells are undergoing pressure atrophy. There is no tendency for the epithelium to invade the depth, nor is there any stroma between the newly formed glands. The stroma of the mucosa shows much hæmorrhage and an abundance of small round cells.

Compare this section with Fig. 233 (p. 445), which shows a marked contrast, new carcinomatous glands having originated from the surface epithelium. The section presents a rather suspicious picture, but the macroscopical appearances of the uterus do not suggest carcinoma. Sections from other parts of the cavity, histologically, fail to show other suspicious areas.

On histological examination, it is found to have an intact surface epithelium, which in places is two or three layers in thickness. At such points the cells are swollen, and between the epithelial cells are a few red blood-corpuscles. At one point the surface epithelium has proliferated in such a manner as to form several glands (Fig. 274). The epithelium lining

these glands is of the low cuboidal type, or somewhat flattened. The gland cavities contain desquamated epithelium, polymorphonuclear leucocytes, and occasionally blood; there is little, if any, intervening stroma. The epithelial cells show no tendency toward any active growth, and the underlying tissue is nowhere involved. The uterine glands are abundant, the majority being small and round on cross section, and having an intact epithelial lining. Some of the glands are dilated; the epithelium of a few of them is very pale, and has proliferated, being five or six layers in thickness. Between these proliferated epithelial cells are little round spaces filled with polymorphonuclear leucocytes, which are also found scattered between the individual cells. The lumina of some of the dilated glands contain necrotic material, desquamated epithelium, and polymorphonuclear leucocytes. The stroma of the mucosa in its superficial portions is markedly infiltrated with blood; in the deeper portion it is normal.

APPARENT SQUAMOUS EPITHELIUM IN THE UTERINE CAVITY IN CASES OF ENDOMETRITIS

This subject will be discussed more fully in Chapter XIX; only a brief reference will here be made to it. In all those cases in which the surface epithelium had proliferated it bore a faint resemblance to the squamous variety, but could hardly be mistaken for it. In Cases 3,526 (p. 525) and 4,921 (p. 513), however, there were areas of thickened surface epithelium, concerning which an absolute differentiation was almost out of the question (see Fig. 275, p. 526). In Case 3,526 the proliferation was near the centre of the uterine cavity, and the epithelium had attained to fully forty layers in thickness, the more superficial cells being pale, but those in the depth staining more deeply. One karyokinetic figure was seen. No prickles could be found on the cells. In Case 4,921 the thickening of the surface epithelium had taken place in a cleft between two polypi, the cells forming an irregularly wedge-shaped mass. They stained intensely, and had formed fully thirty layers.

Gyn. No. 3,526

Dilatation of the cervical glands; acute endometritis with a localized, suspicious thickening of the surface epithelium (Fig. 275); right hydrosalpinx simplex; left haematosalpinx.

G., aged thirty-eight. May 22, 1895.

Gyn.-Path. No. 729. The uterine cavity is 5 centimetres in length and 3.5 centimetres in breadth at the fundus. The mucosa averages 4 millimetres in thickness, is yellowish white in colour, and appears to be soft; it is corrugated. On careful macroscopical examination it is seen to present a finely granular appearance, the largest of the granules not being more than 1 millimetre in diameter.

On histological examination, the mucosa shows a rough, uneven surface, being gathered up into little knob-like projections. The surface epithelium is in most places intact, but at some points the individual cells are swollen, and stain faintly; some are considerably flattened. At several points, and more especially in the vicinity of the fundus, the epithelium has proliferated, varying

from two to six layers in thickness. The epithelial cells are swollen, stain palely, and have nuclei of about twice the usual size. These cells remind one somewhat of squamous epithelium.

Between the cells are polymorphonuclear leucocytes, occurring singly or in clumps. At one point near the centre of the uterine cavity the epithelium reaches fully forty layers in thickness (Fig. 275). The cells forming the superficial layers are pale, but those extending down

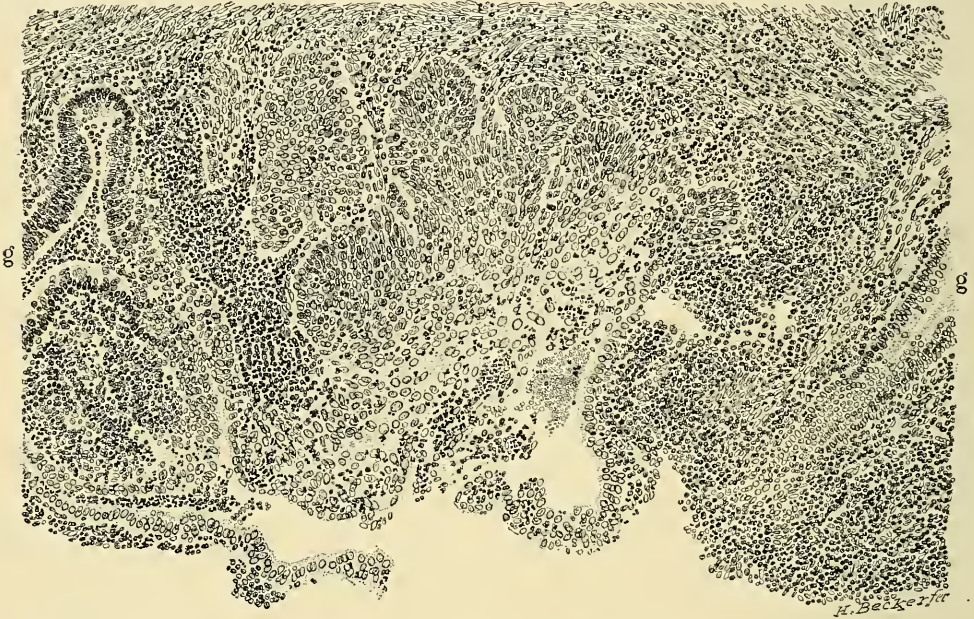

FIG. 275.—AN AREA OF THICKENED SURFACE EPITHELIUM STRONGLY SUGGESTIVE OF SQUAMOUS-CELL CARCINOMA, IN A CASE OF ENDOMETRITIS OF THE BODY OF THE UTERUS. (130 diameters.)

Gyn.-Path. No. 729. *g* and *g* are uterine glands presenting their usual contours, but lined by several layers of epithelium. The one to the left is filled with polymorphonuclear leucocytes. Its epithelium, when traced toward the right, is seen to merge into a greatly thickened area of surface epithelium, which is here composed of at least forty layers of cells, and has penetrated the tissue for a considerable distance. The advancing margin is uneven and convoluted. The epithelial cells forming the ingrowth have oval, vesicular nuclei that are uniform in size, except near the surface, where they are slightly swollen. None stain deeply. Between the epithelial cells, however, are numerous polymorphonuclear leucocytes. The stroma of the mucosa near the surface, and also that in the depth, shows much small-round-cell infiltration. This picture is certainly a very suspicious one, but the macroscopical appearances of the uterus did not even suggest a malignant process, and this is the only area in the uterus that on histological examination bore any resemblance to carcinomatous tissue. If this, then, is really the commencement of a malignant growth, the neoplasm has been taken in the earliest possible stage, and the uterus has been removed.

The inflammatory process certainly stimulates the growth of the epithelium in a certain percentage of cases.

into the stroma stain deeply, and in one nucleus a karyokinetic figure can be seen. This epithelium could hardly be distinguished from the squamous variety, but no prickles are found. Such an area is very suspicious. Between the epithelial cells are polymorphonuclear leucocytes. The stroma of the mucosa shows marked small-round-cell infiltration in the superficial portion together with numerous polymorphonuclear leucocytes. In the deeper portions the stroma is

practically normal, the uterine glands are abundant, and are round or oval on cross section. Their epithelium in the superficial portions of the mucosa is swollen, and has, in places, proliferated. Between the epithelial cells are polymorphonuclear leucocytes, which are also found in the gland cavities.

The picture is one of acute endometritis. The uterine muscle is normal.

PROLIFERATION OF THE GLAND EPITHELIUM IN ENDOMETRITIS

With the proliferation of the surface epithelium there is frequently a coexistent increase in the epithelium just at the mouth of the gland. This is nothing more than might be expected, the surface and gland epithelium merging the one into the other. The gland epithelium in the depth may proliferate, as seen in Case 4,958. Such an occurrence, however, must be rare, since this is the first time that I have encountered it. In this case (Fig. 277, p. 529) the mucosa is everywhere infiltrated by polymorphonuclear leucocytes. The gland seen on longitudinal section has a normal epithelial lining on the left side, but on the right, near the gland floor, the epithelium has proliferated, forming a localized thickening, which almost obliterates the gland lumen. The cells forming this thickening are large, polymorphous, and contain large, oval, vesicular nuclei. As will be seen, there is not the slightest tendency for the cells to invade the surrounding tissue. Nevertheless, so suspicious was I of the condition, that the patient was advised to immediately re-enter the hospital and be again curetted. This was done, and the mucosa showed no trace of malignancy. Up to this time the thickening of the surface epithelium in endometritis had not particularly attracted our attention; hence we did not know that such thickenings might occur apart from carcinoma.

While in this case there is some slight ground for suspecting carcinoma, I am of the opinion that the change was due entirely to the endometritis.

Gyn. No. 4,958

Acute endometritis with localized proliferation of the surface (Fig. 276) and gland epithelium (Fig. 277), giving rise to a suspicion of carcinoma of the body. Curettage three months later showed not the slightest evidence of any malignant process. Patient in excellent health three years after curettage.

M. Operation, January 25, 1897. The cervix was dilated, the uterus curetted, and the perinaeum repaired.

Gyn.-Path. No. 1,495. There was some suspicion of a gonorrhœal infection, but as the scrapings macroscopically appeared to be normal they were not immediately examined.

Histological Examination.—The uterine mucosa presents a wavy surface, and is here and there gathered up into delicate papillary-like projections. The surface epithelium is somewhat flattened, the cells are swollen, and occasionally consist of two or more layers. The cell nuclei are large and swollen; they are vesicular, or take an intense diffuse stain. Scattered between the epithelial cells are numerous small round cells and polymorphonuclear leucocytes.

The uterine glands are abundant, convoluted, and frequently branched. The gland epithelium resembles that on the surface. At one point a striking picture is presented (Fig. 277). A gland along one side has a typical cylindrical epithelial lining, but on the opposite side the epithelium has proliferated, forming an oval nodule, which projects into and almost completely obliterates the gland lumen. The proliferating cells are increased in size, and contain large, oval, vesicular nuclei. The stroma is fairly vascular, and shows marked polymorphonuclear infiltration.

On examination of further sections, localized thickening of the surface epithelium is detected (Fig. 276). One of these thickenings consists of an olive-shaped mass of cells, about eight layers deep. The cells are polymorphous, with oval nuclei, which stain uniformly and somewhat deeply. Between the epithelial cells are a few small round cells and polymorphonuclear leucocytes. There is not the slightest tendency to invade the depth, and the cylindrical epithelium on either side shows little alteration. A short distance from the above nodule is a second one. This is fully eighteen layers in thickness; is sharply defined; its




FIG. 276.—LOCALIZED THICKENINGS OF THE SURFACE EPITHELIUM IN ENDOMETRITIS. (130 diameters.)

Gyn.-Path. No. 1,495. The section is from a scraping. The piece of tissue is very small, and consists of little more than surface epithelium and a fragment of the underlying stroma. On the left side the surface epithelium is intact and normal, but at *a* the cells have proliferated, are swollen, resembling squamous epithelium and forming an oval mass, which consists of fully six layers of cells. Beyond this again the epithelium can be traced. It gradually reaches two or three layers in thickness, and then suddenly proliferates, forming a thickening of at least eighteen layers of cells (*a'*). Between these, which also resemble the squamous type, are polymorphonuclear leucocytes. The stroma of the mucosa shows little alteration. The underlying blood is the result of the curettage.

In adeno-carcinoma of the body we usually have delicate outgrowths of epithelium from the surface, or the formation of new glands, the nuclei frequently containing an increased amount of chromatin. But here the cells are very uniform, and there is no tendency to invade the depth. Furthermore, as will be gathered from the text, curettings from this patient on a later occasion showed no signs of malignancy, and she is well at the end of three years. For a similar thickening of the surface epithelium in endometritis, see Fig. 278 (p. 530).

elements are essentially the same, and between the individual cells are polymorphonuclear leucocytes. In the surface layer the cells are cuboidal.

From the above a diagnosis of acute endometritis, with the suspicion of commencing adeno-carcinoma, was rendered. The patient, who lived three hundred miles away, was notified that it would be advisable for her to return to the hospital.

On March 13, 1897, the uterus was again curetted, a small amount of tissue being removed. On careful examination of various pieces of tissue no distinct evidence of carcinoma could be found, and the patient was allowed to go home.

In this case it is probable that the cell proliferation was caused by the inflammatory process, but the possibility of a very early carcinoma could not with certainty be excluded.

December 23, 1899. Dr. J. H. Tucker, of Henderson, N. C., writes: The patient is in excellent health, and has gained twenty-five

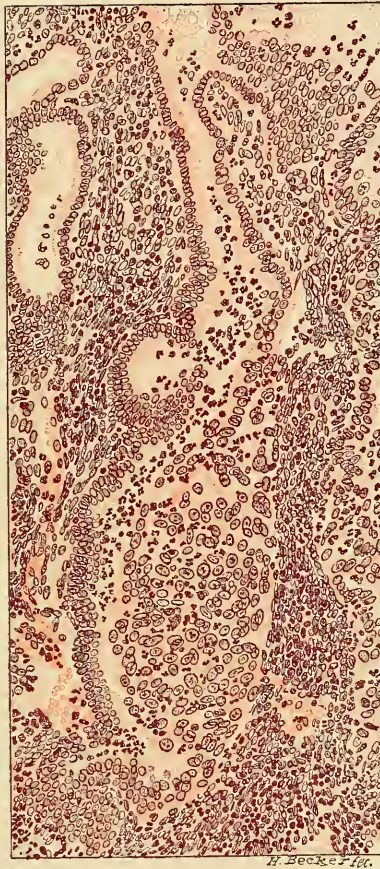


FIG. 277.—LOCALIZED PROLIFERATION OF THE GLAND EPITHELIUM IN ACUTE ENDOMETRITIS.
(175 diameters.)

Gyn.-Path. No. 1495. The section is from a scraping. Occupying the centre of the field is the longitudinal section of a uterine gland, whose lumen is filled with polymorphonuclear leucocytes. The epithelium of the left side is one layer in thickness, but on being traced downward it appears to be several layers thick, owing to the fact that the cells at the bottom of the gland have been cut obliquely. On the right side the epithelium is also only one layer in thickness in the upper portion, but in the lower half it has greatly proliferated, forming an oval mass of cells fully twelve layers thick, and almost obliterating the lumen of the gland. The nuclei of these cells are twice the size of the normal ones, are oval and vesicular, contain no excess of chromatin, and show no tendency to invade the underlying stroma. Between the individual cells are polymorphonuclear leucocytes. The surrounding uterine glands show little change. The stroma of the mucosa shows slight hæmorrhage, marked small-round-cell infiltration, and an occasional polymorphonuclear leucocyte.

The cell proliferation in this case is certainly very suggestive of carcinoma, and at that time we had not seen the similar thickenings of the surface epithelium noted in Fig. 276 and Fig. 278 (p. 530). The subsequent curettage, and the fact that the patient is now well, three years after, show very conclusively that the process was not malignant. Again, it is to be remembered that adeno-carcinoma usually commences with the formation of new glands, and not of solid masses of cells.

pounds in weight. The menopause occurred about one year ago, and to-day there is not a symptom which denotes uterine or pelvic disease of any kind." This letter was written about three years after the last curettage.

CHANGES IN THE BLOOD-VESSELS IN ENDOMETRITIS

The alterations that occasionally occur in the blood-vessels in endometritis are very instructive (Figs. 279, 280, and 281). These were pronounced in Case 2,976 (p. 533), and existed to a limited extent in Cases 4,921 (p. 513), 3,969 (p. 534), and in Gyn.-Path. No. 771 (p. 535).

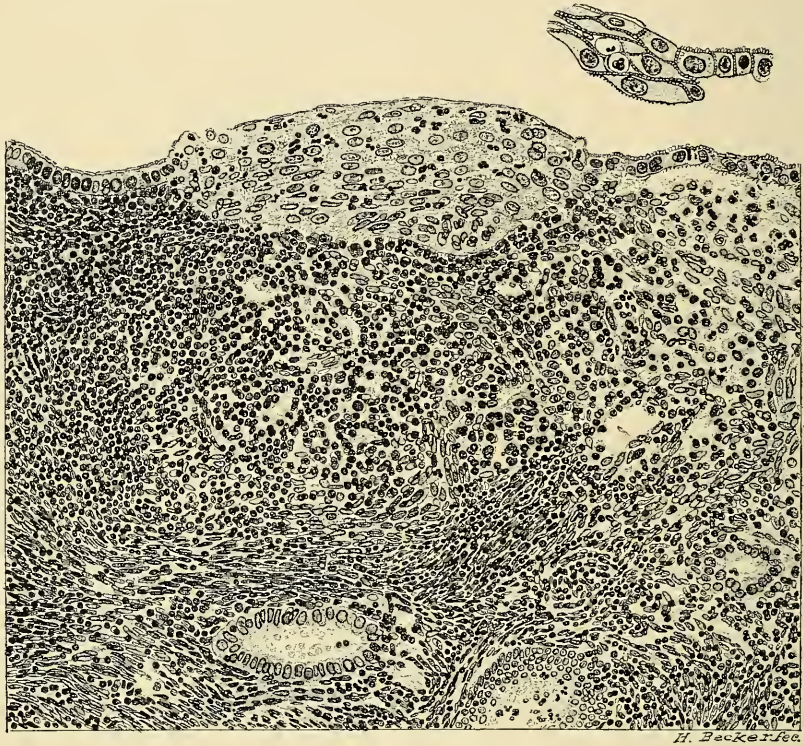

FIG. 278.—LOCALIZED THICKENING OF THE SURFACE EPITHELIUM, SUGGESTING SQUAMOUS EPITHELIUM, IN ENDOMETRITIS IN THE BODY OF THE UTERUS. (165 diameters.)

Gyn.-Path. No. 420. On either side is one layer of slightly flattened but intact surface epithelium. In the central portion, however, the cells form an oval mass fully twelve layers in thickness. These cells are large, have intercellular bridges, as seen in the small sketch above and to the right, and contain slightly swollen, vesicular nuclei. Between the epithelial cells are numerous polymorphonuclear leucocytes and some small round cells. The stroma of the mucosa in the superficial portions consists almost entirely of small round cells. In the deeper portion a normal gland is seen, and to the right of this, along the lower margin, is a gland cut obliquely, which contains a few polymorphonuclear leucocytes.

Although this localized thickening of the surface epithelium is rather suggestive of a malignant process, it must be remembered that an adeno-carcinoma does not usually commence in this way. Again, here the cells are very uniform and contain no excess of chromatin. The subsequent clinical history in analogous cases also shows the benign character of this growth. For similar thickenings of the surface epithelium, see Fig. 276 (p. 528). For a counterpart in gland epithelium, see Fig. 277 (p. 529).

The walls of the larger vessels are swollen, and consist almost entirely of tissue that has undergone hyaline degeneration. Scattered throughout this hyaline material are a few swollen cells, containing large, irregular or oval, somewhat

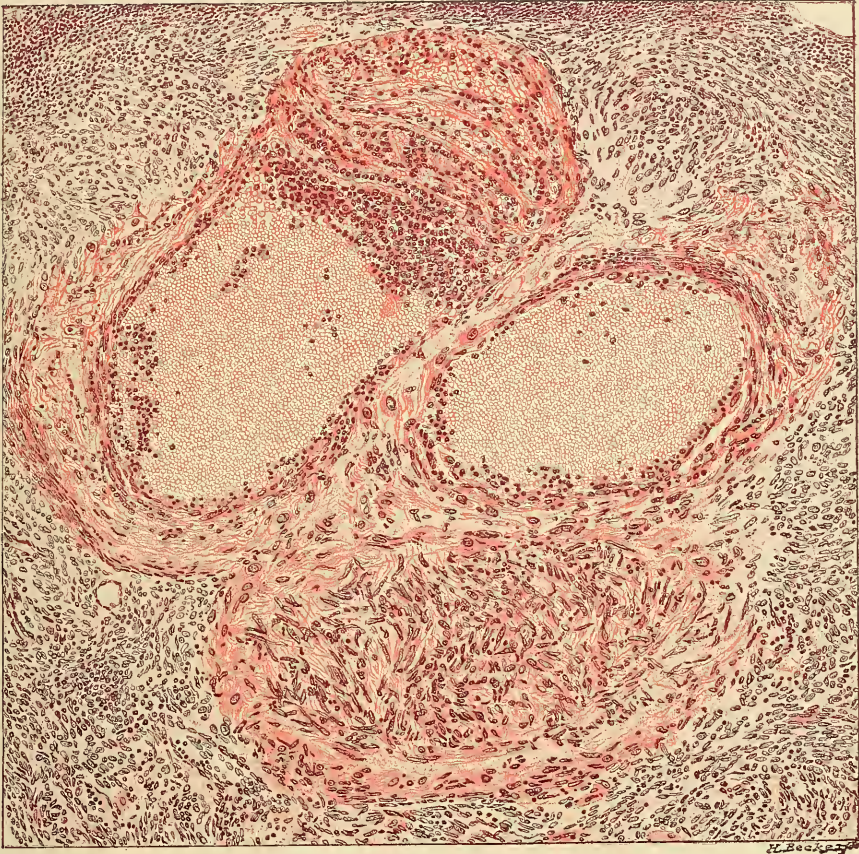


FIG. 279.—CERTAIN CHANGES IN THE BLOOD-VESSELS WHICH SOMETIMES OCCUR IN ENDOMETRITIS.
(140 diameters.)

Gyn.-Path. No. 420. Occupying almost the entire field are three blood-vessels, two above and one below. The one above and to the right is still well preserved, and has clinging to its wall many small round cells and a few polymorphonuclear leucocytes. The wall itself shows considerable hyaline degeneration, some of the stroma cells being swollen, especially in the septum between this and the neighbouring vessel. The vessel above and to the left has undergone thrombosis in the upper half, and there is already a marked accumulation of small round cells and a few well-formed connective-tissue cells. The lower part of the vessel wall shows marked hyaline change, and in it some cells with very large vesicular nuclei are noted. The vessel in the lower part of the field has undergone complete obliteration. In the central portion connective-tissue cells are particularly abundant, but in the outlying regions there is some hyaline degeneration. The enlarged nuclei, found scattered throughout the walls of the vessels, are uniform in size and vesicular. They are evidently swollen connective-tissue cells. The stroma of the mucosa in the lower part of the field is normal. In the upper part it has been almost entirely replaced by small round cells.

deeply staining nuclei. In numerous places the lumina have been obliterated, and the central portion consists of spindle-shaped connective-tissue cells, while surrounding the whole is a zone of hyaline tissue. Scattered here and there through-

out the stroma of the mucosa is a swollen stroma cell, and in the muscle a few similar cells may also be found, usually between muscle bundles, where they appear to be derived from the connective tissue. Occasionally, however, swollen muscle fibres present the same appearances. The changes just noted in the ves-

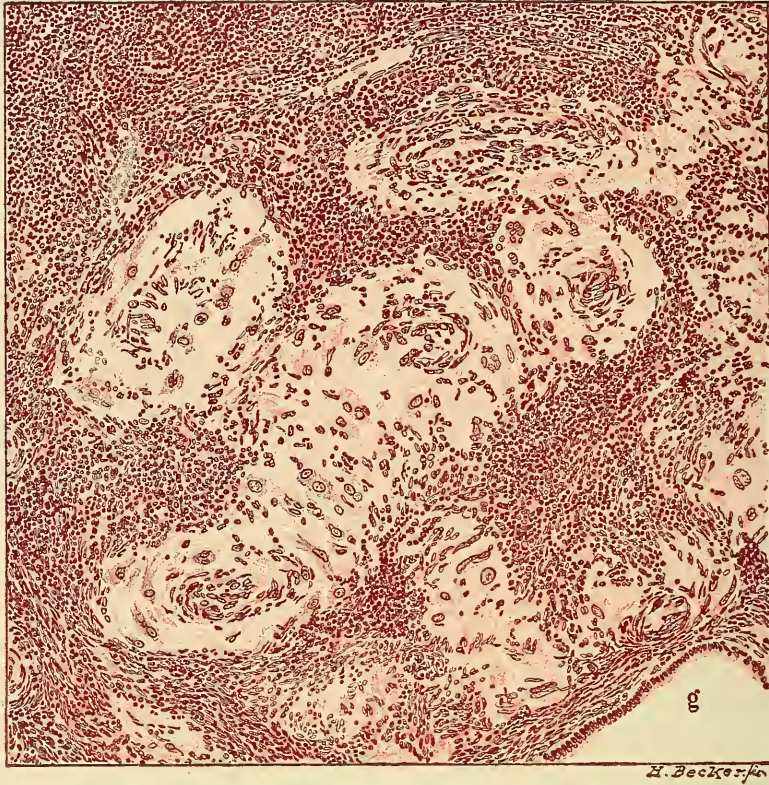


FIG. 280.—CHANGES IN THE WALLS OF THE BLOOD-VESSELS IN ENDOMETRITIS, PRODUCING A PICTURE SUGGESTIVE OF TUBERCULOSIS. (135 diameters.)

Gyn.-Path. No. 420. Nearly all trace of the normal stroma of the mucosa has disappeared, having been replaced by small round cells. Scattered throughout this tissue are pale-staining areas, which appear longitudinal and circular, according as the blood-vessel has been cut lengthwise or transversely. As is seen from the circular arrangement of the central cells, the vessels have become almost, if not completely, obliterated, and the surrounding walls show much hyaline degeneration, while scattered throughout the hyaline material are the large, oval, vesicular nuclei. These are evidently swollen connective-tissue cells belonging to the outer coats of vessels, and bear some slight resemblance to decidual cells. *g* is a portion of a neighbouring gland, which shows little alteration. Just above it is a small zone of normal stroma.

For changes in the larger vessels of the endometrium, see Fig. 279; for those in the capillary, see Fig. 281.

sels are those often seen in the mucosa after pregnancy; the swollen cells, found both in the stroma and in the muscle, resemble decidual cells, but might readily be mistaken for isolated tumour cells so often found in metastases. The presence of the blood-vessels undergoing the degeneration above noted, however, shows conclusively their source of origin.

Cases of Endometritis illustrating Suspicious Degenerations in the Walls of the Blood-vessels

Gyn. No. 2,976

Chronic endometritis with localized thickening of the surface epithelium, suggesting squamous epithelium (Fig. 278). Obliterative changes in the blood-vessels of the mucosa (Figs. 279, 280, and 281). Atrophy of the uterine glands; chronic salpingitis on both sides.

H., aged twenty-five. August 16, 1894.

Gyn.-Path. No. 420. The uterine mucosa averages 1.5 millimetres in thickness, and is pale in colour. Springing from the fundus is a heart-shaped outgrowth, 1.5 centimetres long, 1.5 centimetres broad, and 4 millimetres in thickness; the mucosa over this area shows punctiform hæmorrhages and slight glandular dilatation.

Histological Examination.—The surface of the mucosa is intact; at one point the cells have proliferated, being twelve layers in thickness, and resembling squamous epithelium (Fig. 278). Between these epithelial cells are a few polymorphonuclear leucocytes. The glands are few in number. Some of them are slightly dilated, show a somewhat flattened epithelium, and contain polymorphonuclear leucocytes. The superficial portion of the stroma is rather lax, and consists for the most part of small round cells, which are also abundant in the deeper portions of the stroma. Scattered throughout various portions of the stroma, sometimes situated near the surface, at other times in the vicinity of the muscle, are large, irregular, pale areas, which on examination of further sections are found to be the remains of blood-vessels (Fig. 280). At one point (see Fig. 279) cross sections of three blood-vessels are visible, two of which are patent. Their walls consist of a hyaline tissue, in which a few large, irregularly oval nuclei are still visible. The endothelium is peeling off, and one of the vessels contains much fibrin, which has inclosed in its meshes many mononuclear and some polymorphonuclear leucocytes. The third vessel has undergone complete obliteration, the central portion being filled up by spindle-shaped cells, among which are quite a number of degenerate polymor-

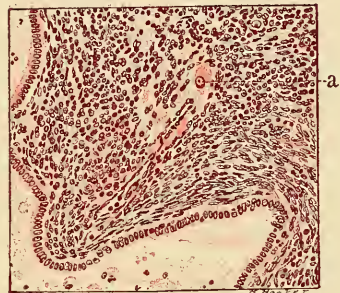


FIG. 281.—CHANGES IN THE CAPILLARY WALLS IN ENDOMETRITIS. (135 diameters.)

Gyn.-Path. No. 420. Along the left side and lower surface of the figure is the margin of a uterine gland lined by one layer of cylindrical epithelium. Its cavity contains a few polymorphonuclear leucocytes, some small round cells, and a granular material that takes the eosin stain—coagulated serum. In the stroma of the mucosa in the upper part of the field are many small round cells. Occupying almost the centre of the section, and on a line from the left lower to the right upper corner, is a long narrow slit, which represents a delicate blood capillary. Surrounding it is a varying amount of hyaline material, and lying against it at one point is a large and irregular cell (*a*) containing a relatively large, vesicular nucleus. It closely resembles a decidual cell.

The change around the capillary is analogous to that seen in Figs. 279 and 280, but is on a smaller scale.

The change around the capillary is analogous to that seen in Figs. 279 and 280, but is on a smaller scale.

phonuclear leucocytes. Surrounding this obliterated vessel is a hyaline zone containing a few large cells. Where the process is far advanced a few small vessel lumina are found surrounded by thick zones of hyaline material, in which are a few large irregular cells, containing oval, or irregularly oval, vesicular nuclei. Nearly all the blood-vessels show more or less hyaline degeneration of their walls (Fig. 281). The blood-vessels in the muscle, even at some distance from the mucosa, show considerable alteration. In the outer coats there are some very large cells having oval, vesicular nuclei. These are almost identical in appearance with those surrounding the blood-vessels in the mucosa, and some of them evidently represent swollen cells forming the outer coats of the vessels, while others apparently arise from the connective tissue between the muscle bundles. Still others are undoubtedly nothing more than swollen muscle fibres, since it is possible to trace every step in the transition from the normal muscle fibres to the large cells.

Gyn. No. 3,969

Endometritis; salpingitis; pelvic peritonitis.

G., aged twenty-five. November 25, 1895.

Gyn.-Path. No. 976. The uterine cavity is 5 centimetres in length and 4 centimetres in breadth at the fundus. The mucosa covering the posterior surface presents a granular appearance, but is smooth and glistening. That covering the upper two thirds of the anterior surface is thick, somewhat roughened or furrowed, and presents several small dark-blue areas of ecchymosis, varying from 1 to 3 millimetres in diameter, as well as some small greenish-yellow areas. There are a few dilated glands, several reaching 2 millimetres in diameter.

Histological Examination.—The uterine mucosa is in part covered by swollen epithelial cells, but in a few places the surface epithelium is absent, and the superficial portions of the mucosa present a granulating surface. The uterine glands are dilated, but have for the most part an intact epithelial lining, which in places, however, has become flattened; some of the epithelial cells are swollen. The gland cavities contain desquamated epithelium, small round cells, and polymorphonuclear leucocytes. Some of the desquamated epithelial cells have taken up yellow, granular pigment, and occasionally small hyaline droplets are found lying in the gland cavities. The stroma of the mucosa shows much small-round-cell and polymorphonuclear leucocytic infiltration, more marked in the anterior wall. Scattered irregularly throughout the stroma are large pale-staining areas, consisting of groups of blood-vessels. The coats of the vessels are thickened, and the individual cells are swollen, contain large pale-staining nuclei, which in many places have undergone marked, or even complete, hyaline degeneration. The lumina of many of the smaller vessels are entirely obliterated. In some only the outer coat appears to have degenerated, in others all are involved. On looking at some of the pale-staining areas, one is immediately impressed with their resemblance to tubercles, but it is possible to trace all stages from the normal vessel to that showing almost complete hyaline degeneration.

Gyn.-Path. No. 771

Uterine scrapings. Small-round-cell infiltration of the stroma; the glands are only slightly altered; certain of the large blood-vessels show some degree of hyaline degeneration in their outer coats, and in this hyaline material are a few large, irregular nuclei.

UTERINE MYOMATA

Myomata are undoubtedly the most frequent form of uterine tumour, and since in a large number of cases their presence gives rise to hæmorrhage, the clinical picture shows some resemblance to that of carcinoma of the body of the uterus. On vaginal examination, the tumour, if it be large and of the subperitoneal or interstitial variety, is easily recognised by its form and consistence. On the other hand, when the growth is only of moderate size and projects into the uterine cavity, some doubt as to its nature may arise. Where the diagnosis is not clear, it will always be wise to curette the uterus.

In over fifty cases of myoma I have made a careful examination of the mucosa, taking sections from all parts of the cavity. In the majority the mucosa was perfectly normal, save for a varying degree of atrophy over submucous myomata. In a few there was glandular hypertrophy, while several showed a mild degree of endometritis. This inflammatory process was in nearly every instance associated with a coincident salpingitis. In one case there was tuberculosis of the endometrium, and on examination of the tubes they also were found to be profoundly involved. These facts are mentioned to demonstrate that the uterine mucosa in cases of myomata suffers little change except through pressure. Accordingly, if a myomatous uterus be curetted, we shall, under ordinary circumstances, find perfectly normal uterine mucosa.* It must be borne in mind that polypi may also be present.

ADENO-MYOMA UTERI DIFFUSUM BENIGNUM †

Extension of the glands into the muscle is by many authors regarded as indicative of malignancy, but we have already seen that this may sometimes occur even under normal conditions. In the following cases, although uterine glands were found invading myomata to a depth of fully two or three centimetres, no evidence of the existence of a malignant process was demonstrable.

I propose here to discuss briefly a variety of adeno-myoma which is diffuse in character, is situated in the inner layers of the uterine wall, and is dependent on the uterine mucosa for its glandular elements.

* Since the foregoing was written we have completed the examination of over five hundred myomata. In four cases adeno-carcinoma of the body was demonstrated, the malignant condition having been obscured by the presence of the large myomata (Fig. 231, p. 442; Fig. 236, p. 451; Fig. 237, p. 454; and Fig. 244, p. 466).

† Cullen, Thomas S. *Adeno-myoma uteri diffusum benignum*. *Johns Hopkins Hospital Reports*, 1897, vol. vi, p. 133.

Such tumours have been mentioned by Rokitansky,* Schatz,† and Schröder,‡ while Diesterweg[#] reports a case which was probably of this character. Von Recklinghausen,|| in the appendix accompanying his recent work, *Die Adenomyome und Cystadenome der Uterus- und Tubenwandung*, has carefully described a case belonging to this group.

In March, 1895, I reported a similar instance before the Johns Hopkins Medical Society, and one month later received another such specimen from the operating room. A detailed account of these two cases is as follows:

Gyn. No. 3,136

Adeno-myoma uteri diffusum benignum (Fig. 282 and Plate IX). Glandular uterine polyp in the cervix. Small interstitial and subperitoneal myomata.

L. W., aged forty-six; single. October 24, 1894.

Complaint: pain in the lower part of the abdomen; dysmenorrhœa and menorrhagia. Menstruation commenced when the patient was eleven years of age, was always regular, but for the past ten years has been associated with severe pains in the right ovarian region. These pains radiate down both limbs, are accompanied by backache, and for the last two years have been so severe that she has been confined to bed for three or four days at each period. At present the flow lasts from ten days to two weeks, and there is a considerable amount of clotted blood. Her last period ceased one week before admission. Her parents are both living and healthy. One brother died of tuberculosis. With the exception of an attack of diphtheria in earlier life, and influenza three years ago, she has always been well.

The patient is a rather anæmic woman, and does not appear to be very strong. Her tongue is pale and flabby; the appetite is fair; the bowels are regular. She is unable to walk much, and cannot lift heavy weights. The outlet is very much relaxed, and presenting at the orifice is a hard, irregular mass, which proves to be the cervix. The external os is patulous, admitting the index finger, and projecting from it is what appears to be a myomatous nodule about the size of a hazelnut. The cone-shaped cervix is continuous with the enlarged uterus, which is apparently freely movable.

Clinical Diagnosis.—Myoma.

Operation, October 31, 1894. On opening the abdomen it was found impossible to raise the uterus out of the pelvis, and the operator was compelled to work in the narrow space between the uterus and the pelvic walls. The ovarian and

* Rokitansky, C. *Ueber Uterusdrüsen-Neubildung im Uterus u. s. w.* Zeitschr. der k. k. Gesellsch. der Aerzte zu Wien, 1860, S. 577.

† Schatz, F. *Ein Fall von Fibroadenoma cysticum diffusum et polyposum corporis et colli uteri.* Archiv f. Gynäk., 1884, Bd. xxii, S. 456.

‡ Schröder. *Handbuch der Krankheiten der weiblichen Geschlechtsorgane.* 7te Auflage, Leipzig, 1886, S. 228.

Diesterweg, A. *Ein Fall von Cystofibroma uteri verum.* Zeitschr. f. Geburtsh. u. Gynäk., 1883, Bd. ix, S. 191.

|| Von Recklinghausen. *Die Adenomyome und Cystadenome der Uterus- und Tubenwandung,* Berlin, 1896.

uterine vessels on both sides were controlled and the uterus was amputated. The lips of the stump were then brought together, and, lastly, the peritoneum from the posterior wall was sutured to that of the anterior, thereby completely covering over the stump. The patient made an uninterrupted recovery, and was discharged December 1st.

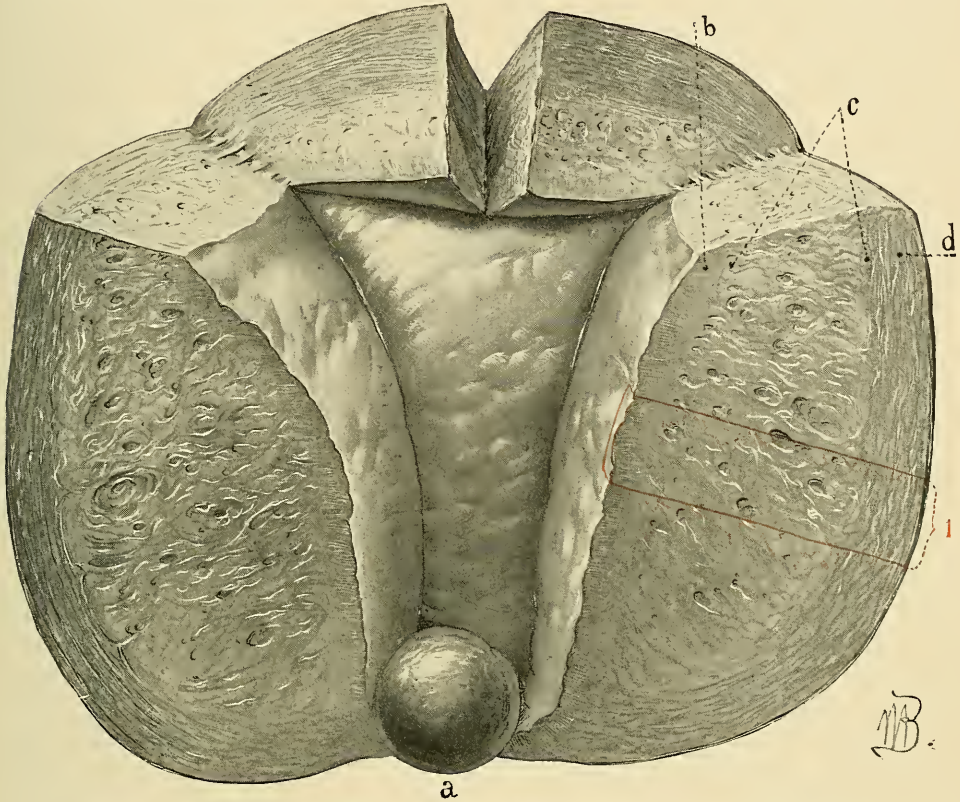


FIG. 282.—DIFFUSE ADENO-MYOMA OF THE ANTERIOR UTERINE WALL. ($\frac{6}{7}$ natural size.)

Gyn.-Path. No. 497. The uterus has been cut open and is seen from the front. The drawing is from the specimen hardened in Müller's fluid. A small portion of the cervix is present. Projecting through the cervical opening is a globular nodule, whose pedicle springs from the uterine cavity just within the internal os. On histological examination this was found to be a myoma everywhere penetrated by glands. The anterior uterine wall is much thicker than usual. It is divisible into two portions: an inner, coarsely striated, and an outer but narrower zone, which is the normal uterine muscle. This outer zone presents a parallel arrangement of its muscle bundles. On examining the fundus carefully, the coarse striation is seen to be confined to the anterior wall. The uterine mucosa, apart from a slight undulation of the surface, is smooth. The small folds described as occurring near the internal os are obscured by the polyp. One of the most striking features is that there is practically no encroachment of the growth on the uterine cavity, the anterior wall showing little, if any, convexity. This is in marked contrast to what takes place in cases of submucous myomata. For the histological picture see Plate IX.

Gyn.-Path. No. 497. The specimen consists of the enlarged uterus, with the tubes and ovaries intact. The uterus is 13 centimetres long, 12 centimetres broad, and 10 centimetres in its antero-posterior diameter. It is approximately globular, and in its contour resembles a normal but enlarged uterus. Anteriorly it is smooth and glistening; posteriorly over its lower two thirds it is denuded

of peritoneum. Situated in the posterior wall, in the vicinity of the left uterine cornu, are four sessile nodules, which are approximately circular. The largest of these is 2 centimetres in diameter. On section they are whitish in colour, and are composed of fibres concentrically arranged. They present the usual myomatous picture. The under cut surface of the uterus measures 12×11 centimetres. In the centre is the cervical orifice, which is 1 centimetre in diameter. Projecting from the right side of this opening is a nodule, 2.5 centimetres in diameter, and apparently covered by mucous membrane, which is somewhat hæmorrhagic.

The anterior uterine wall is 7 centimetres in thickness (Fig. 282), and consists of two distinct portions: the outer, 1 centimetre thick, resembles normal uterine muscle; the remainder of the wall presents a coarsely striated appearance, the striæ running in all directions. Scattered throughout this thickened and striated portion of the uterine wall are round, oval, or elongate, brownish-yellow homogeneous areas, some of which merge directly into the uterine mucosa, while in one or two places are found small cysts, varying from 1 to 4 millimetres in diameter. The striated appearance can be traced directly up to the uterine mucosa, and in some places into it. After the specimen had been hardened in Müller's fluid the contrast between the normal uterine muscle and the thickened striated portion was very sharp, the former being much darker in colour. The posterior wall of the uterus varies from 2.5 to 3.5 centimetres in thickness. It is rather dense, but does not present any coarse striation. Situated in the posterior wall are two interstitial nodules, 1 and 1.5 centimetres, respectively, in diameter; they are pearly white in colour, and are composed of concentrically arranged fibres.

The uterine cavity is 7.5 centimetres in length, and at the upper part 8 centimetres in breadth. The mucous membrane of the anterior uterine wall varies from 7 to 8 millimetres in thickness, is yellowish white in colour, smooth, and glistening. In many places, however, it presents ecchymoses in the superficial portions. In the vicinity of the internal os, and extending upward for about 2.5 centimetres, are three or four longitudinal folds of the mucosa. The depressions between these are about 4 or 5 millimetres in depth. The mucosa covering the posterior wall varies from 3 to 4 millimetres in thickness.

Right side: The tube is 11 centimetres long, and averages 7 millimetres in diameter. Its fimbriated extremity is patent; the parovarium is intact. The ovary measures $8 \times 2.5 \times 1.5$ centimetres; it is pale in colour, smooth, and glistening. It contains two corpora lutea, the larger of which is 2.5 centimetres in diameter.

Left side: The tube is 9 centimetres long and 6 millimetres in diameter. Its extremity is patent; the parovarium is intact. The ovary measures $4 \times 4 \times 1$ centimetres; it is yellowish white in colour, somewhat lobulated, and contains a cyst 2.5 centimetres in diameter. The walls of this cyst are 2 millimetres in thickness, and the inner surface has a dirty brown colour.

Histological Examination.—The nodule projecting into the uterine canal (Fig. 282) is composed of non-striped muscle fibres. Its outer surface is in places covered by cylindrical epithelium, but for the most part by several layers

Fig. 1 is a cross section from the thickened anterior uterine wall in Fig. 282 at point A. It has been enlarged four times. To the left is the uterine mucosa, the surface of which presents a wavy outline. The surface epithelium is intact, and the glands are for the most part normal in size. A few of them are dilated, one reaching a considerable size. On passing toward the right, large numbers of longitudinal glands are seen penetrating downward into the growth between the muscle bundles. These are surrounded by a tissue darker than the muscle—the typical stroma of the mucosa. The greater part of the specimen is composed of bundles of muscle fibres. Some of the bundles present a circular arrangement, others are oblong, and some wind in and out in all directions. These large bundles are again subdivided into smaller ones.

Scattered everywhere throughout the thickened zone are dark areas; some of these are triangular, others are semicircular, while others again are irregular in shape. On examining these areas closely, the majority are found to contain longitudinal or cross sections of glands. Some of these glands are dilated and irregular in contour. A longitudinal section of a gland with a dilatation on one side is seen near the junction of the myomatous zone with the uterine muscle.

The large clear spaces scattered throughout the myomatous zone are dilated glands. Here and there a dark patch is seen in which no glands are present. Islands of stroma devoid of glands also occur. The glandular elements diminish in number in the outer portions of the growth, and at the point where the uterine muscle commences are absent.

The outer zone, consisting of uterine muscle, presents the appearance of normal muscle.

Fig. 2 (300 diameters) is a cross section of a gland taken from Fig. 1 at a. The gland is lined by one layer of cylindrical epithelium, and is surrounded by cells having oval, vesicular nuclei. Its appearance is identical with that of a normal uterine gland. Surrounding the stroma of the gland are non-striated muscle fibres, the majority of which are cut longitudinally.

PLATE IX.—ADENO-MYOMA UTERI DIFFUSUM BENIGNUM.

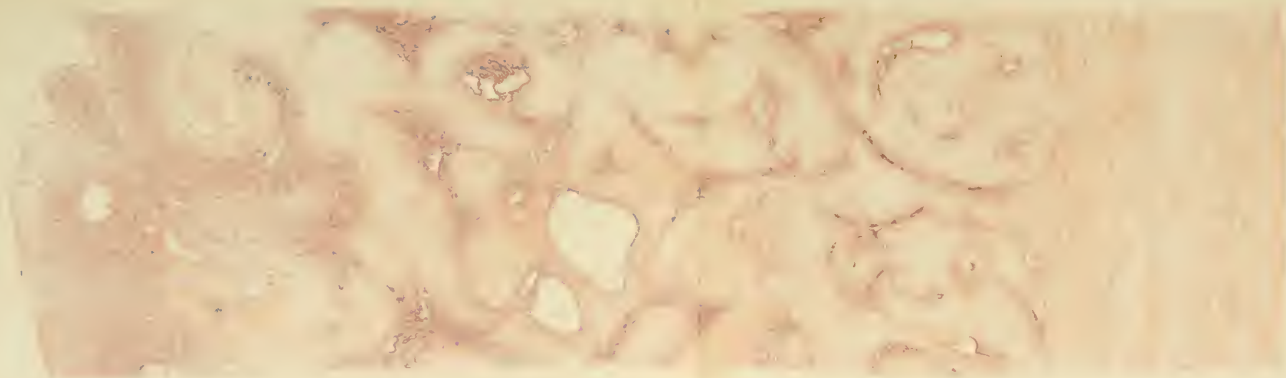
Fig. 1 is a cross section from the thickened anterior uterine wall in Fig. 282 at point 7. It has been enlarged four times. To the left is the uterine mucosa, the surface of which presents a wavy outline. The surface epithelium is intact, and the glands are for the most part normal in size. A few of them are dilated, one reaching a considerable size. On passing toward the right, large numbers of longitudinal glands are seen penetrating downward into the growth between the muscle bundles. These are surrounded by a tissue, darker than the muscle—the typical stroma of the mucosa. The greater part of the specimen is composed of bundles of muscle fibres. Some of the bundles present a circular arrangement, others are oblong, and some wind in and out in all directions. These large bundles are again subdivided into smaller ones.

Scattered everywhere throughout the thickened zone are dark areas; some of these are triangular, others are semicircular, while others, again, are irregular in shape. On examining these areas closely, the majority are found to contain longitudinal or cross sections of glands. Some of these glands are dilated and irregular in contour. A longitudinal section of a gland with a dilatation on one side is seen near the junction of the myomatous zone with the uterine muscle.

The large clear spaces scattered throughout the myomatous zone are dilated glands. Here and there a dark patch is seen in which no glands are present. Islands of stroma devoid of glands also occur. The glandular elements diminish in number in the outer portions of the growth, and at the point where the uterine muscle commences are absent.

The outer zone, consisting of uterine muscle, presents the appearance of normal muscle.

Fig. 2 (200 diameters) is a cross section of a gland taken from Fig. 1 at *a*. The gland is lined by one layer of cylindrical epithelium, and is surrounded by cells having oval, vesicular nuclei. Its appearance is identical with that of a normal uterine gland. Surrounding the stroma of the gland are non-stripped muscle fibres, the majority of which are cut longitudinally.

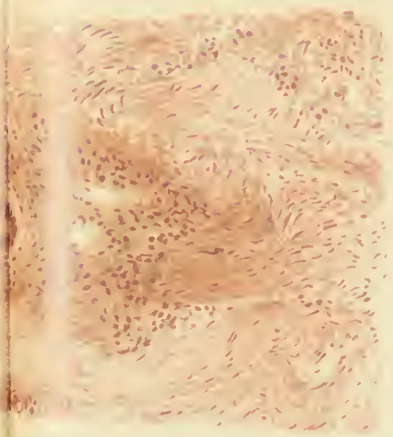
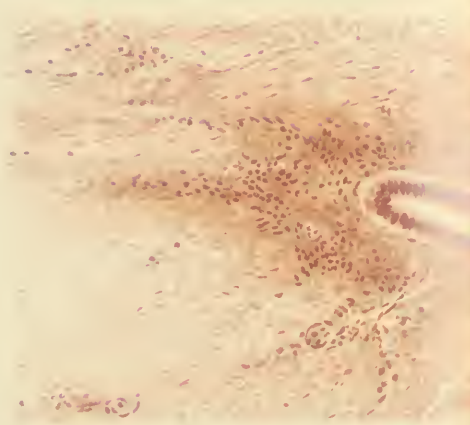


Micrograph 1

Micrograph 2

Micrograph 3

Micrograph 4



of spindle-shaped connective-tissue-like cells. Scattered everywhere throughout the muscle are gland-like spaces varying from a pin-point to 3 millimetres in diameter. These are lined by one layer of epithelium, which in the smaller glands is of the high cylindrical variety. In the dilated glands, however, it is cuboidal, or has become almost flat. The protoplasm of the cells takes the hæmatoxylin stain. The nuclei are oval and vesicular, and in many places it is possible to make out cilia. The glands are empty, or contain a granular material that takes the hæmatoxylin stain. They resemble to some extent those of the cervix. The surface of the mucosa covering the anterior uterine wall presents in places a wavy outline (Plate IX, Fig. 1). Its epithelium is of the high cylindrical variety and is everywhere intact. In a few places it is swollen and somewhat flattened. The glands appear in moderate numbers, are small and round on cross section, and have an intact epithelium. A few of them are slightly dilated and contain desquamated epithelium. They may be followed for 7 to 10 millimetres before any muscular substance is encountered; they then end abruptly, or penetrate into the muscle, where they can in places be traced for at least 1 centimetre; this downgrowth is visible in many places. The stroma of the mucosa is composed of cells whose nuclei vary from an oval, vesicular type, seen near the surface, to the deeply staining examples which appear in the depth of the mucosa. In some places the stroma cells have elongate-oval nuclei, so that they cannot be distinguished from muscle fibres. The superficial portions of the stroma show marked hæmorrhages, which are confined to certain areas. The stroma, as a whole, does not appear to be very vascular.

The thickened and striated portion of the anterior uterine wall is composed of non-striated muscle fibres, which are for the most part cut longitudinally. The fibres run in all directions, are closely packed together, but only in a few places show a concentric arrangement. Scattered throughout this tissue are numerous cells having small, round, deeply staining nuclei which resemble those of lymphoid cells. Under the microscope it is impossible to tell where the coarsely thickened zone ends and the normal uterine muscle commences, the transition from the one into the other being so gradual. Traversing this thickened portion of the uterine wall are small clusters of glands, similar to those of the uterine mucosa (Plate IX, Figs. 1 and 2). These glands are round or oval, and are lined by one layer of cylindrical ciliated epithelium. A few longitudinal sections of the glands are here and there visible. Some of the glands are dilated, one of them reaching 5 millimetres in diameter. The epithelium of the dilated glands is in places somewhat flattened or has entirely disappeared.

In one place two glands are seen opening into a dilated lumen. Nearly all of the glands are surrounded by stroma similar to that of the uterine mucosa. A small isolated gland is occasionally found lying directly between the muscle fibres, and a few of the cysts have no stroma surrounding them. The gland invasion can be traced to the point at which the coarsely striated tissue joins the uterine muscle. The glands are most abundant near the uterine mucosa, and gradually diminish as one passes outward. They may be scattered anywhere throughout the myomatous growth, but appear for the most part to occupy the spaces between the muscle bundles. In only a few places can any concentric arrangement of muscle fibres

be made out around them. The glands themselves show no evidence of degeneration.

From the above it will be seen that there is a diffuse thickening of the muscular tissue in the anterior uterine wall, and that there is a down-growth of normal uterine glands into the newly formed muscle. Along the lower margin of the growth is a typical myomatous nodule, 5 millimetres in diameter.

The mucosa covering the posterior uterine wall is normal.

The right tube and ovary are normal.

The left tube is normal. The small cyst of the left ovary has no epithelial lining; hence its exact origin cannot be ascertained.

Gyn. No. 3,418

Adeno-myoma uteri diffusum benignum. Small interstitial myoma. Normal appendages.

K. B. N., aged forty; married. Admitted April 3, 1895. Complaint: painful and profuse menstruation.

The patient began to menstruate when fourteen years of age. The periods occurred at intervals of from three to four weeks, were profuse, but not accompanied by much pain. She has been married seventeen years; has had one difficult but non-instrumental labour sixteen years ago, after which she was confined to bed for six weeks on account of chills and fever, which were associated with abdominal pains. Eleven years ago she had a miscarriage. Immediately after the birth of the child the menses became very profuse for a time, and then diminished in amount. Five years ago the flow again became copious, and dark clotted blood came away. Pain in the lower abdomen and in the back commenced a few hours before the flow and lasted until the menses were over. The patient has never been strong; at twelve years of age she had malaria and at fifteen pneumonia. Her family history on both sides is decidedly tuberculous, both grandfathers, her mother, one aunt, and two cousins having died of phthisis.

The patient is a well-nourished but rather anæmic woman, weighing one hundred and forty pounds. Her tongue is coated; the appetite is good. She has an occasional headache; experiences no difficulty in locomotion; her feet and ankles occasionally swell; the urine is normal; the last menstrual period ceased two weeks ago, having lasted ten days. On vaginal examination myoma uteri was diagnosed.

Operation, April 6, 1895. An incision, 15 centimetres long, was made in the median line, and the tumour was lifted out of the pelvis. The ovarian vessels, round ligaments, and uterine vessels were tied, and the uterus was amputated low down. The cervical lips were then brought together, and the peritoneum from the posterior pelvic wall was united with that from the anterior. The patient was discharged on May 3d, feeling perfectly well.

Gyn.-Path. No. 661. The specimen consists of the enlarged uterus with its appendages intact. The uterus is pear-shaped, and measures 12 centimetres in length, 10 centimetres in breadth, and 8 centimetres in thickness. It is pinkish in colour, smooth, and glistening. Two centimetres of the cervical canal are present; its mucosa is pearly white in colour, smooth, and glistening, and has

almost entirely lost its rugous appearance. The uterine cavity measures 4.5 centimetres in length, and is 5.5 centimetres in breadth in its upper portion. The posterior wall bulges slightly into the cavity. The mucous membrane is smooth, but presents a mottled appearance, being the seat of extensive hæmorrhage. It is 8 millimetres in thickness. The anterior uterine wall averages 2.5 centimetres in thickness. The posterior wall is 5 centimetres thick, and may be divided into two portions: an inner, which is thickened, coarsely striated, and looks very much like myomatous tissue; and an outer, resembling normal uterine muscle. The contrast is much sharper after the specimen has been hardened in Müller's fluid, the coarsely striated portion staining lightly, the normal muscle deeply. On careful examination of the hardened specimen, grayish-brown granular areas are seen scattered throughout the thickened portion of the wall. These are round or irregular in contour, and as one approaches the uterine cavity are seen to merge directly into the mucosa. Even on macroscopical examination the superficial areas, at least, are seen to be portions of the mucosa that are dipping down into the tumour.

Scattered here and there throughout the tumour are cavities, the largest of which is about 5 millimetres in diameter. They have a smooth, glistening inner surface. Some of them are filled with blood. Along one margin of the tumour is a myomatous nodule, 1 centimetre in diameter. The outer portion of the uterine wall, which corresponds to the uterine muscle, averages 1 centimetre in thickness.

Right side: The tube is 9 centimetres long and 6 millimetres in diameter. It is free from adhesions, and has a patent fimbriated extremity. The parovarium is intact. The ovary measures $3.5 \times 2.5 \times 0.8$ centimetres. It is free from adhesions, and on its under surface contains two slightly dilated Graafian follicles.

Left side: The tube is 7 centimetres long and 0.8 centimetres in diameter. It is free from adhesions, and has a patent fimbriated extremity. The parovarium is intact.

The ovary measures $3.5 \times 2.5 \times 0.5$ centimetres, and is slightly cirrhotic. On its under surface is a corpus luteum, 2.5×1 centimetre.

Histological Examination.—The cervical glands are in most places normal, but here and there have proliferated. The epithelium covering the surface of the cervical mucosa is of the high cylindrical variety; near the junction of the internal os, however, it suddenly changes, and the mucosa is covered by several layers of squamous epithelium. Above this point the typical cervical epithelium is again found. The mucosa covering the posterior wall of the uterus has an intact surface epithelium. Here and there little knob-like masses of the mucosa project into the uterine cavity. In the superficial portions the uterine glands appear in moderate numbers, being small and round on cross section. In the deeper portions they show considerable branching, and in some places it looks as if one gland sent off three or four branches; this appearance is probably due to marked convolution of the glands. In several places the glands are seen extending down into the underlying tumour. This is most noticeable near the upper part of the uterine cavity, where longitudinal sections of two or three glands can be seen passing between muscle bundles into

the depth of the tumour. This is clearly demonstrable with the naked eye. The stroma of the mucosa is rarefied.

The individual stroma cells have oval, vesicular nuclei, and are slightly swollen. Scattered here and there throughout the stroma are small, round cells, occurring either singly or in clumps. The superficial portions of the mucosa show considerable hæmorrhage. The coarsely striated thickening in the posterior uterine wall is composed of non-striated muscle fibres, which are cut both longitudinally and transversely. This tissue is denser than normal uterine muscle, but otherwise closely resembles it. Between the bundles of muscle fibres, and also between the individual fibres, there is considerable small-round-cell infiltration. Scattered freely throughout the tumour are glands. The majority of these are found in groups; some, however, occur singly. In many places they are seen in cross sections, where they appear as rows of oval or round glands. Some have been cut longitudinally, and are cylindrical, others are curved. A few appear to have secondary glands opening into them. The glands, as a rule, are lined by one layer of cylindrical epithelium on which it is possible in many places to make out cilia. A few of them are dilated. The epithelium of some of these is intact, in others it has become flattened or has disappeared. Some of the dilated glands are empty, others contain desquamated epithelium and granular material. Some of the desquamated cells are swollen, and their protoplasm contains yellowish-brown granular pigment.

The largest gland is filled with blood. In many of the glands the epithelium has become desquamated, and the gland is only recognised as a space partially or completely filled with desquamated cells. The groups of glands, and also most of those occurring singly, are surrounded by stroma which separates them from the muscle. This stroma is similar to that of the normal uterine mucosa. Here and there cross sections of three or four glands are seen, in which the epithelial cells lie directly in contact with the muscle. In many places stroma cells contain brown granular pigment. At one or two points a very curious picture is visible: at one end of a space between muscle bundles it is possible to make out a gland undergoing degeneration, and on tracing this a little farther one sees three oval spaces forming a chain; these are almost completely filled with small round cells and others having oval, vesicular nuclei, which look a little like those of epithelioid cells. Each of these masses of cells contains one or more giant cells, which are round, oval, or elongate-oval; their nuclei are vesicular, and are situated in the centre of the cell or around the periphery. These aggregations remind one somewhat of tubercles, but they are probably degenerate glands, since no tubercle bacilli can be detected in these areas, and, furthermore, there is no caseation. There is no definite arrangement of the muscle around the bunches of glands. It looks as if the glands just filled in the spaces between muscle bundles. At one side of this new growth is a typical myomatous nodule, 1 centimetre in diameter; this is entirely devoid of gland elements. The outer zone of the posterior wall, as well as the mucosa covering the anterior uterine wall, are normal. The tubes and ovaries show no pathological changes.

GROSS APPEARANCE OF THE DIFFUSE ADENO-MYOMATA

The uterus may be pear-shaped, and except for some enlargement may look normal; projecting from the surface will probably be a few subperitoneal myomatous nodules. Section of the uterus shows that one wall is much thickened. This thickening occurs in the inner zone, that is, between the mucosa and uterine muscle. The thickened zone resembles a myomatous growth, but the coarse glistening bands, instead of forming a definite nodule, intertwine one with the other, producing a coarse and dense network. The cut surface of this growth gives, as von Recklinghausen points out, the watered-silk appearance. The diffuse growth, as a whole, is much paler than the outer covering of the uterine muscle, but at the point of junction one merges gradually into the other, and there is little difference in colour. The sharp outline presented by the ordinary myoma is lacking. After the tissues have been hardened in Müller's fluid, the contrast between the normal muscle and the new growth is much sharper.

The uterine mucosa covering the inner surface of this diffuse growth does not show the marked convexity characteristic of submucous myomata. The surface is perfectly smooth, or presents a slightly wavy outline. The mucosa in our cases is a little thicker than usual, but the individual elements are normal. At numerous points the mucosa can be seen penetrating into the depth between the muscle bundles. In places it is possible to trace this down-growth of the mucosa for 1 centimetre or more into the muscle.

Scattered freely throughout the growth are small, triangular, crescentic, or irregular islands of tissue, which in colour and consistence resemble the mucosa. These are slightly granular, and in many places contain small cysts. A few of these cysts reach 5 millimetres or more in diameter. The inner surfaces of these cysts have a smooth lining, resembling mucous membrane. The cavities of some are filled with blood. Even macroscopically one sees that the superficial islands, at least, are down-growths of the uterine mucosa.

Small myomata will be found scattered throughout the uterine wall, especially in the vicinity of the diffuse growth.

MICROSCOPICAL APPEARANCES

It will be well to study a section taking in the entire uterine wall, from the uterine mucosa to the peritoneal surface (Plate IX, Fig. 1).

The surface epithelium of the mucosa is intact. The glands present the usual appearance, being cylindrical. In the deeper portions they may be somewhat convoluted. The diffuse thickened area is composed of non-striped muscle bundles which run in all directions. They occur as long bands of fibres, which follow a straight or serpiginous course, and do not show much tendency to arrange themselves concentrically, as in ordinary myomata. This new growth throughout may show small-round-cell infiltration. At numerous points the longitudinal glands are seen penetrating the growth for a distance of 1 centimetre or more. These glands present exactly the same appearance as those on the surface of the mucosa, and are accompanied by the characteristic stroma of the mucosa. The

small, irregular islands of homogeneous tissue seen scattered throughout the tumour are composed of glands with their accompanying stroma. Seen in cross sections the glands appear small and round, but when cut lengthwise they show a typical cylindrical outline. Sometimes they are curved, forming a half-circle. In a few places branchings may be noticed. The glands are lined by one layer of cylindrical epithelium, on which it is frequently possible to distinguish cilia.

The gland cavities are empty, or contain a small amount of granular material. The small cyst-like spaces, seen macroscopically, are dilated glands. The epithelium of some of these is intact, that of others is flattened, or has entirely disappeared. Some of the cyst cavities are empty; others contain desquamated epithelium, which may have taken up light-brown granular pigment; a few are filled with blood. The stroma surrounding these glands is identical in character with that of the uterine mucosa. In places it shows some hæmorrhage; in other parts its cells have taken up yellowish-brown granular blood pigment. Scattered here and there throughout the growth is a small gland, or a row of glands, devoid of stroma, and lying directly between muscle bundles. The glands are most abundant near the uterine mucosa, diminish in number as one passes outward, and in the normal uterine muscle are entirely wanting.

Von Recklinghausen was in places able to make out a definite arrangement of the muscle around the glands. He believes that the growth of the glands and that of the muscle proceed simultaneously. I was unable to detect any special relation of the muscle to the glands. In both cases it looked as if the mucosa had penetrated into the spaces between the muscle bundles. I am constrained to believe that the muscular growth commences in the inner zone just beneath the mucosa, and that the bundles of these fibres, being loosely united with one another, have allowed the uterine glands to penetrate into the depth.

SUBSEQUENT HISTORY. CHANGES IN THE DIFFUSE ADENO-MYOMATA

In Case 3,136 (p. 536) the uterine mucosa of the anterior wall near the internal os was gathered up into longitudinal folds, and projecting from the lower segment of the uterus was a globular polyp consisting of muscle and glands.

Schatz reports a case which appears to have a definite bearing on the subject. The hardened uterus was 16 centimetres long and 8.5 centimetres in diameter. Its walls varied from 2 to 2.5 centimetres in thickness. The uterine cavity contained five rows of broad-based polypi. Each row consisted of from two to six polypi. Between the rows were deep depressions. The polypi pointed toward the internal os. They varied from a pea to a hen's egg in size. The uterine cavity was completely filled with them.

On section, the polypi were found to have a rich blood supply, and in several places bundles of muscle fibres could be seen extending into them, reaching almost to the free surface. Where the muscular element predominated the polypi were very firm. Scattered throughout the uterine wall were small myomata, which were not easily shelled out. In the myomata near the peritoneal surface no cysts were to be seen, but in those near the uterine cavity, and also in the muscle, they were present. The outer portion of the uterine wall was entirely free from cysts. The polypi consisted of spindle-shaped cells, and scat-

tered throughout them were gland-like cavities lined by high cylindrical epithelium. Where dilatation had taken place the gland epithelium was cuboidal. The spindle-shaped cells of the polypi merged imperceptibly into the muscle fibres. There was no evidence of carcinoma.

It would appear that in this case a diffuse adeno-myoma existed, and that the uterus was trying to free itself of the new growth, just as it extrudes ordinary myomata. In such a case the polypoid condition would naturally result.

A publication by Diesterweg also appears to throw some light on our cases. In a woman who for three years had had profuse and painful menstruation, on examination, a nodule the size of a hen's egg was found presenting at the external os. Its surface was somewhat eroded. Its pedicle, which was one inch in thickness, sprang from the uterine cavity. The nodule was composed of concentric layers. Its walls were 1.5 centimetres in thickness, and in its centre was a large cavity, the inner surface of which presented numerous small depressions, giving an appearance resembling that of a ventricle. There was also a smaller cavity the size of a cherry. The walls presented the typical appearance of fibro-myoma, and the cavities were lined by cylindrical ciliated epithelium. They were filled with brownish-black blood.

Two years later the patient was again admitted on account of profuse menstruation. The uterus was enlarged, and admitted a sound for a distance of 13 centimetres. Soon after the administration of ergotin a tumour, the size of a man's fist, presented at the external os. This was removed, and was found to measure $9 \times 7 \times 6$ centimetres. It was composed of myomatous tissue, and contained a cyst the size of a walnut. The cyst was lined by cylindrical ciliated epithelium and filled with blood.

Assuming that Schatz's and Diesterweg's cases belong to the same variety of tumours as Cases 3,136 (p. 536) and 3,418 (p. 540), we may assume three stages:

I. The diffuse adeno-myoma, as seen in our Cases 3,136 and 3,418 and in von Recklinghausen's Case D.

II. The polypoid stage, shown in Schatz's case.

III. The gradual expulsion of the polypi, as noted in Diesterweg's case.

We know uterine myomata usually commence in the interstitial layers of the uterus, and in time pass inward toward the uterine cavity or outward toward the peritoneal surface. In the diffuse adeno-myoma is it not equally probable that portions of the growth might in time be separated and forced toward the peritoneal surface?

Origin of these Tumours

Von Recklinghausen reports a case (IV, *b*) in which the tumour to a great extent resembled those of our cases. He found, however, a peculiar glandular arrangement. In places several glands opened into a chief canal, which after running a short distance became dilated, forming an ampulla. Von Recklinghausen reviews at length the microscopical appearances of remains of the Wolffian body, and finds such a striking resemblance between these and the glands of the tumour that he concludes that the glands in this case are derivatives of the Wolffian body, notwithstanding the fact that they have reached the surface of the mucosa in several places.

Von Recklinghausen believes that the growth, as it encroached upon the uterine cavity, caused partial atrophy of the mucosa and thus allowed the glands of the tumour to open into the uterine cavity. He, however, admits the possibility of these glands being derived from those of the mucosa. I am strongly of the opinion that the various forms of glands described in this case can be readily explained by the pressure to which they have been subjected by the myomatous growth, and that their uterine origin is much more probable.

In Case D, which he reports in the appendix to his monograph, the uterine glands opened in many places on the surface of the mucosa. Von Recklinghausen considers that the glands of the tumour were undoubtedly derived from the uterine glands.

In our two cases the glands of the tumour originated beyond a doubt from those of the uterine mucosa (Plate IX).

Clinical History.—The cases reported by von Recklinghausen, Diesterweg, and myself occurred in patients between forty and forty-six years of age. All of the married women had had children, but in no case had a labour occurred within a few years prior to the operation. All had had painful and profuse menstruation, and the menstrual blood had frequently been clotted. The symptoms manifested are those common to ordinary uterine myomata, and from the clinical history alone one would not be able to detect any manifestation peculiar to this special variety of myoma.

Tabulation of the Chief Points in the History of the Cases of Adeno-myoma diffusum benignum

NAME.	Age.	No. of children.	No. of years since last labour.	Age at which menses commenced.	Character of menses.
Freund and von Recklinghausen.	42	8	8	13	Continual loss of blood for fifteen months.
Diesterweg	40	8	15	Very profuse for three years. More recently the discharge was watery, and later became purulent. The patient had been compelled to remain in bed for the last six weeks prior to the operation.
Kelly and Cullen, Case 3,136	46	Single.	Single.	11	Profuse and painful; clotted blood.
Kelly and Cullen, Case 3,418	40	1	16 Miscarriage 11 years ago.	Profuse and painful; clotted blood.

Diagnosis.—From the symptoms one will be able to make a fairly safe diagnosis of myoma, there being an enlarged uterus, with probably some small subperitoneal nodules on its surface. The uterine cavity will be lengthened, so that in all these cases pregnancy must be excluded. The continual hæmorrhage which has existed for years will negative such a supposition. As one sees from examining Plate IX, Fig. 1, curetting the uterus would prove that

the mucosa is normal, and does not show the slightest sign of a malignant growth.

Treatment.—In the majority of these cases the tumour will be looked upon as a simple myoma, its true character not being determined before operation. Should a diagnosis of adeno-myoma be made, abdominal hysterectomy is indicated. It would be impossible to shell this tumour out of the muscle and still leave the uterus, the two being so intimately united.

Prognosis.—I agree with von Recklinghausen in considering these neoplasms non-malignant. The glands are confined to the new growth, and do not show the slightest tendency to invade the normal muscle. The gland epithelium is only one layer in thickness, and throughout preserves its normal glandular type, in no place tending to proliferate and fill the gland cavity.

It may be mentioned that among all of the adeno-myomata of the uterus observed by von Recklinghausen there were two in which he thought there was a carcinomatous change. The prognosis is good.

SARCOMA OF THE BODY OF THE UTERUS

When compared with adeno-carcinoma of the uterus, this condition is very rare, as may be gathered from the accurate and comprehensive study of J. Whitridge Williams,* who in 1894 was able to collect from the literature only one hundred and forty-four cases of sarcoma. This number included those primary in the cervix, as well as those springing from the body of the uterus.

According to Williams, sarcomata of the uterus may be divided into two main groups: (1) Those affecting the mucosa; (2) those commencing in the parenchyma. The first group is the only one that concerns us for the differential diagnosis. In fully one third of the cases collected the process originated in the endometrium.

Sarcomata usually spring from the upper part of the uterine cavity, and, although occasionally diffuse, as a rule are sharply defined. If the process be detected in the early stage, the surface may be unbroken, the tumour consisting of a single rounded or oval nodule (Fig. 283). Larger growths may be lobulated, as represented in Fig. 285 (p. 552). One striking characteristic is that the surface, when no necrosis has taken place, is usually comparatively smooth, not presenting the fine finger-like appearance seen in adeno-carcinoma. This point of differentiation does not, however, always hold good. Thus, in Fig. 284, the lobulations are not marked, and yet finger-like outgrowths are present. A most beautiful exemplification of the differences between adeno-carcinoma and sarcoma was supplied by Emanuel's† case. A hysterectomy had been performed on a patient forty-seven years old. A smooth, soft tumour, the size of a pigeon's egg, was found springing from the posterior wall of the uterus and projecting

* Williams, J. Whitridge. *Contributions to the Histology and Histogenesis of Sarcoma of the Uterus*. *Amer. Jour. Obst.*, 1894, vol. xxix, p. 721.

† Emanuel, R. *Ueber gleichzeitiges Vorkommen von Carcinom und Sarkom im Uteruskörper*. *Zeitschr. f. Geburtsh. u. Gynäk.*, 1896, Bd. xxxiv, S. 1.

into the cavity. The surrounding mucosa was everywhere gathered up into little papillary folds. On histological examination, the nodule proved to be a typical round-cell sarcoma, while the little papillary folds belonged to an adeno-carcinoma. The illustrations accompanying the article leave no doubt as to the accuracy of the diagnosis.

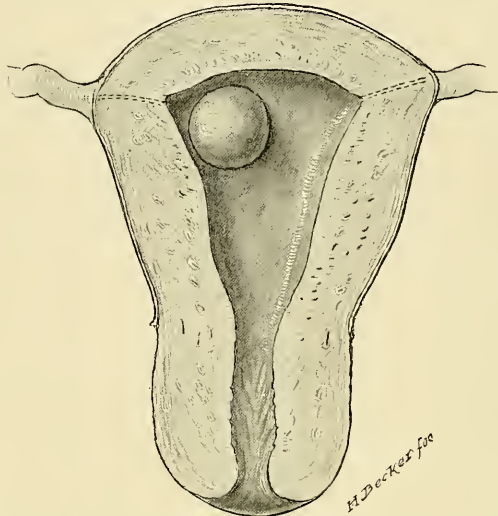


FIG. 283.—A SMALL CIRCUMSCRIBED SARCOMA OF THE BODY OF THE UTERUS.

This case was curetted by Dr. Kelly, and from a microscopical examination of the scrapings a diagnosis of sarcoma was rendered by Dr. Flexner. The nodule is very small, circumscribed, and smooth; it is situated near the right uterine horn. Had the operator not curetted systematically all parts of the cavity, this nodule might have been left undisturbed, and the curettings would then have given an erroneous idea as to the conditions really present. (After H. A. KELLY.)

The sarcomatous nodule, on being cut into, usually presents a smooth, homogeneous, glistening surface, only rarely being traversed by the broad trabeculae noted in adeno-carcinoma. Moreover, the carcinomatous tissue is more granular.

During the last four years we have encountered three cases of sarcoma of the body of the uterus. Two of these have been of the round-cell variety, while the third was a spindle-cell sarcoma. With the giant-cell sarcoma we have had no experience, and shall therefore confine ourselves to the discussion of the differentiation between the first two varieties and adeno-carcinoma of the uterus.

Round-cell Sarcoma.—Histologically, one's attention is instantly drawn to the large areas which show practically no necrosis, but are perfectly preserved. The tissue is composed of a homogeneous mass of cells with little or no intervening stroma (Fig. 286). The cells have round, vesicular nuclei, and are remarkable for their uniformity in size. Occasionally a cell is encountered in process of division. Traversing the growth are many delicate blood capillaries, which ramify in all directions, dividing the tissue up into alveoli. These capillaries are accompanied by a very small amount of stroma. If necrosis takes place, it is usually along one margin, the underlying part of the growth being still unbroken. Thus the picture is very different from that belonging to adeno-carcinoma. In the latter the growth does not usually form large homogeneous masses, but much intervening

stroma is present. The nuclei are not usually uniform in size, and the blood-vessels do not pass in between the individual cells of the growth, but are situated in the surrounding stroma, which is abundant. Again, a large section of adeno-carcinomatous tissue is rarely met with in which some necrosis is not present. Lastly, in adeno-carcinoma a gland-like arrangement can always be made out in some part of the specimen, whereas in sarcoma this is never encountered unless there be a coexistent carcinomatous growth.

Spindle-cell Sarcoma.—The same general points of differentiation hold good here as in the round-cell variety, but instead of the round cells we have the spindle cells, which may not be quite so uniform in size. Occasionally the tumours contain giant cells.

Judging from such cases as the three given here, the diagnosis between adeno-carcinoma of the body and sarcoma would seem easy; but in not a few instances the resemblance between the two processes is so close that an absolute diagnosis is impossible. Fortunately, this is usually a point of no great moment for the operator, since in the presence of a growth which leaves no doubt as to its malignant character the indications for treatment are clear.

In Olshausen's clinic only two cases of sarcoma starting in the uterine mucosa were noted during a period of four years. These were reported by Keller,* who says that in three other cases from an examination of scrapings he had diagnosed sarcoma, but that in each the subsequent removal of the uterus proved that the growth was an adeno-carcinoma.

Clinically, the cases of sarcoma here reported offered no clew as to the diagnosis. One patient was forty-five years of age, the second fifty-six, while the age of the third was unrecorded. The patients had sought medical aid on account of the watery discharge or the uterine hæmorrhage.

Cases of Sarcoma of the Body of the Uterus

Dr. Deale's Patient †

Round-cell sarcoma of the body of the uterus (Fig. 284); hysterectomy.

Mrs. O., aged forty-five, consulted Dr. Deale in June, 1894, for a profuse watery vaginal discharge, which latterly had been tinged with blood. The patient had not suffered any ill effects from the discharge, but was slightly alarmed at the appearance of blood. She had had two children. The menopause had occurred when the patient was forty-two years of age. On vaginal examination, the uterus was found to be small and freely movable, but from the microscopical appearance presented by scrapings sarcoma was diagnosed.

On September 13th, vaginal hysterectomy was performed by Dr. Fry. The patient made an uninterrupted recovery.

Gyn.-Path. No. 602. February 25, 1895.

* Keller, C. *Zur Diagnose des Schleimhautsarcoms des Uteruskörpers.* *Zeitschr. f. Geburtsh. u. Gynäk.*, 1890, Bd. xx, S. 116.

† Deale, Henry B. *Sarcoma Fundi Uteri.* *Amer. Jour. of Obst.*, vol. xxxi, 1895, p. 206.

Diagnosis.—Round-cell sarcoma of the uterus.

Examination of the hardened specimen. The uterus is $10 \times 5 \times 6$ centimetres in its various diameters. The peritoneal surface is smooth and glistening; the cervix, which measures 3.5 centimetres in diameter, shows no loss of tissue. The cervical canal is 3.5 centimetres long; its mucosa is normal. The uterine walls average 2 centimetres in thickness, and the cavity is 4.5 centimetres long. Springing from the posterior wall is a worm-eaten, irregular, sharply defined tumour, 4 centimetres long and 3.5 centimetres broad (Fig. 284). It almost com-

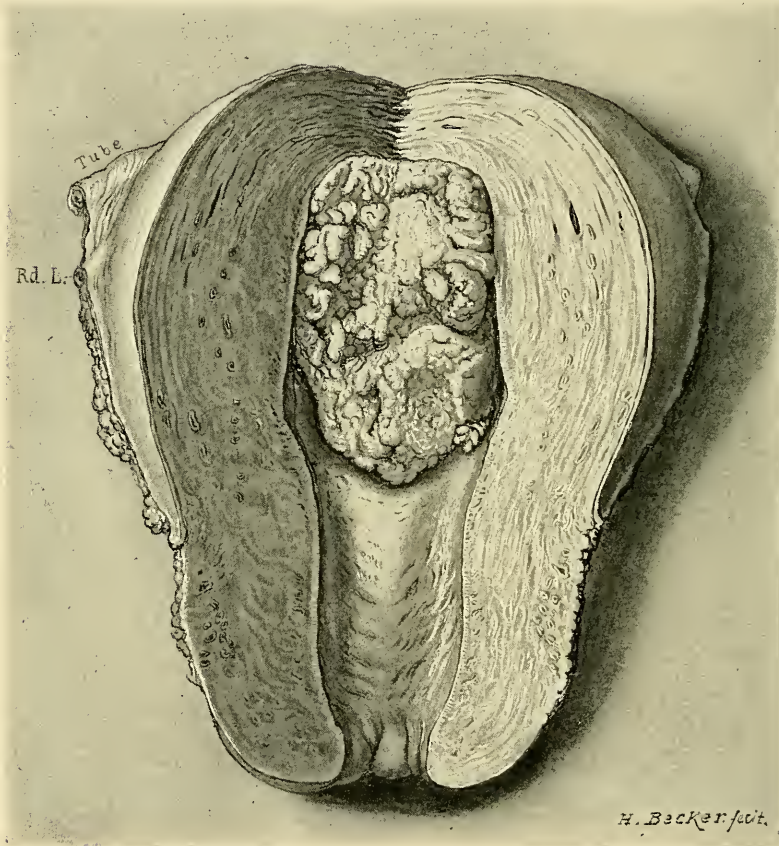


FIG. 284.—A ROUND-CELL SARCOMA OF THE BODY OF THE UTERUS. (Natural size.)

Gyn.-Path. No 602. The uterus is considerably enlarged and its walls are thickened. The cervix is intact; its mucosa, as well as that lining the lower part of the uterine cavity, is normal in appearance. Occupying the greater part of the cavity is a new growth. This is sharply defined from the surrounding mucosa, and has springing from its surface delicate finger-like or polypoid outgrowths. We learn from the text that the posterior wall has been invaded to a considerable depth. It would be impossible, macroscopically, to differentiate between this growth and an adeno-carcinoma of the body.

pletely fills the uterine cavity. On section, it is yellowish white in appearance, and is divided up into areas, varying in size from a pin-point to 4 or 5 millimetres in diameter, by glistening trabeculæ. The growth invades the uterine wall for

probably 6 to 8 millimetres. The uterine mucosa, where not involved by the growth, averages 1.5 millimetres in thickness.

Histological Examination.—The squamous epithelium covering the vaginal portion of the cervix is intact, but near the external os it has apparently been rubbed off, while the underlying tissue is richly infiltrated by small round cells. The cervical glands are convoluted and lined by their characteristic high cylindrical epithelium. The uterine mucosa is rather thin, but its surface epithelium is unbroken. In the vicinity of the new growth the epithelium is thrown up into little papillary folds. The uterine glands are few in number, round on cross section, and are lined by the characteristic epithelium. A few of the glands are dilated, their epithelium is somewhat degenerated, but still intact, while the lumina contain desquamated epithelium and *débris*. The stroma of the mucosa is rather dense, and is for the most part composed of cells having spindle-shaped, deeply staining nuclei.

In the external portions of the growth the uterine glands are found to be very small, while scattered throughout the stroma are strings of deeply staining cells, which apparently have absolutely no connection with the glands. The cells in these areas have round, or irregularly oval, deeply staining nuclei. The mucosa ends abruptly, giving place to the tumour. The latter is composed of masses of cells, presenting an ill-defined alveolar arrangement. Over the greater portion of the specimen the tissue is virtually one homogeneous mass of cells, the nuclei of which are approximately circular, and present a vesicular appearance. Between the cells is a very delicate stroma composed of spindle-shaped cells. Where the tumour is commencing to invade the muscle the tumour cells are seen occurring in single or double rows, with the characteristic spindle-shaped cells between them. The muscle is irregularly involved. The tumour is fairly rich in blood capillaries, the blood in these being separated from the cells of the growth by a single layer of endothelium. The superficial portions of the tumour are necrotic and covered by myriads of polymorphonuclear leucocytes. The growth has extended to both uterine horns, and the muscle along the advancing margin of the tumour shows much small-round-cell infiltration.

Gyn.-Path. No. 698

Round-cell sarcoma of the body of the uterus (Figs. 285 and 286). Extension to the lymphatics of the left uterine horn; small parovarian cyst of the left side. Hysterectomy.

B., admitted to Dr. Kelly's sanatorium, May, 1895.

The patient has for the last eighteen months suffered from metrorrhagia, accompanied by considerable pain. The flow has contained granular or flaky particles. The patient's health was previously good. Her mother died of cancer of the breast at seventy.

On vaginal examination, the cervix is found to be lacerated; the uterus is considerably enlarged.

Operation, May 2, 1895. Combined vaginal and abdominal hysterectomy. After completing the operation, a gauze drain was inserted into the vagina. The patient made an uninterrupted recovery, and was discharged May 30th.

Gyn.-Path. No. 698. The specimen consists of the uterus and its appendages (Fig. 285). The uterus measures $12 \times 9 \times 9$ centimetres. Both anteriorly and posteriorly it is free from adhesions. The cervix is 3.5 centimetres in diameter; the mucosa of the vaginal portion is intact. The cervical canal is 3.5 centimetres in length; its mucosa is smooth and glistening. The uterine walls vary from 2

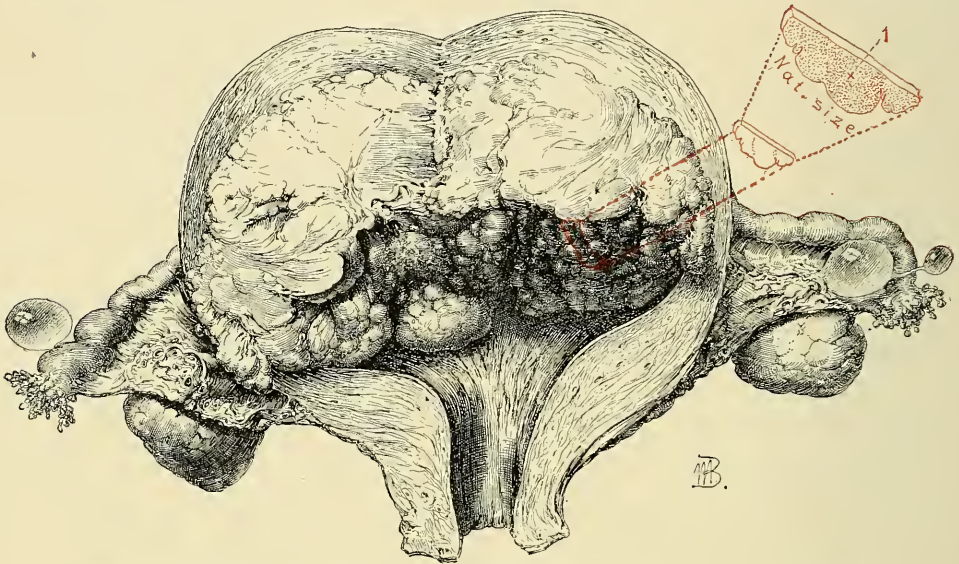


FIG. 285.—A ROUND-CELL SARCOMA OF THE BODY OF THE UTERUS. ($\frac{5}{9}$ natural size.)

Gyn.-Path. No. 698. The uterus, as can be gathered from the description, is much enlarged. The cervical mucosa, as well as that in the lower part of the uterine cavity, presents the usual appearance, but the greater part of the cavity of the uterus is occupied by a new growth. The lower or free surface of this presents a smooth lobulated appearance; the delicate finger-like growths are entirely lacking. The tumour on section is somewhat homogeneous in appearance, and laterally has invaded the muscle almost to the peritoneal surface. Springing from the surface of the right tube is a small subperitoneal cyst; between the left tube and ovary is a small parovarian cyst. The appendages on both sides are normal. From point 1 Fig. 286 is taken. (After H. A. KELLY.)

to 3 centimetres in thickness; the muscle appears to be perfectly normal. Springing from the fundus, and partly also from the posterior wall, is a globular tumour 6.5 centimetres in diameter. This presents a rough, mulberry appearance, is yellowish white, and appears to be very vascular. The individual lobulations vary from 3 millimetres to 2 centimetres or more in diameter. They are perfectly smooth, and are separated from one another by shallow or deep sulci. On section, the tumour presents a grayish-white appearance, and is of the consistence of brain tissue. It is apparently divided up into smaller portions by delicate bands of glistening tissue. The central portion of the tumour is necrotic over an area measuring 4×1 centimetres. The line of junction between the tumour and the uterine muscle is sharply defined. The uterine mucosa, where present, is bluish white, smooth, and glistening.

The right tube and ovary offer nothing of note.

The left tube and ovary are also normal, but situated in the parovarium is a cyst, 1.5 centimetres in diameter.

Histological Examination.—The tumour projecting into the uterine cavity is composed of cells having round or oval nuclei. The contour of the nucleus is sharply defined; its internal portion is pale, but contains fine masses of chromatin. Here and there nuclear figures are to be made out, and in some places eight to ten nuclei are found bunched together. The cells, as a rule, however, show a marked uniformity in size; the tissue is very rich in blood capillaries, which are lined by one layer of endothelium. These capillaries form a regular network, giving the tissue an alveolar arrangement (Fig. 286). A few lymphoid cells are found here and there. The stroma, apart from the small amount accompanying the blood-vessels, is practically absent, as is well shown by van

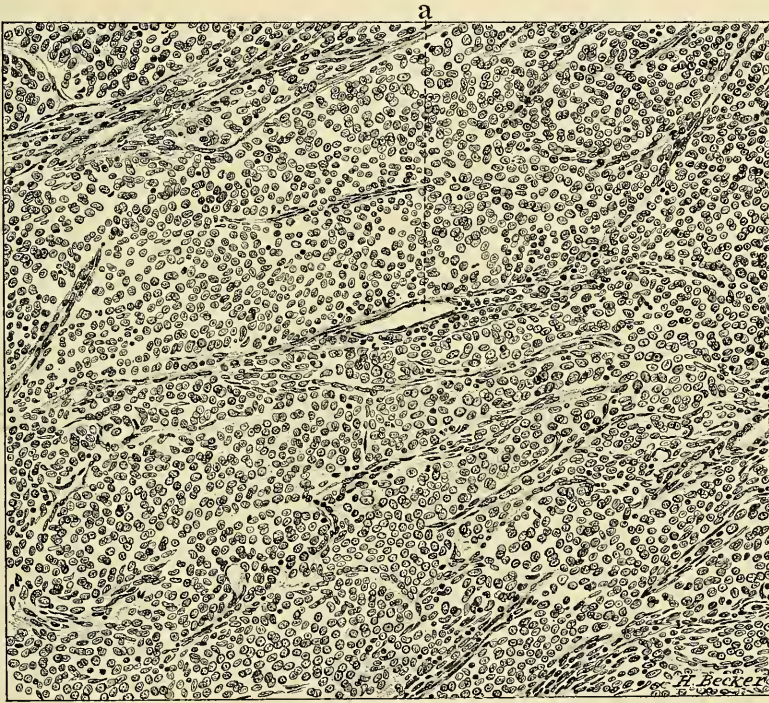


FIG. 286.—ROUND-CELL SARCOMA OF THE BODY OF THE UTERUS. (175 diameters.)

Gyn.-Path. No. 698. The section is from Fig. 285 at point 1. The entire field consists of one homogeneous mass of cells, containing oval or round nuclei of uniform size. Its cells are divided into smaller areas by double rows of spindle cells. *a* is a blood-vessel. With van Gieson's stain it is possible to show that these double rows of spindle cells represent the endothelial walls of blood capillaries. Hence we have this large area of cells traversed by nothing except the delicate blood capillaries.

In carcinoma of the body we should expect to find some evidence of a glandular arrangement, more stroma, and the blood-vessels lying in the stroma instead of between the individual tumour cells. Again, it is exceptional in carcinoma to find such a large area with no evidence of necrosis.

Gieson's stain. The necrotic portions of the tumour are sharply defined; the nuclei do not stain, but the entire tissue takes the eosin. Scattered through-

out it are polymorphonuclear leucocytes and small masses of yellow, granular pigment. There is apparently no breaking-down of the necrotic tissue. The line of junction between the uterine muscle and the new growth is sharply defined—the one ending abruptly at the commencement of the other. There is little, if any, small-round-cell infiltration along the advancing margin, but the uterine muscle in the vicinity of the growth contains large oval spaces, partially filled with a granular material, and containing an occasional polymorphonuclear leucocyte or lymphoid cell. These spaces have an endothelial lining, and are probably lymph channels. The cells are not spindle-shaped, and, although not typical, the growth may be classed as belonging to the round-cell variety of sarcoma.

The uterine mucosa in the lower part of the cavity has a slightly wavy outline. The epithelium is intact, elongate, and has in places proliferated. Between the individual cells are many polymorphonuclear leucocytes. The uterine glands are numerous, round or oval on cross section, and have an intact epithelium. Not a few are dilated, and some are filled with a granular material, or with polymorphonuclear leucocytes. The stroma of the mucosa in the superficial portions shows moderate polymorphonuclear and lymphoid infiltration, and in the deeper portions is somewhat edematous. It has a rich blood supply, and here and there contains atypical lymph nodules. At the junction of the new growth with the uterine muscle some of the glands have been nipped off; they are, however, perfectly normal in appearance. The tumour has evidently commenced beneath the mucosa, since in a few places it has carried the surface epithelium before it. Here the mucosa is seen as a ribbon of cylindrical epithelium covering the surface of the tumour.

The appendages on the right side are normal, but the tube on the left side, at the uterine horn, shows at least four oval or slit-like spaces, lined by one layer of endothelium, and containing granular material. In each of the four is a mass of cells springing into the cavity—probably metastases from the original tumour. The nuclei of these cells are small and round, and the channels in which the aggregations are found are most probably lymph spaces. Sections through other portions of the tube show it to be normal.

The small parovarian cyst, on the left side, has a delicate wall composed of spindle-shaped connective-tissue cells; its inner surface is lined by one layer of low cylindrical ciliated epithelium.

Diagnosis.—Round-cell sarcoma of the body of the uterus. Extension to the lymphatics of the left uterine horn. Small parovarian cyst on the left side. December 1, 1899. The patient is well; there is no evidence of a return of the growth. Length of time since operation, four years and six months.

Gyn. No. 5,309

Spindle-cell sarcoma of the body of the uterus with extension to the broad ligaments. Curettage.

M. K., aged fifty-six, patient of Dr. Charles Spangler, York, Pa., admitted June 3, 1897.

Complaint: profuse offensive uterine discharge; pain in lower part of the abdomen.

The patient has been married eleven years, but has never been pregnant. Her menses commenced at eighteen, were always regular, lasted five days, and were painless. The menopause occurred at forty-five. In June, 1896, she had a slight hæmorrhage for two days, and for the past six months has had hæmorrhages at irregular intervals. Her family history is good. Her father and mother are both living. Her previous history is unimportant.

Present condition: The patient is extremely emaciated and is very weak; the feet are swollen and edematous. She has a pale, cachectic appearance; the tongue is pale and flabby; the appetite is fair; the bowels are constipated. Menstruation for the past week has been painful. On vaginal examination the cervix is found to be thinned out, and springing from the uterus is a cauliflower-shaped mass. This does not involve the cervix or vagina.

Several pieces of the tissue were removed for examination, but as the patient was very weak, and as the disease had extended far laterally, the uterus could not be removed.

Gyn.-Path. No. 1,761. The specimen consists of a considerable amount of whitish tissue, very soft in consistence, but on section presenting a glistening, translucent surface.

Histological Examination.—The tissue is made up of cells more or less irregularly arranged, or running parallel to one another. They are large and spindle-shaped. The majority of the nuclei are large, oval, or elongate-oval, and take a diffuse stain; some are spindle-shaped, while a few appear round. In many places there are very large cells, containing large, irregular, intensely staining nuclei or masses of nuclei. Karyokinetic figures are not very numerous, but here and there an atypical figure can be seen. Nuclear fragmentation has taken place in many parts, while scattered throughout the tissue are numerous small round cells and polymorphonuclear leucocytes. Some portions of the tissue are edematous. The growth is richly supplied with small blood-vessels, and in one section several large vessels are seen. The surface of the specimen is covered with pus.

Diagnosis.—Spindle-cell sarcoma of the body of the uterus.

SECONDARY SARCOMA OF THE BODY OF THE UTERUS

This condition, though rare, is occasionally found. The growth is usually primary in the ovary, and extends to the uterus by continuity. We have met with two cases, in each of which the primary growth was ovarian. In the first case there was a large angio-sarcoma of the left ovary, in which, even with the unaided eye, it was possible to make out the parallel strands, each containing a central blood-vessel. The process had extended to the uterus (Fig. 289). The growth appeared as small nodules in the muscular walls and formed a large, solid mass that occupied almost the entire uterine cavity, and projected through the cervix into the vagina. In the second case (Fig. 287) the primary growth was in the right ovary. It formed a very large lobulated mass, bearing a marked resemblance to a multiple myomatous tumour, and had also extended by continuity to

the uterus. Having become too large for the cavity, it had followed the course of least resistance, and portions of it appeared as a lobulated but smooth growth, projecting from the external os and partially filling the vagina (Fig. 288). In Case 2,894 a soft mass was felt projecting through the external os, and extending upward from the pelvis was a firm bilobate mass, more prominent on the left than on the right side.

If the mass of tissue projecting from the cervical canal had been previously examined, sarcoma could have readily been diagnosed (Fig. 290), and in the presence of the large mass filling the pelvis it is doubtful whether the operator would have attempted the hysterectomy. But when once the abdominal cavity had been opened the hæmorrhage was so great that to abandon the operation was out of the question. In the second case, the growth projecting into the vagina looked much like a small and slightly lobulated submucous myoma; furthermore, the multinodular character of the pelvic growth naturally tended to confirm the diag-

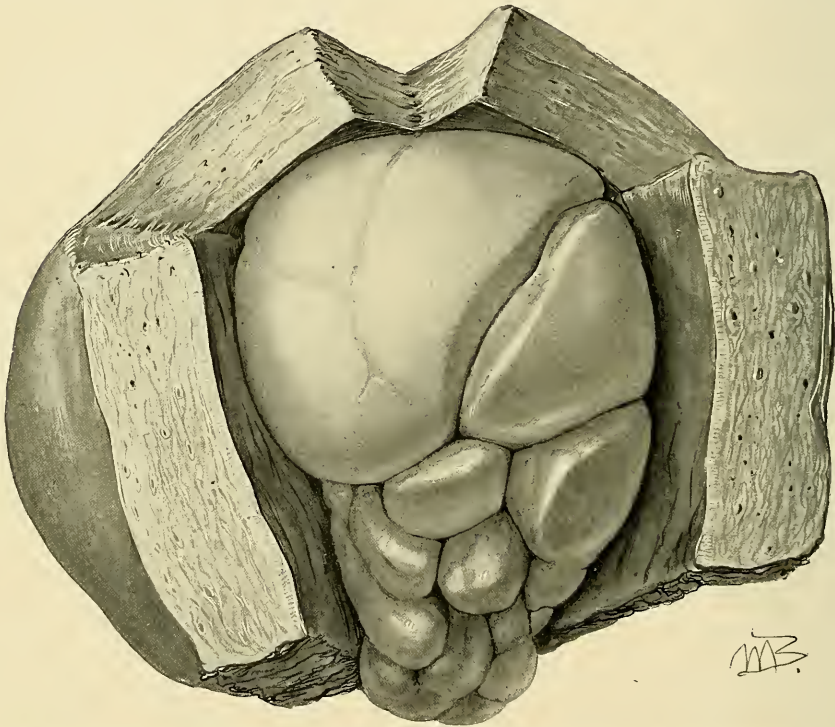


FIG. 287.—SARCOMA OF THE BODY OF THE UTERUS SECONDARY TO THAT IN THE RIGHT OVARY.
(Natural size.)

Gyn.-Path. No. 1,054. The uterus is considerably enlarged. Occupying the posterior wall is a new growth which projects into the uterine cavity, forming two large and numerous smaller, sharply defined, smooth, and faceted nodules. Their shapes and relations to one another remind one somewhat of calculi. On histological examination, it is found that the surfaces of several are still covered by the mucosa, which is, of course, much atrophied. The part of the growth projecting through the cervix presented the picture seen in Fig. 288. (After H. A. KELLY.)

nosis of a myomatous uterus. Even granting that the nodule filling the vagina had been rather soft, the clinician would hardly have suspected that he was deal-

ing with a sarcoma. Microscopical examination of a small piece of this growth would, of course, have shown the sarcomatous nature of the tumour.

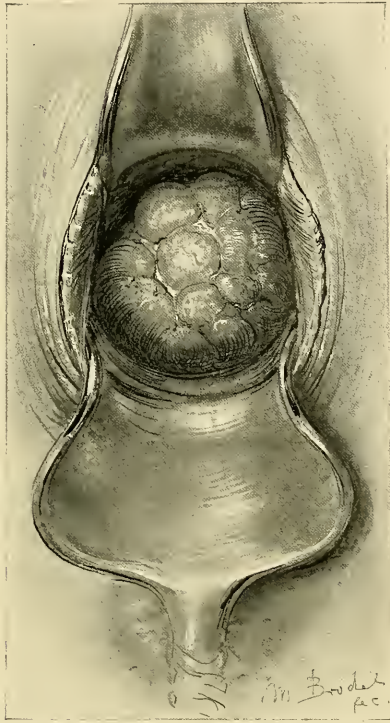

FIG. 288.—SECONDARY SARCOMA OF THE BODY OF THE UTERUS WITH THE PROTRUSION OF A PORTION OF IT THROUGH THE EXTERNAL OS. ($\frac{3}{4}$ natural size.)

Gyn.-Path. No. 1,054. To obtain a clear idea of the growth in the uterine cavity, see Fig. 287. Filling the upper part of the vaginal vault is a rounded, smooth, and slightly lobulated mass, which on histological examination is found to consist almost entirely of spindle cells. (After H. A. KELLY.)

In all cases in which there is an obscure abdominal tumour, and at the same time a growth springing from the cervical canal, it will be well to examine, as a matter of routine, a portion of the latter microscopically before attempting complete removal.

Gyn. No. 2,894

Angio-sarcoma of the left ovary. Extension to the uterus by continuity and also apparently by metastasis, the growth in the uterus being a spindle-cell sarcoma; atrophy of the uterine mucosa; calcareous nodules in both tubes and also in the right ovary.*

L. R., aged forty-eight. Admitted July 3, 1894, complaining of enlargement in the lower part of the abdomen, pain in the abdomen, and also in the back.

* Cullen, Thomas S. *Angio-sarcoma of the Ovary*. *Johns Hopkins Hospital Bulletin*, 1894, vol. v, p. 134.

Menstruation commenced at fourteen years, and has always been regular. She has been married over twenty years and has had two children, the youngest of whom is twelve years of age. There is also a history of numerous miscarriages. The family record is unimportant.

History of the present illness: In January the menses became profuse and painful, and have continued to be so. During May she first experienced a severe grinding pain in the left ovarian region. This has continued, and at times radiates down the thighs. Simultaneously with the first appearance of the pain, a mass was noticed in the abdomen just above the pubes; this has gradually increased in size.

On physical examination, the lower zone of the abdomen is found distended, the superficial veins are congested, and palpation reveals a firm bilobate mass springing from the pelvis. This extends slightly higher on the left than on the right side.

The anterior lip of the cervix is flush with the vaginal wall; the os is very patulous, admitting the index finger, and on the left side of the cervical canal a soft mass can be felt. The uterus is enlarged, and appears to be continuous with the mass on the left side.

July 7, 1894. Operation. Abdominal hysterectomy.

An incision, 19 centimetres long, was made through the abdominal walls. On the left side the pelvis was found to be choked by a soft mass, which was slightly movable; over this lay the rectum, which had been displaced toward the right side.

Both the rectum and sigmoid flexure were attached to the tumour by their posterior surfaces. The left ovarian vessels were secured, and enucleation was begun. In freeing the left side the tumour commenced to tear, and it was necessary to hurry the operation as much as possible on account of hæmorrhage. The uterus was then amputated at the cervix, and the cervical stump closed by five silk sutures. Nodules of the growth still remained in Douglas's cul-de-sac, on the left side near the former site of the tumour, and also between the cervical stump and the posterior wall of the bladder.

A large gauze drain was placed in the lower angle of the wound, and the abdomen was closed by silkworm-gut sutures, which included all the abdominal coats. The duration of the operation was fifty-one minutes.

The following day, on removal of the drain, about 15 cubic centimetres of thick, bloody fluid escaped. The discharge gradually assumed the character of pus, and was still present when the patient left the hospital. There was a slight rise of temperature for the first two weeks, 102.5° F. being the highest point reached. The patient was discharged September 3d.

Gyn.-Path. No. 372. The portion of the uterus in the specimen measures 10 × 12 × 9 centimetres. It is irregularly globular, bright red in colour, and covered both anteriorly and posteriorly by a few delicate adhesions. The under cut surface is 5 centimetres in diameter. The uterus is firm and non-yielding; its walls average 2.5 centimetres in thickness, and scattered throughout them are numerous homogeneous fatty-like masses, varying from .5 to 1.5 centimetres in diameter (Fig. 289). One of these presents dark-red patches, which are appar-

ently small blood-vessels. The posterior part of the fundus is occupied by a sub-mucous nodule $8 \times 7 \times 5$ centimetres. This is somewhat lobulated, and resembles raw beef in colour. Springing from the lower margin of the nodule and continuous with it is a finger-like mass measuring $6 \times 4 \times 1.5$ centimetres. This

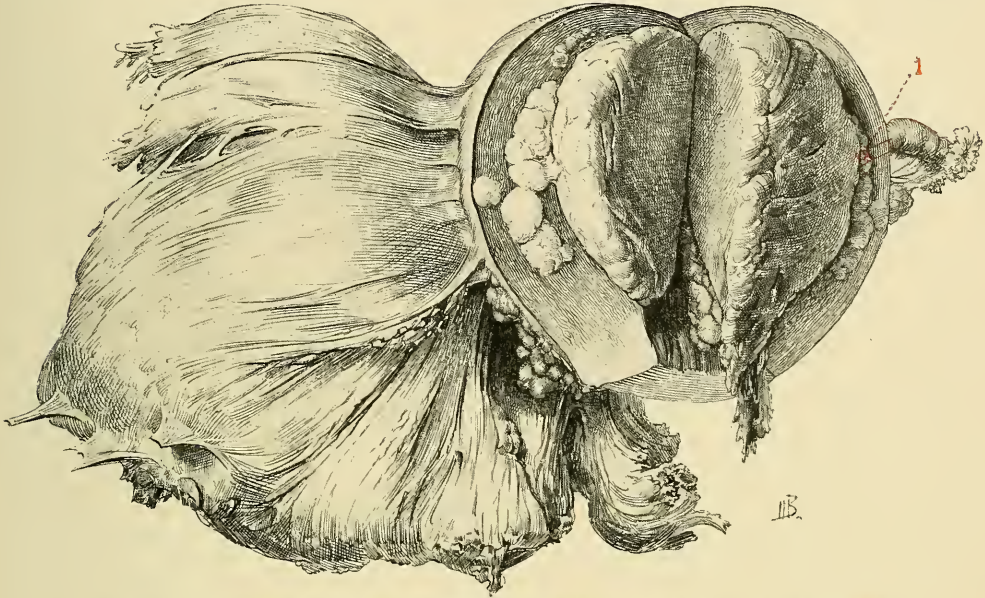


FIG. 289.—ANGIO-SARCOMA OF THE OVARY WITH EXTENSION TO THE BODY OF THE UTERUS.
($\frac{2}{6}$ natural size.)

Gyn.-Path. No. 372. The specimen is seen from behind. On the left side is a large, somewhat lobulated, torn mass, with numerous adhesions attached to its outer margins. The lower and inner portions of the tumour are composed almost exclusively of fibres running parallel to one another. The mass is intimately adherent to the left side of the uterus. The uterus is at least three times the usual size; its walls are twice the normal thickness, while studding the muscle are irregularly lobulated or round nodules. These are yellowish and waxy in appearance, and stand out prominently. The uterine cavity is occupied by a large nodule, having attached to its lower surface a ragged mass that projects through the cervix. There is a total absence of the finger-like processes, and the growth forms a large homogeneous mass. Rarely, if ever, do we find carcinoma reaching such proportions and yet showing so little degeneration. The lower portion of the uterine cavity and a small part of the cervical canal are visible. To the right of the uterus portions of the right tube and ovary can be distinguished. From point 1 Fig. 290 is taken.

projects into the cavity, and its lower teat-like extremity protrudes from the cervix. The uterine cavity is 7 centimetres long and approximately 2.5 centimetres in diameter. The mucosa on the anterior surface is whitish yellow in colour and 1 millimetre in thickness.

Springing from the right side of the cavity is a polyp, 1.5 centimetres in diameter. The large nodule which projects into the uterine cavity is not covered by mucosa, but presents a slightly worm-eaten appearance.

The right tube and ovary are small but apparently normal.

On the left side of the uterus is a mutilated kidney-shaped mass, 16×10.5 centimetres, the convexity of which is directed away from the uterus, while the concave portion is adherent over an area 8×9 centimetres. During operation the tumour was partially divided into three lobulated masses. On sepa-

rating these still farther from one another, they are seen to be composed of fibres, which run in parallel rows. These fibres are light red in colour, and resemble strands of muscle. In the centre of each fibre, and running parallel with its long axis, is a delicate blood-vessel. Other portions of the tumour are pale, homogeneous, and resemble brain tissue, but on further examination are found to be also composed of fibres. There is apparently no breaking-down of the tissue.

The left tube is 11 centimetres long and 5 millimetres in diameter. Its outer extremity is adherent to the tumour. The parovarium is intact. No trace of the ovary is to be made out.

Histological Examination.—The left ovary is intimately adherent to the tumour, there being no dividing line between the two. A portion of the

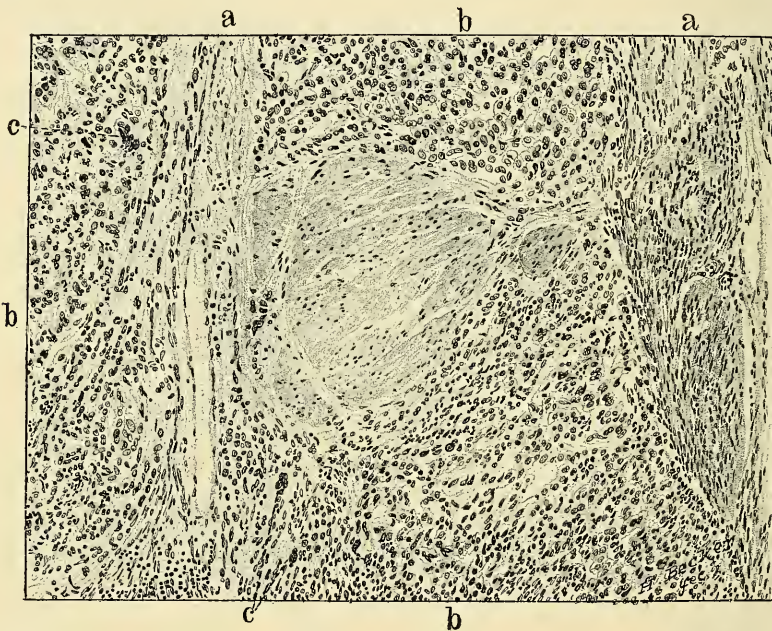

FIG. 290.—SARCOMA OF THE BODY OF THE UTERUS SECONDARY TO SARCOMA OF THE OVARY.
(140 diameters.)

Gyn.-Path. No. 372. The section is from Fig. 289 at point 1. The areas indicated by *a* consist of normal uterine muscle. The areas *b*, *b*, *b* stain deeply, and the cells are much larger than the muscle fibres. The nuclei are large, round, oval, or elongate. They may be vesicular or stain deeply, as seen at various points indicated by *c*. A glance is sufficient to show that the growth is malignant. No glands are visible, nor is there the grouping of cells into nests, so characteristic of squamous-cell carcinoma. From this section alone sarcoma would be strongly suspected.

ovary is recognised by several large corpora fibrosa and a corpus luteum. The tumour mass is composed of spindle cells cut longitudinally and transversely, these tending to arrange themselves around blood-vessels, which are very numerous.

The vessels have an inner lining of endothelium, surrounding which in some places is a delicate muscular coat, showing in the outer portions evidences of hya-

line degeneration. Immediately surrounding the muscular coat are eight to ten layers of spindle-shaped cells running parallel with the vessel.

In other portions of the tumour the blood-vessels are not so abundant, and the spindle cells do not maintain any definite arrangement. Many of the latter have large oval nuclei; others show nuclear figures, while some apparently contain two to three deeply staining nuclei.

Here and there the tumour shows coagulation necrosis, sometimes with, sometimes without, nuclear fragmentation, while in other places polynuclear leucocytes are present.

The uterus: The nodules scattered throughout the uterine wall are composed of cells precisely similar to those of the tumour (Fig. 290). These show, however, no tendency to arrange themselves around blood-vessels. The large nodule projecting into the uterine cavity is similar in nature and presents numerous necrotic areas. On its free surface very little degeneration can be made out.

The uterine mucosa: The cervical glands are for the most part normal; a few, however, are dilated. The change from the cervical to the uterine mucosa is gradual, the latter being exceedingly thin. The surface epithelium is intact. The glands are scant in number, cylindrical, and have an intact epithelial lining. Those glands in the depth of the mucosa run parallel to the surface. The stroma of the uterine mucosa is of moderate density.

The left tube presents some hæmorrhage in the muscular coat, and a few calcareous nodules are seen just beneath the peritoneum. The right tube and ovary also contain a few calcareous nodules.

TUBERCULOSIS OF THE ENDOMETRIUM

Tuberculosis of the endometrium appears under two forms: (a) miliary tuberculosis; (b) chronic diffuse tuberculosis.

The former variety is rare, being seen only in a certain percentage of patients dying with general miliary tuberculosis. No such case is included in our series.

Chronic diffuse tuberculosis in its very early stages is not recognisable by the naked-eye examination, as is instanced by Cases 3,193 (p. 564) and 3,303 (p. 568) of our series. Here the mucosa presented the usual yellowish-white appearance, and was smooth and glistening. When the process is a little farther advanced there may still be no loss of tissue (see Autopsy 654, p. 570), but just beneath the surface a few yellowish-white nodules can be seen. These vary from 1 to 2 millimetres in diameter, and are usually situated near the fundus, the region in which the process has commenced.

Otto von Franqué* reported a case of squamous-cell carcinoma of the cervix, in which, 2 centimetres above the internal os, a soft reddish nodule, the size of a cherry, was found projecting from the mucosa; a similar nodule was detected farther up in the body. Both of these were supposed to be metastases from the carcinoma, but on microscopical examination were found to be dilated glands, around the margins of which were typical tubercles. The mucosa between the

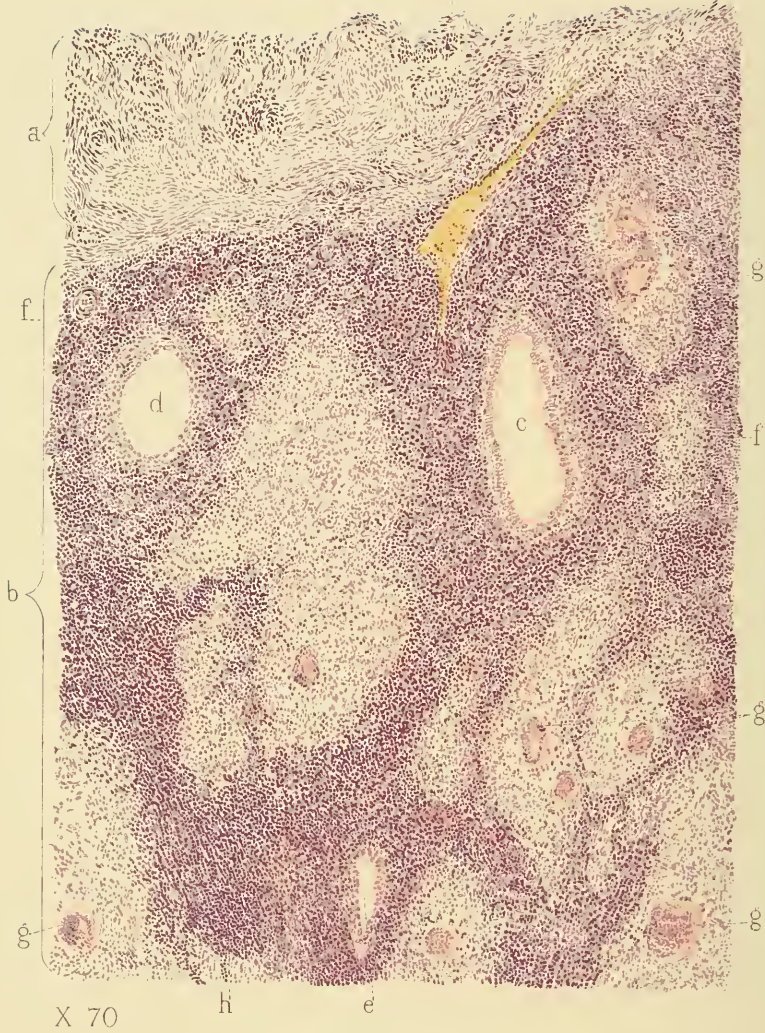* von Franqué, Otto. *Zur Histogenese der Uterustuberkulose. Sitzungsber. d. physik-med. Gesell. zur Würzburg*, 1894, No. 4.

tubercles will in the early stages appear normal, unless there has been a coincident or previous endometritis. When the disease has made farther progress, the tubercles become larger and more prominent, giving to the mucosa an uneven and roughened appearance. Some of these nodules have in the meantime broken down and formed ulcers. The ulcerated areas may be shallow and present a worm-eaten appearance, or have undermined edges. If the tubercle has been quite superficial, a shallow ulcer may be looked for, as the necrosis is greater near the surface than in the depth. If the tubercle be deeply situated, an ulcer with undermined edges is likely to result. The ulcers are at times surrounded by small yellow tubercles. The process gradually extends, the areas of caseation increase and become irregular, and eventually the entire endometrium is converted into caseous material. Should the cervix become occluded, an accumulation of this caseous material may take place, giving rise to a condition resembling pyometra. The tuberculous process gradually extends to the muscle, sometimes reaching as far as the peritoneum, when rupture of the uterus may occur.

Histological Examination.—In the early stages the mucosa over the lower portion of the body is normal. On passing toward the fundus the surface epithelium, though unbroken, here and there is swollen, and stains faintly. As will be seen later, it is beneath the epithelium at these points that the tubercles are found. The surface epithelium has at various points proliferated, forming little teat-like prominences or delicate gland-like spaces. The uterine glands are small and round on cross section, and have an intact epithelium; a few, however, may be dilated and partially filled with desquamated epithelium. With the low power, pale-staining areas are seen scattered throughout the stroma of the mucosa. These are readily recognised as clusters of epithelioid cells. With the high power it is sometimes possible to make out all transitional stages between the stroma cells and epithelioid cells, as is well shown in specimens from Autopsy 654 (p. 570). The epithelioid nests are surrounded by small round cells, which are sharply defined from the normal stroma cells. Some of the tubercles, especially those at the fundus, contain giant cells which are irregular, oval, or round in contour (see Fig. 291, p. 565), and which contain oval, vesicular nuclei, arranged either around the margin of the cell, at one or both poles, or scattered promiscuously throughout the protoplasm.

From Case 3,303 we are inclined to believe that at least some of the giant cells are formed by the coalescence of several epithelioid cells, their protoplasm fusing into one plaque, while the nuclei remain distinct. The centres of many of the tubercles show a tendency to become infiltrated with polymorphonuclear leucocytes. Where the process is more pronounced the gland epithelium may have proliferated. This is seen in Case 3,193 (p. 564), where the epithelial cells had formed a typical tubercle, which contained a giant cell and which projected into the gland cavity. Von Franqué was able to make out precisely the same changes in another case which he reported.

The tubercles continue to enlarge and soon merge together; the surface epithelium disappears; the greater part of the mucosa becomes invaded by tuberculous material, which undergoes caseation; and finally, the caseous areas break down, giving rise to ulcers. In a section made through an early ulcer the



Tuberculosis of the endometrium.

PLATE X.—TUBERCULOSIS OF THE ENDOMETRIUM.

Gran. Path. No. 502. *a* indicates the normal uterine muscle; *b* is the muscle; *c* a normal uterine gland; *d* a dilated gland with flattened epithelium. *e* represents a gland slightly compressed, with partially disorganized epithelium. *f* scattered throughout the stroma of the mucosa are tubercles. *g* *h* *i* *j* *k* *l* *m* *n* *o* *p* *q* *r* *s* *t* *u* *v* *w* *x* *y* *z* are recognized as pale-staining areas composed of epithelioid cells; *aa* as larger cell groups consisting of giant cells, oval or elongate in shape, containing many nuclei arranged around the margin or grouped in the centre, and surrounded by wide zones of epithelioid cells. Infiltrated the stroma are masses of small round cells, particularly abundant in *aa*. *v* is a vein.

It will be noted that the growth is entirely limited to the connective-tissue elements, the epithelium showing no activity, but on the contrary becoming atrophic and disappearing. Hence there is no likelihood of confusing the histological picture of tuberculosis of the endometrium with adenocarcinoma of the body of the uterus. (After H. A. Kirby.)

appearances are as follows: The surface of the ulcer is covered by necrotic material, in which the fragments of a few nuclei or some polynuclear leucocytes are visible, the underlying tissue consisting of epithelioid cells and many small round cells. Scattered throughout this zone are typical tuberculous giant cells. On passing outward toward the muscle the small round cells increase in number, while the epithelioid cells gradually diminish until the normal muscle is reached. As the tuberculous process continues to advance, it invades the muscle, the entire thickness of which may be occupied by tuberculous tissue. Tubercle bacilli are found on the surface of the mucosa, in the glands, epithelioid nests, and in the giant cells. They are especially numerous in the caseous areas.

SYMPTOMATOLOGY

There are no symptoms pathognomonic of this disease, and such indications as might be present would probably be masked by those due to tuberculosis of other organs. The menstruation, in the three cases in which histories could be obtained, was irregular; two of the patients had a slight leucorrhœa, the third had no vaginal discharge. Two were white and two were black; the colour of the fifth is unknown. The ages of four of the patients were three, seventeen, twenty-six, and thirty-three years respectively.

DIFFERENTIAL DIAGNOSIS

From the following cases it will be seen that, clinically, tuberculosis of the endometrium does not resemble carcinoma in any particular. There are no hæmorrhages, and if there be a discharge it is leucorrhœal in character.

It is only on examination of the uterus after removal that confusion is apt to arise, and then only when the process is far advanced. In the early stages of a tuberculous endometritis, one, or much more frequently several small whitish-yellow nodules are seen studding the mucosa in the upper part of the cavity. On microscopical examination of these areas, the surface epithelium is found to be unbroken and the glands are normal; but scattered throughout the stroma are little clusters, or even large masses, of epithelioid cells, and sometimes typical tubercles (Plate X and Fig. 291).

Where there is one large nodule, it is usually surrounded by a zone of small tubercles. In the later stages the uterine cavity may be lined by caseous material, but on the margins of the growth it is impossible to find the delicate papillary projections so characteristic of adeno-carcinoma. The line of demarcation between the tuberculous tissue and the muscle is sharply defined; the tissue may be yellowish white, but it has not the firm consistence which is found in carcinoma.

The histological examination of such a tuberculous uterus at once sets at rest any doubt upon the matter. The inner surface is covered by caseous material, and the underlying tissue is composed of masses of epithelioid cells, among which the typical giant cells are usually scattered in abundance. Thus it is evident

that the picture is totally different, since the epithelium plays no active rôle in the process.

*Cases of Tuberculosis of the Endometrium**

Gyn. No. 3,193

Tuberculous peritonitis; double tuberculous salpingitis; tuberculosis of the endometrium (Fig. 291), probably secondary to that of the tubes.

M. L., aged seventeen. Admitted November 20, 1894. On entrance, she complained of enlargement of the abdomen, associated with abdominal pain. Her menses commenced at fifteen, and were irregular, occurring at intervals of from two to eight weeks. About two weeks before each period she would have sharp, shooting pains in the lower part of the abdomen, but with the appearance of the menstrual discharge the pain would cease. The flow was moderate in amount, and lasted from two to four days. The last menstrual period occurred in May, 1894. Her family history is unimportant. The patient had the "grippe" in December, 1893, and has not felt well since that time. In March, 1894, she had "malaria," having chills every other day. In May of the same year she developed pleurisy, which lasted until the first week in June.

About three weeks ago her abdomen commenced to enlarge, and she has had occasional sharp abdominal pain. This has not been confined to any one locality. She has had no nausea and no vomiting. The patient at present is fairly well nourished; the mucous membranes are pale; the tongue is coated; the appetite is good, but the bowels are somewhat constipated. She has neither urinary difficulty nor leucorrhœa. The abdomen is slightly and symmetrically prominent. By palpation, nothing can be detected; on percussion, a distinct wave of fluctuation can be elicited.

Operation, November 21st. Abdominal hysterectomy.

Gyn.-Path. No. 519. The specimen consists of a portion of the uterus with the tubes and ovaries intact; also of a small piece of peritoneum. The portion of the uterus present is 4 centimetres long, 5.5 centimetres broad, and 3.5 centimetres in its antero-posterior diameter. Both the anterior and posterior surfaces of the uterus are covered by a hæmorrhagic, somewhat shaggy membrane, 2 millimetres in thickness, which, besides covering the uterus, is continued laterally over the surfaces of the tubes. This membrane can be stripped off, leaving a white, somewhat roughened surface beneath. The uterine walls average 1.5 centimetres in thickness, and are pale pink in colour. The uterine cavity is 2.5 centimetres in length; its mucosa is pale, yellowish white in colour, slightly corrugated, but smooth and glistening. Near the internal os a few dilated glands can be seen, the largest of which is 2.5 millimetres in diameter. The uterine mucosa varies from 2 to 3 millimetres in thickness.

Histological Examination.—The glands of the uterine mucosa in the vicinity of the internal os are for the most part normal; some of them, how-

* These cases were published in the *Johns Hopkins Hospital Reports*, 1895, vol. iv, p. 441. We have had twenty-one additional cases of tuberculosis of the endometrium between that time and December 1, 1899.

ever, are dilated. The epithelium of these dilated glands is cuboidal. About 1 centimetre from the fundus the surface epithelium is found to be intact; the glands are small and round on cross section, and have an intact epithelium, but the stroma just beneath the surface epithelium contains tuberculous nodules, some with, others without, giant cells. The giant cells are large, irregular in contour, and are partially filled with elongate-oval, deeply staining nuclei. Surrounding these cells are epithelioid cells, the nuclei of which are club-shaped, oval, or semi-lunar. The stroma in the vicinity of such nodules is infiltrated by lymphoid cells. The deeper portions of the mucosa are perfectly normal.

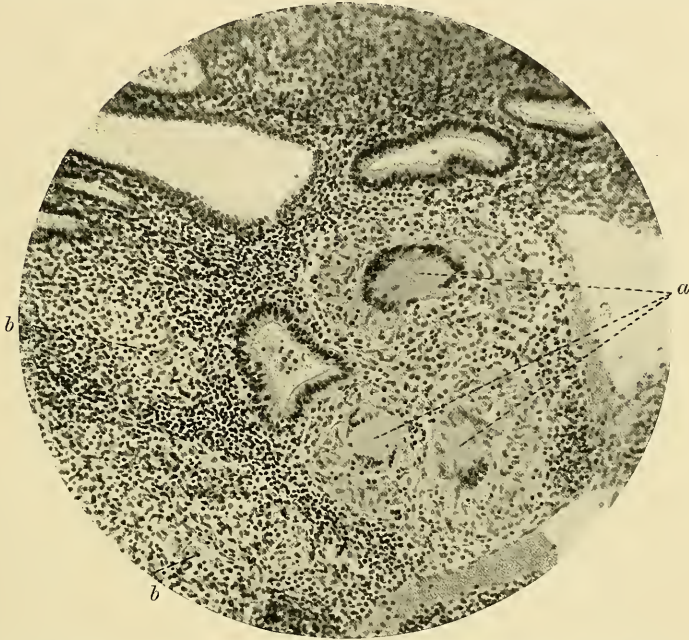


FIG. 291.—PHOTOMICROGRAPH OF A SECTION TAKEN FROM THE FUNDUS OF THE UTERUS IN CASE 3,193.
(250 diameters.)

Gyn.-Path. No. 519. Three uterine glands can be seen. These are recognised by their epithelial lining and by the cavities in their centres. The gland nearest the centre contains some desquamated epithelium. To the extreme left is a dilated gland, along one margin of which the epithelium is still faintly visible. Near the middle of the field three tubercles (*a*) can be seen. In the centre of each is a giant cell. The nuclei of these cells are arranged principally around the margin. Surrounding the giant cells are pale-staining epithelioid cells, while scattered throughout the stroma everywhere are small round cells. To the left of the centre in the stroma are two small, pale-staining areas (*b*)—clusters of epithelioid cells.

On passing a little farther upward toward the fundus a dilated gland is seen, the epithelium of which is partially intact. Where the epithelium has disappeared the walls are invaded by epithelioid cells. The cavity of this gland contains epithelioid cells, and also a giant cell. Near the fundus the process is still more advanced. The surface epithelium becomes somewhat wavy, its individual cells more cuboidal, while just beneath the surface, at these points, are delicate glands lined by cuboidal epithelium. Where the process is most advanced, the surface epithelium has disappeared, and nearly the entire thickness of the mucosa is occupied by epithelioid and lymphoid cells. Scattered throughout this newly

formed tissue are numerous large, irregular giant cells. These are most abundant along the advancing margin of the growth. There is no caseation. Tubercle bacilli can be demonstrated on the surface of the mucosa, in the lumina of the glands, and also in the giant cells. We are dealing with a tuberculosis of the

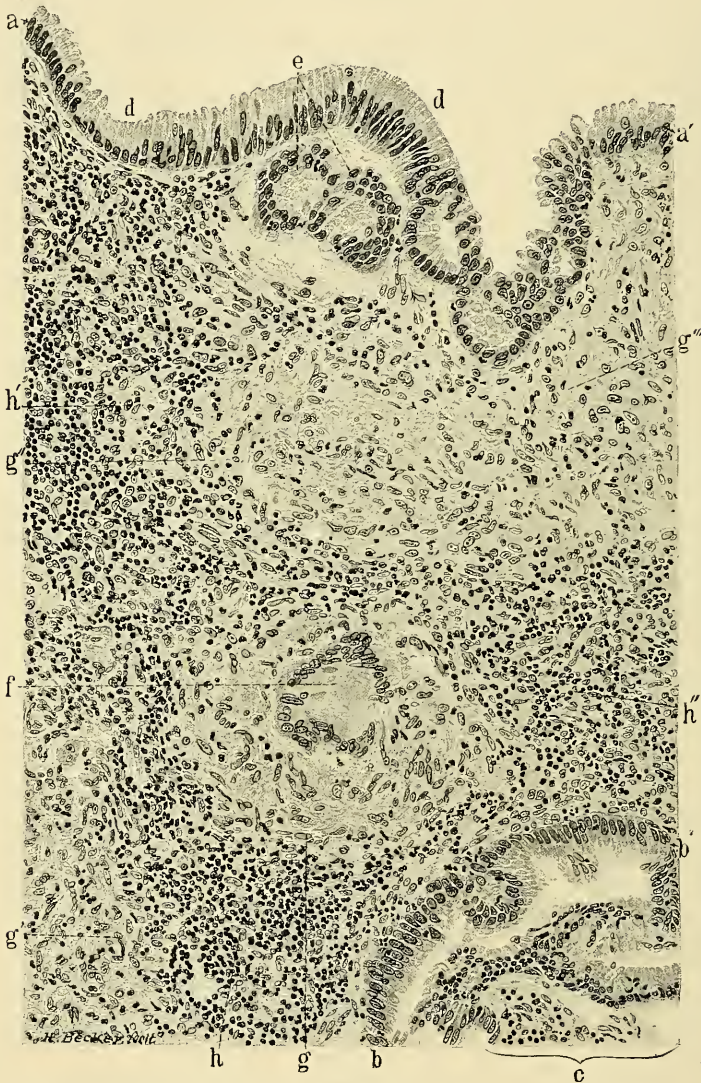

FIG. 292.—SCRAPINGS FROM A TUBERCULOUS CERVIX. (180 diameters.)

Gyn.-Path. No. 546. There is no breaking down of the cervical tissue. From *a* to *a'*, and from *b* to *b'*, are areas of surface epithelium, while at *d*, *d* the typical high cylindrical cervical epithelium is seen. The areas indicated by *e* are the bases of cervical glands. Lying in the stroma is a well-formed giant cell (*f*) with many oval and elongate-oval, vesicular nuclei, arranged irregularly around its margins. Surrounding it is the zone of epithelioid cells indicated by *g*. Other areas of epithelioid cells (tuberculous tissue) are seen at *g'*, *g''*, and *g'''*. Scattered throughout the stroma of the cervix are many small round cells, indicated by *h*, *h'*, *h''*. The portion marked off by *c* is a fragment of cervical mucosa which has become tacked on to this section. At *b* a few small round cells have wandered in between the epithelial cells.

endometrium limited to the upper half of the uterine cavity, and most pronounced at the fundus.

Gyn. No. 3,236

Tuberculosis of the endometrium, diagnosed from scrapings.

H. J., aged twenty-six; coloured. Was admitted December 11, 1894.

The patient has never had any serious illness, but has always been rather frail. Her menses commenced at sixteen, and were regular for the first three years. She was married at nineteen, but has had no children, and denies any miscarriages. For the last seven years the menses have been very irregular. At first they were profuse, and the patient passed clots of blood; at another time they ceased for one year. Her mother died of cancer of the breast; her brothers and sisters are healthy.

Present condition: The patient's general condition is good; her heart and lung sounds are negative. In one breast are a few small nodules. She has a somewhat profuse vaginal discharge, and micturition is painful. The urine is amber-coloured, acid, with a specific gravity of 1022. It contains neither sugar nor albumin. On vaginal examination, the uterus is found to be anteposed, normal in size, and freely movable.

On December 13th the small nodules of the breast were enucleated by Dr. Clark, and on microscopical examination Dr. Bloodgood found them to be fibromata. The uterine cavity was curetted at the time that the nodules were removed.

The patient was discharged on December 21st. The examination of the scrapings is as follows:

Histological Examination.—The surface of the uterine mucosa presents a wavy outline. The epithelium covering its surface is of the high cylindrical variety, and is everywhere unbroken; between the individual cells, however, are a few polymorphonuclear leucocytes. The glands are round and small on cross section, and have an intact epithelium. The stroma of the mucosa is rather dense, and with the low power numerous pale-staining areas are seen scattered throughout it. These are composed of epithelioid cells. In the centre of most of these clumps are found giant cells, which contain a large number of nuclei, arranged principally at one pole (see Fig. 292). The stroma is everywhere infiltrated by lymphoid cells. One of the tubercles contains many polynuclear leucocytes. No caseation can be seen. Tubercle bacilli are demonstrable in the giant cells.

“Asylum Patient”

Tuberculous salpingitis and caseous tuberculosis of the endometrium following tuberculous peritonitis, which apparently originated from ulcers in the ileum. There was tuberculosis of both lungs.

L. B., an inmate of an insane asylum. Autopsy by Professor Welch, February 3, 1886.

Our specimen consists of portions of the uterus and of one tube.

Histological Examination.—The piece of the cervix present is perfectly normal. The greater part of the uterine mucosa is necrotic, while scattered throughout the necrotic material are moderate numbers of polymorphonuclear leucocytes. Some of the uterine glands are visible in the depth of this necrotic material. They are moderately dilated, and have a partially intact epithelium, which is either cylindrical or cuboidal in form. Surrounding the glands is a moderate amount of stroma, which is markedly infiltrated by polymorphonuclear leucocytes, and shows considerable nuclear fragmentation. The muscular tissue, just beneath the mucosa, has here and there a very rich blood supply, while between the individual muscle fibres are large numbers of polymorphonuclear leucocytes and young connective-tissue cells. The infiltration extends about 6 millimetres into the muscle and then entirely disappears. Scattered here and there throughout the muscle, especially in the vicinity of the caseous material, are numerous giant cells, most of which are surrounded by zones of epithelioid cells. A few giant cells are seen, around which no epithelioid or lymphoid cells are found. No tubercle bacilli could be demonstrated; their absence may be due to the length of time since the specimen was obtained.

Gyn. No. 3,303

Commencing tuberculosis of the endometrium; tuberculosis of both tubes; tuberculous abscess of the left ovary.

A. M., aged thirty-three. Admitted February 1, 1895. On entrance, she complained of pain in the lower abdomen, and of frequent, prolonged, and painful menstruation.

Twelve years ago she had an attack of "pelvic inflammation," the chief signs of which were great pain and tenderness in the lower part of the abdomen. At that time she had a profuse leucorrhœa. Since this illness she has never been strong, and any exposure to cold would bring on a severe attack of pain in the lower abdomen. This was accompanied by slight fever, swelling of the abdomen, and painful defecation. Two months ago she had a severe attack, the pain being in both ovarian regions, and radiating to the lower extremities. For the last five weeks she has had constant pain in the region of the left ovary; this has been much aggravated on exertion and at the menstrual period. The patient has been married four years, but has had neither children nor miscarriages. She began to menstruate when she was twelve years of age, and was regular until two years ago, when the periods were only three weeks apart. The duration of menstruation has increased, lasting from eight to ten days. The last menstruation took place about January 15th. She has a slight, non-offensive, non-irritating leucorrhœa. Her family history is unimportant, and none of her relatives have died from tuberculosis.

The patient at present is debilitated, and appears somewhat anæmic. On vaginal examination, the uterus is found to be retroflexed and adherent; on the left side a distinct mass, about 10 centimetres in diameter, can be felt.

Operation, February 2d. Abdominal hysterectomy.

She was discharged March 5th, feeling perfectly well.

Gyn.-Path. No. 586. The uterus is $6 \times 5.5 \times 3.5$ centimetres. Anteriorly and on the fundus are a few delicate adhesions, some of which contain fat, and are apparently omental in origin. The posterior surface is practically free from adhesions. A portion of the cervical canal, 2 centimetres in length, is present. The mucosa of this is whitish in colour, smooth, and glistening. The uterine walls average 2 centimetres in thickness, and are whitish pink in colour. The uterine cavity is 3 centimetres in length, and at the fundus is 2 centimetres in breadth. The mucosa is whitish yellow, smooth, and glistening; here and there it presents a few ecchymoses. It averages 2.5 millimetres in thickness.

Histological Examination.—The epithelium covering the cervical mucosa is intact; the underlying stroma, however, shows a moderate amount of small-round-cell infiltration. The surface of the uterine mucosa is for the most part smooth and glistening, but here and there presents a wavy outline. The surface epithelium is everywhere intact, but in a few places it is somewhat swollen, and stains faintly. Between the individual epithelial cells are a moderate number of polymorphonuclear leucocytes. Here and there the surface epithelium has proliferated, and forms small finger-like projections. The glands are few in number, small and round on cross section, or slightly dilated. The gland epithelium is everywhere intact. The cavities of the dilated glands contain a moderate amount of desquamated epithelium and granular material. The stroma of the mucosa is of the usual density.

About 1 centimetre from the fundus a cluster of epithelioid cells can be seen, in the centre of which many polymorphonuclear leucocytes are visible. One or two similar nodules are seen near the fundus. These contain large giant cells in their centres. The nuclei of the giant cells are elongate-oval and vesicular, and are arranged either along the margin of the cell or are situated at one pole. It is over these nodules that the surface epithelium is swollen, and stains poorly. The stroma of the mucosa in the vicinity is very rich in small round cells. The deeper portions of the stroma are unaltered. One of the giant cells is composed of a large irregular plaque of protoplasm, throughout which are scattered at irregular intervals typical epithelioid nuclei. The appearances would suggest that the protoplasm of the different cells had coalesced, forming one large mass; the nuclei, however, appear to have been perfectly preserved.

The uterine muscle is unaltered. The interesting points in connection with the endometrium are as follows: The tuberculous changes are confined to the upper segment; the surface epithelium is everywhere intact, but stains poorly over the areas occupied by the tubercles; all the tubercles are situated in the superficial portions of the mucosa. Tubercle bacilli are to be seen scattered throughout the tuberculous areas. Both tubes show advanced tuberculosis. The left ovary is occupied by an abscess, the walls of which are composed of typical tuberculous tissue.

The tuberculosis of the endometrium is undoubtedly secondary to that of the tubes.

Autopsy 654

Anatomical diagnosis: Tuberculosis of the lymph glands, lungs, pleurae, pericardium, peritoneum, liver, spleen, kidneys, Fallopian tubes, and endometrium.

E. W., aged three; coloured. Died April 22, 1895.

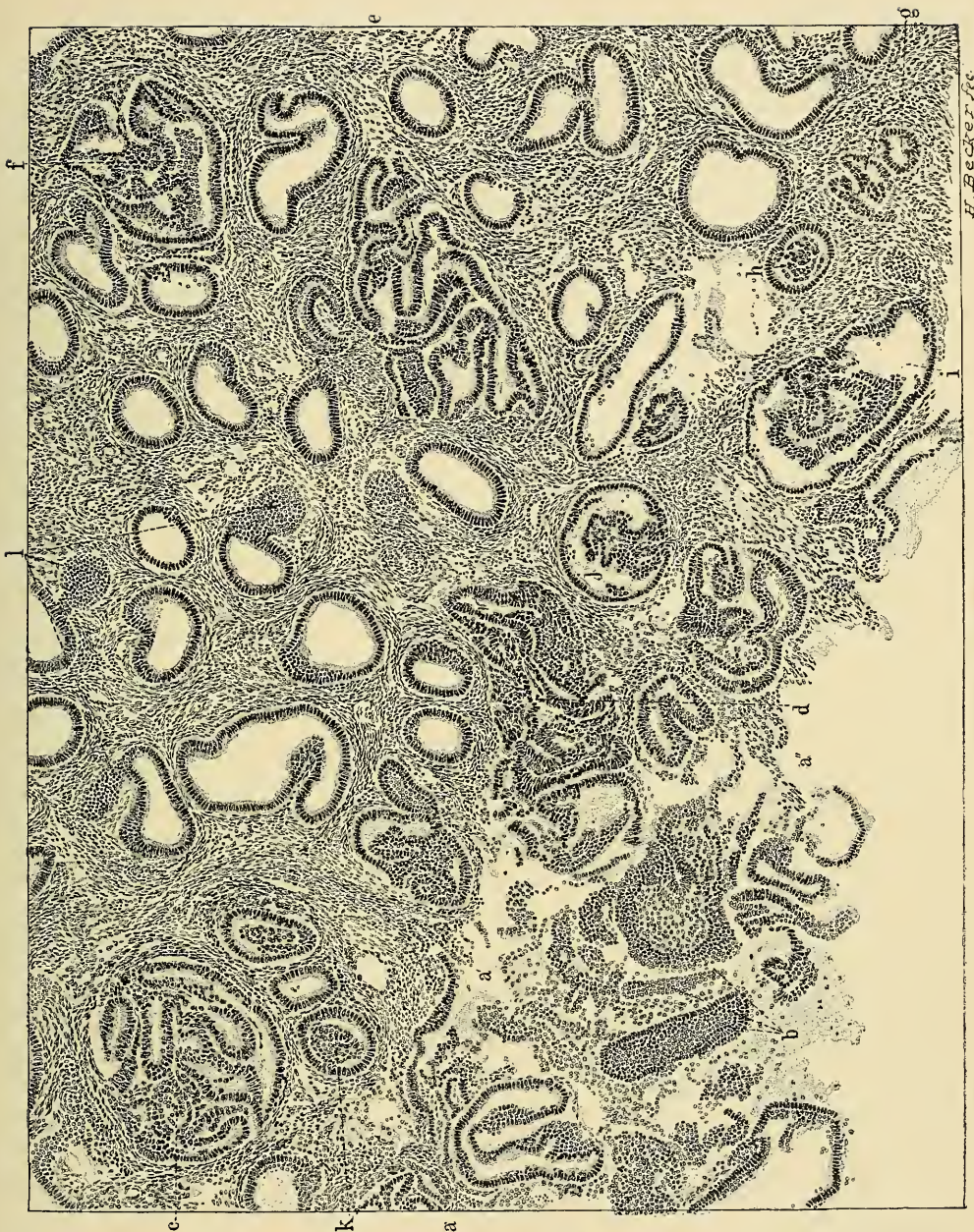A description of the generative organs is as follows:

The vaginal mucosa is transversely corrugated, is bright bluish white in colour, smooth, and glistening. The uterus is 2.3 centimetres in length, 9 millimetres in breadth, and 5 millimetres in its antero-posterior diameter. Anteriorly and posteriorly it is smooth and glistening. The cervix is 7 millimetres in diameter, and projects 6 millimetres into the vagina. The cervical lips are exceedingly delicate, in some places being not more than 2 millimetres in thickness. The cervical canal is 1.5 centimetres in length. Its mucosa is yellowish in colour, smooth, and glistening, and presents shallow longitudinal furrows. The uterine walls average 2 millimetres in thickness. The uterine cavity is 1 centimetre in length. Its mucosa is bluish white, and longitudinally furrowed. Just beneath the surface of the mucosa a few minute, pin-point, whitish-yellow dots can be seen.

Histological Examination.—The vaginal mucosa is normal. The vaginal portion of the cervix is unaltered; the cervical portion is covered by cylindrical epithelium, which conforms to the usual type. Opening on the surface of the cervical mucosa are the shallow glands, which are only slightly convoluted. The junction of the cervical with the uterine mucosa is sharply defined. The uterine mucosa near the internal os is covered by cylindrical epithelium, the nuclei of which are elongate-oval, and stain somewhat deeply. The uterine glands are few in number, but appear to be perfectly normal. On passing upward, the surface epithelium gradually disappears, and small masses of epithelioid cells are scattered throughout the stroma. Near the fundus the degenerative changes are more marked; the superficial portions of the mucosa have here and there undergone complete necrosis, and between this necrotic material and the normal stroma is a zone of epithelioid cells intermingled with small round cells. In one or two places giant cells can be made out in the epithelioid nests. The tissue, however, is characterized by the absence of giant cells. Tubercle bacilli are easily demonstrable, both in the caseous areas and also in the nests of epithelioid cells. The

FIG. 293.—A SUSPICIOUS BUT BENIGN AREA FROM A SCRAPING. (100 diameters.)

Gyn.-Path. No. 144. The portion of the section in the left lower corner, inclosed by the letters *a, a', a''*, consists of small fragments of glands that have been scraped off and distorted by the curette. These glands are lined by one layer of normal epithelium. At several points, as indicated by *b*, the epithelium has been cut obliquely, and consequently appears to be many layers in thickness; but it will be noted that the nuclei are regularly arranged and are uniform in size. The area *c* shows a complicated branching arrangement in the depth of a gland. (For similar but less complex pictures, see Fig. 20, p. 24, and Fig. 21, p. 25). Each of the projections is lined by but a single layer of cylindrical epithelium, and all the cells are uniform. *d* is a somewhat similar area cut obliquely and just along the bottom of the gland in such a way that the epithelium appears to be several layers in thickness. In *e* the convoluted gland arrangement is well marked; the epithelium is one layer in thickness and the cells are uniform in size. *f* is a projection springing from the side of a gland near its base, and corresponds very well with that shown in Fig. 21, *a* (p. 25). *g* indicates three cross sections of a small convoluted gland. *h* shows a normal gland with a little stem projecting up from the bottom; *i* is a similar but larger one. *j* is a normal gland with projections springing



H. Becker, Inc.

FIG. 293.

from its side; *k*, a normal gland with a mass of desquamated epithelium in its centre. *l* indicates areas where the gland has been cut on the bevel. The stroma of the mucosa is composed of spindle cells, containing spindle-shaped, or oval, vesicular nuclei. Here and there the stroma shows irregular losses of substance, due to tearing by the curette. The glands, as a rule, are equidistant from each other, and the epithelium everywhere is of the normal type. The only suspicious areas are *c*, *d*, *e*, and *f*. Pictures resembling these are not infrequently found in the bottoms of normal glands. The subsequent clinical history in this case showed no evidence of a malignant process.

December 28, 1899. Dr. G. S. Bonner, of Clifton Forge, Va., informs me that the patient's condition has been very good since the operation (curettage) was performed. The patient has had no hæmorrhages. Length of time since the examination of the uterine mucosa, five years and three months.

uterine muscle is not involved. It has, however, an exceptionally rich blood supply. The mucosa of both tubes has undergone almost complete caseation; in this caseous material many bacilli can be found. Both ovaries are normal.

From these appearances it is probable that the tuberculous process in the endometrium is secondary to that of the tubes, since the process is much farther advanced in the latter, and only the upper part of the uterine cavity is involved.

SUSPICIOUS SCRAPINGS

Notwithstanding the sharp lines of differentiation between adeno-carcinoma and other pathological processes in the body, there are a certain number of cases in which the scrapings present so numerous confusing pictures that only after a long period of careful study of such specimens can one feel safe in giving a positive opinion. Such a scraping is shown in Fig. 293. Here we have numerous suspicious-looking areas, and yet on careful examination the changes are found to be due to small tags of tissue distorted by the curette, to the obliquity of the sections through the epithelium, and to the small irregularly branching stems so frequently found at the bases of the glands.

For a description of deciduoma malignum see Chapter XXII.

CHAPTER XVIII

TREATMENT OF CARCINOMA OF THE BODY OF THE UTERUS

1. Vaginal hysterectomy.
2. Abdominal hysterectomy.
3. Removal of the lymph glands.

THE operative cases in our series have been divided into two main groups: those in which vaginal hysterectomy was performed, and those in which the abdominal route was adopted. It must be borne in mind that these cases extend over a period of between six and seven years, during which time such rapid strides in the operative technique have been made that many of the descriptions will be of merely historic interest.

VAGINAL HYSTERECTOMY

In those cases in which vaginal hysterectomy was performed it was customary to curette the uterus and then sew the cervical lips together. Occasionally, as a preliminary procedure, it was found necessary to incise the perinæum to allow of the required space for operation. This step was adopted in Case 2,817 (p. 390), that of Dr. Eccles's patient (p. 386), and Case 2,436 (p. 361). In the last case the perinæum was immediately repaired, but broke down slightly on the eighth day. During the spring of 1897, Case 4,746 entered the hospital, and on examination of the scrapings, adeno-carcinoma of the body was diagnosed. The uterus was removed *per vaginam*, and as there was an old complete tear of the perinæum, it was deemed advisable to repair it at the same time. The wound broke down to a considerable extent, but fortunately granulated up nicely, no fistula being left. It can hardly be a matter of surprise when the tissues do not heal kindly, since there is always great danger of infection from the sloughing and carcinomatous tissue, which renders a thorough cleansing and the maintenance of an aseptic field practically impossible. A much greater danger—the transplantation of particles of carcinomatous tissue into incisions in the perinæum—has been treated of by Hahn,* Winter,† Schopf, ‡ Leopold,§ and Hofmeier. || The point is dealt with at length in Chapters VIII and XXVII.

* Hahn, E. *Ueber Transplantation von carcinomatöser Haut.* *Berl. klin. Wochenschr.*, 1888, Bd. xxv, S. 413.

† Winter, G. *Ueber die Recidive des Uteruskrebses, insbesondere über Imprecidive.* *Zeitschr. f. Geburtsh. u. Gynäk.*, 1893, Bd. xxvii, S. 101.

‡ Schopf, F. *Uebertragung von Carcinom auf frische Wunden in einem Falle von vaginaler Totalexstirpation des Uterus.* *Wien. klin. Wochenschr.*, 1891, Bd. iv, S. 840.

§ Leopold, G. *Arbeiten aus der königl. Frauenklinik*, Leipzig, 1895, Bd. ii, S. 203.

|| Hofmeier, M. *Zur Anatomie und Therapie des Carcinoma corporis uteri.* *Zeitschr. f. Geburtsh. u. Gynäk.*, 1895, Bd. xxxii, S. 171.

In Case 2,817 (p. 390), while traction was being made on the cervix, it tore off, and abdominal hysterectomy had to be resorted to.

ABDOMINAL HYSTERECTOMY

In the majority of those cases in which the abdomen was opened the uterus was amputated at the cervix, as in Gyn.-Path. No. 780 (p. 383), Gyn. Nos. 2,832 (p. 371), and 3,258 (p. 375). With our present insight into the histological changes we should not now be satisfied to leave any portion of the uterus.

In cases of squamous-cell carcinoma and adeno-carcinoma of the cervix we found that the chief difficulty to contend with was supplied by the lateral extension of the growth, which often rendered an entire enucleation impossible, not only on account of the close proximity of the cervix to the pelvic wall, but because the ureters were so often implicated. In adeno-carcinoma of the body, the cervix is not fixed, and the uterus can therefore be drawn partially out of the pelvis. Again, even should the growth penetrate the entire thickness of the uterus, it has a long distance to travel before it reaches the pelvic wall or encroaches upon the ureters. A third advantage of great value is that the operator can at all times see what he is doing, since he is not obliged to work so deep in the pelvis. It is thus readily seen that the removal of the uterus by the abdominal route is much easier in adeno-carcinoma of the body than in carcinoma of the cervix.

As one unpleasant feature, it may be noted that, where the growth has eaten almost entirely through the uterus, as in Case 2,817 (p. 390), the top may tear off during the enucleation. Such an accident, however, is equally likely to occur during vaginal hysterectomy.

The operation best suited to these cases is an abdominal hysterectomy, the entire uterus being removed with its appendages intact. Preparatory to the operation it will greatly facilitate matters to catheterize the ureters, but this precaution is not so imperative as in carcinoma of the cervix.

The aim of the conscientious operator is to avoid castration whenever possible; hence, in the majority of hysteromyomectomies the ovaries are left *in situ*, and from the statistics thus far gained the conservatism has been rewarded by the partial or complete absence of the unpleasant sequelæ, so common after removal of the appendages.

In cases of carcinoma I would nevertheless strongly advise in all instances the removal of the tubes and ovaries with the uterus, since it has been shown that in some of our cases, although the disease was apparently in a very early stage, the appendages were nevertheless involved. Both Löhlein* and Reichel† have called attention to the secondary involvement of the ovaries, and advise their removal with the uterus.

* Löhlein. *Demonstration eines Carcinoma corporis uteri bei gleichzeitigem Carcinom beider Ovarien.* Deutsche med. Wochenschr., 1889, Bd. xv, S. 502.

† Reichel, P. *Ueber das gleichzeitige Vorkommen von Carcinom des Uteruskörpers und des Eierstockes.* Zeitschr. f. Geburtsh. u. Gynäk., 1888, Bd. xv, S. 354.

Removal of the Glands.—In Chapter II we learned that the lumbar glands are those most likely to be affected in adeno-carcinoma of the body. Nevertheless, they are rarely implicated in otherwise operable cases, and I know of no attempt having been made to remove them. Doubtless, however, the time is coming when they will also be removed in suspicious cases. The iliac glands should always be inspected, because, if the carcinomatous process has commenced near the internal os, as in Case Gyn.-Path. Nos. 1,412 and 1,414 (p. 424), or if the growth has involved the cervix secondarily, they may contain metastases.

As was also pointed out in Chapter II, the lymphatics from the uterine horn and its immediate vicinity merge into a lymph channel that passes down along the round ligament to the inguinal glands. Thus, if the carcinoma extends to the uterine horn, secondary growths may be found in the inguinal lymph glands.

In this connection it will be well to remember that adeno-myoma of the round ligament may occasionally, on account of its position, be mistaken for an enlarged lymph gland. In June, 1896, I reported* the first case of this character that had been observed. The patient was thirty-seven years of age, and had been married thirteen years. Eight years previous to admission she first noticed a slight swelling in the right inguinal region, which during the last two years had increased in size. It was somewhat painful, especially after exertion and during

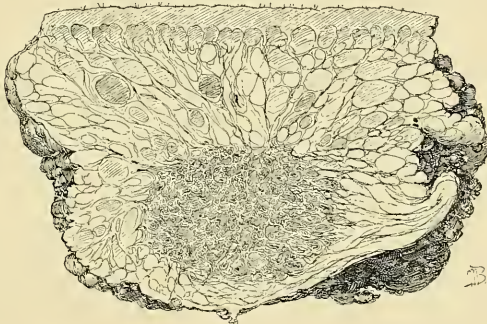


FIG. 294.—ADENO-MYOMA OF THE ROUND LIGAMENT. (Natural size.)

Gyn.-Path. No. 928. The figure represents a longitudinal section of the tissue removed. The greater part consists of fat, and the surface is covered by skin. Occupying the lower part is an oval area, dark in colour, and composed of fibres running in all directions—the myoma. Passing off from it are numerous strands, which merge into the adipose tissue. The small dark areas in the myoma represent dilated gland cavities. The large and small dark masses in the adipose tissue are hæmorrhages. For the histological picture of the adeno-myoma, see Fig. 295.

the menstrual period. An oval incision having been made, and the nodule freed laterally and posteriorly, it was found to be intimately adherent above to the right round ligament. Several enlarged lymph glands were also removed and the cavity was closed. The round nodule (Gyn.-Path. No. 928; see Fig. 294) measured $3.5 \times 3 \times 2$ centimetres, and was embedded in a quantity of fat. On section, it was found to be composed of an interlacing bundle of fibres forming a dense network, while scattered throughout the nodule were many small, pale,

* Cullen, Thomas S. *Adeno-myoma of the Round Ligament*. *Johns Hopkins Hospital Bulletin*, 1896, vol. vii, p. 112.

translucent, homogeneous areas, some of which contained round, oval, or irregular spaces. On histological examination the growth proved to be a myoma; the translucent areas consisted of a mucosa composed of glands and a stroma identical with that of the normal uterine mucosa (Fig. 295).

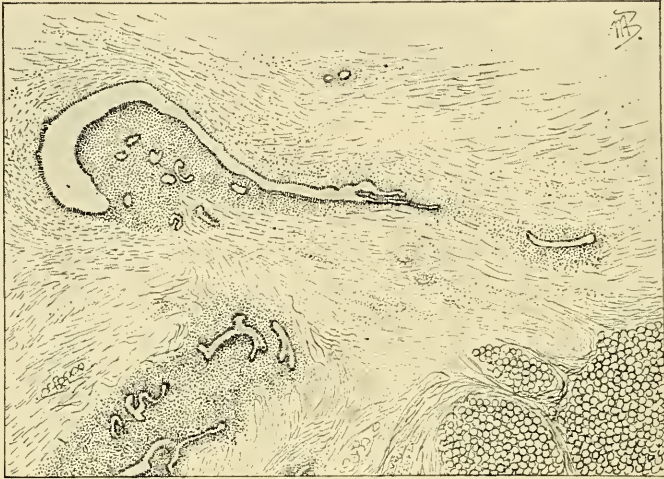

FIG. 295.—ADENO-MYOMA OF THE ROUND LIGAMENT. (16 diameters.)

Gyn.-Path. No. 928. The section is taken from the oval nodule in Fig. 294. The framework consists of non-striped muscle fibres cut chiefly longitudinally. Scattered throughout the muscle are glands, which may occur singly or in groups. They are round, oval, or irregular, and show some branching. All are lined by one layer of cylindrical epithelium, and even the smaller ones are surrounded by a definite stroma, which with the high power is seen to be identical with that of the uterine mucosa. In the right lower corner is adipose tissue. A few stray fat cells are found in the myoma. This growth bears no resemblance to adeno-carcinoma.

In May, 1897, I removed a similar nodule from the left side, the same variety of gland being found on histological examination. Similar growths have since been reported by Pfannenstiel,* Blumer,† and others. As seen from the description, these nodules are hard and dense, therein differing from carcinomatous metastases, which are usually soft in some part, and lighter in colour, contrasting sharply with the lymphoid tissue. On histological examination, there is, of course, no resemblance whatsoever.‡

Vaginal hysterectomy is to be avoided where possible, being reserved for patients with very thick abdominal walls, in whom an abdominal operation would

* Pfannenstiel. *Ueber die Adenomyome des Genitalstranges. Verhandlungen der deutschen Gesellschaft f. Gynäk.*, 1897, S. 195.

† Blumer, George. *A Case of Adeno-myoma of the Round Ligament. Amer. Jour. Obstet.*, 1898, Bd. xxxvii, p. 37.

‡ A small adeno-myoma may occasionally be found lying free in the broad ligament. Dr. W. G. MacCallum recently called my attention to such a nodule, which was not more than 2 millimetres in diameter. On histological examination, it presented a picture similar to that seen in Fig. 295. It is never safe to make a positive diagnosis of a metastatic growth until the supposition has been verified by histological examination.

be fraught with much difficulty, for elderly persons that cannot stand a prolonged operation, or for very weak individuals.

The chief disadvantages of this operation are :

1. The operator has no accurate idea how far the growth has extended—a point at times not thoroughly recognised even when the abdomen is first opened.

2. The chief steps of the operation are taken in the dark, many of the ligatures being placed by touch.

3. By the vaginal route it is impossible to inspect or to remove the iliac or lumbar glands.

For the preparatory treatment of the patient, the catheterization of the ureters, the technique of vaginal and abdominal hysterectomy, the complications occurring during and after operation, and the after-treatment, the reader is referred to Chapter VIII, in which these points are dealt with *in extenso*. The palliative treatment is also fully discussed in the same chapter.

CHAPTER XIX

PRIMARY SQUAMOUS-CELL CARCINOMA OF THE BODY OF THE UTERUS

SQUAMOUS EPITHELIUM IN THE BODY OF THE UTERUS

IN 1885 Zeller* reported the results of his examinations of the uterine mucosa in sixty-three cases of endometritis. In every variety of chronic endometritis he claims that the cylindrical epithelium of the body may produce several layers of squamous epithelium, the deepest being cylindrical. In many of his cases, previous to curettage, applications of soda, carbolic acid, or sublimate, had been made to the uterine cavity. His descriptions of the histological changes found in the mucosa are by no means convincing, and subsequent writers have expressed much hesitancy in accepting Zeller's view that such a change is so frequently found.

Von Rosthorn,† in 1894, reported a case of hornification of the uterine mucosa. The patient was forty-one years of age, and had had six normal labours and two abortions; after the last abortion, which had occurred three and a half years before admission, the membranes were curetted away. Her menses became profuse, and it was found necessary to curette a second time. On admission, the flow was very copious, and the body of the uterus was slightly enlarged. Curettings showed that the surface of the uterine mucosa was covered by squamous epithelium. The uterus was removed eight days later, and sections, made from all portions, showed that the mucosa was still intact, being covered by several layers of squamous epithelium. In the depth, where cell-nests were found, the marginal cells were cuboidal in form, while the central portions of the nest consisted of large cell elements. The cell bodies were large, and the nuclei were oval and sharply defined. Where this process was more advanced, the surface epithelium showed a horny change, the cells being devoid of nuclei. This horny layer sent large finger-like projections into the depth, and in the deeper portions were epithelial pearls resembling those found in squamous-cell carcinoma. Nuclear figures in all stages were very abundant, especially in the finger-like down-growths. The glands were few in number; their epithelium was of the cuboidal type.

Von Rosthorn was not sure that the growth was in reality a carcinoma, although there was a typical squamous epithelial lining of the uterine cavity.

* Zeller, A. *Plattenepithel im Uterus (Psoriasis uterina)*. *Zeitschr. f. Geburtsh. u. Gynäk.*, 1885, Bd. xi, S. 56.

† von Rosthorn, A. *Ueber Schleimhautverhornung der Gebärmutter*. *Festschr. zur Feier des fünfzigjährigen Jubiläums der Gesellschaft für Geburtsh. u. Gynäk.*, Wien, 1894, S. 319.

Ries, in 1896, in speaking of a condition which he terms "ichthyosis uteri,"* reports the case of an inverted uterus, in which, on making a section through the mucosa, he found it covered by squamous epithelium. The deepest layer was cylindrical; next came several layers of cells, some of which were prickle cells, while resting on these were one or more layers of flat cells, all of which contained nuclei. Ries, in an examination of over two hundred uterine scrapings, found the condition described by Zeller only in one instance; in this case there was also a coexistent carcinoma of the cervix.

For over six years the uterine mucosa has been examined in all cases in which the organ has been removed or scrapings have been made. In only nine out of fifty instances have I found a thickening of the surface epithelium resembling squamous epithelium. In all there was an endometritis varying in degree. It can, I think, be safely said that it is most exceptional to find a thickening of the surface epithelium, except in association with endometritis. Judging from our experience, about 20 per cent of the cases of endometritis show thickenings resembling squamous epithelium. These nine cases are reported in detail in Chapter XVII. The thickening of the surface epithelium may be localized and sharply circumscribed, as is seen in Fig. 278 (p. 530) and Fig. 276 (p. 528); or it may be more diffuse and penetrate the stroma of the mucosa, as is well shown in Fig. 275 (p. 526). In only one instance have we found a localized thickening of the gland epithelium resembling squamous epithelium (see Fig. 277, p. 529).

PRIMARY SQUAMOUS-CELL CARCINOMA OF THE BODY OF THE UTERUS

This is of very rare occurrence, only a few cases being recorded in the literature, the majority of which I have collected. Of these quite a number are doubtful, and will be discussed after the authentic cases have been reviewed. It has not been our good fortune to see a case of this variety.

Carl Gebhard,† in a paper published in 1892, dealt with the varieties of carcinoma arising from the epithelium lining the uterine cavity, and with squamous-cell carcinoma of the body of the uterus. He cited the case of a woman, sixty-six years of age, who for thirty years had suffered with prolapsus of the vagina. Scrapings from the uterine cavity gave the usual picture of squamous-cell carcinoma, while, to clinch matters, typical epithelial pearls were found. Hysterectomy was performed. The walls were thick, and on examination of the uterine cavity, its anterior surface, as well as the fundus, were found to be furrowed and covered by white, crumbly, rather dry tumour masses, which in places penetrated the uterus for 1 centimetre. The advancing margin of the growth was convex and sharply defined. The mucosa over the posterior wall was finely granular, resembling an abscess membrane. There was stenosis at the internal os, and pyometra had apparently resulted. The cervix proper was perfectly normal.

* Ries, E. *Ichthyosis Uteri*. *Amer. Gyn. and Obst. Jour.*, 1896, p. 184, vol. viii.

† Gebhard, C. *Ueber die vom Oberflächenepithel ausgehenden Carcinomformen des Uteruskörpers sowie über den Hornkrebs des Cavum uteri*. *Zeitschr. f. Geburtsh. u. Gynäk.*, 1892, Bd. xxiv, S. 1.

Histological examination of the growth substantiated the diagnosis made from the scrapings. The stroma of the growth was scanty in amount, and the epithelial nests, some large, others small, frequently communicated with one another. The cells varied considerably in size and shape, and in the outermost layer, which formed the margin of the nest, were smaller than those in the more central portions. Pearls were found in the centres of cell-nests.

The case was certainly one of primary squamous-cell carcinoma of the body of the uterus.

Kaufmann* published another case in 1894, which, however, was associated with adeno-carcinoma of the body. The patient was sixty-four years old, and for over six years had been suffering from uterine hæmorrhages. On histological examination, it was possible to make out two distinct processes: the characteristic growth of the adeno-carcinoma, and an independent squamous epithelial growth. In places the epithelial pearls could be seen projecting like tongues into the lumina of the carcinomatous glands.

Flaischlen,† in 1895, reported the case of a woman, fifty-four years of age, who had ceased to menstruate several years previously. On admission, the uterus was curetted and squamous-cell carcinoma of the body was diagnosed. On examination of the organ after removal, the growth was found situated in the anterior wall. The posterior wall showed no evidence of a neoplasm; the cervix was intact. On histological examination, the tumour was seen to extend from the lower part of the cavity to about the middle of the body. The surface of the growth was covered by thick squamous epithelium, which sent into the depths prolongations, some of which showed a certain degree of degeneration in their central portions, while numbers contained epithelial pearls. The intervening tissue was markedly infiltrated with small round cells. In the middle of the anterior wall the growth had penetrated almost to the peritoneal surface. The mucosa covering the posterior wall consisted of a granulating surface attached to which were pus cells. This condition had evidently been caused by the pyometra, which was noted on opening the uterus. Beneath this granulating surface were a few uterine glands, the majority of which were dilated. They did not appear in any way connected with the squamous epithelium, but seemed to have played an entirely passive rôle.

Both from the description and also the illustrations one sees that the case was undoubtedly one of primary squamous-cell carcinoma of the body of the uterus.

Among the doubtful instances are those of Piering, Emanuel, Hofmeier, and Gellhorn. Piering‡ published his case in 1887. The patient was fifty-four years of age. The lower part of the cervix was firm, as if from cicatricial tissue; on the posterior lip were several nodules as large as peas. In the anterior uterine wall was a globular tumour, involving the mucosa and a large part of the muscle; beneath it was a second tumour about the size of a hazel-nut, while just

* Kaufmann. *Eine eigenartige Form carcinomatöser Entartung des Endometrium corporis. Jahresbericht der schlesischen Gesellschaft für vaterländische Cultur.* Jahrg. 72, 1894, S. 52.

† Flaischlen, N. *Ueber den primären Hornkrebs des Corpus uteri.* *Zeitschr. f. Geburtsh. u. Gynäk.*, 1895, Bd. xxxii, S. 347.

‡ Piering, O. *Ueber einen Fall von atypischer Carcinombildung im Uterus.* *Zeitschr. f. Heilk.*, 1887, Bd. viii, S. 335.

above the internal os appeared a small dense prominence, similar in character. On histological examination the cervical growth proved to be a squamous-cell carcinoma. The nodules found in the body of the uterus were also of the same type; they contained epithelial pearls. At no point in the cavity was the characteristic epithelium demonstrable, having been replaced by that of the squamous variety. Piering thinks that the growth in the body of the uterus was more advanced than that in the cervix; he concluded that the process was primary in the body, the cervix being secondarily involved.

From the description of the case, however, it would rather appear that the growth began in the cervix. It must be remembered that it is by no means necessary that the primary growth be larger than the secondary one. Take, for example, a cancer of the pyloric end of the stomach with secondary growths in the liver; here the secondary growth is often many times larger than the parent tumour. Gebhard likewise thinks that the growth in Piering's case was primary in the cervix.

Emanuel,* in 1895, carefully described the case of a woman, forty-four years of age. Clinically, carcinoma of the cervix was diagnosed, but on examination of scrapings squamous-cell carcinoma of the body was demonstrable. The uterus was somewhat enlarged; the external os was intact, but the cervix presented a crater-like appearance, and when the uterus was opened the neoplasm was found to be continuous with that occupying the body. No internal os could be made out. The mucosa of the uterine cavity presented a peculiar whitish, dull, glistening appearance, which at once led Emanuel to think that a squamous epithelial growth existed in the body. The surface was everywhere studded with smaller and larger elevations. On histological examination, although the squamous epithelium covering the vaginal portion showed no loss of continuity, the cervix was the seat of a typical squamous-cell carcinoma. In the uterine cavity no trace of cylindrical epithelium or of glands could be found, but the surface was everywhere covered by a thick layer of squamous epithelium, which in most places had penetrated into the depth in the form of long processes. Epithelial pearls were everywhere visible. In the posterior uterine wall the growth had reached almost to the peritoneal surface. Emanuel believed that the growth originated in the body for the following reasons: (1) The diffuse and regular spreading out of the disease in the body. (2) The involvement of the deeper layers of the uterine muscle as far as the peritoneal surface. (3) The likelihood that secondary carcinoma of the cervix may follow a carcinoma of the body.

In this case direct continuity between the growth in the cervix and that in the body could be demonstrated, and the only question to be decided concerns the site of origin. We know from the work of Ruge and Veit, and from our own observations, that, although the squamous epithelium usually ends at or near the external os, it not infrequently extends for a varying distance up the cervical canal, sometimes reaching even as high as the internal os. Emanuel's case can be very readily explained in this way, as a considerable portion of the growth was below the internal os. In Case 3,698 (Fig. 106) of our series the growth had

* Emanuel. *Ueber einen weiteren Fall von Hornkrebs des Uteruskörpers*. *Zeitschr. f. Geburtsh. u. Gynäk.*, 1895, Bd. xxxii, S. 477.

sprung from the cervix, between the external and internal os, and at the time of operation had not gone beyond the external os. On macroscopical examination, one would have instantly said that from its location the growth was an adenocarcinoma, but the histological picture was typical of squamous-cell carcinoma.

The patient, whose case was reported by Gellhorn* in 1897, was fifty-eight years of age. She had been pregnant five times, and had ceased to menstruate at fifty. In 1894 she suffered with slight hæmorrhages, which, however, ceased for a time. Just before admission they returned with increased severity, but the patient was in no way incapacitated for work. From an examination of the scrapings, squamous-cell carcinoma of the body was diagnosed. From Gellhorn's drawings it is seen that the growth occupied the upper half of the cervix and the lower third of the uterine cavity. Sections from the uterus gave appearances characteristic of a squamous-cell growth, and pearls were demonstrated.

This case is open to the same objection as Emanuel's, inasmuch as the growth occupied part of the cervix, and may have started there instead of in the body.†

Hofmeier, ‡ in 1895, reported the case of a woman, fifty-four years of age, who gave a history of carcinoma; on examination of portions of the cervix, adenocarcinoma of the cervix was diagnosed. The uterus was 11 centimetres in length, and the mucous membrane lining the upper part of the uterine cavity was covered by "villi" to within 2.5 centimetres of the internal os. Between this growth and the part of the cervix whence the piece had been cut out the mucosa was somewhat thickened, but otherwise normal. The growth in the body in its upper portion was composed almost entirely of cells, in which no distinct structure or connective-tissue arrangement could be made out. In the deeper portions and in some places between the muscle fibres the typical picture of adeno-carcinoma was presented. Toward the lower part the new growth gradually merged into normal mucosa; nevertheless, the entire surface over a wide area was covered by several layers of flat epithelium, which in part had penetrated the underlying tissue in solid masses. In several places hornification was noted.

Hofmeier's description of the case is not sufficient to convince one that a squamous-cell growth existed. Not infrequently, as is illustrated in Fig. 199 (p. 381), the epithelium near the surface in cases of adeno-carcinoma proliferates, and large masses of cells are formed, showing no definite arrangement and no intervening stroma, while at other points the gland cavities become obliterated, and solid prolongations appear to be penetrating into the depth (Fig. 165, p. 321). The illustration accompanying Hofmeier's paper represents a picture very often noted in adeno-carcinoma, and is even less convincing than the description of the case.

From the foregoing it is seen that there are on record at least three cases—those of Gebhard, Kaufmann, and Flaischlen—in which primary squamous-cell

* Gellhorn, G. *Zur Casuistik der Hornkrebs des Gebärmutterkörpers*. *Zeitschr. f. Geburtsh. u. Gynäk.*, 1897, Bd. xxxvi, S. 430.

† Since writing the above I have had the pleasure of a visit from Dr. Gellhorn. After a thorough discussion of his case, he still firmly believes that the growth was primary in the uterine cavity.

‡ Hofmeier, M. *Zur Anatomie und Therapie des Carcinoma corporis uteri*. *Zeitschr. f. Geburtsh. u. Gynäk.*, 1895, Bd. xxxii, S. 171.

carcinoma of the body of the uterus existed. Löhlein* reports a case diagnosed from scrapings, but as no operation was allowed, further details could not be obtained.

The ages of the patients were fifty-four, sixty-four, and sixty-six respectively, showing that the disease manifested itself long after the menopause.

On macroscopic examination of the specimens, as was noted, besides the uneven surface, the mucosa presented a peculiar whitish and crumbly appearance, instantly reminding one of squamous epithelium. Histologically, the main features of the picture were identical with those found in squamous-cell carcinoma of the cervix. (See Chapter IV.)

To this chapter is appended the following case of squamous-cell carcinoma of the cervix, in which the growth manifested a greater tendency to extend over the inner surface of the uterine cavity than to invade the underlying muscle.

Gyn. No. 4,489

Squamous-cell carcinoma of the cervix with extension to the body of the uterus (Fig. 296). Thickening of the vaginal mucosa (Fig. 297). Squamous epithelium lining the uterine cavity (Fig. 298). Hysterectomy. The patient is well, three and a half years after operation.

G., aged sixty-five. Admitted July 1, 1896.

Operation. Pan-hysterectomy.

Gyn.-Path. No. 1,244. The specimen consists of the uterus with its appendages intact, together with a cuff of vaginal mucosa (Fig. 296). The uterus measures $8 \times 5 \times 3$ centimetres, and is free from adhesions. The cervix is enlarged, indurated, and measures 4 centimetres in diameter. Its lips are flush with the vaginal vault, and are infiltrated by a new growth, which presents an ulcerated surface, and has thickened, elevated margins. The vaginal mucosa, especially on the left side, is also altered. It is fully three times the normal thickness, and is slightly granular in appearance. This thickening extends fully 3 centimetres beyond the cervix. The line of advancement is sharply defined, and the mucosa of the thickened area is darker in colour. When the uterus is opened, the entire cervix and the lower part of the body are found to be invaded by the new growth. The inner surface, corresponding to the wall of the cervical canal, presents an eaten-out appearance, while projecting into the canal are several polypoid masses, averaging 6 millimetres in length and about 2 millimetres in breadth. The growth, on section, presents a porous appearance, extends laterally almost to the cut surface, and is sharply outlined from the surrounding muscle. Upward the process has extended to within 2 centimetres of the fundus. Here the advancing margin is elevated, and consists of delicate threads. There are one or two localized thickenings springing directly from the fundus. These also look like portions of the new growth. The appendages offer nothing of interest.

* Löhlein. *Gynäk. Tagesfragen*, Wiesbaden, 1893, S. 173.

Histological Examination.—A section embracing the normal vaginal mucosa, and extending to the cervix, shows very distinctly where the thickening commences. Up to this point the vaginal mucous membrane is perfectly normal, but here it becomes fully five times the normal thickness. The papillæ are elongated, and project above the surface (Fig. 297). The deep cylindrical layer of cells is not so well defined. The nuclei of nearly all the cells are swollen and stain deeply; numerous nuclear

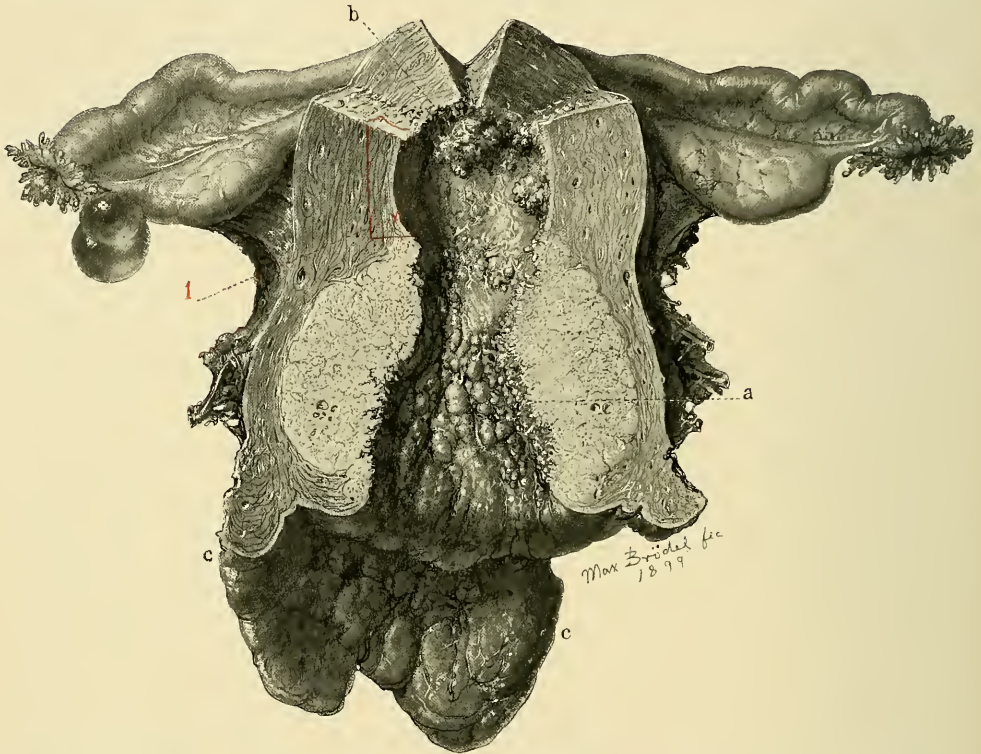


FIG. 296.—SQUAMOUS-CELL CARCINOMA OF THE CERVIX WITH EXTENSION TO THE BODY OF THE UTERUS. (5/6 natural size.)

Gyn.-Path. No. 1,244. The uterus has been opened posteriorly, the ovaries being seen in front. The cervix is considerably thickened, but intact. The mucosa lining the cervical canal anteriorly presents an uneven and nodular appearance; posteriorly, it is covered by delicate finger-like outgrowths (*a*). The cervical walls and the lower part of the body of the uterus are occupied by a neoplasm, divided up into smaller areas by delicate trabeculae. The growth is sharply defined, and has invaded the uterine walls to a depth of more than 1 centimetre. The mucosa in the upper part of the uterine cavity in some places appears normal, but springing from the fundus (*b*), and also from the sides, are small tumour growths. Attached to the cervix is a cuff of vaginal mucosa (*c*). The appendages on both sides appear to be normal, but at the fimbriated end of the left tube are two delicate-walled cysts. From point 1 Fig. 298 is taken.

figures are to be seen. The cells in the superficial layers have undergone hornification, and in some places necrosis. In this layer are quite a number of polymorphonuclear leucocytes. On passing still farther upward, the papillæ are seen to be longer, while the epithelial cells in the sulci extend more deeply into the underlying tissue. A few cross sections of these processes, penetrating inward, are seen lying free in the stroma.

The growth in the cervix is a typical squamous-cell carcinoma. Laterally it has extended to the cut surface, and portions appear to have been left behind. Upward it has involved the whole uterine cavity. The chief point of interest is

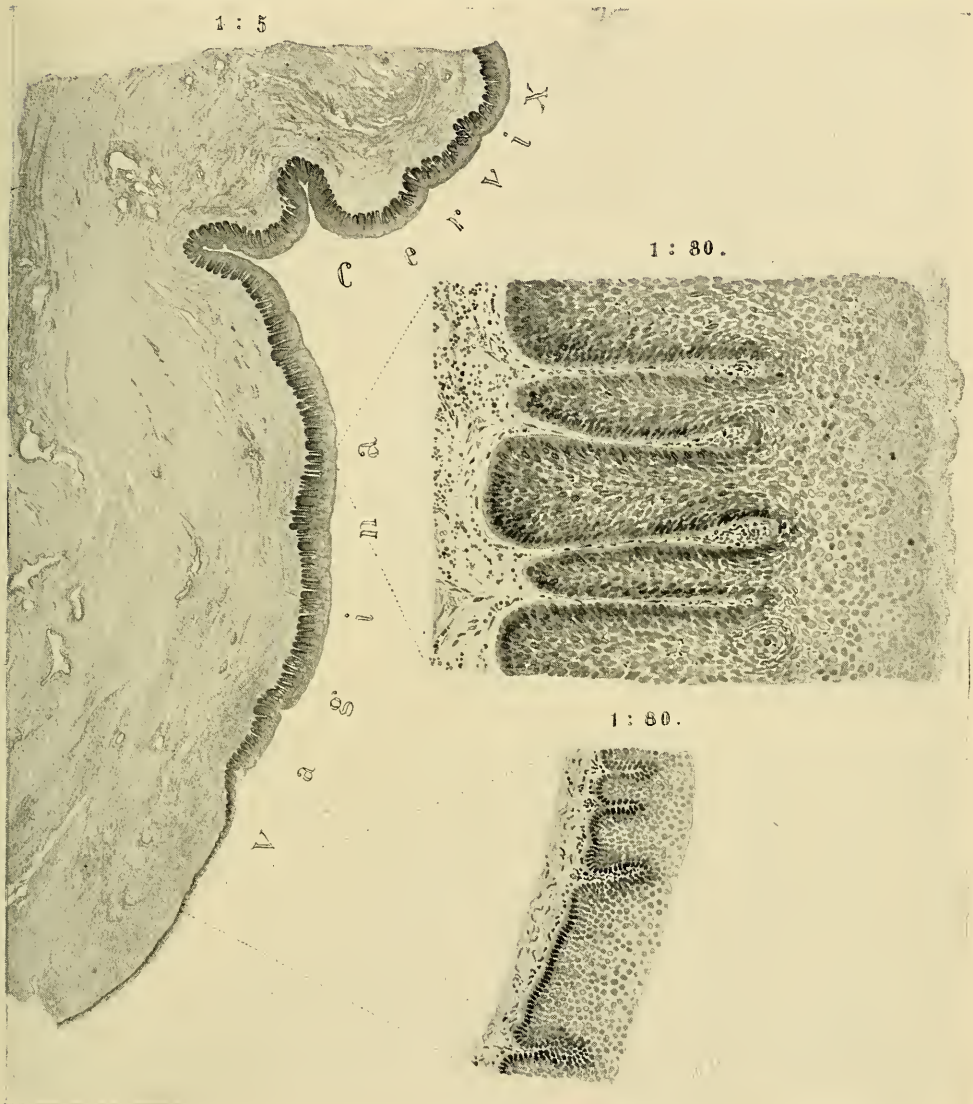


FIG. 297.—THICKENING OF THE VAGINAL EPITHELIUM IN THE NEIGHBOURHOOD OF A SQUAMOUS-CELL CARCINOMA.

Gyn.-Path. No. 1,244. On the left is a portion of the cervix magnified five times. In the lower portion the mucosa is of the normal thickness, but it suddenly becomes fully three or four times as thick, and the papillae are greatly lengthened. On referring to the figures on the right, where the mucosa is magnified eighty times, we see that the lower portion is unaltered, while in the thickened area the papillae are greatly lengthened, are relatively more slender, and have clubbed extremities. The epithelial cells are more closely packed, somewhat swollen, but still uniform. The surface has undergone necrosis. This alteration is very instructive, but in no way indicates the presence of a malignant growth. As we have seen, a similar change may occur (Fig. 95, p. 186) in cases of simple hypertrophy of the cervix. (After H. A. KELLY.)

the way in which the uterine mucosa is implicated. In the body of the uterus, just as in the vagina, there exists a growth on the surface, showing but little tendency to invade the deeper portions. The surface of the uterine mucosa is covered by many layers of cells from the new growth, but there is no tendency to invade the underlying tissue (Fig. 298). In other words, the carcinoma has formed a superficial lining for the uterine cavity. The cells form a coat varying from ten to fifty or more layers in thickness. Their nuclei are usually oval, and stain diffusely; a few contain nuclear figures. In the superficial layers there occasionally occur large masses of protoplasm, containing large, laminated,

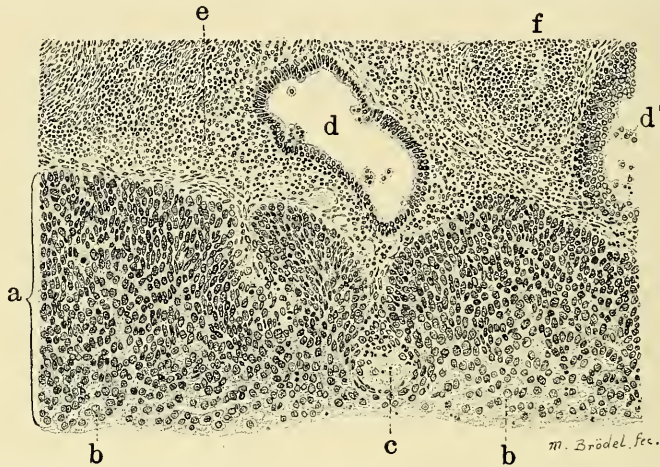


FIG. 298.—EXTENSION OF A SQUAMOUS-CELL CARCINOMA OF THE CERVIX ALONG THE SURFACE OF THE ENDOMETRIUM IN THE BODY OF THE UTERUS. (100 DIAMETERS.)

Gyn.-Path. No. 1,244. The section is taken from Fig. 296 at point *l*. *a* indicates the thickness of the surface epithelium within 1.5 centimetres of the fundus. The epithelium is many layers in thickness. The cells near the surface, especially at points indicated by *b*, cannot be distinguished from those of the squamous variety. The nuclei of all the epithelial cells show marked uniformity in size and staining properties. At two points delicate stems of stroma pass toward the surface between the epithelial cells; *c* represents a blood-vessel at the tip of one of them. *d* is a normal uterine gland containing a few desquamated epithelial cells. At *d'* a gland has been cut on the bevel. The stroma of the mucosa near the epithelium shows considerable small-round-cell infiltration (*e*). At *f* is a well-defined lymphoid nodule.

From this picture alone one could not diagnose carcinoma, but in the section the direct continuity could be traced between the thickened endometrium, and the squamous-cell carcinoma and the cervix. It is evident that the growth was deriving part of its nourishment from the endometrium, otherwise the projection of stroma with the accompanying blood-vessel (*e*) would not be present.

deeply staining masses of chromatin. The underlying uterine glands are few in number, but are unaltered: the stroma of the mucosa presents a normal appearance. The appendages show no change.

Diagnosis.—Squamous-cell carcinoma of the cervix, with extension to the vaginal vault, and to the mucosa of the body of the uterus.

December 28, 1899. Dr. J. McP. Scott, of Hagerstown, Md., writes me that there is no return of the growth, and that the patient has had no hæmorrhages. "Her general condition is good—except she has had a slight paralysis in no way associated with the condition concerning which you inquire." Length of time since operation, three and a half years.

CHAPTER XX

A RARE VARIETY OF ADENO-CARCINOMA OF THE UTERUS*

Not being able to properly classify this case, I have thought it advisable to consider it in a separate chapter, hoping that it may form a nucleus around which similar cases may be collected, or that at some later period it may receive its proper classification.

Clinically, three points are of especial interest: (1) the advanced age of the patient—seventy-six years; (2) the total absence of hæmorrhages during the whole course of the disease; (3) the fact that, notwithstanding the extent of the growth, the symptoms were of only one year's duration. On examining Fig. 299, one is immediately impressed with the uniform involvement of the entire uterine cavity, the body being implicated to no less a degree than the cervix. Again, the inner surface presents dome-like elevations, instead of the papillary or tree-like growths so common in adeno-carcinoma both of the cervix and of the body of the uterus. Another remarkable feature is that, notwithstanding the advanced age of the patient, the uterus was the size of that of a three months' pregnancy.

On histological examination, the growth is found to be glandular in type. The glands (Plate XI) are large, and are lined by one layer of high cylindrical epithelium; the nuclei rest directly on the bases of the cells. The lumina contain a homogeneous material that takes the hæmatoxylin stain. In fact, the glands, together with their contents, resemble those found in the cervix. In cervical adeno-carcinoma the gland epithelium usually ceases to resemble that normally present in the cervix, and the cells no longer secrete the normal mucus that is recognised by its reception of the hæmatoxylin stain. In the variety of adeno-carcinoma of the cervix in which the gland type is, on the whole, well preserved (the *adenoma malignum* of Gebhard), the gland cavities are not nearly so large as in this case, nor do the epithelial cells resemble those of the normal cervix, as was noted in our Case 2,625 (see Fig. 157, p. 307; Fig. 158, p. 308). Thus it is seen that we cannot class this neoplasm with any group now known, and must consider it as standing alone. I am inclined to think the growth originated in the cervix, but it is difficult to account for the uniform involvement of both cervix and body.

* Cullen, Thomas S. *Contributions to the Science of Medicine Dedicated by his Pupils to William Henry Welch on the Twenty-fifth Anniversary of his Doctorate.* Johns Hopkins Press, Baltimore, 1900, p. 401.

Gyn. No. 3,693

N. G., aged seventy-six; white. Admitted July 30, 1895.

Complaint: profuse leucorrhœal discharge; severe abdominal pain.

The patient has been married fifty-six years, and has had seven normal labours. The menses ceased twenty-five years ago. She has always been healthy. One grandfather died of cancer; several of her relatives were tuberculous.

For the last year she has had a profuse, yellowish, vaginal discharge, and has experienced sharp, shooting pains all through the abdomen, for the relief of which, during the last six months, she has taken a great deal of opium. At no time has she had uterine hæmorrhages. Her general condition is poor; she eats very little; her tongue is red and fissured; the bowels are constipated.

On vaginal examination, the cervix is found to be intact, but enlarged; the uterus is about the size of that of a three months' pregnancy.

Operation, Aug. 3, 1895. Abdominal hysterectomy. The uterus was lifted up as far as possible and the vessels on either side were controlled. The entire uterus and a part of the vaginal vault were removed. Since it was feared that the right ureter had been included in a ligature, it was dissected out as far as possible, slit longitudinally, and a sound was introduced. The ligature, which was in fault, was found and cut, but it was still impossible to pass the sound farther up. The bladder having been opened, a sound introduced into the ureteral orifice could be readily passed up toward the kidney, a fact which showed clearly that the ureter was patent. The wounds in the ureter and bladder were brought together by mattress sutures. The abdominal incision was closed and a gauze drain was introduced into the vagina. The patient made a good recovery, and was discharged September 8th.

Gyn.-Path. No. 828. The specimen consists of the uterus and appendages intact. Both anteriorly and posteriorly the organ is smooth and glistening. Projecting from the anterior surface, about 2.5 centimetres from the fundus, are two subperitoneal nodules (Fig. 299). These are irregular in contour, whitish yellow, and covered by peritoneum. They do not project more than 2 millimetres from the surface. The smaller nodule is 1.5 centimetres in diameter, the larger about 3 centimetres. Just posterior to the right cornu is a similar elevation, 2.5 centimetres in diameter. On palpation, the uterus seems to contain many areas which present a stony hardness. The cervix is 3.5 centimetres in diameter and is intact. It feels somewhat soft to the touch, but at the same time one obtains the impression that there are deeper areas which are exceedingly dense. On section, the cervical mucosa is found to present the usual appearances for a distance of 5 millimetres, but above this point it is practically impossible to distinguish between the cavity of the cervix and that of the body, both being of equal breadth. The combined cavity measures 10 centimetres in length. Almost from the external os to the fundus the walls are composed of a necrotic-looking tissue, which is gathered up into large and small dome-like masses. Covering the inner surface is a dirty,

greenish or reddish material. The uterine walls from cervix to fundus are invaded by a new growth, which penetrates the muscle to within from 8 to 2 millimetres of the surface. At the points at which the elevations were noticed on the surface, the wall has been invaded throughout its entire thickness, these areas being nothing more

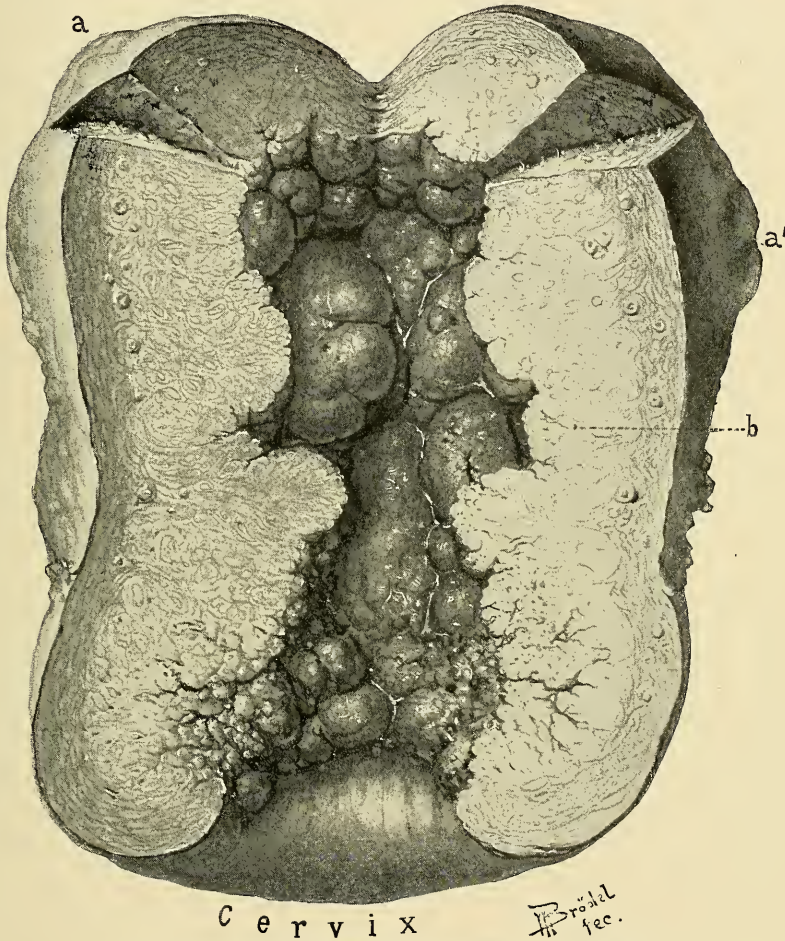


FIG. 299.—ADENO-CARCINOMA OF THE UTERUS. (Natural size.)

Gyn.-Path. No. 828. The uterus is nearly three times its usual size, and presents a nodular surface, as noted at *a* and *a'*. The cervix is greatly thickened, but both the vaginal portion and the external os are still intact. The organ, from the external os to the fundus, is occupied by a new growth, which entirely obliterates the normal landmarks. The uterine cavity is lined by large and small dome-like masses, consisting, as will be seen from the description, almost entirely of necrotic tissue. The new growth has invaded the cervix and body uniformly, extending in most places to within 5 millimetres of the peritoneal covering, and at *a* and *a'* reaching the outer surface. The growth is whitish in colour, very friable, and stands out in sharp contrast to the uterine muscle. Plate XI is a section taken from *b*.

than a continuation of the growth. The cervix and body are almost uniformly involved, although the former, perhaps, has suffered a little more extensively. The new growth, on section, is semi-translucent and glistening, and has scattered

throughout it numerous minute, yellowish-white granules. The uterine walls, including the new growth and the muscle, vary from 1.2 to 3 centimetres in thickness.

The right tube and ovary present the usual appearance. The left tube looks normal, but in the broad ligament, especially near the uterine cornu, are numerous hard, yellowish-white granules, varying from a pin-point to 3 millimetres in diameter. Many of these occur in chains which run parallel with the tubes. The ovary presents nothing of importance.

Histological Examination.—The mucosa covering the vaginal portion of the cervix is intact, and the cervical glands in the vicinity of the external os present the usual appearance. About 3 millimetres within the os, however, they become smaller, are irregular in contour, and penetrate the stroma more deeply than usual. Above this the inner surface of the uterus presents a rough, uneven appearance, and is covered by necrotic material, which contains blood and polymorphonuclear leucocytes. The glands which have penetrated the stroma occur for the most part in groups; at other times a single large, markedly convoluted gland is seen (Plate XI). The epithelium corresponds closely with that of the cervical glands, the individual cells being of the high cylindrical type, with protoplasm that stains very faintly, and nuclei situated at the bases of the cells. The majority of the gland cavities contain a homogeneous material that takes the hæmatoxylin stain faintly. Scattered throughout this material are a few desquamated epithelial cells, necrosed cells, or polymorphonuclear leucocytes. On the whole, the gland epithelium shows little tendency to fill the lumina. The tissue surrounding the glands shows a moderate amount of small-round-cell infiltration, and occasionally contains small solid nests of the growth. The uterine cavity presents a similar picture, there being no trace of the normal mucosa.

The yellowish-white nodules noted both on the anterior and on the posterior surface of the uterus form portions of the growth, and consist of precisely the same morphological elements. The tumour is an adeno-carcinoma. Its epithelium corresponds exactly with that of the cervix. Its glandular arrangement is similar to that seen in adeno-carcinoma of the cervix, and the secretion of the substance that takes the hæmatoxylin stain is usually peculiar to the cervical glands. In view of these facts we are inclined to believe that the growth originated in the cervix. It is interesting to note that, although the uterine cavity has been so uniformly invaded, the growth has not extended downward beyond the external os. It is hardly probable that all the diseased tissue has been removed.

The right tube at the uterine cornu is normal, but the uterine muscle surrounding it has been invaded by the new growth. The tube throughout its entire extent is senile, but is perfectly normal. The ovary offers nothing of importance.

The left cornu has also been invaded by glands of the new growth. The tube is senile, but sections taken from a point fully 3 centimetres from the uterus show that just beneath the folds of the mucosa and in close proximity to the blood-vessels are minute metastases (Fig. 300). These are situated in delicate vessels, evidently lymph spaces. The ovary is normal.

PLATE XI.—A RARE FORM OF ADENOCARCINOMA OF THE UTERUS. (50 diameters.)

(Fig. 1.)—This section was taken from Fig. 890 at a point midway between the external os and the fundus. It is a large gland having numerous smaller ones opening into it. In some places it is lined by low cylindrical epithelium, as indicated by c, the cells parting over the elongate, somewhat deeply staining nuclei. In other portions the epithelium appears to be several layers in thickness, but this appearance in most places is due to obliquity of the section. The gland cavity is filled with material in part homogeneous, in part fibrillated, which takes the haematoxylin stain, and has scattered throughout it desquamated epithelial cells and detritus. This substance is mucous, and corresponds closely with that found in normal cervical glands. It indicates cross sections of adjoining glands. Their epithelium is similar to that of a, and the gland also contains much mucus. At b the gland is seen to contain numerous swollen, desquamated epithelial cells and at a corresponding point just above the gland the epithelium is wanting. At c the gland epithelium appears to have been many layers in thickness, but the cells have lost their cylindrical shape and have become spherical, while the lumen contains a large amount of exfoliated epithelium, fragmented nuclei, and pus cells. y represents the stroma, consisting of cells having elongate, spindle-shaped nuclei. At x the stroma shows much small-round-cell infiltration, and contains two small spherical, purple areas. These are probably sections of small glands from which the epithelial elements have almost disappeared, leaving little except the mucus. At z the epithelium has disappeared, and the underlying stroma shows much small-round-cell infiltration. The epithelial cells, on the whole, are uniform in size, and the gland is well preserved, there being little tendency in this section for the epithelium to fill the lumen. It is remarkable to find glands of this character situated so far up in the uterine cavity. From this section alone the diagnosis of a malignant growth would not be warranted. A reference to the text will, however, show that other portions of the growth present an unmistakable adenocarcinoma.

... of the ... glands ...

The ... glands ...

The ... glands ...

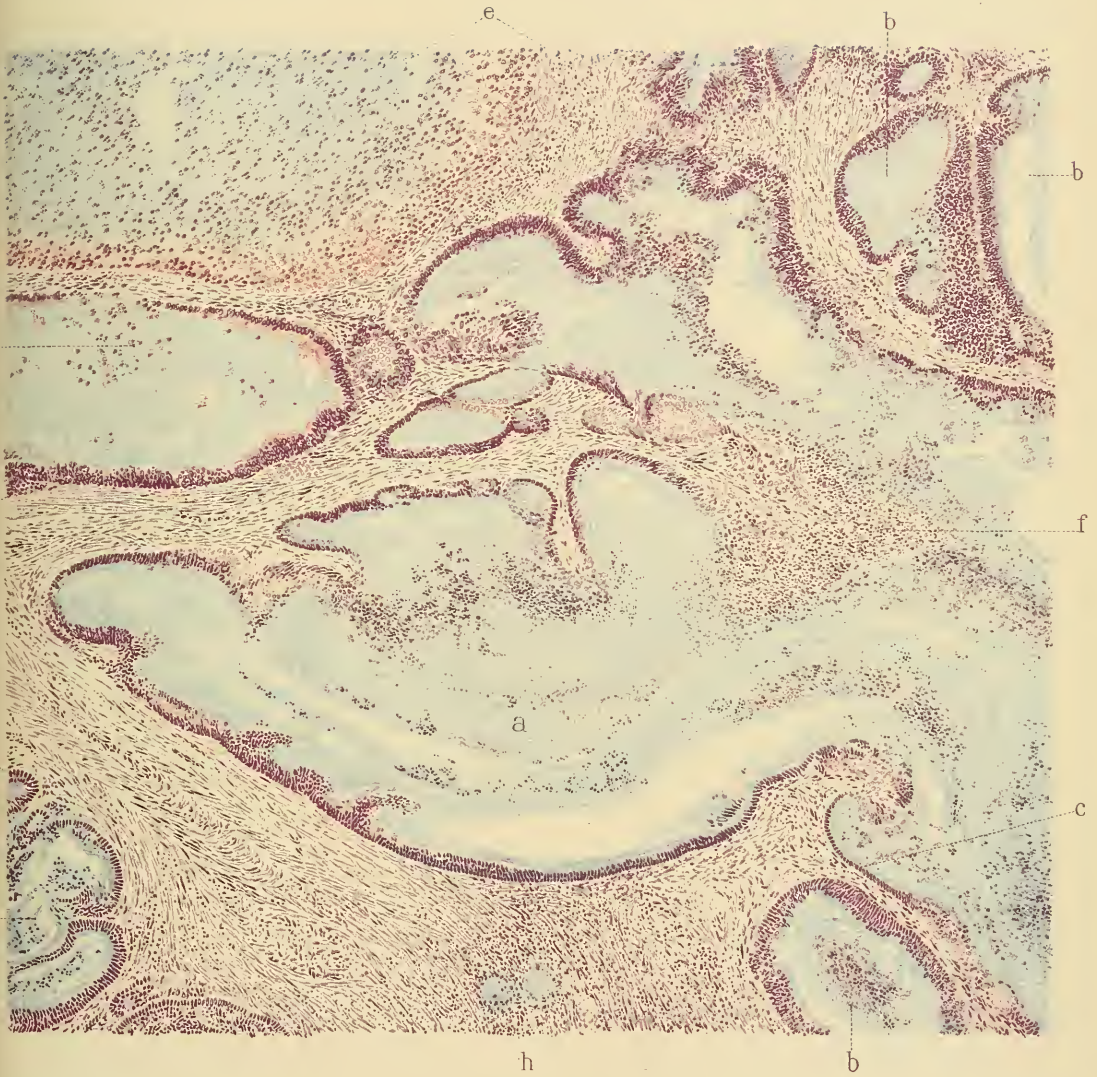
PLATE XI.—A RARE FORM OF ADENO-CARCINOMA OF THE UTERUS. (50 diameters.)

Gyn.-Path. No. 828. The section was taken from Fig. 299 at b, a point midway between the external os and the fundus. a is a large gland having numerous smaller ones opening into it. In some places it is lined by low cylindrical epithelium, as indicated by c, the cells having oval or elongate, somewhat deeply staining nuclei. In other portions the epithelium appears to be several layers in thickness, but this appearance in most places is due to obliquity of the section. The gland cavity is filled with material in part homogeneous, in part fibrillated, which takes the hæmatoxylin stain, and has scattered throughout it desquamated epithelial cells and detritus. This substance is mucus, and corresponds closely with that found in normal cervical glands. b indicates cross sections of adjoining glands. Their epithelium is similar to that of a, and they also contain much mucus. At d the gland is seen to contain numerous, swollen, desquamated epithelial cells, and at a corresponding point just above the gland the epithelium is wanting. At e the gland epithelium appears to have been many layers in thickness, but the cells have lost their cylindrical shape and have become spherical, while the lumen contains a large amount of exfoliated epithelium, fragmented nuclei, and pus cells. g represents the stroma, consisting of cells having elongate, spindle-shaped nuclei. At h the stroma shows much small-round-cell infiltration, and contains two small spherical, purple areas. These are probably sections of small glands from which the epithelial elements have almost disappeared, leaving little except the mucus. At f the epithelium has disappeared, and the underlying stroma shows much small-round-cell infiltration. The epithelial cells, on the whole, are uniform in size, and the gland type is well preserved, there being little tendency in this section for the epithelium to fill the lumina. It is remarkable to find glands of this character situated so far up in the uterine cavity. From this section alone the diagnosis of a malignant growth would not be warranted. A reference to the text will, however, show that other portions of the growth present an unmistakable adeno-carcinoma.

... of the ... glands ...

The ... glands ...

The ... glands ...



A rare form of adeno-carcinoma of the uterus.

Diagnosis.—Adeno-carcinoma of the uterus (probably cervical in origin) involving the entire cavity and extending to both cornua. Involvement of the folds of the left tube:

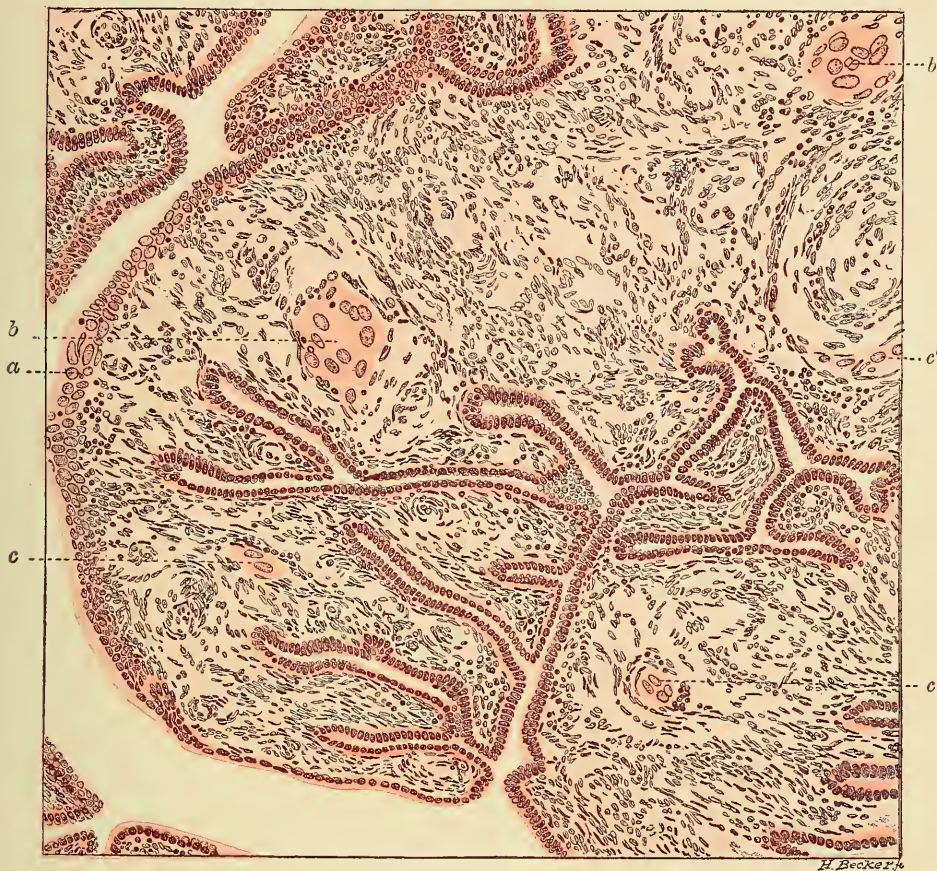


FIG. 300.—CARCINOMA OF THE FALLOPIAN TUBE SECONDARY TO THAT IN THE UTERUS. (210 diameters.)

Gyn-Path. No. 828. The section is taken from the left tube at a point 3 centimetres from its uterine end. Occupying the major part of the field is a greatly enlarged tubal fold. It is covered by one layer of low cuboidal epithelium, containing oval, somewhat deeply staining nuclei. In some places the epithelial cells are flattened, but at other points, as at *a*, they are considerably swollen. The stroma of the folds is rather dense, and at points indicated by *b* contains deeply staining areas, in which the cells are very large, and have large, oval, vesicular nuclei. These are groups of cancer cells. Other carcinomatous cells are seen at *c* and *c'*. At *c'* they form a single row parallel to and partially surrounding a blood-vessel. They are probably lying in a lymph space.

February 1, 1900. Dr. C. H. Spencer, Centre Moreland, Pa., writes me that the patient died one year after the operation. There was no evidence of a local return of the growth. The patient had no hæmorrhages. When she left the hospital the urine contained albumin. The patient continued to be weak and anæmic, and general dropsy developed before death.

CHAPTER XXI

COINCIDENT APPEARANCE OF CARCINOMA IN THE CERVIX AND IN THE BODY OF THE UTERUS

HERE reference is made not to cases similar to those reported by Emanuel* and Gellhorn,† in which the situation of the growth has favoured the coincident involvement of the cervix and the body by continuity, but to those in which the cervical growth is apparently separated from the neoplasm in the body by an intervening strip of normal tissue.

Piering,‡ in 1887, reported a case in a woman, aged fifty-four, in which the cervix was firm as if from cicatricial tissue, and presented on its posterior lip several thickenings the size of peas. Just above the internal os was a small dense prominence; higher up, a second, the size of a hazel-nut, was found, while projecting into the cavity of the corpus from the anterior wall was a globular tumour which involved the mucosa and the muscle to a considerable depth. On histological examination, the growth in the cervix and those scattered throughout the body were found to be typical squamous-cell carcinomata.

Pfannenstiel,# in 1893, published the case of a woman, fifty-three years of age. This patient had had six children and two miscarriages. The menopause had occurred at forty-eight. The cervix was occupied by a growth which extended down to the external os, and in the uterine cavity was a nodule about the size of a twenty-five cent piece. On histological examination, both the growth in the cervix and that in the body proved to be squamous-cell carcinomata.

Abel,|| in 1889, had a patient sixty-two years of age. She was the mother of ten children, and had ceased to menstruate at fifty-one. The lower portion of the cervical canal was soft, and large quantities of tissue were scraped away with the curette. Histological examination confirmed the diagnosis of carcinoma, and hysterectomy was performed. In the posterior wall, near the fundus, was a circumscribed nodule the size of a pea. This protruded about 2.5 millimetres from

* Emanuel, R. *Ueber einen weiteren Fall von Hornkrebs des Uteruskörpers.* *Zeitschr. f. Geburtsh. u. Gynäk.*, 1895, Bd. xxxii, S. 477.

† Gellhorn, G. *Zur Casuistik der Hornkrebs des Gebärmutterkörpers.* *Zeitschr. f. Geburtsh. u. Gynäk.*, 1897, Bd. xxxvi, S. 430.

‡ Piering, O. *Ueber einen Fall von atypischer Carcinombildung im Uterus.* *Zeitschr. f. Heilk.*, 1887, Bd. viii, S. 335.

Pfannenstiel, J. *Beitrag zur pathologischen Anatomie und Histogenese des Uteruskrebses auf Grund eines weiteren Falles von "doppeltem Carcinom an der Gebärmutter."* *Centralbl. f. Gynäk.*, 1893, Bd. xvii, S. 414.

|| Abel, Karl. *Ein Fall von circumscriptem Cervixcarcinom und gleichzeitigem isolirtem Krebsknoten im Fundus uteri.* *Berl. klin. Wochenschr.*, 1889, Bd. xxvi, S. 675.

the surface, and was surrounded by an inflammatory zone. The cervical and uterine growths were of the same type. The variety of carcinoma was not mentioned, but from the description one would infer that it was an adeno-carcinoma.

P. Ruge* mentions a case of cancer—apparently an adeno-carcinoma—of the cervix. After removal of the uterus he detected in the body a carcinomatous growth, which, however, was separated from the cervical neoplasm by a considerable interval of healthy tissue. Ruge thought that the two carcinomata had arisen independently of one another.

Hofmeier † reports in detail the case of a woman, fifty-four years of age, who gave a history pointing to carcinoma. Examination of a portion of the cervix revealed adeno-carcinoma, and hysterectomy was performed. The mucosa in the upper part of the uterine cavity was covered by “villi,” and the growth extended to within 2.5 centimetres of the internal os. Between the neoplasm and the part of the cervix from which the piece had been cut out the mucosa was somewhat thickened, but was otherwise normal. Histologically the growth in the body proved to be an adeno-carcinoma.

Orth, ‡ in speaking of adeno-carcinoma of the body, says that, besides the continuous advancement of the carcinoma, there is a discontinuous progress, and that in the latter case one finds several nodules, usually in the mucosa, and entirely separated from the original tumour. Winter and Ruge, # in writing upon carcinoma of the cervix, say that extension by metastasis, both into the substance and also into the mucosa of the uterus, is not rare.

Naturally the question presents itself, If the growth be primary in the cervix, how is it that we may have isolated nodules in the body of the uterus?

A careful study by Seelig || throws much light on this point. The case was one of squamous-cell carcinoma of the cervix. In the anterior cervical lip and extending over the vaginal wall was a tumour mass. Microscopically a few nests of cancer cells were found lying between the cervical glands near the external os, but the innermost layers of muscle, as well as the mucosa, were free from the growth, whereas in the outer portions of the cervix were numerous cell-nests. To the naked eye the body of the uterus appeared to be free, but on histological examination there were carcinomatous masses in the perivascular lymph vessels in the muscle of the body. Seelig made most careful serial sections, and was able to trace the continuity of the growth in the body with that in the cervix.

In Case 2,625 (p. 305) there was an adeno-carcinoma of the cervix (see Fig. 156, p. 306), while from the appearance of the uterine cavity one would not for a moment have suspected that the body was implicated. Histological study, however, showed the uterus to be studded with neoplasms, there being also secondary carcinomatous masses in the small polyp situated about the middle of the uterine cavity. On examining Fig. 159 (p. 309), the glands of the new

* Ruge, P. *Zeitschr. f. Geburtsh. u. Gynäk.*, 1886, Bd. xii, S. 202.

† Hofmeier, M. *Zur Anatomie u. Therapie des Carcinoma corporis uteri. Zeitschr. f. Geburtsh. u. Gynäk.*, 1895, Bd. xxxii, S. 171.

‡ Orth, J. *Lehrbuch der speciellen pathologischen Anatomie*, 1893, Bd. ii, S. 472.

Winter and Ruge. *Lehrbuch der gynäkologischen Diagnostik*, Leipzig, 1896.

|| Seelig, A. *Pathologisch-anatomische Untersuchungen über die Ausbreitungswege des Uterus-carcinoms im Bereiche des Genitaltractus. Virchow's Archiv*, 1895, Bd. cxl, S. 80.

growth can be seen lying between the normal uterine glands forming the polyp. In this case the carcinoma had also extended to the uterine horns (Fig. 160, p. 310).

These two cases are sufficient to show that the growths in the body may be direct continuations of that in the cervix. It is not necessary that the growth travel from cervix to body along the surface; it may pass down into the depth of the uterine muscle, and then at some distant point again reach the surface. This explanation will hold good in cases of both squamous-cell carcinoma and adenocarcinoma of the cervix, in which secondary growths have been found in the body.

It is generally understood that the lymph flow is from cervix to body. Hence it cannot at once be assumed that a primary cancer in the body can give rise to a secondary growth in the cervix. There are, however, two ways in which such metastases might take place: (1) By a retrograde flow in the lymph channels, whereby the carcinomatous particles would be carried from the body to the cervix. This occasional backward flow of lymph has been treated of fully by von Recklinghausen,* Vierth,† and others. (2) Through an implantation of carcinomatous particles, as they pass down through the cervical canal.

The first seems to us the more likely method of transport. Naturally, also, prolongations of the growth, stretching out in all directions, independent of the lymph channels, must be thought of. Extension by the second method—by implantation—could hardly take place, inasmuch as the particles of carcinomatous tissue, that come away in the discharge, are invariably necrotic and mixed with a foul material, and one can hardly imagine that such particles would be likely to ingraft themselves on a distant part and further develop.

Were we to find a squamous-cell carcinoma of the cervix and an adeno-carcinoma of the body, or the converse, or an adeno-carcinoma of the cervix and an entirely different variety of adeno-carcinoma of the body, we might consistently speak of two carcinomatous processes occurring independently of each other.

The coincident appearance of carcinoma of the cervix and of the body is of minor interest to the pathologist, although formerly it was of great import to the surgeon. In the earlier days of operative interference for cervical carcinoma it was customary to be contented with amputation of the cervix; hence, in cases in which a carcinoma of the body was likewise present, the operation was of little value. Since we now always remove not only the uterus but its appendages, and as much of the surrounding tissue as possible, this factor has lost its former clinical significance.

* Von Recklinghausen. *Ueber die venöse Embolie und den retrograden Transport in den Venen und in den Lymphgefäßen.* Virchow's *Archiv*, 1885, Bd. c, S. 503.

† Vierth, K. *Ueber rückläufige Metastase in den Lymphbahnen.* *Beiträge z. path. Anat. u. allg. Path.*, Jena, 1895, Bd. xviii, S. 515-533.

CHAPTER XXII

DECIDUOMA MALIGNUM. SARCOMA UTERI DECIDUO-CELLULARE (SÄNGER)

1. Anatomical appearances.
2. Histological examination.
3. Metastases.
4. Source of origin.
5. Clinical history.
6. Prognosis.
7. Treatment.

THIS term is applied to a group of cases in which, during or shortly after pregnancy, a malignant growth develops in the body of the uterus. Säger was the first to call attention to this condition. In July, 1888, at a meeting of the Leipzig Obstetrical Society, he reported "two unusual cases of abortion." In one of these, a woman, twenty-three years of age, had aborted during the eighth week, and died seven months later; at autopsy, in the uterine wall were found four large, soft, spongy, reddish tumours, which had given rise to metastases in the lungs, the diaphragm, the tenth rib, and the right iliac fossa. Histological examination showed the neoplasm to be a markedly hæmorrhagic tumour made up of cells similar to those found in the decidua—a "malignant deciduoma forming metastases," which belonged to the sarcoma group and to a variety never before observed.

In 1890, Pfeiffer, quite independently of Säger, published a similar case, and likewise proposed to call the condition *deciduoma malignum*.

Following the appearance of Säger's and Pfeiffer's reports, specimens from several older cases, which had been before described as adeno-carcinomata and sarcomata, were re-examined, and some of these were found to belong to the group under consideration.

More recently quite a number of instances have been reported, so that J. Whitridge Williams,* after thoroughly examining all the records up to June, 1895, was able to collect twenty-five cases, which from a clinical stand-point belonged to this group. Dorland,† in a paper published in 1897, tabulated fifty-two cases which he considered authentic. Since that time the number has been materially increased. Gebhard‡ alone reported three cases in 1897.

* Williams, J. Whitridge. *Deciduoma Malignum*. *Johns Hopkins Hospital Reports*, 1895, vol. iv, p. 461.

† Dorland, W. A. N. *The Statistics of Malignant Deciduoma*. *Univ. Med. Mag.*, Philadelphia, 1897, vol. ix, p. 696.

‡ Gebhard, C. *Ueber drei Fälle von sogenanntem malignem Syncytion*. *Verhandl. der deutschen Gesellsch. f. Gynäk.*, 1897, Bd. vii, S. 313.

The monographs of Williams and Dorland have been so exhaustive and clear that we cannot do better than quote their results in detail.

Anatomical Appearances.—On examining the vagina a nodule is frequently noticed on one or both labia, or situated a short distance within the vaginal orifice. This nodule is usually very vascular, presenting a spongy appearance, is friable, and frequently shows areas of necrosis or ulceration. Numerous similar nodules are often scattered throughout the vagina; in fact, vaginal metastases are present in nearly half of the cases. In one instance, reported by P. Müller, a row of cystic tumours had developed in the posterior vaginal wall.

The cervix is generally somewhat enlarged and soft, as a result of the recent pregnancy; on opening the organ, a tumour, 3 centimetres or more in diameter, is seen springing from some part of the uterine cavity. It is irregular in form, reddish in colour, friable, and shows considerable breaking-down; the surrounding uterine muscle is often the seat of secondary nodules, while the growth itself may penetrate the entire thickness of the uterus.

Histological Examination.—The superficial portions of the nodule usually show necrosis, and only fibrin and polymorphonuclear leucocytes are to be seen. In the deeper portions, where the growth is still preserved, a most remarkable picture is exhibited. The tissue presents an alveolar structure, and to a great extent is composed of irregular cavities of varying sizes and shapes, filled with blood and fibrin (Figs. 301 and 304). At no point is it possible to trace an endothelial lining in these cavities. They are separated from one another by irregular bands of tissue composed of large epithelioid cells of varying size. Where the cells are closely packed together they are usually more or less spindle-shaped, with a nucleus filling the greater part of the cell, and staining somewhat deeply, while the cell body stains readily with eosin, presents a distinctly granular appearance, and contains vacuoles of varying sizes. When separated from one another by hæmorrhage, the cells assume a polygonal or rounded form, and closely resemble the epithelial type (Fig. 302, p. 605). In some places only one layer of cells is found between two adjoining blood spaces, and occasionally only the anastomosing branching processes of cells divide them. The nuclei are usually round or oval, and vary considerably in size; sometimes also they are very irregular in shape. They stain quite deeply, and present a well-marked network of chromatin. Many of the cells contain two or more nuclei, and are similar to those seen in normal decidual tissue. It is rare in this part of the tumour to find cells containing more than from six to eight nuclei. No trace of intercellular tissue is to be detected in this part of the specimen. In other portions of the tumour are areas composed of long, wavy, more or less parallel bands of protoplasm (Fig. 303, p. 606). These contain nuclei arranged in a single row or in groups, so as to give the picture of giant cells. The protoplasm is quite granular, stains readily with eosin, and contains many vacuoles. The nuclei vary greatly in shape, but are mostly round or oval. They contain a thick chromatin network, stain deeply, and usually present one or two sharply defined nucleoli. These bands resemble to a marked degree syncytium. The surrounding muscle shows marked small-round-

cell infiltration. Thus it is seen that the growth contains elements resembling both decidual cells and the typical syncytium.

Most of these growths appear to have contained both varieties of cells, but in Sanger's original tumour he found no syncytium, and all the cells resembled more or less those of the decidual type. At the meeting of the German Gynecological Society in 1897, Sanger said that, after careful study, he was still unable to find any trace of syncytium. Unfortunately, the original tumour had not been kept, so that further sections could not be made.

METASTASES

In the fifty-two cases reported by Dorland, secondary growths were found in 70.76 per cent. The relative frequency of incidence of metastases in the various organs was as follows :

In the lungs.....	78.37 per cent.
“ vagina	54 “
“ spleen.....	13.5 “
“ ovary	13.5 “
“ kidney.....	13.5 “
“ liver.....	10.8 “
“ broad ligament.....	10.8 “
“ pelvis	10.8 “
“ brain	5.4 “

Macroscopically the secondary growths were sharply defined, very vascular, and resembled the intact portions of the primary growth. Histologically they corresponded with the original growth in all respects.

SOURCE OF ORIGIN

These growths occur during or shortly after pregnancy, and are found at the placental site. They may therefore, as was pointed out by Marchand, arise from four sources: 1, the decidual cells; 2, the syncytium covering the villi; 3, Langhans' cell layer; 4, the stroma of the villi.

It would appear that the majority arose in part at least from the syncytium, but there are a certain number, as is exemplified by Sanger's case, in which no syncytium could be detected. Whether the cells that resemble decidual cells are really of this nature, or belong to the inner layer of cells covering the villi—the layer of Langhans—is as yet undecided.

Nearly all authors agree that the decidual cells are merely the swollen stroma cells of the mucosa, but here the unanimity ceases. Many claim that the syncytium is of maternal origin; others are equally certain that it is of fetal origin. Our own observations would lead us to favour this latter view. Furthermore, it is doubtful whether Langhans' layer in reality consists of epithelial cells, some believing that it probably represents nothing more than the outlying stroma cells, which have of necessity assumed a marginal arrangement.

With this uncertainty it is impossible to decide whether the growth be a carcinoma or sarcoma, or a combination of the two processes. The clinical

features alone are sufficient to class it as a morbid process entirely distinct from ordinary carcinoma or sarcoma, and it would seem that for the present at least the name *deciduoma malignum* should be retained.

CLINICAL HISTORY

Among the first symptoms noted are the repeated and profuse uterine hæmorrhages, which in the later stages are associated with a fetid or watery discharge. Curettings from the uterus show the presence of characteristic tissue. Pelvic pain develops; the patient grows profoundly anæmic, and cachexia appears. Later on, œdema of the vulva with vaginal metastases may be found. The patient becomes more and more prostrated, and there may be hæmoptysis, due to pulmonary metastases. From the absorption of septic material there is frequently slight elevation of temperature and repeated rigours.

Dorland, in a series of fifty patients, gives the following data as to the age :

Between fifteen and twenty years	2 cases.
“ twenty and twenty-five years	12 “
“ twenty-five and thirty years	11 “
“ thirty and thirty-five years	12 “
“ thirty-five and forty years	1 case.
“ forty and forty-five years	7 cases.
“ forty-five and fifty years	3 “
“ fifty and fifty-five years	2 “

From this table it is seen that in nearly all the disease occurred during the period at which the sexual functions were active, and that many of the patients were so young that carcinoma could practically be excluded.

In forty-two of the cases collected by Dorland, the number of previous pregnancies is recorded :

During or after the first pregnancy	2 cases.
“ “ “ second “	5 “
“ “ “ third “	10 “
“ “ “ fourth “	5 “
“ “ “ fifth “	6 “
“ “ “ sixth “	2 “
“ “ “ seventh “	3 “
“ “ “ eighth “	1 “
“ “ “ ninth “	4 “
“ “ “ tenth “	2 “
“ “ “ thirteenth “	2 “

In one of the primiparæ (Ahlfeld's case) the pregnancy was situated in the Fallopian tube.

Nature of the Pregnancy immediately Preceding the Development of the Deciduoma.—Here Dorland points out the close association existing between the occurrence of a vesicular mole and the appearance of *deciduoma malignum* :

Number of cases.	Nature of pregnancy.
1	after a tubal pregnancy.
1	“ a miscarriage at the sixth month.
12	“ an abortion.
17	“ a labour at term.
20	“ the discharge of a hydatidiform mole.

In those cases in which abortions had occurred, two of the women had previously expelled hydatidiform moles. Thus, in twenty-two (43.3 per cent) of the cases there was a history of the expulsion of a vesicular mole at some time prior to the appearance of the disease.

PROGNOSIS

The malignancy of this disease is strikingly shown in the fact that out of the series collected by Dorland, thirty-one cases, or 59.6 per cent, manifested symptoms either during labour or within four weeks of that time. It is further shown by the fact that in 78.97 per cent death occurred within six months after the appearance of the symptoms.

TREATMENT

It is clearly evident that the uterus must be removed in all cases in which the disease has not extended too far. Unfortunately, a growth of this nature invades the tissues with such rapidity that a delay of a few days may be sufficient to render all radical procedures useless. Accordingly, we must look for some means of detecting its presence at the earliest moment.

The large percentage of cases following the expulsion of hydatidiform moles is of peculiar significance. Neumann,* being impressed with this fact, undertook investigations bearing more especially on this point. At the meeting of the Gesellschaft f. Gynäkologie in 1897, he described in detail eight cases in which a hydatidiform mole had been expelled; five of these patients remained perfectly well; the remaining three developed deciduoma malignum.

In the cases of the patients in whom no malignant growths afterward developed the moles presented the usual picture. The villi formed small cysts; the stroma was without vessels, and in certain areas was somewhat increased, while in other parts it was rarefied, and in many places was infiltrated with mucus. The cells of Langhans' layer, as well as the syncytium, in many places showed proliferation.

In the second group the same histological changes were present, but in some places a very unusual picture was found. At these points the syncytium was invading the stroma of the villi in such a way that it seemed as though the tenacious fluid protoplasm was pouring itself out into the rarefied connective tissue after the manner of the pseudopods of amoebae. With this

* Neumann. *Ueber Blasenmole und malignes Deciduom. Verhandl. der deutschen Gesellschaft. f. Gynäk.*, 1897, S. 304.

penetration into the stroma the syncytial nuclei increased in size, and the syncytium formed large, indistinctly outlined cell elements.

In many villi were large cell elements entirely foreign to their proper stroma. That these cells had originated from the syncytium was unmistakable, and they were wholly analogous to the syncytial tumour elements in the walls of the uterus.

Neumann found these changes with great regularity in hundreds of sections, and was further able to determine that they were most marked in a mole from a case in which the expulsion was followed at a very early date by the detection of the deciduoma. It appears that in this case the malignant growth had commenced in the uterus before the mole was expelled.

Ruge, who examined the specimens, though acknowledging the exactitude of Neumann's observations, thought it somewhat doubtful whether the syncytial cells in the stroma of the villi could be considered identical with the malignant degenerative changes found in deciduoma.

Schmorl* reports a case in which, eighteen weeks after a normal delivery, a tumour was detected in the vagina. Death occurred within six months. The uterus and appendages were not involved by any growth, but metastases were found in the lungs, liver, kidneys, and intestines. The vaginal neoplasm and the metastases gave the typical picture of the syncytial growth. Schmorl believed that the process had originally started in the placenta, which, however, had been expelled before the uterus was directly attacked, but not until metastases had commenced.

The cases reported by Neumann and Schmorl are certainly very suggestive, and teach that in all instances in which a mole is expelled it will be well to make an immediate histological examination of many portions of the specimen. If there be signs of malignancy not definite enough to warrant a hysterectomy, the uterus may be curetted. One must be careful, however, not to mistake the decidual cells (Fig. 264, p. 504), or the giant cells normally found in the muscle (Fig. 267, p. 509) at the site of the placenta, for elements of a malignant growth. There is little danger of erring, as the syncytial tissue found in deciduoma is typical.

When the diagnosis has been made, there should be no delay in removing the uterus. Abdominal hysterectomy is the operation to be preferred.

We have not had a case of deciduoma malignum in our own series, but were allowed to study Williams's case thoroughly. As it is such a typical instance and has been so accurately described, we quote it in detail from the *Johns Hopkins Hospital Reports*, vol. iv, p. 462.

History.—R. W., aged thirty-five years, was a full-blooded negress, both her parents having been born in Africa. Her family history was good, both parents being still alive. She had been treated by Dr. Harris for malaria some two years previously, and for bronchitis about six months before her last pregnancy. She

* Schmorl. *Demonstration eines syncytialen Scheidentumors*. *Monatsschr. f. Geburtsh. u. Gynäk.*, 1897, Bd. vi, S. 444.

had had five pregnancies, the third ending in a miscarriage at the sixth month, and the others at full term; in all of her labours, with the exception of the last, she was attended by a midwife.

During her last pregnancy she felt somewhat apprehensive as to the result, and engaged Dr. Harris to attend her. The pregnancy was perfectly normal, excepting a transient attack of slight albuminuria a few days before confinement.

April 15, 1894. She was delivered spontaneously of a dead child. The labour was slow, and lasted about thirty hours, a good deal of blood being lost during the third stage. The placenta was "soft and boggy," but there was no loss of blood after its expulsion.

The puerperium was not entirely normal, the temperature remaining at about 100° F., and she felt very much prostrated. Dr. Harris saw her for eight days, when he discontinued his visits.

About one week later the patient's mother informed him that there was a small and painful nodule, about the size of a pea, on the right labium majus, for which he prescribed some soothing wash without seeing the patient.

Three weeks after the labour he was called once more to the case, and found the right labium swollen to about the size of a hen's egg, and very painful. In it was a bright-red tumour the size of a walnut, which rapidly increased in size, and soon became gangrenous and ulcerated on its surface, so that a month after labour it had attained the size of a hen's egg, was markedly necrotic on its surface, and was accompanied by a very odorous discharge.

There were no symptoms indicating any involvements of the uterus, and as the patient was rapidly growing worse, he advised her to enter the Maryland General Hospital, which she did on May 16th, and died there, July 12, 1894.

When admitted to the hospital she was suffering with septicæmia, and examination showed a large sloughing mass, which occupied nearly the whole of the right labium and adjacent tissue, in the centre of which there was a large fistulous opening into the rectum, through which fæces were discharged. The temperature varied from 99° in the morning to 103° F. in the afternoon, but during the last three weeks of life it did not rise above 100° F. Death from exhaustion, with marked emaciation.

The clinical diagnosis was "sloughing hæmatoma of the vulva with septicæmia."

ABSTRACT OF AUTOPSY PROTOCOL

There are a few scattered flakes of grayish-white lymph on the intestinal peritoneum; the peritoneum is pale, and the peritoneal cavity contains about 50 cubic centimetres of clear fluid.

The genital tract and rectum were removed *en masse*. At the entrance of the vagina, involving its posterior and lateral aspects and both labia majora, there is an irregularly shaped raised mass, of a dark, grayish-red, mottled appearance, which is marked by deep furrows of ulceration. This is about 10 centimetres in circumference, and extends for about 6 centimetres up the posterior vaginal wall. At the upper border of this mass, on the posterior wall of the vagina, there is an irregularly shaped opening, 2 centimetres in diameter, which communicates with

the rectum. Its edges are not raised. On section, the mass is of a mottled gray and red colour, is soft and friable, and is separated from the underlying tissues by a paler, grayish zone.

On the left lateral wall of the vagina, 4 centimetres below the cervix, there is an oval area, raised 5 centimetres above the surrounding tissues, which measures 1.5 by 1 centimetre, is of a grayish-red colour, and presents a granular appearance. It is soft, and readily breaks down under the fingers. On section, it is also of a grayish-red colour, and extends through the vagina into the underlying tissues.

The cervix is soft, considerably dilated, and has very thin walls. On the right side of its vaginal surface there is a small ulcer; its canal is free from ulceration and new growth.

The body of the uterus is about twice the normal size, and its cavity is considerably dilated. On section, its wall is very pale, and softer than usual. The mucosa is pale, and free from ulcerations.

From the posterior wall of the body of the uterus an irregular mass, 3.5 centimetres long and 2 centimetres wide, projects 1.5 centimetres into the cavity of the uterus. Its surface is uneven, and grayish white in colour, marked here and there by greenish-gray areas. At its lower portion, just above the os internum, there is an irregularly shaped superficial loss of substance, which is covered by a loosely adherent, foul-smelling slough. On section, the tumour presents a grayish-red granular appearance.

In the fundus, beneath the mucosa, there is a smaller tumour, the size of an almond, which on section presents the same appearance as the large tumour.

The left tube is of the usual size, its fimbriated extremity is free, and a thin milky fluid can be expressed from it.

The left ovary is smaller than normal, and from its hilum arises a dark-red tumour, the size of a hazel-nut, which is soft, breaks down under the finger, and on section closely resembles placental tissue.

Adjacent to this, and corresponding to the parovarium, is a small multilocular cyst, the size of a lemon, which contains clear fluid.

The right tube presents the same appearance as the left. The left ovary is irregularly nodular in shape, and on section contains several small cysts with hæmorrhagic margins and clear contents.

Left Lung. There are numerous thin adhesions, particularly on the upper and anterior surface of the superior lobe. On its surface, as well as on section, the lung is seen to be occupied by a large number of irregularly shaped, round, or oval nodules, which vary from a pea to a walnut in size, the majority being situated in its peripheral portion. They are grayish red in colour, some presenting soft grayish areas in their centre. They easily break down under the finger, are readily enucleated from the surrounding lung substance, and closely resemble placental tissue in appearance.

At one point, upon enucleating a nodule, a vessel of considerable size is seen, whose walls are infiltrated by the growth, which appears to project into its lumen.

The right lung is likewise studded by large numbers of similar nodules. In both lungs the tissue between the nodules presents its usual appearance and crepitates.

The bronchial mucous membrane is normal, as are also the bronchial glands.

H e a r t . The heart is normal, but several atheromatous patches are seen in the upper part of the aorta.

L i v e r . The liver is not enlarged. It presents marked fatty degeneration, and scattered through it are numerous hæmorrhagic nodules, the largest not exceeding a hazel-nut in size.

S p l e e n . The spleen is twice its normal size, is soft and almost diffuent, the entire organ being the seat of an infarction. It also contains several small metastases.

K i d n e y s . The kidneys are not enlarged, but present marked fatty degeneration. In the cortex of both, just at the base of the pyramids, are several dark-red hæmorrhagic areas, which vary from 2 to 10 millimetres in diameter, with whitish or grayish centres.

The renal pelves, ureters, bladder, suprarenals, are normal. The mucous membrane of the stomach and intestines is very pale, but otherwise normal.

Agar cultures from the lungs, spleen, liver, and kidneys were sterile.

MICROSCOPIC EXAMINATION

Small pieces from the various organs were immediately placed in 95 per cent alcohol, from which very satisfactory sections were obtained.

Sections were first made through the larger nodule on the posterior wall of the uterus and the adjacent portions of the uterine wall. The mucosa covering the uterine wall in the vicinity of the tumour was very slightly changed. Its surface epithelium was intact, and in places ciliated, and its glandular structures presented their usual appearance.

The interglandular connective tissue was increased in amount, and scattered through it were considerable numbers of round cells and leucocytes. The mucous membrane could be traced for a considerable distance up along the sides of the tumour, where it gradually disappeared, the surface epithelium disappearing first, while the stroma and glands persisted longer. Nowhere in the mucosa could any trace of decidual tissue be found, nor did it present any suggestions of sarcomatous change.

It was found that the new growth had invaded portions of the muscularis, which were still covered by but slightly changed mucosa, and had consequently undermined it to some extent, but by far the greater part of the growth was not covered by mucosa.

The entire superficial portion of the nodule is composed of necrotic material, which, indeed, makes up its greater part. The most superficial portions are entirely necrotic, and we are able to distinguish only threads of fibrin and very dense leucocytic infiltration. Lower down, as we approach the real substance of the tumour, the necrosis becomes less absolute, and in the necrotic masses we are able to distinguish the outlines of cells whose nuclei have disappeared.

As we approach still nearer, we find very large individual cells scattered through the threads of fibrin, in whose meshes are large quantities of blood cells, which are accompanied by many more leucocytes than normal. These cells are

very large, and present a decidedly epithelial appearance, though they are somewhat suggestive of the larger epithelioid decidual cells.

The boundary line between the necrotic tissue and the new growth is very irregular, as is also the line of demarcation between the latter and the subjacent muscular tissue.

Under the low power the most striking feature of the growth is its marked alveolar structure, its greater part being made up of irregularly shaped cavities of

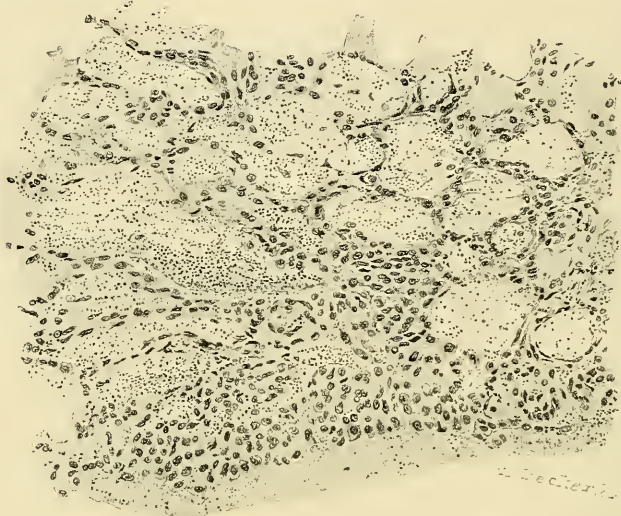

FIG. 301.—ALVEOLAR ARRANGEMENT IN DECIDUOMA MALIGNUM. (60 diameters.)

The section is from the primary tumour. The tissue is composed of polygonal cells containing oval nuclei, the greater number of which are vesicular. These cells closely resemble decidual cells. Scattered throughout the tissue, and forming fully one half of the field, are sinuses filled with blood and containing many polymorphonuclear leucocytes, as indicated by the small dark specks. The sinuses are totally devoid of endothelium, and the tumour cells forming the delicate partitions between them are drawn out and distorted. (After J. WHITRIDGE WILLIAMS.)

very varied size and shape, which are filled with blood and fibrin and contain numerous leucocytes (Fig. 301).

Nowhere in these cavities are we able to discover any trace of an endothelial lining. They are separated from one another by irregularly shaped bars of tissue, which are made up of large epithelioid cells, of varying shape and size, which likewise form the boundaries of the blood spaces.

Where the cells are closely packed together they are usually more or less spindle-shaped, with a nucleus filling the greater part of the cell, and staining somewhat deeply, while the cell body stains readily with eosin, presents a distinctly granular appearance, and contains vacuoles of varying size. Where they are less closely packed together, and especially where the individual cells are separated from one another by hæmorrhage, they assume a polygonal or rounded shape, and closely resemble epithelial cells (Fig. 302). In other places, especially where the bars of tissue separating the alveolar spaces are very thin, the cells may present irregular branching outlines, and send out long branching processes, which apparently anastomose with similar projections from other cells.

In some instances only a single layer of cells divides one blood space from another, and at times they appear to be separated only by the anastomosing branching processes, and not even by the whole thickness of a cell body. Some of these cells resemble stellate connective-tissue cells in shape, but differ from them by their much larger size.

The nuclei are usually large or oval, and vary considerably in size, but are sometimes very irregular in shape, corresponding to the general outlines of the cells which they occupy. They stain quite deeply with the usual stains, and present a well-marked chromatin network. In most of them we observe a single nucleolus, and not infrequently two, which are large and very prominent. A considerable difference in staining, however, appears in nuclei belonging to cells of apparently the same character, some staining much more intensely than others,

Considerable numbers of the cells contain two or more nuclei, giving rise to pictures similar to those obtained in normal decidual tissue. It is rare, however, in this part of the tumour, to find cells containing more than six or eight nuclei. In some of them we observe typical, and in others atypical, mitotic figures.

Throughout this portion of the growth we are unable to find any trace of intercellular tissue or reticulum, most of the cells lying in apposition, and when

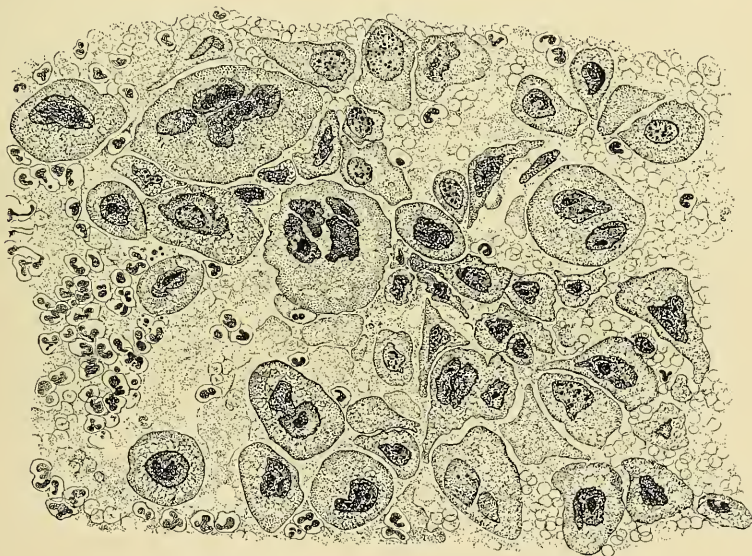


FIG. 302.—ISOLATED TUMOUR CELLS IN DECIDUOMA MALIGNUM.

This section is from the lower margin of Fig. 301. There is no stroma whatever. The cells lie perfectly free, vary greatly in size and shape, their protoplasm containing many small vacuoles. The nuclei may be oval and vesicular, or irregular in shape and deeply staining, or one cell may contain anywhere from two to five nuclei. Separating the cells from one another are blood and polymorphonuclear leucocytes. (After J. WHITRIDGE WILLIAMS.)

they are separated from one another it is only by blood or threads of fibrin, thus giving the tissue a decidedly epithelial appearance. Nowhere in the cell bars are we able to find any trace of blood or lymph vessels, consequently necrotic areas are of frequent occurrence.

The boundary line between the new growth and the muscularis is very irregular, as the latter is being invaded in all directions by offshoots from the tumour. In places we may see bands of cells making their way between the muscle cells, and frequently causing degeneration and atrophy of the latter; in other places we see masses of the characteristic tumour cells making their way along the lumina of what appear to be venous channels, and here and there we find small areas of tumour formation in the muscularis, at some distance from and without any apparent connection with the main growth. A marked zone of leucocytic infiltration always precedes and surrounds the new growth as it invades the muscularis.

At one side of the tumour there is an area which at first sight presents an absolutely different appearance (Fig. 303).

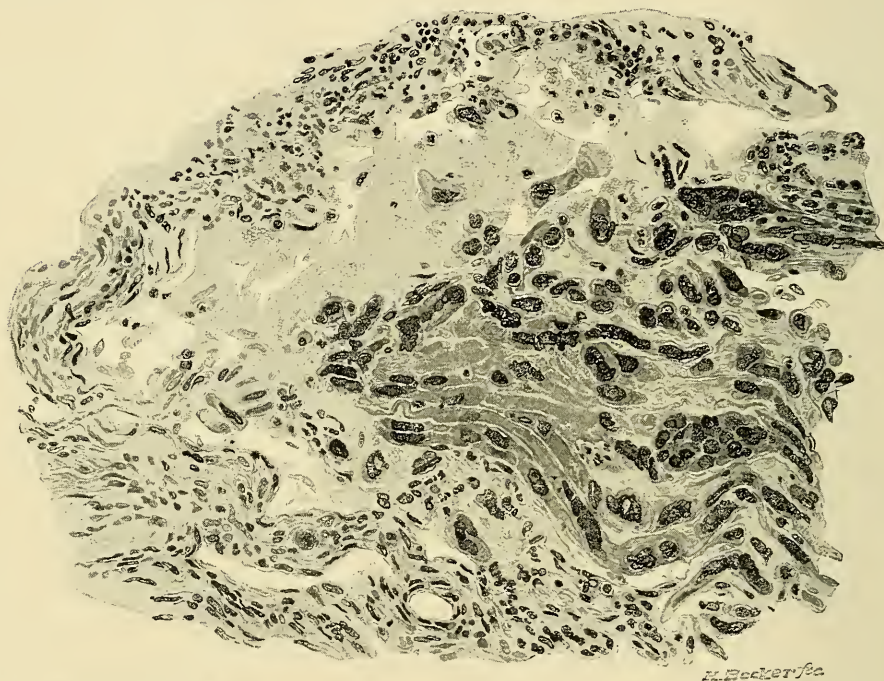


FIG. 303.—SYNCYTIAL MASSES INVADING A VENOUS CHANNEL IN A CASE OF DECIDUOMA MALIGNUM.

The section is from the uterine wall at the margin of the growth. To the left and below we have swollen, non-striped muscle, showing slight small-round-cell and polymorphonuclear leucocytic infiltration, and forming a portion of the wall of a large venous sinus; while projecting in from the right are ribbons of protoplasm containing round, irregular or elongate, and deeply staining nuclei. In the upper part of this mass of tumour cells are seen numerous isolated polygonal cells closely resembling decidua cells. In the extreme upper part of the sinus is a large giant cell. (After J. WHITRIDGE WILLIAMS.)

Here we find a mass, composed of long, wavy, more or less parallel bands of cells, connected at one end with the main body of the tumour, but with its free end projecting into a cavity, which is partially lined by endothelium, and is apparently of venous origin.

On closer examination, we find that we do not have to deal with individual cells, at all, but with long, narrow, worm-like bands of protoplasm with nuclei

embedded in them, but presenting absolutely no trace of division into cells. For the most part these bands contain a single row of nuclei, but in other places they are arranged in groups, giving rise to structures similar to giant cells. Their protoplasm is quite granular, stains readily with eosin, and contains many vacuoles. The nuclei vary greatly in shape, but are mostly round or oval. They contain a thick chromatin network, stain deeply, and usually present one or two sharply marked nucleoli (Fig. 303).

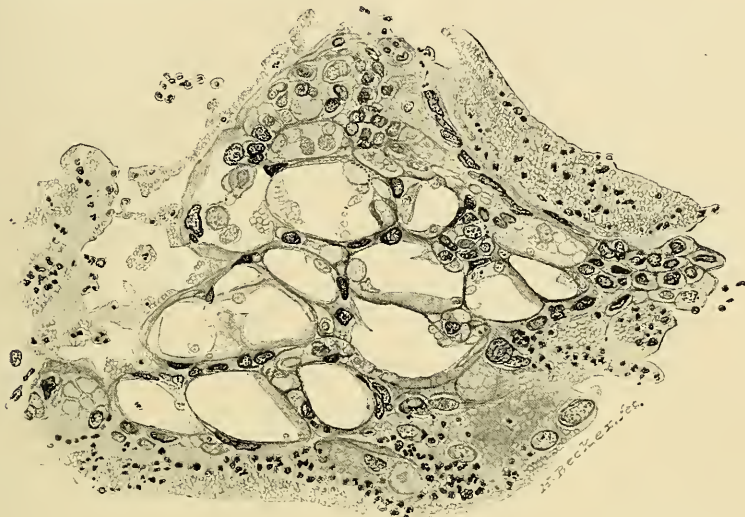


FIG. 304.—VAGINAL METASTASES IN DECIDUOMA MALIGNUM. (150 diameters.)

The cells forming the little mass are so arranged that they inclose vacuoles, and remind one somewhat of fat droplets. Surrounding the growth are blood and polymorphonuclear leucocytes. (After J. WHITRIDGE WILLIAMS.)

The muscular tissue adjoining this area presents a large amount of leucocytic infiltration; many of the muscle nuclei are enlarged and swollen and contrast markedly with the normal muscle cells, which are at some little distance from them, and between which all stages of gradation may be observed.

At first it appeared as if the above-mentioned protoplasmic bands were derived from them, but closer examination shows that this is not the case; for the larger the muscle nuclei become the more faintly do they stain and the less resemblance do they bear to the nuclei in the protoplasmic masses or syncytium, and it is evident that we only have to do with degenerating muscle cells, and not with those which are being transformed into tumour elements.

Not far distant from this area containing well-marked syncytium we find other areas presenting a similar but not so well marked structure. At one point we find an areolated area which at first glance resembles a mass of large fat cells (Fig. 304); but on closer examination we find that we have before us a considerable number of quite large, round, or irregularly shaped cavities, lying in a mass of protoplasm, which shows no trace of division into individual cells, and which corresponds to the syncytium above described. The partitions separating the cavities, which appear to be empty or filled by transparent contents, are gener-

ally quite thin, usually being but a small fraction of the diameter of the cavities in thickness. Many of the nuclei lie in the partition walls and are then usually spindle-shaped, while those in the other portions of the mass are more oval in shape. Both the protoplasm and its inclosed nuclei correspond exactly in structure and staining qualities to those found in the protoplasmic bands (Fig. 303), and there can be no doubt as to their identity, their only difference consisting in the presence of the alveolar spaces.

After carefully examining these areas and then going back to the main part of the tumour, we find that many portions which at first appeared to be made up of individual cells are really small masses of syncytium, and some of the blood spaces likewise appear to be bounded by it. In fact, the likeness becomes so striking in many places that we cannot help asking if it is not possible that even the cells, which still appear as individuals, may not have a similar origin, and perhaps be due to transverse or oblique sections through syncytial bands, sections through narrow worm-like bands giving rise to the smaller mononuclear cells, and those through thicker masses appearing as multinuclear or even giant cells—appearances analogous to those obtained on section through the placenta in its early stages, when we find mononuclear as well as giant cells scattered through the intervillous spaces, which are undoubtedly produced by sections through chorionic syncytium.

Sections through the entire thickness of the fundus, including the smaller nodule, show that it presents essentially the same structure as the larger nodule, except that it is much more necrotic. This nodule is almost entirely covered by uterine mucous membrane, which is of the same character as that which partially covers the larger nodule. In several places, deep down in the tissue, we found several cut-off portions of uterine glands, whose epithelium is desquamated, and lies loose in their lumina. At first sight they appeared to be isolated areas of tumour formation, but a closer examination reveals their true nature, and their marked difference from the cells of the new growth.

The chief point of interest in these sections is that we find in the uterine wall, at least 1 centimetre distant from the tumour mass, several apparently normal veins, which contain thrombi composed of typical tumour cells which are embedded in a mass of fibrin and lie loose in the lumina of the vessels, and are apparently in transit to some remote portion of the body, probably the lungs, where they might have given rise to other metastases.

We next cut sections through the necrotic tumour mass at the entrance of the vagina. At its margin it is covered by the typical stratified epithelium of the epidermis, with the characteristic pigmentation in its deeper layers (the woman being a negress). Beneath this is the subcutaneous tissue, with bundles of striated muscle crossing it in all directions.

The great part of the tumour formation is composed of well-preserved blood, which is not contained in the vessels, and in which there are many more leucocytes than usual.

The cellular part of the metastasis is only clearly marked at the margins of the growth, where it is seen to present the same general structure as the nodules in the uterus.

Here we observe the same alveolar structure, only more highly developed, the

greater part of the metastasis being composed of free blood in spaces, and the same two varieties of cells (?).

Here the protoplasmic bands or masses of syncytium appear in much greater abundance, are more clearly marked than in the primary tumour, and assume all sorts of bizarre forms. In some places we find structures almost resembling cross sections of chorionic villi—that is, more or less circular bodies surrounded by a protoplasmic band, which contains nuclei arranged in a single row, but presents absolutely no trace of division into cells, in whose centre there are a number of polygonal epithelioid cells, whose nuclei as a rule stain less deeply. In none of these structures, however, do we find any trace of blood-vessels or real stroma, nor any trace of a second layer of definite epithelial cells (Langhans' *Zellschicht*) beneath the syncytium. In other words, we are unable to find more than a superficial resemblance to chorionic villi.

In other places the definitely characteristic syncytium appears to form a distinct border, beneath which there are several layers of what appear to be definitely marked epithelial cells (?). In other places it forms large finger-like masses, with nuclei scattered all though them, which lie free in the blood, and do not appear to be in connection with any form of cells.

We also observed most beautiful giant cells, with large numbers of irregularly placed nuclei, which are clearly produced by sections through syncytial masses. Some of the alveolar spaces are apparently completely bounded by syncytium of varying thickness, which in places sends out long branching processes, just as in the primary uterine tumour.

The protoplasm composing this syncytium is finely granular, and takes on a yellowish-red stain with eosin. Scattered through it are numerous vacuoles, which vary in size from cavities scarcely visible under a high power to very large cavities, some being empty and others containing blood, but none of them presenting any trace of an endothelial lining. Some of them appear to be produced by the degeneration and final disappearance or dropping out of nuclei, while others have certainly no connection with nuclear changes.

The nuclei are of various shapes and sizes, and occasionally assume very bizarre forms. They all contain a definite chromatin network, but vary greatly in their staining properties, some staining intensely and others quite lightly. This is strikingly observed in some of the finger-like bands of syncytium which lie perfectly free in the blood, and in which there is absolutely no trace of division into cells, when one nucleus may stain very intensely and possibly the one adjoining it very lightly; so that if they occurred in separate cells there would be no hesitation in saying that they were totally different, and perhaps of different origin. On the whole, however, they stain very intensely. In most of them one or more nucleoli can be observed.

The individual cells, to which we have already referred as being bounded by or inclosed within masses of syncytium, present a distinctly epithelial appearance. There is absolutely no trace of reticulum between them, and they are frequently packed very closely together.

The greater part of these cells are occupied by large nuclei, which, as a rule, stain less intensely than those in the syncytium, but correspond entirely with the syncytial nuclei, which stain lightly. The small amount of protoplasm which

surrounds the nuclei is slightly granular, stains exactly as does that of the syncytium, and likewise contains numbers of small vacuoles.

The boundary line between the metastasis and the surrounding tissue is marked by a layer of leucocytic infiltration, and tumour cells may be seen invading it in all directions.

At several points it is clearly seen that the tumour cells have broken through vessel walls, and in some instances have partially or entirely replaced their endothelial lining.

Small thrombi, composed apparently of individual cells or giant cells, may occasionally be detected in the small veins of the subcutaneous tissue at a very considerable distance from the metastasis itself.

Sections through the metastases in the various organs present identically the same structure as that at the entrance of the vulva, varying from it only in the fact that they are surrounded by different tissues; it is therefore unnecessary for us to consider them in detail.

They all present the same markedly hæmorrhagic character, and the cellular elements are only well preserved at their margins.

The pulmonary metastases are much more necrotic than those in the other organs, but otherwise do not differ from them.

In all the organs the metastases are surrounded by marked areas of leucocytic infiltration.

In the kidney there is marked increase in the cells about the glomeruli, combined with marked degeneration of the epithelium of the convoluted tubules, which is presumably fatty.

In the spleen there are various infarcted areas, and in the lungs many of the alveoli are filled with leucocytes, desquamated epithelium, and fibrin.

It is thus seen that we have to deal with a very remarkable new growth, which cannot readily be classed among any of the well-known tumours occurring in the uterus.

The greater part of the original tumour, as well as the metastases, is made up of blood, which lies either free in the tissues or inclosed within cavities formed by the tumour cells, while its cellular part is composed of large elements, some of which appear as epithelial cells (?), and others as larger or smaller masses of syncytium.

Nowhere in the tumour can any trace of blood-vessels or reticulum be discovered, and it appears to be composed solely of epithelial cells (?) and masses of syncytium, which are grouped together with apparently no attempt at tissue formation, but which lie free in areas of hæmorrhage without apparent integral connection with the surrounding tissues.

The metastases present the same characteristics, and appear to be thrombotic or embolic masses of cells, which multiply in the vessels and cause their rupture, with consequent hæmorrhage into the surrounding tissue. In these hæmorrhagic areas the cells live on and multiply, until they form masses too large to be nourished simply by osmosis, when they undergo necrotic changes. Accordingly, the ontological interpretation of the tumour is no easy matter, not to speak of the difficulties involved in positively settling its histogenesis.

CHAPTER XXIII

PREGNANCY COMPLICATING CARCINOMA OF THE CERVIX

1. Age of patient.
2. Course of pregnancy.
3. Treatment in operable cases complicated by pregnancy.
 1. Operation in the early months.
 2. Treatment in the later months.
 3. Vaginal hysterectomy during the later months.
4. Treatment in hopeless cases of carcinoma of the cervix associated with pregnancy.
 1. Casarean section.
 2. Porro operation.
5. Report of cases of carcinoma of the cervix complicated by pregnancy.

FROM time to time isolated instances of this complication have been reported, but for our present knowledge of the subject we are mainly indebted to Cohnstein, Theilhaber, and Olshausen. Cohnstein,* in 1873, collected as far as possible the cases prior to that time and discussed them in detail. A similar task was undertaken in 1894 by Theilhaber,† who analyzed the cases reported from 1873 to 1893. Lastly, in the spring of 1897, R. Olshausen ‡ read a very important paper on the same subject before the Obstetrical and Gynæcological Society of Berlin.

The occurrence of pregnancy during the course of carcinoma of the cervix, although not common, is no great rarity. Cohnstein's series included 134 cases up to 1873, while Theilhaber, for the succeeding twenty years, collected a total of 165. Scheibe,# in an inaugural dissertation published in Halle in 1893, says that Winkel observed 8 cases in 15,000 labours, Sutugin 2 in 9,000, Stratz 12 in 17,900—a percentage of .047 when all these cases are included. Fehling,|| in the last three years, has observed 5 cases in about 3,000 labours; while Noble,^ when reporting 4 cases of his own in 1895, said that he had been able to find records of 166 cases recorded since 1886.

* Cohnstein. *Ueber die Complication der Schwangerschaft und Geburt mit Gebärmutterkrebs.* *Arch. f. Gynäk.*, 1873, Bd. v, S. 366.

† Theilhaber. *Die Behandlung des Uteruscarcinoms in der Schwangerschaft und bei der Geburt.* *Arch. f. Gynäk.*, 1894, Bd. xlvii, S. 56.

‡ Olshausen, R. *Carcinom des Uterus und Schwangerschaft.* *Zeitschr. f. Geburtsh. u. Gynäk.*, 1897, Bd. xxxvii, S. 1.

Scheibe, W. *Ueber die Complication des Uteruscarcinoms mit Schwangerschaft, Geburt und Wochenbett.* *Inaug.-Diss.*, Halle, 1893.

|| Fehling, H. *Das Verhalten des Arztes bei Complication von Schwangerschaft u. Geburt mit Carcinoma colli uteri.* *Münchener med. Wochenschr.*, 1897, Bd. xlv, S. 1,314.

^ Noble, G. H. *One Hundred and Sixty-six Cases of Carcinoma of the Pregnant Uterus occurring since 1886.* *Med. News*, 1895, vol. lxxvii, p. 667.

Age of Patient.—In 58 of Cohnstein's patients accurate data as to the age were obtainable :

16	were	between	twenty-seven	and	thirty-three	years	of	age.
19	“	“	thirty-four	and	thirty-seven	years	of	age.
23	“	“	thirty-eight	and	forty-nine	years	of	age.

These figures show clearly that where carcinoma of the cervix and pregnancy coexist the patients are, on an average, much younger than those in whom carcinoma alone is present.

In each case it is naturally of interest to determine whether the pregnancy has commenced prior to or after the onset of the carcinomatous process. Not infrequently the marked involvement of the cervix proves clearly that the carcinoma existed before the patient became pregnant. Cohnstein found that in seventeen per cent of his series symptoms of the growth were noted prior to the impregnation, and, according to Scheibe, similar cases were observed by Sutugin and Merkel.

As might be surmised from the fetid discharge, pregnancy is not so prone to occur as under ordinary conditions; nevertheless, the figures just given show that it is by no means a great rarity. Where a thorough curettage is performed, as was done in Leinzinger's* case, the chances for impregnation would naturally seem greater than when the carcinoma is left untouched, since, as a result of the operation, all necrotic tissue and the foul-smelling discharge are for the time done away with.

Varieties of Carcinoma of the Cervix.—Cohnstein, in 127 of his cases, found that 86 were adeno-carcinomata and 41 squamous-cell carcinomata (?). We must, however, not place implicit confidence in these numbers, inasmuch as, prior to 1873, the histological descriptions often showed some inaccuracy, and not a few cases were diagnosed macroscopically, no histological examination being made.

In the 5 cases that came under Fehling's care, 4 were squamous-cell carcinomata and 1 was an adeno-carcinoma of the cervix. Personally we have not had sufficient experience to be able to decide which variety is the more frequent. Clinically, or from an operative stand-point, this point is of no great moment.

Clinical History.—The patient will come complaining of the usual bloody or watery discharge. If the carcinoma be first detected the pregnancy may be overlooked, since the free hæmorrhages may be mistaken for a disordered menstrual flow. The loss of blood is often exceptionally severe in these cases on account of the extreme vascularity of the uterus. The symptoms are, on the whole, similar to those ordinarily found in squamous-cell carcinoma or adeno-carcinoma of the cervix (see Chapters VI and XI), with the addition of those which belong to pregnancy.

* Leinzinger, E. *Ein Fall von Konzeption nach curettirtem Cervixcarcinom.* *Centralbl. f. Gynäk.*, 1897, Bd. xxi, S. 502.

THE COURSE OF THE PREGNANCY

In 29 per cent of Cohnstein's cases the patients either aborted or miscarried. From the pregnancies going to term in Cohnstein's series 36.2 per cent of the children were born alive; Theilhaber's figures show 47.2 per cent. Pregnancy may go on to term and labour come on in the usual way without any untoward symptoms. In some cases, however, very disastrous results may follow. If the growth be far advanced, it is possible for deep tears to take place in the hard but friable carcinomatous tissues, so that the bladder or rectum is opened; at another time the entire carcinomatous tumour may be torn off and expelled through the vulva, as happened in Meig's case (cited by Theilhaber), in which, however, the child was afterward born spontaneously. Rupture of the uterus has been reported by Hecker, Chantreuil, Oldham, and by d'Ontrepont, in whose case the uterus gave way after the fourth pain.

According to Müller,* Hermann found reports of 11 ruptures in 180 cases and Cohnstein cited 14 cases in which the women died undelivered. Of these pregnancies, 13 were at term, one at the seventh month. The patient may pass term without delivery, as was demonstrated by Menzies' † patient, who died seventeen months after conception; at autopsy the liquor amnii had disappeared, but the child, although somewhat compressed, showed no signs of maceration.

TREATMENT

We thoroughly agree with the view of Kaltenbach, that wherever a carcinoma occurs during pregnancy the radical operation, if possible, is to be performed at once, and must not be delayed in order to afford a chance of life to the child. All are agreed that during the early months operation should be performed immediately, but where the woman is in good condition, and the child is within a month or two of viability, the operator is sometimes prevailed upon to wait.

With our present knowledge of carcinoma, both clinically and from a pathological stand-point, the inclination to yield to these considerations and to delay is rapidly disappearing. During pregnancy the uterine muscle fibres swell up, and at the same time the spaces between the muscle bundles increase in size, so that even on macroscopical examination the muscle presents a spongy or porous appearance (Fig. 305, p. 620). The tissues are much more vascular, and, as one would naturally infer, under such favourable conditions the neoplasm makes rapid progress. Davis, ‡ in the *American Text-Book of Obstetrics*, says that cancer of the uterus increases with great rapidity during pregnancy, and still more rapidly during the puerperal condition. Coe, § from a study of a number of cases, also reaches a similar

* Müller, P. *Carcinom des Uterus. Handbuch der Geburtshülfe*, Stuttgart, 1889, Bd. ii, S. 874.

† Menzies. *Eine Schwangerschaft durch Uteruskrebs bis zum 17ten Monat verlängert. Monatsschr. f. Geburtsh.*, v. 1855, S. 207.

‡ Davis, E. P. *Amer. Text-Book of Obst.*, Phila., 1895, p. 187.

§ Coe, H. C. *Cancer of the Cervix Uteri complicating Pregnancy. Amer. Jour. Obst.*, 1893, p. 515.

conclusion. From Scheibe we learn of a very interesting experiment performed by Zweifel, with a view of ascertaining the rapidity of the growth. Having observed in an early pregnancy a commencing squamous-cell carcinoma of the cervix, he passed a silk ligature along the margin of the growth, and found that in two weeks it had extended the breadth of two fingers beyond this point. The examination was rendered easy by the fact that the growth was very sharply defined, different in colour, and of very firm consistence, in contrast to the soft, succulent surrounding tissue.

It is not to be wondered at that in former years the friends, family physicians, and clergy objected to the sacrifice of the child, when at the same time the mother would in all probability be subjected to a dangerous and probably fatal operation. But since it has now been proved that the mother can in the majority of cases be saved by prompt operative interference, the former opposers of the operation are most likely to be among its firmest advocates.

Whenever an operable carcinoma of the cervix is detected, a radical operation should be performed at once. By delay we shall probably sacrifice the mother's life, and at the same time have only a limited chance of saving the child.

OPERATIONS IN THE EARLY MONTHS

Our object is, of course, to remove the entire uterus and to get beyond the carcinomatous growth. Accordingly, two operations are open for selection. After the technique employed in laparotomies had reached its present degree of excellence, vaginal hysterectomy was employed less and less, but within the last few years numerous surgeons have been coming back to the vaginal route in performing hysterectomy for carcinoma of the cervix. Among these may be mentioned Doyon, Dührssen, Hegar, Winter, and Olshausen, who in a very recent article has shown the remarkably good results obtained by removing the uterus by the vaginal route.

In the majority of cases of carcinoma of the cervix our chief difficulty lies in getting at the tissue on either side of the cervix. Now, in pregnancy the vagina is more capacious, the tissues are soft, and on account of its increased elasticity the uterus can be drawn much lower down than usual. As a result, one can reach lateral structures much farther out than would be possible under ordinary circumstances. The objection that after the third month the uterus is too large to bring out through the vagina is more apparent than real, since the difficulty is very easily obviated in the following way: After the cervix has been ringed and freed from the vagina and parametrium, it may be split; the foetus and placenta are then removed, after which the uterus is sufficiently small to be brought with ease through the natural passage. This operation is not accompanied by any serious amount of hæmorrhage. The vaginal method not only has the advantage that it takes less time—a matter of no small importance—but the immediate results, so far as can be learned at present, are much better. Fehling has collected eleven cases of abdominal hysterectomy with five deaths, while in Olshausen's series of twenty-five cases of vaginal hysterectomy not a single fatality is

recorded. Despite the fact that several of the cases reported by Fehling were operated upon at a time when the technique was far less perfect than it is to-day, the striking contrast between the abdominal and vaginal operation is still evident. The permanent results obtained by Olshausen are remarkably good. Up to 1895 he had had nine vaginal hysterectomies; one patient died at the end of six months, but the cause of death could not be ascertained; four had a return of the growth, which was evident in five, six and a half, seven months, and three and a half years respectively. The remaining four women are well at the end of two and a half years, five and three quarters years, six and a half years, and seven and a half years.

Statistics, therefore, show that vaginal hysterectomy is the method which promises the best results in carcinoma of the cervix, when operative interference is instituted during the early months of the pregnancy.*

The plan of removing the fœtus and waiting several days or weeks for involution to take place, has been abandoned, not only because sepsis may follow from material introduced from the cervix, but also on account of the loss of valuable time involved in such a procedure. The fœtus, placenta, and uterus are now removed at one operation.

TREATMENT IN CARCINOMA OF THE CERVIX IN PREGNANCY IN THE LATER MONTHS

Most operators think that after the third month of pregnancy the uterus should be removed *per abdomen*, but Olshausen and others have performed vaginal hysterectomy as late as the fifth month. After this time Cæsarean section and abdominal hysterectomy are recommended.

The usual vaginal cleansing is carefully looked after, and the membranes may or may not be ruptured. A longitudinal incision is made through the anterior wall of the uterus, and the child drawn out by the feet as rapidly as possible. During this time the bleeding may be readily checked by encircling the cervix with a rope of gauze, by means of which the uterine vessels can be tightly compressed. The cord is tied; the placenta is sometimes removed, or at other times is left in the uterus. The further steps in the hysterectomy are identical with those described on p. 224. One inconvenience in connection with these operations should be mentioned. Owing to the increased intra-abdominal pressure, the bladder will not balloon out; as a consequence it is difficult, or sometimes impossible, to catheterize the ureters, and there is great danger of including them in the ligatures.

VAGINAL HYSTERECTOMY DURING THE LATER MONTHS OF PREGNANCY

In January, 1898, Fritsch † reported a case of total extirpation of the uterus at full term. The patient was the mother of four children, and during this preg-

* The possibility of implantation must be borne in mind.

† Fritsch, H. *Vaginale Totalexstirpation eines carcinomatösen Uterus am Ende der Schwangerschaft*. *Centralbl. f. Gynäk.*, 1898, Bd. xxii, S. 1.

nancy had had uterine hæmorrhages, which toward the end became more frequent. On admission, she was very anæmic, and had lost much flesh; the pulse was 100. The vagina was capacious and smooth; the cervix was represented by a small tumour, evidently carcinomatous in character. The child was in the first position; the foetal heart sounds were normal. On the day following admission labour pains commenced, and on examination the os was found dilated to 6 centimetres in diameter.

Preparations were immediately made for vaginal hysterectomy. The membranes were ruptured, and a deep slit was made with a pair of scissors in the healthy part of the cervix. Forceps were then applied, and by the exertion of strong traction a living child was delivered. There was moderate hæmorrhage, and the placenta was rapidly delivered by Credé's method. Vaginal hysterectomy was then performed in the usual way.

Fritsch claims that the operation is especially easy for the following reasons: 1. The puerperal uterus is easily drawn down; in fact, one can almost operate without using a speculum. 2. It is easily differentiated from its surroundings, so that, as soon as the vagina is ringed, the uterus can be drawn down with the utmost ease and the adjacent tissues pushed up. 3. It is so soft that it can be stretched or drawn in any direction, so that its circumference can be greatly diminished. Fritsch stretched the uterus until it measured about 30 centimetres in length, and until the diameter of the fundus was not more than half as much as that of a puerperal uterus at the second week.

No blood escaped from the uterus during the operation. The patient was under the anæsthetic fifty minutes, and the operation lasted thirty minutes. She made a good recovery.

Mittermaier,* in the same number of the *Centralblatt für Gynäkologie*, reports the removal of a uterus *per vaginam* at the end of the seventh month of pregnancy. The woman was forty-three years of age, and had borne eight children. The right side of the cervix was intact, but behind and on the left side was a crater-like ulcer. After curetting away the carcinomatous tissue, the cervix was ringed, and the base of the parametrium tied off with catgut and Douglas's sac opened. The peritoneal cavity was then cut into anteriorly. Two stout clamps were now pushed into the cervical canal and fastened. The anterior lip having been slit between the clamps, on introducing a finger into the uterus it was ascertained that the placenta was not situated on the anterior wall. Two artery forceps were applied in this situation, and an incision was made between them. In this way the membranes were ruptured, and the normal quantity of fluid escaped. As delivery did not proceed spontaneously, version was performed, and the child was easily brought out. The slit in the cervix was now closed with a continuous catgut suture, and the uterus was removed without difficulty. Free hæmorrhage occurred at two stages: first, when the carcinomatous tissue was curetted away, and a second time when the finger was introduced to turn the child. The patient made an uneventful recovery.

* Mittermaier. *Zur Behandlung des Uteruscarcinoms in der Gravidität.* *Centralbl. f. Gynäk.*, 1898, Bd. xxii, S. 5.

As yet the vaginal operation in the later months has been rarely tried, but it appears to offer two great advantages. It is quickly performed, Fritsch's case only requiring thirty minutes. It can readily be understood that speed is a matter of importance, inasmuch as the patient, after the loss in strength consequent to a seven or nine months' pregnancy and a coexistent carcinoma, is in no condition to withstand a long operation. Even in our Case 5,398 (p. 619), in which the nutrition of the patient had been carefully attended to for some time prior to the operation, the pulse reached 160 before she left the table. Again, in operating through the vagina there is less danger of infecting the abdominal cavity.

Fritsch has twice operated by the abdominal route, both patients recovering. He says that the operation is difficult, bloody, and long. So confident is he that the vaginal hysterectomy is safer and easier, that, in closing, he says: "Abdominal extirpation of the pregnant carcinomatous uterus will certainly not be performed any more."

The selection of the method of operation in the later months must, of course, be left to the individual operator; but I should not be at all surprised to see the abdominal route abandoned entirely in these cases associated with pregnancy.

TREATMENT IN HOPELESS CASES OF CARCINOMA OF THE CERVIX ASSOCIATED WITH PREGNANCY

Here we can only look to the comfort of the mother and wait till the child comes to term. The question then arises, What is to be done? We know that the cervix is very hard, and allows of only slight dilatation except at the risk of a great amount of tearing of the dense but friable carcinomatous tissue; again, even if the cervix is freely lacerated, the child will often be dead before the labour is over. Sometimes the cervix will not dilate at all, and rupture takes place in the lower uterine segment. Both rupture of the uterus and a deep tear of the cervix are fraught with much danger, since, in the former, fatal hæmorrhage is almost sure to occur, while, in the latter, infection will in many cases take place from the necrotic and foul-smelling material.

Just before labour commences, the growth may as far as possible be curetted away; then, as soon as labour has started, stellate incisions should be made in the cervix, after which labour may terminate in the usual way, or the application of the forceps may be necessary. Unfortunately, as might be expected, there is a tendency for the incisions to be still further lengthened by the tearing of the tissues, so that in these cases also there is great danger of subsequent sepsis not only from infection through the wounds, but also from septic material which may be carried into the uterine cavity on the instrument or on the hands of the operator. Theilhaber collected eighteen cases in which forceps were applied; sixteen of the patients lived, and two died.

Turning may be necessary for the delivery of the child, but, as is shown by Theilhaber, the dangers are great, since there were three deaths in his series of five cases.

If the child be dead and the head be very large, perforation may have to be resorted to. Here also the mortality is great, Theilhaber reporting ten cases

with four deaths. From the above it is seen that, at best, delivery by the vaginal route is very dangerous.

Caesarean Section.—When the child is viable Cæsarean section seems to offer fairly good results. A long abdominal incision is made, and the body of the uterus is virtually drawn out of the incision. Bleeding is controlled by placing a gauze rope around the cervix and making firm traction. A free incision is made over the convex anterior surface of the uterus down to the mucosa. The membranes are now exposed and the fluid escapes. The child is drawn out by the feet as rapidly as possible, and the cord is clamped and cut. The placenta is now peeled out, leaving the uterus practically empty. It is astonishing how little blood is lost when the cervix is compressed in the manner mentioned. The incision in the uterus is now closed by interrupted catgut sutures, which go as deep as the mucosa, or, if necessary, through it. Superficial approximation sutures are then applied, and the gauze compress is removed from around the cervix. If any bleeding follow, additional sutures are applied until it is checked. The abdomen is then closed in the usual way.

It is generally conceded that after this procedure in inoperable cases there is great danger of sepsis. Of two patients who were treated by Olshausen in this way, one died of sepsis on the fifth day.

The Porro operation seems to be followed by better results, since the large and soft uterus is removed. After the Cæsarean section has been performed for the delivery of the child, the uterus is removed in the usual way by amputating at the cervix. Care must be exercised not to cut too close to the carcinomatous tissue, as there are frequently small abscesses scattered throughout it. After the amputation has been completed, the peritoneum from the anterior pelvic wall is drawn over the stump and united with that from the posterior wall.

Caesarean section followed by the Porro operation is the procedure to be recommended in these cases. In all instances, however, one must be prepared to meet with infection.

Gyn. No. 1,661

Adeno-carcinoma of the cervix in a patient five months pregnant. Abdominal hysterectomy. One year later an attempt was made to ligate the internal iliac arteries, but the abdomen was found to be completely choked with the recurrent growth.

C. T., aged twenty-nine; white. Admitted March 9, 1894.

This patient first entered the hospital November 4, 1892, with signs of carcinoma. She was then five months' pregnant. On vaginal examination the growth was found to have involved the greater part of the cervix. Abdominal hysterectomy was performed, and she made a good recovery. At the time, it was doubtful whether the entire growth had been removed or not.

At present she is much emaciated, and her face indicates extreme and prolonged suffering. She complains of excruciating pain immediately after micturition, and says that at times she feels as if everything were coming down through

the vagina. The pain is so severe that two grains of morphia are required every six hours.

Her bowels are constipated, but defecation is not painful. The whole upper part of the vagina is filled with a sloughing fungating mass, and induration is found extending to the pelvic walls on all sides. To complicate matters, there are communications between the vagina and rectum, and the vagina and bladder.

Operation, March 15, 1894. An attempt was made to ligate the internal iliac arteries, in order to cut off the blood supply to the pelvis. On opening the abdomen, the pelvis was found choked with the neoplasm together with the adherent intestines, so that it was impossible to reach the arteries. The abdomen was immediately closed. The patient's general condition continued to be about the same; her pain, however, gradually increased, and she grew so noisy that it was necessary to isolate her. Death occurred May 8th.

Microscopical examination of the tissues by Dr. J. Whitridge Williams showed the growth to be an adeno-carcinoma.

Gyn. No. 5,398

Pregnancy complicating a squamous-cell carcinoma of the cervix (Fig. 305). Development of decidual cells from the stroma of the cervix (Fig. 306). Extension of the carcinoma to the body of the uterus (Fig. 307). Caesarean section; complete hysterectomy with removal of a portion of the vaginal vault. Recurrence.

E. C., aged thirty-four; married. Admitted July 29, 1897.

The patient was in the hospital a few months ago, and a carcinoma of the cervix was diagnosed. As she was several months pregnant, it was thought advisable to delay the operation until the child was viable. When she was admitted this time the uterus was about the size of that of a seven-and-a-half-months' pregnancy. From time to time careful examinations were made to see if the foetal heart-beats were still strong.

Operation, September 27, 1897. A long abdominal incision was made and the uterus was delivered. A stout gauze rope controlled the uterine vessels at the cervix, and a sweeping cut was then made through the anterior uterine wall, care being taken to go just as far as the foetal membranes. The abdominal cavity was carefully walled off by gauze, the membranes were quickly ruptured, the foetus was grasped by the feet and delivered. The cord having been controlled by two artery clamps, a cut was made between them. The foetus, which was partially asphyxiated, was quickly resuscitated. The uterus was now removed in the usual way, from left to right. The ureters were alarmingly close to the carcinomatous areas, but by tracing them down from the pelvic brim they were readily isolated. Considerable difficulty was experienced in removing the entire growth on the right side of the vaginal vault. After all bleeding points had been checked the abdominal cavity was washed out and closed. The pulse at the end of operation was 160. Five hundred cubic centimetres of salt solution were introduced into the breast.

The temperature after operation rose on two occasions as high as 102° F. There was a slight suppuration from the lower angle of the incision. The patient made a good recovery, and was discharged on November 2d.

Her husband visited the hospital on April 7, 1898, and said that his wife was doing splendidly; at that time she had no pain and no discharge. The baby died two months after birth.

Gyn.-Path. No. 1,971. The uterus is pear-shaped, approximately 17 centimetres long, 15 centimetres broad, and 10 centimetres in its antero-posterior diameter (Fig. 305). Both anteriorly and posteriorly it is smooth and glistening. In the anterior wall is an incision 10 centimetres in length, which is naturally much shortened, owing to the uterine contraction which followed the removal of the child. Projecting through the opening is a portion of the placenta. The cervix is converted into a rough, worm-eaten mass; its lower portion averages 6 centimetres in diameter, and consists of minute finger-like processes, or of conglomerate masses, 6 millimetres or more in diameter. To the right of the cervix is a portion of the growth, 5 centimetres in diameter and 1 centimetre in thickness; at this point the growth has invaded the vaginal vault; upward it extends for fully 2 centimetres. Within the internal os it is soft, friable, stands out in sharp contrast to the surrounding muscle, and has on all sides advanced to the cut surface. Thus it is hardly possible that the entire tumour has been removed. On the right side the uterine artery has been resected for a distance of 4 centimetres. The uterine walls vary from 2 to 3.5 centimetres in thickness; they are very porous, and their blood-vessels are much dilated. The uterine cavity is 10 centimetres in length, and approximately 13 centimetres in breadth at the fundus. The mucosa presents a wrinkled surface, evidently due to the contraction of the uterus. Although gathered up into little elevations and depressions, the mucosa is smooth. Attached to the left side of the body from cervix to fundus is a portion of the chorion. On pulling this away slightly, the underlying mucosa presents a shaggy appearance, due to numerous delicate adhesions. At some points the membrane is firmly attached by adhesions fully 1 centimetre in breadth.

The placenta is approximately circular, and averages about 16 centimetres in diameter; it is everywhere intact, and presents the usual appearance. The cord is situated in the centre, and averages 1 centimetre in diameter.

The right Fallopian tube is 9 centimetres in length, and averages 6 millimetres in diameter; it is free from adhesions. The ovary is $3.2 \times 2.5 \times 1$ centimetres, contains a corpus luteum scarcely 1 centimetre in diameter, and is free from adhesions.

The left tube is 11 centimetres in length, and near its outer end reaches 7 millimetres in diameter. It is free from adhesions, but just beneath its fimbriated extremity are three small cysts, the largest being 7 millimetres in diameter. The ovary measures $4.5 \times 2.5 \times 6$ centimetres, and is much flattened; no adhesions are present.

Histological Examination.—Sections from the lower portion of the cervix show that the surface of the growth is in places covered over by polymorphonuclear leucocytes, and that the tissue itself is composed of large and

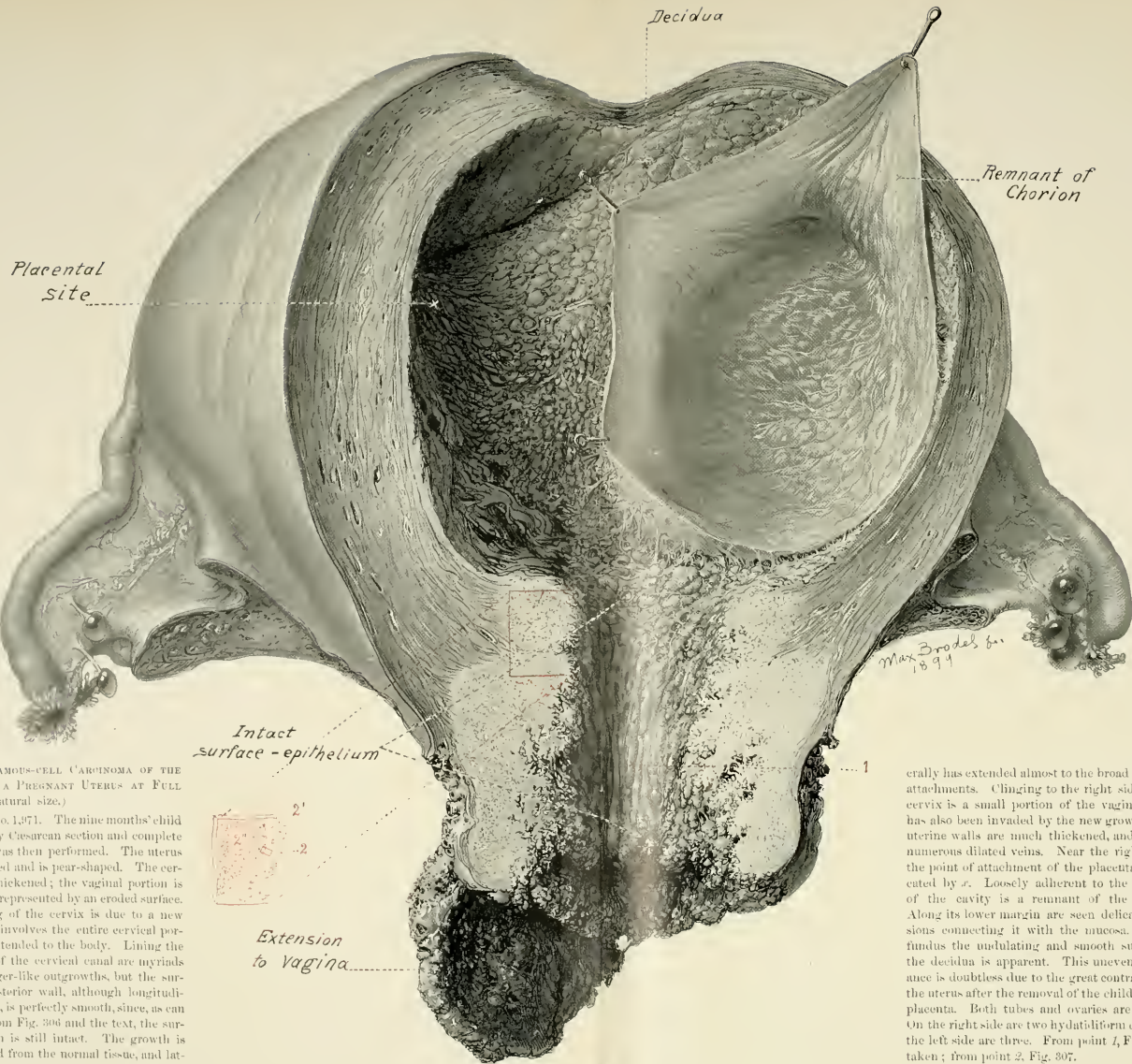


FIG. 305.—SQUAMOUS-CELL CARCINOMA OF THE CERVIX IN A PREGNANT UTERUS AT FULL TERM. (Natural size.)

Gyn.-Path. No. 1,371. The nine months' child was removed by Cæsarean section and complete hysterectomy was then performed. The uterus is much enlarged and is pear-shaped. The cervix is greatly thickened; the vaginal portion is wanting, being represented by an eroded surface. The thickening of the cervix is due to a new growth, which involves the entire cervical portion and has extended to the body. Lining the anterior wall of the cervical canal are myriads of delicate finger-like outgrowths, but the surface of the posterior wall, although longitudinally furrowed, is perfectly smooth, since, as can be gathered from Fig. 306 and the text, the surface epithelium is still intact. The growth is sharply defined from the normal tissue, and lat-

terally has extended almost to the broad ligament attachments. Clinging to the right side of the cervix is a small portion of the vagina, which has also been invaded by the new growth. The uterine walls are much thickened, and contain numerous dilated veins. Near the right cornu the point of attachment of the placenta is indicated by *x*. Loosely adherent to the left side of the cavity is a remnant of the chorion. Along its lower margin are seen delicate adhesions connecting it with the mucosa. At the fundus the undulating and smooth surface of the decidua is apparent. This uneven appearance is doubtless due to the great contraction of the uterus after the removal of the child and the placenta. Both tubes and ovaries are normal. On the right side are two hydatidiform cysts; on the left side are three. From point 1, Fig. 306 is taken; from point 2, Fig. 307.

small nests of squamous cells. In some places these nests are very irregular and branch in every direction; at other points they form long finger-like processes, or are seen as small, round, or oval nests. The epithelial cells around the margins of the nest show a slight tendency to become cuboidal or cylindrical. The cell nuclei vary considerably in size, are round, oval, elongate, or irregularly triangular in form. The nuclei in the central portion of the nests are frequently spindle-shaped. In some of the large cell-nests there are distinct evidences of hornification, and in other nests the central portion has undergone complete coagulation necrosis.

In sections from some portions of the cervix are seen projecting from the surface numerous finger-like processes, which consist of stems of stroma covered externally by a varying amount of epithelium. Sometimes the covering on one side consists merely of one layer of cells, whereas on the opposite side there may be four or five layers. The nuclei of these cells are irregular in size, and stain fairly deeply. On tracing the epithelial covering of these finger-like processes into the depth, it is found to penetrate the underlying stroma in all directions, sometimes forming solid cell-nests, at other times appearing as mere slits lined by one layer of epithelium, while a little farther on it may form solid nests. Were one to study these slit-like spaces alone, endothelioma would naturally be suspected; but in our specimen it is possible to trace the continuity of the epithelium covering the surface of the growth with that lining the slit-like spaces—a finding which conclusively shows the epithelial origin of the growth.

On passing a short distance farther up the cervical canal, a few cervical glands can be seen opening out on the surface, while the stroma surrounding them is everywhere infiltrated by nests of the new growth. Still a little higher the cervical surface epithelium is seen to be perfectly preserved; a gland is here and there visible, but the stroma is everywhere infiltrated by the new growth (Fig. 306). The stroma cells are markedly altered. Immediately beneath the surface epithelium they are practically normal, but the deeper ones have become much swollen, are oval or polygonal, and have oval, faintly staining nuclei; they form typical decidual cells—a most interesting finding, inasmuch as the section is taken from a point apparently midway between the external and internal os. That we are dealing with cervical cells there can be no doubt, as the overlying surface epithelium belongs to the typical high cylindrical variety, while on either side of these decidual cells are cervical glands. Still nearer to the internal os the surface epithelium is seen to be intact. The blood-vessels immediately beneath are greatly dilated, and long strings of cells of the new growth are seen penetrating the underlying tissue in all directions. These lie immediately beneath the surface epithelium, run parallel with it, but do not appear to have disturbed its continuity at any point. The stroma shows much small-round-cell and some polymorphonuclear leucocytic infiltration.

Upward the growth has extended into the uterine cavity. The uterine mucosa as such is not visible, having been converted into typical decidua, which in the superficial portions has undergone complete necrosis, and has scattered

throughout it numerous polymorphonuclear leucocytes. The underlying decidua shows much small-round-cell infiltration. All through the decidua there appear

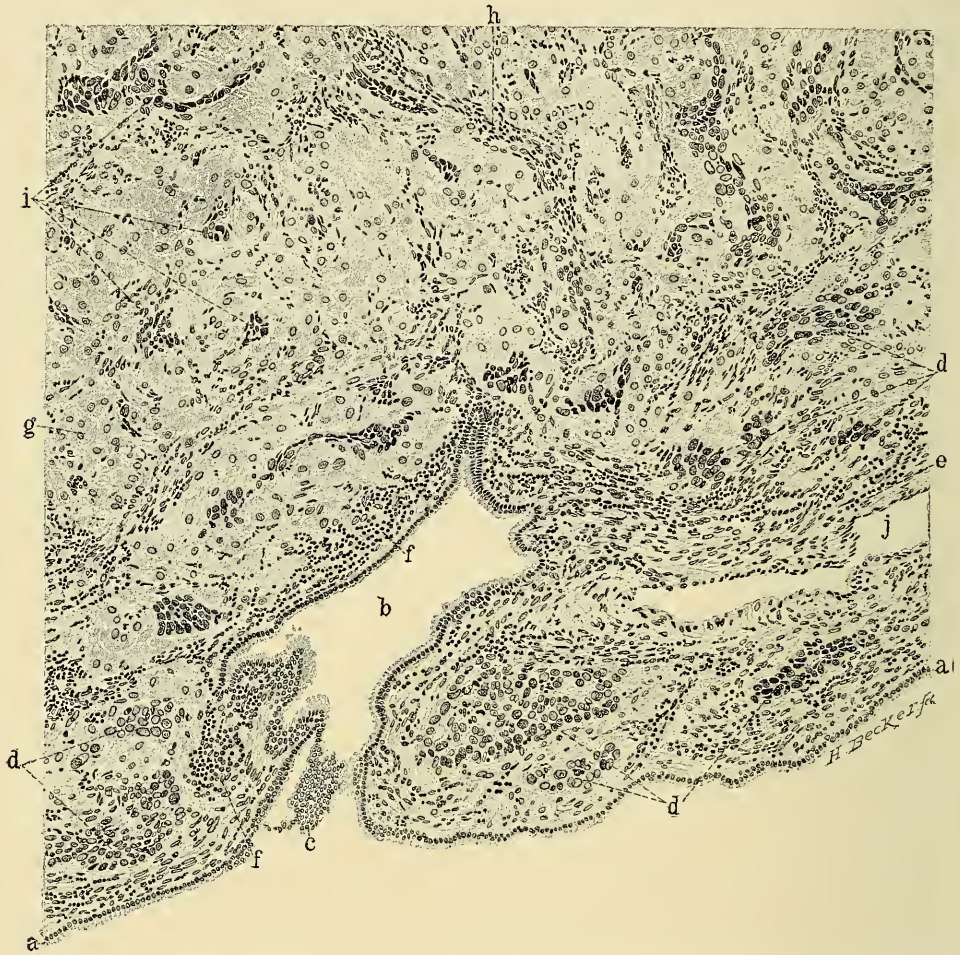


FIG. 306.—SQUAMOUS-CELL CARCINOMA OF THE CERVIX WITH DEFINITE FORMATION OF DECIDUAL CELLS FROM THE STROMA OF THE CERVIX. (110 diameters.)

Gyn.-Path. No. 1,971. The section is from Fig. 305 at point 1, midway between the external and internal os. *a* is the surface epithelium, everywhere intact. Its cells are cylindrical; the nuclei are situated at or near the bases. Opening on the surface is the gland *b*, which also shows a perfectly preserved epithelium. *c* is the tip of a gland tuft projecting upward from the under surface. Scattered throughout the tissue near the surface are nests of cancer cells indicated by the letter *d*. The nuclei of these cells are, as a rule, round or oval and fairly uniform in size, but a few are small, irregular, and deeply staining. *e* is one of the normal stroma cells containing an elongate-oval, vesicular nucleus. Scattered throughout the stroma near the surface are small round cells (*f*). In the deeper portions of the stroma a marked transformation has taken place, nearly all of the stroma cells having been transformed into decidual cells (*g*). In a few places (*h*) strands of normal stroma cells exist. The nests of cancer cells in the decidua are much compressed and are therefore smaller; their nuclei are diminished in size and stain deeply. Several such areas are indicated by *i*. *j* is a large vein. More typical decidual tissue than has here developed from the cervical stroma could not be found.

numerous venous sinuses, while in the vicinity of the muscle a few of the uterine glands are visible (Fig. 307). These are oblong or irregular in shape, and tend to

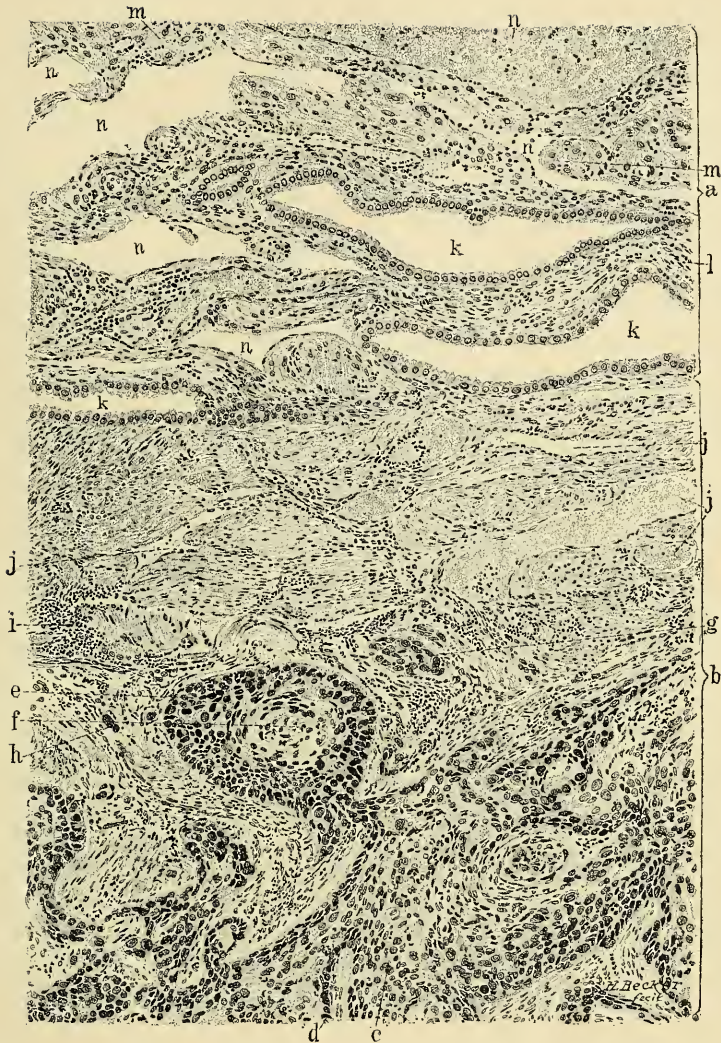


FIG. 307.—EXTENSION OF SQUAMOUS-CELL CARCINOMA OF THE CERVIX TO THE BODY OF THE UTERUS IN A CASE OF PREGNANCY. (80 DIAMETERS.)

Gyn.-Path. No. 1,971. The section is from Fig. 305 at point *z*, and is divisible into two portions: *a*, consisting of uterine mucosa; *b*, being made up of the underlying muscle. Almost the entire lower border, as indicated by *e*, is carcinomatous tissue. The outlines of the individual cells cannot be seen, but the nuclei have round, oval or elongate-oval, pale or deeply staining nuclei. Where the cancer cells are in contact with the stroma, as at *d*, they tend to be cuboidal, and stain deeply. Between the epithelial cells are a few small round cells and polymorphonuclear leucocytes. *e* is a nest of cancer cells, continuous with the larger area just described. Its nuclei vary considerably in size and shape, and stain intensely. In the central portion is a typical epithelial pearl. The cells are more spindle-shaped and have a spherical arrangement. In the centre of this pearl are a few polymorphonuclear leucocytes (*f*). *g* is a small nest of cancer cells; *h*, an isolated, deeply staining, carcinomatous cell. *i* is an area of small-round-cell infiltration of the muscle. Scattered throughout the muscle are numerous veins (*j*). *k* indicates dilated uterine glands, running parallel to, instead of at right angles to, the muscle. Their epithelium is swollen, cuboidal in shape, and stains faintly. At the muscle the stroma of the mucosa (*l*) consists of spindle-shaped cells, but nearer the surface is made up of typical decidua (*m*). *n* indicates venous sinuses.

run parallel to the surface; their epithelial lining is intact, but the nuclei are larger than usual, and are much paler; instead of being cylindrical, the cells are frequently polygonal in form. At a few points the glands extend into the depth between muscle bundles. Penetrating the underlying muscle in all directions are cell-nests of the new growth, in many of which the central portions have undergone hornification, while not infrequently the cells have dropped out. Other nests contain giant cells—large oval masses of protoplasm having ten or more nuclei bunched in their centres. The decidua in some places has been invaded by the new growth, which at such points extends to the surface. The decidua along the advancing margin of such a growth shows very marked small-round-cell infiltration. The uterine muscle along the advancing margin of the growth shows only slight signs of reaction in some places, but at other points there is much small-round-cell infiltration. The uterine mucosa throughout the upper part of the cavity appears as decidua. The muscle is considerably swollen, and its blood supply is especially abundant. The connective tissue between the different muscle bundles is very lax.

Laterally, on the right side, the growth has extended into the broad ligament; it is doubtful whether it has been entirely removed. Sections from various portions of the placenta, especially along its margin, fail to reveal any invasion by the new growth. The placental tissue is normal. The growth in the cervix is a squamous-cell carcinoma. It is interesting to note the marked involvement of the cervix, and at the same time the almost perfect preservation of the cervical surface epithelium. The pregnancy seems to have had a definite influence on the rapidity of the growth, as is evidenced by the frequent formation of small slit-like cavities by the cells, which have evidently penetrated so rapidly that they have not had time to form large nests. The lax condition of the uterine tissue, due to the pregnancy, naturally offers a diminished resistance to the penetration of the carcinomatous tissue.

The right tube presents the usual appearance. The ovary is normal, and contains what appears to be a corpus luteum of pregnancy. The individual luteal cells are fairly uniform in size, and have oval, uniformly staining nuclei, which vary considerably in size, some being fully three times as large as others. Dividing the corpus luteum up into segments are definite strands of stroma, consisting of spindle-shaped cells. The stroma contains large and small blood-vessels, which travel toward the centre of the corpus luteum. The centre consists of connective tissue poor in spindle-shaped cells. Separating the individual corpora lutea cells from one another are numerous spindle-shaped cells.

The left tube is very vascular; its mucosa is normal. The left ovary is unaltered.

January 2, 1900. For some time the patient has had a vaginal discharge, and at present is suffering from severe pains in her right side. She has not had any more hæmorrhage, but from her letter it is quite evident that there is a return of the growth. It is now two years and three months since the operation.

CHAPTER XXIV

CLINICAL PHENOMENA COMMON TO ALL VARIETIES OF CARCINOMA OF THE UTERUS

1. General appearance.
2. Hæmorrhage.
3. Watery or purulent discharge.
4. Pain.
5. Causes of emaciation.
6. Causes of cachexia.
7. Anæmia.
8. Fever.

General Appearance.—In many cases the patient, when first seen, looks perfectly well, and one would not for an instant suspect any serious trouble, whereas, on examination, the disease may be far advanced, or even inoperable. On the other hand, thin, anæmic, and cachectic women may supply some of the early and favourable cases. In brief, it may be said that, while it is often possible to form a fairly good idea from the general condition, external appearances are not infrequently very deceptive.

Hæmorrhage, as has been noted, is one of the most frequent symptoms; as a rule, it occurs early in the disease, but occasionally is absent throughout the whole course. This symptom is very easily explained. In squamous-cell carcinoma of the cervix the delicate, finger-like outgrowths are readily broken off by the slightest touch, and from the open mouths of the numerous capillaries much blood escapes. The same reason may be assigned for the free oozing occurring in adeno-carcinoma of the cervix, but here, since the growth is situated in the cervical canal, it is protected from injury, and consequently the losses of blood are not so frequent. In adeno-carcinoma of the body increased vascularity is also present, so that with the gradual necrosis and disintegration of the tissues hæmorrhage is very apt to occur.

A watery or purulent discharge is noted in practically all of the cases in the late stages. It is due to the gradual disintegration of the cells. First there is a necrosis; this is followed by polymorphonuclear leucocytic infiltration, and the tissue gradually melts away. The same process is found whether the growth be situated in the cervix or in the body; and the more extensive the growth, the more profuse the flow. Histologically, this discharge is found to consist of serum, fibrin, red blood-corpuscles, polymorphonuclear leucocytes, and necrotic cells. The yellow and profuse leucorrhœa is to a great extent dependent upon the preponderance of polymorphonuclear leucocytes. The uterine discharge is usually very offensive, and so characteristic that in the later months

one can almost make a diagnosis from the odour. It causes much irritation of the external genitals.

Pain is a variable quantity in the early stages; some patients, indeed, throughout the entire illness complain of no pain whatever. Others, even at an early period, suffer with cramp-like pains in the uterus or have frequent back-ache. As the process passes beyond the uterus and the growth presses upon the nerve trunks, the pain is no longer limited to the pelvis and back, but often extends to the thighs, knees, and even to the calves of the legs. So excruciating is the suffering in the late stages that many patients have to be kept constantly under the influence of morphia. While the greater part of the pain is undoubtedly due to pressure, yet some of it must be the result of a neuralgic condition consequent upon the progressive anæmia and the absorption of toxic substances.

Causes of Emaciation.—As the disease progresses the patient usually loses weight, but, as appears from some of our cases, the body at autopsy may still be well nourished. The loss of flesh is to some extent due to the absence of appetite which invariably belongs to the late stages. Some light has been thrown on this subject by Müller, Klemperer, and others. Müller,* in a paper published in 1889, after reviewing the findings of previous observers, deals with various factors that must be taken into consideration in determining the excretions in the sick. Not only must quantitative tests be made of the urinary and intestinal secretions, but the quantity and the quality of the substances taken as nourishment must be carefully estimated. Furthermore, he points out that it is difficult to keep patients on the same simple food for several days, and in those suffering from some chronic disease the amount taken depends largely upon the condition of the appetite. Thus, in attempting to ascertain the influence of a malignant tumour on metabolism, it will be necessary to choose those cases in which there is no complication which might modify the results. Accordingly, patients with fever or œdema will furnish no exact criteria, since in the former metabolism is increased, while in the latter it is diminished. In his experimental researches into the amount of nitrogen contained in the urine and fæces of a man fasting, Müller found in ten days an average of 10 grammes each day. In the case of a woman who was suffering from carcinoma, although the amount of nourishment taken gradually diminished, the nitrogenous products in the urine increased from day to day, so that on an average the nitrogen excreted in twenty-four hours through the urine and fæces amounted to 7.439 grammes more than that contained in the ingesta. In summing up his results, Müller says that the nitrogenous excretion exceeded the amount received in the nourishment—in other words, the body was losing its albuminous contents.

In the seven cases of cancer reported this loss was manifested. In two the amount lost was not greater than occurred in healthy individuals receiving a similar insufficiency of nourishment, but in the remaining five the excretion was more abundant than in healthy individuals under corresponding conditions.

* Müller, F. *Stoffwechseluntersuchungen bei Krebskranken. Zeitschr. f. klin. Med.*, 1889, Bd. xvi, S. 496.

Müller also showed that it was impossible to counteract the loss by abundant nourishment. The amount of nitrogenous excretion increased with the increase of food.

Klemperer,* who has worked along the same lines, substantiates Müller's results. In six of the eight cases of carcinoma examined by him he found an increased nitrogenous excretion.

According to Lubarsch,† von Noorden examined the stomach contents of five very sick patients suffering from carcinoma of the uterus, and in none did he find free hydrochloric acid in the gastric juice. In seven other cases the normal amount was present.

Causes of the Cachexia.—While the emaciation and cachexia usually go hand in hand, it is no rare occurrence to find marked cachexia, even though the patient may be still richly supplied with adipose tissue. There are several factors which doubtless are concerned in the production of the yellowish, waxy condition. In the first place, the hæmorrhages are frequent, and consequently an anæmia is present. This is still further increased owing to the steady diminution in the appetite. The continuous uterine discharge also has its effect. But certainly one of the most important factors is the absorption of poisonous products from the degenerating portions of the growth, producing, as Lubarsch aptly says, a form of auto-intoxication.

Anæmia.—In the early stages of the disease this is rarely noted, the blood being found to present apparently little alteration. With the progress of the growth, however, numerous changes are noted.

According to Lubarsch, who has collected the literature, the changes are: (a) chemical; (b) alterations in the red and white corpuscles; (c) changes in the serum.

The blood becomes more watery, deficient in hæmoglobin, and an actual diminution in number of the red and white corpuscles is noted. Lubarsch found a diminished alkalescence of the blood in carcinoma of the uterus. Einhorn says that there is an increase in the number of leucocytes, and thinks that this is due to an irritation of the lymph glands. Schneider, in twelve cases, found a marked increase in the white blood-corpuscles.

To Strauer ‡ we are indebted for a most painstaking study on this point in cases of tuberculous and carcinomatous patients. He counted the number of red and white blood cells, and estimated the amount of solid substances in the blood. One gramme of blood was first weighed in a closed glass dish. After being placed in a vacuum and dried over concentrated sulphuric acid for two or three days, it was again weighed and the percentage of solid material determined. To estimate the solids in the serum alone, 1 gramme of blood was placed in a second vessel so tilted that in the coagulation the serum separated from the coagulum. On the second day the serum was pipetted off into a third glass. It was then

* Klemperer, G. *Stoffwechselversuche an Krebskranken. Charité-Annalen*, 16. Jahrg., S. 138.

† Lubarsch, O. *Ergebnisse der allgemeinen pathologischen Morphologie und Physiologie des Menschen und der Tiere.* Lubarsch u. Ostertag, Wiesbaden, 1895.

‡ Strauer, O. *Systematische Blutuntersuchungen bei Schwindsüchtigen und Krebskranken. Zeitschr. f. klin. Med.*, 1894, Bd. xxiv, S. 295.

weighed and dried over concentrated sulphuric acid. The normal percentage of solids according to his results were :

For the blood.....	21.5 per cent.
For the serum.....	10.75 " "

The blood was always obtained from a vein of the forearm, and Strauer pointed out, as other observers have done, that it is important to always remove the specimen from the same part of the body. He reports (p. 310) an inoperable carcinoma of the uterus in a patient forty-two years of age. There was but little wasting of the muscles or fat, and no fever. The entire vaginal portion of the cervix bled on the slightest touch. A complete examination of the blood gave the following results :

May 2, 1893.

Red blood-corpuses.....	3,500,000
Leucocytes.....	12,000
Solid constituents of the blood.....	16.54 per cent.
Specific gravity.....	1044

On May 13th a second examination gave :

Red blood-corpuses.....	4,400,000
Leucocytes.....	12,000
Solid constituents of the blood.....	17.33 per cent.
Solid constituents of the serum.....	10.98 " "

Strauer also gives details of the case of a woman suffering from an inoperable cancer of the uterus; her skin had a jaundiced appearance, and she had occasional fever.

Red blood-corpuses.....	1,500,000
Leucocytes.....	10,000
Solid constituents of the blood.....	17.07 per cent.
Solid constituents of the serum.....	9.55 " "
Specific gravity.....	1043

In this country very careful observations concerning the condition of the blood in cases of carcinoma have been made by Sailer and Taylor,* of the Pepper Laboratory in Philadelphia. They report on 22 cases, of which 3 were carcinomata of the uterus.

In their Case IX they found the following :

Hæmoglobin.....	30 per cent.
Red corpuses.....	3,600,000
Leucocytes.....	10,000

Differential count :

Neutrophilic polymorphonuclears.....	76.2 per cent.
Oxyphilic polymorphonuclears.....	.6 " "
Mononuclears and transitionals.....	9.8 " "
Lymphocytes.....	13.4 " "

* Sailer and Taylor. *The condition of the Blood in the Cachexia of Carcinoma. Internat. Med. Mag.*, 1897. vol. vi, p. 404.

In Case XI :

Hæmoglobin	23 per cent.
Red blood-corpuses.....	1,856,125
Leucocytes.....	18,750

Differential count :

Neutrophilic polymorphonuclears.....	76.5 per cent.
Oxyphilic polymorphonuclears.....	1 " "
Mononuclears and transitionals.....	12.5 " "
Lymphocytes.....	10 " "

In Case XX :

Hæmoglobin	37 per cent.
Red blood-corpuses.....	2,190,000
Leucocytes.....	14,000

Differential count :

Neutrophilic polymorphonuclears.....	70.5 per cent.
Oxyphilic polymorphonuclears.....	2.5 " "
Mononuclears and transitionals.....	12.5 " "
Oxyphilic mononuclears.....	.5 " "
Lymphocytes.....	14 " "

In these cases there was cachexia, and it is interesting to note the diminished number of the reds and the slight leucocytosis. Sailer and Taylor point out that the excess of the mononuclear and transitional forms occurred mainly at the expense of the lymphocytes.

Thus we learn that the poverty of the blood is more marked with the progress of the disease. While patients in the early stages show only a slight deterioration, the cachectic individuals reveal an important diminution in the number of red blood-corpuses, in the percentage of albumin, and in the specific gravity of the blood. In most of the cases there is a leucocytosis.

Cabot,* in his text-book, gives an admirable chapter on the condition of the blood in malignant disease. In most cases the specific gravity shows a reduction corresponding with the diminution in the hæmoglobin. The number of red blood-corpuses in the early stage is nearly normal. In the 75 cases which came under his observation, there were at the beginning of the treatment, on an average, 4,140,000 red corpuses to the cubic millimetre.

In 48 cases of malignant tumour he found on an average 54 per cent of hæmoglobin. The highest figures in the cases of this series were 100 and 90 per cent of hæmoglobin respectively; the lowest, 20 per cent.

As the disease progresses the red blood-corpuses and hæmoglobin steadily diminish, so that at death a count of 1,000,000 cells to the cubic millimetre is not rare.

According to Cabot, the individual red cells are frequently diminished in diameter, the very large forms seen in pernicious anæmia being rare in the anæmia of malignant disease. Nucleated red corpuses are usually found in advanced cases; these are generally of the normoblastic type, but in very cachectic cases Cabot has found myeloblasts, although these were less abundant than

* Cabot, R. C. *Clinical Examination of the Blood*, 1897, p. 287.

the normoblasts. The same author found that in the following cases of carcinoma of the uterus admitted to the Massachusetts General Hospital there was a leucocytosis.

Cancer of the Uterus

CASE.	Age.	Red cells.	White cells.	Percentage of hæmoglobin.	Remarks.
1.....	48	2,696,030	19,400	20	October 26th.
		3,232,000	30,700	27	October 28th.
2.....	51	34,900	Differential count of 1,000 cells; polymorphonuclears, 88 per cent; small lymphocytes, 11.7; eosinophiles, 2 per cent; myelocytes, .1 per cent; 2 normoblasts.
3.....	31	2,889,680	22,250		

Fever.—In the late stages it is not uncommon for the patient to have an elevation of temperature of the remittent type. This can readily be traced to the absorption of portions of the decomposing tumour. Were it not that the uterus is so situated that drainage is easy, elevations of temperature would undoubtedly be more frequent.

CHAPTER XXV

PROGNOSIS

1. Reliability of statistics.
2. Recurrence.
3. Prolapse of the Fallopian tube.
4. Granulation tissue around silk ligatures.
5. Squamous-cell carcinoma of the cervix :
 1. Final results in cases in which hysterectomy was performed.
 2. Analysis of the successful cases.
 3. Tabulation of cases coming too late for complete removal of the uterus.
 4. Cases which came to autopsy.
 5. Summary of cases of squamous-cell carcinoma of the cervix.
6. Adeno-carcinoma of the cervix :
 1. Ultimate results after hysterectomy.
 2. Cases that came too late for removal of the uterus.
 3. Summary of cases of adeno-carcinoma of the cervix.
7. Adeno-carcinoma of the body of the uterus :
 1. Final results in cases in which hysterectomy was performed.
 2. Analysis of the successful cases.
 3. Nature of operation in the successful cases.
 4. Cases coming too late for complete removal of the uterus.
8. General summary of all the cases of carcinoma of the uterus.

THE statistics of operations for carcinoma of the uterus offer many uncertainties. In some instances the surgeons have run but little risk, picking out merely those cases which were in the earliest stages. Thus they have been able to report a goodly percentage of recoveries. On the other hand, there are those who disregard the question of statistics altogether, and are content to operate provided there is the slightest possibility of saving the patient. With the latter group we are in thorough sympathy, although their records naturally show more failures. It is clearly the duty of every surgeon to take advantage of any reasonable chance of benefiting the patient. Little would be gained by quoting a long array of statistics, and we shall content ourselves with reporting briefly the results obtained in the Johns Hopkins Hospital, leaving aside the question of the exact number of permanent cures effected, inasmuch as our cases date back only six or seven years.

To the clinician and pathologist alike the ultimate result of the operation is of the greatest interest, since it is only after a careful study of numerous instances and an analysis of the subsequent histories that one can venture upon even a provisional prognosis. In all of our cases letters have been sent to the doctors who originally referred the patients to the hospital, and with very few exceptions a prompt and full report has been received. Some patients came to the hospital unaccompanied by a physician, and the majority of these we have also been able to locate; but in a few instances letters, after travelling from place to place, were returned unopened. As the prognosis in nearly all of these unlocated patients

was unfavourable, we have thought it wiser to be on the safe side, and include them among the dead.

Recurrence.—In nearly all such cases the return was local, the first manifestation being a return of the hæmorrhages. In a certain number, however, no bleeding occurred, and suspicion was first aroused by a gradually increasing debility of the patient. Digital examination revealed hard, nodular, or diffuse thickening in the vaginal vault and extending to the broad ligaments. The subsequent history was similar to that noted in inoperable cases. The following was the only one of our cases in which metastases took place without evidence of a local return of the growth.

Case 5,782 (p. 459) was a very early adeno-carcinoma of the body of the uterus, and a favourable prognosis was rendered. The patient remained well for over a year, but suddenly the inguinal, axillary, and cervical glands became enlarged, and she died twenty months after operation.

Prolapse of the Fallopian Tube.—On examining the vaginal vault several weeks after operation, one is occasionally surprised to find a red, congested area in one or other angle of the incision. On palpation, its surface is found to be smooth, velvety, and does not show the slightest tendency to bleed. We have had at least three such instances in the hospital, and on careful examination the condition was found to be due to prolapse of the fimbriated extremity of the Fallopian tube.

Granulation Tissue around Silk Ligatures.—When studying the various steps in vaginal and abdominal hysterectomy, it was noted that quite a number of silk ligatures were employed. We have also seen that frequently following hysterectomy there is some slight infection, and occasionally around an infected stitch in the vaginal vault granulation tissue develops. On making a vaginal examination, a soft, friable mass can be felt in the vault. This bleeds readily, but the surrounding tissue shows no induration. In these cases it is frequently possible to detect the ligatures in the midst of the newly formed tissue. In this connection the report of Dr. Duffy, in Case 2,294 (p. 98), is of interest. Such a ligature was found shortly after operation, but the patient is well six years later. It is very easy to mistake this condition for a return of the growth.

Final Results in Cases of Squamous-cell Carcinoma of the Cervix in which Hysterectomy was Performed

INITIAL AND DATE.	Gyn. No.	Gyn-Path. No.	Nature of operation.	RESULT.	
				Immediate.	Final.
L., Oct., 1893. .	2,248	62	Abdominal hysterectomy (ligation of both internal iliac arteries).	Growth not entirely removed.	Death ten months later.
H., Nov., 1893.	2,294	78	Vaginal hysterectomy.	General local condition much improved.	January 6, 1900, Patient cured; length of time since operation, six years and two months.
M., Nov., 1893.	2,415	93	Combined vaginal and abdominal hysterectomy.	Recovery.	Recurrent nodules removed from vaginal vault seven months later; patient died of pneumonia, February, 1895.
D., Dec., 1893.	2,452	109	Vaginal hysterectomy.	Recovery.	January 1, 1900, Perfectly well; length of time since operation, six years.

Final Results in Cases of Squamous-cell Carcinoma of the Cervix—(Continued)

INITIAL AND DATE.	Gyn. No.	Gyn.-Path. No.	Nature of operation.	RESULT.	
				Immediate.	Final.
S., Nov., 1893. .	2,405	94	Combined vaginal and abdominal hysterectomy.	Death on the fourth day.
W., Feb., 1894.	2,590	169	Vaginal hysterectomy.	Recovery.	Return of growth. Death, November, 1894.
J., Feb., 1894. .	2,591	172	Vaginal hysterectomy.	Recovery.	Local return in vaginal scar shortly after leaving the hospital. Death, June 3, 1894.
C., Feb., 1894. .	2,572	173	Vaginal hysterectomy.	Recovery.	Marked local return. Death, September 17, 1897.
O., March, 1894	2,624	192	Vaginal hysterectomy.	Recovery.	Rapid return in vaginal vault and laterally. Death, November, 1894.
E., March, 1894	2,627	198	Vaginal hysterectomy.	Recovery.	Death, eight months later, of gradual asthenia.
L., July, 1894. .	2,928	388	Combined vaginal and abdominal hysterectomy.	Death on the ninth day.
E., Oct., 1894. .	3,114	481	Incomplete vaginal and abdominal hysterectomy.	Improved.	Death, three months after operation.
H., Oct., 1894. .	3,126	493	Combined vaginal and abdominal hysterectomy.	Recovery.	Patient died of exhaustion, two months after leaving the hospital.
D., Dec., 1894.	3,243	549½	Vaginal hysterectomy.	Recovery.	Return of the growth. Death, two and a half years after operation.
H., March, 1895	3,348	625	Abdominal hysterectomy.	Death, a few days after operation.
H., May, 1895.	3,370	709	Abdominal hysterectomy.	Recovery.	There was a return of the growth, and the patient has since died.
Y., June, 1895.	3,563	741	Abdominal hysterectomy.	Recovery.	Patient cannot be located.
H., Jan., 1896. .	(Dr. Noble)	770 and 888	Vaginal hysterectomy.	Recovery.	No return of the growth. Patient died of pneumonia, December 14, 1896.
W., June and Nov., 1895 . .	3,595	773	Vaginal hysterectomy.	Recovery.	Return of the growth noted shortly after operation.
H., June, 1895.	3,609	784	Combined vaginal and abdominal hysterectomy.	Death on the fourth day.
D., July, 1895.	3,666	813	Abdominal hysterectomy.	Recovery.	The growth reappeared, and the patient died two years and seven months after operation.
N., Sept., 1895.	3,698	832	Vaginal hysterectomy.	Recovery.	Examination, May 6, 1896. Recurrence noted in the vaginal vault.
P., Oct., 1895. .	3,813	901	Abdominal hysterectomy; removal of pelvic lymph glands.	Recovery.	On examination, August 17, 1896, recurrence was noted in the vaginal vault.
M., April, 1894.	2,695	244	Attempted abdominal hysterectomy; curettage; removal of appendages on both sides.	Growth not entirely removed.	
R., Aug., 1894.	2,964	418	Combined vaginal and abdominal hysterectomy.	Recovery.	Local return of the growth. Death due to pulmonary hæmorrhage, four years and two months after operation.

Final Results in Cases of Squamous-cell Carcinoma of the Cervix—(Continued)

INITIAL AND DATE.	Gyn. No.	Gyn-Path. No.	Nature of operation.	RESULT.	
				Immediate.	Final.
K., Feb., 1895.	3,222	597	Combined vaginal and abdominal hysterectomy.	Improved: growth not entirely removed. Recovery.	
D., Oct., 1895..	3,888	924	Abdominal hysterectomy, with removal of pelvic lymph glands.	Recovery.	No answer received.
C., Nov., 1895.	3,930	957	Abdominal hysterectomy.	Recovery (unfavourable prognosis). Recovery.	Not located.
H., Jan., 1896.	4,056	1,032	Abdominal hysterectomy; removal of pelvic lymph glands.		Dr. D. L. Harrell, of Harrell, Va., informs me that the growth reappeared about six months after the operation, the patient dying three months later.
P., Jan., 1896..	4,070	1,036	Complete hysterectomy; removal of pelvic lymph glands.	Patient very weak immediately after operation; gradually improved. Death, on the thirtieth day.
E., Feb., 1896.	4,143	1,070	Abdominal hysterectomy; removal of pelvic lymph glands.	Recovery.	The hæmorrhages continued from the time the patient left the hospital until her death, two months later.
LeC., Feb., 1896	4,176	1,090	Abdominal hysterectomy.	Recovery.	The patient died seven months after leaving the hospital; great suffering, evidently a return of the growth.
H., April, 1896	4,279	1,138	Abdominal hysterectomy (radical).	Improved.	January 13, 1900. The patient says she has great pain in the back and hips, and that large clots frequently pass from the vagina. In July last she had a very severe hæmorrhage, losing a great quantity of blood, and her doctor found it very difficult to stop the bleeding. Shortly after her urine commenced to pass involuntarily, evidently owing to a vesico-vaginal fistula. There is now a continual discharge of urine. Her letter shows conclusively that there is a return of the growth, but the patient is still alive, three years and nine months after the operation.
J., May, 1896..	4,328	1,194	Hysterectomy (radical).	Recovery.	Could not be located.
C., June, 1896.	4,430	1,211	Abdominal hysterectomy.	Death on the eleventh day.
G., July, 1896..	4,489	1,244	Abdominal hysterectomy.	Recovery.	The patient shows no evidence of return of the growth. Length of time since operation, three years and six months.
K., Aug., 1896.	4,545	1,272	Abdominal hysterectomy; removal of pelvic lymph glands.	Improved (prognosis bad).	The patient died in the Johns Hopkins Hospital from a recurrence in 1897, thirteen months after operation.

Final Results in Cases of Squamous-cell Carcinoma of the Cervix—(Continued)

INITIAL AND DATE.	Gyn. No.	Gyn-Path. No.	Nature of operation.	RESULT.	
				Immediate.	Final.
S., Nov., 1896..	Gen. Hosp. No. 17,487	1,376	Abdominal hysterectomy.	Recovery.	A relative informs me that for a month after leaving the hospital the patient appeared to be improving, but the growth soon returned. "Her suffering was terrible." She died July 9, 1897, eight months after operation.
R., Nov., 1896.	4,806	1,384 and 1,396	Abdominal hysterectomy.	Recovery.	January 4, 1900. The patient writes: "I am only too glad to tell you I know my life has been prolonged by my operation. I am in very good health. I have not had any hæmorrhages at all." Length of time since operation, three years and one month.
S., Jan., 1897..	4,976	1,507 and 1,533	Incomplete abdominal hysterectomy.	Patient died on the thirteenth day.
F., May, 1897..	5,203	1,676	Incomplete abdominal hysterectomy.	Growth not entirely removed.	
B., May, 1897..	5,251	1,699	Abdominal hysterectomy.	Recovery.	December 28, 1899. Dr. E. C. Peterson, of Baltimore, informs me that the patient has had no hæmorrhages, but that there is some pelvic trouble, probably a return of the growth.
A., June, 1897.	5,266	1,764	Abdominal hysterectomy.	Recovery.	January 9, 1900. Dr. R. B. Norment writes that the patient's general condition is "excellent." The "patient is in better condition than she had been for years previous to the operation." Length of time since operation, two years and seven months.
G., July, 1897..	Sanatorium.	1,832	Abdominal hysterectomy.	Recovery.	June 29, 1899. Examination showed a return of the growth in the vaginal vault two years after operation.
L., Sept., 1897.	5,541	1,919 and 1,933	Abdominal hysterectomy.	Improved.	The husband writes me that the patient died shortly after leaving the hospital. She did not regain her strength, but rapidly wasted away.
A., Oct., 1897..	5,575	1,936	Abdominal hysterectomy.	Improved.	January 8, 1900. Dr. E. H. Parsons, of Piedmont, W. Va., writes me that the patient "seems to be in perfect health." There is no evidence of a return of the growth. She has had no hæmorrhages. There is a ventral hernia, three inches in diameter, at the site of the abdominal scar. Length of time since operation, two years and three months.

Final Results in Cases of Squamous-cell Carcinoma of the Cervix—(Continued)

INITIAL AND DATE.	Gyn. No.	Gyn.-Path. No.	Nature of operation.	RESULT.	
				Immediate.	Final.
C., July, 1897..	5,398	1,971	Cæsarean section, followed by abdominal hysterectomy.	Recovery.	January 2, 1900. From the patient's letter there is evidently a return of the growth. Length of time since operation, two years and three months.
S., Dec., 1897..	5,727	2,024	Abdominal hysterectomy.	Recovery.	January 10, 1900. Dr. William T. Watson, of Baltimore, writes me that there is a return of the growth. The patient is confined to her room, and one leg and thigh are very much swollen; locomotion is difficult.
W., Feb., 1898.	5,853	2,142 and 2,151	Abdominal hysterectomy.	Recovery.	December 30, 1899. Dr. W. S. Love, of Winchester, Va., informs me that there is no evidence of a return of the growth. The patient's general condition is "very good." "She has gained in weight, and in general appearance is the picture of health." Length of time since operation, one year and ten months.
P., April, 1898.	5,959	2,263	Combined vaginal and abdominal hysterectomy.	Recovery.	December 22, 1899. The patient is "perfectly well," one year and nine months since operation.
S., April, 1898.	Sanatorium.	2,319	Abdominal hysterectomy.	Recovery.	December 2, 1899. The patient's husband writes that she is permanently confined to her room, and that she suffers a great deal at times and is much reduced in flesh. There is every reason to believe that the growth has returned.
A., May, 1898.	6,062	2,338 and 2,378	Vaginal hysterectomy.	Improved.	January 6, 1900. Dr. James McGee, of Raleigh, N. C., informs me that there was a return of the growth, and that the patient had intense pain. Death, which took place June 4, 1899, was due to peritonitis. The patient lived just thirteen months after operation.
S., June, 1898.	6,176	2,432	Vaginal hysterectomy.	Died the same night.
R., Sept., 1898.	6,368	2,611	Vaginal hysterectomy.	Improved.	January 1, 1900. Dr. A. S. Hydrick, of Orangeburg, S. C., informs me that the patient has had no hæmorrhages, and that there is not the slightest evidence of a return of the growth. She is in good health, except for vesical irritation, which requires her to urinate almost every hour. Prior to the operation there was no bladder trouble. Length of time since operation, fifteen months.

Final Results in Cases of Squamous-cell Carcinoma of the Cervix—(Continued)

INITIAL AND DATE.	Gyn. No.	Gyn-Path. No.	Nature of operation.	RESULT.	
				Immediate.	Final.
A., Oct., 1898..	6,416	2,637 and 2,652	Vaginal hysterectomy.	Dr. Thomas H. West, of Keyser, W. Va., informs me that the growth reappeared in three months. There were slight hæmorrhages; the patient gradually became emaciated, suffered a great deal, and died nine months after operation. The intestines protruded through a hernial opening in the vaginal vault.
McA., Nov., 1898.	6,492	2,706	Vaginal hysterectomy.	Recovery.	December 13, 1899. No evidence of a return. Length of time since operation, one year.
R., Dec., 1898..	Sanatorium.	2,771	Vaginal hysterectomy.	Recovery.	December 15, 1899. Dr. Kelly has just examined the patient, and finds her perfectly well. Length of time since operation, about eleven months.
R., Dec., 1898..	6,560	2,782 and 2,794	Vaginal hysterectomy.	Recovery.	December 21, 1899. The patient informs me that she has had no hæmorrhages since operation. She is perfectly well, but is continually worrying because people tell her that those suffering from cancer are never permanently cured. Length of time since operation, one year.
R., Jan., 1899..	6,656	2,890	Vaginal hysterectomy.	Recovery.	January 3, 1900. The patient has been perfectly well since the operation, and has had no hæmorrhages. On examination, the vagina is found shortened, and ends in a sharp scar in the midline, with a shallow pocket at each end. In the left angle is a soft tuft of tissue, probably due to a ligature. There is absolutely no sign of infiltration at any point. Length of time since operation, ten months. Dr. R. H. Smith, of Havre de Grace, Md., has written me since the examination was made, and the patient is still in good health.
B., Jan., 1899..	Sanatorium.	3,001 and 3,005	Vaginal hysterectomy.	Died.	
L., April, 1899.	6,831	3,072 and 3,097	Vaginal hysterectomy.	Recovery.	Dr. Horace Fritz, of Quincy, Pa., informs me that the growth reappeared about August 1st, and that the patient died just six months after the operation. He says "she was unconscious for four days prior to death." This was probably due to compression of the ureters.

From the foregoing table of 61 cases of squamous-cell carcinoma of the cervix we learn some interesting facts, but, on the whole, the results are most distressing. In 4, after starting the operation, a removal of the growth was found to be impossible, and further operative interference was abandoned. Nine patients died as a direct result of the operation. The subsequent histories of 4 could not be obtained, and these patients are probably dead, as the prognosis given at operation was unfavourable; 31 have died, or have given unmistakable evidences of a return of the growth. Thus, out of 61 patients, we have only 13 now (January, 1900) living and well. Some of the patients died shortly after leaving the hospital; others remained well for months; 1 patient (No. 2,964) lived for four years and two months, and then died from a pulmonary hæmorrhage.

Further Analysis of the Successful Operations for Squamous-cell Carcinoma of the Cervix

NAME.	Gyn. No.	Gyn.-Path. No.	Length of time since operation.	
			Years.	Months.
H.....	2,294	78	6	2
D.....	2,452	109	6	0
G.....	4,489	1,244	3	6
R.....	4,806	1,384 and 1,396	3	1
A.....	5,266	1,764	2	6
A.....	5,575	1,936	2	3
W.....	5,853	2,142 and 2,152	1	10
P.....	5,959	2,263	1	9
R.....	6,368	2,611	1	3
M. C. A.....	6,492	2,706	1	0
R.....	Sanatorium.	2,771	0	11
R.....	6,560	2,782 and 2,794	1	0
R.....	6,656	2,890	0	10

In Cases 2,294 and 2,452 we are certainly justified in saying that the patients are cured, but in the remainder the length of time that has elapsed since operation is too short to warrant any definite prognosis.

In 6 of these cases the uterus was removed *per vaginam*; in 5, by the abdominal route; in the remaining 2, combined vaginal and abdominal hysterectomy was performed.

This table of successful cases is a very small one, but such results need in no wise discourage the surgeon. In the past the patient has frequently presented herself when the disease was far advanced; furthermore, with the older operations there was a great likelihood of leaving portions of the growth behind, or of implanting carcinomatous material into healthy tissue. With the early diagnosis of the disease and the employment of Werder's operation the percentage of recoveries will be greatly increased.

Such a long list as the following, of cases in which no permanent relief could be afforded, is certainly appalling; but when the general practitioner insists upon making a vaginal examination in all cases in which a hæmorrhagic discharge is complained of—as he most certainly will in the near future—similar series of inoperable cases will only rarely be found.

Cases of Advanced Squamous-cell Carcinoma of the Cervix that came too Late for a Complete Removal of the Uterus

Gyn. No.	Date of operation.	Name.	Gyn-Path. No.	Nature of operation.
2,411.....	November, 1893	P.	89	Amputation of cervix.
2,449.....	December, 1893	M.	105	Curettagc.
2,509.....	January, 1894	F.	136	"
2,588.....	February, 1894	E.	170	"
2,599.....	February, 1894	B.	181	"
2,668½ (?).....	March, 1894	F.	216	"
	April, 1894	Van B.	241	"
2,725.....	April, 1894	M.	267	"
2,728.....	April, 1894	W.	268	"
	June, 1894	A.	348	"
2,885.....	July, 1894	D.	365	"
	July, 1894	B.	403	"
2,963.....	August, 1894	D.	415	"
2,977.....	August 15, 1894	S.	419	"
3,200.....	November 26, 1894	D.	529	"
3,229.....	December 13, 1894	T.	545	"
3,265.....	January 12, 1895	H.	567	"
3,525.....	May 25, 1895	H.	730	"
4,038.....	December 27, 1895	S.	1,022	"
4,090.....	January 27, 1896	J.	1,049	"
4,209.....	March 14, 1896	B.	1,109	"
4,281.....	April 11, 1896	G.	1,146	"
4,492.....	July 3, 1896	K.	1,246	"
4,581.....	August 17, 1896	P.	1,282	"
4,645.....	September 19, 1896	Y.	1,319	"
4,717½.....	October 17, 1896	G.	1,347	"
4,855.....	December 5, 1896	C.	1,433	"
Private.....	March 3, 1897	A.	1,597	"
5,187.....	April 19, 1897	H.	1,666	"
5,253.....	May 14, 1897	C.	1,710	"
5,413.....	August 7, 1897	M.	1,855	"
5,414.....	August 7, 1897	E.	1,859	"
5,570.....	October 12, 1897	B.	1,954	"
5,700.....	November 20, 1897	E.	2,011	"
5,717.....	November 26, 1897	C.	2,018	"
5,745.....	December 11, 1897	K.	2,042	"
5,771.....	January 5, 1898	S.	2,069	"
5,816.....	January 27, 1898	D.	2,114	"
5,833.....	January 31, 1898	J.	2,123	"
5,836.....	February 2, 1898	G.	2,130	"
5,874.....	February 17, 1898	P.	2,163	"
5,958½.....	March 21, 1898	W.	2,236	"
5,991.....	April 4 and 18, 1898	W.	2,269 and 2,301	"
6,052.....	April 25, 1898	R.	2,315	"
6,051.....	April 25, 1898	L.	2,318	"
6,073.....	May 5, 1898	W.	2,348	"
6,105.....	May 18, 1898	H.	2,368	"
6,126.....	May 28, 1898	S.	2,388	"
6,203.....	June 29, 1898	D.	2,455	"
6,271.....	August 3, 1898	R.	2,535	"
6,317½.....	August 26, 1898	A.	2,576	"
6,330.....	September 2, 1898	M.	2,584	"
6,388.....	October 3 and 18, 1898	N.	2,624	Curettagc; autopsy.
6,422.....	October 12, 1898	S.	2,647	Removal of tissue from the cervix.
6,429.....	October 15, 1898	R.	2,650	Curettagc.
	October 22, 1898	M.	2,686	"
Private.....	November 26, 1898	E.	2,757	"
6,549.....	Nov. 29 and Dec. 17, 1898	B.	2,764 and 2,800	"
6,662.....	November 30, 1898	S.	2,895	"
6,669.....	February 4, 1899	S.	2,908	"
6,761.....	March 14, 1899	L.	2,982	"
6,829.....	April 13, 1899	H.	3,075	"

Autopsies in Cases of Squamous-cell Carcinoma of the Cervix

Gyn. No.	Date of admission.	Name.	Autopsy No.	Gyn.-Path. No.
518.....	March 11, 1891	D.	178	
	July, 1895	L.	684	795
	August, 1895	J.	711	
4,047	March, 1896	D.	779	1,092
4,374.....	May, 1896	H.	810	1,203
4,491.....	July, 1896	L.	824	1,262
5,092.....	March, 1897	S.	926	1,631
6,388.....	October, 1898	N.	...	2,624

Summary of Cases of Squamous-cell Carcinoma of the Cervix

Cases in which hysterectomy was performed or attempted.....	61
Patients coming too late for operation	62
Total	123
Number of operative cases now living.....	13, or 21 per cent.

ULTIMATE RESULTS IN CASES OF ADENO-CARCINOMA OF THE CERVIX IN
WHICH HYSTERECTOMY WAS PERFORMED

Although this variety of cancer of the cervix is supposed to be comparatively rare, we have the complete records of at least sixteen cases. As will be seen from the accompanying tabulation, the prognosis in this class of cases is exceptionally grave.

INITIAL AND DATE.	Gyn. No.	Gyn.-Path. No.	Nature of operation.	RESULT.	
				Immediate.	Final.
H., March, 1894	2,625	195	Vaginal hysterectomy.	Recovery.	The patient died suddenly five months after operation.
H., March, 1894	2,631	199	Vaginal hysterectomy.	Died on the seventh day.
G., May, 1894..	2,782	308	Abdominal hysterectomy.	Recovery.	December 22, 1898. The patient is perfectly well. five years and seven months after operation.
Z., Aug., 1894.	2,990	427	Vaginal hysterectomy.	Recovery.	November, 1899. The patient is well. No evidence of a return, five years and three months after operation.
H. May, 1895.	3,356	619	Combined vaginal and abdominal hysterectomy.	Recovery.	Local recurrence; death, four years and one month after operation.
P., April, 1895.	3,452	685	Abdominal hysterectomy.	Improved; growth not entirely removed.	
E., July, 1895.	3,616	787	Abdominal hysterectomy.	Recovery.	Death, from a local recurrence, four years and one month after operation.
G., Sept., 1895.	3,693	828	Abdominal hysterectomy.	Improved.	January 6, 1900. Dr. C. A. Spencer, of Centre Moreland, Pa., writes as follows: "The patient had albumen in the urine when she returned here, and continued weak and anæmic, with bad nutrition. She died about one year after with general dropsy."

INITIAL AND DATE.	Gyn. No.	Gyn.-Path. No.	Nature of operation.	RESULT.	
				Immediate.	Final.
C., Nov., 1895..	3,923	951	Abdominal hysterectomy, with removal of pelvic lymph glands.	Recovery.	The patient died just three months after leaving the hospital.
N., March, 1896	4,228	1,117	Combined vaginal and abdominal hysterectomy.	Death on the table, apparently due to the anæsthetic.	
C., Oct., 1896..	Sanatorium.	1,611	Abdominal hysterectomy; growth not entirely removed.	Patient lived four months.
F., Feb., 1898..	5,821	2,145	Abdominal hysterectomy.	Recovery.	The patient could not be located.

From an analysis of this table we learn that 2 patients died as a result of the operation: 1 on the table from the anæsthetic, the other on the seventh day. In 2 it was evident at the time of operation that the growth had not been entirely removed; 5 patients showed a recurrence, 1 dying three months after leaving the hospital, another five months subsequent to reaching home. In two instances the patients died from local recurrences, four years and one month after operation; the subsequent history of 1 patient could not be obtained. Two women are still living and well, the one five years and seven months after operation, the other five years and three months after removal of the uterus. Thus, out of 12 cases of adeno-carcinoma of the cervix we are only positive that 2 are still living and well.

Cases of Adeno-carcinoma of the Cervix that came too Late for a Radical Operation

GYN. No.	Date of operation.	Name.	Gyn.-Path. No.	Nature of operation.
2,954.....	July 30, 1894	B.	407	Curettagé.
3,036.....	September 13, 1894	S.	445	"
3,712.....	September 12, 1895	L.	838	"
5,281.....	May 24, 1897	J.	1,739	"
6,170.....	June 21, 1898	M.	2,433	"
<i>Autopsy</i>				
	June 22, 1896	W.	1,229	Autopsy No. 813

Summary of Cases of Adeno-Carcinoma of the Cervix

In 12 cases hysterectomy was performed; only 2 (16 per cent) of the patients are known to be living; 6 came too late for operation.

FINAL RESULTS IN CASES OF ADENO-CARCINOMA OF THE BODY OF THE
UTERUS IN WHICH HYSTERECTOMY WAS PERFORMED

The following record of the final results are of importance, since it is in adeno-carcinoma of the body of the uterus that the most satisfactory results may be looked for.

INITIAL AND DATE.	Gyn. No.	Gyn- Path. No.	Nature of operation.	RESULT.	
				Immediate.	Final.
G., Dec., 1893.	2,436	100	Vaginal hysterectomy.	Recovery.	January 1, 1900. Condition excellent. Length of time since operation, six years.
D., June, 1894.	2,813	322	Attempted abdominal hysterectomy; removal of appendages on both sides; growth not removed.		
A., June, 1894.	2,817	321	Combined vaginal and abdominal hysterectomy.	Recovery.	February 6, 1900. Dr. A. S. Mason, of Hagerstown, Md., writes as follows: "To-day Mrs. A. called to see me, and I made a careful examination, both digital and with speculum. I find the vaginal incision in a perfectly healthy condition, the resultant cicatrix soft and smooth. Mrs. A.'s condition to-day is one of absolute health." Length of time since operation, five years and seven months.
A., June, 1894.	2,832	345	Abdominal hysterectomy (amputation at the cervix).	Recovery.	January 1, 1900. The patient is well. Length of time since operation, five years and six months.
P., July, 1894.	2,934	392	Abdominal hysterectomy.	Recovery.	December 16, 1899. The patient is perfectly well. Length of time since operation, five years and four months.
A., Jan., 1895.	3,258	559	Abdominal hysterectomy (amputation at the cervix).	Recovery.	Return of growth. Death, October 17, 1896.
M., June, 1895.	Sanatorium.	780	Abdominal hysterectomy (amputation at the cervix).	Recovery.	Return of growth; death, on January 24, 1898.
G., Nov., 1895.	3,967	979	Abdominal hysterectomy (radical).	Recovery.	January 24, 1900. Dr. E. S. Ash, of Wadesboro, N. C., writes me that the patient's general condition is "very good." There is no evidence of a return of the growth. Length of time since operation, four years and two months.
A., Nov., 1895.	Sanatorium.	944	Vaginal hysterectomy.	Recovery.	December 1, 1899. The patient is perfectly well. Length of time since operation, four years.
M., Jan., 1896.	Dr. Eccles	1,124	Vaginal hysterectomy.	Recovery.	The growth returned, and the patient died eight months after operation.

INITIAL AND DATE.	Gyn. No.	Gyn-Path. No.	Nature of operation.	RESULT.	
				Immediate.	Final.
N., March, 1896	4,232	1,129	Vaginal hysterectomy.	Death.	
P., April, 1896.	4,262	1,133 and 1,137	Abdominal hysterectomy.	Recovery.	December 22, 1899. The patient is well, three years and eight months after operation.
R., April, 1896.	Dr. Eccles	1,154 and 1,192	Vaginal hysterectomy.	December 25, 1899. No return of the growth, three years and eight months since operation.
W., Oct., 1896.	4,665	1,332	Abdominal hysterectomy.	Improved. Unfavourable prognosis given.	Patient could not be located.
W., May, 1896.	Sanatorium.	1,349	Abdominal hysterectomy; cystectomy.	Recovery.	January 21, 1900. Dr. Mary Sherwood writes that the patient is in fair physical condition, but that she has never felt quite so strong as before. There has been no return of the discharge. Length of time since operation, three years and seven months.
C., June, 1896.	Sanatorium.	1,350	Abdominal hysterectomy.	Recovery.	December 16, 1899. Dr. Kelly has just heard from this patient. She is in good health, and gives no symptoms of a return of the growth. Length of time since operation, three years and five months.
G., Oct., 1896..	4,745	1,358	Vaginal hysterectomy.	Recovery.	December 1, 1899. The patient is in excellent health, and there is not the slightest evidence of a return of the growth. Length of time since operation, three years and one month.
S., Oct., 1896..	4,746	1,359	Vaginal hysterectomy.	Recovery.	December 28, 1899. Dr. William P. Beall, of Greensboro, N. C., writes me that there is no evidence of a return of the growth. The patient has had no hæmorrhages since the operation. Her general condition is "first rate; health better than for years before operation. She is gaining flesh." Length of time since operation, three years and two months.
P., Nov., 1896.	Sanatorium.	1,412 and 1,414	Abdominal hysterectomy, with removal of pelvic lymph glands.	Recovery.	September 1, 1899. The patient is well, two years and nine months after operation.
S., Jan., 1897..	4,922	1,473	Abdominal hysterectomy.	Recovery.	December 28, 1899. The patient is in "excellent condition." Length of time since operation, one year and eleven months.
K., Jan., 1898..	5,782	2,075 and 2,084	Abdominal hysterectomy (radical).	Recovery.	Death, twenty months later, with involvement of inguinal, axillary, and cervical lymph glands.

INITIAL AND DATE.	Gyn. No.	Gyn-Path. No.	Nature of operation.	RESULT.	
				Immediate.	Final.
H., Feb., 1898.	5,858	2,119 and 2,146	Abdominal hysterectomy.	Death.	
S., Feb., 1898..	5,876	2,161 and 2,183	Vaginal hysterectomy.	Recovery.	December 21, 1899. Dr. J. Edward Smoot, of Concord, N. C., writes me that the patient regained her strength in five or six months. For ten weeks after operation there was a blood-tinged vaginal discharge. On only one occasion was there any hæmorrhage. This was slight, and followed a tedious buggy ride three or four months after operation. "The patient is now in better health than she has been for several years." Length of time since operation, one year and ten months.
B., March, 1898	5,957	2,238	Abdominal hysterectomy.	Recovery.	December 27, 1899. No return of hæmorrhages; patient feels well. Length of time since operation, one year and nine months.
A., April, 1898.	6,008	2,279 and 2,283	Abdominal hysterectomy.	Recovery.	January 20, 1900. The patient writes that, so far as she knows, she is "perfectly well." Length of time since operation, one year and eight months.
C., Nov., 1898.	6,535	2,291 and 2,750	Abdominal hysterectomy.	Recovery.	No evidence of a return of the growth. Length of time since operation, thirteen months.
S., Oct., 1898..	6,448	2,672	Abdominal hysterectomy.	Improved.	Dr. E. A. Ward, of Hedgesville, W. Va., writes me that the growth reappeared six weeks after the patient left the hospital. She died in the middle of March, 1899, about five months after operation.
C., Jan., 1899..	6,581	2,797	Combined vaginal and abdominal hysterectomy.	Recovery.	December 16, 1899. Examination showed no evidence of a return of the growth, eleven months after operation.
D., Nov., 1898.	Sanatorium.	2,867	Abdominal hysterectomy.	Patient very ill when admitted. Removal incomplete.	Death on the sixth day.
L., Jan., 1899..	6,659	2,897	Vaginal hysterectomy.	Recovery.	December 22, 1899. Patient is free from a return, eleven months after operation.

From the preceding table of 30 cases of adeno-carcinoma of the body of the uterus we learn that 3 died as a result of the operation; 6 succumbed to local recurrences at periods varying from five months to two years and seven months after the removal of the uterus; 1 could not be located. The remaining 20, so far as we can judge, are free from cancer.

Further Analysis of the Cases of Adeno-carcinoma of the Body of the Uterus, in which the Patients are still Living and Well

In this tabulation we give the exact length of time that has elapsed since the uterus was removed.

NAME.	Gyn.-Path. No.	Gyn. No.	Number of years since operation in the successful cases.	
			Years.	Months.
G	100	2,436	6	0
A	321	2,817	5	6
A	345	2,832	5	6
P	392	2,934	5	4
A	944	(Sanatorium.)	4	0
G	979	3,967	4	2
P	1,133 and 1,137	4,262	3	8
R	1,154 and 1,192	(Dr. Eceles.)	3	8
W	1,349	(Sanatorium.)	3	7
C	1,350	(Sanatorium.)	3	5
G	1,358	4,745	3	0
S	1,359	4,746	3	2
P	1,412 and 1,414	(Sanatorium.)	2	9
S	1,473	4,922	1	11
S	2,161 and 2,183	5,876	1	10
B	2,238	5,957	1	9
A	2,279 and 2,283	6,008	1	8
C	2,291 and 2,750	6,535	1	1
C	2,797	6,581	0	11
L	2,897	6,659	0	11

Even taking it for granted that the 1 patient, whose subsequent history could not be obtained, is dead, we still have 20 out of the 30, or 66 per cent, showing no evidence of a return of the growth at the present time.

Nature of Operation in the Twenty Successful Cases

- In 6, vaginal hysterectomy.
- In 12, abdominal hysterectomy.
- In 2, combined vaginal and abdominal hysterectomy.

Cases of Adeno-carcinoma of the Body of the Uterus too far Advanced to allow of the Removal of the Organ

GYN. No.	Date of operation.	Name.	Gyn.-Path. No.	Nature of operation.
.....	October, 1894	H.	161	Curettage.
4,611.....	November 14, 1895	S.	969 and 1,311	"
5,075.....	September 5, 1896	R.	1,574	"
	March, 1897			

Autopsies in Advanced Cases of Adeno-carcinoma of the Body of the Uterus

GYN. No.	Date of admission.	Name.	Autopsy No.	Gyn.-Path. No.
2,634 ..	March, 1894	S.		222
6,581. . .	October, (?) 1898	H.	1,220	2,808

Summary of Results in Thirty-five Cases of Adeno-carcinoma of the Body of the Uterus

The uterus was removed in 30 cases; 20 (66 per cent) women are now living and well. Five patients came too late for hysterectomy.

GENERAL SUMMARY OF THE CASES OF CARCINOMA OF THE UTERUS*

VARIETY OF CARCINOMA.	Operative cases.	Patients well, January 1, 1900.
Squamous-cell carcinoma of the cervix.....	61	13 = 21 per cent.
Adeno-carcinoma of the cervix.....	12	2 = 16 "
Adeno-carcinoma of the body of the uterus.....	30	20 = 66 "
<i>Cases Coming too Late for Operation</i>		
Squamous-cell carcinoma of the cervix.....	62	
Adeno-carcinoma of the cervix.....	6	
Adeno-carcinoma of the body.....	5	
Total	176	

The prognosis is most favourable in adeno-carcinoma of the body; least promising in adeno-carcinoma of the cervix.

Although it may be well, before the operation, to inform the relatives in a general way as to the chances for the patient, it is never safe, under any circumstances, to give a positive prognosis. In quite a number of cases in which the disease is apparently in a very early stage, when the abdomen is opened, it is found impossible to remove the entire carcinomatous tissue. On the other hand, reference to the records shows that in some instances, despite the fact that the diseased tissue extended almost to the cut surface of the uterus and a most unfavourable prognosis was rendered, several of the patients are living after five or six years. Furthermore, in several instances in which from the histological examination alone a favourable prognosis was given, the patients died several months or years later with a return of the growth. Of course it may have happened that the primary growth was in some cases entirely removed, and that the recurrence was due solely to implantation. The adoption of Werder's method will to a great extent remove this possibility.

* For various reasons several cases have been omitted from this tabulation.

CHAPTER XXVI

ETIOLOGY OF CARCINOMA

1. Heredity:
 1. An instance in which three sisters developed carcinoma of the uterus.
 2. Family history with reference to heredity in forty-nine cases of squamous-cell carcinoma of the cervix.
 3. Family history in twelve cases of adeno-carcinoma of the cervix.
 4. Family history in thirteen cases of adeno-carcinoma of the body of the uterus.
2. Trauma as a cause of cancer:
 1. In squamous-cell carcinoma of the cervix.
 2. In adeno-carcinoma of the cervix.
 3. Pregnancy as a factor in the causation of adeno-carcinoma of the body of the uterus.
 4. Does endometritis predispose to the development of adeno-carcinoma of the body of the uterus?
3. Origin of carcinoma from embryonic inclusion of epithelial elements.
4. Ribbert's theory.
5. The parasitic origin of cancer.
6. Cancer primarily a disease of the epithelium.

INASMUCH as our material has been limited almost entirely to uterine tissue, it would not be within our province to enter here into an exhaustive discussion upon the etiology of carcinoma. Nevertheless it may not be out of place to say a few words upon the following points bearing upon this subject :

1. Heredity.
2. Trauma.
3. Embryonic cell inclusion.
4. Ribbert's theory.
5. The parasitic origin of cancer.
6. Cancer as a primary disease of the epithelium.

HEREDITY

Possibly the majority of physicians and laymen are strongly impressed with the idea that heredity plays a well-defined rôle in the causation of cancer; nor are there wanting numerous instances tending to substantiate this view. It is probable that no more striking example could be cited than the following: A certain lady was operated upon in a distant city for cancer of the uterus, and died under the anæsthetic. One of her sisters had a hysterectomy performed for adeno-carcinoma of the body on January 9, 1899; in the following April another sister presented herself, saying that she had some similar trouble. The uterus was curetted and carcinoma diagnosed. It may also be added that the father's death had been due to cancer of the face. But while such cases, or groups of cases, taken by themselves, would be strongly suggestive of an hereditary tendency, only after the careful study of a long series, and an exact determination of the relative incidence of cancer among the members of a large number of

families, could anything approaching to a satisfactory conclusion be arrived at. In seventy-four of our cases it was possible to elicit fairly satisfactory information as regarded the family history.

*An Instance in which Three Sisters developed Carcinoma of the Uterus**

Gyn. No. 6,581

Adeno-carcinoma of the body of the uterus.

A. C., aged fifty-six. Admitted December 13, 1898.

The menopause was thought to have been passed seven years ago. Two years later, however, a flow appeared and occurred at regular intervals until a year ago. Since that time it has been irregular and profuse. There has been loss of weight for three years, weakness and general ill-health for nearly a year. About two and a half months before admission the patient had a profuse hæmorrhage, during which large blood clots formed. For the last three years there has been a profuse leucorrhœal discharge, not offensive nor irritating. For two weeks before admission, pain, which had hitherto been absent, has been complained of. It is situated in the lower part of the abdomen, and is sharp and cutting in character. One sister died while being etherized for removal of cancer of the uterus (probably of the body). Her father died of a cancer of the face. Otherwise the family history is good.

The uterus was removed on January 9, 1899. An attempt was made to perform vaginal hysterectomy, but it was found necessary to open the abdomen. The patient made a good recovery, and was discharged February 6th.

Gyn.-Path. No. 2,823. Diagnosis.—Adeno-carcinoma of the body of the uterus involving the entire cervix and the left uterine cornu.

December 16, 1899. The patient has just been examined. She is in good health, and there is nothing to indicate a return of the growth. Length of time since the operation, eleven months.

Gyn. No. 6,869

Adeno-carcinoma of the body of the uterus.

Miss M. G. C., aged fifty-two. Admitted April 25, 1899. The menopause occurred five years ago. Six months prior to admission the patient noticed a vaginal discharge resembling the menstrual flow. It was accompanied by some pain on both sides in the lower part of the abdomen. The discharge has been incessant since it first appeared. There has been no irritation, and no offensive odour. She has experienced a feeling of distention in the lower part of the abdomen, and at night pain over the same region. Backache occasionally has been present. The general health has been good, and there has been no loss of weight or strength.

Operation, May 1, 1899. The ureters were catheterized, and the uterus was removed *per abdomen*. Convalescence was uninterrupted.

Gyn.-Path. No. 3,125. Diagnosis.—Adeno-carcinoma of the body of the uterus.

* It was impossible to get a full history of the first sister's case.

FAMILY HISTORY IN FORTY-NINE CASES OF SQUAMOUS-CELL CARCINOMA OF THE UTERUS

NAME.	Gyn. No.	Gyn.-Path. No.	Family history as regards cancer.
G.....	2,041	14	Negative.
P.....	2,411	89	"
M.....	2,415	93	"
S.....	2,405	94	"
D.....	2,452	109	"
F.....	2,509	136	"
W.....	2,590	169	Maternal grandfather died of cancer; organ involved not stated.
E.....	2,689	170	Negative.
J.....	2,591	172	"
B.....	2,599	181	"
O.....	2,624	192	"
E.....	2,627	198	"
M.....	2,695	244	"
F.....	2,568½	260	One uncle died of carcinoma of the lip.
M.....	2,725	267	Negative.
A.....	2,847	348	"
D.....	2,885	365	"
D.....	2,939	403	"
R.....	2,964	411	"
D.....	2,963	415	"
S.....	2,997	419	Father died of cancer; organ involved not stated.
S.....	3,059	453	Negative.
E.....	3,114	481	Father died probably of cancer of the stomach.
H.....	3,126	493	Mother died of cancer of the uterus; maternal grandmother died probably of cancer of the uterus.
T.....	3,229	521	Negative.
D.....	3,203	529	"
D.....	3,243	549½	"
H.....	3,265	567	"
K.....	3,322	597	"
H.....	3,525	730	"
W.....	3,595	773	"
H.....	3,609	784	"
L.....	3,463	795	"
D.....	3,666	813	"
D.....	3,698	832	"
P.....	3,813	890	"
D.....	3,888	924	"
C.....	3,930	957	"
S.....	4,038	1,022	One sister died of cancer of the stomach.
P.....	4,070	1,036	Negative.
J.....	4,090	1,049	One sister died of cancer of the uterus.
E.....	4,143	1,070	Negative.
Le C.....	4,176	1,090	Mother died of carcinoma of the left breast.
J.....	4,328	1,184	One paternal aunt died of carcinoma; organ involved not stated.
C.....	4,430	1,211	Negative.
L.....	4,491	1,262	"
S.....	5,092	1,631	"
R.....	5,959	2,263	"
McA.....	6,492	2,706	"

Family history free from cancer..... 40 cases.
 Family history of cancer..... 9 " (18 per cent).
 Total..... 49 "

From the above it is seen that in 40 out of 49 cases of squamous-cell carcinoma of the cervix no history whatever of carcinoma in the family could be elicited, and in only 2 of the remaining 9 cases was there a definite record of cancer of the uterus occurring in relatives. Thus in only 18 per cent of the 49 cases had any member of the family suffered from any form of cancer, showing that in at least 82 per cent any hereditary tendency could be almost positively excluded.

FAMILY HISTORY IN TWELVE CASES OF ADENO-CARCINOMA OF THE CERVIX

NAME.	Gyn. No.	Gyn.-Path. No.	Family history as regards cancer.
R	1,964	6	Negative.
H	2,625	195	"
H	2,631	199	"
G	2,782	308	"
Z	2,990	427	"
S	3,036	445	"
H	3,356	619	"
E	3,616	787	"
G	3,693	828	One grandfather died of cancer; organ involved not specified.
L	3,717	838	Negative.
C	3,923	951	Grandfather died of cancer; organ involved not specified.
N	4,228	1,117	One uncle died of cancer of the face.

Family history free from cancer. 9 cases.
 Family history of cancer. 3 " (25 per cent).
 Total. 12 "

Our group of cases of adeno-carcinoma of the cervix in which the family history could be obtained is very small. In 9 out of 12 cases the relatives have been free from cancer, while in the remaining 3 the disease was limited entirely to the male members of the family.

FAMILY HISTORY IN THIRTEEN CASES OF ADENO-CARCINOMA OF THE BODY OF THE UTERUS

NAME.	Gyn. No.	Gyn.-Path. No.	Family history as regards cancer.
S	2,634	204 and 222	Negative.
A	2,817	321	One uncle died of cancer; situation not mentioned.
D	2,813	322	Negative.
P	Sanatorium.	392	"
A	2,832	324 and 345	"
A	3,258	556 and 559	"
G	3,967	979	"
S	4,922	1,473	Cousin on mother's side died of cancer of the rectum.
P	4,262	1,133 and 1,137	Negative.
H	5,858	2,146	"
B	5,957	2,338	"
H	6,439	2,808	"
L	6,659	2,897	"

Family history free from cancer. 11 cases.
 Family history of cancer. 2 " (15 per cent).
 Total. 13 "

In only 2 out of 13 cases (15 per cent) of adeno-carcinoma of the body in which the family history was obtainable had relatives suffered from cancer; in not a single instance was the uterus the seat of the process.

Taking our tables dealing with the three varieties of carcinoma of the uterus together, in only about 19 per cent was there evidence of carcinoma in the family. These figures, so far as they go, tend to show that heredity plays a minor rôle in the development of cancer of the uterus.

TRAUMA AS A CAUSE OF CANCER

(a) *Squamous-cell Carcinoma of the Cervix*

TRAUMA

Trauma is thought by many to be an important factor in the development of malignant processes in general. Among the most common sites of origin of cancer are the breast, lip, stomach, rectum, and uterus. The breast, occupying an exposed position, is easily injured by blows; the lip can readily be bitten by the teeth, or wounded by a broken pipe; the stomach may suffer more or less constant irritation produced by undigested food; while the rectum may be fissured or torn by large scybalous masses. The uterus lies in a protected position, and its mucosa is not readily wounded. There are, however, three ways in which it may be injured: (1) By normal labour, the cervix being usually lacerated; (2) as a result of a miscarriage; (3) by instruments which are used to dilate the cervical canal. In 50 of our cases of squamous-cell carcinoma of the cervix, in which accurate data were available (see p. 174), 49 (98 per cent) had had children, while 17 of the 50 had miscarried. Dr. Kelly,* in his private practice, has seen 3 cases of cancer of the cervix in nulliparæ, but in 1 of these the cervix had been dilated. Emmet † met with a carcinoma of the cervix in a virgin, and in this case also the cervix had been instrumentally dilated. When one considers the large number of women who remain unmarried, and finds that nearly all the victims of squamous-cell carcinoma of the cervix have had children, one cannot but conclude that the injuries incidental to labour have a potent influence in the development of this variety of cancer.

We rarely see the carcinoma of the cervix early enough to determine from just what point the growth has commenced, but Boldt, ‡ in one of his cases, was able to show that the original point of attack was in the depths of a laceration of the cervix.

(b) *Adeno-carcinoma of the Cervix*

Out of 14 cases in which definite data were obtainable, 12 of the patients were married and had had children; 2 were single. That adeno-carcinoma of the

* Kelly, H. A. Personal communication.

† Emmet, J. A. Personal communication to Dr. H. A. Kelly.

‡ Boldt, H. J. *Clinical Gynecology*. Edited by Keating and Coe, 1895, p. 604.

cervix is much less frequent than the squamous-cell variety, may possibly be due to the fact that during parturition the outer or vaginal portion of the cervix suffers the greater amount of injury, the cervical mucosa being relatively protected.

(c) *Pregnancy as a Factor in the Causation of Adeno-carcinoma of the Body of the Uterus*

It has already been said that nearly every victim of cancer of the cervix has had children. On the other hand the occurrence of pregnancy would seem to have little to do with the origin of adeno-carcinoma of the body of the uterus. On referring to p. 473, where the previous histories of 19 cases of carcinoma of the body of the uterus are tabulated, it will be found that 10 of the 19 women (or 52 per cent) had never had children. Seventeen of these patients were married, and it is a significant fact that 6 out of the 17 had never conceived—a far higher ratio of sterility than is found under normal conditions. It is just possible that the cause that prevented conception is in some way responsible for the development of the carcinoma.

Does endometritis predispose to the development of adeno-carcinoma of the body of the uterus? From a study of the cases of endometritis cited in Chapter XVII (p. 512), the reader might with some justification think that there was probably some definite relationship between this condition and the development of adeno-carcinoma. With this point in mind I carefully examined the mucosa in 19 cases of carcinoma of the body, and found that in only 2 (Gyn. No. 5,858, p. 452, and Gyn. No. 5,957, p. 449) was there any definite evidence of endometritis; it should be added that in both of these cases the uterus was much enlarged, and contained several myomata. Naturally, in all of the cases of adeno-carcinoma of the body there was some small-round-cell or polymorphonuclear leucocytic infiltration along the advancing margin of the growth, but no endometritis existed *per se*. From the study of the material at our disposal, I have not been able to arrive at any definite conclusions.

ORIGIN OF CARCINOMA FROM EMBRYONIC INCLUSION OF
EPITHELIAL ELEMENTS

This theory, generally attributed to Cohnheim, had previously (as was pointed out by Pianese*) been advanced by Durante in 1874, one year before the appearance of Cohnheim's publication. According to these two authorities, during foetal life portions of the epithelium become nipped off and included in the connective tissue. In after years these isolated colonies of cells are in some manner stimulated to activity, and give rise to carcinomata. This theory had many advocates, but in recent years it has gradually been abandoned.

* Pianese, C. *Beitrag zur Histologie und Aetiologie des Carcinoms*. Ziegler's *Beiträge* (Supplementheft), Jena, 1896.

From previous chapters it has been seen that three definite varieties of mucosa are to be found in the uterus, and we know that three* well-defined kinds of cancer develop in the uterus. We also know that a cancer starting in the vaginal portion of the cervix will be of the squamous-cell type; that one originating from the cylindrical epithelium of the cervix will be of a characteristic type; whereas, if the mucosa of the body be first implicated, we have a growth belonging to a different group. Now, according to Cohnheim's theory, whenever a squamous-cell carcinoma of the cervix has developed, some of the squamous cells must have been nipped off during fœtal life, and would be found lying in the stroma of the cervix; furthermore, since cancer of the cervix of the squamous-cell type is very common, we should not infrequently meet with these embryonic inclusions. In careful examinations of the cervix in a large number of cases, I have never yet been able to detect any nests of cells whose presence would bear such an interpretation.

Again, for the production of adeno-carcinoma of the cervix it would be necessary that several of the glands should have been nipped off. On this point I cannot speak with the same certainty, inasmuch as the continuity of the glands with the surface can only rarely be traced. It can, however, be said with certainty that the glands invariably are fully developed, and are not lined by an epithelium that could be called embryonic. In two instances I have found a few gland-like spaces in the cervical stroma, fully 1.5 centimetres from the mucosa proper. These were irregular in form, and lined by low cylindrical epithelium, which bore no resemblance to that of the cervical glands. These gland-like spaces, according to some authorities, are probably remains of the Wolffian duct. Their presence is of little significance, since we know that adeno-carcinoma of the cervix develops from the surface and gland epithelium, and that in the early stages of the disease it is never found such a distance from the surface.

In adeno-carcinoma of the body of the uterus we have been able to trace the rise of the carcinoma both from the surface and gland epithelium, and no such theory is necessary to explain its development; furthermore, in the examination of the endometrium in several hundred cases, I have never once seen groups of epithelial cells in the mucosa that resemble in any way an embryonic type.

In cancer of the uterus, whether starting in the cervix or in the body, we have never found the slightest evidence in support of the theory of an embryonic origin.

RIBBERT'S THEORY

Ribbert † says: "I do not attribute the appearance of tumours to the embryological character of the cells which have been nipped off, but to their separation from the organic continuity." He claims that carcinoma does not begin by an invasion of the connective tissue by the epithelium, but that at first there is

* For the sake of clearness we leave out the fourth variety—squamous-cell carcinoma of the body—of which there are about six authentic cases.

† Ribbert. *Ueber die Entstehung der Geschwülste*. *Deutsche med. Wochenschr.*, 1895, Bd. xxi, S. 9, 24, 45, 62.

an active increase of the connective tissue just beneath the epithelium. To avoid any possible confusion, I quote Ribbert's own words: "Dabei sah ich dann, dass der Anfang der Krebsbildung nicht durch ein Eindringen des Epithels in das Bindegewebe gekennzeichnet ist, sondern dass die erste Erscheinung in einer lebhaften Zellvermehrung des subepithelialen Bindegewebes besteht" (S. 63). According to this author, then, the connective-tissue cells increase to such an extent that they invade the epithelial layer and nip off epithelial cells or groups of cells; this isolated epithelium at a later period is capable of producing carcinoma. Let us briefly consider how far this theory could be applied to cancer of the uterus. In squamous-cell carcinoma of the cervix, as has been seen, in the early stages there is a cauliflower excrescence from the surface (Fig. 45, p. 62, Fig. 46, p. 63, and Fig. 47, p. 67); in other words, we have a definite outgrowth from the surface, but no nipping-off whatever (see Fig. 48, p. 68). Furthermore, the epithelium forming these outgrowths is directly continuous with that of the vaginal portion of the cervix. Thus, in the early stages—during the development of the cauliflower outgrowth—the actual condition is the exact opposite to that presumed to exist by Ribbert.

Along the edge of an early carcinoma some very interesting changes are to be noted. For instance, in Fig. 41 (p. 57) the epithelium is just commencing to penetrate into the depths. The cells are more closely packed together and stain more deeply, but are not being nipped off by the connective tissue. The two strands of stroma seen are papillæ of the mucosa. In Fig. 42 (p. 58) a still more instructive change may be observed. The normal squamous cells are being transformed into cells of the new growth, and yet the epithelium is nowhere being nipped off. Here also the histological pictures fail to support Ribbert's view.

If this theory held good, we should naturally expect it to apply equally well to adeno-carcinoma of the cervix or body. In adeno-carcinoma of the cervix the opportunity of following the early changes is not so satisfactory, inasmuch as the cervical canal is so small that the growth becomes compressed. In Fig. 157 (p. 307), however, we have a section from a fairly early growth, in which the distinct papillary outgrowth is present. The small branches are covered by several layers of epithelium, which is directly continuous with that lining the glands in Fig. 158 (p. 308). Again, in Fig. 151 (p. 290), although the surface epithelium has proliferated, forming many new glands, no connective tissue has wandered in between the epithelial cells. In all of the histological pictures the epithelium of the surface is directly continuous with that in the depths, and there is no evidence of any nipping-off of epithelial elements.

In adeno-carcinoma of the body of the uterus we have an excellent opportunity of studying the early stages. If the carcinoma were due to a nipping-off of cells by the stroma, we should naturally expect to find the growth penetrating the underlying tissue to a considerable extent. In Fig. 185 (p. 365) the growth is in a very early stage, and is limited almost entirely to the surface. In Fig. 191 (p. 374), although the uterine cavity is almost filled with the growth, the muscle shows very little involvement. No better example of the early development of carcinoma of the body can be found than is seen in Fig. 193 (p. 377). Here, in the lower part of the field, are minute prickles, representing the earliest recognisable

stages of the growth. As was gathered from the histological examination, the connective tissue is absolutely passive. Fig. 236 (p. 451) presents another clear example of the limitation of the growth to the surface.

If, then, the gross appearances in adeno-carcinoma of the body are strong evidence against Ribbert's theory, the histological pictures are still more conclusive. In Fig. 195 (p. 378) we have the earliest stage, consisting of a tiny outgrowth composed entirely of epithelial cells. Similar stages are seen in Fig. 196, *b* and *b'* (p. 379). From an examination of Plate VIII, Fig. 198 (p. 381), Fig. 233 (p. 445), Fig. 209 (p. 396), Fig. 181 (p. 357), Fig. 235 (p. 447), and Fig. 234 (p. 446), it will be seen that the carcinomatous growth is entirely epithelial in character, the connective tissue playing a passive rôle. It is rarely possible to see the early changes in the gland epithelium, but in Fig. 188 (p. 370), in which the carcinoma is exceedingly small, we can recognise new glands developing from the epithelium of the mother gland, but no nipping-off epithelium is demonstrable, the glands lying one against the other. A somewhat similar picture is seen in Fig. 220 (p. 418).

In conclusion, it may be said that the histological pictures in all the varieties of carcinoma of the uterus tend to disprove Ribbert's theory.

THE PARASITIC ORIGIN OF CANCER

Our work has been essentially along histological lines, the chief aim in view being concerned with the early recognition of carcinoma, in order that the organ involved may be removed at the earliest possible moment. Nevertheless, in the many specimens examined, numerous peculiar cell changes were noted. From a somewhat extended review of the literature, also, we have become most interested in the so-called parasitic origin of carcinoma, especially in its relation to cancer of the uterus.

METHODS OF CELL MULTIPLICATION IN CARCINOMA

Arnold was one of the first to pay attention to this subject; in 1879 he published an important article dealing with the nuclear division in the cells of tumours.* He examined sections from large numbers of tumours, fresh and on a heated stage. His views, published at that time, correspond somewhat closely with those now held. Among the other important contributions are those of Cornil,† Stroebe, Müller, Hansemann,‡ Pianese, and Amann.# The cancer cells multiply by indirect division, and not infrequently all stages in the karyokinetic cycle correspond to those in the normal cell, but we often encounter abnormally large and abnormally small cells. This condition is due to the

* Arnold, J. *Beobachtungen über Kerntheilungen in den Zellen der Geschwülste*. Virchow's *Archiv*, 1879, Bd. lxxviii, S. 279.

† Cornil, V. *Mode de multiplication des noyaux et des cellules dans l'épithéliome*. *Journal de l'anatomie et de la physiologie*, 1891, p. 97.

‡ Hansemann, D. *Studien über die Spezificität, den Altruismus und die Anaplasie der Zellen*. Berlin, 1893.

Amann, Jr. *Ueber Kernstrukturen in Uteruscarcinomen*. *Verhandl. der deutschen Gesellschaft. f. Gynäk.*, 6. Kongress. Wien, 1895, S. 755.

unequal division of the chromosomes and cell protoplasm—*asymmetric mitoses*. Müller* says that he has succeeded in finding *asymmetric mitosis* in all carcinomata examined by him, but failed to detect them in any benign tumour. Stroebe,† on the other hand, has found them not only in malignant tumours, but also in benign growths, and even in normal tissue. Giant cells are not infrequently seen in carcinoma; they usually arise by division of the nucleus without a corresponding change in the cell protoplasm. The nucleus divides into two nuclei, and these in turn produce four, and so on; or one large nucleus may contain three, four, or even five attraction spheres, and a corresponding number of nuclei are thus formed. Very large, lamellated, mulberry-shaped nuclei are often noted; these result from an incomplete division of the nucleus, evidently through several successive cycles, since not infrequently ten or more lamellations are seen. Giant cells may also be formed through the coalescence of two or more neighbouring cells.

CELL INCLUSIONS

We frequently see large mother cells containing one or more cells lying in their protoplasm. Cornil, who followed such pictures closely, found that they resulted from irregular nuclear division. A small portion of the nucleus becomes isolated, while in the principal part of the chromatin the process of evolution continues. Cornil gives numerous illustrations supporting this view; his Fig. 35, which is most convincing, shows that a direct connection exists between the active mass of chromatin and that portion which has gone to form the nucleus of the included cell.

In the older portions of carcinomatous growths the cell protoplasm may contain red blood-corpuscles, as seen in Fig. 54, *c* (p. 89), or polymorphonuclear leucocytes, as noted in Fig. 38 *B* (p. 54). This drawing also shows that they have invaded the nucleus. Stroebe has seen leucocytes free in the cell protoplasm, and surrounded by a clear space—in other words, lying in a vacuole.

CELL DEGENERATION

Either the cell protoplasm, the nucleus, or both, may be involved in a degenerative process. The literature on this subject is voluminous. Nearly every one who has made a study of the parasitic theory has found it necessary to deal with the various degenerative processes, inasmuch as what one authority takes to be a degeneration, a second may consider an undoubted parasite. Among the most frequent types are the fatty, mucoid, pseudo-colloid or colloid degeneration, hornification, necrosis, and calcification. Furthermore, a substance resembling amyloid is produced, but Lubarsch‡ says that it is not true amyloid. To bring out the various forms different stains have been employed.

Hyaline degeneration in the cell protoplasm is to be seen in Fig. 75, *B* (p. 137), and in the nuclei in Fig. 75, *A*, *C*, and *D*, Fig. 76 (p. 138), and Fig. 77 (p. 139).

* Müller, V. *Ueber celluläre Vorgänge in Geschwülsten*. *Virchow's Archiv*, 1892, Bd. cxxx, S. 512.

† Stroebe, H. *Zur Kenntniss verschiedener cellulärer Vorgänge und Erscheinungen in Geschwülsten*. *Ziegler's Beiträge zur pathologischen Anatomie*, Jena, 1892, Bd. xi, S. 1.

‡ Lubarsch, O. *Ergebnisse der allgemeinen Pathologie u. s. w.* Lubarsch u. Ostertag, Wiesbaden, 1895.

THE PARASITIC THEORY

Many observers claim that cancer is due to parasites—probably protozoa or blastomycetes—while others affirm that all of the so-called parasites are nothing more than cell degenerations. Although it is not our intention to enter into a discussion of this subject, the views of a few authorities may be briefly referred to. Thus Pianese, in the preface to his monograph, says: "How many uncertainties, how many doubts, have embarrassed me during this long period of investigation; how many times have I changed my views! The hypothesis concerning the parasitic nature of those unusual productions which one meets with in carcinoma was to me almost a certainty at the commencement of my investigations, and on examination of the first specimens which I had obtained according to the methods of other authors. But as I evolved new methods of hardening and staining, these pictures lost their significance, until now, at the close of my investigation, they have for me no importance whatever. I acknowledge that the parasitic nature of carcinoma is to a certain point a brilliant and justifiable hypothesis, but all the forms that have as yet been described as parasites are easily explained as special cell alterations." Lubarsch, in closing a critical review of the literature, says: "Even this brief consideration is already sufficient to awaken doubt as to the parasitic nature of the cell inclusions. Every author has different pictures and different ideas; what the one looks upon as parasites, the other describes as cells and nuclear degeneration; what appears to one to be definite spore formation, to another seems open to the gravest doubt. In a word, the combined investigations are so manifold and confusing that a criterion as to the parasitic nature is wanting." Councilman,* after giving a very valuable review of the etiology of carcinoma, in conclusion says: "A general consideration of the articles referred to here shows that the question is still undecided, but by far the weight of evidence is opposed to the parasitic idea." Gaylord and Pease † have for several years been carrying on extensive investigations as to the origin of cancer, and have brought forward some very suggestive data in support of the parasitic theory.

The views held by Hansemann, Hauser, and others, that cancer is primarily a disease of the epithelium, is gradually gaining ground, and is undoubtedly correct, but we still remain totally ignorant of the causes of this cell alteration.

Summing up the various analyses as to the causation of carcinoma, we find that heredity seems to have little influence; trauma as produced by parturition apparently bears a causal relation to cancer of the cervix, but not to that of the body. Neither the theory of Cohnheim nor that of Ribbert explain its origin; and the weight of evidence is against the parasitic theory.

The results of the many investigations, while giving us an increased knowledge concerning the histological structure of carcinoma, have still left its etiology an unsettled question.

* Councilman, W. T. *The Etiology of Carcinoma*. *Boston Med. and Surg. Jour.*, 1895, vol. cxxxii, pp. 256 and 282.

† Gaylord, H. Personal communication.

CHAPTER XXVII

INOCULATION EXPERIMENTS BEARING UPON THE NATURE AND ETIOLOGY OF CARCINOMA

1. Experimentation on animals.
2. Experimental observations on human beings.
3. Accidental implantation of carcinoma into healthy tissue during vaginal hysterectomy.

ALTHOUGH the experiments referred to in the present chapter have to do with carcinoma in general, the results are applicable to cancerous processes in the genitalia no less than to those that occur in other parts of the body, the essential features being identical.

EXPERIMENTATION ON ANIMALS

B. von Langenbeck,* one of the earliest investigators, injected particles of a medullary carcinoma of the humerus, two hours after its removal, into the left femoral vein of a dog; two months later, on killing the animal, he found carcinomatous nodules in the lungs. The right lung contained two or three nodules about the size of linseed granules, while in the substance of the middle lobe was a nodule the size of a field bean. Microscopical examination showed that all were without doubt carcinomata. This experiment shows that carcinomatous particles, when introduced into the blood current, may grow, the process being analogous to an embolus, which eventually forms a metastasis at some distant point.

A similar experiment was performed by Follin and Lebert.† They diluted with water the juice from an extirpated carcinoma of the breast, and injected from 60 to 70 grammes of the fluid into the jugular vein of a dog. The animal died after fourteen days, and at autopsy a number of carcinomatous nodules, varying in size from a small pea to a bean, were found in the heart muscle, and pin-head nodules in the liver. As Lebert said, these authors wished merely to record their findings, but would not postulate any definite deductions from their experiment.

Nowinski‡ was the first to succeed in making a direct inoculation. He took carcinomatous tissue from the nose of a dog and made fifteen inoculations into other dogs. Two of his experiments were successful, pea-sized nodules forming

* von Langenbeck, B. *Ueber die Entstehung des Venenkrebses und die Möglichkeit Carcinome vom Menschen auf Thiere zu übertragen.* Schmidt's Jahrbuch, 1840, Bd. xxv. S. 99.

† Follin and Lebert. *Virchow's Archiv*, 1867, Bd. xl, S. 538.

‡ Nowinski, N. M. *Zur Frage über die Impfung der krebsigen Geschwülste.* *Centralbl. f. med. Wissensch.*, Berlin, 1876, Bd. xiv, S. 790.

at the site of the implantation. One of these in three months grew to the size of a walnut, and produced undoubted carcinomatous involvement in the lymph glands. In the first case he inoculated the animal by introducing into an incision in the back a piece of carcinomatous tissue, 2 millimetres in diameter, the wound being then immediately closed.

Hanau,* in 1889, also published positive experiments. From a gland metastasis of a squamous-cell carcinoma of the vulva of a rat two male rats were inoculated in the scrotum. One died after seven weeks with a general peritoneal carcinosis; in the other, which was killed after eight weeks, two nodules were apparent at the site of inoculation. One nodule was the size of a pea. The microscopical examination showed that the growths were carcinomatous, and that they corresponded exactly with the original tumour. A third male rat, inoculated from the two just mentioned, was shown at the Berlin Congress. There was a wide-spread involvement of the peritoneum by the carcinoma. Hanau thinks that the failures of others to produce carcinoma is due (1) to inoculation of animals different in kind from those that were originally infected; (2) to suppuration in the material to be inoculated; (3) to the employment of young animals; (4) to the implantation in wounds instead of in serous cavities.

Wehr † says that under certain conditions it is possible to produce a carcinomatous growth that will lead to the death of the animal. In his experiments the material used was obtained either from the dog's prepuce or from a vaginal carcinoma in a bitch. These growths showed a papillary arrangement, and were soft. An incision 8 millimetres long was made, and the carcinomatous tissue carried under the skin for a distance of from 3 to 4 centimetres from the point of entrance. He experimented on twenty-six dogs, using five vaginal carcinomata and two cancers of the prepuce. In one of the cases in which four inoculations were made, the nodules reached the size of plums or nuts. Four months later each nodule was surrounded by an inflammatory zone, and soon all disappeared, but in the surrounding subcutaneous tissue were found several secondary carcinomatous nodules. These gradually increased in size, and in about two months the animal died. The autopsy showed that besides the tumours the entire area around the coccyx and in the neighbouring parts contained tumour masses varying in size from that of a nut to that of an apple. The urethra was pressed against the symphysis, the bladder had ruptured, the animal having died from hæmorrhage, and as a result of the presence of urine in the abdominal cavity. Further, the anterior nipple contained two carcinomatous glands, and isolated nodules were scattered throughout the spleen.

Morau, ‡ in 1891, reported the inoculation into a white mouse of particles of a squamous-cell carcinoma from an animal of the same species. It was successful, and several other mice were inoculated from the first. Tumours developed not only at the point of inoculation, but also in the abdominal organs.

* Hanau, A. *Krebsverimpfung von Ratte auf Ratte*. *Deutsche med. Wochenschr.*, 1889, Bd. xv, S. 489.

† Wehr. *Weitere Mittheilungen über die positiven Ergebnisse der Carcinom-Überimpfungen von Hund auf Hund*. *Archiv f. klin. Chir.*, Berlin, 1889, Bd. xxxix, S. 226.

‡ Morau, M. *Le Bulletin médical*, t. v, 1891, p. 445.

Fischel,* in 1892, published the results of his attempts to inoculate rats from tumours removed from human beings. His material consisted of two breast cancers, nine other carcinomata, a small-round-cell sarcoma, and a melanosarcoma. Twenty-three rats were inoculated. The inoculations were intra-peritoneal, intravenous, and subcutaneous. During the interval between the removal of the tumour and the implantation, which never exceeded fifteen minutes, the tissues were kept in normal salt solution at 38° C. One animal died of sepsis, but the wounds in the remaining cases healed by first intention. The pieces of tumour introduced sometimes measured 1 centimetre in diameter, but were often much smaller. In all of the examinations the results were negative. It was found that the tissue introduced into the peritoneal cavity after a few hours began to act as a foreign body, being surrounded by omentum and mesentery, while, on histological examination, fibrin and leucocytes could be found penetrating it. Even within twenty-four hours degenerative changes could be detected in the implanted nodules, its cells becoming cloudy.

From the foregoing experiments it has been shown beyond doubt that, in a certain number of instances at least, carcinoma can be transferred to another animal of the same species. This brings up the questions: 1. Can carcinoma be transmitted from one person to another? 2. Can a person suffering from carcinoma inoculate himself in another portion of his body?

EXPERIMENTAL OBSERVATIONS ON HUMAN BEINGS

Thorn,† in six inoperable cases of carcinoma of the uterus, made twenty implantations into the vaginal mucosa to see if it were possible to ingraft upon it the original growth. In some instances he sewed small pieces of the carcinoma under the vaginal mucosa, while in others he rubbed particles of the cancer into the small wounds that had been made. None of the experiments were successful. It is readily seen that in these cases the environment was anything but favourable. In the first place, only the older portions of the growth could be obtained, inasmuch as no radical operation was performed; and again, over the site of the inoculation there was a continual offensive uterine discharge, which would almost certainly have been sufficient to prevent any taking of the graft.

Cornil,‡ in 1891, reported the experiments of a certain Frenchman who had twice succeeded in inoculating the healthy breast of an individual from the opposite breast which had been amputated. One case was a carcinoma, the other a sarcoma. In the first experiment a small tumour developed soon after the inoculation.

Reincke# reports two cases which, although not in the true sense experiments, nevertheless are most instructive in this connection.

* Fischel, F. *Uebertragungsversuche mit Sarcom- und Krebsgewebe des Menschen auf Thiere. Fortschritte der Medicin*, 1892, Bd. x, S. 1.

† Thorn, W. *Zur Infektiosität des Carcinoms. Centralbl. f. Gynäk.*, 1894, Bd. xviii, S. 228.

‡ Cornil, V. *Bull. acad. de méd.*, t. xxv (*Séance du 23 Juin*, 1891).

Reincke, J. *Mittheilungen von der inneren Station des allgemeinen Krankenhauses in Hamburg. Virchow's Archiv*, 1870, Bd. li, S. 391.

In the first case, in which there were secondary carcinomatous nodules in the peritoneal cavity, a tumour of the diameter of a dollar had developed along the line of a trocar puncture. This growth was situated between the abdominal muscles, so that it was separated from the peritoneal cavity by connective tissue

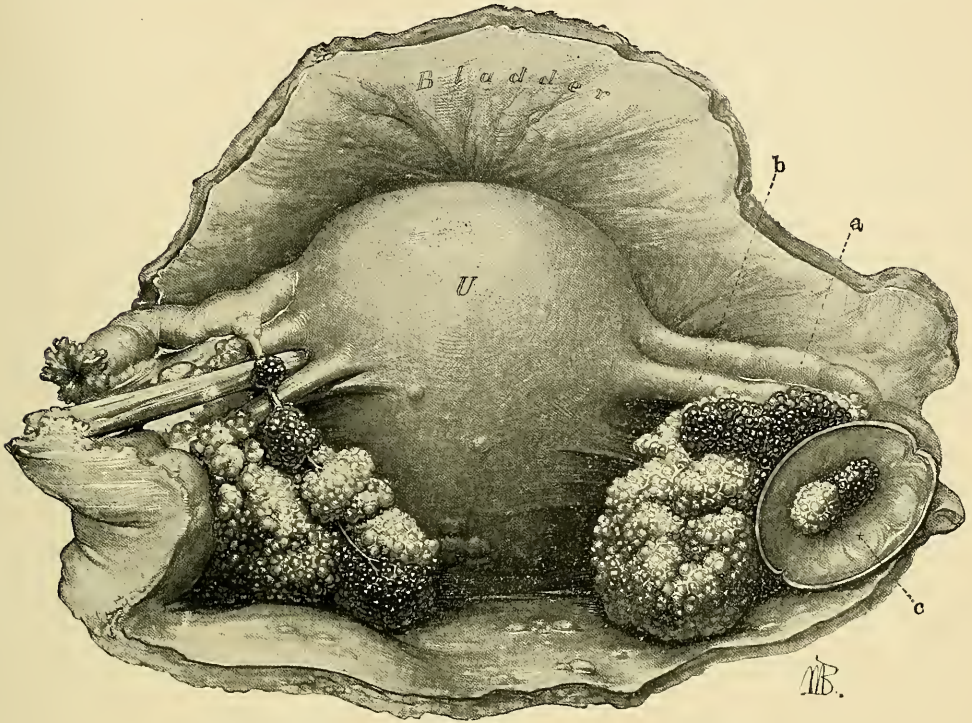


FIG. 308.—PAPILLOMATA OF BOTH OVARIES. ($\frac{1}{5}$ natural size.)

Gyn.-Path. No. 595. The uterus is seen from behind. Its surface is free from adhesions, but here and there just beneath the peritonæum are small and isolated, or conglomerate, slightly raised nodules. A few similar outgrowths are also seen beneath the peritonæum of Douglas's cul-de-sac. *a* is the right tube; *b*, the thickened right tubo-ovarian ligament. Occupying the site of the right ovary is a finely lobulated, papillary growth. The upper fourth of this is dark in colour, as a result of hæmorrhage into its stroma. *c* is a small ovarian cyst containing two papillary masses, the one light in colour, the other darker and hæmorrhagic. A similar condition is seen on the left side. Here the growth has become adherent to the Fallopian tube, and it is interesting to see the papillary masses developing along the delicate stem of stroma. The darker parts of the growth contain hæmorrhages. (After H. A. KELLY.)

and healthy muscle. On histological examination, morphologically it was identical with the primary tumour.

In the second case, general peritoneal carcinosis existed. Two punctures were made, and several weeks afterward subcutaneous metastases were found along the track of the trocar. These were separated from the peritoneum by healthy tissue.

I have noted a somewhat analogous case in the Johns Hopkins Hospital, but here, instead of carcinoma, there were numerous papillomata in the abdominal cavity.

Gyn. No. 3,323

Papillo-cystoma of both ovaries (Fig. 308); extension to the peritonaeum; paracentesis, followed several weeks later by exploratory laparotomy; death. Development of the papillomatous growths in the abdominal wall along the track of the trocar (Figs. 309 and 310).

A., admitted February, 1895.

An exploratory abdominal section was made, and the patient died two days later. There were typical papillomata springing from both ovaries and studding Douglas's cul-de-sac (Fig. 308).

At autopsy a piece of the abdominal wall at the site of an old trocar puncture was obtained, and scattered throughout the wall at this point were small areas, varying from 2 to 5 millimetres in diameter, filled with a pinkish, crumbly material which had a very rich blood supply (Fig. 309). These masses could be traced to within 2 millimetres of the skin surface.

Gyn.-Path. No. 595. On histological examination, the abdominal wall at the site of the trocar puncture had been invaded to within a short distance of the

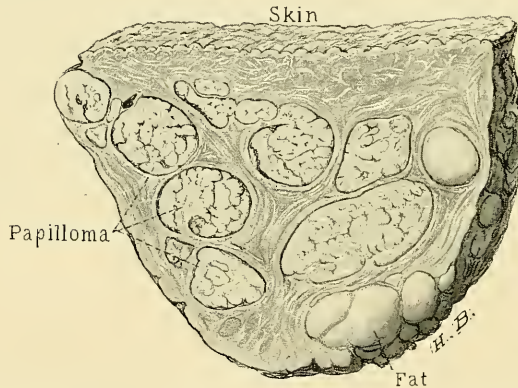


FIG. 309.—A PAPILLARY GROWTH TRANSPLANTED TO THE ABDOMINAL WALL BY A TROCAR INTRODUCED TO RELIEVE ASCITES. (3 diameters.)

Gyn.-Path. No. 595. Both ovaries were the seat of papillomata (Fig. 308), which had involved the surrounding peritonaeum. The abdominal cavity was filled with fluid. At autopsy I obtained the portion of the abdominal wall containing the trocar puncture, which was several weeks old. Scattered throughout the abdominal wall are small cyst-like spaces, containing papillary ingrowths. On examining Fig. 310, it is seen that these are histologically identical with papilocystoma of the ovary. Along the margins of the section are clumps of fat.

skin surface by the papillary growth, which had preserved its usual characteristics (Fig. 310). Many of the cavities into which the tree-like masses had penetrated were filled with desquamated epithelium and polymorphonuclear leucocytes.

The results of the French investigator, and the observations made by Reincke and myself, are sufficient to prove that under favourable conditions cells of a new growth may be transferred from one part of the body to another and still continue to grow.

IMPLANTATION DURING VAGINAL HYSTERECTOMY

Having seen that under favourable conditions cancer can be inoculated into an animal of the same species—for example, from dog to dog or rat to rat—and having learned that it is possible for cancer of one part to be inoculated into an-

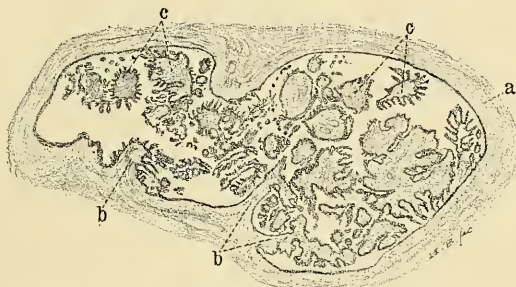


FIG. 310.—PAPILLOCYSTOMA OF THE ABDOMINAL WALL SECONDARY TO THAT OF THE OVARY AND TRANSPLANTED BY A TROCAR. (14 diameters.)

Gyn.-Path. No. 595. This represents one of the small papillary areas in Fig. 309. *a* is the wall composed of connective tissue. Projecting into the cyst cavity are portions of little tree-like ingrowths (*b*). Similar processes are seen in cross section at *c*. The stroma of the ingrowths is continuous with that of the surrounding tissue. The inner surface of the cyst and its little trees are covered by one layer of epithelium. This secondary growth is a fac-simile of the original ovarian papilloma, and has been transplanted to the abdominal wall just beneath the skin.

other portion of the same human body, it is only natural to inquire whether it is not possible that during a vaginal hysterectomy, in which the vagina has at times to be incised to allow of enough room, carcinomatous particles may lodge in the vaginal wounds. Although this subject has been referred to briefly in Chapter VIII, we will here report cases in detail, which apparently give an emphatic answer in the affirmative.

In 1891 Schopf* reported a case in which he performed vaginal hysterectomy for cancer of the body of the uterus, and on account of the narrow vagina had to make incisions into the two lateral walls. After three months carcinomatous nodules were found in the scars on both sides of the vagina. The nodules soon broke down and ulcerated, but there was no evidence of a return of the growth in the pelvis. The variety of carcinoma is not mentioned.

Hofmeier,† in 1895, reported the case of a patient fifty-five years of age. Adeno-carcinoma of the body was diagnosed from scrapings, and vaginal hysterectomy was performed. As the vagina was very narrow it was necessary to incise it deeply on both sides. Less than a year afterward an ulcerating nodule, the size of a walnut, was found in the left vaginal scar, while the scar in the vault showed no evidence of any return of the disease. The growth in the left scar proved to be an adeno-carcinoma, showing histological characteristics identical with those of the original tumour.

* Schopf, F. *Uebertragung von Carcinom auf frische Wunden in einem Falle von vaginaler Totalexstirpation des Uterus.* *Wien. klin. Wochenschr.*, 1891, Bd. iv, S. 840.

† Hofmeier, M. *Zur Anatomie und Therapie des Carcinoma corporis uteri.* *Zeitschr. f. Geburtsh. u. Gynäk.*, 1895, Bd. xxxii. S. 171.

Leopold,* during a vaginal hysterectomy for squamous-cell carcinoma of the cervix, found that the right labium majus had been injured by the leg holder. The injury was, however, trivial, as there was no bleeding and no sutures were required. One year later the patient returned, presenting a hard, movable nodule, as large as a walnut, situated on the labium exactly at the site of the injury. On removal, the growth proved to be a typical squamous-cell carcinoma. Leopold was inclined to believe that it had resulted from an inoculation at the time of operation.

While in the cases of Schopf and Hofmeier the possibility of the growths being metastases cannot be absolutely excluded, it is certainly highly significant that the neoplasms were found just in the clefts where incisions had been made.

It will be certainly wise, at present at least, to consider these cases as examples of implantation, and in performing hysterectomy to avoid as far as possible any chance of conveying particles of the carcinomatous tissue to the healthy parts.

* Leopold, G. *Arbeiten aus der königlichen Frauenklinik in Dresden*. Leipzig, 1895, Bd. ii, S. 203.

APPENDIX

A PLEA FOR THE EARLY DIAGNOSIS OF MALIGNANT DISEASE OF THE UTERUS

WE have insisted before that in all cases of malignant disease of the genitalia an early diagnosis is of vital importance. On this point we can hardly express our opinion better than by quoting from an address by J. Knowsley Thornton, read before the Section of Obstetrics and Gynæcology at the annual meeting of the British Medical Association, held in London, July-August, 1895.

“How is an early diagnosis to be made? Clearly by neglecting no menstrual departure from the normal, however trivial it may at first sight appear, but at once to encourage the patient to accurately describe symptoms, and above all to insist in the most determined manner on a local examination. Here it will be apparent that I, as a consultant, appeal for help to the great body of those who are now listening to my remarks, to my professional brethren engaged in general practice. I, in common with those situated as I am, too seldom have an opportunity of diagnosing early, because the majority of the patients come to us too late, when the disease has already advanced nearly, or quite, beyond the limits of surgical aid. Let me then appeal to all engaged in family practice who listen to me here, and to that larger body who may read my words when reproduced in the medical journals, to sternly cast aside that too great modesty, or that tendency to treat as trivial small symptoms, and to at once take alarm about, and carefully investigate, every case in which there is brought to their notice an abnormality in menstruation, or a vaginal discharge of any kind, however trifling. A very grave responsibility lies at the doors of the medical profession for the small progress made in the early diagnosis of uterine cancer and its successful treatment. How constantly is the consultant told: ‘I mentioned it to my doctor weeks or months ago, but he said, “Oh, it is nothing; I will send you a little medicine or a little injection,” and never even suggested any internal examination, so I did not like to trouble him again till the pain became so bad or the discharge so troublesome, and then he examined me and said I must have special advice at once.’ Invaluable weeks or months gone, and then the verdict of the consultant, ‘It is not a case for operation,’ which really means ‘You have come too late,’ but cannot be so candidly expressed, because he must guard the reputation of his professional brother. I admit that the false modesty of the patient, especially in some classes of society, makes the position a difficult one, especially for the young family doctor, but let me implore you all to awake to what is at stake, and to be firm in your demand for an examination, and if you have any doubt after such an exami-

nation, to urge that the patient should at once seek the advice of some one who has larger opportunities than yourself for forming a sound opinion. I will go one step further, and ask you, if there should be any to whom such a temptation comes, never to go on treating a case in which there is a shadow of doubt, either because you doubt or because you want practice; if the case is susceptible of treatment at all, it is only surgical treatment which can avail, and that of so severe a kind that it requires the knowledge of the specialist if ever any disease did or does require special knowledge and special skill in operative treatment."

INDEX OF AUTHORS

Where the illustrations of other writers have been utilized black-faced numbers are employed.

- Abel, John J., 412.
 Abel, Karl, 592.
 Abel, K., 318.
 Ahlfeld, 598.
 Amann, Jr., 655.
 Amiss, T. B., 408.
 Arnold, J., 655.
 Ash, E. S., 390, 642.
- Baker, N. D., 253.
 Barker, Lewellys F., 4.
 Beall, William P., 643.
 Benekiser, A., 114.
 Binswanger, O., 249, 270.
 Bloodgood, Joseph C., **246**, 421, 567.
 Blumer, George, **171**, 576.
 Bokelmann, 272.
 Boldt, H. J., 651.
 Bonner, G. S., 571.
 Bürekle, J., 115, 270.
 Burk, R., 163.
- Cabot, R. C., 629.
 Chantrenil, 613.
 Chiari, H., 335.
 Clark, C. M., 41.
 Clark, John G., 3, 14, **43**, 213, 214, **219**, 224, **226**, **227**, **228**, 230, 235, **254**, 567.
 Coe, H. C., 613.
 Cohnheim, J., 652.
 Cohnstein, 611, 612, 613.
 Cone, Sydney, 162, 421.
 Cornil, V., 1, 655, 656, 660.
 Councilman, William T., 4, 657.
 Credé, 132, 152, 177.
 Cullen, Thomas Stephen, 535, 546, 557, 575, 587.
 Cullen, Thomas Stephen, and G. L. Wilkins, 510.
- Dashiell, Rufus W., 393.
 Davis, E. P., 613.
 Deale, Henry B., 549.
 Diesterweg, A., 345, 536, 546.
 Dorland, W. A. N., 595, 597, 598, 599.
 Douglas, 498.
 Doyon, 614.
 Dudley, A. P., 274.
 Duffy, Charles, 98, 632
 Dührssen, 614.
 Durante, 652.
- Eccles, F. R., 368, 371, 386, 388, 479, 573.
 Edebohl, 235.
 Einhorn, 627.
 Elischer, J., 113.
 Emanuel, R., 547, 580, 581, 582, 592.
 Emmet, J. A., 651.
- Fehling, H., 611, 612, 614.
 Finney, John M. T., 237, 272.
 Fischel, F., 660.
 Fischer, E., 414.
 Flaischlen, N., 580, 582.
 Flexner, Simon, 4, 251, 548.
 Follin and Lebert, 658.
 Frankenhäuser, 14.
 von Franqué, Otto, 561, 562.
 Freund, W. A., 211, 546.
 Fritsch, H., 615, 617.
 Fritz, Horace, 637.
 Fry, 549.
- Ganghofner, F., 335.
 Gaylord and Pease, 657.
 Gebhard, C., 304, 311, 323, 352, 360, 579, 581, 582, 587, 595.
 Gellhorn, G., 580, 582, 592.

- Glass, 481.
 Gorter, Nathan R., 94.
- Haddaway, 64.
 Hahn, E., 222, 573.
 Halsted, W. S., 212, 222.
 Hanau, A., 52, 659.
 Hansemann, D., 52, 655, 657.
 Harrell, D. L., 634.
 Hauser, 52, 657.
 Hecker, 613.
 Hegar, 614.
 Henle, 328.
 Hermann, 613.
 Hertz, J. Lincoln, 495.
 Hesse, B., 436.
 Hobach, J. W., 463.
 Hofmeier, M., 223, 573, 580, 582, 593, 663, 664.
 van Hook, 246.
 Hurdon, Elizabeth, 244, 286, 291, 349, **350, 351, 352**, 448.
 Hydrick, A. S., 636.
- Kaltenbach, 613.
 Kaufmann, E., 346, 470, 471, 580, 582.
 Keller, C., 549.
 Kelly, Howard A., 3, **7, 9, 10, 11, 12, 13, 42, 44, 56, 77, 116, 122, 133, 144, 170, 186, 190, 205, 212, 214, 215, 216, 217, 218, 220, 224, 225, 228, 234, 236, 246, 247, 248, 253, 255, 256, 257, 258, 259, 261, 262, 263, 264, 274, 285, 287, 288, 331, 367, 368, 373, 380, 394, 395, 397, 428, 429, 482, 546, 548, 552, 556, 557, 563, 585, 637, 643, 651, 661.**
- Klebs, 52, 355.
 Klemperer, G., 177, 627.
 Krukenberg, R., 305.
 Kurtz, W., 121.
- Landau, 272.
 von Langenbeck, B., 658.
 Lebert and Follin, 658.
 Leinzinger, E., 612.
 Leopold, G., 223, 272, 573, 664.
 Löhlein, 437, 574, 583.
 Love, W. S., 636.
 Lubarsch, O., 52, 355, 360, 422, 656, 657.
- MacCallum, W. G., 576.
 Mackenrodt, A., 212.
 Marchand, 597.
 Mason, A. S., 375, 642.
 McCallum, A., 386.
- McCoy, 71.
 McGee, James, 636.
 Meek, H., 479, 480.
 Meig, 613.
 Menzies, 613.
 Merkel, 612.
 Mittermaier, 616.
 Morau, M., 659.
 Müller, F., 626.
 Müller, P., 596, 613.
 Müller, V., 655, 656.
- Neumann, 599, 600.
 Nicaise, 222.
 Niebergall, E., 471.
 Noble, Charles P., 87, 88.
 Noble, G. H., 611.
 von Noorden, 627.
 Norment, R. B., 635.
 Nowinski, N. M., 658.
- Oldham, 613.
 Olshausen, R., 214, 549, 611, 614, 615, 618.
 Orth, J., 3, 593.
 d'Outrepont, 613.
- Parsons, E. H., 635.
 Pawlik, K., 212, 270.
 Pease and Gaylord, 657.
 Peterson, E. C., 635.
 Pfannenstiel, J., 114, 576, 592.
 Pfeiffer, 595.
 Pianese, C., 652, 655, 657.
 Pick, L., 29.
 Piering, O., 580, 581, 592.
 Poirier, P., 15, 421.
 Pomtow, G., 120.
- Ramsay, Otto, 3, 129.
 von Recklinghausen, 345, 346, 536, 543, 544, 545, 546, 547, 594.
 Reeser, Howard S., 401.
 Reichel, P., 271, 272, 274, 437, 574.
 Reincke, J., 660, 662.
 Ribbert, 355, 653, 654.
 Ries, E., 212, 213, 224, 437, 579.
 Robin, 1.
 Robinson, M. E., 92.
 Rokitansky, C., 536.
 von Rosthorn, A., 471, 578.
 Ruge, C., 600.
 Ruge, C., and Veit, 2, 18, 282, 304, 311, 352, 581.
 Ruge, P., 593.
 Ruge and Winter, 125, 179, 191, 305, 360, 449, 593.
 Rumpf, 213, 214, 224.

- Russell, William W., 3, 15, 229, 230, 245, **330**, 367, 368, **416**, **417**, 421, **422**.
- Sailer and Taylor, 628.
- Sänger, M., 270, 274, 595, 597.
- von Säxinger, 163.
- Schatz, F., 536, 544, 545.
- Scheibe, W., 611, 612, 614.
- Schmorl, 600.
- Schneider, 627.
- Schopf, F., 223, 573, 663, **664**.
- Schroeder, 211, 536.
- Scott, J. McP., 586.
- Seelig, A., 45, 125, 593.
- Seldner, S. W., 205.
- Sherwood, Mary, 643.
- Smith, R. H., 637.
- Smoot, J. Edward, 644.
- Sondheimer, J., 409.
- Spangler, Charles, 554.
- Spencer, C., 591, 640.
- Spiegelberg, 198.
- Stokes, J. Ernest, 3, 464.
- Stratz, 611.
- Strauer, O., 627, 628.
- Stroebe, H., 52, 655, 656.
- Sutton, 507.
- Sutugin, 611, 612.
- Taylor and Sailer, 628.
- Thaue, G. D., 14.
- Theilhaber, 611, 613, 617.
- Thiersch, C., 1.
- Thorn, J., 411.
- Thorn, W., 125.
- Thornton, J. Knowsley, 665.
- Tucker, J. H., 529.
- Veit and Ruge, 2, 18, 282, 304, 311, 352, 581.
- Vierth, K., 415, 594.
- Vineberg, H. N., 412.
- Virchow, R., 163.
- Wagner, Ernst, 2, 43, 121, 132, 148, 152, 162, 163, 165, 172, 173, 177, 421, 438.
- Waldeyer, H., 2, 282.
- Walshe, W. H., 162.
- Ward, E. A., 644.
- Watson, William T., 636.
- Wehmer, F., 437.
- Wehr, 659.
- Weigert, 198.
- Welch, William Henry, 2, 3, 4, 144, 411, 567.
- Werder, 225, 226, 229, 231, 337.
- West, T., 366, 637.
- Whitehead, J. H., 363.
- Wilkins, G. L., and Thomas Stephen Cullen, 510.
- Williams, John, 2, 120, 281, 328, 411, 413, 436.
- Williams, J. Whitridge, 178, 198, 510, 547, 595, 600, **604**, **605**, **606**, **607**, 619.
- Williams, Roger, 2, 132, 164, 165, 172, 435.
- Winkel, 611.
- Winter, George, 158, 222, 327, 422, 573, 614.
- Winter and Ruge, 125, 179, 191, 305, 360, 449, 593.
- Wolff, J. H., 120.
- Zeller, A., 471, 578.
- Zweifel, 614.

INDEX OF CASES ARRANGED ACCORDING TO THEIR
GYNÆCOLOGICAL NUMBERS

PAGE		PAGE		PAGE	
Gyn. No. 518	162	Gyn. No. 2,964	102	Gyn. No. 4,038	108
Gyn. No. 1,134	249	Gyn. No. 2,976	533	Gyn. No. 4,070	160
Gyn. No. 1,661	618	Gyn. No. 2,990	286	Gyn. No. 4,090	221
Gyn. No. 1,964	312	Gyn. No. 2,997	89	Gyn. No. 4,143	61
Gyn. No. 2,041	74	Gyn. No. 3,036	302	Gyn. No. 4,176	73
Gyn. No. 2,136	413	Gyn. No. 3,038	486	Gyn. No. 4,232	301
Gyn. No. 2,248	275	Gyn. No. 3,059	66	Gyn. No. 4,262	440
Gyn. No. 2,294	96	Gyn. No. 3,114	117	Gyn. No. 4,328	155
Gyn. No. 2,405	79	Gyn. No. 3,120	519	Gyn. No. 4,374	151
Gyn. No. 2,411	60	Gyn. No. 3,126	69	Gyn. No. 4,430	250
Gyn. No. 2,415	125	Gyn. No. 3,136	536	Gyn. No. 4,489	583
Gyn. No. 2,436	361	Gyn. No. 3,193	564	Gyn. No. 4,491	145
Gyn. No. 2,449	149	Gyn. No. 3,203	105	Gyn. No. 4,653	522
Gyn. No. 2,452	111	Gyn. No. 3,229	71	Gyn. No. 4,921	513
Gyn. No. 2,492	324	Gyn. No. 3,236	567	Gyn. No. 4,922	397
Gyn. No. 2,509	94	Gyn. No. 3,243	90	Gyn. No. 4,958	527
Gyn. No. 2,568½	236	Gyn. No. 3,246	520	Gyn. No. 5,041	488
Gyn. No. 2,572	92	Gyn. No. 3,258	375	Gyn. No. 5,092	132
Gyn. No. 2,590	55	Gyn. No. 3,265	106	Gyn. No. 5,308	199
Gyn. No. 2,591	265	Gyn. No. 3,303	568	Gyn. No. 5,309	554
Gyn. No. 2,599	98	Gyn. No. 3,322	252	Gyn. No. 5,327	268
Gyn. No. 2,624	76	Gyn. No. 3,323	662	Gyn. No. 5,340	364
Gyn. No. 2,625	305	Gyn. No. 3,340	519	Gyn. No. 5,398	619
Gyn. No. 2,627	64	Gyn. No. 3,348	205	Gyn. No. 5,782	459
Gyn. No. 2,631	291	Gyn. No. 3,356	295	Gyn. No. 5,858	452
Gyn. No. 2,634	431	Gyn. No. 3,370	203	Gyn. No. 5,946	483
Gyn. No. 2,658	491	Gyn. No. 3,408	485	Gyn. No. 5,957	449
Gyn. No. 2,689	99	Gyn. No. 3,418	540	Gyn. No. 5,959	242
Gyn. No. 2,695	251	Gyn. No. 3,437	524	Gyn. No. 6,388	128
Gyn. No. 2,725	277	Gyn. No. 3,452	319	Gyn. No. 6,439	463
Gyn. No. 2,728	100	Gyn. No. 3,463	141	Gyn. No. 6,447	342
Gyn. No. 2,782	284	Gyn. No. 3,476	516	Gyn. No. 6,492	75
Gyn. No. 2,800	486	Gyn. No. 3,525	106	Gyn. No. 6,564	194
Gyn. No. 2,813	408	Gyn. No. 3,526	525	Gyn. No. 6,581	648
Gyn. No. 2,817	390	Gyn. No. 3,595	82	Gyn. No. 6,659	401
Gyn. No. 2,824	518	Gyn. No. 3,609	239	Gyn. No. 6,869	648
Gyn. No. 2,828	492	Gyn. No. 3,616	297	Asylum patient	567
Gyn. No. 2,832	371	Gyn. No. 3,666	121	Dr. Deale's patient, Gyn.-	
Gyn. No. 2,844	493	Gyn. No. 3,693	588	Path. No. 602	549
Gyn. No. 2,847	88	Gyn. No. 3,698	207	Mrs. M. (Dr. Eccles)	386
Gyn. No. 2,870	492	Gyn. No. 3,712	303	Mrs. R. (Dr. Eccles)	368
Gyn. No. 2,885	166	Gyn. No. 3,813	72	Dr. Glass's patient, Gyn.-	
Gyn. No. 2,894	557	Gyn. No. 3,888	85	Path. No. 2,048	481
Gyn. No. 2,928	272	Gyn. No. 3,923	314	Dr. Meek's patient, Gyn.-	
Gyn. No. 2,939	101	Gyn. No. 3,930	67	Path. No. 799	479
Gyn. No. 2,954	311	Gyn. No. 3,955	415	Dr. Noble's patient, Gyn.-	
Gyn. No. 2,960	521	Gyn. No. 3,967	388	Path. No. 888	87
Gyn. No. 2,963	107	Gyn. No. 3,969	534		

INDEX OF GYNÆCOLOGICAL-PATHOLOGICAL NUMBERS AND AUTOPSIES

In quite a number of instances the cases are referred to solely by their pathological numbers, and in many places in the text only the gynæcological-pathological number is mentioned. Hence I have thought it advisable to give a complete table of the pathological numbers, and also include a list of the autopsies.

	PAGE		PAGE		PAGE
Gyn.-Path. No. 6 . . .	314	Gyn.-Path. No. 336 . . .	492	Gyn.-Path. No. 595 . . .	662
Gyn.-Path. No. 14 . . .	75	Gyn.-Path. No. 343 . . .	493	Gyn.-Path. No. 602 . . .	549
Gyn.-Path. No. 62 . . .	276	Gyn.-Path. No. 345 . . .	373	Gyn.-Path. No. 607 . . .	519
Gyn.-Path. No. 78 . . .	97	Gyn.-Path. No. 348 . . .	88	Gyn.-Path. No. 608 . . .	516
Gyn.-Path. No. 89 . . .	61	Gyn.-Path. No. 355 . . .	492	Gyn.-Path. No. 619 . . .	295
Gyn.-Path. No. 91 . . .	186	Gyn.-Path. No. 365 . . .	166	Gyn.-Path. No. 625 . . .	205
Gyn.-Path. No. 93 . . .	126	Gyn.-Path. No. 372 . . .	558	Gyn.-Path. No. 627 . . .	181
Gyn.-Path. No. 94 . . .	79	Gyn.-Path. No. 388 . . .	273	Gyn.-Path. No. 655 . . .	188
Gyn.-Path. No. 100 . . .	361	Gyn.-Path. No. 392 . . .	394	Gyn.-Path. No. 659 . . .	485
Gyn.-Path. No. 105 . . .	149	Gyn.-Path. No. 403 . . .	101	Gyn.-Path. No. 661 . . .	540
Gyn.-Path. No. 109 . . .	112	Gyn.-Path. No. 407 . . .	312	Gyn.-Path. No. 662 . . .	498
Gyn.-Path. No. 120 . . .	498	Gyn.-Path. No. 410 . . .	521	Gyn.-Path. No. 665 . . .	524
Gyn.-Path. No. 126 . . .	325	Gyn.-Path. No. 411 . . .	103	Gyn.-Path. No. 678 . . .	320
Gyn.-Path. No. 128 . . .	503	Gyn.-Path. No. 413 . . .	518	Gyn.-Path. No. 682 . . .	482
Gyn.-Path. No. 136 . . .	96	Gyn.-Path. No. 415 . . .	108	Gyn.-Path. No. 685 . . .	320
Gyn.-Path. No. 144 . . .	571	Gyn.-Path. No. 418 . . .	104	Gyn.-Path. No. 686 . . .	511
Gyn.-Path. No. 148 . . .	325	Gyn.-Path. No. 419 . . .	90	Gyn.-Path. No. 698 . . .	552
Gyn.-Path. No. 161 . . .	411	Gyn.-Path. No. 420 . . .	533	Gyn.-Path. No. 705 . . .	516
Gyn.-Path. No. 169 . . .	57	Gyn.-Path. No. 427 . . .	289	Gyn.-Path. No. 709 . . .	203
Gyn.-Path. No. 170 . . .	100	Gyn.-Path. No. 445 . . .	302	Gyn.-Path. No. 729 . . .	525
Gyn.-Path. No. 172 . . .	267	Gyn.-Path. No. 452 . . .	187	Gyn.-Path. No. 730 . . .	106
Gyn.-Path. No. 173 . . .	93	Gyn.-Path. No. 452 . . .	486	Gyn.-Path. No. 740 . . .	507
Gyn.-Path. No. 181 . . .	99	Gyn.-Path. No. 453 . . .	66	Gyn.-Path. No. 754 . . .	505
Gyn.-Path. No. 186 . . .	506	Gyn.-Path. No. 481 . . .	119	Gyn.-Path. No. 770 . . .	87
Gyn.-Path. No. 192 . . .	78	Gyn.-Path. No. 484 . . .	519	Gyn.-Path. No. 771 . . .	535
Gyn.-Path. No. 195 . . .	307	Gyn.-Path. No. 493 . . .	70	Gyn.-Path. No. 773 . . .	83
Gyn.-Path. No. 198 . . .	65	Gyn.-Path. No. 497 . . .	537	Gyn.-Path. No. 780 . . .	384
Gyn.-Path. No. 199 . . .	292	Gyn.-Path. No. 501 . . .	510	Gyn.-Path. No. 784 . . .	241
Gyn.-Path. No. 204 . . .	432	Gyn.-Path. No. 519 . . .	564	Gyn.-Path. No. 787 . . .	298
Gyn.-Path. No. 213 . . .	491	Gyn.-Path. No. 521 . . .	71	Gyn.-Path. No. 795 . . .	141
Gyn.-Path. No. 216 . . .	54	Gyn.-Path. No. 529 . . .	105	Gyn.-Path. No. 799 . . .	479
Gyn.-Path. No. 222 . . .	432	Gyn.-Path. No. 534 . . .	478	Gyn.-Path. No. 813 . . .	122
Gyn.-Path. No. 244 . . .	252	Gyn.-Path. No. 546 . . .	566	Gyn.-Path. No. 828 . . .	588
Gyn.-Path. No. 260 . . .	239	Gyn.-Path. No. 549½ . . .	90	Gyn.-Path. No. 832 . . .	209
Gyn.-Path. No. 267 . . .	278	Gyn.-Path. No. 552 . . .	520	Gyn.-Path. No. 838 . . .	303
Gyn.-Path. No. 268 . . .	101	Gyn.-Path. No. 556 . . .	376	Gyn.-Path. No. 870 . . .	508
Gyn.-Path. No. 308 . . .	285	Gyn.-Path. No. 559 . . .	378	Gyn.-Path. No. 888 . . .	87
Gyn.-Path. No. 312 . . .	486	Gyn.-Path. No. 567 . . .	106	Gyn.-Path. No. 890 . . .	72
Gyn.-Path. No. 321 . . .	390	Gyn.-Path. No. 572 . . .	510	Gyn.-Path. No. 924 . . .	86
Gyn.-Path. No. 322 . . .	408	Gyn.-Path. No. 578 . . .	503	Gyn.-Path. No. 928 . . .	575
Gyn.-Path. No. 324 . . .	371	Gyn.-Path. No. 585 . . .	482	Gyn.-Path. No. 941 . . .	341
Gyn.-Path. No. 332 . . .	477	Gyn.-Path. No. 586 . . .	569	Gyn.-Path. No. 951 . . .	315
Gyn.-Path. No. 332 . . .	518	Gyn.-Path. No. 592 . . .	563	Gyn.-Path. No. 957 . . .	68

	PAGE		PAGE		PAGE
Gyn.-Path. No. 969 . . .	417	Gyn.-Path. No. 1415 . . .	479	Gyn.-Path. No. 2750 . . .	365
Gyn.-Path. No. 976 . . .	534	Gyn.-Path. No. 1429 . . .	492	Gyn.-Path. No. 2775 . . .	195
Gyn.-Path. No. 979 . . .	388	Gyn.-Path. No. 1442 . . .	349	Gyn.-Path. No. 2792 . . .	196
Gyn.-Path. No. 982 . . .	522	Gyn.-Path. No. 1466 . . .	513	Gyn.-Path. No. 2808 . . .	467
Gyn.-Path. No. 994 . . .	367	Gyn.-Path. No. 1473 . . .	398	Gyn.-Path. No. 2823 . . .	648
Gyn.-Path. No. 1022 . . .	110	Gyn.-Path. No. 1495 . . .	527	Gyn.-Path. No. 2890 . . .	50
Gyn.-Path. No. 1036 . . .	160	Gyn.-Path. No. 1507 . . .	46	Gyn.-Path. No. 2897 . . .	405
Gyn.-Path. No. 1042 . . .	299	Gyn.-Path. No. 1509 . . .	184	Gyn.-Path. No. 3125 . . .	648
Gyn.-Path. No. 1049 . . .	222	Gyn.-Path. No. 1543 . . .	488		
Gyn.-Path. No. 1054 . . .	556	Gyn.-Path. No. 1574 . . .	357		
Gyn.-Path. No. 1070 . . .	63	Gyn.-Path. No. 1631 . . .	138		
Gyn.-Path. No. 1090 . . .	73	Gyn.-Path. No. 1699 . . .	54		
Gyn.-Path. No. 1090 a . . .	53	Gyn.-Path. No. 1700 . . .	159		
Gyn.-Path. No. 1092 . . .	169	Gyn.-Path. No. 1761 . . .	555		
Gyn.-Path. No. 1117 . . .	301	Gyn.-Path. No. 1773 . . .	200		
Gyn.-Path. No. 1124 . . .	387	Gyn.-Path. No. 1847 . . .	193		
Gyn.-Path. No. 1133 . . .	441	Gyn.-Path. No. 1924 . . .	183		
Gyn.-Path. No. 1137 . . .	444	Gyn.-Path. No. 1959 . . .	510		
Gyn.-Path. No. 1147 . . .	49	Gyn.-Path. No. 1971 . . .	620		
Gyn.-Path. No. 1154 . . .	368	Gyn.-Path. No. 2048 . . .	481		
Gyn.-Path. No. 1184 . . .	156	Gyn.-Path. No. 2075 . . .	459		
Gyn.-Path. No. 1192 . . .	369	Gyn.-Path. No. 2084 . . .	461		
Gyn.-Path. No. 1203 . . .	152	Gyn.-Path. No. 2146 . . .	453		
Gyn.-Path. No. 1211 . . .	251	Gyn.-Path. No. 2221 . . .	501		
Gyn.-Path. No. 1229 . . .	333	Gyn.-Path. No. 2238 . . .	450		
Gyn.-Path. No. 1244 . . .	583	Gyn.-Path. No. 2242 . . .	483		
Gyn.-Path. No. 1262 . . .	145	Gyn.-Path. No. 2263 . . .	242		
Gyn.-Path. No. 1281 . . .	502	Gyn.-Path. No. 2291 . . .	364		
Gyn.-Path. No. 1311 . . .	420	Gyn.-Path. No. 2307 . . .	182		
Gyn.-Path. No. 1352 . . .	340	Gyn.-Path. No. 2602 . . .	338		
Gyn.-Path. No. 1352 . . .	522	Gyn.-Path. No. 2624 . . .	129		
Gyn.-Path. No. 1405 . . .	349	Gyn.-Path. No. 2658 . . .	130		
Gyn.-Path. No. 1412 . . .	424	Gyn.-Path. No. 2663 . . .	343		
Gyn.-Path. No. 1414 . . .	426	Gyn.-Path. No. 2706 . . .	75		

LIST OF AUTOPSIES

Autopsy 178	162
Autopsy 261	172
Autopsy 273	249
Autopsy 333	173
Autopsy 446	413
Autopsy 486	325
Autopsy 490	150
Autopsy 505	432
Autopsy 654	570
Autopsy 684	141
Autopsy 701	164
Autopsy 779	169
Autopsy 810	152
Autopsy 812	251
Autopsy 813	331
Autopsy 824	145
Autopsy 926	135
Autopsy 957	269
Autopsy 970	193
Autopsy 1171	130
Autopsy 1220	466
Autopsy 1257	197

I N D E X

- Abdominal abscess as a result of adeno-carcinoma of the body of the uterus, 413.
- Abdominal hysterectomy, 224.
- alarming symptoms occurring during, 234.
 - attempted, in squamous-cell carcinoma of the cervix, 100.
 - causes of death following, 248.
 - complications arising during, 235.
 - diet for first ten days following, 233.
 - employment of, in adeno-carcinoma of the body of the uterus, 574.
 - exsection of a portion of the base of the bladder, 242.
 - for adeno-carcinoma of the cervix in a patient five months pregnant, 618.
 - for squamous-cell carcinoma of the cervix, 242.
 - hæmorrhage complicating, 236, 298.
 - incontinence of urine after, 160.
 - injury of bladder during, 239.
 - nausea following, 232.
 - regulation of bowels after, 233.
 - tearing off of body, 235.
 - tearing off of cervix at vesical junction, 118.
 - uretero-vaginal fistula after, 427.
- Abdominal wall, papillocystoma of, secondary to that of the ovary, 662.
- Abscess, abdominal, following adeno-carcinoma of the body of the uterus, 413.
- in kidney due to adeno-carcinoma of the body of the uterus, 413.
 - in pelvic floor following vaginal hysterectomy, 287.
 - ovarian, with squamous-cell carcinoma of the cervix, 130.
 - suprarenic, following adeno-carcinoma of the body of the uterus, 413.
 - tuberculous, of the ovary, 568.
 - tubo-ovarian, associated with adeno-carcinoma of the cervix, 298.
- Abcesses, miliary, in kidney in squamous-cell carcinoma of the cervix, 150, 165.
- Adeno-carcinoma, and squamous-cell carcinoma in the body of the uterus, 470.
- in one horn of a uterus bicornis, 412.
 - of a uterine polyp, secondary to adeno-carcinoma of the cervix, 309.
- Adeno-carcinoma of the body of the uterus, advanced, 645.
- age at which it develops, 473.
 - analysis of successful cases, 645.
 - areas resembling squamous epithelium in, 362, 381, 382.
 - areas suggestive of papillocystoma of the ovary, 419.
 - arising from proliferation of the surface epithelium, 396.
 - ascites in the late stages, 431.
 - atypical proliferation of the gland epithelium, 418.
 - autopsies in advanced cases, 645.
 - calcareous plates in, 387.
 - calculus in uterine cavity with, 412.
 - cervical endometritis in, 455.
 - changes in surface epithelium in, 355.
 - character of uterine discharge in, 472.
 - chromatin in, 441.
 - chronic endometritis of the body in, 457.
 - closely simulated by convoluted glands in a benign mucosa, 571.
 - closely simulated by hypertrophy of the uterine glands, 494.
 - coincident appearance of carcinoma of the cervix, 592.
 - commencing near the internal os, 391, 425.
 - danger of amputating at the cervix, 377, 384.
 - developing from the tips of polypi, 355, 448.
 - development of new glands in, 419, 446.
 - diagnosed from one group of cells, 441.
 - diagnosed from scrapings, 358, 362, 363, 368, 372, 373, 376, 441, 462.
 - differential diagnosis, 476.

Adeno-carcinoma of the body of the uterus, differential diagnosis from gland hypertrophy of pregnancy, 501.
 differential diagnosis from sarcoma, 549.
 differential diagnosis from tuberculosis of the endometrium, 563.
 early, 356, 365, 367, 369, 374, 404, 445.
 endometritis as a causal factor, 652.
 "everting form," 360.
 extension to the broad ligament, 408.
 extension to the bronchial lymph glands, 423, 432.
 extension to the Fallopian tube, 410, 437.
 extension to the inguinal glands, 423, 432.
 extension to the larger lymph channels and lymphatic glands, 421.
 extension to the lymph glands in the neck, 431.
 extension to a myoma, 410, 433, 469.
 extension to the omentum, 435.
 extension to the pelvic lymph glands, 427.
 extension to the pericardial lymph glands, 432.
 extension to the peritoneal surface, 394.
 extension to the round ligament, 422.
 fibrino-purulent peritonitis with, 413.
 final results after hysterectomy, 642.
 finger-like outgrowths along margin, 378, 380.
 finger-like processes histologically resembling those found in squamous-cell carcinoma, 452.
 finger-like projections in, 377, 384, 447.
 formation of solid nests resembling those of squamous-cell carcinoma, 450.
 formation of young glands in the interior of an older one, 370.
 giant cells in the glands, 407, 432.
 gland involvement rare in operable cases, 422.
 gross appearances of, 353.
 hæmorrhages in, 472.
 hæmatometra, hæmatocolpos, and atresia vaginae senilis, 409.
 heredity in, 650.
 histological appearances in, 354.
 histologically closely resembling papilloma of the ovary, 400.
 in the coloured race, 475.
 interstitial myomata with, 454.
 "inverting form," 360.
 involvement of pelvic lymph glands, 414.
 large lamellated nuclei, 446.
 large myoma with, 442, 451.
 little or no involvement of the muscle, 374.
 manner in which new glands develop, 419.
 menstrual history in, 473.
 metastases following, 435.
 metastases in the adrenal gland, 467.
 metastases in the Fallopian tube, 410, 437.

Adeno-carcinoma of the body of the uterus,
 metastases in the liver, 414, 436, 465.
 metastases in the lungs, 436, 466.
 metastases in the mesentery, 465.
 metastases in the ovary, 437.
 metastases in the pancreas, 467.
 metastases in the peritoneum, 431, 466.
 metastases in the pleurae, 436, 466.
 multiple uterine myomata and papillocystoma of both ovaries with, 463, 466.
 muscle intact in, 445.
 necrosis of the surface, 385.
 new glands developing in the tips of finger-like projections, 446.
 obscured by presence of large myomata, 439, 470.
 occlusion of the fimbriated extremities of the tubes, 373.
 originating from proliferation of surface epithelium, 396.
 other pathological processes associated with, 439.
 pain in, 474.
 perforation of the organ, 413.
 portion slightly suggestive of gland hypertrophy, 419.
 pregnancy with, 473, 652.
 preservation of gland type, 406, 462.
 proliferation of the gland epithelium resembling squamous epithelium, 382.
 proliferation of the surface epithelium along margin of growth, 378.
 proliferation of the surface epithelium resembling squamous epithelium, 374, 381.
 pyometra with, 409, 413.
 rapidity of growth in, 474.
 recto-vaginal fistula subsequent to operation in, 383.
 removal of lymph glands in, 575.
 renal abscesses with, 413.
 secondary growths in the omentum, 431, 465.
 secondary growths in the peritoneum, 435, 466.
 secondary growths in the vaginal wall, 414, 416, 417.
 shape of organ preserved in, 375.
 simulated by some cases of endometritis, 512, 514, 516, 524.
 simulated, owing to imperfect hardening of normal mucosa, 477.
 simulating deciduoma malignum, 458.
 small myomata in, 439.
 small parovarian cyst with, 386.
 small subperitoneal adeno-myoma with, 459.
 squamous-cell carcinoma with, 470.
 suggested by hypertrophy of uterine glands, 491, 493, 494.

- Adeno-carcinoma of the body of the uterus,
 symptoms of, 472.
 treatment of, 573.
 tree-like outgrowth in, 357.
 tubes and ovaries in, 437.
 unusual polypoid condition in, 402, 403.
 uterine calculi with, 411, 412.
- Adeno-carcinoma of the cervix, age of patients
 with, 334,
 apparently early and independent adeno-car-
 cinoma of body with, 319, 322.
 autopsy findings in, 331.
 bedsore over sacrum in, 332.
 carcinomatous gland in, 300.
 cauliflower outgrowth in, 295, 302, 303, 312, 319.
 clinical history in, 334.
 commencing in a gland, 282.
 compressing a double ureter, 331.
 condition of ovaries in, 327.
 condition of patient on admission to hospital
 in, 336.
 condition of tubes in, 327.
 continuity of epithelium of outgrowth with
 that lining the glands in, 309.
 development of, from surface epithelium, 284,
 290.
 differential diagnosis from endothelioma of
 the cervix, 352.
 differential diagnosis from squamous-cell car-
 cinoma of the cervix, 347.
 differential diagnosis in, 339.
 differentiation from squamous-cell carcinoma
 of the cervix, 207.
 early, 285, 289.
 early gland changes in, 293.
 encircling of the ureter, 330.
 extension of, to the bladder, 327.
 extension of, to the broad ligament, 312, 326,
 331.
 extension of, to the liver, 330, 332.
 extension of, to the lymph channels, 317, 318.
 extension of, to the rectum, 319, 327.
 extension of, to a uterine polyp, 309.
 extension of, to the vagina, 297, 303, 305, 312,
 315, 319, 326, 330.
 extension of, to a vein, 317.
 formation of giant cells, 303.
 formation of solid nests resembling those of
 squamous-cell carcinoma, 321.
 glandular branching in, 293, 296.
 gross appearances in, 280.
 heredity in, 650.
 histological difference from squamous-cell car-
 cinoma of the cervix, 348.
 in a child eight years of age, 335.
- Adeno-carcinoma of the cervix, in a patient five
 months pregnant, 618.
 in the coloured race, 336.
 increase in nuclear chromatin, 300.
 initial symptoms in, 335.
 late cases of, 641.
 lymph glands in, 328, 329.
 menstrual history in, 335.
 microscopical appearances in, 281.
 number of pregnancies in cases of, 335.
 organs secondarily involved in, 326.
 pain in, 336.
 perforation of the rectum, 331.
 prognosis in, 327, 640.
 proliferation of the gland epithelium, 316.
 proliferation of the surface epithelium of body
 of the uterus in a case of, 318.
 pyometra, 312, 313.
 rare form of, 307.
 secondary, in uterine horn, 310.
 secondary to ovarian growth, 323, 324.
 simulated by squamous-cell carcinoma of the
 cervix, 167.
 simulated by squamous-cell carcinoma where
 the centres of cell-nests have dropped out,
 104.
 simulated by thickened cervical epithelium,
 338.
 suggested from unusual location of squamous-
 cell carcinoma of the cervix, 208.
 summary of cases of, 641.
 trauma as a cause of, 651.
 treatment of, 337.
 tubo-ovarian abscess in, 298.
 tubo-ovarian cyst in, 296.
 ultimate results after hysterectomy, 640.
 without uterine hæmorrhages, 291.
- Adeno-carcinoma of the uterus, a rare variety
 of, 587.
 equal involvement of the cervix and body,
 589.
 preservation of gland type and secretion of
 mucus, 590.
 secondary growth in the Fallopian tube, 591.
- Adeno-carcinoma, sarcoma, myoma, and uterine
 polypi in the same uterus, 471.
- Adenoma, limitation of the term, 281.
- "Adenoma malignum," 304.
- Adeno-myoma, diffuse, of anterior uterine wall,
 gross appearances, 537.
 of the round ligament, 575, 576.
 projecting into the cervical canal, 345.
 subperitoneal, associated with adeno-carci-
 noma of the uterus, 460.
 uteri diffusum benignum, 535.

- Adrenal gland, carcinoma of, secondary to adeno-carcinoma of the body of the uterus, 467.
 cyst of, associated with squamous-cell carcinoma of the cervix, 152.
- Age of patients, in adeno-carcinoma of the body of the uterus, 473.
 in adeno-carcinoma of the cervix, 334.
 in squamous-cell carcinoma of the cervix, 174.
- Albumen as nourishment after abdominal hysterectomy, 233.
- Alcohol as a hardening agent, 36.
- Alcohol, injections of, in cancer of the cervix, 279.
- Amputation at the cervix, danger of, in adeno-carcinoma of the body of the uterus, 377, 384.
- Amputation of the cervix, 211.
- Anæmia in carcinoma of the uterus, 627.
- Aneurismal needle, blunt, with left curve, 258.
- Appearance, general, in carcinoma of the uterus, 625.
- Arm, slough in, following transfusion of salt solution into the radial artery, 298.
- Arterial trunks of lower abdomen, 13.
- Arteries, common iliac, 9, 13.
 of endometrium, 24.
 uterine, size during pregnancy, 14.
- Artery, internal iliac, 9.
 branches of, 275.
 ligation of, to check cancer of the cervix, 237, 238, 274, 276, 277.
- Artery, ovarian, anastomosis of, 11.
 course of, 11.
 origin of, from accessory renal artery, 13.
 origin of, from aorta, 13.
- Artery, uterine, anastomosis of, 11.
 anastomosis with opposite uterine artery, 14.
 anastomosis with ovarian artery, 14.
 branches of, 11, 12.
 course of, 12.
 course of muscular branches of, 14.
 difficulty of isolation in stout individuals, 12.
 dissection during abdominal hysterectomy, 226.
 hemorrhage from, during hysterectomy, 110, 273, 286, 298.
 ligation of, in abdominal hysterectomy, 227, 238, 275.
 ligation of, in squamous-cell carcinoma of the cervix, 251.
 method of distinguishing, during vaginal hysterectomy, 259.
 origin of, 9, 12.
 relation to ureter, 9.
- Autopsies in advanced cases of adeno-carcinoma of the body of the uterus, 645.
 in cases of squamous-cell carcinoma of the cervix, 640.
- Autopsy findings in adeno-carcinoma of the cervix, 326.
- Axillary glands, systematic study of, in cancer of the breast, 421.
 removal of, in cancer of the breast, 212.
- Bath, sponge, value after abdominal hysterectomy, 233.
- Bedsore, in cases of squamous-cell carcinoma of the cervix, 163.
 over sacrum, in adeno-carcinoma of the cervix, 332.
- Bicornate uterus, adeno-carcinoma in one horn, 412.
- Bladder, accidental removal of portion of, during vaginal hysterectomy, 268.
 accidental rent in, during vaginal hysterectomy, 267.
 after abdominal operation, 230.
 anastomosis of ureter into, 427.
 carcinoma of, secondary to adeno-carcinoma of the cervix, 327.
 carcinoma of, secondary to squamous-cell carcinoma of the cervix, 99, 131, 135, 141, 144, 146, 147, 151, 164.
 containing large clot in squamous-cell carcinoma of the cervix, 132.
 contraction of, where vesico-vaginal fistula exists, 132.
 diphtheric inflammation of, 269.
 examination of, with patient in knee-chest posture, 215.
 excision of a portion of base of, during abdominal hysterectomy for squamous-cell carcinoma of the cervix, 242.
 freed from attachment to symphysis, facilitating ureteral anastomosis, 288.
 inflammation of, associated with squamous-cell carcinoma of the cervix, 132.
 injury of, during abdominal hysterectomy, 239, 242, 276.
 injury of, during vaginal hysterectomy, 255, 265, 267, 268.
 irritability of, lessened after abdominal operation, by enema of salt solution, 230.
 mucosa of, as seen from above, 217.
 rupture of, during separation from adherent uterus in squamous-cell carcinoma of the cervix, 240.
 separation from vagina in Werder's operation, 229.

- Bladder, small ulcer just within urethral orifice of, in squamous-cell carcinoma of the cervix, 132.
suture of, following vaginal hysterectomy, 267.
suture of rent in, produced during abdominal hysterectomy, 240.
- Blood, examination of, in cases of carcinoma of the uterus, 627.
- Blood-vessels, changes in, in endometritis, 530, 531, 532, 534.
development of decidual cells from endothelium of, 505.
extension of carcinoma to, 125, 317.
- Body, appearance of, at autopsy in squamous-cell carcinoma of the cervix, 162.
of uterus, differential diagnosis in cancer of, 476.
- Bones, pelvic, carcinoma of, secondary to squamous-cell carcinoma of the cervix, 130, 152.
- Bowels, regulation of, following abdominal hysterectomy, 233.
- Breast, carcinoma of, successfully transplanted into the healthy opposite breast, 660.
systematic study of the axillary glands in cancer of, 421.
- Broad ligament, contents of, 10.
extension of squamous-cell carcinoma to, 60, 65, 66, 94, 100, 101, 105, 124, 139, 142, 150, 221, 240, 250, 251, 276, 277.
extension to, from adeno-carcinoma of the body, 408.
extension to, from adeno-carcinoma of the cervix, 312, 326, 330, 331.
formation of, 9.
hæmorrhage from, during vaginal hysterectomy, 111, 271.
involvement of, at times only recognisable after opening the abdomen, 235.
involvement of, secondary to spindle-cell sarcoma of the body of the uterus, 554.
mass of cancer cells projecting into vein of, 317.
- Bronchial glands, carcinoma of, secondary to squamous-cell carcinoma of the cervix, 136, 159.
carcinoma of, secondary to adeno-carcinoma of the body of the uterus, 423, 432.
- Cachexia, in carcinoma of the uterus, 627.
occurring in squamous-cell carcinoma of the cervix, 177.
- Cæsarean section followed by Porro operation in advanced cases of carcinoma of the cervix, 618, 619.
- Calcareous plates in muscle, in adeno-carcinoma of the body of the uterus, 387.
- Calculi, uterine, associated with adeno-carcinoma of the body of the uterus, 411.
- Calculus removed from the uterine cavity during curettage, 412.
- Cancer, ætiology of, 647, 651, 652, 653, 655.
- Cancer of the cervix, complicated by pregnancy, 611.
hygienic rules in inoperable cases of, 279.
local palliative treatment of, 278.
treated by injections of alcohol, 279.
treatment in cases of severe hæmorrhage in, 279.
treatment of, with zinc paste 279.
- Cancer of the uterus, general summary of cases, 646.
- Carcinoma, cell degeneration in, 656.
cell inclusions in, 656.
cell multiplication in, 655.
development of, along the line of trocar puncture, 661.
- Carcinoma of the body of the uterus, points from which to take sections, 37.
secondary to that in the ovary, 438.
- Carcinoma of one breast transplanted into the healthy opposite breast, 660.
- Carcinoma of the cervix, 40, 41, 97.
advanced and associated with pregnancy, treatment in, 617.
advanced, complicated by pregnancy, value of Cæsarean section in, 618.
advanced, with pregnancy, value of Porro operation in, 618.
and advanced pregnancy, value of vaginal hysterectomy in, 615.
attempt to check, by ligation of internal iliac arteries, 274.
complicated by pregnancy, clinical history in, 612.
complicated by pregnancy, treatment of, 613.
course of pregnancy in cases of, 613.
effect exerted by pregnancy upon growth of, 613.
extension to blood-vessels, 125.
portions best suited for microscopical examination, 37.
with pregnancy, operation in early months, 614.
- Carcinoma of the uterus, with non-malignant enlargement of lymph glands, 421.
a local process, 2.
anæmia in cases of, 625.
cachexia in cases of, 627.
classification into four groups, 4.

- Carcinoma of the uterus, clinical phenomena common to all varieties of, 625.
- duty of family physician in early diagnosis of, 3.
- emaciation in cases of, 626.
- examination of blood in, 627.
- fever in, 630.
- frequency of, 2, 3.
- general appearance of patient, 625.
- general summary of cases, 646.
- hæmorrhages in, 625.
- heredity as a cause of, 647.
- in three sisters, 648.
- lack of pathognomonic symptoms in early stages of, 4.
- number of cases in the Johns Hopkins Hospital from May, 1893, to April, 1899, 3.
- pain in, 626.
- recurrence in, 632.
- value of curettage for diagnostic purposes in, 4.
- watery or purulent discharge in, 625.
- Carcinoma transplanted from one animal to another of the same species, 659.
- "Carcinomatous degeneration" of a myoma, 410.
- Catheterization of the ureters, 216, 218, 220.
- instruments required in, 216.
- Catheters, ureteral, in position preparatory to hysterectomy, 219.
- Cauliflower outgrowth, in adeno-carcinoma of the cervix, 295, 302, 303, 312, 319.
- in squamous-cell carcinoma of the cervix, 41, 43, 55, 62, 64, 66, 67, 70, 74, 82, 88, 129, 265, 277.
- Cell, very large, containing large irregular mass of chromatin, 96.
- containing polymorphonuclear leucocytes, 54.
- in squamous-cell carcinoma of the cervix, 138.
- Cell degeneration, in carcinoma, 656.
- in squamous-cell carcinoma of the cervix, 54, 137, 138, 139.
- Cell division, atypical, in squamous-cell carcinoma of the cervix, 99.
- Cell formation, atypical, in squamous-cell carcinoma of the cervix, 139.
- Cell inclusions in carcinoma, 656.
- Cell multiplication in carcinoma, 655.
- Cell-nest, apparent, due to a fold in the mucosa, 183.
- Cell-nests in squamous-cell carcinoma of the cervix containing giant cells, 95.
- dropping out of, causing resemblance to adeno-carcinoma of the cervix, 104.
- remarkably large, 151.
- Cell-nests, showing disintegration, 53.
- Celloidin, 38.
- Cells, decidual, development of, from endothelium of blood-vessels, 505.
- relative sizes of, in squamous-cell carcinoma of the cervix, 209.
- Cervical canal, adeno-myomata projecting into, 345.
- histological appearance of mucosa in, 18.
- length of, 8.
- points of constriction of, 8.
- transition into uterine cavity, 8.
- Cervical endometritis occurring in cases of adeno-carcinoma of the body of the uterus, 455.
- Cervical epithelium, cylindrical, thickening of, 338.
- development of adeno-carcinoma from, 284.
- Cervical gland, a giant cell in the wall of a, 340.
- Cervical glands, 18, 19.
- dilatation of, 8, 187.
- dilatation of, associated with adeno-carcinoma of the body of the uterus, 367.
- partial obliteration of, by squamous-cell carcinoma, 59, 93.
- Cervical mucosa, abnormal extension downward of, 179.
- an apparent cell-nest due to folding of, 183.
- arbor vitæ, 8.
- arborescent appearance of, 8.
- colour of, 8.
- Cervical myomata, interstitial, 345.
- submucous, 344.
- Cervical polyp, 92, 189, 341, 342, 343, 344.
- Cervix, adeno-carcinoma of, gross appearances in, 280.
- amputation of, 211.
- carcinoma of, and pregnancy, 611.
- carcinoma of, effect of pregnancy upon growth, 613.
- carcinoma of, sections from, 37.
- carcinoma of, treatment where pregnancy exists, 613, 614.
- carcinoma of, with coincident appearance in the body of the uterus, 592.
- clinical appearance of the vaginal portion in the living, 40.
- closure by silk-worm gut ligatures to control hæmorrhage following curettage in adeno-carcinoma of the body of the uterus, 361.
- condition of, in multiparæ, 8.
- condylomata of, 191, 195, 196, 197.
- danger of amputation at, in adeno-carcinoma of the body of the uterus, 377.
- divisions of, 6.

- Cervix, endothelioma of, 210, 349.
erosion of, 181.
gummata of, 192.
high cylindrical epithelium of, 19.
hypertrophy of, 185, 186.
initial lesion of, in syphilis, 192.
interstitial myomata of, 191.
laceration of, 41, 187.
lymphatics of, 15.
method of removal of piece for diagnosis, 27.
microscopical appearances in, 281.
points to be noted in examination of, 31, 32.
relation to vaginal vault, 7, 8.
sarcoma of, 198, 199, 201, 202.
shape of, 7.
showing small tags of scar tissue, 187.
simple ulceration of, due to prolapsus, 183.
slight changes in gland epithelium of, 339.
slight erosion of cervical portion of, 182.
squamous-cell carcinoma of. See Squamous-cell carcinoma of the cervix.
squamous epithelium so distorted by curettage as to resemble squamous-cell carcinoma, 184.
syphilitic ulceration of, 191.
tearing away of, during vaginal hysterectomy for adeno-carcinoma of the body of the uterus, 390.
tears of, 8.
thickening of gland epithelium of, simulating adeno-carcinoma, 338.
thickening of vaginal portion, due to dilatation of cervical glands, 186.
tuberculosis of, 193, 195, 196, 197, 346, 566.
"ulceration" of, 180, 181.
vaginal portion, character of epithelial covering, 17.
- Chromatin, increase of, in adeno-carcinoma of the cervix, 300.
increase of, in adeno-carcinoma of the body of the uterus, 418, 441, 447.
increase of, in squamous-cell carcinoma of the cervix, 49, 96.
- Clinical phenomena common to all varieties of carcinoma of the uterus, 625.
- Cloaca, formation of, in squamous-cell carcinoma of the cervix, 149.
- Clark's radical method of removing the uterus, 213.
- Club-like outgrowths from the surface of the mucosa in endometritis, 522.
- Cohnheim's theory as to the etiology of carcinoma, 652.
- Colon, inflammation of, in squamous-cell carcinoma of the cervix, 148.
- Complications arising during abdominal hysterectomy, 235.
- Condylomata of the cervix, 191.
- Condylomata and tuberculosis of the cervix, 195, 196.
- Constipation as a cause of hæmorrhage in squamous-cell carcinoma of the cervix, 61.
- Convulsions, probably uræmic, in squamous-cell carcinoma of the cervix, 145.
- Corpus luteum cyst of the ovary, associated with squamous-cell carcinoma of the cervix, 155.
- Crater-like excavation, in squamous-cell carcinoma of the cervix, 105, 118, 143, 150, 160.
- Curettage, danger of error unless all parts are curetted, 29.
in adeno-carcinoma of the body of the uterus, accompanied by free hæmorrhage, 361.
in adeno-carcinoma of the cervix, followed by elevation of temperature, 302.
in inoperable cases of carcinoma of the cervix, 278.
instruments required for, and method of procedure in, 28.
systematic, of the uterus, 28, 29.
with accidental opening of peritoneal cavity, 279, 303.
with accidental puncture of vesico-uterine septum, 313.
- Cylindrical cervical epithelium, development of adeno-carcinoma from, 290.
- Cyst, corpus luteum, occurring with squamous-cell carcinoma of the cervix, 155.
dermoid, of ovary, associated with squamous-cell carcinoma of the cervix, 155.
ovarian, accompanying squamous-cell carcinoma of the cervix, 94.
small, parovarian, associated with adeno-carcinoma of the body of the uterus, 386.
- Cystitis, acute hæmorrhagic, developing in acute peritonitis following incomplete hysterectomy for carcinoma of the cervix, 251.
diphtheric, associated with squamous-cell carcinoma of the cervix, 132.
- Cystoscope, 131, 215.
- Death, as a result of ligation of a ureter during abdominal hysterectomy, 249.
causes of, following abdominal hysterectomy, 248.
immediate causes of, in squamous-cell carcinoma of the cervix, 178.
- Decidua, 501, 504, 623.
development of, in a uterus in which a pregnancy existed in a rudimentary horn, 510.

- Decidual cells, development of, from the endothelium of blood-vessels, 505.
development of, from stroma cells of the cervix, 622.
- Decidual giant cells, developing in the uterine muscle, 506, 507, 508, 509.
- Deciduoma malignum, 595.
alveolar arrangement in, 604.
anatomical appearances in, 596.
clinical history of, 598.
histological appearances in, 596.
metastases from, 597, 601, 602, 603, 607.
prognosis in, 599.
simulated in places by adeno-carcinoma of the body of the uterus, 458.
sources of origin, 597, 599.
treatment of, 599.
with syncytial mass invading a venous channel, 606.
- Dermoid cyst of the ovary, associated with squamous-cell carcinoma of the cervix, 155, 241.
- Description, systematic, of histological appearances of the uterus, 39.
- Diagnosis, rapid, of scrapings, 29.
- Differential diagnosis, in adeno-carcinoma of the body of the uterus, 476.
in adeno-carcinoma of the cervix, 339.
in squamous-cell carcinoma of the cervix, 178.
in tuberculosis of the endometrium, 563.
- Dilators, uterine, 28.
- Discharge in cancer of the uterus, 45, 472.
- Douche, vaginal, after vaginal hysterectomy, 263.
- Douglas's *cul-de-sac*, accidental opening of, in curettage, 279, 303.
- Emaciation, causes of, in cancer of the uterus, 626.
- Embryonic inclusion of epithelial elements, as a source of origin of carcinoma, 652.
- Endometritis, cervical, associated with adeno-carcinoma of the body of the uterus, 455.
changes in blood-vessels in, 530, 531, 532, 533.
changes in the walls of blood-vessels producing a picture suggestive of tuberculosis, 532.
chronic, in a case of adeno-carcinoma of the body of the uterus, 457.
chronic, in pyometra associated with squamous-cell carcinoma of the cervix, 244.
of the body of the uterus, with small out-growths from the surface of the mucosa, 517, 521, 522, 523.
- Endometritis, localized thickening of surface epithelium suggesting squamous epithelium, 525, 528, 530.
polypoid, 515, 516.
polypoid, suggesting adeno-carcinoma of the body of the uterus, 516.
presenting gross appearances somewhat resembling adeno-carcinoma of the body of the uterus, 512.
proliferation of gland epithelium in, 527, 529.
relation of, to the development of adeno-carcinoma of the body of the uterus, 652.
slight proliferation of surface epithelium with formation of new glands, 524.
suggesting early adeno-carcinoma of the body of the uterus, 512.
suspicious histological changes, 517, 524, 526.
- Endometrium, arteries of, 24.
atypical proliferation of gland epithelium with formation of new glands, in adeno-carcinoma of the body of the uterus, 418.
changes in, at the menstrual period, 25.
changes in the surface epithelium, in adeno-carcinoma of the body of the uterus, 355.
changes in the surface of, along the margin of an adeno-carcinoma of the body, 378, 379, 380.
characteristic changes in, occurring during pregnancy, 495.
commencing tuberculous of, 568.
comparison between that hardened in Müller's fluid and alcohol, 36.
condition of, in adeno-carcinoma of the cervix, 318.
condition of, in pyometra, 244.
condition of, in squamous-cell carcinoma of the cervix, 113.
decidual development in, 502, 504, 505, 510.
earliest changes in gland epithelium of, in adeno-carcinoma of the body of the uterus, 356, 369.
early changes in surface and gland epithelium of, in adeno-carcinoma of the body of the uterus, 404.
effect of air on mucosa hardened in Müller's fluid, 37.
exfoliated menstrual membrane, 511.
extension of squamous-cell carcinoma of the cervix over the surface of, 586.
extension of squamous-cell carcinoma of the cervix to, 584.
finer structure of the veins of, 26.
glandular hypertrophy of, 75, 98, 488, 489, 490, 491, 493, 494, 500, 502.
in cases of extra-uterine pregnancy, 509.

- Endometrium, isolated carcinomatous nodule in, in squamous-cell carcinoma of the cervix, 114.
 large venous sinuses in, causing free hæmorrhages, 480.
 line of demarkation between mucosa and muscle, 24.
 normal, after the menopause or following removal of the appendages, 22.
 normal, apparently near menstrual period, 23.
 normal epithelium of, 21, 22, 26.
 passive involvement of a uterine gland in, in squamous-cell carcinoma of the cervix, 119.
 polypoid condition of, in adeno-carcinoma of the body of the uterus, 402, 403.
 polypoid formation of, 482.
 proliferation of the stroma cells, in some way causing hæmorrhage, 478.
 proliferation of the surface epithelium of, in cases of adeno-carcinoma of the cervix, 318, 322.
 removal of, for diagnosis, 28.
 stroma of, 24.
 suspicious changes in, 322, 571.
 systematic examination of, 33.
 tuberculosis of, 197, 561, 565, 570.
 veins of, 25.
 wide variations of, under normal conditions, 21.
- Endothelioma of the cervix, 210, 349, 350, 351.
 differential diagnosis, 210, 352.
- Enema, salt solution, to prevent thirst after abdominal operation, 230.
- Epithelial pearls, in squamous-cell carcinoma of the cervix, 48, 49.
- Epithelioma. See Squamous-cell carcinoma.
- Epithelium, cylindrical, of the body, 21, 22, 23, 26.
 cylindrical, of the cervix, 18, 19.
 squamous, suspicious changes along the margin of a carcinoma, 57.
 transition of squamous, into carcinomatous, 58.
- Erosion of the cervix, 180, 181, 182.
- Ether, death from, during abdominal hysterectomy, 301.
- Etiology of carcinoma, 647.
 Cohnheim's theory, 652.
 parasitic origin, 655.
 Ribbert's theory, 653.
 trauma, 651.
- Etiology of deciduoma malignum, 597.
- Eversion of the cervical mucosa, 180.
- "Everting form" of adeno-carcinoma of the uterus, 360.
- Excitement as a cause of uterine hæmorrhage, in squamous-cell carcinoma of the cervix, 149.
- Extra-uterine pregnancy, condition of uterine mucosa in cases of, 509.
- Fallopian tube, carcinoma of, secondary to adeno-carcinoma of the body of the uterus, 410.
 carcinoma of, secondary to squamous-cell carcinoma of the cervix, 157.
 carcinomatous on the surface, secondary to squamous-cell carcinoma of the cervix, 139.
 complete torsion of, 86.
- Fallopian tubes, condition of, in adeno-carcinoma of the body of the uterus, 437.
 condition of, in adeno-carcinoma of the cervix, 327.
 condition of, in squamous-cell carcinoma of the cervix, 153.
 prolapse of, after vaginal hysterectomy, 265, 632.
 tuberculosis of, 123, 193, 197, 564, 567, 568.
 tuberculosis of, associated with squamous-cell carcinoma of the cervix, 122.
- Fallopian tubes and ovaries, removal of, 260, 574.
- Fever, in carcinoma of the uterus, 630.
- Finger-like outgrowths in adeno-carcinoma of the body of the uterus, 362, 377, 378, 380, 381, 384, 446, 447, 451.
 in squamous-cell carcinoma of the cervix, suggesting angio-sarcoma, 84.
- Finger-like projections in squamous-cell carcinoma of the cervix, 41, 50, 51, 54, 64, 68, 81, 84, 91, 103, 128.
- Finney's treatment of general suppurative peritonitis, 272.
- Fistula, recto-vaginal, 150, 269, 274, 331, 383.
 recto-vaginal, following vaginal hysterectomy, 150, 269, 274.
 recto-vaginal, occurring in adeno-carcinoma of the body of the uterus, 383.
 uretero-vaginal, 177, 270, 271, 427, 428, 429.
 vesico-vaginal, 82, 132, 146, 147, 166, 168, 269, 276.
- Forearm, slough in, following transfusion of salt solution into radial artery, 298.
- Formalin as a hardening agent, 36.
 method for frozen sections, 29.
- Freund's operation, 211.
- Frozen sections of tissue, 29, 30.
- Gangrene of leg following injury of the corresponding internal iliac artery and vein, 237.
- Genital excoriation, in squamous-cell carcinoma of the cervix, 208.

- Giant cells, decidual, 506, 508, 509.
 in adeno-carcinoma of the cervix, 303.
 in a carcinomatous gland in adeno-carcinoma of the body of the uterus, 407, 432.
 in squamous-cell carcinoma of the cervix, 95, 97, 105, 106, 113, 118, 139.
 in the wall of a cervical gland, 340.
 in the wall of a dilated gland from a uterine polyp, 487.
 placental, 496, 499.
- Gland changes, early, in adeno-carcinoma, 293, 356, 369, 404.
- Gland epithelium, proliferation of, in acute endometritis, 527, 529.
 proliferation of, with formation of new glands in adeno-carcinoma of the body of the uterus, 370.
- Gland hypertrophy, 75, 98, 488, 489, 490, 491, 493, 494, 500, 502.
 moderate, in a myomatous uterus, 490.
 of endometrium, in squamous-cell carcinoma of the cervix, 98.
 suggested by portions of adeno-carcinoma of the body of the uterus, 419.
- Gland type, preservation of, in adeno-carcinoma of the body of the uterus, 462.
- Glands, axillary, removal of, in cancer of the breast, 212.
 bronchial, metastases in, in adeno-carcinoma of the body, 423, 432.
 bronchial, metastases in, in squamous-cell carcinoma of the cervix, 136, 159.
 cervical, 18, 19.
 cervical, dilatation of, 8, 187.
 characteristic skein-like grouping of, in adeno-carcinoma of the body of the uterus, 358.
 developing from the surface epithelium in endometritis, 524.
 developing in tips of finger-like projections, in adeno-carcinoma of the body of the uterus, 446.
 iliac, carcinoma of, secondary to squamous-cell carcinoma of the cervix, 130, 137, 151, 158, 159, 161, 162.
 iliac, removal of, in hysterectomy for cancer of the cervix, 228.
 inguinal, secondary carcinoma in adeno-carcinoma of the body, 423, 432.
 inguinal, secondary carcinoma of, in squamous-cell carcinoma of the cervix, 134, 137, 159.
 lumbar, metastases in, from a squamous-cell carcinoma of the cervix, 130, 138, 159.
 lymph, acute swelling of, in carcinoma of the cervix, 162.
- Glands, lymph, carcinoma of, secondary to adeno-carcinoma of the cervix, 328, 329.
 lymph, involved in squamous-cell carcinoma of the cervix, 130, 132, 134, 137, 138, 151, 158, 159, 161, 162.
 lymph, removal of, during hysterectomy for adeno-carcinoma of the uterus, 575.
 mesenteric, carcinoma of, secondary to squamous-cell carcinoma of the cervix, 132, 158, 162.
 pelvic. See Iliac glands.
 retroperitoneal. See Lumbar glands.
 uterine, contents of, 24.
 uterine, dichotomous branching of, 21, 24.
 uterine, frequent extension into the muscle under normal conditions, 24.
 uterine, normal, 20, 22, 24, 26.
 uterine, stems of stroma projecting from their bases, 24, 25.
- Goniometer, 216.
- Granulations in vaginal vault resembling recurrent squamous-cell carcinoma of the cervix, 98.
- Granulation tissue around silk ligatures, 98, 632.
- Hæmatocolpos, associated with adeno-carcinoma of the body of the uterus, 409.
- Hæmatometra, associated with adeno-carcinoma of the body of the uterus, 409.
- Hæmaturia, after catheterization of the ureters, 232.
 in squamous-cell carcinoma of the cervix, 134, 177.
- Hæmorrhage, after vaginal hysterectomy, 92, 270.
 causes of, in squamous-cell carcinoma of the cervix, 175.
 complicating abdominal hysterectomy, 236.
 from internal iliac vein during abdominal hysterectomy, 236.
 from uterine arteries during vaginal hysterectomy, 273.
 from venous sinuses in the endometrium, 480.
 in adeno-carcinoma of the body of the uterus, 472.
 in squamous-cell carcinoma of the cervix, 56, 61, 70, 100, 121, 134, 149, 175.
 profuse, occurring during curettage in adeno-carcinoma of the body of the uterus, 361.
 treatment of, in inoperable cases of cancer of the cervix, 279.
 uterine, completely relieved by periodic curettage, 479.

- Hardening agents, choice of, 36.
- Heredity as a cause of carcinoma of the uterus, 647, 648, 649, 650.
- Hernia, umbilical, associated with squamous-cell carcinoma of the cervix, 134.
- Hyaline degeneration of the nuclei in squamous-cell carcinoma of the cervix, 137, 138.
degeneration of the walls of the blood-vessels in endometritis, 530, 531, 532, 533.
- Hydatidiform moles, relation of, to the development of deciduoma malignum, 599.
- Hydroureter, accompanying squamous-cell carcinoma of the cervix, 130, 145, 163, 171, 269.
- Hydrosalpinx simplex, 86, 151, 468.
- Hydroureter, caused by ligation of the ureter, 245.
due to adeno-carcinoma of the cervix, 331.
due to occlusion of lower end of ureter by scar tissue, 269.
due to squamous-cell carcinoma of the cervix, 130, 135, 145, 150, 152, 165, 170, 277.
- Hygienic treatment in inoperable cases of cancer of the cervix, 279.
- Hypertrophied cervix, 185, 186.
- Hypertrophy of the uterine glands, 98, 488, 489, 490, 491, 493, 494, 500, 502.
- Hysterectomy, abdominal, 234.
as a palliative measure, 278.
injury of internal iliac vein during, 236.
preparation of patient for, 214, 215, 216, 223.
retention of urine after, 232.
- Ichthyosis uteri, 579.
- Iliac arteries, internal, edema of lower extremities following ligation of, 278.
ligation of, 237, 238, 274, 275, 276, 277, 278.
- Iliac artery, internal, branches of, 275.
- Iliac glands, and uterus as seen after radical operation for cancer of the cervix, 228.
carcinoma of, secondary to squamous-cell carcinoma of the cervix, 130, 137, 151, 158, 159, 161, 162.
removal of, in the radical operation for cancer of the cervix, 62, 228.
- Ilium, crest of, secondary involvement from squamous-cell carcinoma of the cervix, 130, 152.
- Implantation, danger of carrying malignant tissue into healthy tissue on instruments, 222, 223, 662, 663.
- Incontinence of urine, simulating vesico-vaginal fistula, 86.
- Infection, as a cause of death after hysterectomy, 248, 271.
- Inferior vena cava, thrombosis of, in squamous-cell carcinoma of the cervix, 163.
- Inguinal glands, carcinoma of, secondary to adeno-carcinoma of the body of the uterus, 423, 432.
carcinoma of, in squamous-cell carcinoma of the cervix, 134, 137, 159.
papilocystomata of, secondary to similar growths in the ovary, 466.
- Inoculation experiments bearing upon the etiology of carcinoma, 658, 660.
- Instruments for catheterization of the ureters, 216.
- Internal iliac vein, injury of, during abdominal hysterectomy, 236.
- Intestinal adhesions following vaginal hysterectomy, 274.
- Intestines, carcinoma of, secondary to squamous-cell carcinoma of the cervix, 136.
prolapse of, following vaginal hysterectomy, 261, 271, 272.
- "Inverting form" of adeno-carcinoma of the body of the uterus, 360.
- Kidney, abscess in, secondary to cancer of the uterus, 150, 165, 413.
condition of, in advanced squamous-cell carcinoma of the cervix, 130, 145, 150, 152, 163, 164, 165, 269.
metastases in, secondary to deciduoma malignum, 603.
- Knee-chest posture for catheterization of the ureters, 215, 218.
- Laceration of the cervix, 41, 187.
- Leg, gangrene of, following ligation of corresponding internal iliac artery and vein, 237.
edema of, following ligation of internal iliac arteries, 278.
edema of, in squamous-cell carcinoma of the cervix, 134.
- Ligatures, difficulty in applying, in vaginal hysterectomy, 110.
old silk, producing a picture somewhat resembling squamous-cell carcinoma of the cervix, 188.
removal of, after vaginal hysterectomy, 263.
slipping of, from broad ligament, during vaginal hysterectomy, 260, 270.
- Liver, carcinoma of, secondary to adeno-carcinoma of the body of the uterus, 414, 436, 465.
carcinoma of, secondary to adeno-carcinoma of the cervix, 330, 332.
carcinoma of, secondary to squamous-cell carcinoma of the cervix, 172.

- Liver, metastases in, from deciduoma malignum, 603.
- Lumbar lymph glands, 16, 421.
- metastases in, from squamous-cell carcinoma of the cervix, 130.
- Lung, metastases in, 136, 173, 436, 466, 602.
- Lungs, condition of, in patients dying of squamous-cell carcinoma of the cervix, 172.
- Lymph channels, extension of adeno-carcinoma of the cervix to, 317, 318.
- Lymph glands, bronchial, carcinoma of, secondary to adeno-carcinoma of the body of the uterus, 423, 432.
- enlargement of, due solely to connective-tissue-cell proliferation in carcinoma of the uterus, 421.
- extension of adeno-carcinoma of the body of the uterus to, 421.
- iliac. See under Squamous-cell carcinoma.
- inguinal, carcinoma of, secondary to adeno-carcinoma of the body of the uterus, 423, 432.
- inguinal, papillocystomata of, secondary to similar growths in the ovary, 466.
- involvement of, rare, in operable cases, 158, 422.
- lateral to the cervix (Henle), 16.
- of neck, carcinoma of, secondary to adeno-carcinoma of the body of the uterus, 424, 434.
- pelvic, carcinoma of, secondary to adeno-carcinoma of the body of the uterus, 427.
- pericardial, carcinoma of, secondary to adeno-carcinoma of the body of the uterus, 432.
- removal of, during hysterectomy for adeno-carcinoma of the body of the uterus, 575.
- Lymph spaces, carcinomatous masses in, in squamous-cell carcinoma of the cervix, 110.
- Lymph vessel, containing a mass of cancer cells, in squamous-cell carcinoma of the cervix, 112.
- Lymphatics of the body of the uterus, 15.
- of the cervix, 15.
- of the upper part of the vagina, 15.
- of the uterine horn, 15.
- of the uterus, anastomosis between those of the cervix and body, 16.
- of the uterus, arrangement of valves, 16.
- "Malignant adenoma," 304.
- Malignant deciduoma, 595.
- Menopause, normal endometrium after, 22.
- Menstrual history, in adeno-carcinoma of the body of the uterus, 473.
- in adeno-carcinoma of the cervix, 335.
- Menstrual history, in cases of squamous-cell carcinoma of the cervix, 175.
- Menstrual membrane, exfoliated, 511.
- Menstrual period, changes in endometrium at, 25.
- intact surface epithelium at, 25.
- Mesenteric glands, carcinoma of, secondary to squamous-cell carcinoma of the cervix, 137, 162.
- Mesentery, carcinoma of, secondary to adeno-carcinoma of the body of the uterus, 465.
- Mesosalpinx, extension to, from squamous-cell carcinoma of the cervix, 139.
- Metabolism in cases of squamous-cell carcinoma of the cervix, 177.
- Metastase, rückläufige*, 415.
- Metastases, following adeno-carcinoma of the body of the uterus, 435.
- in deciduoma malignum, 597.
- Miscarriages, history of, in patients suffering with squamous-cell carcinoma of the cervix, 175.
- Moles, hydatidiform, relation of, to development of deciduoma malignum, 599.
- Mucosa, cervical, 18.
- cervical, abnormal extension downward of, 179, 180.
- cervical, an apparent cell-nest due to a fold in, 183.
- cervical, eversion of, 180.
- of the body of the uterus. See Endometrium.
- Müller's fluid as a hardening agent, 4, 36, 42.
- Muscle, uterine, extension of normal glands into, 478.
- uterine, line of demarkation between it and mucosa, 24.
- Myoma, carcinoma of, secondary to adeno-carcinoma of the body of the uterus, 410, 433, 469.
- "carcinomatous degeneration" of, 410.
- diffuse adeno-myoma, 535, 537.
- sarcoma, adeno-carcinoma and uterine polypi in the same uterus, 471.
- sloughing submucous, 190.
- Myomata, associated with adeno-carcinoma of the body of the uterus, 439, 442, 451, 454, 466, 470.
- importance of determining the condition of the endometrium in cases of, 449.
- interstitial cervical, 191, 345.
- multiple uterine, associated with squamous-cell carcinoma of the cervix, 133.
- small, associated with adeno-carcinoma of the body of the uterus, 439.
- submucous cervical, 344.

- Myomata, uterine, 465, 535.
- Myomatous uterus with moderate gland hypertrophy of the endometrium, 490.
- Nabothian follicles, 8, 187, 367.
associated with adeno-carcinoma of the body of the uterus, 367.
- Neck, carcinoma of lymph glands of, secondary, to adeno-carcinoma of the body of the uterus, 434.
- Necrosis of surface of an adeno-carcinoma of the body of the uterus, 385.
- Needle, blunt aneurismal, with left curve, 258.
- Negress, adeno-carcinoma of the body in the, 475.
adeno-carcinoma of the cervix in the, 336.
squamous-cell carcinoma of the cervix in the, 178.
- Nephritis, associated with squamous-cell carcinoma of the cervix, 152, 164.
- Nerves, motor, of the uterus, 14.
sacral plexus, 12.
sympathetic, of the uterus, 14.
- Nuclear changes in squamous-cell carcinoma of the cervix, 48, 54, 137, 138, 139.
- Nuclei, large lamellated, in adeno-carcinoma of the body of the uterus, 446, 447.
- Œdema, in the lower extremities following ligation of the internal iliac arteries, 278.
of the extremities in advanced squamous-cell carcinoma of the cervix, 134, 178.
- Omentum, carcinoma of, secondary to adeno-carcinoma of the body of the uterus, 431, 435, 465.
- Operation for diagnosis, 27.
- Outgrowth from the surface of the mucosa in endometritis of the body of the uterus, 521, 523.
- Ovarian abscess with squamous-cell carcinoma of the cervix, 130.
- Ovarian artery, anastomosis of, 11.
course of, 11.
origin from accessory renal artery, 13.
origin from aorta, 13.
- Ovarian vein emptying into inferior vena cava, 13.
emptying into renal vein, 13.
- Ovarian vessels, relations to the ureters, 13.
- Ovaries, condition of, in adeno-carcinoma of the body of the uterus, 437.
condition of, in adeno-carcinoma of the cervix, 327.
condition of, in squamous-cell carcinoma of the cervix, 153.
- Ovaries, removal of, during vaginal hysterectomy, 260.
- Ovaries and tubes, advisability of their removal with the uterus in adeno-carcinoma of the body, 574.
- Ovary, adeno-carcinoma of, with extension to the cervix, 323, 324.
angio-sarcoma of, with extension to the body of the uterus, 559.
carcinoma of, secondary to adeno-carcinoma of the body of the uterus, 437.
carcinoma of, secondary to squamous-cell carcinoma of the cervix, 140, 155.
carcinoma of, with secondary growths in the uterus, 438.
corpus luteum cyst of, associated with squamous-cell carcinoma of the cervix, 155.
dermoid cyst of, associated with squamous-cell carcinoma of the cervix, 155, 241.
metastases in, secondary to deciduoma malignum, 602.
papilocystomata of, associated with adeno-carcinoma of the body of the uterus, 466.
papilocystomata of, suggested by adeno-carcinoma of the body of the uterus, 400, 419.
papilloma of, 74, 155, 661.
sarcoma of, with a secondary growth in the body of the uterus, 556, 560.
tuberculous abscess of, 568.
- Pain, in adeno-carcinoma of the body of the uterus, 474.
in adeno-carcinoma of the cervix, 336.
in carcinoma of the uterus, 626.
in squamous-cell carcinoma of the cervix, 176.
- Palliative treatment in carcinoma of the cervix, 278.
- Pancreas, carcinoma of, secondary to adeno-carcinoma of the body of the uterus, 467.
- Papillary growth transplanted to abdominal wall by trocar introduced to relieve ascites, 662, 663.
- Papilocystomata of both ovaries with metastases in inguinal glands, 466.
of the ovaries associated with adeno-carcinoma of the uterus, 466.
of the ovary with adhesions to intestinal loops, 465.
- Papilloma of the ovary, associated with squamous-cell carcinoma of the cervix, 74, 155.
histologically simulated by adeno-carcinoma of the body of the uterus, 400.
implanted into abdominal wall by trocar, 223.
- Papillomata of the ovaries with ascites, 661, 662, 663.

- Parasitic origin of cancer, 655, 657.
- Parovarian cyst, associated with adeno-carcinoma of the body of the uterus, 386.
- Pearls, epithelial, in squamous-cell carcinoma of the cervix, 48, 49.
- Pelvic bones, carcinoma of, secondary to squamous-cell carcinoma of the cervix, 152.
- Pelvic contents, relations of, 7, 10, 13.
- Pelvic veins, thrombosis of, in squamous-cell carcinoma of the cervix, 163.
- Pericardial lymph glands, carcinoma of, secondary to adeno-carcinoma of the body of the uterus, 432.
- Perinaeum, incisions in, to obtain necessary space in vaginal hysterectomy for adeno-carcinoma of the body of the uterus, 223, 266, 267, 361, 386, 390, 663.
- Peritoneal cavity, accidental opening into, during curettage, 279, 303, 313.
- danger of accidentally opening into, during bimanual examination in late stages of squamous-cell carcinoma of the cervix, 168.
- Peritoneum, carcinoma of, secondary to adeno-carcinoma of the body of the uterus, 431, 435, 466.
- carcinoma of, secondary to squamous-cell carcinoma of the cervix, 137.
- Peritonitis, fatal, following prolapse of bowel into vagina after vaginal hysterectomy, 261.
- fibrino-purulent, as a result of advanced adeno-carcinoma of the body of the uterus, 413.
- following abdominal hysterectomy, 241, 453.
- tuberculous, 564.
- Phlebitis in leg following vaginal hysterectomy, 403.
- Physometra, commencing in squamous-cell carcinoma of the cervix, 117.
- Placenta, retained, 500, 501.
- Placental giant cells, so-called, 496, 499.
- Pleurae, carcinoma of, secondary to adeno-carcinoma of the body of the uterus, 436, 466.
- carcinoma of, secondary to squamous-cell carcinoma of the cervix, 136.
- Polyp, cervical, 70, 189, 339, 341, 342, 343, 344.
- uterine, containing adeno-carcinoma, secondary to adeno-carcinoma of the cervix, 309.
- uterine, containing giant cells in the wall of a dilated gland, 487.
- Polypi, adeno-carcinoma of the body of the uterus developing from the tips of, 448.
- sarcoma, adeno-carcinoma and myoma in the same uterus, 471.
- uterine, 123, 309, 471, 481, 482, 484, 485, 487.
- uterine, adeno-carcinoma of the body of the uterus developing from, 355.
- Polypoid endometritis, 514, 515, 516.
- Polypoid formation, in adeno-carcinoma of the body of the uterus, 455; of endometrium, 482.
- Porro operation, when advanced carcinoma of the cervix and pregnancy coexist, 618.
- Pregnancy, and adeno-carcinoma of the body of the uterus, 473.
- and carcinoma of the cervix, operations employed in the early months, 614.
- as a factor in the causation of adeno-carcinoma of the body of the uterus, 652.
- characteristic changes occurring in the endometrium during, 495.
- complicating carcinoma of the cervix, 611, 613, 615, 618, 619, 620.
- effect of, on the growth of carcinoma of the cervix, 613, 624.
- extra-uterine, condition of the uterine mucosa in, 509.
- gland hypertrophy in, 500, 502.
- in carcinoma of the cervix, treatment of, in the later months, 615.
- in rudimentary uterine horn with typical decidua in the unimpregnated uterus, 510.
- simulated by pyometra, occurring in adeno-carcinoma of the cervix, 313.
- stellate laceration of the cervix in, 187.
- unruptured tubal, with normal uterine mucosa, 510.
- Prognosis, in adeno-carcinoma of the body of the uterus, 642, 645.
- in carcinoma of the uterus, 631, 646.
- in cases of adeno-carcinoma of the cervix, 327, 641.
- in deciduoma malignum, 599.
- in squamous-cell carcinoma of the cervix, 98, 632, 638, 639, 640.
- Prolapse of Fallopian tube into vagina after vaginal hysterectomy, 265, 632.
- of intestine following vaginal hysterectomy, 261, 271.
- Prolapsus accompanied by ulceration of the cervix, 183.
- and squamous-cell carcinoma of the cervix, 120.
- Purulent discharge, in carcinoma of the uterus, 625.
- Purulent peritonitis, secondary to squamous-cell carcinoma of the cervix, 130.
- Pyometra, and physometra in squamous-cell carcinoma of the cervix, 116.
- associated with adeno-carcinoma of the cervix, 311, 312, 313.
- cause of, in squamous-cell carcinoma of the cervix, 115, 116.

- Pyometra, clinically somewhat resembling pregnancy, 313.
 developing in adeno-carcinoma of the body of the uterus, 409, 413.
 in squamous-cell carcinoma of the cervix, 114, 116, 117, 167, 243.
- Pyonephrosis, 152, 164, 269.
 associated with squamous-cell carcinoma of the cervix, 152, 164.
- Pyoureter, 150, 152, 269.
 associated with squamous-cell carcinoma of the cervix, 150, 152.
- Radical methods of removing the uterus, 212, 213, 225, 230.
- Rapid diagnosis from uterine tissues, 29.
- Rectoscope, as an aid to diagnosis in suspected carcinoma of the rectum, 148.
- Recto-vaginal fistula, 150, 269, 274, 331, 383.
- Recto-vaginal septum, extension to, in squamous-cell carcinoma of the cervix, 99.
- Rectum, accidental removal of portion of, during vaginal hysterectomy, 268.
 carcinoma of, secondary to adeno-carcinoma of the cervix, 319, 327, 331.
 carcinoma of, secondary to squamous-cell carcinoma of the cervix, 139, 141, 146, 148, 151, 168.
 perforation of, in adeno-carcinoma of the cervix, 331.
 separation of, from the vagina in Werder's operation, 229.
- Recurrence in carcinoma of the uterus, 632.
- Recurrence of carcinoma, simulated, 98, 632.
- Retro-peritoneal glands, carcinoma of, secondary to squamous-cell carcinoma of the cervix, 138, 159.
- Ribbert's theory, 653, 654.
- Ries's radical method for removal of the uterus, 212.
- Round-cell sarcoma of the body of the uterus, 548, 550, 552, 553.
- Round ligament, adeno-myoma of, 575, 576.
 carcinoma of, secondary to adeno-carcinoma of the body of the uterus, 422.
- Rückläufige Metastase*, 415.
- Rumpf's radical method of removing uterus, 213.
- Salt solution, enema to prevent thirst after abdominal operation, 230.
 infusion under breast during abdominal hysterectomy, 234.
 transfusion of, into radial artery followed by sloughs in arm and forearm, 298.
- Sarcoma, adeno-carcinoma, myoma, and uterine polypi in the same uterus, 471.
 and adeno-carcinoma of the body of the uterus, 471.
 angio-, closely simulated by finger-like outgrowths in squamous-cell carcinoma of the cervix, 84.
 angio-, of ovary with extension to the body of the uterus, 559.
 of the body of the uterus, 547, 548, 549, 550, 552, 553, 554, 555, 556, 557, 560.
 of the body of the uterus, differential diagnosis from adeno-carcinoma of the body of the uterus, 549.
 of the cervix, 198, 199, 200, 201, 202, 206.
 of the ovary with secondary growth in the body of the uterus, 556, 560.
 uteri deciduo-cellulare, 595.
- Scar tissue, small tags of, on the cervix, 187.
- Scirrhus squamous-cell carcinoma of the cervix, 108, 109, 141.
- Scrapings, errors in diagnosis due to want of care in labelling, 33.
 from a tuberculous cervix, 566.
 from which adeno-carcinoma of the body of the uterus was diagnosed, 358, 362, 372, 376, 392, 441.
 suggesting adeno-carcinoma of the body of the uterus, owing to imperfect hardening, 477.
 suspicious, but benign area from, 571.
 uterine, method of studying, 33.
- Searcher, ureteral, 216.
- Silk ligatures, granulation tissue around, simulating recurrence in the vaginal vault, 98, 632.
- Silk, sizes used during vaginal hysterectomy, 254.
- Sloughing submucous myoma, with clinical symptoms suggesting squamous-cell carcinoma of the cervix, 190.
- Space, the clear, 225.
- Spindle-cell sarcoma of the body of the uterus, 549, 554.
- Spleen, metastases in, secondary to deciduoma malignum, 603.
- Squamous-cell carcinoma and adeno-carcinoma of the body of the uterus in the same individual, 470.
- Squamous-cell carcinoma of the cervix, 40, 41, 45, 46, 51, 55, 56, 60, 75, 80, 85, 167, 205, 207, 208.
 abscess in cellular tissue between uterus and rectum, 70.
 abscesses in kidney, 150, 165.
 abundant blood supply along advancing margin, 53.

- Squamous-cell carcinoma of the cervix, advanced, 266, 267, 639.
- advanced, condition of kidneys in, 163.
- advancing margin of, 45.
- age of patient, 174.
- analysis of successful cases, 638.
- appearance of body at autopsy, 162.
- appearance of necrotic cervix a few days after curettage, 130.
- appearance on cut section, 43.
- appearances of individual cancer-cells, 48.
- associated with chronic diffuse nephritis, 152.
- associated with commencing tuberculosis of Fallopian tubes, 123.
- associated with cyst in adrenal gland, 152.
- associated with diphtheric cystitis, 132.
- associated with œdema of leg, 134.
- associated with prolapsus, 120.
- associated with small papilloma of ovary, 74, 155.
- associated with tuberculous peritonitis, 122.
- autopsy in cases of, 640.
- average number of pregnancies in cases of, 174.
- bedsores in, 163.
- cartilaginous consistence of, 44.
- cauliflower outgrowth, 41, 42, 43, 55, 62, 63, 64, 66, 67, 70, 71, 72, 73, 74, 82, 88, 97, 129, 237, 265, 276.
- cell changes in, 54, 89, 137, 138.
- cell degeneration in, 54.
- cell-nests in, 53, 102, 151.
- cell-nests showing disintegration in, 53.
- cells containing large irregular masses of chromatin in, 96.
- cervical polyp in, 70, 92.
- changes in nuclei, 48, 54, 137, 138, 139.
- clinical differentiation from submucous myomata, 189, 190.
- clinically simulated by inflammation of the cervix due to old silk ligatures, 188.
- cloaca in, 149.
- condition of, following ligation of the left internal iliac vein and both internal iliac arteries, 238.
- condition of lungs in, at autopsy, 172.
- condition of ovaries in, 153.
- condition of patient in first stage of, 175.
- condition of squamous epithelium along outer edge of growth, 46.
- condition of tubes in, 153.
- condition of uterine mucosa in, 113.
- containing epithelial pearls, 48, 49.
- containing giant cells, 48, 95, 105, 106, 113, 118, 139.
- containing small abscesses, 44.
- Squamous-cell carcinoma of the cervix, convulsions before death in, 145.
- corpus-luteum cyst of right ovary in, 155.
- crater-like cavity in, 45, 143, 150, 160.
- curettage in inoperable cases in, 278.
- cystitis in, 132.
- danger of accidentally opening peritoneal cavity during bimanual examination in late stage, 168.
- death with signs of uræmia, 141, 145.
- decidual cells in the stroma of the cervix in pregnancy in, 622.
- dermoid cyst of ovary in, 155, 241.
- different sizes of cells in, 209.
- differential diagnosis, 179, 207.
- difficilty in clinically diagnosing, 87, 199.
- discharge in, 45, 175, 177.
- earliest changes in surface epithelium, 47, 57.
- excoriation of genitals in, 208.
- extension along surface of the endometrium in the body of the uterus in, 586.
- extension to and erosion of crest of ilium in, 130, 152.
- extension to bladder in, 99, 131, 135, 141, 144, 146, 147, 151, 164.
- extension to body of uterus, 45, 584, 623.
- extension to broad ligament, 60, 65, 66, 94, 100, 101, 105, 124, 139, 142, 150, 221, 240, 250, 251, 276, 277.
- extension to glands of cervix in, 48, 59, 93.
- extension to recto-vaginal septum in, 99.
- extension to rectum in, 139, 141, 146, 148, 151, 168.
- extension to right broad ligament preventing passage of the ureteral bougie in, 73, 220.
- extension to vagina, 44, 45, 65, 66, 73, 86, 94, 111, 125, 127, 138, 156, 164, 207, 221, 240, 620.
- finger-like outgrowths in, 41, 45, 50, 51, 54, 64, 68, 81, 84, 91, 103, 128.
- from location suggesting adeno-carcinoma, 208.
- gland hypertrophy of the endometrium in, 75, 98, 114.
- granulations in vaginal vault resembling return of, 98, 632.
- gross differences from adeno-carcinoma of the cervix, 347.
- hæmaturia in, 134, 177.
- hæmorrhage into the bladder in, 132.
- hæmorrhages in, 56, 61, 134, 175.
- heredity in, 649.
- histological appearances of necrotic surface, 53.

- Squamous-cell carcinoma of the cervix, histological differences, from adeno-carcinoma of the cervix, 348.
- histological differences, from endothelioma of the cervix, 210.
- histological resemblance to adeno-carcinoma, 167.
- hyaline degeneration of nuclei in, 139.
- hydronephrosis in, 130, 145, 163, 171, 269.
- hydrosalpinx in, 86, 151.
- hydroureter, 130, 135, 145, 150, 152, 165, 170, 277.
- iliac glands, removal of, in, 62, 228.
- illustrative cases, 55.
- immediate causes of death in, 178.
- in the coloured race, 178.
- increase of chromatin in, 49, 96.
- inflammation of colon in, 148.
- involvement of a uterine gland in, 119.
- involvement of lymph glands in, 158, 159, 161.
- involvement of urethra in, 152.
- involving the mesosalpinx, 139.
- involving the pelvic bones, 130, 152.
- isolated nodule in the body of the uterus in, 114.
- late stage, 168.
- ligation of internal iliac artery in, 237, 238, 274, 275, 276, 277.
- ligation of uterine arteries and veins in, 251.
- menstrual history in cases of, 175.
- metabolism in, 177.
- metastases in bronchial lymph glands, 136, 159.
- metastases in iliac lymph glands, 130, 137, 151, 158, 159, 161, 162.
- metastases in inguinal glands, 134, 137, 159.
- metastases in lumbar glands, 130.
- metastases in lymph glands, 158.
- metastases in mesenteric glands, 137, 158, 162.
- metastases in the retroperitoneal glands, 138, 159.
- multiple myomata in, 133.
- myoma invaded in, 133, 136.
- nephritis in, 152, 164.
- normal nuclear division in, 99.
- nuclear figures in, 48, 99.
- cedema of extremities in, 178.
- omental adhesions attached to body of uterus, 80.
- ovarian abscess with, 130.
- pain in, 176.
- palliative treatment of, 278.
- partial obliteration of glands of cervix in, 59, 93.
- prognosis, 632.
- Squamous-cell carcinoma of the cervix, purulent peritonitis in, 130.
- pyo- and physometra in, 116.
- pyometra in, 114, 116, 117, 167, 243.
- pyonephrosis in, 152, 164.
- pyoureter in, 150, 152.
- recto-vaginal fistula in, 150.
- resembling adeno-carcinoma, due to partial dropping out of cell-nests, 104, 131.
- resembling sarcoma, 206.
- rupture of bladder during dissection of, 240.
- scheme illustrating method of development, 52.
- scirrhus, 108, 109, 141.
- secondary growths in liver in, 172.
- secondary growths in lungs in, 136, 173.
- secondary growths in the ovary in, 140, 155.
- secondary growths in the pleuræ in, 136.
- secondary nodules in Fallopian tube in, 139, 157.
- secondary nodules in the peritoneum in, 137.
- secondary nodules in the stomach in, 138.
- secondary nodules on the intestines in, 136.
- secondary nodules, removal of, in, 82.
- sieve-like arrangement of stroma in, 43.
- simulated by adeno-carcinoma of the cervix where gland epithelium formed solid nests, 321.
- simulated by distorted but normal squamous epithelium of vaginal portion, 184.
- simulated by lacerated cervix in pregnancy, 188.
- simulated by solid nests in adeno-carcinoma of the body of the uterus, 450.
- small cyst of ovary with, 94.
- stages of, 41, 43, 54, 56, 175, 176, 177.
- stimulated to increased activity by pregnancy, 624.
- summary of cases of, 640.
- surrounding both ureters, 240.
- suspicious changes about margin of growth, 46, 57.
- symptoms of, 175, 177.
- tearing off of body during abdominal hysterectomy for, 235.
- thickening of the vaginal epithelium in the vicinity of, 585.
- thrombosis of inferior vena cava in, 163.
- thrombosis of the pelvic veins in, 163.
- transition of normal into carcinomatous epithelium, 58.
- trauma as a cause of, 651.
- treatment of, 211.
- tuberculous uterus in, 122.
- uretero-vaginal fistula in, 177.

- Squamous-cell carcinoma of the cervix, vaginal examination in, 45, 175, 176, 177.
- vesico-vaginal fistula as a result of operation, 82.
- vesico-vaginal fistula with, 132, 146, 147, 164, 168.
- Squamous-cell carcinoma, primary, of the body of the uterus, 578.
- simulated by thickening of the surface epithelium in endometritis of the body of the uterus, 526.
- Squamous epithelium, apparent in the uterine cavity in endometritis, 525, 528, 530.
- in the body of the uterus, 578.
- of the cervix, distorted so as to resemble squamous-cell carcinoma, 184.
- simulated by proliferated gland epithelium in adeno-carcinoma of the body of the uterus, 382.
- simulated by proliferated surface epithelium of the endometrium, 528, 530.
- simulated by proliferated surface epithelium in adeno-carcinoma of the body of the uterus, 371, 374, 381.
- Staining and mounting of sections, 38.
- Stomach, carcinoma of, secondary to squamous-cell carcinoma of the cervix, 138.
- Stroma, in squamous-cell carcinoma of the cervix, 51.
- Submucous cervical myomata, 189.
- Supraphrenic abscess, following adeno-carcinoma of the body of the uterus, 413.
- Symptoms common to all varieties of carcinoma of the uterus, 625.
- due to escape of urine into abdominal cavity, 429.
- in adeno-carcinoma of the body of the uterus, 472.
- initial, in adeno-carcinoma of the cervix, 335.
- in squamous-cell carcinoma of the cervix, 174.
- in tuberculosis of the endometrium, 563.
- Synechial buds, 499.
- mass invading venous channel in deciduoma malignum, 606.
- ribbons in deciduoma malignum, simulated by adeno-carcinoma of the body of the uterus, 458.
- Syphilis of the cervix, 191, 192.
- Tags of scar tissue on the cervix, 187.
- Technique, 37, 38, 104.
- Temperature, slight elevation of, after hysterectomy, 232.
- Tenaculum, blunt, for catching ligatures, 260.
- Thirst, after abdominal operations, 230.
- Thrombosis of the femoral vein, following abdominal hysterectomy for carcinoma of the cervix, 63.
- Transfusion of salt solution into radial artery, followed by sloughs in arm and forearm, 298.
- Transplantation, carcinoma developing in the abdominal wall along the course of a trocar puncture due to, 661.
- Trauma as a cause of cancer, 651, 652.
- Treatment, following hysterectomy, 233, 262.
- of adeno-carcinoma of the body of the uterus, 573.
- of adeno-carcinoma of the cervix, 337.
- of carcinoma of the cervix in pregnancy, 613, 615, 617.
- of deciduoma malignum, 599.
- of squamous-cell carcinoma of the cervix, 211, 278.
- palliative, in carcinoma of the cervix, 278.
- Tree-like outgrowth in adeno-carcinoma of the body of the uterus, 357, 372, 374.
- Tubal pregnancy, 509, 510.
- unruptured, with normal uterine mucosa, 510.
- Tuberculosis, and condylomata of the cervix, 195, 196, 197.
- of the cervix, 193, 346, 566.
- of the endometrium, 197, 532, 561, 563, 565, 568, 570.
- of the endometrium, symptoms of, 563.
- of the Fallopian tubes, 123, 197, 564, 567.
- of the Fallopian tubes and squamous-cell carcinoma of the cervix, 123.
- of the uterus and squamous-cell carcinoma of the cervix, 121.
- Tuberculous abscess of the ovary, 568.
- peritonitis associated with squamous-cell carcinoma of the cervix, 122.
- Tubo-ovarian abscess associated with adeno-carcinoma of the cervix, 298.
- cyst, occurring in cases of adeno-carcinoma of the cervix, 296.
- Ulcer of the cervix, 181.
- Ulceration of the cervix, 180, 181.
- of the cervix due to prolapsus, 183.
- of the cervix, syphilitic, 191.
- Umbilical hernia associated with squamous-cell carcinoma of the cervix, 134.
- Uræmia, death from, in squamous-cell carcinoma of the cervix, 141.
- due to ligation of the ureter, 245.
- from occlusion of the lower end of ureter, 269.
- Ureter, accidental ligation of, during abdominal hysterectomy, 245, 249, 270.

- Ureter, anastomosis into bladder, 248, 427.
 catheterization of, 73, 212, 218, 219, 221.
 constriction of, by ligature during vaginal hysterectomy, 126.
 course of, in the pelvis, 14.
 dilatation of, in squamous-cell carcinoma of the cervix, 165.
 exploratory incision into, to determine whether included in the ligature, 588.
 dissection of, out of carcinomatous tissue, 276.
 double, 330, 331.
 hæmaturia following catheterization of, 232.
 hydro-, associated with carcinoma of the cervix, 130, 135, 145, 150, 152, 170, 277, 330, 331.
 hydro-, following occlusion of lower end of ureter in scar tissue, 269.
 injury of, during hysterectomy, 245, 270, 287.
 lateral anastomosis of, 248.
 ligation of, as cause of death following hysterectomy, 245, 248, 271.
 ligation of, followed by development of uretero-vaginal fistula, 271.
 location of, during an abdominal operation, 10.
 method of detecting whether it is tied or not, 245.
 occlusion of, due to scar tissue around vesical orifice, 269.
 partial constriction of, by ovarian vein, 171.
 position of, at pelvic brim, 10.
 pyo-, 269.
 pyo-, associated with squamous-cell carcinoma of the cervix, 150, 152.
 relation of, to other structures, 10, 11, 13.
 surrounded by squamous-cell carcinoma of the cervix, 240.
 treatment of injured, 245.
 turning fistulous opening into bladder, 248, 428, 429.
 vesical orifice of, 9.
- Ureteral anastomosis, facilitated by freeing bladder from symphysis, 288.
 bougie, accidental breaking of, during vaginal hysterectomy, 110, 270.
 catheterization, 212, 218, 219.
 catheterization, obstruction to, 73, 221.
 end-to-end anastomosis, 248.
 incision, closure by mattress sutures, 588.
 instruments, sterilization of, 216.
 mons, 220.
 mound, 220.
 orifices, 217, 220.
 searcher, 216.
- Uretero-cystostomy after uretero-vaginal fistula, 287, 288.
- Uretero-ureteral anastomosis, 246, 247, 248.
 Uretero-vaginal fistula, after hysterectomy, 270, 287, 427.
 Uretero-vaginal fistula, in advanced cases of squamous-cell carcinoma of the cervix, 177.
 Urethra, carcinoma of, secondary to squamous-cell carcinoma of the cervix, 152.
 inner orifice of, 9, 217.
 Urethral dilator, 214.
 Urine, after abdominal hysterectomy, 232.
 blood in, in advanced cases of squamous-cell carcinoma of the cervix, 134, 177.
 escape of, into abdominal cavity with alarming symptoms, 429.
 incontinence of, simulating vesico-vaginal fistula, 86.
 retention of, after abdominal hysterectomy, 232.
- Uterine artery, anastomoses of, 11, 14.
 branches of, 11, 12, 14.
 course of, 9, 11, 12.
 dissection of, in abdominal hysterectomy, 226.
 hæmorrhage from, during vaginal hysterectomy, 110, 273, 286.
 ligation of, in abdominal hysterectomy, 227, 238.
 ligation of, in squamous-cell carcinoma of the cervix, 251.
 method of distinguishing, during vaginal hysterectomy, 259.
 relation of, to the ureter, 11.
 size of, during pregnancy, 14.
- Uterine calculi, associated with adeno-carcinoma of the body of the uterus, 411, 412.
 Uterine cavity, measurements of, 8.
 shape of, 8.
 transition into cervical canal, 8.
- Uterine, eurettes, 28, 29.
 dilators, 28.
 glands, contents of, 24.
 glands, dichotomous branching of, 21, 24.
 glands, hypertrophy of, 488, 489, 490, 491, 493, 494, 500, 502.
 glands, normal, 21, 22, 26, 478.
 glands, normal extension of, into uterine muscle, 24, 477, 478.
 glands, normal schematic representation of, 22.
 glands, nuclear figures in epithelium of, 24, 26.
 glands, passive involvement of, in squamous-cell carcinoma of the cervix, 119.
 glands, stems of stroma projecting from the bases of, 22, 24, 25.
 hæmorrhages, in adeno-carcinoma of the body of the uterus, 472.

- Uterine horn, carcinoma of, secondary to adenocarcinoma of the cervix, 310.
- horn, lymphatics of, 15.
- horn, sarcoma of, secondary to sarcoma of the body, 554.
- lymphatics, valves of, 16.
- mucosa, blood supply of, 14.
- mucosa. See also Endometrium.
- mucosa, colour of, 8; delicacy of, 34.
- mucosa, condition of, in adenocarcinoma of the cervix, 318.
- mucosa, condition of, in squamous-cell carcinoma of the cervix, 113.
- mucosa, gross appearance of glands of, 8.
- mucosa, in extra-uterine pregnancy, 509, 510.
- mucosa, isolated carcinomatous nodule in, in squamous-cell carcinoma of cervix, 114.
- mucosa, removal of, for diagnosis, 38.
- mucosa, thickness of, 8.
- mucosa, veins in, 14.
- myomata, 535.
- polyp, 481, 482, 484, 485.
- polyp, with dilated glands containing giant cells in its wall, 487.
- polypi, adenocarcinoma of the body of the uterus developing from, 355.
- polypi, in a case of myoma, 484.
- polypi, sarcoma, adenocarcinoma, and myoma in the same uterus, 471.
- scrapings, systematic examination of, 31.
- veins, 11, 14.
- veins, ligation of, in squamous-cell carcinoma of the cervix, 251.
- wall, penetration of entire thickness of, by adenocarcinoma of the body of the uterus, 394.
- Uterus, an abdominal organ in the child, 8.
- anatomy of, 5.
- and iliac glands, as seen after abdominal hysterectomy, 228.
- and vagina, partial prolapse of, with elongated and lacerated cervix, 255.
- appearance of, after enucleation in vaginal hysterectomy, 254.
- blood supply of, 11, 14.
- carcinoma appearing simultaneously in the cervix and body of, 592.
- distance of, from promontory of sacrum, 10.
- fixed attachment of, 8.
- lymphatics of, 15.
- measurements of, 6.
- method of opening, 34, 35.
- motor nerves of, 14.
- muscular layers of, 6.
- myomatous, choking pelvis, 465.
- Uterus, normal, laid open, 6.
- perforation of, following adenocarcinoma of the body, 413.
- peritoneal covering of, 9.
- points to be noted in description of, 35, 39.
- primary squamous-cell carcinoma of the body of, 578.
- radical methods of removing, 212, 213, 230.
- relations of, on longitudinal section, 5.
- sarcoma of the body of, 547, 548, 549, 550, 552, 553, 554.
- sarcoma of the body of, secondary to angiosarcoma of the ovary, 559, 560.
- sarcoma of the body of, with protrusion through the external os, 557.
- secondary carcinoma of the body of, 438.
- smaller than normal, in a case of adenocarcinoma of the body, 373.
- squamous epithelium in the body of, 578.
- sympathetic nerves of, 14.
- tuberculosis of, 193, 561.
- Vagina, adenocarcinoma of, secondary to adenocarcinoma of the body of the uterus, 414, 417.
- carcinoma of, due to implantation, 223, 663.
- carcinoma of, secondary to adenocarcinoma of the cervix, 297, 303, 305, 312, 315, 319, 326, 330.
- carcinoma of, secondary to squamous-cell carcinoma of the cervix, 41, 45, 65, 66, 73, 86, 94, 111, 125, 127, 138, 156, 164, 207, 221, 240, 620.
- lateral incisions into, to obtain space during vaginal hysterectomy, 254, 266, 267, 361, 386, 390.
- lymphatics of upper part of, 15.
- metastases in, secondary to deciduoma malignum, 601.
- sarcoma of, secondary to sarcoma of the cervix, 199.
- separation of, from bladder in Werder's operation, 229.
- separation of, from rectum in Werder's operation, 229.
- Vaginal atresia, associated with adenocarcinoma of the body of the uterus, 409.
- douche after vaginal hysterectomy, 263.
- epithelium, thickening of, in the neighbourhood of squamous-cell carcinoma of the cervix, 585.
- examinations, in squamous-cell carcinoma of the cervix, 43, 176, 177.
- Vaginal hysterectomy, 253, 576, 615.
- accidental ligation of ureter during, 270, 271.

- Vaginal hysterectomy, accidental removal of portions of bladder and rectum during, 268.
 adhesions of intestinal loops to pelvic floor following, 274.
 advantage of, in later months of pregnancy, for carcinoma of the cervix, 615.
 aneurismal needle usually employed in, 258.
 appearance of vault several weeks after operation, 264.
 application of ligatures to the broad ligament, 110, 257, 270.
 causes of death after, 271.
 fecal fistula in vaginal vault following, 274.
 hæmorrhage following, 92, 110, 111, 270, 286.
 hæmorrhage from right broad ligament during, 111.
 importance of periodic examinations following, 264.
 in adeno-carcinoma of the body of the uterus, 573, 576.
 infection following, 271.
 injury to bladder during, 265, 267, 287.
 injury to ureters during, 270, 287.
 lateral incisions in perinaum on account of small outlet in, 254, 266, 267, 361, 386, 390.
 preparation of patient for, 253.
 prolapse of Fallopian tube after, 265.
 prolapse of intestine following, 261, 271.
 remote sequelæ of, 274.
 removal of drain after, 263.
 removal of inflamed appendages during, 260.
 removal of ligatures after, 263.
 tearing away of the cervix during, 266, 267.
 thrombosis of veins of the leg following, 403.
 treatment after, 262.
 various steps of, 256-264.
- Vaginal metastases, in deciduoma malignum, 607.
 mucosa, containing isolated nodules, in squamous-cell carcinoma of the cervix, 45.
 pack applied after vaginal hysterectomy, 260.
 portion of cervix, thickening of, due to dilatation of cervical glands, 186.
 vault, appearance of, several weeks after vaginal hysterectomy, 264.
 vault, recurrence in, simulated by granulation tissue around silk ligatures, 98, 632.
- Vein, adeno-carcinoma of cervix growing into, 314, 317.
 injury to internal iliac, during abdominal hysterectomy, 236.
 thrombosis of femoral, following abdominal hysterectomy for squamous-cell carcinoma of the cervix, 63.
- Veins, of endometrium, 14, 25, 26.
 of leg, thrombosis of, following vaginal hysterectomy, 403.
 ovarian, emptying into inferior vena cava, 13.
 ovarian, emptying into renal vein, 13.
 pelvic, thrombosis of, in squamous-cell carcinoma of the cervix, 163.
 uterine, 11, 14.
 uterine, ligation of, in squamous-cell carcinoma of the cervix, 251.
 vaginal, as a source of hæmorrhage during hysterectomy, 11.
- Vena cava, inferior, thrombosis of, in squamous-cell carcinoma of the cervix, 163.
- Venous channel, syncytial mass invading, in deciduoma malignum, 606.
 sinuses, in uterine mucosa, causing free hæmorrhages, 480.
 trunks of lower abdomen, 13.
- Vesico-uterine septum, accidental puncture of, during enurettage, 313.
- Vesico-vaginal fistula, caused by squamous-cell carcinoma of the cervix, 132, 146, 147, 164, 168.
 fistula, due to removal of vaginal carcinoma, 82.
 fistula, following hysterectomy, 269, 276.
 fistula, suggested by incontinence of urine, 86.
- Villi of placenta retained for several weeks, 501.
- Watery discharge in carcinoma of the uterus, 625.
- Werder's operation, 225, 231, 232.
- Worry as a cause of uterine hæmorrhage in squamous-cell carcinoma of the cervix, 149.
- Zinc paste in the treatment of cancer of the cervix, 279.



